

MANUAL
OF
OPERATIVE SURGERY

Lane Medical Library

BY

JOSEPH D. BRYANT, M. D.

PROFESSOR OF ANATOMY AND CLINICAL SURGERY, AND ASSOCIATE PROFESSOR OF ORTHOPEDIC SURGERY, BELLEVUE HOSPITAL MEDICAL COLLEGE; VISITING SURGEON TO BELLEVUE HOSPITAL; CONSULTING SURGEON TO THE BUREAU OF MEDICAL AND SURGICAL RELIEF, OF BELLEVUE HOSPITAL; CONSULTING SURGEON TO THE NEW YORK LUNATIC ASYLUM, AND TO THE NORTHWESTERN DISPENSARY.

WITH ABOUT EIGHT HUNDRED ILLUSTRATIONS



NEW YORK
D. APPLETON AND COMPANY

1887

K

WASSEL : 37A1

COPYRIGHT, 1886,
BY D. APPLETON AND COMPANY.

All rights reserved.

M32
B915
1886

TO
STEPHEN SMITH, M. D.
AND
TO MY PRECEPTOR
GEORGE W. AVERY, M. D.

This Volume

IS RESPECTFULLY INSCRIBED
THOUGH BUT A MEAGER RECOGNITION OF THE MANY KINDNESSES
SHOWN BY THEM TO
THE AUTHOR



P R E F A C E .

THE frequent request on the part of those whom it has been my pleasure to instruct in operative surgery during the past few years, to make a book based somewhat on the plan I have employed in teaching this subject, is the principal incentive to my action. The field of operative surgery is too well cultivated already for one to do more in this brief space than aid the student of surgery to acquire established facts. The works of Ashhurst, Agnew, Gross, Erichsen, Holmes, Smith, Esmarch, Packard, Stimson, and many others, together with the current medical literature, have been consulted. The illustrations, which are numerous, have been selected in most instances from standard works, although a considerable number of original and modified illustrations have been introduced. Mr. W. F. Ford, of the reputable firm of Caswell, Hazard & Co., of this city, kindly provided the instrumental cuts, as is to be seen by the "Index of Illustrations." The author desires to acknowledge the aid derived from the above-mentioned sources, and trusts the reader will find something to commend in the pages that are to follow. The author regrets that sufficient data are not at hand to permit the "results" to be given in all instances as modified by the antiseptic method of treatment. The operations peculiar to the female sex, and the eye and ear, have not been considered, since they are entitled, in the opinion of the author, to a more extended consideration than the intentional scope of this work will admit. The author desires to acknowledge the valuable services of Drs. Glover, C. Arnold, and Herman M. Biggs, in connection with the proof-reading, and of Dr. Arnold also for the complete indices of the book. The assistance of Dr. A. H. Doty in preparing many of the original illustrations is likewise gratefully acknowledged.

JOSEPH D. BRYANT, M. D.

66 W. THIRTY-FIFTH STREET, NEW YORK, *October 28, 1886.*

CONTENTS.

CHAPTER I.

GENERAL CONSIDERATIONS.

	PAGE
Definition of operative surgery—Facts to be ascertained before operating—Season of the year for operating—Time of day—Surroundings of the patient—Temperature of the room—Place for an operation—Nursing—Preparatory treatment—Diet—Essential and preparatory requirements—Anæsthetics—Inflammability of ether—Chloroform more dangerous than ether—Varieties of inhalers—Amount of ether required—Purity of the anæsthetic—Dangers of—How to prepare a patient for anæsthesia—Method of administering ether—Treatment for an overdose of ether—Intestinal etherization—Local anæsthesia—Instruments necessary for operating—Methods of holding the scalpel—Forms of incisions—Instruments should be plain—Receptacle for instruments—Operating table—Empty vessels—Clean towels and old linen—Antiseptic solutions—Sponges	1

CHAPTER II.

AGENTS FOR CONTROLLING HEMORRHAGE.

Styptics—Position—Elastic bandage—Compresses—Digital pressure—Davy's lever—Petit's tourniquet—Trendelenburg's rod—Acupressure—Torsion—Forceps—Tenacula—Cautery—Ligatures—Assistants—Patient prepared	23
---	----

CHAPTER III.

TREATMENT OF OPERATION WOUNDS.

Sutures—Needles—Needle-holders—Various forms of sutures—Drainage-tubes—Canalization—Antiseptic spray—Antiseptic douche—Antiseptic dressings—Antiseptic solutions—Quietude of patient—Common preparations for an antiseptic operation—Open dressings—Precautionary requirements of operations—Special emergencies of operations	41
---	----

CHAPTER IV.

LIGATURE OF ARTERIES.

Guides to ligaturing—Making primary incision—Opening the sheath of a vessel—Passing the ligature—Instruments required for ligaturing—Ligature of abdominal aorta—Of common iliac arteries—Of internal iliac artery—Of gluteal artery—Of sciatic artery—Of internal pudic artery—Of dorsalis pedis artery—Of external iliac artery—Of epigastric artery—Of deep circumflex artery—Of femoral artery—Of innominate artery—Of subclavian artery—Of vertebral artery—Of	
--	--

	PAGE
internal mammary artery—Of axillary artery—Of brachial artery—Of radial artery—Of ulnar artery—Of superficial palmar arch—Of common carotid artery—Of the common carotids—Of the external carotid artery—Of the internal carotid artery—Of the superior thyroid artery—Of the lingual artery—Of the facial artery—Of the temporal artery—Of the occipital artery	56

CHAPTER V.

OPERATIONS ON VEINS, CAPILIARIES, ETC.

Ligature of veins—Operations for varicose veins—Injection—Acupressure—Subcutaneous ligaturing—Hemorrhoids—Operation for internal hemorrhoids—Excision—Crushing—Ligaturing—Ligature with incision—Injection—Varicocele, treatment of—By excision of the scrotum—By compression with wires or pins—By subcutaneous ligaturing—Venesection—Transfusion—With blood—With saline solutions—With milk—Mother's mark—Treatment of—Nævi—Treatment of—Cirsoid growths—Treatment of	117
--	-----

CHAPTER VI.

OPERATIONS ON THE NERVOUS SYSTEM.

Operations for hydrocephalus—For meningocele—For hydrorachis—Trepining the cranium—Instruments for—Precautions in—Location of special functions of brain—Operations on supra-orbital nerves—On infra-orbital nerves—On superior maxillary nerves—On inferior dental nerve—On lingual nerve—On facial nerve—On great occipital nerve—On auricularis magnus nerve—On spinal accessory nerve—On musculo-cutaneous nerve—On musculo-spiral nerve—On median nerve—On radial and ulnar nerves—On great sciatic nerve—On internal popliteal nerves—On external popliteal nerves—On small sciatic nerves—On anterior and posterior tibial nerves—On plantar nerves—On perincal nerves—On anterior crural nerve—On long saphenous nerve—On short saphenous nerve—Nerve suturing—Nerve transplantation	134
--	-----

CHAPTER VII.

OPERATIONS ON TENDONS, FASCIAE, AND MUSCLES.

Instruments for tenotomy—Rules for tenotomy—Tenotomy of flexor sublimis and profundus digitorum muscles—Of extensor communis digitorum—Of extensor primi internodii, secundi internodii, and ossis metacarpi pollicis—Of flexor carpi radialis—Of flexor carpi ulnaris—Of biceps of forearm—Of tibialis posticus—Of flexor longus digitorum of leg—Of flexor longus pollicis of leg—Of tendo Achillis—Of peroneus longus and brevis—Of tibialis anticus—Of extensor proprius pollicis—Of extensor longus digitorum—Of peroneus tertius—Of biceps of leg—Of inner hamstring tendons of leg—Of the quadriceps extensor tendon—Of pectineus—Of adductor longus—Of tensor vaginæ femoris—Of sartorius—Of multifidus spinæ—Of latissimus dorsi—Of erector spinæ—Of sterno-cleido-mastoid—Of the plantar fascia—Of the palmar fascia—Dupuytren's contraction—Tendon suturing	151
--	-----

CHAPTER VIII.

OPERATIONS ON BONES.

Gouging—Instruments necessary for—Sequestrotomy—Instruments necessary for—Direct method of—Indirect method of—Excision—Time of operating—Instru-	
--	--

ments necessary for—Treatment of excision wounds—Excision of the upper jaw—Special instruments for—Complete removal of—Operation by median incision—Excision below floor of orbit—Subperiosteal excision of—The superior maxillæ may be removed simultaneously—Excision of the inferior maxilla—Excision of central portion of—Of lateral portion of—Of half of—Of entire bone—Of the alveolar process of—Operations for anchylosis of—Excision of the sternum—Excision of a portion of a rib—Excision of the clavicle—Excisions of the scapula—Excisions of the humerus—Excision of glenoid angle of scapula—Excisions of the elbow-joint—Excision of the ulna—Excision of the radius—Excisions of the wrist-joint—Excision of the lower extremities—Of the bones of the forearm—Of the metacarpo-phalangeal joints—Of the phalangeal joints—Of the metatarso-phalangeal joints—Of the metatarso-tarsal joints—Of the tarsal joints—Excision of the calcaneum—Of the astragalus—Excisions of the ankle-joint—Excision of the bones of the leg—Excisions of the knee-joint—Excision of the patella—Of the great trochanter—Excisions of the hip-joint—Excision of the coccyx—Osteotomy—Instruments employed for—Neck of femur, sections of—Supra-condyloid osteotomy—Osteo-arthritis—Osteotomy for genu varum—For “bow-legs”—For hallux valgus—Osteoplasty 161

CHAPTER IX.

AMPUTATIONS.

General considerations—Care in making flaps—Classification of flaps—Comparative merits of different forms of flaps—Agents required for an amputation—Proper manner of holding amputating knife—Proper manner of carrying it around the limb—Proper manner of using the saw—How to operate—Use of retractors—Amputations at the phalangeal articulations—Amputations at the metacarpo-phalangeal articulations—Amputations at the carpo-metacarpal articulations—Amputations through the metacarpal bones—Amputations at the wrist-joint—Amputations at the elbow-joint—Amputations of the forearm—Amputations of the arm—Amputations at the shoulder-joint—Amputations above the shoulder-joint 222

CHAPTER X.

AMPUTATIONS OF THE LOWER EXTREMITIES.

Amputations of the phalanges in their continuity—Amputations of single toes—Amputations of adjoining toes—Amputation of toes at metatarso-phalangeal joints—Amputation through metatarsal bones—Amputation of great toe, with its metatarsal bone—Amputation of the fifth toe, with its metatarsal bone—Lisfranc's amputation—Chopart's amputation—Forbes' modification of Chopart's amputation—Sub-astragaloid disarticulation—Hancock's amputation—Tripiet's method—Mollière's method—Syme's amputation—Modification of Syme's operation—Roux's operation—Pirogoff's amputation—Modifications of Pirogoff's amputation—Le Fort's modification of Pirogoff's amputation—Esmarch's modification of Le Fort's operation—Mikulicz's amputation—Supra-malleolar amputation—Amputations at the lower third of the leg—Amputations at the middle third of the leg—Amputations at the knee-joint—Amputations through the condyles of the femur—Carden's method—Gritti's method—Stokes' method—Amputations of the thigh—Amputations at the hip-joint 255

CHAPTER XI.

DEFORMITIES.

Brisement forcé—Barton's operation for ankylosis—Curvature of the spine—Plaster-of-Paris jacket for—Webbed fingers, treatment for—Ingrown nail—Ogston's treatment of flat-foot—Stokes' treatment of—Tarsectomy 297

CHAPTER XII.

PLASTIC SURGERY.

Preparation of patient for—Formation of flaps—Methods of transfer of flaps—Skin-grafting—Rhinoplasty—Mechanical appliances for deformed nose—Hare-lip—Cheiloplasty—Stomatoplasty—Staphyloplasty—Staphyloraphy—Uranoplasty—Elongated uvula, treatment of 304

CHAPTER XIII.

OPERATIONS ON THE MOUTH, PHARYNX, AND ŒSOPHAGUS.

Salivary fistula, treatment of—Excision of tonsils—Treatment for tongue-tie—For ranula—Excision of the tongue—Œsophagotomy—Dilatation of the Œsophagus—Œsophagectomy—Œsophagostomy 335

CHAPTER XIV.

OPERATIONS ON HOLLOW VISCERA IN CONTACT WITH SEROUS SURFACES.

Indications to be met—Forms of sutures employed for sewing serous surfaces—Gastrostomy—Gastrotomy—Gastro-enterostomy—Duodenostomy—Jejunostomy—Resection of the pylorus—Cholecystotomy—Cholecystectomy—Laparotomy—Enterotomy—Enterectomy—Colotomy—Iliac abscess, operation for—Artificial anus, treatment for—Nephrotomy—Nephrectomy—Nephro-lithotomy—Nephrorraphy—Splenectomy—Paracentesis abdominis—Hernia—Radical cure of—Kclotomy 348

CHAPTER XV.

OPERATIONS ON THE ANUS AND RECTUM.

Examination of anus—Operation for imperforate anus—For absence of anus—For fistula in ano—Surgical anatomy of rectum—Operations for prolapsus ani—For cancer of rectum—For stricture of rectum—For imperforate rectum 401

CHAPTER XVI.

OPERATIONS ON THE URINARY BLADDER.

Introduction of a catheter or sound into the bladder—Introduction of whalebone guides—Aspiration of bladder—Cystotomy—Digital exploration of bladder—Treatment of extroversion of bladder—Puncturing bladder—Lithotriety—Litholapaxy—Lithotomy 416

CHAPTER XVII.

OPERATIONS ON THE PENIS AND SCROTUM.

Operations for hydrocele—Castration—Circumcision—Treatment of paraphymosis—Methods of amputation of penis—Extirpation of penis—Operations for hypo-

CONTENTS.

xi

	PAGE
spadias—Operations for epispadias—Urethroraphy—Urethroplasty—External perineal urethrotomy—Internal urethrotomy—Tapping the urethra	455

CHAPTER XVIII.

MISCELLANEOUS OPERATIONS.

Tapping the pericardium—Extirpation of the breast—Extirpation of the axillary glands—Extirpation of the parotid gland—Paracentesis thoracis—Perforation of the antrum—Plugging posterior nares—Removal of nasal polypi—Removal of naso-pharyngeal polypi—Deviation of the septum nasi, operations for—Laryngotomy—Tracheotomy—Laryngo-tracheotomy—Intubation of the larynx—Pharyngotomy—Laryngectomy—Removal of goitre—Arthrectomy—Wiring patella—Movable bodies in joints, operation for—Ganglion, operations for—Wiring of bones for compound fractures	479
---	-----

B



ILLUSTRATIONS.

	PAGE
ABDOMINAL sections, location of incisions for. Fig. 568.	<i>Original.</i> 352
Acupressure. Figs. 45-47.	<i>Thomas Bryant.</i> 32
Allingham's screw crushing instrument for hemorrhoids. Fig. 170.	<i>Caswell, Hazard & Co., W. F. Ford, N. Y.</i> 120
Amputating knife, how to grasp. Fig. 315.	<i>Original.</i> 231
Amputating knife, how to carry around limb. Fig. 316.	<i>Original.</i> 232
Amputating knife, how to carry around limb, another method. Fig. 317.	<i>S. Smith.</i> 232
Amputating knife, how carried around limb, a common method. Fig. 318.	<i>Esmarch.</i> 232
Amputation, catching bleeding points. Fig. 327.	<i>Packard.</i> 234
Amputation by circular method. Fig. 303.	<i>Esmarch.</i> 224
Amputation by circular method, dissecting up flap. Fig. 304.	<i>Esmarch.</i> 225
Amputation by circular method, dissecting up flap, how not to do it. Fig. 305.	<i>Esmarch.</i> 225
Amputation by circular method, circular division of muscles. Fig. 306.	<i>Esmarch.</i> 226
Amputation, circular method, sawing the bone. Fig. 324.	<i>Ashhurst, modified.</i> 234
Amputation, circular, stump after. Fig. 307.	<i>Esmarch.</i> 226
Amputation, circular, modified. Fig. 308.	<i>Ashhurst.</i> 227
Amputation, equilateral flaps. Fig. 313.	<i>Esmarch.</i> 229
Amputation, Hancock's. Figs. 402, 403.	<i>Esmarch.</i> 266
Amputation, periosteal flap. Figs. 425, 427.	<i>Original.</i> 274, 275
Amputation, rectangular flap. Figs. 311, 312.	<i>Gross.</i> 229
Amputation, sawing the bone. Fig. 324.	<i>Ashhurst, modified.</i> 234
Amputation, Teale's method. Figs. 311, 312.	<i>Gross.</i> 229
Amputation, flap by transfixion. Figs. 309, 310.	<i>Gross.</i> 228
Amputation, De Lignerolles'. Figs. 398-403.	<i>Esmarch.</i> 264-266
Amputation at medio-tarsal articulation, Chopart's. Fig. 386.	<i>Neu.</i> 260
Amputation at medio-tarsal articulation, Chopart's. Figs. 392-397.	<i>Esmarch.</i> 262-264
Amputation at metatarso-phalangeal articulation, square-flap method, of all the toes.	
Figs. 380-383.	<i>Esmarch.</i> 258, 259
Amputation, sub-astragaloid. Figs. 398-403.	<i>Esmarch.</i> 264-266
Amputation, sub-astragaloid, De Lignerolles'. Figs. 398-401, 403.	<i>Esmarch.</i> 264-266
Anæsthetics, administering, drawing the tongue forward. Fig. 9.	<i>Esmarch.</i> 13
Anæsthetics, administering, pressing the jaw forward. Fig. 10.	<i>Esmarch.</i> 14
Anchylosis, bony, Barton's operation for. Fig. 461.	<i>Gross.</i> 298
Aneurism needle and director combined. Fig. 97.	<i>C., H. & Co., Ford.</i> 59
Aneurism needle, Fletcher's. Fig. 100.	<i>C., H. & Co., Ford.</i> 60
Aneurism needle, Mott's. Fig. 99.	<i>C., H. & Co., Ford.</i> 60
Aneurism needle, Syme's. Fig. 98.	<i>C., H. & Co., Ford.</i> 60
Aneurism needle, "Student's." Fig. 100.	<i>C., H. & Co., Ford.</i> 60
Ankle-joint, disarticulation at the. Figs. 404-409, 413-415, 417-424.	
<i>Esmarch.</i>	267, 268, 270, 271-273
Ankle-joint, disarticulation at the. Fig. 410.	<i>Original.</i> 269
Ankle-joint, amputation at, modification of Syme's. Fig. 410.	<i>Original.</i> 269
Ankle-joint, amputation at, removal of the entire foot, Syme's. Figs. 404-409.	
<i>Esmarch.</i>	267, 268

	PAGE
Ankle-joint, amputation at, Roux's. Figs. 411, 412.	<i>Gross.</i> 270
Ankle-joint, amputation at, Esmarch's. Figs. 421-424.	<i>Esmarch.</i> 273
Ankle-joint, amputation at, Bruns'. Fig. 420.	<i>Esmarch.</i> 272
Ankle-joint, excision of, internal incisions. Fig. 275.	<i>Esmarch.</i> 201
Ankle-joint, excision of, removal of lower end of fibula. Fig. 274.	<i>Esmarch.</i> 200
Ankle-joint, excision of. Fig. 272.	<i>Esmarch.</i> 199
Ankle-joint, anatomy of. Fig. 273.	<i>Esmarch.</i> 200
Ankle-joint, anatomy of, inner side. Fig. 276.	<i>Esmarch.</i> 201
Ankle-joint, amputation at, Pirogoff's. Figs. 413-415	<i>Esmarch.</i> 270, 271
Ankle-joint, amputation at, Pirogoff's. Fig. 416.	<i>S. Smith.</i> 271
Ankle-joint, amputation at, Pirogoff's. Fig. 417.	<i>Esmarch.</i> 271
Ankle-joint, amputation at, Le Fort's. Figs. 418-419.	<i>Esmarch.</i> 272
Anklets and wristlets, Pritchard's. Fig. 695.	<i>C., H. & Co., Ford.</i> 443
Antiseptic adhesive plaster between sutures. Fig. 77.	<i>Esmarch.</i> 43
Antiseptic dressing in position. Fig. 90.	<i>B. A. Watson.</i> 50
Antiseptic spray apparatus, Weir's. Fig. 89.	<i>C., H. & Co., Ford.</i> 43
Anus, absence of. Fig. 619.	<i>Gross.</i> 408
Anus, artificial, enterotome applied. Fig. 577.	<i>Packard.</i> 373
Aorta, abdominal, and inferior vena cava. Fig. 101.	<i>Sedillot.</i> 61
Aponeurotome. Fig. 711.	<i>C., H. & Co., Ford.</i> 453
Arch, palmar, superficial linear guide to. Fig. 161.	<i>Gross.</i> 106
Arm, amputation of, Langenbeck. Fig. 364.	<i>Esmarch.</i> 249
Arm, amputation of, by long anterior flap. Fig. 366.	<i>Esmarch.</i> 250
Arm, amputation of, by unequal skin-flaps. Fig. 365.	<i>Esmarch.</i> 249
Arteries, femoral, deep and superficial, relations of. Fig. 122.	<i>Gray.</i> 77
Arteries, iliac, linear guides to. Fig. 102.	<i>Stimson, modified.</i> 61
Arteries, iliac, venous relations of. Fig. 103.	<i>Sedillot.</i> 62
Arteries, iliac, venous relations of. Fig. 108.	<i>Sedillot.</i> 62
Arteries, ligature of, opening sheath of vessel. Fig. 92.	<i>Gross.</i> 58
Arteries, ligature of, passing aneurism needle. Fig. 98.	<i>Esmarch.</i> 58
Arteries, ligature of, passing probe. Fig. 94.	<i>Esmarch.</i> 58
Arteries, ligature of, primary incision. Fig. 91.	<i>Packard.</i> 57
Arteries of neck, linear guide. Fig. 136.	<i>Stimson, modified.</i> 86
Arteries of neck and face, linear guide. Fig. 137.	<i>Original.</i> 89
Artery, abdominal aorta and inferior vena cava. Fig. 101.	<i>Sedillot.</i> 61
Artery, axillary, ligature of first portion. Fig. 141.	<i>Sedillot.</i> 96
Artery, axillary, ligature of first portion. Fig. 142.	<i>Mott.</i> 97
Artery, axillary, ligature of third portion. Fig. 144.	<i>Sedillot.</i> 98
Artery, axillary, linear guide to third portion. Fig. 143.	<i>New.</i> 97
Artery, brachial, digital compression of. Fig. 88.	<i>Esmarch.</i> 28
Artery, brachial, ligature of, in middle third. Fig. 146.	<i>Sedillot.</i> 99
Artery, brachial, ligature of, in middle third. Fig. 147.	<i>Mott.</i> 100
Artery, brachial, tourniquet applied. Fig. 41.	<i>Esmarch.</i> 23
Artery, brachial, ligature of, in lower third. Fig. 148.	<i>Sedillot.</i> 100
Artery, brachial, ligature of, in lower third. Fig. 149.	<i>Mott.</i> 100
Artery, brachial, linear guide to. Fig. 145.	<i>New.</i> 98
Artery, carotid, common, ligature of. Fig. 164.	<i>Mott.</i> 108
Artery, carotid, common, ligature of, below omo-hyoid muscle. Fig. 163.	<i>Sedillot.</i> 108
Artery, carotid, common, surgical anatomy of. Fig. 162.	<i>Sedillot.</i> 106
Artery, carotid, external, surgical anatomy of. Fig. 165.	<i>Sedillot.</i> 108
Artery compressor, Gross's. Fig. 57.	<i>C., H. & Co., Ford.</i> 34
Artery compressor, Milne's. Fig. 58.	<i>C., H. & Co., Ford.</i> 35
Artery compressor, Speir's. Fig. 61.	<i>C., H. & Co., Ford.</i> 35
Artery, dorsalis pedis. Fig. 130.	<i>Packard.</i> 81
Artery, dorsalis pedis, ligature of. Fig. 131.	<i>Sedillot.</i> 82
Artery, dorsalis pedis, linear guide to. Fig. 126.	<i>Stimson, modified.</i> 79
Artery, epigastric, linear guide to. Fig. 111.	<i>Stimson, modified.</i> 70
Artery, epigastric, course of. Fig. 610.	<i>Gray.</i> 386

ILLUSTRATIONS.

XV

	PAGE
Artery, facial, ligature of. Fig. 168.	<i>Sedillot.</i> 116
Artery, femoral, compression of, digital. Fig. 87.	<i>Esmarch.</i> 78
Artery, femoral, ligature of, at apex of Scarpa's triangle. Fig. 118.	<i>Sedillot.</i> 75
Artery, femoral, ligature of, at apex of Scarpa's triangle. Fig. 119.	<i>Mott.</i> 75
Artery, femoral, ligature of, in Hunter's canal. Fig. 120.	<i>Sedillot.</i> 76
Artery, femoral, ligature of, in Hunter's canal. Fig. 121.	<i>Mott, modified.</i> 76
Artery, femoral, ligature of, in upper third. Fig. 116.	<i>S. Smith.</i> 73
Artery, femoral, linear guide to. Figs. 111-114.	<i>Stimson, modified.</i> 70-73
Artery, femoral, relations of. Fig. 115.	<i>Sedillot.</i> 73
Artery, femoral, relations of. Fig. 117.	<i>Gray.</i> 74
Artery, femoral, tourniquet applied to. Fig. 40.	<i>Esmarch.</i> 29
Artery, gluteal, ligature of. Fig. 107.	<i>S. Smith.</i> 67
Artery, gluteal, linear guide to. Fig. 106.	<i>Stimson, modified.</i> 66
Artery, iliac, common, incision for ligaturing. Fig. 104.	<i>Otis, modified.</i> 68
Artery, iliac, external, ligature of. Fig. 112.	<i>S. Smith.</i> 70
Artery, iliac, external, ligature of. Fig. 113.	<i>Mott.</i> 70
Artery, iliac, external, linear guide to. Fig. 111.	<i>Stimson, modified.</i> 70
Artery, iliac, primitive, ligature of. Fig. 105.	<i>Otis, modified.</i> 64
Artery, lingual, ligature of. Fig. 166.	<i>Sedillot.</i> 114
Artery, lingual, surgical anatomy of. Fig. 167.	<i>Esmarch, modified.</i> 114
Artery, oburator, course of. Fig. 614.	<i>Gray.</i> 400
Artery, occipital, ligature of. Fig. 169.	<i>Sedillot.</i> 117
Artery, popliteal, ligature of, at lower third. Fig. 125.	<i>S. Smith.</i> 79
Artery, popliteal, ligature of, at upper third. Fig. 124.	<i>Sedillot.</i> 78
Artery, popliteal, linear guide to. Fig. 123.	<i>New.</i> 78
Artery, pudic, linear guide to. Fig. 109.	<i>S. Smith.</i> 68
Artery, pudic, passing needle around. Fig. 110.	<i>S. Smith.</i> 68
Artery, radial, ligature of, at apex of styloid process. Fig. 155.	<i>Sedillot.</i> 103
Artery, radial, ligature of, at lower third. Fig. 153.	<i>Sedillot.</i> 103
Artery, radial, ligature of, at lower third. Fig. 154.	<i>Mott.</i> 103
Artery, radial, ligature of, at upper third. Fig. 151.	<i>Sedillot.</i> 103
Artery, radial, ligature of, at upper third. Fig. 152.	<i>Mott.</i> 103
Artery, radial, linear guide to. Fig. 150.	<i>Stimson, modified.</i> 101
Artery, sciatic, ligature of. Fig. 108.	<i>S. Smith.</i> 67
Artery, sciatic, linear guide to. Fig. 106.	<i>Stimson, modified.</i> 66
Artery, subclavian, ligature of third portion. Fig. 139.	<i>Sedillot.</i> 91
Artery, subclavian, ligature of third portion. Fig. 140.	<i>Mott.</i> 91
Artery, subclavian, surgical anatomy of. Fig. 138.	<i>Sedillot.</i> 90
Artery, temporal, ligature of. Fig. 168.	<i>Sedillot.</i> 116
Artery, torsion of an. Fig. 49.	<i>Esmarch.</i> 33
Artery, tibial, anterior, ligature of, at middle third. Fig. 129.	<i>Sedillot.</i> 81
Artery, tibial, anterior, linear guide to. Fig. 126.	<i>Stimson, modified.</i> 79
Artery, tibial, posterior, ligature of, at lower third. Fig. 135.	<i>Sedillot.</i> 84
Artery, tibial, posterior, ligature of, at middle third. Fig. 133.	<i>Sedillot.</i> 84
Artery, tibial, posterior, ligature of, at middle third. Fig. 134.	<i>Mott.</i> 84
Artery, tibial, posterior, linear guide to. Fig. 132.	<i>Stimson, modified.</i> 83
Artery, ulnar, ligature of, at junction of middle and upper thirds. Fig. 156.	<i>Sedillot.</i> 104
Artery, ulnar, ligature of, at junction of middle and upper thirds. Fig. 157.	<i>Mott.</i> 104
Artery, ulnar, ligature of, at lower third. Fig. 158.	<i>Sedillot.</i> 105
Artery, ulnar, ligature of, at lower third. Fig. 159.	<i>Mott.</i> 105
Artery, ulnar, ligature of, at wrist. Fig. 160.	<i>Sedillot.</i> 105
Artery, ulnar, linear guide to. Fig. 150.	<i>Stimson, modified.</i> 101
Aspirator, Fitch's. Fig. 581.	<i>C., H. & Co., Ford.</i> 378
Aspirator, trachea. Fig. 786.	<i>C., H. & Co., Ford.</i> 497
Aspirator, Potain's. Fig. 580.	<i>C., H. & Co., Ford.</i> 378
Atomizer, Richardson's. Fig. 14.	<i>C., H. & Co., Ford.</i> 17
Band, compression, Nicaise's. Fig. 29.	<i>Esmarch.</i> 25

	PAGE
Bandage, elastic. Fig. 27.	<i>Esmarch.</i> 24
Bandage, elastic, applied. Fig. 29.	<i>Esmarch.</i> 25
Bandage, rubber, Martin's. Fig. 33.	<i>C., H. & Co., Ford.</i> 27
Bistouri caché, Civiale's. Fig. 747.	<i>C., H. & Co., Ford.</i> 475
Bistouries and scalpels. Fig. 15.	<i>C., H. & Co., Ford.</i> 18
Bistoury, beaked, Gouley's. Fig. 741.	<i>C., H. & Co., Ford.</i> 471
Bladder, evacuating apparatus or washer, Bigelow's. Fig. 670.	<i>C., H. & Co., Ford.</i> 432
Bladder, evacuating apparatus or washer, Otis'. Figs. 671, 672.	<i>C., H. & Co., Ford.</i> 433
Bladder, evacuating apparatus or washer, Thompson's. Fig. 669.	<i>C., H. & Co., Ford.</i> 432
Bladder, extroversion of the, Bigelow's operation. Fig. 651.	<i>S. Smith.</i> 424
Bladder, extroversion of the, Bigelow's operation. Fig. 652.	<i>Agnau.</i> 424
Bladder, extroversion of the, Maury's operation. Fig. 650.	<i>S. Smith, modified.</i> 423
Bladder, extroversion of the, Wood's operation. Figs. 653, 654.	<i>Gross.</i> 425
Bladder, puncturing the. Fig. 657.	<i>Bumstead & Taylor.</i> 426
Blow-pipe. Fig. 64.	<i>C., H. & Co., Ford.</i> 36
Bone pliers, Butcher's. Fig. 487.	<i>C., H. & Co., Ford.</i> 316
Bougies à boule, Otis'. Fig. 745.	<i>C., H. & Co., Ford.</i> 475
Bougies, filiform. Fig. 646.	<i>C., H. & Co., Ford.</i> 420
Bougies, non-metallic. Fig. 746.	<i>C., H. & Co., Ford.</i> 475
Breast, removal of the. Fig. 753, 754.	<i>S. Smith.</i> 479
Breast, removal of the, incisions for. Fig. 755.	<i>Gross, modified.</i> 480
Buck's needle conductor. Fig. 48.	<i>C., H. & Co., Ford.</i> 32
Bunion, with hallux valgus. Fig. 468.	<i>Gross.</i> 302
Canal, femoral, location of. Fig. 612.	<i>Gray.</i> 398
Canula, Belloq's. Fig. 757.	<i>C., H. & Co., Ford.</i> 484
Canula, polypus, nasal. Fig. 760.	<i>C., H. & Co., Ford.</i> 485
Capillaries, subcutaneous ligaturing of. Figs. 189-194.	<i>S. Smith.</i> 183
Carpo-metacarpal articulation, amputations at. Figs. 341-345.	<i>Esmarch.</i> 240, 241
Carpus, ligaments of dorsal surface of. Fig. 266.	<i>Esmarch.</i> 194
Carpus, ligaments of palmar surface of. Fig. 287.	<i>Esmarch.</i> 194
Carpus, synovial membranes of. Fig. 265.	<i>Esmarch.</i> 193
Catheter, chemise. Fig. 694.	<i>C., H. & Co., Ford.</i> 443
Catheter, double-elbowed, Mercier's. Fig. 636.	<i>C., H. & Co., Ford.</i> 416
Catheter, elbowed, Mercier's. Fig. 637.	<i>C., H. & Co., Ford.</i> 416
Catheter, evacuating, Bigelow's. Fig. 673.	<i>C., H. & Co., Ford.</i> 433
Catheter, evacuating, spiral-tipped, Warren's. Fig. 674.	<i>C., H. & Co., Ford.</i> 434
Catheter, evacuating and lithotrite combined, author's. Fig. 677.	<i>C., H. & Co., Ford.</i> 436
Catheter-guide, Keyes'. Fig. 640.	<i>C., H. & Co., Ford.</i> 417
Catheter-guide, Otis'. Fig. 641.	<i>C., H. & Co., Ford.</i> 417
Catheter, olivary gum. Fig. 642.	<i>C., H. & Co., Ford.</i> 417
Catheter, passing a. Fig. 644.	<i>Bumstead & Taylor.</i> 417
Catheter entering bladder. Fig. 645.	<i>Bumstead & Taylor.</i> 419
Catheter, self-retaining. Fig. 638.	<i>C., H. & Co., Ford.</i> 416
Catheter, self-retaining, Holt's. Fig. 639.	<i>C., H. & Co., Ford.</i> 416
Catheter, velvet-eye. Fig. 643.	<i>C., H. & Co., Ford.</i> 417
Catheter, tunneled, and guide, Gouley's. Fig. 649, 742.	<i>C., H. & Co., Ford.</i> 421
Catlin. Fig. 321.	<i>C., H. & Co., Ford.</i> 233
Cautery-irons. Fig. 63.	<i>C., H. & Co., Ford.</i> 86
Cautery, thermo, Paquelin's. Fig. 65.	<i>C., H. & Co., Ford.</i> 38
Cheek-compressor for hare-lip, Hainsley's. Fig. 496.	<i>Gross.</i> 320
Chisel. Fig. 225.	<i>C., H. & Co., Ford.</i> 162
Chisels. Fig. 292.	<i>C., H. & Co., Ford.</i> 215
Cheiloplasty, lower lip, Celsus' method. Fig. 498.	<i>New.</i> 320
Cheiloplasty, lower lip, Celsus' method. Fig. 499.	<i>Stimson, modified.</i> 321
Cheiloplasty, lower lip, contracted, Buck's method. Figs. 502, 503.	<i>Buck.</i> 322, 323
Cheiloplasty, lower lip, horizontal incision. Fig. 500.	<i>Stimson.</i> 321
Cheiloplasty, lower lip, Malgaigne's method. Fig. 504.	<i>Stimson.</i> 324

	PAGE
Cheiloplasty, lower lip, operation by V-shaped incision. Fig. 497.	<i>Stimson.</i> 320
Cheiloplasty, lower lip, Sedillot's method. Fig. 505.	<i>Stimson.</i> 324
Cheiloplasty, Syme's method. Fig. 501.	<i>New.</i> 322
Cheiloplasty, upper lip, Dieffenbach's method. Figs. 508, 509.	<i>Agnew.</i> 326
Cheiloplasty, upper lip, Buck's method. Figs. 506, 507.	<i>Buck.</i> 324, 325
Cheiloplasty, upper lip, Sedillot's vertical-flap method. Figs. 510, 511.	<i>Stimson, modified.</i> 326
Chloroform inhaler, Esmarch's. Fig. 1.	<i>Esmarch.</i> 6
Clamp, bandage, Langenbeck's. Fig. 32.	<i>C., H. & Co., Ford.</i> 26
Clamp, Bodenhamer's. Fig. 729.	<i>C., H. & Co., Ford.</i> 462
Clamp, scrotal, Henry's. Fig. 173.	<i>C., H. & Co., Ford.</i> 129
Clamps, nasal septum, Adams'. Fig. 771.	<i>C., H. & Co., Ford.</i> 492
Collins' transfusion instrument. Fig. 185.	<i>Esmarch.</i> 129
Colon, ascending, surgical relations of. Fig. 572.	<i>Treves.</i> 370
Colon, descending, surgical relations of. Fig. 571.	<i>Treves.</i> 369
Colotomy, left lumbar. Figs. 573-575.	<i>Original.</i> 371
Colotomy, left lumbar. Fig. 576.	<i>Packard.</i> 372
Colotomy, left lumbar (Amussat), linear guide to colon. Fig. 570.	<i>S. Smith, modified.</i> 367
Compress, conical. Fig. 36.	<i>Esmarch.</i> 27
Compress, oblong. Fig. 35.	<i>Esmarch.</i> 27
Compress, pyramidal. Fig. 34.	<i>Esmarch.</i> 27
Crutch, Clover's, applied. Fig. 696.	<i>Original.</i> 444
Dilator, Dolbeau's. Figs. 632, 638.	<i>C., H. & Co., Ford.</i> 440
Dilators, œsophageal. Fig. 547.	<i>C., H. & Co., Ford.</i> 345
Dilator, trachea, Chassaignac's. Fig. 790.	<i>C., H. & Co., Ford.</i> 495
Dilator, trachea, Trousscau's. Fig. 779.	<i>C., H. & Co., Ford.</i> 495
Dilator, urethral, Gross'. Fig. 714.	<i>C., H. & Co., Ford.</i> 454
Director, Allingham's. Fig. 629.	<i>C., H. & Co., Ford.</i> 407
Director, grooved. Fig. 24.	<i>C., H. & Co., Ford.</i> 20
Director, grooved, and aneurism needle combined. Fig. 97.	<i>C., H. & Co., Ford.</i> 59
Director, hernial, Lewis'. Fig. 603.	<i>C., H. & Co., Ford.</i> 392
Double hook, Langenbeck's. Fig. 778.	<i>C., H. & Co., Ford.</i> 495
Drainage, spiral, Ellis'. Fig. 87.	<i>C., H. & Co., Ford.</i> 46
Drainage-tube, rubber. Fig. 38.	<i>C., H. & Co., Ford.</i> 46
Drill, bone, French. Fig. 791.	<i>C., H. & Co., Ford.</i> 509
Elbow-joint, amputation at. Fig. 360.	<i>Esmarch.</i> 247
Elbow-joint, amputation at, circular. Fig. 361.	<i>Esmarch.</i> 247
Elbow-joint, amputation at, single-flap. Fig. 362.	<i>S. Smith.</i> 243
Elbow-joint, disarticulation at. Figs. 360, 361.	<i>Esmarch.</i> 247
Elbow-joint, disarticulation at. Figs. 362, 363.	<i>S. Smith.</i> 243
Elbow-joint, excision of, Hüter. Fig. 259.	<i>Esmarch.</i> 189
Elbow-joint, excision of, exposing internal condyle. Fig. 263.	<i>Esmarch.</i> 189
Elbow-joint, excision of, Langenbeck. Fig. 261.	<i>Esmarch.</i> 189
Elbow-joint, excision of, Liston. Fig. 262.	<i>Esmarch.</i> 189
Elbow-joint, ligaments of. Fig. 260.	<i>Esmarch.</i> 189
Elbow-joint, relations of ulnar nerve to. Fig. 258.	<i>Esmarch.</i> 188
Elevator. Figs. 198-200.	<i>C., H. & Co., Ford.</i> 186
Enterectomy, Treves' apparatus for. Fig. 569.	<i>Treves.</i> 366
Epispadias, Nélaton's operation for. Figs. 734, 735.	<i>New.</i> 467
Epi-padias, Thiersch's operation for. Fig. 736, 737.	<i>Stimson.</i> 468
Ether inhaler, Allis'. Figs. 8, 4.	<i>Heath.</i> 7
Ether inhaler, cloth and paper. Fig. 2.	<i>Original.</i> 7
Ether inhaler, Clover's. Fig. 6.	<i>C., H. & Co., Ford.</i> 9
Ether inhaler, Lente's modified. Fig. 5.	<i>C., H. & Co., Ford.</i> 9
Ether inhaler, Noyes'. Fig. 8.	<i>C., H. & Co., Ford.</i> 11
Ether inhaler, Squibb's. Fig. 7.	<i>C., H. & Co., Ford.</i> 10
Etherization, intestinal, apparatus for. Fig. 18.	<i>C., H. & Co., Ford.</i> 17

	PAGE
Fascial contractions. Fig. 221.	<i>Abbe.</i> 160
Fascial contractions, Dupuytren's incisions for. Fig. 222.	<i>Abbe.</i> 160
Fascia, nicking. Fig. 23.	<i>Esmarch.</i> 90
Fasciotome. Fig. 219.	<i>C., H. & Co., Ford.</i> 162
Femur, subcutaneous division of neck of, Adams'. Fig. 298.	<i>Gross.</i> 216
Femur, subcutaneous division of neck of, Sayre's lines of section. Fig. 294.	<i>Gross.</i> 217
Femur, subcutaneous division of neck of, Volkmann's. Fig. 295.	<i>Poore.</i> 218
Flexor tendons of fingers, linear guide to. Fig. 161.	<i>Gross.</i> 106
Fingers, amputations of. Figs. 333-340.	<i>Esmarch.</i> 238-240
Fistula in ano. Fig. 621.	<i>Van Buren.</i> 404
Fistula in ano, dividing fistulas. Figs. 626-628.	<i>S. Smith.</i> 406
Fistula in ano, probing a fistula. Fig. 622.	<i>Puckard.</i> 405
Fistula in ano, variations in. Figs. 623, 624.	<i>Van Buren.</i> 405
Fistula, fecal, enterotome applied. Fig. 577.	<i>Puckard.</i> 373
Fistula, salivary, Horner's operation. Fig. 537.	<i>Puckard.</i> 386
Fistula, salivary, seton in position. Fig. 536.	<i>Gross.</i> 386
Forceps, artery, Hamilton's (F. H.). Fig. 52.	<i>C., H. & Co., Ford.</i> 34
Forceps, artery, and needle-holder combined. Fig. 76.	<i>C., H. & Co., Ford.</i> 43
Forceps, artery, spring-catch, fenestrated, Liston's. Fig. 51.	<i>C., H. & Co., Ford.</i> 33
Forceps, bone-cutting, curved, Liston's. Figs. 228, 229.	<i>C., H. & Co., Ford.</i> 163
Forceps, bone-cutting, straight, Liston's. Fig. 227.	<i>C., H. & Co., Ford.</i> 163
Forceps, bone-holding, Farabeuf's. Figs. 233, 326.	<i>C., H. & Co., Ford.</i> 168, 234
Forceps, bone-holding, Ferguson's. Fig. 238.	<i>C., H. & Co., Ford.</i> 168
Forceps, bone-holding, Langenbeck's. Fig. 238.	<i>C., H. & Co., Ford.</i> 168
Forceps, cross-bar (hemostatic). Fig. 566.	<i>C., H. & Co., Ford.</i> 358
Forceps, gouge, Hoffman's. Fig. 207.	<i>C., H. & Co., Ford.</i> 137
Forceps, lion-jaw, Ferguson's. Fig. 325.	<i>C., H. & Co., Ford.</i> 234
Forceps, lithotomy, curved. Fig. 690.	<i>C., H. & Co., Ford.</i> 442
Forceps, lithotomy, straight. Fig. 689.	<i>C., H. & Co., Ford.</i> 442
Forceps, mouse-tooth, Liston's. Fig. 53.	<i>C., H. & Co., Ford.</i> 34
Forceps, needle, Gross'. Fig. 533.	<i>C., H. & Co., Ford.</i> 332
Forceps, needle, Prout's. Fig. 74.	<i>C., H. & Co., Ford.</i> 42
Forceps, needle, Sands'. Fig. 75.	<i>C., H. & Co., Ford.</i> 42
Forceps, needle, Stimson's. Fig. 73.	<i>C., H. & Co., Ford.</i> 42
Forceps, phymosis, Fisher's. Fig. 718.	<i>C., H. & Co., Ford.</i> 458
Forceps, phymosis, Henry's. Fig. 717.	<i>C., H. & Co., Ford.</i> 458
Forceps, polypus, nasal, curved. Fig. 758.	<i>C., H. & Co., Ford.</i> 485
Forceps, polypus, nasal, straight. Fig. 759.	<i>C., H. & Co., Ford.</i> 486
Forceps, rectal, Byrnes'. Fig. 620.	<i>C., H. & Co., Ford.</i> 404
Forceps, rhinoplastos, Adams'. Fig. 770.	<i>C., H. & Co., Ford.</i> 491
Forceps, sequestrum, Ferguson's. Fig. 203.	<i>C., H. & Co., Ford.</i> 137
Forceps, sequestrum, Van Buren's. Fig. 202.	<i>C., H. & Co., Ford.</i> 137
Forceps, serrefine. Fig. 54.	<i>C., H. & Co., Ford.</i> 34
Forceps, tenaculum, Prince's. Fig. 62.	<i>C., H. & Co., Ford.</i> 35
Forceps, throat, Burge's. Fig. 553.	<i>C., H. & Co., Ford.</i> 348
Forceps, throat, Cusco's. Fig. 552.	<i>C., H. & Co., Ford.</i> 347
Forceps, throat, Mathieu's. Fig. 551.	<i>C., H. & Co., Ford.</i> 347
Forceps, thumb. Fig. 22.	<i>C., H. & Co., Ford.</i> 20
Forceps, torsion, Hewson's. Fig. 50.	<i>C., H. & Co., Ford.</i> 33
Forceps, trachea. Fig. 785.	<i>C., H. & Co., Ford.</i> 497
Forceps, wire-twisting, Sims'. Fig. 525.	<i>C., H. & Co., Ford.</i> 329
Foulis' fastening (for elastic bandage) in position. Fig. 30.	<i>Esmarch.</i> 26
Foulis' fastening (for elastic bandage) with rubber cord. Fig. 31.	<i>Esmarch.</i> 26
Gastro-enterostomy. Fig. 565.	<i>British Medical Journal.</i> 355
Gastrostomy, needles in position. Fig. 564.	<i>S. Smith, modified.</i> 353
Genu valgum. Fig. 236.	<i>Poore.</i> 218
Genu valgum, Macewen's line of bone section. Fig. 297.	<i>Macewen.</i> 219

	PAGE
Genu valgum, Macewen's method. Figs. 298-300.	<i>Macewen.</i> 219
Genu valgum, Ogsten's method. Figs. 301, 302.	<i>Macewen.</i> 219
Gorget, blunt. Fig. 687.	<i>C., H. & Co., Ford.</i> 441
Gorget, hooked. Fig. 713.	<i>C., H. & Co., Ford.</i> 454
Gouge, curved. Fig. 205.	<i>C., H. & Co., Ford.</i> 137
Gouge, straight. Fig. 204.	<i>C., H. & Co., Ford.</i> 137
Gouge, Szymanowsky's. Fig. 206.	<i>C., H. & Co., Ford.</i> 137
Guides, whalebone, Gouley's. Fig. 647.	<i>C., H. & Co., Ford.</i> 420
Hare-lip, complicate l. Fig. 495.	<i>Gross.</i> 319
Hare-lip, double. Fig. 494.	<i>Agnew.</i> 319
Hare-lip, simple, double-flap method. Figs. 490, 491.	<i>S. Smith, modified.</i> 313
Hare-lip, simple, double-flap method, Giralde's. Figs. 492, 493.	<i>S. Smith, modified.</i> 313
Hare-lip, simple, incision for direct union. Fig. 488.	<i>Agnew.</i> 317
Hare-lip, simple, single-flap method. Fig. 489.	<i>S. Smith, modified.</i> 313
Hernia, femoral, Wood's operation for the radical cure of. Figs. 597, 598, 599.	<i>Stimson.</i> 389, 390
Hernia, inguinal, direct. Fig. 611.	<i>Puckard.</i> 397
Hernia, inguinal, oblique. Figs. 603, 603.	<i>Puckard.</i> 395
Hernia, inguinal, Agnew's apparatus for the radical cure of. Fig. 556.	<i>C., H. & Co., Ford.</i> 363
Hernia, inguinal, Wood's apparatus for the radical cure of. Fig. 587.	<i>C., H. & Co., Ford.</i> 384
Hernia, inguinal, Wood's operation for the radical cure of. Fig. 589.	<i>Gross.</i> 384
Hernia, inguinal, Wood's operation for the radical cure of. Figs. 589, 590.	<i>Stimson.</i> 385
Hernia, inguinal, Wood's operation for the radical cure of. Fig. 591.	<i>Gross.</i> 385
Hernia, inguinal, Wood's operation for the radical cure of. Figs. 592, 593.	<i>Stimson.</i> 385
Hernia, inguinal, modification of Wood's operation for the radical cure of. Figs. 595, 596.	<i>Stimson.</i> 386, 387
Hernia, inguinal, Wutzer's apparatus for the radical cure of. Fig. 585.	<i>C., H. & Co., Ford.</i> 383
Hernia, sac of a. Figs. 583.	<i>Puckard.</i> 380
Hernia, sac of a, and contents. Fig. 584.	<i>Puckard.</i> 380
Hernia, umbilical, instruments for. Fig. 600.	<i>C., H. & Co., Ford.</i> 390
Hip-joint, amputation at, by long anterior and short posterior flap, Maenec. Figs. 450-453.	<i>Esmarch.</i> 290-292
Hip-joint, amputation at, Dieffenbach's circular method. Figs. 455-457.	<i>Esmarch.</i> 293, 294
Hip-joint, amputation at, elastic ligature for. Fig. 454.	<i>Esmarch.</i> 292
Hip-joint, amputation at, Malgaigne's method. Fig. 453.	<i>S. Smith.</i> 295
Hip-joint, amputation at, Malgaigne's method. Figs. 459, 460.	<i>Agnew.</i> 295, 296
Hip-joint, excision of, Langenbeck's longitudinal incision. Fig. 286.	<i>Esmarch.</i> 210
Hip-joint, excision of, Sayre's line of incision. Fig. 287.	<i>New.</i> 211
Hip-joint, excision of, sawing off head of femur. Fig. 285.	<i>Esmarch.</i> 210
Hip-joint, excision of, White's posterior curved incision. Fig. 283.	<i>Esmarch.</i> 209
Hip-joint, external rotator muscles and sciatic nerve. Fig. 284.	<i>Esmarch.</i> 209
Humerus, attachments to head of. Fig. 254.	<i>Esmarch.</i> 183
Humerus, excision of, upper end. Fig. 252.	<i>Esmarch.</i> 185
Humerus, excision of, upper end, raising tendon. Fig. 253.	<i>Esmarch.</i> 186
Humerus, excision of, upper end, sawing head of humerus. Fig. 255.	<i>Esmarch.</i> 186
Hydrocele, rubber bag for injecting. Fig. 716.	<i>C., H. & Co., Ford.</i> 457
Hydrocele, tapping a. Fig. 715.	<i>Gross.</i> 456
Hypospadias, Anger's operation for. Fig. 731.	<i>New.</i> 464
Hypospadias, Duplay's operation for. Fig. 732.	<i>New.</i> 465
Hypospadias, Gouley's operation for. Fig. 730.	<i>Gouley.</i> 464
Hypospadias, Szymanowsky's operation for. Fig. 733.	<i>S. Smith.</i> 466
Intubation of the larynx, O'Dwyer's instruments for. Fig. 790.	<i>C., H. & Co., Ford.</i> 503
Jaw, the, pressing forward, during administration of anæsthetics. Fig. 10.	<i>Esmarch.</i> 14

	PAGE
Kelotomy. Figs. 604-607.	<i>Puckard</i> . 393, 395
Kingsley's nasal lever. Fig. 486.	<i>Kingley</i> . 315
Knee-joint, amputation at, bilateral method. Figs. 430, 431.	<i>Esmarch</i> . 279
Knee-joint, amputation at, Carden's. Fig. 437.	<i>Stimson, modified</i> . 282
Knee-joint, amputation at, circular method. Figs. 432-434.	<i>Esmarch</i> . 280
Knee-joint, amputation at, Gritti's. Fig. 438.	<i>Stimson, modified</i> . 282
Knee-joint, amputation at, long anterior and short posterior flap. Figs. 435, 436.	<i>Esmarch</i> . 281
Knee-joint, amputation at, Stokes'. Fig. 438.	<i>Stimson, modified</i> . 282
Knee-joint, disarticulation at. Figs. 432-436.	<i>Esmarch</i> . 280, 281
Knee-joint, disarticulation at. Figs. 430, 431.	<i>S. Smith</i> . 279
Knee-joint, disarticulation at. Fig. 437.	<i>Stimson, modified</i> . 282
Knee-joint, excision of, Langenbeck's incision. Fig. 280.	<i>Esmarch</i> . 205
Knee-joint, excision of, line of section in, and epiphyseal cartilage of. Fig. 277.	<i>Stimson</i> . 203
Knee-joint, excision of, Mackenzie's anterior curved incision. Fig. 278.	<i>Esmarch</i> . 204
Knee-joint, excision of, Mackenzie's operation, lines of division of bone. Fig. 279.	<i>S. Smith</i> . 205
Knee-joint, excision of, Ollier's incision. Fig. 282.	<i>Stimson</i> . 207
Knee-joint, tendons at inner side of. Fig. 281.	<i>Esmarch</i> . 206
Knife, metacarpal. Fig. 319.	<i>C., H. & Co., Ford</i> . 233
Knife, Langenbeck's, for staphylorrhaphy. Fig. 518.	<i>C., H. & Co., Ford</i> . 328
Knives, amputating. Fig. 314.	<i>C., H. & Co., Ford</i> . 231
Knives, hernial. Figs. 601, 602.	<i>C., H. & Co., Ford</i> . 392
Knot, granny. Fig. 69.	<i>Heath</i> . 38
Knot, reef. Fig. 68.	<i>Heath</i> . 38
Knot, reef, first step in tying. Fig. 70.	<i>Heath</i> . 38
Knot, reef, second step in tying. Fig. 71.	<i>Heath</i> . 39
Knot, reef, third step in tying. Fig. 72.	<i>Heath</i> . 39
Knot, surgeon's. Fig. 67.	<i>Heath</i> . 38
Larynx and trachea, surgical anatomy of. Fig. 774.	<i>Gray</i> . 494
Larynx, external cartilages of. Fig. 773.	<i>Esmarch</i> . 493
Leg, amputation of, bilateral flaps. Fig. 428.	<i>S. Smith</i> . 275
Leg, amputation of, lower third, with periosteal reflection. Figs. 425-427.	<i>Original</i> . 274, 275
Leg, amputation of, long external flap. Fig. 429.	<i>Esmarch</i> . 278
Leg, transverse section of middle third of. Fig. 128.	<i>Esmarch</i> . 80
Leg, transverse section of upper third of. Fig. 127.	<i>Esmarch</i> . 80
Lever, Davy's, applied. Fig. 43.	<i>Davy</i> . 30
Ligature-carrier, Allingham's. Fig. 630.	<i>C., H. & Co., Ford</i> . 407
Ligature of arteries, opening sheath of vessel. Fig. 92.	<i>Gross</i> . 58
Ligature of arteries, passing aneurism needle. Fig. 98.	<i>Esmarch</i> . 58
Ligature of arteries, passing probe. Fig. 94.	<i>Esmarch</i> . 58
Ligature of arteries, primitive incision. Fig. 91.	<i>Puckard</i> . 57
Ligature, tying a. Fig. 66.	<i>Heath</i> . 37
Lithoclast, Dolbeau's. Fig. 691.	<i>C., H. & Co., Ford</i> . 442
Lithoclast, Gouley's. Fig. 681.	<i>C., H. & Co., Ford</i> . 439
Lithotome, Briggs' modified. Fig. 710.	<i>C., H. & Co., Ford</i> . 452
Lithotome (double), Dupuytren's. Fig. 690.	<i>C., H. & Co., Ford</i> . 447
Lithotome, Hutchison's. Fig. 700.	<i>C., H. & Co., Ford</i> . 447
Lithotome, Smith's. Fig. 698.	<i>C., H. & Co., Ford</i> . 446
Lithotomy bisector, Wood's. Fig. 707.	<i>C., H. & Co., Ford</i> . 450
Lithotomy bistoury, Little's. Fig. 705.	<i>C., H. & Co., Ford</i> . 449
Lithotomy conductor and scoop. Fig. 688.	<i>C., H. & Co., Ford</i> . 441
Lithotomy director, Little's. Fig. 704.	<i>C., H. & Co., Ford</i> . 448
Lithotomy knife, Blizard's. Fig. 686.	<i>C., H. & Co., Ford</i> . 441
Lithotomy knife, Dupuytren's. Fig. 685.	<i>C., H. & Co., Ford</i> . 441

	PAGE
Lithotomy, lateral incision of the prostate in. Fig. 697.	<i>Van Buren & Keyes.</i> 445
Lithotomy, medio-lateral method, Buchanan. Fig. 709.	<i>Van Buren & Keyes.</i> 451
Lithotomy, perineal, external incisions in. Fig. 708.	<i>S. Smith.</i> 450
Lithotomy scoop, Luer's. Fig. 692.	<i>C., H. & Co., Ford.</i> 442
Lithotomy staff. Fig. 689.	<i>C., H. & Co., Ford.</i> 441
Lithotomy staff. Fig. 684.	<i>C., H. & Co., Ford.</i> 441
Lithotomy staff and bisector, Wood's. Fig. 706.	<i>C., H. & Co., Ford.</i> 449
Lithotomy staff, Little's. Fig. 701.	<i>C., H. & Co., Ford.</i> 448
Lithotomy staff, Markoe's. Fig. 702.	<i>C., H. & Co., Ford.</i> 448
Lithotomy staff, rectangular. Fig. 703.	<i>C., H. & Co., Ford.</i> 440
Lithotrite and evacuating catheter combined, author's. Fig. 677.	<i>C., H. & Co., Ford.</i> 436
Lithotrite, Bigelow's. Fig. 664.	<i>C., H. & Co., Ford.</i> 431
Lithotrite, fenestrated blades, Bigelow's. Fig. 666.	<i>C., H. & Co., Ford.</i> 431
Lithotrite, fenestrated jaws. Fig. 662.	<i>C., H. & Co., Ford.</i> 429
Lithotrite, Keyes'. Figs. 667, 668.	<i>C., H. & Co., Ford.</i> 431
Lithotrite, non-fenestrated blades, Bigelow's. Fig. 665.	<i>C., H. & Co., Ford.</i> 431
Lithotrite, non-fenestrated jaws. Fig. 663.	<i>C., H. & Co., Ford.</i> 429
Lithotrite, Thompson's. Fig. 661.	<i>C., H. & Co., Ford.</i> 429
Lithotriety, perineal, Dolbeau's method, first step. Fig. 678.	<i>Gouley.</i> 437
Lithotriety, perineal, Dolbeau's method, second step. Fig. 679.	<i>Gouley.</i> 438
Lithotriety, perineal, Dolbeau's method, third step. Fig. 680.	<i>Gouley.</i> 438
Little's searcher. Fig. 659.	<i>C., H. & Co., Ford.</i> 427
Location of fissure of Rolando and special areas. Fig. 212.	<i>Roberts.</i> 141
Loops, Ricord's. Fig. 180.	<i>Ricord.</i> 125
Mallet, lead. Fig. 208.	<i>C., H. & Co., Ford.</i> 187
Maxillæ, superior, removal of both. Fig. 246.	<i>New.</i> 174
Maxilla, inferior, linear guide for removal of half. Fig. 247.	<i>New.</i> 177
Maxilla, inferior, severing connections of. Fig. 248.	<i>Agnew.</i> 177
Maxilla, superior, linear guide for removal of. Fig. 243.	<i>New.</i> 171
Maxilla, superior, division of processes of. Fig. 244.	<i>Agnew.</i> 172
Maxilla, superior, excision of, subperiosteal. Fig. 245.	<i>New.</i> 178
Medio-tarsal articulation, amputations at. Fig. 386.	<i>New.</i> 260
Metacarpal bones, amputation of last four, by transfixion. Fig. 350.	<i>Esmarch.</i> 243
Metacarpal bone, amputation through one. Fig. 346.	<i>Watson.</i> 240
Metacarpal bone, amputation through one. Fig. 347.	<i>Stimson.</i> 241
Metacarpal bone, stump after amputation through third. Fig. 348.	<i>Watson.</i> 243
Metacarpal bones, amputation of last four, appearance of stump. Fig. 352.	<i>Esmarch.</i> 243
Metacarpal bones, amputation of last four, line of dorsal flap. Fig. 351.	<i>Esmarch.</i> 243
Metacarpal bones, amputation of last four, line of palmar flap. Fig. 349.	<i>Esmarch.</i> 243
Metacarpal bones, amputation through fourth and fifth. Fig. 347.	<i>Watson.</i> 242
Metacarpal bones, disarticulation of last four. Figs. 349-352.	<i>Esmarch.</i> 243
Metacarpo-phalangeal articulation, disarticulation at. Figs. 339-345.	<i>Esmarch.</i> 240, 241
Metatarso-phalangeal articulation, excision of, U-shaped incision. Fig. 270.	<i>New.</i> 197
Metatarso-phalangeal articulation, amputation at. Fig. 275.	<i>Esmarch.</i> 256
Metatarso-phalangeal articulation, amputation of all the toes. Figs. 380-383.	<i>Esmarch.</i> 258, 259
Metatarso-phalangeal articulation, amputation at, removal of a single toe. Fig. 376.	<i>S. Smith.</i> 256
Metatarso-phalangeal articulation, amputation at, removal of great toe, lateral-flap method. Fig. 377.	<i>Esmarch.</i> 256
Metatarso-phalangeal articulation, amputation at, removal of great toe, lateral-flap method, completion of operation. Fig. 378.	<i>Esmarch.</i> 257
Metatarso-phalangeal articulation, amputation at, square-flap method. Fig. 379.	<i>Esmarch.</i> 257
Metatarso-phalangeal articulation, disarticulation at the. Figs. 380-385.	<i>Esmarch.</i> 258, 259
Miculicz's amputation of foot. Fig. 336.	<i>New.</i> 260
Mouth-gag, Mason's. Fig. 514.	<i>C., H. & Co., Ford.</i> 327

	PAGE
Nares, posterior, plugging the. Fig. 756.	<i>C., H. & Co., Ford.</i> 484
Nasal plugs, ivory. Fig. 772.	<i>C., H. & Co., Ford.</i> 492
Nerve, circumflex. Fig. 257.	<i>Gray.</i> 188
Nerve, crural, anterior, exposed. Fig. 216.	<i>Agnew.</i> 149
Nerve, maxillary, superior, Pancoast's lines of incision for exposing. Fig. 213.	<i>Pancoast, modified.</i> 143
Nerve, musculo-spiral. Fig. 257.	<i>Gray.</i> 188
Nerve, sciatic, great, exposed. Fig. 215.	<i>Agnew.</i> 148
Nerve, sciatic, great, linear guide to. Fig. 123.	<i>New.</i> 78
Nerve, spinal accessory, De Morgan's operation. Fig. 214.	<i>Agnew.</i> 146
Oesophagotomy, internal, Sands' instrument for. Fig. 548.	<i>C., H. & Co., Ford.</i> 346
Os calcis, excision of. Fig. 271.	<i>Gross.</i> 198
Osteotomes. Fig. 292.	<i>C., H. & Co., Ford.</i> 215
Osteotrite, Marshall's. Fig. 226.	<i>C., H. & Co., Ford.</i> 163
Palate, cleft, degrees of deformity. Figs. 528, 529.	<i>S. Smith.</i> 350
Palate, cleft, freshening borders in. Fig. 530.	<i>Puckard.</i> 330
Palate, soft, muscles of the. Fig. 532.	<i>Gray.</i> 331
Paracentesis abdominis, introducing trocar. Fig. 582.	<i>S. Smith, modified.</i> 379
Paraphymosis. Fig. 724.	<i>S. Smith.</i> 461
Paraphymosis, reduction of, first method. Fig. 726.	<i>S. Smith.</i> 461
Paraphymosis, reduction of, second method. Fig. 727.	<i>S. Smith.</i> 461
Paraphymosis, reduction of, third method. Fig. 728.	<i>S. Smith.</i> 462
Paraphymosis, results of the constriction. Fig. 725.	<i>S. Smith.</i> 461
Patella, wiring the, fragments united. Fig. 793.	<i>British Medical Journal.</i> 510
Patella, wiring the, wire introduced. Fig. 792.	<i>British Medical Journal.</i> 510
Periosteotome, Goodwillie's. Fig. 522.	<i>C., H. & Co., Ford.</i> 322
Periosteotome, Sands'. Fig. 237.	<i>C., H. & Co., Ford.</i> 167
Periosteotome, Sayre's. Figs. 282, 521.	<i>C., H. & Co., Ford.</i> 164, 329
Phalangeal articulations of the hand, disarticulation at. Figs. 333-338.	<i>Esmarch.</i> 238, 239
Phalangeal articulations of foot, disarticulation at. Fig. 375.	<i>Esmarch.</i> 256
Phalangeal articulations of foot, disarticulation at. Fig. 376.	<i>S. Smith.</i> 256
Phalangeal articulations of foot, disarticulation at. Figs. 377-379.	<i>Esmarch.</i> 256, 257
Phalanges of hand, attachment of tendons. Fig. 332.	<i>Original.</i> 237
Phalanx of hand, amputation of, making flap. Fig. 384.	<i>Esmarch.</i> 238
Phalanx of hand, amputation of, flap completed. Fig. 335.	<i>Esmarch.</i> 238
Phalanx of hand, amputation of, by transfixion. Fig. 386.	<i>Esmarch.</i> 238
Phalanx of hand, amputation of, opening joint. Fig. 337.	<i>Esmarch.</i> 238
Phalanx of hand, flexed. Fig. 333.	<i>Esmarch.</i> 238
Phymosis, clamping foreskin. Fig. 720.	<i>S. Smith.</i> 459
Phymosis, dorsal slit. Fig. 723.	<i>Gross.</i> 460
Phymosis, Keyes' operation for. Fig. 722.	<i>Keyes.</i> 460
Phymosis, steps of operation. Fig. 721.	<i>Original.</i> 459
Pin-carrier, Post's. Fig. 85.	<i>C., H. & Co., Ford.</i> 46
Pincers, intestinal, Abbe's. Fig. 507.	<i>C., H. & Co., Ford.</i> 358
Pins, adjustable pointed. Fig. 86.	<i>C., H. & Co., Ford.</i> 46
Pins, hare-lip. Fig. 81.	<i>C., H. & Co., Ford.</i> 46
Pins, Wood's rectangular. Fig. 594.	<i>Stimson.</i> 386
Plastic surgery, jumping method. Fig. 474.	<i>Prince.</i> 306
Plastic surgery, paper protective. Fig. 469.	<i>Prince.</i> 305
Plastic surgery parallel incisions. Figs. 470, 471.	<i>Prince.</i> 305
Plastic surgery, transverse incisions. Figs. 472, 473.	<i>Prince.</i> 306
Polypus, nasal, removing by snare. Fig. 764.	<i>Packard.</i> 486
Polypus, nasal, removing, double canula in position. Fig. 765.	<i>Gross.</i> 487
Polypus, nasal, removing, lines of incision. Fig. 766.	<i>New.</i> 487
Polypus, nasal, removing, Nélaton's operation. Fig. 768.	<i>New.</i> 488
Polypi, naso-pharyngeal, removing, Langenbeck's incisions. Fig. 767.	<i>New.</i> 488

	PAGE
Probang, bristle. Fig. 549.	<i>C., H. & Co., Ford.</i> 347
Probang, bucket. Fig. 550.	<i>C., H. & Co., Ford.</i> 347
Probang, sponge. Fig. 550.	<i>C., H. & Co., Ford.</i> 347
Prolapsus ani. Fig. 631.	<i>Van Buren.</i> 410
Prolapsus ani, complete, with peritoneum. Fig. 638.	<i>Van Buren.</i> 411
Prolapsus ani, with invagination. Fig. 632.	<i>Van Buren.</i> 410
Pylorus, resection of, outlines of incisions for. Fig. 568.	<i>Billroth.</i> 359
Rectum ending in a blind pouch. Fig. 635.	<i>Van Buren.</i> 415
Rectum, imperforate. Fig. 634.	<i>Gross.</i> 414
Relations of fissures and convolutions of brain to external surface of skull.	<i>Fig. 211. Roberts.</i> 140
Respiration, artificial, first movement. Fig. 11.	<i>Esmarch.</i> 15
Respiration, artificial, second movement. Fig. 12.	<i>Esmarch.</i> 16
Retractor, in amputations for one bone. Fig. 329.	<i>Esmarch.</i> 236
Retractor, in amputations for two bones. Fig. 328.	<i>Esmarch.</i> 236
Retractor, in amputations, three-tailed, applied. Fig. 330.	<i>Esmarch.</i> 236
Retractor, in amputation, two-tailed, applied. Fig. 331.	<i>Esmarch.</i> 237
Retractor, in tracheotomy. Fig. 776.	<i>C., H. & Co., Ford.</i> 495
Retractor, cheek. Fig. 515.	<i>C., H. & Co., Ford.</i> 328
Retractor, Mott's. Fig. 95.	<i>C., H. & Co., Ford.</i> 59
Retractor, Parker's. Fig. 96.	<i>C., H. & Co., Ford.</i> 59
Retractors. Figs. 235, 236.	<i>C., H. & Co., Ford.</i> 164, 167
Rhinoplasty, closure by transverse incision. Fig. 475.	<i>New.</i> 308
Rhinoplasty, Dieffenbach's method. Fig. 481.	<i>Dieffenbach.</i> 319
Rhinoplasty, Indian method. Fig. 483.	<i>New.</i> 312
Rhinoplasty, Italian method. Fig. 484.	<i>Stimson.</i> 312
Rhinoplasty, Ollier's method. Fig. 485.	<i>New.</i> 313
Rhinoplasty, repair by jumping. Figs. 478, 479.	<i>Buck.</i> 309
Rhinoplasty, repair by sliding. Figs. 476, 477.	<i>New.</i> 303
Rhinoplasty, Verneuil's method. Fig. 482.	<i>New.</i> 311
Rongeur. Fig. 201.	<i>C., H. & Co., Ford.</i> 136
Saphenous opening. Fig. 613.	<i>Gray.</i> 399
Saw, Adams'. Fig. 289.	<i>C., H. & Co., Ford.</i> 213
Saw, bow, Butcher's. Fig. 323.	<i>C., H. & Co., Ford.</i> 233
Saw, bow, common. Fig. 322.	<i>C., H. & Co., Ford.</i> 233
Saw, broad-bladed. Fig. 320.	<i>C., H. & Co., Ford.</i> 233
Saw, chain. Fig. 239.	<i>C., H. & Co., Ford.</i> 163
Saw, chain-carrier. Fig. 240.	<i>C., H. & Co., Ford.</i> 168
Saw, Langenbeck's. Fig. 288.	<i>C., H. & Co., Ford.</i> 212
Saw, Langenbeck's key-hole. Fig. 231.	<i>C., H. & Co., Ford.</i> 164
Saw, Lente's. Fig. 230.	<i>C., H. & Co., Ford.</i> 164
Saw, lifting-back, metacarpal. Fig. 241.	<i>C., H. & Co., Ford.</i> 169
Saw, oral, Goodwillie's. Fig. 526.	<i>C., H. & Co., Ford.</i> 329
Saw, Shrady's. Fig. 290.	<i>C., H. & Co., Ford.</i> 213
Saw, Shrady's, modified. Fig. 291.	<i>C., H. & Co., Ford.</i> 213
Saw, Szymanowski's. Fig. 242.	<i>C., H. & Co., Ford.</i> 169
Scalpel, method of holding, first position. Fig. 16.	<i>Bernard and Huette.</i> 18
Scalpel, method of holding, first position. Fig. 17.	<i>Puckard.</i> 19
Scalpel, method of holding, second position. Figs. 18, 19.	<i>Bernard and Huette.</i> 19
Scalpel, method of holding, third position. Figs. 20, 21.	<i>Bernard and Huette.</i> 19
Scalpel, trachea. Fig. 775.	<i>C., H. & Co., Ford.</i> 495
Scalpels. Figs. 233, 234.	<i>C., H. & Co., Ford.</i> 164
Scalpels and bistouries. Fig. 15.	<i>C., H. & Co., Ford.</i> 164
Scapula, excision of body. Fig. 250.	
Scapula, excision of entire. Fig. 249.	
Scapula, excision of glenoid angle. Fig. 256.	

	PAGE
Scapula, excision of subperiosteal. Fig. 251.	<i>New.</i> 184
Scoop and conductor, lithotomy. Fig. 688.	<i>C., H. & Co., Ford.</i> 441
Scoop, Hebra's. Fig. 224.	<i>C., H. & Co., Ford.</i> 162
Scoop, Volkmann's. Fig. 223.	<i>C., H. & Co., Ford.</i> 162
Scissors, Allingham's. Fig. 629.	<i>C., H. & Co., Ford.</i> 407
Scissors, curved. Fig. 25.	<i>C., H. & Co., Ford.</i> 21
Scissors, curved for staphylorrhaphy, etc. Fig. 520.	<i>C., H. & Co., Ford.</i> 329
Scissors, phymosis, Taylor's. Fig. 719.	<i>C., H. & Co., Ford.</i> 459
Scissors, straight, probe-pointed. Fig. 26.	<i>C., H. & Co., Ford.</i> 21
Searcher, Gouley's. Fig. 660.	<i>C., H. & Co., Ford.</i> 427
Searcher, Little's. Fig. 659.	<i>C., H. & Co., Ford.</i> 427
Searcher, Thompson's. Fig. 658.	<i>C., H. & Co., Ford.</i> 427
Serrefine, Langenbeck's. Fig. 55.	<i>C., H. & Co., Ford.</i> 34
Serrefine, wire. Fig. 56.	<i>C., H. & Co., Ford.</i> 34
Shoulder-joint, amputation at, by circular incision, flaps united. Fig. 371.	<i>Esmarch.</i> 254
Shoulder-joint, amputation at, by circular incision, removal of bone. Fig. 370.	<i>Esmarch.</i> 253
Shoulder-joint, amputation at, oval, Larrey. Fig. 372.	<i>S. Smith.</i> 254
Shoulder-joint, amputation at, oval, Larrey, forming inner flap. Fig. 373.	<i>S. Smith.</i> 254
Shoulder-joint, amputation at, Spence's method. Fig. 374.	<i>Esmarch.</i> 254
Shoulder-joint, disarticulation of, Dupuytren. Fig. 367.	<i>Esmarch.</i> 251
Shoulder-joint, disarticulation of, Dupuytren, flaps united. Fig. 369.	<i>Esmarch.</i> 252
Shoulder-joint, disarticulation of, Dupuytren, making inner flap. Fig. 368.	<i>Esmarch.</i> 252
Skull, course of arteries and sinuses of. Fig. 209.	<i>Esmarch.</i> 138
Snare, polypus, nasal, Codman and Shurtleff's. Fig. 762.	<i>C., H. & Co., Ford.</i> 486
Snare, polypus, nasal, Jarvis'. Fig. 763.	<i>C., H. & Co., Ford.</i> 486
Snare, polypus, nasal, Sexton's. Fig. 761.	<i>C., H. & Co., Ford.</i> 486
Sonde à dart. Fig. 712.	<i>C., H. & Co., Ford.</i> 454
Sound, tunneled, Gouley's. Fig. 648.	<i>C., H. & Co., Ford.</i> 421
Speculum, rectal, Allingham's. Fig. 618.	<i>C., H. & Co., Ford.</i> 402
Speculum, rectal, bivalve. Fig. 616.	<i>C., H. & Co., Ford.</i> 402
Speculum, rectal, Williams'. Fig. 617.	<i>C., H. & Co., Ford.</i> 402
Speculum, rectal, Thebaud's dilating. Fig. 625.	<i>C., H. & Co., Ford.</i> 406
Spine, curvature of the, Sayre's apparatus for. Figs. 462-464.	<i>C., H. & Co., Ford.</i> 298, 299
Staphylorrhaphy, freshening borders. Fig. 531.	<i>Puckard.</i> 330
Staphylorrhaphy, looped suture in. Fig. 534.	<i>S. Smith.</i> 333
Stomatoplasty. Fig. 512.	<i>Buck.</i> 327
Suspensory, Morgan's. Fig. 172.	<i>Gross.</i> 121
Suture, continuous, or Glover's. Figs. 80, 555.	<i>Esmarch.</i> 44, 349
Suture, hare-lip. Figs. 82, 83.	<i>Esmarch.</i> 45
Suture, interrupted. Fig. 78.	<i>Esmarch.</i> 44
Suture, intestinal, Czerny-Lembert's. Fig. 561.	<i>Mostig-Moorhof.</i> 351
Suture, intestinal, Gely's, external appearance. Fig. 557.	<i>Stimson.</i> 350
Suture, intestinal, Gely's, internal appearance. Fig. 558.	<i>Otis.</i> 350
Suture, intestinal, Gussenbauer's. Fig. 562.	<i>Mostig-Moorhof.</i> 351
Suture, intestinal, Jobert's. Figs. 559, 560.	<i>Esmarch.</i> 351
Suture, intestinal, Lembert's. Figs. 554-556.	<i>Esmarch.</i> 349
Suture, quilled. Fig. 81.	<i>Thomas Bryant.</i> 44
Sutures, tension of. Fig. 79.	<i>Thomas Bryant.</i> 44
Syringe, débris, Van Buren's. Fig. 693.	<i>C., H. & Co., Ford.</i> 443
Tampon, trachea, Trendelenburg's. Fig. 769.	<i>C., H. & Co., Ford.</i> 491
Tarso-metatarsal articulation, amputations at. Fig. 386.	<i>New.</i> 260
Tarso-metatarsal articulation, amputation at, Lisfranc's. Fig. 386.	<i>New.</i> 260
Tarso-metatarsal articulation, amputation at, Bauden's modification of Lisfranc's. Fig. 386.	<i>New.</i> 260
Tarso-metatarsal articulation, amputation at, Hey's modification of Lisfranc's. Fig. 386.	<i>New.</i> 260

	PAGE
Tarso-metatarsal articulation, amputation at, Skey's modification of Lisfranc's.	Fig. 386. <i>New.</i> 260
Tarso-metatarsal articulation, disarticulation at. Figs. 387-391.	<i>Esmarch.</i> 261, 262
Tarso-metatarsal articulation, disarticulation at. Figs. 411, 412.	<i>Gross.</i> 270
Tarso-metatarsal articulation, disarticulation at. Fig. 410.	<i>Original.</i> 269
Tarso-metatarsal articulation, disarticulation at. Fig. 416.	<i>S. Smith.</i> 271
Tenaculum. Figs. 59, 519.	<i>C., H. & Co., Ford.</i> 35, 328
Tenaculum, application of, to vessels. Fig. 60.	<i>Packard.</i> 35
Tenaculum-retractor. Fig. 777.	<i>C., H. & Co., Ford.</i> 495
Tendon, dividing a. Fig. 220.	<i>Sayre.</i> 152
Tendons, flexor, of fingers, linear guide to. Fig. 161.	<i>Gross.</i> 106
Tenotomies. Figs. 217, 218.	<i>C., H. & Co., Ford.</i> 151, 152
Thigh, amputation of, bilateral flaps. Fig. 428.	<i>S. Smith.</i> 275
Thigh, amputation of, Celsus' single circular incision. Figs. 442, 443.	<i>Esmarch.</i> 286
Thigh, amputation of, circular-integumentary flap, amputated portion.	Fig. 441. <i>Gross.</i> 285
Thigh, amputation of, circular-integumentary flap, conical cavity of stump.	Fig. 440. <i>Gross, modified.</i> 284
Thigh, amputation of, periosteal flap. Fig. 439.	<i>Esmarch, modified.</i> 284
Toe, amputation at the metatarso-phalangeal articulation. Fig. 375.	<i>Esmarch.</i> 256
Toes, amputation of all, at the metatarso-phalangeal articulation. Figs. 380-383.	<i>Esmarch.</i> 255, 259
Toe, amputation of a single, at the metatarso-phalangeal articulation. Fig. 376.	<i>S. Smith.</i> 256
Toe, amputation of a single, at the metatarso-phalangeal articulation, lateral-flap method. Fig. 377.	<i>Esmarch.</i> 256
Toe, amputation of a single, at the metatarso-phalangeal articulation, lateral-flap method, completion of operation. Fig. 378.	<i>Esmarch.</i> 257
Toe, amputation of a single, at the metatarso-phalangeal articulation, square-flap method. Fig. 379.	<i>Esmarch.</i> 257
Toe, great, amputation of, at proximal end of metatarsal bone. Fig. 384.	<i>Esmarch.</i> 259
Toe, little, amputation of, and metatarsal bone. Fig. 385.	<i>Esmarch.</i> 259
Toe-nail, ingrowing. Fig. 467.	<i>Gross.</i> 302
Tongue, excision of, écraseur in position. Fig. 544.	<i>Agnew.</i> 341
Tongue, excision of, Kocher's operation. Fig. 546.	<i>Kocher.</i> 343
Tongue, excision of, Regnoli's incision. Fig. 545.	<i>Gross.</i> 342
Tongue, excision of, removal of a V-shaped piece. Fig. 541.	<i>S. Smith.</i> 339
Tongue, excision of, removal of a V-shaped piece, flaps united. Fig. 542.	<i>S. Smith.</i> 339
Tongue, hypertrophy of. Fig. 543.	<i>Buck.</i> 340
Tongue, the, drawing forward, during administration of anæsthetics. Fig. 9.	<i>Esmarch.</i> 13
Tonsillotome, Hamilton's. Fig. 539.	<i>C., H. & Co., Ford.</i> 337
Tonsillotome, Mackenzie's. Fig. 540.	<i>C., H. & Co., Ford.</i> 338
Tonsillotome, Tiemann's. Fig. 538.	<i>C., H. & Co., Ford.</i> 337
Tourniquet, abdominal, Brandis'. Fig. 449.	<i>Esmarch.</i> 289
Tourniquet, abdominal, compression pad and elastic band. Fig. 448.	<i>Esmarch.</i> 288
Tourniquet, abdominal, elastic ligature. Fig. 454.	<i>Esmarch.</i> 292
Tourniquet, abdominal, Esmarch's. Fig. 445.	<i>C., H. & Co., Ford.</i> 287
Tourniquet, abdominal, Esmarch's, applied. Fig. 446.	<i>C., H. & Co., Ford.</i> 288
Tourniquet, abdominal, Lister's. Fig. 447.	<i>C., H. & Co., Ford.</i> 288
Tourniquet, abdominal, Pancoast's. Fig. 444.	<i>C., H. & Co., Ford.</i> 287
Tourniquet, Knebel's improved. Fig. 42.	<i>Esmarch.</i> 28
Tourniquet, Petit's. Fig. 39.	<i>Esmarch.</i> 28
Tourniquet, Petit's, applied to femoral artery. Fig. 40.	<i>Esmarch.</i> 28
Trachea and larynx, surgical anatomy of. Fig. 774.	<i>Gray.</i> 66
Trachea, opening the. Fig. 787.	<i>Esmarch.</i> 66
Trachea, vascular relations of the. Fig. 789.	<i>Packard.</i> 66
Transfusion apparatus, Bull's. Fig. 187.	<i>C., H. & Co., Ford.</i> 66
Transfusion apparatus, Collins'. Fig. 185.	<i>Esmarch.</i> 66

	PAGE
Transfusion apparatus, Fryer's. Fig. 184.	<i>C., H. & Co., Ford.</i> 128
Transfusion, direct. Fig. 183.	<i>C., H. & Co., Ford.</i> 128
Transfusion, introducing tube. Fig. 182.	<i>Esmarch.</i> 127
Transfusion, removing fibrin from blood. Fig. 186.	<i>Esmarch.</i> 129
Transfusion, straining blood. Fig. 188.	<i>Esmarch.</i> 131
Trendelenburg's rod. Fig. 44.	<i>C., H. & Co., Ford.</i> 31
Trephine, crown. Fig. 195, 196.	<i>C., H. & Co., Ford.</i> 136
Trephine, crown, application of. Fig. 210.	<i>Esmarch.</i> 138
Trephine, Galt's. Fig. 197.	<i>C., H. & Co., Ford.</i> 136
Trocar and canula. Fig. 579.	<i>C., H. & Co., Ford.</i> 378
Trocar, rectum. Fig. 655.	<i>C., H. & Co., Ford.</i> 425
Trocar, rectum, Buck's. Fig. 656.	<i>C., H. & Co., Ford.</i> 425
Trocar, Wood-Harris. Fig. 578.	<i>C., H. & Co., Ford.</i> 378
Tube (curved) and guide, Keyes'. Fig. 676.	<i>C., H. & Co., Ford.</i> 434
Tube (straight) and guide, Keyes'. Fig. 675.	<i>C., H. & Co., Ford.</i> 434
Tube, trachea, bivalve. Figs. 783, 784.	<i>C., H. & Co., Ford.</i> 496
Tube, trachea, hard rubber. Fig. 782.	<i>C., H. & Co., Ford.</i> 496
Tube, trachea, in position. Fig. 788.	<i>Esmarch, modified.</i> 498
Tube, trachea, silver. Fig. 781.	<i>C., H. & Co., Ford.</i> 496
Uranoplasty. Fig. 535.	<i>Gross.</i> 334
Urethra, tapping the. Fig. 752.	<i>Bumstead & Taylor.</i> 478
Urethrometer, Otis'. Fig. 748.	<i>C., H. & Co., Ford.</i> 476
Urethroplasty. Fig. 738.	<i>Stimson.</i> 470
Urethroplasty, Nélaton's operation. Fig. 739.	<i>Original.</i> 470
Urethroplasty, Rigaud's operation. Fig. 740.	<i>Original.</i> 471
Urethrotome, Otis'. Figs. 749, 750.	<i>C., H. & Co., Ford.</i> 476, 477
Urethrotome, Pect's. Fig. 751.	<i>C., H. & Co., Ford.</i> 477
Urethrotomy, operation of, drawing apart lips of the incision. Fig. 744.	<i>Original.</i> 478
Urethrotomy staff, grooved, Syme's. Fig. 743.	<i>C., H. & Co., Ford.</i> 472
Variocoele, Keyes' needle for. Fig. 179.	<i>C., H. & Co., Ford.</i> 124
Varicocele, treatment by elastic traction. Fig. 178.	<i>Gross.</i> 124
Varicocele, treatment by occlusion by pins. Fig. 174.	<i>Packard.</i> 123
Varicocele, treatment by Ricord's loops. Fig. 180.	<i>Ricord.</i> 125
Varicocele, Vidal's operation. Figs. 175-177.	<i>Packard.</i> 123
Veins, spermatic, varicose. Fig. 171.	<i>Gross.</i> 121
Venesection with scalpel. Fig. 181.	<i>Esmarch.</i> 125
Webbed fingers. Fig. 465.	<i>Annandale.</i> 300
Webbed fingers, Nélaton's operation. Fig. 466.	<i>Annandale.</i> 301
Whitehead's forceps. Figs. 516, 517.	<i>C., H. & Co., Ford.</i> 328
Whitehead's hoe. Fig. 527.	<i>C., H. & Co., Ford.</i> 350
Whitehead's mouth-gag. Fig. 513.	<i>C., H. & Co., Ford.</i> 327
Whitehead's spiral needle. Fig. 523.	<i>C., H. & Co., Ford.</i> 329
Wrist-joint, amputation at, circular method. Fig. 353.	<i>Esmarch.</i> 244
Wrist-joint, amputation at, flaps united. Fig. 354.	<i>Esmarch.</i> 244
Wrist-joint, amputation at, double flap. Figs. 355, 356, 358.	<i>Esmarch.</i> 245, 246
Wrist-joint, amputation at, single palmar flap. Fig. 357.	<i>S. Smith.</i> 245
Wrist-joint, amputation at, double flap, appearance of stump. Fig. 359.	<i>Esmarch.</i> 246
Wrist-joint, excision of, Langenbeck's incisions. Fig. 268.	<i>Esmarch.</i> 195
Wrist-joint, excision of, lateral incisions. Fig. 264.	<i>Esmarch.</i> 198
Wrist-joint, excision of, Lister's incisions. Fig. 269.	<i>Stimson.</i> 196

OPERATIVE SURGERY.

CHAPTER I.

GENERAL CONSIDERATIONS.

Operative Surgery treats of the manual procedures necessary to properly accomplish the surgical object in view. The operation to be done is the execution of a verdict that is, or should be, based upon surgical principles and laws in a sense comparable to legal proceedings in the Courts of Justice. The surgeon, in most instances, however, holds the threefold position of judge, jury, and executioner. It is, therefore, very essential for the welfare of the patient that he properly interpret the surgical laws and principles relating to the case, in order that the verdict to follow may be just, and its execution cast no opprobrium upon himself or his profession. To be able to operate understandingly, requires not only a thorough knowledge of the principles of surgery, but a fair knowledge of the ways and means of accomplishing the desired purpose.

It is not enough to be able to remove in a skillful manner an offending member or disease, but it is equally important for the surgeon to so prepare the patient and himself that no unanticipated complication can occur immediately prior to, during, or subsequent to the operation.

Regarding the principles of surgery proper, the reader is referred to the many works upon that subject; since it is not the intention of the author to intrude upon this department of surgery, except in so far as it may be found expedient to apply them to the immediate safety of the patient during and subsequent to the operation.

Prior to an operation, especially if it be one of any magnitude, it is essential that the following facts be ascertained:

First. The physical condition of the heart, lungs, brain, and great vessels.

Second. If there be an acute surgical or other condition of the essential organs of the body.

Third. If there be any

Fourth. If the patient be anæmic or scorbutic. If he have syphilis, phthisis, epilepsy, diabetes, or be in danger of delirium tremens.

Fifth. If he be willing and ready for the operation.

Upon the healthful condition of the heart, lungs, brain, etc., may depend the expediency of giving an anæsthetic, and the choice between them. If the kidneys be diseased, it may be inadvisable to operate upon the urethra or bladder, or even to give an anæsthetic; if the great vessels be dilated or atheromatous, much discretion must be employed in its selection and administration. It should not be forgotten, however, that the mental emotion and physical suffering attendant upon an operation, when performed without anæsthesia, may be of greater moment than with its use.

If the injury demanding an operation be recent, and the patient be suffering from a severe shock, it should be deferred until reaction is established. If the shock be out of proportion to the visible injury, a careful examination of the patient must be made to ascertain its cause. If a complicating injury be discovered, which of itself imperils the life of the patient, all idea of an immediate operation must be deferred. These thoughtful attentions will lessen the pungency of the oft-repeated satirical expression, "The operation was successful, but the patient succumbed."

If the patient be already anæmic, or scorbutic, the loss of blood added to the shock of the operation may expose him to greater dangers than if the operation be postponed. Unfortunately, however, in a majority of cases, the conditions calling for operative interference are the prime factors which determine the degree of the blood changes, and will not, of themselves, admit of any delay.

The existence of syphilis, phthisis, diabetes, etc., exerts a marked influence on the recovery, and their importance must not be underestimated in connection with this fact. If a patient be addicted to the continuous use of intoxicating beverages, and worse still, if he receive an injury during a prolonged debauch, it seriously complicates his case, not only directly from the previous effects upon his bodily vigor, but from the impending danger of delirium tremens.

It is not necessary to the successful issue of an operation that the patient be ready and willing; yet, if such a fortunate combination be present, it will weigh heavily in favor of ultimate success. It is prudent, however, that he should be ready in a legal sense; that is, that his consent be gained.

If the operation be a *dernier ressort* he should be given the opportunity of adjusting his business and spiritual affairs. If they be prematurely adjusted—if such be possible—the knowledge of it, and the quiet of mind resulting therefrom, will become valuable aids toward his recovery.

Season of the Year.—Autumn and spring are the best seasons for

surgical operations. Still, it is not always practicable to render this knowledge available. It is best to avoid, as far as possible, extremes of temperature. Fair weather with an ascending barometer is more propitious than the reverse.

The time of day should be such as to secure a good light until the completion of the operation.

The surroundings of the patient subsequent to the operation are to be studied with great care. The sick-room should be commodious and sunny, and, when possible, be on the second floor, with a southern exposure, and with the door and windows so arranged that it can be easily ventilated without exposure to improper air-currents. All sewer-connected wash-basins or other receptacles of waste must be excluded from the room. The plainer the walls and ceilings the better; for, if the patient become delirious, the outlines and figures of modern decorations may invite and form the basis of exciting illusions. It is better at all times, for hygienic reasons, that the room be as plain as possible, and that all unnecessary articles be removed therefrom, especially when it is to be reoccupied as a sick-room. During convalescence, and after all dangers from septic influences are passed, objects of interest may be placed upon the mantels and walls, which can be varied from time to time to please the fancies of the patient.

The temperature of the room should be maintained at about 70° Fahr. Pure air is quite as essential to a rapid recovery as good food. The room should be thoroughly ventilated at least once each day; this can be readily done by opening the windows and doors, thereby creating a through-and-through current, at the same time using caution that the patient be protected from direct draughts, and be well covered till the temperature shall have resumed a suitable standard. The presence of flowers and other odoriferous agents are not to be encouraged in the sick-room, although they may exert a good moral influence, in that they remind the patient of the existence of sympathizing friends without. It must always be made as cheerful as possible, consequently all annoyances are to be removed whenever the fancies of the patient indicate their presence.

Place for an Operation.—The office of the surgeon is not a proper place to do operations of any magnitude, or even those requiring the use of an anæsthetic, because the rest and quiet that should follow the former can not be had if the patient be removed; and, moreover, anæsthesia is often followed by persistent nausea and vomiting, and not infrequently by prolonged noisy delirium.

Nursing.—All who require the services of a nurse should, if possible, secure one who has had considerable experience and is a professional. The well-intended attentions and observations of solicitous friends are often burdensome to the patient, and misleading to the surgeon, and are

as apt to be controlled by their sympathy for the patient, as by the desire to consult the express wishes of the medical attendant. It is well to remember, however, that a discreet friend is a far better attendant than a garrulous self-sufficient nurse. The attendant who proffers his views and experience in the sick-chamber, hoping thereby to honestly impress all present with his worth, is as detrimental to the moral atmosphere of the room, as closed windows and doors are to the physical.

Preparatory Treatment.—This should be directed to the improvement of the patient's general condition; also to directly combating the constitutional diseases which may affect the ultimate result.

Diet.—Precisely the variety and amount of food to be given are matters which must be determined by the requirements of the individual cases. Milk, eggs, milk-punch, stimulants, etc., are stereotyped articles, the usefulness of which is well established. They should not, in any instance, if it be possible to avoid it, be substituted by the traditional beef-tea, and more elaborate chemical extracts with which the market is cloyed.

The requirements necessary to secure favorable results in surgical operations may be divided into the essential and the precautionary.

The essential requirements consist of such implements, agents, and information as are necessary to the proper performance of an operation, as well as to a due consideration of the result.

The precautionary are those which are useful in the various emergencies that may complicate an operation; and it is necessary, if they are to be of practical utility, that they should be at hand and be prepared for immediate use.

ESSENTIAL REQUIREMENTS.

First. A knowledge of the usual result of the operation about to be performed.

Second. A practical knowledge of the anatomy of the parts involved in the operation.

Third. Anæsthetics; proper means of administering, and of combating their dangers.

Fourth. The necessary implements and a knowledge of their use.

Fifth. Suitable trays to hold instruments.

Sixth. Operating-table, sponges, empty vessels, antiseptic solutions, and rubber cloths.

Seventh. Agents for controlling hemorrhage.

Eighth. Assistants of suitable number and proficiency.

Ninth. A patient properly prepared for the procedure.

Tenth. Proper materials for dressing wounds and a knowledge of their use.

A knowledge of the usual result of the operation about to be performed is one of the chief factors to be employed to determine its

propriety; and is, therefore, entitled to be first considered. This knowledge can be gained from only two sources: First, the personal experience of the operator and of those from whom he may be able to obtain an opinion. Second, the recorded experience of the profession. The first implies the calling of a consultation, which should always be done whenever a doubt exists in the mind of the operator; such a course not only offers to the patient every available chance, but, in unfortunate results, frequently serves to sooth the feelings of disappointment experienced by all concerned. If a consultation be not feasible, the surgeon must then rely upon the recorded practical knowledge of the profession, a knowledge which is modified from year to year by the improvement and increase of surgical expedients; consequently, the statistics of a certain operation must be recent, if they are to be of the greatest practical utility.

A practical understanding of the anatomy of the part involved in an operation is always essential to the comfort of the operator, and often to the safety of the patient. This knowledge is somewhat difficult to obtain and is always of uncertain tenure. In the case of the general practitioner, it consists chiefly of that which can be gleaned from text-books and anatomical plates: often called "Flat Anatomy," added to the anatomical knowledge retained since graduation. Those who reside in large cities can avail themselves of the ample opportunities afforded, to rehearse important operations. When the dead can be made generally subservient to the welfare of the living, then all medical men can avail themselves of the only means of becoming fully able to surgically "Do unto others as they would that others should do unto them."

Anæsthetics.—The anæsthetics in established use are ether, chloroform, and nitrous oxide or laughing-gas.

Ether.—This is employed far more in surgery than both the others combined. The chief objections to its use are its pungency, the liability of its causing nausea and vomiting, its inflammability, and production of cerebral excitement.

Its disagreeable *pungency can be lessened*, in fact, almost entirely obviated, by allowing a good volume of air to mingle with it during the first moments of its administration. One has but to cover his own face with the well-charged ether-cone in common use, to realize the sense of impending suffocation, which is experienced by the unwary patient, whose struggles to resist it are often violent, and suggestive of the belief that, upon his part, the struggle is for life. Scenes of this kind should always be avoided, more especially when the patient is suffering from any complications which will expose him to an additional peril. The *nausea and vomiting* following, are not of sufficient importance to contra-indicate the use of ether, except in such cases in which it would be otherwise objectionable.

The resultant vomiting is chiefly dangerous, where solid food has

been recently taken, in often causing suffocation by its entering the larynx and trachea.

Inflammability.—This is only to be regarded while operating in the presence of artificial light or with the actual cautery. There is, however, but little danger, since the weight of the vapor causes it to create a downward current, thereby tending to remove it from contact with the igniting agent. It is safer, however, for all concerned, to treat it on such occasions as if it were only awaiting the slightest opportunity to assert its power. The *cerebral excitement* which often precedes complete anæsthesia may be due to an idiosyncrasy, or be augmented by surrounding circumstances. The patient should be assured that no harm will attend its administration; it should be given in a gentle manner, slowly in the beginning, that the mucous membranes may not suffer too great irritation, and complete quietude on the part of all present should be maintained, since talking often serves to excite the inebriated fancies, and forms the basis of disorderly actions. The handling of the part to be operated upon, prior to complete insensibility, is a fertile source of annoyance, and is often suggestive to the patient of the impending operation. These are precautions which should be observed during the administration of all anæsthetics.

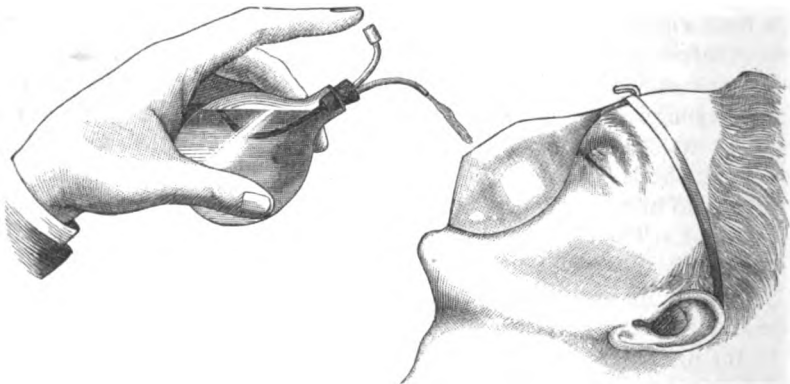


FIG. 1.—Esmarch's chloroform inhaler.

Chloroform is more dangerous than ether, and should not be used, unless the contra-indications to the use of ether are exceedingly strong. Although it has a pleasant odor and is devoid of pungency, is less liable to induce vomiting and cerebral excitement, is non-inflammable and more rapid in action than ether, yet these facts weigh but little as against the additional dangers incurred by its use. At the present time its application as an anæsthetic is almost entirely limited to children, and to obstetrical practice. Chloroform can be administered by pouring a few drops on a napkin which is held a short distance from the nose, or by the agency of an inhaler devised by Esmarch (Fig. 1), which

consists simply of a properly shaped wire frame-work covered by flannel and fastened to the head.

Nitrous oxide is the most agreeable and least dangerous of the anæsthetics in general use. Its employment is limited to operations of short duration. It can not be classed as a practical anæsthetic, since the expense, the cumbersome apparatus for administration, and its transient effects unfit it for general use. It is, however, often employed where the presence of cardiac or other organic diseases contra-indicate the use of ether or chloroform.

Inhalers.—The variety of inhalers for administering anæsthetics is large. It is no part of my intention to discuss the comparative virtues of the various forms ; but rather to select those in common use, and aid the general practitioner residing at a distance from the basis of surgical supplies to extemporize at least one which will meet the pressing indications.

The simplest method of administering any anæsthetic, and the one generally employed with chloroform, is by moistening a towel or napkin. In the case of ether, this is very unsatisfactory ; inasmuch as it involves an unnecessary expenditure of time and of ether, and produces a less satisfactory anæsthesia than any other method. There are other pertinent objections to it, but those already mentioned are of sufficient weight to dismiss its further consideration.

The simplest form of an ether cone, or inhaler, is the one that has been for a long time in common use in many of the hospitals of this city (Fig. 2).

The method of its construction is simple, and the materials employed are always accessible. A sheet of paper of strong texture, or, three or four layers of an ordinary newspaper, two feet in length and eighteen or twenty inches in width, together with a strong piece of cloth, the dimensions of which shall exceed those of the paper two or three inches, and a dozen ordinary pins, are all that is required to construct it. Place the cloth—a towel is usually employed—and the paper on a table, with the paper uppermost ; fold them in the middle of their long diameter, which will bring the cloth on the outer surfaces and the paper within. Then fold them in the short diameter, the length of the fold corresponding to the distance from the symphysis mentis to the root of the nose of the patient ; when thus folded, pin the outer and inner extremities firmly through the whole texture of the sides, using care that the pins be so placed that they will not stick in the patient's face, or in the hands of the administrator of the anæsthetic. Several pins are now to be passed through all the textures in various situations to hold them firmly together. One end of this tube must now be closed, which is easily and quickly accomplished by turning

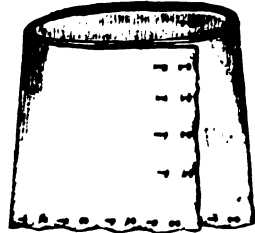
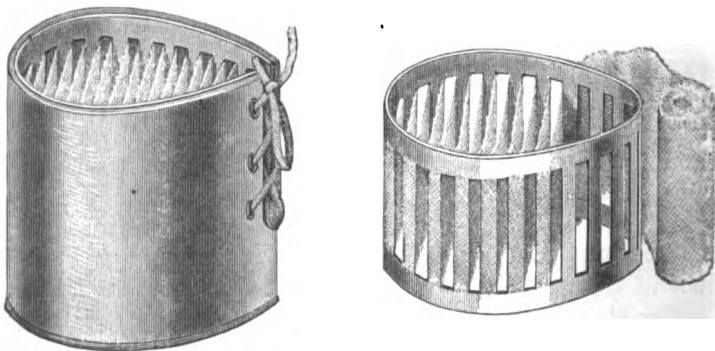


FIG. 2.—Cloth and paper cone.

inward its borders, and securely pinning them to each other. It is better to close the end corresponding to the free extremities of the material, thereby giving a firmer basis to the cone. Into the top of the cone is then crowded a good-sized sponge, or a piece of coarse-textured cloth, always observing that it be beyond the reach of the nose and face of the patient. Absorbent cotton or several layers of muslin may be interposed between the surfaces of the upper end, instead of their being closed by turning and pinning as just described, when, if this material be now confined in position by means of pins, and the end covered with a layer of thin gauze, the ether can then be poured upon the interposed material and administered without removing the cone from the face. It likewise admits the requisite amount of air. The advantages which this simple inhaler possess over the permanent and more expensive ones are quite numerous. It can not be damaged by the patient, nor will the face be bruised by its borders during his struggles; it is a temporary affair, and therefore need never be used a second time—a fact which is obviously of considerable importance in a fastidious and hygienic sense. It does not, however, admit of the easy regulation of the amount of ether to be given, nor the amount of air to be admitted; it is also liable, unless care be used in replenishing it with ether, to permit the anæsthetic to flow into the eyes and upon the face of the patient; in addition, the air-space is almost invariably contracted during the struggles of the patient; yet these are objections which can be easily surmounted by a requisite amount of caution. The amount of ether required with this apparatus is less than if a napkin be used alone, while it exceeds that employed in the more perfect inhalers.

Allis' Inhaler, which consists of a fenestrated metallic frame-work



FIGS. 3, 4.—Allis' inhaler.

for the support of cloth partitions, surrounded by an adjustable leather or rubber covering, is simple, efficient, portable, and can be quite easily cleansed (Figs. 3 and 4). Its advantages, briefly stated, are the

following : It allows a free admission of air from above, which becomes saturated with ether ; the evaporating surface is great, causing thereby a rapid vaporization, which hastens anæsthesia and saves ether ; the ether can be replenished through the top, which obviates the necessity of removing the inhaler and interrupting the administration. The cloth partitions can be readily changed whenever propriety and cleanliness demand it.

The inhalers of Lente, Squibb, Noyes, and others, are all serviceable, and whoever possesses either of them can, so far as the apparatus is concerned, administer ether with safety. It is not necessary to the safety of the patient that any one of them be employed. It is, however, necessary to the safety of the patient, no matter which one

be used, that the administrator of the anæsthetic shall rely more upon his knowledge of the principles governing its administration than upon the mechanism of the apparatus. With a proper knowledge of these principles, it matters but little whether one or another form of inhaler be used.

Lente's Modified Inhaler (Fig. 5).—When this is to be used, either a piece of old muslin, lint, or a suitable amount of cotton batting can

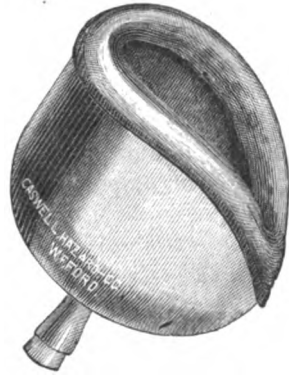


FIG. 5.—Lente's modified inhaler.

be confined in position at the top by a wire or whalebone fastening. The amount of air admitted can be easily regulated by the adjust-

ment of the stopper at the top, and the ether can be poured in at this situation if it be undesirable to remove the apparatus from the face.

Clover's Inhaler (Fig. 6) consists of a receptacle holding two ounces of ether—a mouth-piece cushioned with inflated rubber fitting closely over the patient's nose and mouth, and connected with the ether receptacle in such a manner that the amount of ether inhaled may be increased or diminished




FIG. 6.—Clover's inhaler.

at will, and a rubber bag which receives the expired air charged with ether vapor.

The advantages claimed for this inhaler are : the patient can be anæsthetized in a very short time ; the depression of the system is not so great ; the patient recovers consciousness more quickly and does not feel the effects of ether so long as with the plain ether inhalers. The amount of ether to be inhaled is graduated by turning the receptacle : when turned on *O*, no ether is inhaled ; when at 1, $\frac{1}{4}$ of the usual amount ; at 2 $\frac{1}{4}$, the usual amount ; at 3 $\frac{1}{4}$, and at *F* the full amount is inhaled. Thus the quantity of ether administered can be increased or diminished during the operation.

Another important point is, that there is so little ether consumed that the inhaler is very valuable for use in hospitals and in the field.



FIG. 7.—Squibb's inhaler.

Squibb's Inhaler (Fig. 7).—This consists of an hour-glass-shaped muslin bag, one end of which is cut off to fit the face

of the patient. The narrow portion is made to receive a tin tube several inches in length and two in diameter ; the round end serves the purpose of an air-chamber. When the bag is to be used, it should be wetted with water and thoroughly squeezed, to render it only partially pervious to the passage of air or other vapor. Into the tin tube a piece of flannel and blotting-paper rolled together, each about six inches wide and eighteen inches long, are thrust, after which they are saturated with ether ; or it may be done before their introduction. The open end of the apparatus is then placed over the mouth and nose of the patient, and the administration commences. One to two and a half ounces is quite enough to properly anæsthetize the patient.

Noyes' Inhaler (Fig. 8).—This apparatus is simple of construction. It consists of a flexible air-chamber at one end and a face-piece at the other. Between the two is a small tin chamber to contain the ether. The bag or air-chamber is perforated by a small hole, that allows the entrance of a sufficient amount of air, which enters the lungs together with the ether at each effort of inspiration. The amount of ether used with this, is about the same as with the preceding.

The amount of ether required to produce insensibility depends upon several conditions, the most important of which are, the susceptibility of the patient, the manner of administering, and the purity of the anæsthetic. Some persons can be completely anæsthetized by an ounce, and even less, if it be not wasted ; on the other hand, those are occasionally met with who "take ether badly," and can not be rendered quiet unless a large amount be given ; rarely, a case is encountered

which will not yield to its influence, and the surgeon is forced to desist, from fear of killing the patient. It is not prudent to determine in advance the definite amount that will be used, except pos-

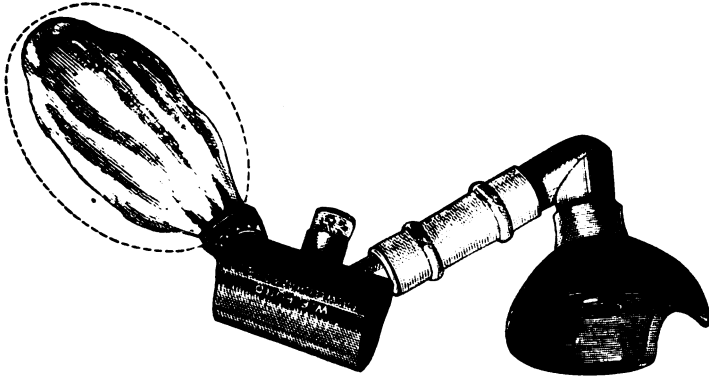


FIG. 8.—Noyes' inhaler.

sibly in some peculiar cases. Anæsthesia is never to be attempted unless the surgeon can be certain he has a sufficient amount to complete the operation, for nothing can be more humiliating than to be obliged to discontinue an operation for the purpose of procuring additional ether. It is not prudent to begin an operation that requires much time and care, unless at least one pound of ether be at hand.

Purity of the Anæsthetic.—It is important that the anæsthetic be pure, in order that the amount taken may be suitably judged, and a proper interpretation placed upon the effect produced. The anæsthetics of Squibb, of Brooklyn, are generally considered to be of a superior quality.

Dangers from the Use of Ether.—The dangers attending the use of an anæsthetic may be reduced to a minimum, provided proper attention be given to the physical conditions recognized as contra-indicating or requiring caution in their use, together with a display of ordinary care in administering. Before administering it, the condition of the heart, lungs, brain, kidneys, vessels, etc., should be ascertained, even though there be no apparent evidences of disease. If they have undergone organic changes, or, if the patient have laryngeal obstruction from any cause, be suffering from bronchitis, or be pregnant, the greatest caution must be employed in the administration, even if it be administered at all. The degree of the disease, and the condition of the patient dependent thereon, together with the necessity of an immediate operation, and its severity, must determine the advisability of an anæsthetic. If the patient have advanced heart and kidney disease, phthisis, or aneurism, it is better to use nitrous oxide; chloroform, even, has been used under such circumstances instead of ether, on account of its causing less excitement and vomiting.

The danger from a full stomach is great, especially if the ingesta be solid; since, if vomiting occur, the food may be sucked into the larynx and trachea, causing death by suffocation; moreover, nausea and vomiting are more frequent and persistent when the stomach is partially filled with food. It is impracticable to lay down all the important relations existing between the use of an anæsthetic and the various complications that may exist as contra-indications. The surgeon must be largely controlled by the circumstances surrounding each individual case. If it be determined to administer ether or chloroform to a patient suffering from a debilitated heart, the latter's action must be strengthened by the administration of digitalis some days prior to, as well as by stimulants during the operation. If the patient have laryngeal obstruction, from spasm of the glottis or other causes, the pungency of the ether, and spasm of the respiratory muscles, when added to the already lessened area of the respiratory chink, and the diminished aëration of the blood resulting therefrom, may be often sufficient to produce rapid unconsciousness and impending death from asphyxia. In my opinion, chloroform is the better anæsthetic under such circumstances.

How to Prepare a Patient for Anæsthesia.—First. Inform yourself of the state of the brain, heart, lungs, kidneys, vessels, etc.; if disease be found, inform the patient or the friends of the additional dangers incurred.

Second. Count the pulse and respiration, noting the character of each, and making due allowance for the excitement dependent upon surrounding circumstances. These observations will be far more valuable if they have been taken some time prior to the immediate operation.

Third. See that no solid food has been taken for at least six to eight hours before; if so, evacuate the stomach by means of a simple and rapid emetic. The practical way of having the stomach in a proper condition is to omit the meal preceding the operation. If the time be too long for this, a glass or two of milk five or six hours before will meet the indications.

Fourth. Remove all false teeth from the mouth, or whatever else might fall into the larynx.

Fifth. Loosen all constricting bands which surround the abdomen, chest, and throat.

Sixth. Cause the evacuation of the contents of the bladder and rectum; this will often prevent the soiling of the clothes and the patient.

Seventh. Place the patient upon the back, with the head and shoulders slightly raised; neck not bent.

Eighth. If the patient have a beard, wet it to prevent the rapid escape of the ether through it.

Ninth. Adjust windows and doors to admit fresh air, without exposing the patient to a draught.

Tenth. Disarm the patient of all fears of danger attending the use of the anæsthetic.

The assistant who is to administer the anæsthetic should have at his convenience a basin, a towel, and a tenaculum or forceps. The first for the reception of the dejections from the stomach; the towel to remove the saliva, etc., from the mouth and face; the tenaculum or forceps, to pull forward the tongue if it fall backward over the glottis (Fig. 9).

It is recommended, and with much force, to administer, hypo-

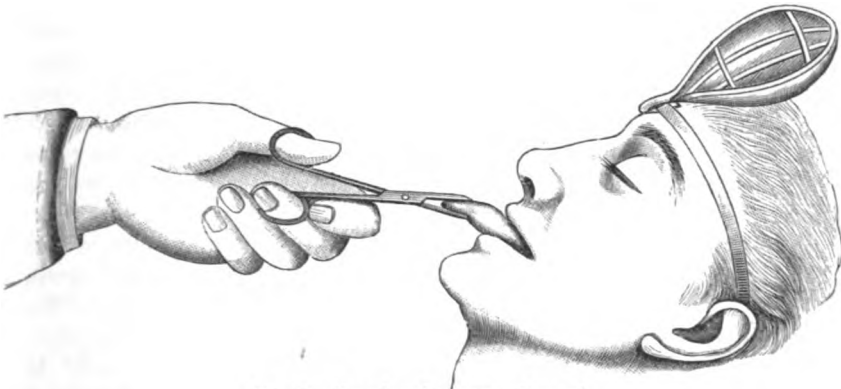


FIG. 9.—Drawing the tongue forward.

dermically or otherwise, a dose of morphia an hour or so before anæsthesia is to be commenced. It quiets the nervous excitement of the patient, reduces the amount of ether otherwise necessary, and prolongs its effect, lessens the tendency to nausea and vomiting, and diminishes shock. Moderate inebriation has been produced immediately in advance of an operation by giving brandy or whisky, and for substantially the same reasons.

Method of Administering Ether.—This will depend somewhat upon the variety of inhaler used; if it be of ordinary construction, commence by pouring a small amount (an ounce or so) into or upon the inhaler, and adjust it so that a good volume of air shall mingle with the ether for the first few moments of the administration. After the sense of pungency has somewhat subsided, the patient should be told to “cough,” “breathe deeply,” at the same time the fresh air is to be quite rapidly excluded. The patient soon becomes oblivious, and may be fully anæsthetized without further trouble. This is recognized by the insensibility of the conjunctiva, or, what is better, a relaxed muscular system, which is ascertained by noting the absence of any resistance to flexing or extending the extremities. If an extremity

be raised from the bed, it will fall directly downward and lie motionless. Stertorous breathing is likewise a concomitant of complete anæsthesia. More often, however, the patient will be seen to pass through the three distinct stages of anæsthesia, which will vary in their length and manifestations, according to his peculiarities. The attention of the administrator of the anæsthetic should always be directed to the character of the respiration and pulse, the color of the surface and its temperature. The respiration is often temporarily arrested or impeded by the tonic stage, causing marked cyanosis. This is quite readily relieved by making sudden and forcible pressure in the epigastrium, or slapping the chest with the naked hand or a wet towel. The respiration may be obstructed or prevented, at any period of anæsthesia, by foreign bodies in the larynx and trachea, such as false teeth, vomited matter, etc. In complications of this character, the obstructing agent must be removed immediately or death will ensue, unless tracheotomy be performed. The glottis may become stopped by the falling backward of the tongue; this usually occurs during the stage of complete anæsthesia, and is to be instantly remedied by drawing the tongue forward by the aid of a tenaculum, or dry towel, or forceps.

If the jaw be pressed forward during the administration of the anæsthetic by the administrator (Fig. 10), the muscular attachments

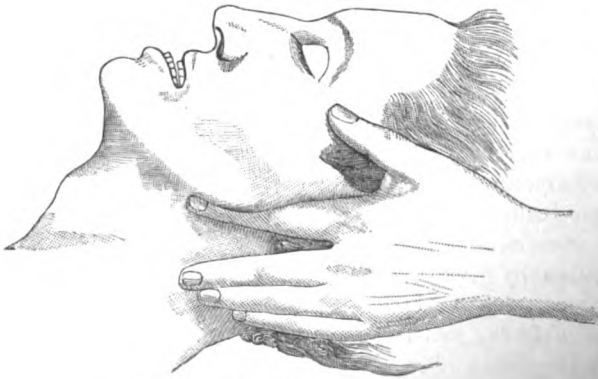

FIG. 10.—Pressing the jaw forward.

of the base of the tongue are separated, and its base depressed and drawn forward.

The treatment for the relief of poisoning, due either to an overdose of ether or chloroform, is substantially the same. Successful treatment

will depend not only upon the presence of mind of the surgeon, but upon the precautionary preparations which have been made for such a contingency, as well as the rapidity and force with which the remedies are applied.

The anæsthetic must be stopped at once; the head lowered and the tongue pulled forward; windows and doors opened to admit fresh air; artificial respiration (Figs. 11 and 12); flagellation of the face and chest by towels wet with cold water; hypodermic injections of brandy

whisky, or ammonia; inhalation of nitrite of amyl, and the use of electricity employed. It is not intended that these remedies shall be used in the order mentioned; but the surgeon and his assistants will find their time and thoughts occupied in carrying them into execution—such of them as may admit of instant application. Under no con-

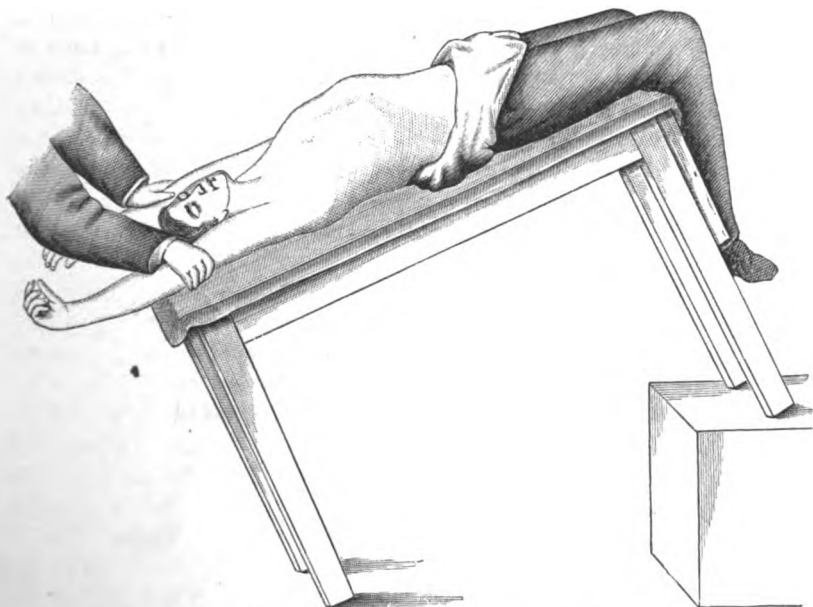

FIG. 11.—Artificial respiration—first movement.

sideration must the efforts of resuscitation be allowed to flag, or be stopped, until every hope of saving the life has some time since passed.*

Intestinal Etherization.—Since the appearance in the “Lyon médical” of March 30, 1884, of M. Mollière’s article, calling the attention of the profession to the feasibility of etherization by the rectum and setting forth the advantages to be gained thereby, not a few prominent members of the profession have made trial of it. This mode of administration is a simple one. The ether is put into a bottle of suitable size—holding four or five ounces—with which a rubber tube of convenient length, terminating in a nozzle, is connected. The bottle containing the ether is placed in water of a temperature of 120° to

* In performing artificial respiration the movements should be done slowly and with a regularity similar to the normal act of breathing. The arms upward and downward with the rapidity of a pump-handle is irritating; yet, under the influence of exciting surroundings, such attention are not infrequently made.

140° Fahr., and the nozzle inserted into the rectum of the patient. The ether vapor resulting from the ebullition passes through the tube into the rectum and is absorbed by the intestinal mucous membrane. An apparatus that is especially devised for the rectal administration (Fig. 13) simplifies the procedure somewhat. The advantages claimed for this method by Mollière are not, as yet, verified by American surgeons. At the present time, therefore, this method can not be said to equal the older one, except, perhaps, for operations about the face, or when ether is contra-indicated on account of the irritation it causes the mucous membranes of the respiratory apparatus, especially if they be diseased. And, even under these conditions, the number of fatal cases already reported as due to its use are evidence, as yet, of the greater safety of the old plan.

It is not unlikely that it may prove serviceable in intestinal obstruc-




FIG. 12.—Artificial respiration—second movement.

tion due to invagination, inasmuch as the distention and relaxation of the intestinal walls which it causes may overcome their abnormal relations.

Local Anæsthesia.—Although there are numerous agents in use for this purpose, ether possesses the greatest number of practical advantages. The following instrument (Fig. 14) is the one commonly used for purposes of local anæsthesia, and is employed in those minor

operations which can be quickly done. The pain that follows the return of sensibility to the benumbed parts is often more severe and prolonged than the immediate suffering from the operation without its use. The tissues should not be frozen, but benumbed; since to freeze them increases the pain and retards repair.

Cocaine. — Solutions of this important drug can be employed both hypodermically and endermically in many minor surgical operations. Ten to twenty drops of a five-per-cent. solution injected at the site of the operation will usually, in a few minutes, render the part insensible to pain. It can be applied to mucous surfaces, like those of the nose and pharynx, by means of a spray. It is sometimes employed in the urethra to obviate the pain and irritation incident to the passage of instruments into this canal. It is proper for me to state in this connection, however,

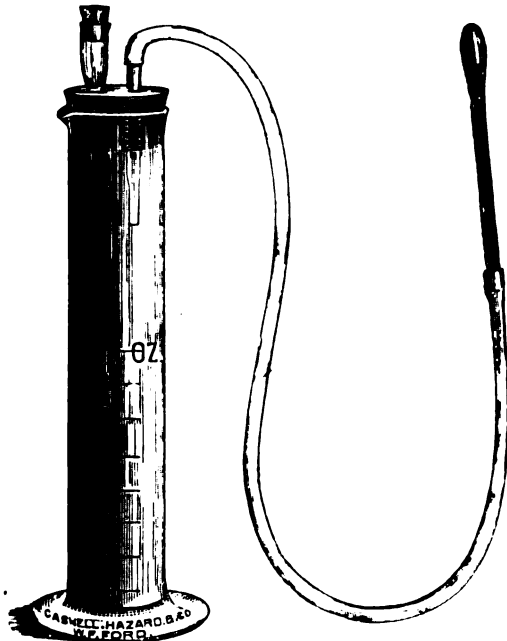


FIG. 13.--Apparatus for intestinal etherization.

that it should never be employed in any instance when the sensations of the patient are necessary to guide the operator in his action.

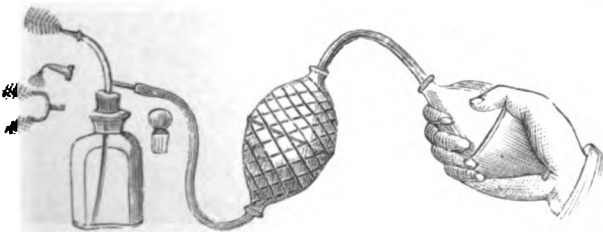


FIG. 14.—Richardson's atomizer.

There is reason to believe that even a small dose may, in rare instances, cause alarming symptoms of depression; still, it seems to be proved that its unfavorable constitutional effect may be obviated, while its local effect is increased and prolonged, by obstructing the return circulation from the part to which it has been applied.

INSTRUMENTS NECESSARY FOR THE PERFORMANCE OF OPERATIONS.

The instruments necessary for the performance of an operation must, of necessity, be regulated by its magnitude and nature. They can, however, for the sake of brevity, be divided into those in general use, and, those for special purposes. The ones in general use include scalpels and bistouries of various forms (Fig. 15), thumb-forceps, grooved directors, and scissors. Those for special purposes are used in performing the operations which, in most instances, caused their creation. These will be considered in connection with the operation to which they are particularly adapted.

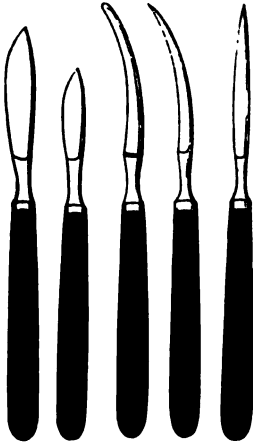


FIG. 15.—Scalpels and Bistouries.

Method of Holding the Scalpel.—Three positions are commonly recommended, each of which is subdivided into two. The basis of the positions rests upon the manner of holding the ordinary table-knife, the pen, and the violin-bow.

Figs. 16 and 17 represent the subdivisions of the first position; they indicate that force or firmness are desired. Figs. 18 and 19 represent the subdivisions of the second position. These are taken when quick, delicate, and precise movements are required. Figs. 20 and 21 are the subdivisions of the third position, and are employed when caution is used in conjunction with delicacy in cutting.

These positions are more essential to graceful than to successful operating.

Thumb-Forceps (Fig. 22) are used in connection with the scalpel or scissors. They are employed to pick up tissues like the fascia, etc., which are to be incised at the point grasped for the purpose of inserting the grooved director. The scalpel or bistoury should be held at nearly a right angle to the forceps when the incision is made, especially when important structures lie immediately beneath (Fig. 23).

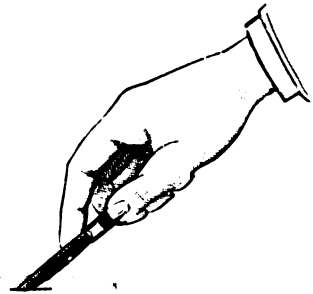


FIG. 16.

The Grooved Director (Fig. 24) is used to raise the tissues which are to be divided with caution. It should be five or six inches in length, depending upon the length of the incision and the depth of the dissection to which it is to be inserted; flexible, with a broad ex-

tremity to grasp, and a pocket at the end of the groove to arrest the point of the knife or scissors. It should not be pushed beyond the

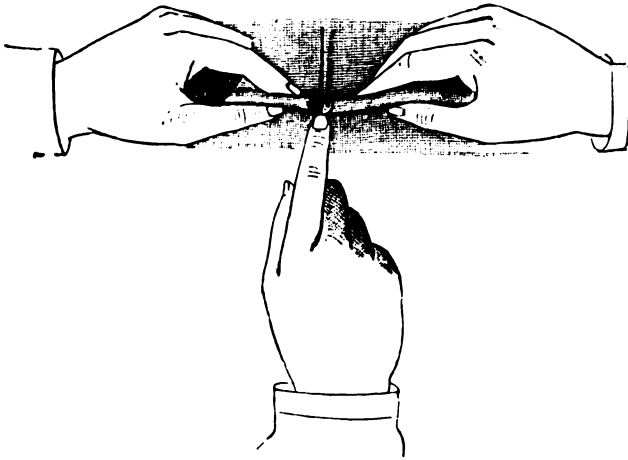


FIG. 17.

extremities of the external incision, because of the danger of making pockets in the soft parts, which will impede drainage. The tissues



FIG. 18.

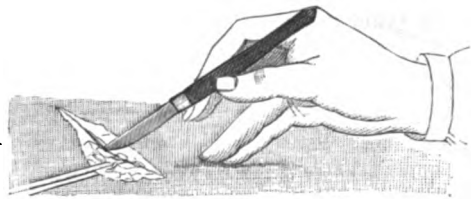


FIG. 19.

raised upon the director must not be divided beyond the angles of the external incision. Care should be taken when the director is passed between a serous membrane and its superimposed fascia that the mem-



FIG. 20.




FIG. 21.

brane does not fold over the advancing extremity, thereby causing it to be punctured or divided by the knife or scissors.

The Scissors.—They are used as a substitute for the scalpel in incisions of great depth, combined with limited space and a necessity

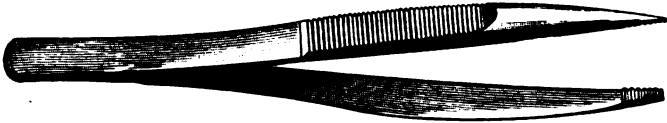


FIG. 22.—Thumb forceps.

for caution. Less hemorrhage follows their use than from the scalpel, owing to the crushing nature of their force. They should be more or

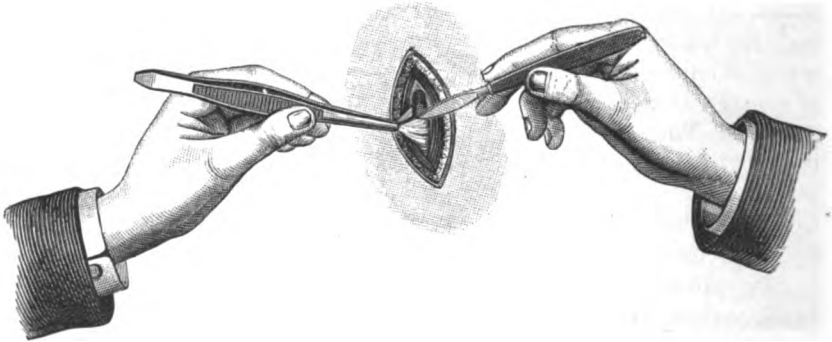


FIG. 23.—Nicking fascia.

less angular, to accommodate them to the depth of the operation-wound (Figs. 25 and 26).

Incisions.—The varieties of incisions are numerous, and are named from the shape which they take. The outlines of incisions are controlled very largely by the underlying anatomy, the desire to secure good drainage, and to avoid disfiguring the patient. There is a greater danger of making an incision too short than too long; and of the two, the former is the greater evil. A long, deep, clean-cut



FIG. 24.—Grooved director.

incision will drain better and heal more quickly than a short deep one bounded by tissues which have been disturbed by the efforts to accomplish a definite purpose within a too limited space. The various forms of incisions will appear in connection with the operations to which they are applicable.

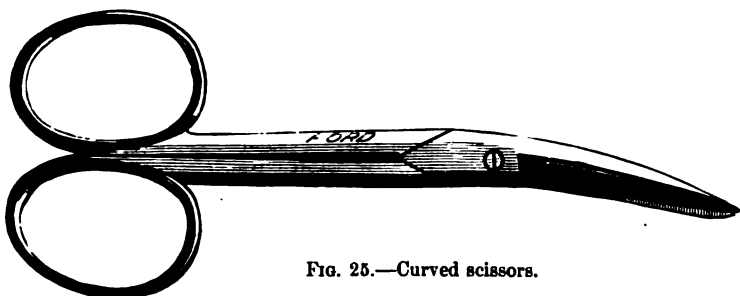


FIG. 25.—Curved scissors.

Instruments should be Plain.—All instruments associated with surgery should, when practicable, be constructed in a plain and substantial manner. The handles and shanks of the knives should be smooth and closely fitted, or, what is better, the entire instrument should be made of metal and be highly polished. The inequalities of instruments tend to catch impurities, and should never be tolerated when they but serve to embellish the implement.

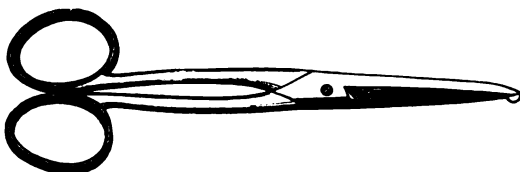


FIG. 26.—Straight probe-pointed scissors.

Receptacle for Instruments.—It is better that all instruments be made aseptic before they are employed; for this purpose, a shallow tray of suitable dimensions should be filled with an antiseptic fluid, and the instruments immersed therein for an hour or two before they are used. This tray, with the contents, should be placed at a convenient distance, in order that the instruments may be taken directly from it when needed. If they are to be again required, they should be returned to the tray as soon as used.

Operating-Table.—The patient should always be placed upon a regular operating-table, or an ordinary table of sufficient height to suit the convenience of the surgeon. To operate upon a bed or lounge, as is often done, not only cripples the resources of the surgeon, but robs him, too often, of a suitable light, to say nothing of the soiling of the bedding. There are numerous styles of operating-tables, many of which are of very ingenious construction; they are, however, much better suited for hospital than private practice. The ordinary table, covered by an old quilt and rubber cloth, will meet all common indications.

Empty Vessels.—There should always be a good supply of empty pails and basins to receive the waste-water, soiled linen, amputated parts, etc. At least one empty basin should be provided to receive the soiled sponges, otherwise they may fall upon the floor or table, and be stepped upon or lost. Two pails of antiseptic water, one hot and one

cold, should be provided to wash the sponges during, and the hands and instruments after the operation ; for the latter purpose hot water is better.

Clean Towels and Old Linen.—An abundance of these should be at hand, and for obvious reasons. However, if the operation is being conducted on strict antiseptic principles, they must not be used until after the wound is dressed ; unless they be, at first, saturated with an antiseptic solution.

Antiseptic Solutions must be abundantly provided and used in the place of water, by all who are obliged to handle the undressed wound or the instruments which are to be brought in contact with it. Carbolic acid is more often used than all the others combined. It is cheap, efficient, and easily obtained. Two solutions are commonly employed : one called the weaker, and the other the stronger solution. The latter can be made in the following manner :

Carbolic-acid crystals	1 part.
Alcohol	1 “
Water.....	20 parts.

This is employed to wash the wound before and subsequent to an operation. It is used for the spray, and to purify all the instruments ; it may be used to wash the hands prior to operating, but this strength is objectionable, since it often benumbs the keen sense of touch and otherwise causes them to feel disagreeable. The weaker solution is made by taking—

Carbolic-acid crystals	1 part.
Alcohol	1 “
Water.....	40 parts.

This is employed for the general purpose of cleanliness, and has, therefore, a somewhat more extended range of usefulness.

Carbolic acid is often combined with oleaginous substances in the proportions of one of the acid to five or ten of the substance, although it is thought that the antiseptic power of the acid is lessened if not entirely prevented, by all such combinations. Ligatures may be soaked in these preparations, and lint be saturated with them and applied directly to the raw surfaces. The objections to carbolic acid are its offensive odor, and liability to produce poisoning. The former can be tolerated, while the latter can be prevented in nearly all instances by not allowing the strong solution to become confined within the tissues. Solutions of the chloride of zinc (1-15), iodine (1-500), sulpho-carbolate of zinc (1-80), bichloride of mercury (1-2,000 to 1-10,000), biniodide of mercury (1-2,000), a saturated solution of boracic acid, sulphurous acid, pure or diluted (1-2), or a saturated solution of iodoform and ether, are employed as washes, or modified applications for wounded surfaces. The objectionable odor of iodoform may be masked by adding to it one tenth of its weight of thymol, Tonka

bean, or balsam of Peru. The solutions of the bichloride of mercury (1-2,000 to 1-10,000) are deserving of especial consideration, inasmuch as they bid fair to supplant the carbolic-acid solutions as antiseptic agents; like the former, they are cheap, accessible, and efficient; unlike carbolic-acid solutions, however, they are inoffensive, more innocuous, and do not benumb the sensations of the operator. They should be freshly prepared before using, and their tendency to chemical transformation into the chloride, by exposure, counteracted by the addition of a small amount of common salt. The liability of mercurial poisoning from their use during an operation is of little practical importance. It is not advisable, however, to employ them for the purpose of the daily cleansing of wounds of larger size, since their constitutional effects may be produced. For this purpose they should not be used oftener than twice per week, and then they should be carefully drained from the wound cavity and the patient be rigidly scrutinized to detect the first manifestation of their constitutional effects. Peroxide of hydrogen is an efficient fluid for antiseptic purposes, but its use is not practicable on account of the difficulty of obtaining it.

Sponges.—The variety known as “surgeons’ sponges” are the best, although expensive. The larger sponges of a proper texture can be cut into pieces of a suitable size, thoroughly cleansed and disinfected, when they will answer all purposes. No sponge of whatever quality should be used till it has been thoroughly deprived of all foreign matters and disinfected. It is a good practice to select and cleanse a number of sponges, and keep them in a closed jar containing a strong solution of carbolic acid or other disinfectant until needed. They should not be repeatedly used; it is far more consistent with careful surgery to get a new supply in each individual case than to use them, even a second time, under the most favorable circumstances.

CHAPTER II.

AGENTS FOR CONTROLLING HEMORRHAGE.

The agents that arrest hemorrhage are multifarious and suited to all of its phases. They may be divided into the natural and artificial, each of which may be subdivided into the temporary and permanent. A natural agent is one interposed by nature; one which results as a natural consequence from an interference with the inherent tendencies or endowments of the vessels and blood. The principal temporary natural hemostatics consist of the contraction and retraction of

the inner coat of a divided or ligatured vessel, accompanied by the formation of a blood-clot within it. The contraction and retraction, to be perfect, require that the coats of the vessels be not diseased, and that they be properly constricted by the ligature or other force. The formation of the internal clot requires that a suitable distance, depending upon the size of the vessel, shall exist between the ligature and the collateral branches ; also, that the coats of the vessel be not greatly diseased.

These points are of importance in determining the site and feasibility of an operation. The permanent natural agent is the organization and contraction of the clot, thereby completely occluding the artery ; this result will depend largely upon the condition of the coats of the vessel, and has a very important bearing upon the possibility of that much to be dreaded sequel to an operation, secondary hemorrhage.

Artificial Hemostatics.—This class is always temporary. The following are the well-recognized ones in constant use : Cold, styptics, posture of the injured part, bandages of various forms, digital and instrumental pressure ; also, pressure by a simple, or a graduated compress, acupressure, torsion, forceps, serrefines, compressors, cautery, etc. ; finally, and best of all, the ligature.

Styptics, such as liquor ferri subsulphatis, tannin, etc., are frequently employed to check oozing ; hot water is especially indicated when the patient is debilitated or suffering from severe shocks. Liquor ferri subsulphatis is decidedly objectionable where union by first intention is desired, but is very serviceable when an antiseptic styptic is required.

Position.—Elevation or flexion of a limb serves to impede its circulation, and thereby lessens the tendency to hemorrhage. The reverse of this principle directs us to lower the head in prostration from loss of blood.

Bandages. — These may be divided into two distinct classes, the inelastic and elastic. The inelastic, or ordinary roller, is used to check capillary and venous oozing by applying it firmly over the bleeding part.

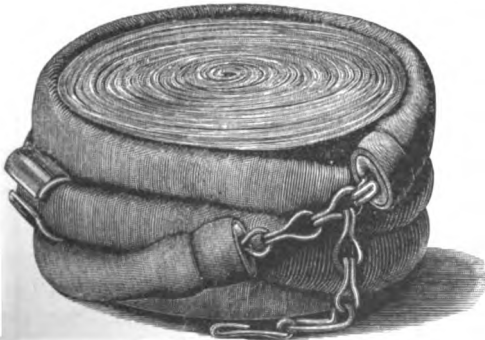

FIG. 27.—Elastic bandage.

The Elastic Bandage—of which Esmarch is the projector—is made of elastic webbing the width of an ordinary roller, and of sufficient length to meet the requirements (Fig. 27). It is to be applied firmly in a spiral manner to the limb, from the distal extremity upward (Fig. 28) to a good distance above the point to be oper-

ated upon, where it is supplemented by a rubber cord, or strap, passed firmly around the limb at this point, and fastened by a clasp or hook adapted to that special purpose (Figs. 29, 30, and 31). The bandage is then removed by unwinding it from above downward. The clamp devised by Langenbeck (Fig. 32) can be applied to the upper turns of the bandage, or, the upper turns can be tied together by a piece of an ordinary roller bandage, after which the rubber bandage is removed from below upward. The independent cord or strap can be fastened in a similar manner. After the removal of the bandages the limb will have a cadaverous aspect, being entirely devoid of blood, and the necessary operation can be performed and the wound dressed even without the least hemorrhage. This, like many other useful agents, has objectionable features. Its removal is often

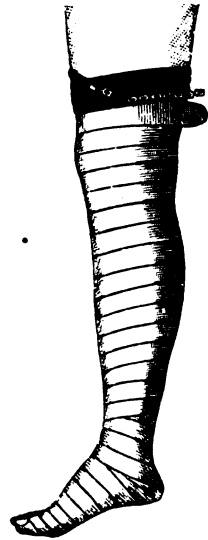


FIG. 28.—Elastic bandage applied.

followed by a large amount of persistent oozing ; its application may force into the circulation deleterious elements which

will form the basis of disease ; it has temporarily paralyzed the part to which it was applied, and caused transient disturbances of the general circulation. These latter are not, however, sufficiently important to contra-indicate its use. The tendency to severe oozing is an objection which must stand against it ; but its power to force improper products from diseased or injured parts into the general circulation can be obviated by omitting its application to those parts ; that is, by raising the limb and holding it till well depleted by the force of gravity, then applying it to the sound parts, above the seat of injury or disease, and using the rubber band as before. The elastic ban-

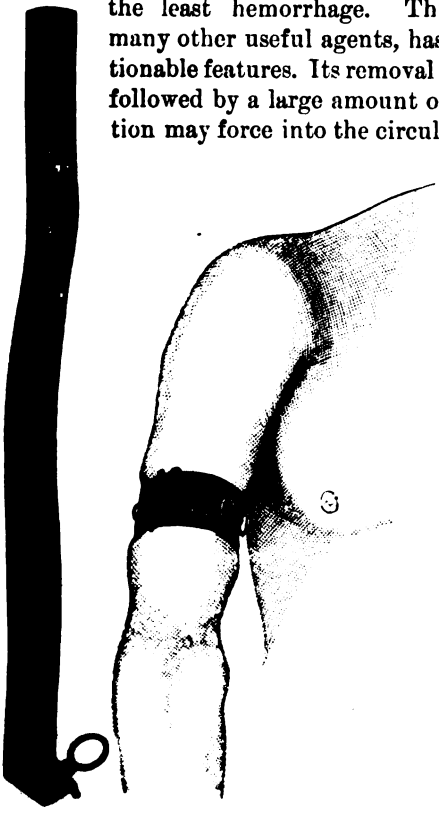


FIG. 29.—Nicaise's compression band.

dages can be made to serve another and very important purpose, that of forcing into the circulation of the trunk the blood in the extremi-

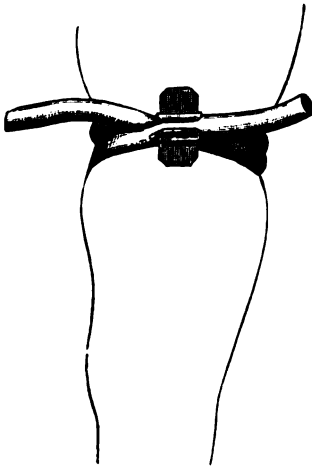


FIG. 30.—Foulis' fastening in position.

ties in cases of extreme prostration from hemorrhage. Martin's bandage (Fig. 33) is simply a rubber roller, and is used to meet the same indications as the former. It can be, however, more readily cleaned than a webbed one, and in this particular is preferable to it. Solid rubber rings of a suitable size to pass firmly over an extremity have been used as a substitute for the rubber bandage. In connection with the digits, and even the foot, hand, and wrist, they act quite well, but have not as yet gained the support of the profession.

Compresses.—Two kinds of compresses are in common use—the simple and the graduated. The former consists of several thicknesses of cloth, or other suitable material, folded into small dimensions and placed over the vessel, or upon the part which it is desired to compress, and held in position by a tightly drawn bandage or strip of adhesive plaster.

The graduated compress may be of the form of an inverted pyramid or cone, and oblong (Figs. 34, 35, and 36). Its apex should be firm and unyielding, to give an equal and constant pressure.

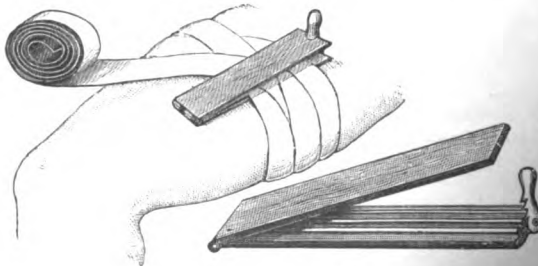


FIG. 32.—Langenbeck's clamp.

The whole arrangement can be made of superimposed layers of cloth, antiseptic gauze, or adhesive plaster, of a size and shape to symmetrically form its structure. It is employed to press upon the deep-seated vessels of the soft parts, and to arrest

ties in cases of extreme prostration from hemorrhage. Martin's bandage (Fig. 33) is simply a rubber roller, and is used to meet the same indications as the former. It can be, however, more readily cleaned than a webbed one, and in this particular is preferable to it. Solid rubber rings of a suitable size to pass firmly over an extremity have been used as a substitute for the rubber bandage. In connection with the digits, and even the foot, hand, and wrist, they act quite well, but have not as yet gained the support of the profession.




FIG. 31.—Foulis' fastening with rubber cord.

to give an equal and constant pressure. The whole arrangement can be made of superimposed layers of cloth, antiseptic gauze, or adhesive plaster, of a size and shape to symmetrically form its structure. It is employed

hemorrhage from within a deep wound or cavity. Care must be employed in properly adjusting it, else it may impede venous return, or cause pain by pressing upon large nervous trunks.

Digital pressure is the most available of all the pressure hemo-



FIG. 33.—Martin's bandage.




FIG. 34.—Pyramidal compress.

statics. It is constantly at hand, and often intuitively seeks to arrest the flow of blood. It is necessary only to add to a sensitive finger and a sensible brain, a knowledge of where and how to apply the force, to render this form of pressure of inestimable value. The vessel should be pressed against some resisting part; as, where it lies in contact with a bone. If the bone be deeply seated, the vessel must always be pressed toward it (Fig. 37), unless, as is done in many cases, the limb be grasped so as to bring the ends of the fingers against the vessel (Fig. 38). If blood flows from an open wound, direct pressure must be made




FIG. 35.—Oblong compress.

upon the bleeding points with one hand, while the other hastens to compress the main artery above the point of hemorrhage. It is not necessary to use great force to interrupt the blood current; moreover,



FIG. 36.—Conical compress.

to do so tires the arm and hand, and causes the patient much pain; use just force enough to interrupt all blood flow. The thumb of the right hand is the best digit to apply at first; afterward, it may be relieved in various ways by the aid of the fingers and thumbs of those in attendance. If secondary hemorrhage be anticipated, or have

occurred, the proper point for pressure on the body or limb must be indicated by some indelible substance, so that, in case of a sudden flow,

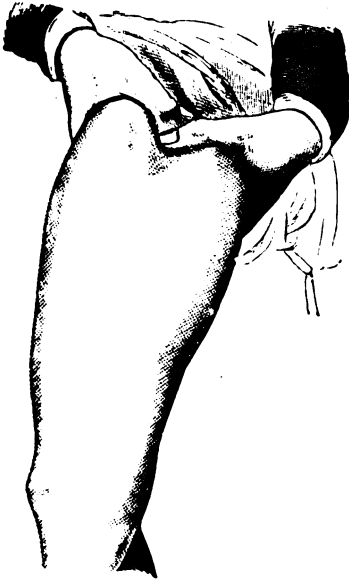


FIG. 37.—Digital compression of femoral.

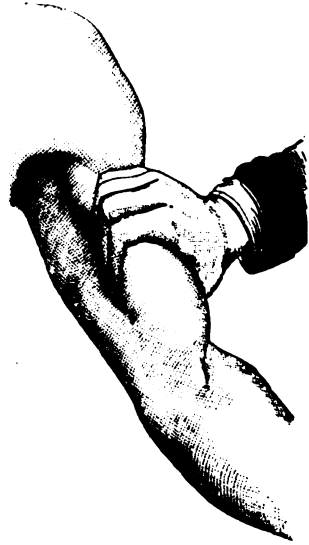

FIG. 38.—Digital compression of brachial.

any attendant can arrest it ; with this object in view, all the attendants must be instructed in the details of making pressure, and be thoroughly impressed with the necessity of constant vigilance and instant action.

Vessels that are inaccessible to digital compression can be controlled often by the handle of a key, or by a short crutch ; the applied extremity of either should always be covered by some soft material to prevent injuring the vessel.

Vessels that are inaccessible to digital compression can be controlled often by the handle of a key, or by a short crutch ; the applied extremity of either should always be covered by some soft material to prevent injuring the vessel.

Instrumental Pressure.—Under this heading are included the various forms of tourniquets and such other devices as are not directly connected with the adjustment of ligatures to bleeding vessels. The tourniquet in common use was invented by Petit.

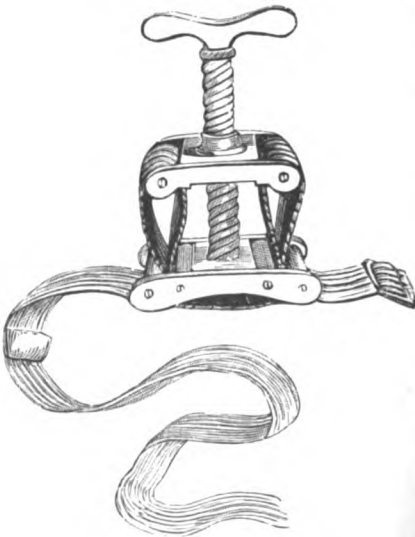


FIG. 39.—Petit's tourniquet.

and is no doubt familiar to all (Fig. 39). It should be cautiously applied, and so directed that the pressure will compress the vessel against

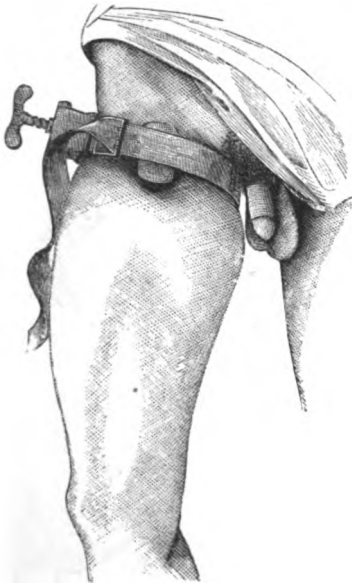

FIG. 40.—Tourniquet applied to femoral.




FIG. 41.—Tourniquet applied to brachial.

the bone, when possible. A simple and effective tourniquet can be extemporized by placing a roller bandage over the site of the vessel, confining it in position by a handkerchief passed around the arm. If the handkerchief be then tied and twisted by a stick, the circulation will be effectually stopped (Fig. 42).

Davy's Lever is an implement devised by the surgeon whose name it bears. It is employed for the especial purpose of controlling hemorrhage in amputations at the hip-joint. It is passed up the rectum in the direction of that canal a sufficient distance to make pressure on the common iliac artery on the side from which the limb is to be removed. The pressure is



Robert's in

is then carried to the right or left sufficiently to lie between the bodies of the lumbar vertebræ and the psoas-magnus muscle. The lower extremity must then be raised, to bring the requisite pressure upon the vessel (Fig. 43).

It has been employed by its designer and other surgeons with sig-




FIG. 45.—Davy's lever applied.

nal success. It can be more safely applied to the left than to the right side, on account of the left iliac artery being nearer to the rectum than the right. Its introduction must be preceded by an injection of sweet-oil, after which it must be cautiously introduced, and held in position by a gentle, though firm, pressure. If unnecessary force be used, it may tear or perforate the gut. The instrument in question is round, turned from ebony, and from eighteen to twenty inches in length. The surface is smooth, and its extremities rounded; its

largest diameter is about five eighths of an inch. It can be graduated so that the surgeon will be able to estimate the exact extent of its entrance to the bowel. Its shape has been variously modified to meet the requirements suggested by its more extended use.

Trendelenburg's Rod.—This is likewise used for the same purpose, but in an entirely different manner (Fig. 44). It is passed through the soft parts at such a depth as to include the whole thickness of the proposed flap. A strong rubber cord is then passed over its extremities with sufficient force to compress the vessels in the tissues above it. The flap can then be made and the vessels ligatured without loss of blood, after which the rod is withdrawn and the remaining flap made in a similar manner. The principle is a feasible one, but it has not yet been enough practiced to become an established method.

Acupressure.—This plan, as a means of controlling hemorrhage, was devised by Sir James Y. Simpson, and is used much less in this than in foreign countries. Acupressure is applied in many modified ways; the modifications may, however, be reduced practically to two in number: one, where the pin is carried through the soft parts under the vessel, and the point elevated and pushed through at an angle sufficient to cause it to tightly close the lumen of the artery.

If this be not effective, additional pressure can be made by passing beneath each extremity of the pin several turns of cotton yarn or of the ordinary silk ligature. This method is often employed to arrest hemorrhage from small branches in the palm of the hand and other similar situations, and should be supplemented by Buck's pin-conductor (Fig. 48), which is passed beneath the vessel and out through the integument; then the pin is inserted into its open extremity and carried through by withdrawing the needle. The second method is the reverse of the first, the pin resting upon and pressing the vessel downward upon the deep-seated tissue, instead of upward against the superficial. The distance from the end of the vessel at which the pressure is applied depends upon its size; if large, within one-half inch; if smaller, the distance can be lessened proportionately to its size.

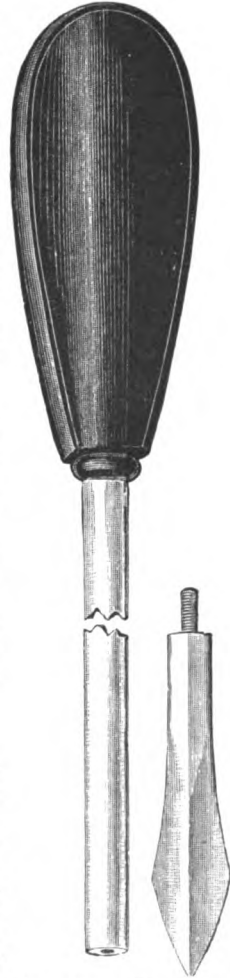


FIG. 44. — Trendelenburg's rod.

Circumclusion, torsoclusion, and retroclusion are variations of the method of pin-pressure produced either by twisting or compressing the

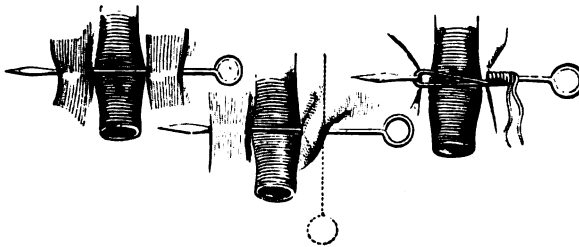


FIG. 45.—Pin above vessel.

FIG. 46.—Oblique insertion of pin.

FIG. 47.—Pin beneath vessel.

caliber of the vessel. These various methods seem to possess but one distinct practical advantage over the occlusion of the same channels by catgut ligature; they can be more safely ap-

plied to vessels with brittle coats due to atheromatous and other changes. The minute description of the various modifications of acupressure can be found in the text-books of the day. *The pins*, which are made of gold, silver, steel, and iron, are of various lengths; they have glass heads and differently shaped points. A further description or an illustration is not necessary, since they can be satisfactorily ordered. *Shawl-pins*, ordinary pins and needles, can be substituted, if the exigencies of the case require it.

Torsion. — Torsion is not as modern a procedure as its limited employment would warrant the belief. It consists in thoroughly isolating and drawing down the vessel, seizing it firmly with a pair of forceps, about one-half inch above its extremity, and twisting the end several times till its resist-

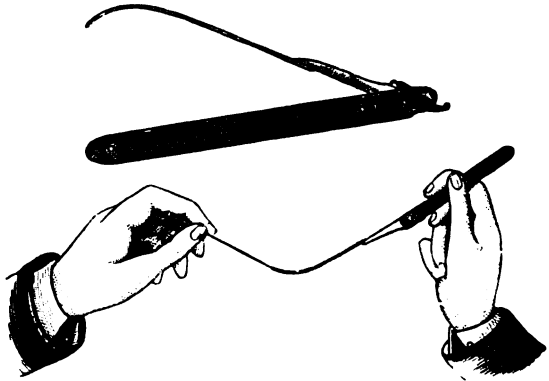


FIG. 48.—Buck's needle conductor.

ance is overcome (Fig. 49); care being taken not to twist it off. The blood is then allowed to impinge upon the twisted portion before the vessel is released, to test the completeness of the occlusion. The twisting produces a mutilation and breaking up of the coats of the vessel, which occlude its caliber, and cause a rapid formation of the internal clot. It is evident, if the coats be diseased and brittle, that much caution is necessary in twisting them, else a good basis for the occurrence of secondary hemorrhage will be established. Torsion-forceps, which combine in one instrument the hold-

ing and twisting forceps, are far more convenient (Fig. 50). Torsion as a substitute for the ligature is not considered with much favor in this country, except in individual instances. It is commonly employed, however, to check the small bleeding points seen on the surface of freshly cut wounds.

Forceps, Serrefines, and Tenacula.—Since these instruments are closely associated in common usefulness, they can be spoken of in connection with each other. The spring-catch fenestrated forceps are the best. There are two patterns of these: Liston's (Fig. 51), and those devised by Prof. Hamilton (Fig. 52).*

The expansion of the fenestrated extremity carries the ligature around the vessel, rendering it practically impossible to tie the end of the instrument, as in the case of the simple Liston forceps (Fig. 53).

Liston's mouse-tooth forceps, while they are not suitable for the common purpose of catching bleeding vessels, are nevertheless of great




FIG. 49.—Torsion of an artery.

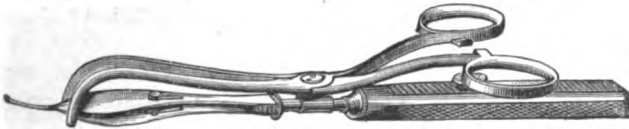


FIG. 50.—Hewson's torsion forceps.

service in securing bleeding points on flat surfaces, especially when surrounded by dense tissues.

The serrefine-forceps are of great utility to control bleeding points

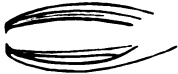

FIG. 51.—Liston's spring-catch fenestrated artery forceps.

during an operation. They can be easily and quickly adjusted, and, by their pressure on the coats of the small vessels, the necessity of afterward using a ligature may be obviated.

They can be used to catch and control bleeding points to which the

* The slide-catch arterial forceps of Esmarch are strong and serviceable, although they can not be so quickly applied as the snap-catch varieties.

application of a ligature is impossible, and even be allowed to remain upon the vessel till all danger of bleeding has subsided. There are

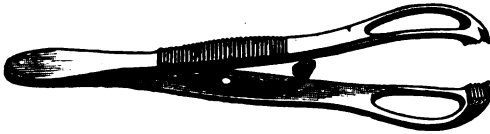


FIG. 52.—Hamilton's (F. H.) artery forceps.

several varieties of these instruments. The forcep-serrefine, which is the largest (Fig. 54); the angular and straight, and those of Langenbeck (Fig. 55). The first are admirably adapted to controlling large vessels, and, by their grasping and

self-retaining forces, can be employed in connection with other tissues. Dr. J. L. Little, of this city, devised a forcep-serrefine having a fenestrated biting extremity, resembling in all practical respects the extremity of the fenestrated artery forceps. The one devised by Gross (Fig. 57) can be attached to the bleeding point, the handle unscrewed, and the blades permitted to remain until all danger of bleeding has ceased. The smaller ones (Figs. 55 and 56) are employed to catch small bleeding points.



FIG. 53.—Liston's mouse-tooth forceps.

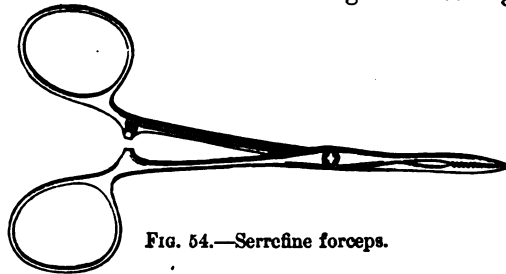


FIG. 54.—Serrefine forceps.

Milne's compressing forceps (Fig. 58) are closely allied in principle to the serrefine; they are likewise useful for compressing the

smaller arteries in their course through the soft tissues, as the coronary arteries in the operation for hare-lip. Langenbeck's are also admirable for a similar purpose.

Tenaculum (Fig. 59).— This is used to pick up and draw vessels from the soft parts. If the extremity of a vessel be too short to be ligatured by the aid of forceps, it can be trans-



FIG. 55.—Langenbeck's serrefine.

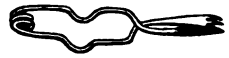

FIG. 56.—Wire serrefine.

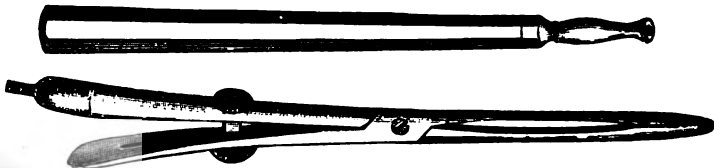


FIG. 57.—Gross' artery compressor.

fixed along with a small portion of the contiguous soft parts by the tenaculum, and a ligature thrown around the combined tissues (Fig. 60). If a nick be made on either side of the tissues raised by the tenaculum, the ligature can be more securely applied and the vessel more firmly grasped.

Prince's tenaculum forceps combine the principles of both instruments, and can be used with advantage (Fig. 62).

The arterial compressor of Speir, of Brooklyn (Fig. 61), is an instrument of undoubted efficacy, but the advantages which it is said to possess over the ordinary ligatures are not of enough importance to commend it to general use. A small portion of the vessel is isolated and its hook-like extremity passed around it; the handle is then turned until the coats are compressed sufficiently to divide the innermost, as is accomplished in the tightening of the ordinary ligature.

Cautery.—This remedy,

once a universal means of controlling hemorrhage, has now but a limited application. There are three varieties of cautery in common use: the *actual*, the *thermo-* and *galvano-cauteries*. The actual cautery requires the cautery irons

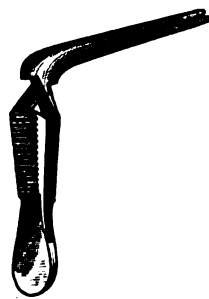


FIG. 58.—Milne's artery compressor.

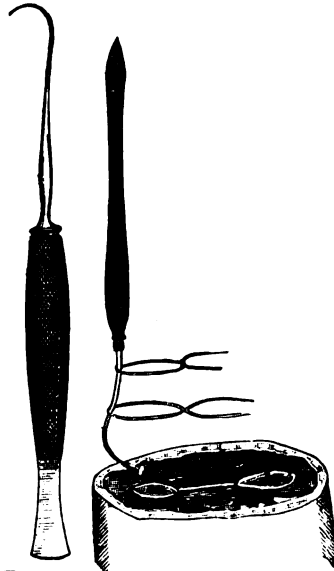


FIG. 59.—Tenaculum. FIG. 60.—Application of tenaculum to vessels.




FIG. 61.—Speir's artery compressor.

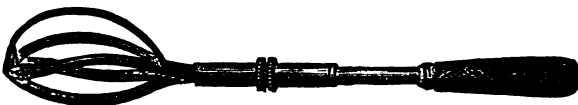

FIG. 62.—Prince's Tenaculum forceps.

(Fig. 63), which should be accompanied by the blow-pipe (Fig. 64), although they can be heated by ordinary means. The blow-pipe is by far

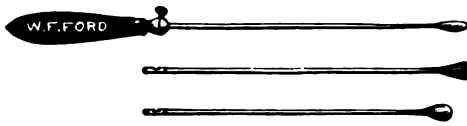


FIG. 63.—Cautery irons.

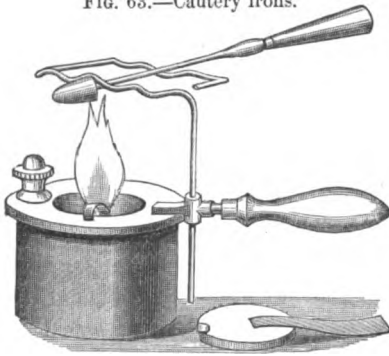


FIG. 64.—Blow-pipe.

the best, since during the summer months, or in unfavorable situations, when great haste is necessary, the domestic means of heating them will be inadequate. The irons can be made incandescent, or of a dull red color; the latter is the better, since it burns more deeply and is less liable to be followed by secondary hemorrhage.

Thermo-cautery.—The instrument designed by M. Paquelin for this purpose is exceedingly ingenious. It consists of a thoroughly isolated hollow handle,

provided with three movable platinum cauterizers, into which, after they have been heated in the flame of a spirit lamp, a continuous stream of benzine vapor is introduced by the means of a double spray bulb connected by a tube with the bottle containing it (Fig. 65); this

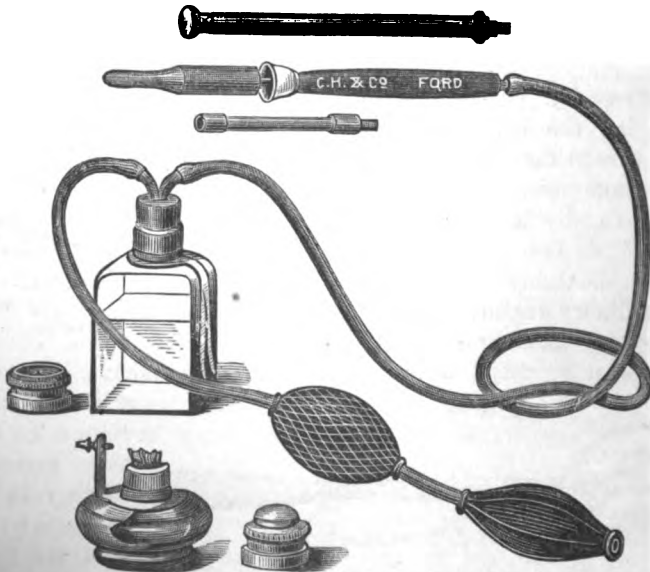


FIG. 65.—Paquelin's thermo-cautery.

brings the cauteries quickly to the required temperature, which can be maintained for an indefinite length of time by squeezing the rubber bulb. The range of the usefulness of this instrument is more extended than the former. It is used, not only for the same purposes, but can be employed as a cutting implement for the removal of morbid growths, etc., when union by first intention becomes a lesser consideration than the annoyance from primary hemorrhage.

Galvano-cautery.—This method is chiefly employed in connection with uterine surgery, although it is a proper expedient in connection with all operations where the use of the *écraseur* is admissible.

Ligatures.—The ligature is by far the best general agent for con-

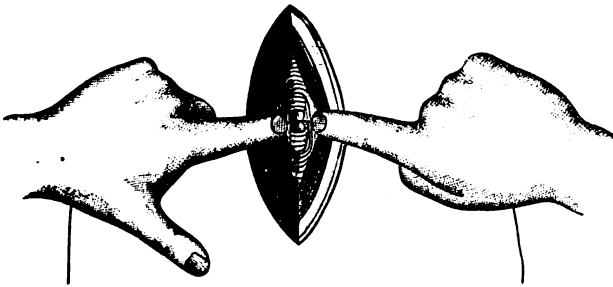


FIG. 66.—Tying a ligature.

trolling hemorrhage. It can be readily applied, is easily portable, and can always be obtained in some form. Ligatures may be classified according to their nature into *organic* and *inorganic*. The latter are very infrequently used, and then in the form of fine silver or iron wire, which is looped rather than tied around the vessel. The organic comprise the hemp, silk, and catgut varieties, which should be made at least from twelve to sixteen inches in length, depending on the depth of the wound in which they are to be applied. They must be of sufficient strength to withstand the traction necessary to cause complete occlusion of the vessel. Their size must depend somewhat upon the force to be employed in tying. The requisite force to properly occlude a vessel can not be estimated by ounces or pounds, but is largely a matter of experience. The traction should be made steadily, and over the ends of the forefingers or thumbs, without disturbing the relations of the vessel to its surrounding parts (Fig. 66). The giving away of the inner coat of a vessel indicates that the ligature is drawn sufficiently tight. This can not be felt, however, except in connection with the larger vessels. Great caution is to be exercised to prevent any tissues other than the walls of the vessel being included in the grasp of the ligature. If a nerve be included the patient will be tormented by constant pain, which may not cease even with the disappearance of the constricting agent. All tissues, other than the coats

of the vessel, not only cause additional irritation, but delay the separation of the ligature.

Knots.—The security of the ligature depends very much on the kind of knot tied. The surgeon's knot is tied by making two turns of the ligature at first instead of one (Fig. 67); it will not slip when drawn tightly, and should always be employed when the knot is to be made beyond the sight of the surgeon, otherwise the first half of it may slip without his knowledge, thereby resulting in an imperfect ligaturing of the vessel. It sometimes happens, owing to the ligature becoming soaked, that this knot can not be drawn as tightly as one with a




FIG. 67.—Surgeon's knot.




FIG. 68.—Reef-knot.




FIG. 69.—Granny knot.

single turn. If it binds in this manner, the tying of the second part will leave the whole very insecure.

The Reef or Square Knot.—Either this, or the preceding, must always be employed in tying a vessel. The reef-knot (Fig. 68) is easily confounded with the "granny knot" (Fig. 69), which is insecure. The following description of the method of tying the reef-knot, taken from Heath, is too graphic to be substituted by any other: "The ligature is to be held in the palm of the right hand between the thumb and finger; the end is then to be drawn around the forefinger and carried across the right thumb and inserted between the fourth fingers of the right hand (Fig. 70). The left hand seizes the other end, and the ends of the threads are being done in Fig. 71. There will now be no difficul-

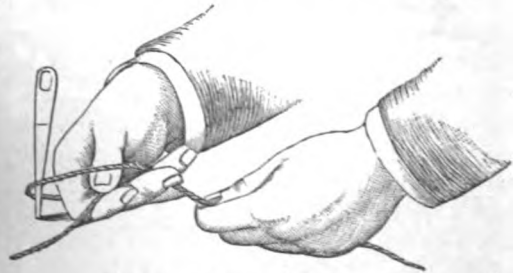

FIG. 70.—First step in tying reef-knot.

ties will now be no difficul-

ty in drawing the knot thus formed tight with the forefingers, or, if preferred, with the thumbs (Fig. 72). To complete the knot by making another tie, the same manœuvre is to be effected, taking care always to begin with the opposite hand to that which began before. It is quite immaterial which hand begins the first part of the knot, so long as the opposite one always begins the second part; in this way, with a little practice, the reef-knot may be unerringly tied with the greatest rapidity." When the knot is completed, it will be seen




FIG. 71.—Second step.

that the ends of the ligatures lie parallel with and in contact with the portion of the ligature which surrounds the vessel (Fig. 68).

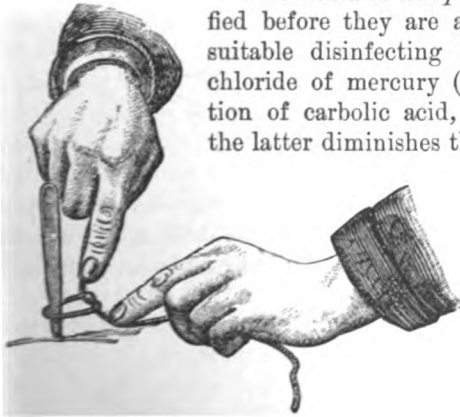


FIG. 72.—Third step.

The *silk* and *hemp* ligatures must be well purified before they are applied by being placed in a suitable disinfecting solution. A solution of bichloride of mercury (1-1,500), or the strong solution of carbolic acid, may be employed, although the latter diminishes the strength of the ligature by impairing the integrity of its fiber.

If the ligatures be wound on small glass bobbins and placed in suitably sized large-mouthed bottles containing the antiseptic fluid for a week or ten days, then transferred to similar bottles containing absolute alcohol, their ends escaping through a

narrow groove in the side of the cork, they can be unwound as required without exposing the remaining portions to external influences. If uncarbolicized, they should be freshly waxed. After tying, one end may be cut short and the other allowed to hang from the wound.

The iron-dyed silk ligature recommended by Pancoast is credited by some with the attributes of the aseptic ones.

Catgut ligatures are now in established use in surgery; they, like other ligatures, vary in size and strength, and a selection must be

made in accordance with the purposes in view. If properly chosen they can be relied upon to fulfill the ordinary indications of the silk ligature. Crude catgut of assorted sizes can be purchased of dealers in surgical supplies and be asepticized to suit the fancy of the surgeon, or it may be procured already prepared for use after the methods in common practice. Catgut can be tied by the surgeon's or the reef-knot, but is less secure than silk. A third tie should always be added to whichever of the two is employed. The ends are cut close to the point of tying, and the wound closed irrespective of the presence of the ligature. Aseptic kangaroo tendon, silkworm gut, aortic tissue, whalebone tissue, etc., are also commended for special purposes, but they possess a greater novelty than practical utility.

The crude material is variously prepared to conform to the demands of asepsis, ready absorption, and non-irritation. It can be placed in a bichloride solution—1 to 100 of water—for ten minutes, then into a weaker one—1 to 1,000—for twelve or fourteen hours, and afterward wound on bobbins and kept for ready use in absolute alcohol in the manner before described; or it may be prepared after the method of Kocher, of Berne, by first putting it into the oil of juniper for twenty-four hours, and afterward into absolute alcohol. Ligatures prepared by these methods meet all of the indications admirably, and are devoid of the slipping tendencies of those kept in acid and oil after the manner of Mr. Lister. The following method of preparing ligatures was recommended by Lister, in his inaugural address of June 28, 1881 :

“Dissolve one part of chromic acid in 4,000 parts of distilled water, and add to the solution 200 parts of pure carbolic acid; into this liquid immediately put catgut equal in weight to the carbolic acid. At the end of forty-eight hours it is sufficiently prepared. Then it is to be removed from the solution, dried, and placed in one-to-five carbolized oil. It is then fit for use.” The dry chromicized catgut is not satisfactory, owing to its hardness and power of resisting absorption.

Assistants.—The number of efficient assistants necessary to conduct an operation with ease is modified by its character.

To *one* must be intrusted the administering of the anæsthetic, and watching the pulse, respiration, and circulation of the patient. By combining these duties the administrator of the anæsthetic becomes the immediate observer of its effects, and he must always be prepared to carry into execution the various expedients that are recommended in the complications attending anæsthesia. If the temporal and radial pulsations be compared before its administration, the assistant will be able to judge of one from the character of the other. He can then give the anæsthetic, hold forward the lower jaw to prevent swallowing the tongue (Fig. 10), and, with the finger on the temporal artery, he will be able to attend to the necessities of the case without any interruption.

To a *second* should be assigned the care of the instruments; handing them to the surgeon when asked for, and returning them to a place of safety after being used.

To a *third* may be intrusted the care of the sponges; he must always see to it that a suitable number be well squeezed and placed at the convenience of the operator.

To a *fourth* the ligatures should be given. He can first hold the limb, when necessary, after which he may either sponge or ligature the vessels, as best suits the circumstances of the case or the fancy of the operator. The securing of the bleeding points and the necessary sponging are best done by the operating surgeon; however, these are matters which will become self-regulating as the operation progresses. All assistants must be proficient, especially the one who ligatures the vessel, and the one who administers the anæsthetic. When the surgeon is not able to avail himself of a suitable number of assistants, he must then draw upon his own resources. This can be done by placing the sponges and instruments where they can be conveniently reached, when he can sponge, secure, and tie the vessels. If the circumstances demand it, he can at the same time control the administration of the anæsthetic. If the operation is to be antiseptic, the entire charge of the douching should be given to one assistant.

The patient should always be prepared for the operation. The physical, legal, and spiritual aspects of a preparation have been heretofore considered under various headings, consequently little remains to be advised other than to properly cleanse and shave the part to be operated upon.

CHAPTER III.

TREATMENT OF OPERATION-WOUNDS.

It is absolutely necessary to have the proper materials for uniting and dressing wounds, together with a knowledge of their use.

As soon as the operation is completed the wound should be washed thoroughly with the strong solution of carbolic acid, or other antiseptic, which not only purifies it, but serves to check the capillary oozing of the incised surfaces. The proper securing of the incised surfaces and the dressing of the wound involve three important considerations: 1, the retentive coaptation of the divided tissues; 2, perfect drainage; 3, the application of some suitable protective dressing. If union by first intention be a desideratum, the incised surfaces must be kept in perfect coaptation. For this purpose there are numerous means employed. The part bearing the wound should be so placed as

to avoid all muscular contraction, or undue tension of the soft parts. Strips of adhesive plaster with or without roller bandages, or simple compresses may meet the indications. These agents constitute the common dressings of a less recent date, and are at the present time open to the objection of interfering with union by first intention, except they be of an antiseptic nature.

Sutures may be classified with reference to their composition or method of arrangement. They are of either organic or inorganic nature.

Those of an organic nature are most commonly used; but which of these is the best is more a matter of personal preference than a surgical requirement. The silk, hemp, catgut, and horse-hair sutures belong to this class, and are respectively employed as best suits the preference of the surgeon. The silk and the hemp varieties are constantly employed, and if carbolized they cause but little irritation, may become absorbed, and, when present, can be removed without pain.

The proper introduction of sutures under all conditions requires needles of various shapes and sizes: the curved and straight; those with round and edged extremities. These are too familiar to all to require other than a passing mention. The curved are used in cavities and depressions; the straight on plane surfaces. Those with an edged extremity cut the tissues they pass through, while the smoother separate the tissues and avoid the hemorrhage that so often follows the track of the former. The latter are, however, inserted with greater difficulty.

Needle forceps, or holders (Figs. 73, 74, 75), should always be at

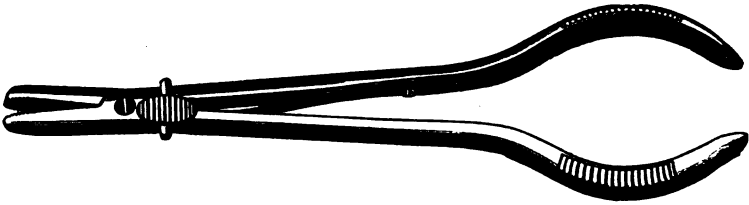


FIG. 73.—Stimson's needle forceps.

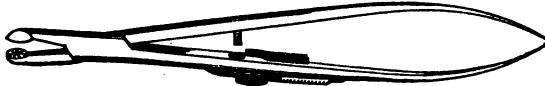

FIG. 74.—Prout's needle forceps.

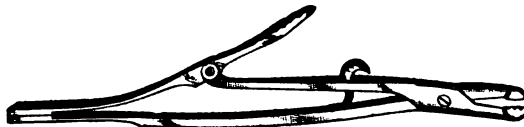


FIG. 75.—Sands' needle forceps.

hand to aid in conducting the needles steadily through the tissues. The instrument bearing the artery forceps at one end and the needle-holder at the other (Fig. 76) is an admirable and compact implement.




FIG. 76.—Combined forceps and needle-holder.

Horse-hair.—When carbolized, this causes but slight irritation, and is well adapted to those cases requiring but little force to maintain coaptation and where scarring from sutures is to be avoided.

Catgut as a suture possesses the same special advantages that belong to it as a ligature. It rarely produces irritation, and if allowed to remain will become absorbed without ulceration. If, however, much force is required to unite the wound, catgut is less reliable than silk.

Inorganic or Metallic Sutures.—Those in common use are the silver and iron wire. They can be retained *in situ* longer than the uncarbolized silk or hemp, with less danger from ulceration. Their application and removal, however, are attended with more pain than either of the others. The silver wire is more expensive than the iron; aside from this, it matters little which be used. The depth to which sutures should be passed, the distance between them, and their tension, depend upon the depth of the wound, and the tendency of its lips to separate. The object of all sutures is to hold the surfaces of wounds in close contact until union occurs. To accomplish this they must be carried to such depth, and be placed at such distances from each other, as will best accomplish the purpose. They can, if necessary, be supplemented by strips of adhesive plaster passed between them that have been heated by immersion in a hot solution of bichloride of mercury (1-500) (Fig. 77). Sutures must never be drawn too tightly (Fig. 79), or the tissues within their grasp will be strangulated, causing ulceration and disfigurement.

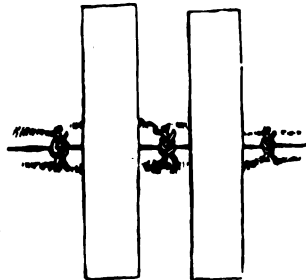


FIG. 77.—Antiseptic adhesive plaster between sutures.

If the integument within the grasp of a suture remain white after it is tightened, the suture must be loosened before the final dressing is completed. The length of time sutures should remain is to be governed by the danger of ulcera-

tion and disfigurement, also the tendency of the wound to open. In exposed portions of the body, they should be removed as soon as notable irritation is observed. The rapidity and extent of the ulcerative process can be lessened, by relieving any undue traction upon them, by strips of adhesive plaster or by other supporting means.

Different Forms of Sutures.—The interrupted, continuous, quilled, hare-lip, etc., are the forms in common use. The special varieties for intestinal sewing will be shown in connection with operations upon the intestines.

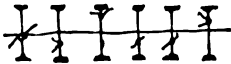


FIG. 78.—Interrupted suture.

The interrupted suture is the one in everyday use, and has a more general application than the other forms (Fig. 78). It is made by passing a needle armed with a well-prepared suture through the integument, from a line to a third of an inch or more from the borders of the wound, depending upon its size, depth, and retractive force. The ends are then united by a reef-knot, drawn with sufficient force to oppose the surfaces without puckering the skin (Fig. 79). The ends of the suture can be united at alternate sides of the wound, or at one of its points of exit alone.

The interrupted suture is the one in everyday use, and has a more general application than the other forms (Fig. 78). It is made by

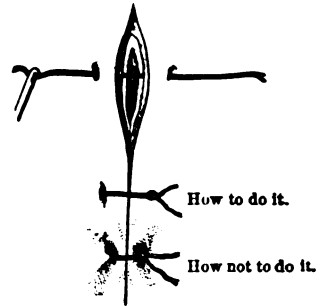


FIG. 79.—Tension of sutures.




FIG. 80.—Continuous, or glover's suture.

The latter is the better, since, if the dressings cling to the extremities, their removal is less liable to interfere with the line of coaptation.

The continuous suture, sometimes called the glover's suture (Fig. 80), is used to unite superficial wounds, and such others as require little force to secure a proper adjustment of the divided sur-

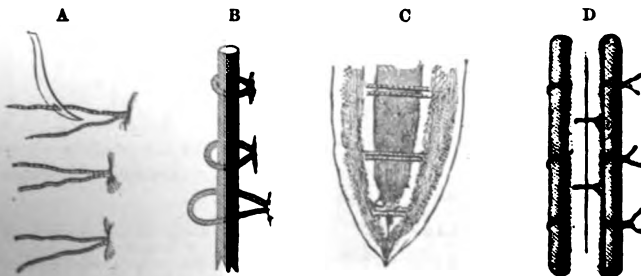


FIG. 81.—Quilled suture.

faces. This is made by passing the needle diagonally from one side of the wound over to the other.

The Quilled Suture.—This is made by passing several strong double threads through the lips of the wound, half an inch or so apart, and tying them over quills, wood, etc., while they lie parallel with the cut (Fig. 81). It is used about the vagina, perineum, etc., when deep gaps are to be closed.

The Twisted or Hare-lip Suture (Figs. 82 and 83).—This is made by pushing a pin through the edges of the wound, and passing cotton yarn around it to confine it in position (Fig. 83). The yarn should be changed as often as it becomes soiled. If it be properly carbolized before application, it lessens its tendency to cause irritation. An ordinary pin or needle can be used, although those specially adapted for the purpose are preferable (Fig. 84). They can be, if not spear-pointed, pushed or drawn through the tissues by aid of Post's (Fig. 85) or Buck's pin-carrier, after which the points should be nipped off and separated from the skin by a small strip of adhesive

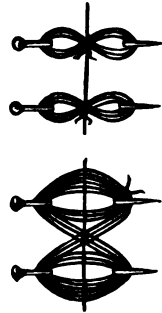


FIG. 82.—Hare-lip suture.

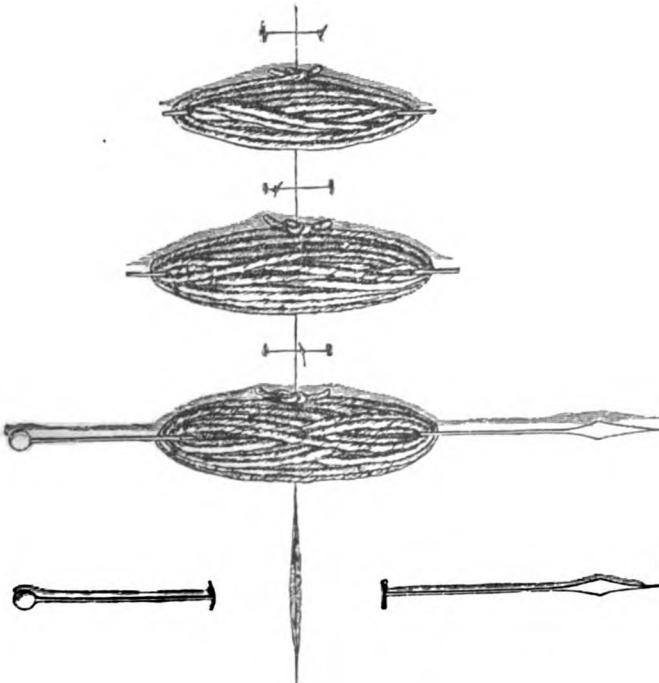


FIG. 83.—Hare-lip suture.

plaster. Pins with adjustable spear-shaped points can be employed and carried into position by the fingers of the operator (Fig. 86).

There are various other special forms of sutures which will be considered under their proper headings.

Drainage.—This is not only of the greatest importance in securing successful union of the divided surfaces, but also to the safety of the patient. Good drainage to a wound is as potent to its cleanliness, as is the good drainage of a dwelling to the healthfulness of its occupants. No one local condition will interfere so materially with the process of healing, or expose the patient to greater constitutional danger, than the collection and decomposition of fluids in a wound. Drainage may be secured through dependent incisions, or, better still, by the introduction into the wound of a drainage-tube. Horse-hairs or threads introduced into the wound in some cases answer quite well. The long extremities of the silk or linen ligatures, if allowed to extend from its most dependent portion, will drain it, though somewhat imperfectly.




FIG. 84. FIG. 85. FIG. 86.
 FIG. 84.—Hare-lip pins. FIG. 85.—Post's pin-carrier. FIG. 86.—Adjustable pointed pin.

Ellis' Drainage Spiral (Fig. 87), or that which is still more practically, the rubber drainage-tube (Fig. 88), will fulfill the indications more perfectly. An ordinary piece of black or white rubber tubing, of about one fourth of an inch in diameter, with holes in the sides at irregular intervals, can be inserted into the bottom of the wound cavity through its most dependent portion. Another can be introduced into the upper portion of the cavity through the uppermost angle of the wound. The size should



FIG. 87.—Ellis' drainage spiral.



FIG. 88.—Rubber drainage tube.

vary with the dimensions of the wound. They are more often too small than too large. They must be fastened in position

tion, or they may slip into the wound; this can be done by passing a thread through the projecting extremity and tying it around the limb. If a single tube be passed so as to protrude from both sides of the wound, it can be securely fastened by passing an ordinary safety pin through each extremity. However, it is better to use two short tubes

than one long one ; the use of the latter introduces into the wound a superfluous amount of rubber, which does not perform a duty commensurate with its presence. In either case it is necessary to allow for the swelling of the parts, else the pins or threads may cause constriction of the injured tissues. The outer extremities should then be cut off flush with the soft tissues. The wound can be washed through the upper tube, while all discharges will pass from the lower one. The length of time they should remain must depend upon the character and amount of the discharge. When the amount is small and of inoffensive nature, they can be removed. It must not be forgotten that the tubes, as foreign bodies, may excite the discharge which they are introduced to carry off.

The decalcified tubes of Neuber are admirable, although not sufficiently accessible to supplant the rubber ones ; moreover, they not infrequently become absorbed before the wound is sufficiently healed to properly dispense with their use. Several strands of the ordinary antiseptic catgut can be introduced together and retained in the wound ; they drain satisfactorily, and are easily absorbed. Chicken-bones, decalcified by a weak solution of hydrochloric acid, may be extemporized, and, while they are suitable substitutes for the rubber tubes, they are too hard to be absorbed, and consequently do not add materially to the surgeon's equipment. A drainage-tube can be pushed into position often, although it is better if it be aided by a director or probe inserted within it, either as a propelling agent or a guide. It may be pushed or drawn into place by the ordinary thumb-forceps ; the latter is the better if the wound be open.

Canalization.—This term is applied by Neuber to a method of establishing good drainage to a wound without the use of tubes. Shallow and deep canalization comprise its varieties. The former is the draining of shallow subcutaneous cavities by oval-shaped punctures a fourth of an inch or so in width through the integumentary laps at the most dependent portion of the wound. These punctures vary in number and situation to meet the demands of the case, and are made by a punch, in construction not unlike the leather-punch ; in fact, the latter may be employed as a suitable substitute. Deep canalization is directed to the drainage of deep wound cavities, such as are formed by the removal of the female breast, of the connective tissue from the axilla, and other deep wounds, which, when united by granulation, produce an objectionable amount of cicatricial tissue. The integument at either border of the wound is loosened from its deep connections to an extent sufficient to permit its borders to be easily drawn or slid into apposition with each other and carried to the bottom of the wound cavity, to which they are connected by sutures. The surface then appears concave or trough-like, and is covered by the depressed integument, which it is intended shall become united to the walls and floor of the cavity by first intention.

Protective Dressings.—These include the ordinary dressings, such as one who is a long way from the base of supplies, or not a believer in the modern methods, would employ: as covering the wound with a linen cloth kept moist with a weak solution of carbolic acid, or water; the application of adhesive plaster, and covering it with medicated cloths held in position by bandages or plasters. Of the modern methods, the one bearing the name of Lister, its designer, is deserving of especial mention, not only on account of its acknowledged worth, but also from the fact, that other measures involving similar principles are advocated, the same result being sought by the aid of different agents.

The requirements for the Lister treatment are the atomizer or spray, carbolic-acid solution, drainage-tube, protective, antiseptic gauze, Mackintosh, antiseptic catgut ligatures, and that everything to be brought in contact with the wound be made aseptic by a strong solution of carbolic acid or other proper fluid.

The *Antiseptic Spray Apparatus* consists of a kettle, lamp, spray-tube, and a bottle to contain the solution of a strong carbolic acid (Fig. 89). The spray is produced and directed upon the site of the operation before the first incision is made. It should be continued




FIG. 89.—Weir's spray apparatus.

through the whole operation, and until the wound is surrounded by the protective dressing. It is always to be used when the wound is redressed.

The *Protective*, which somewhat resembles oiled-silk, is placed over the wound and extended an inch or so from its border, with openings through it for the mouths of the drainage-tubes. A small piece of the antiseptic gauze wet in the strong solution of carbolic acid can be laid over and beyond the protective. Numerous layers—eight or ten—of the antiseptic gauze are then made to cover the part, their borders extending a good distance beyond the edge of the wound. Around

the whole is wrapped the Mackintosh, which is confined in position by bandages made of the antiseptic gauze.

This dressing can be removed on the second or third day, the wound washed out, protective and Mackintosh purified, and clean gauze substituted, after which it need not be examined again—other things being equal—within a week or ten days, unless the discharges soak through it.

At the present time the spray is less often employed than formerly. In place of it, the surface to be operated upon should be thoroughly scrubbed for three minutes with a brush and soap and water, and afterward washed with a strong solution (1-20) of carbolic acid (Kümmell) and some other suitable disinfectant, as aq. chlorinii or a solution of thymol, and the surfaces contiguous to it should be covered by towels saturated with the same disinfecting solution, which should be kept thoroughly wet by it during the operation. The operation-wound should be likewise thoroughly douched with some disinfecting fluid during the entire course of the procedure. In all other respects, however, the details are substantially similar to the preceding.

The Douching apparatus is easily made by siphoning the antiseptic solution from a receptacle through a long, small rubber tube, to the end of which is attached a metallic one that discharges the fluid upon the wound through a number of coarse openings at its extremity. The flow can be regulated by pinching the tube, or by the attachment of a regulator constructed to meet the indication.

The part to be operated upon should be isolated by means of rubber cloths, to prevent the patient's clothing becoming saturated by the antiseptic fluid, and by towels saturated by strong antiseptic solutions. If the operating table be tilted sidewise it will facilitate the escape of the fluid upon the floor, or into receptacles provided for the purpose.

Cotton-batting Dressing.—Cotton batting, or that which is better, borated, or salicylated cotton, is frequently employed as a protective dressing in place of the antiseptic gauze. The results obtained, warrant the belief that it is entitled to be considered worthy of an extended application. It exerts a very desirable uniform pressure upon the parts to which it is applied, thereby aiding coaptation and fostering union.

Combined Dressing.—Combined dressing is made by placing several thicknesses of borated or other variety of antiseptic batting between two layers of antiseptic gauze. This is shaped to suit the circumstances of the case and applied over the gauze that is placed in immediate contact with the wound and confined in position by antiseptic bandages (Fig. 90).

Iodoform Dressing.—Iodoform can be dissolved in ether, and after the operation thrown upon the incised surface by means of an ordinary

atomizer. The ether will evaporate and leave the iodoform evenly deposited over the incised surfaces.

It can be better applied, if pulverized, and blown into the wound by an insufflator. The wound is then closed by antiseptic sutures,

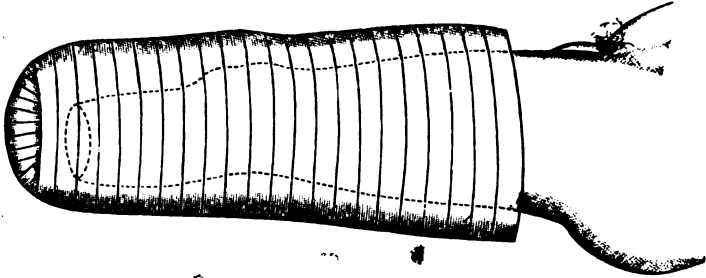


FIG. 90.—Antiseptic dressings in position.

drainage-tubes introduced, iodoform sprinkled upon the integument in the vicinity of the wound, and the other antiseptic dressings applied, which are bandaged in place and allowed to remain until they become soiled, when the wound is redressed as before. It is a common practice to sprinkle pulverized iodoform upon the immediate and contiguous surface of parts operated on, after the closure of the wound, as soon as the douche is stopped. The dressings are then applied as before.

The odor of iodoform, and its occasional deleterious effects upon the nervous system, of the patient, should make its free use upon large surfaces infrequent and cautious, especially if the wound be one of the scalp.

Iodoform gauze is made use of in many instances. It can be made extemporaneously, by rubbing iodoform into sterilized gauze, or by saturating sterilized gauze with an ethereal solution of iodoform. This variety of gauze seems, at the present time, to be indispensable in the treatment of deep wounds associated with the rectum, vagina, etc.

Peat Dressing.—Into a small carbolized gauze bag light peat or turf is introduced, combined with $2\frac{1}{2}$ per cent of iodoform; over this a large bag filled with carbolized peat is applied, and the whole bandaged firmly in position. The fine peat serves admirably to make equable pressure and absorb the discharges, and need not be re-applied until it has become soiled.

Coarse and fine jute, wood-wool, wood-pulp, moss, peat, saw-dust, etc., can each be made antiseptic if it be steeped six or eight hours in a solution of bichloride of mercury (1-1,000), with 5 per cent of glycerin, then wrung out and allowed to dry, when suitably sized pads or bags can be made, one inch or two thick, by aid of some variety of antiseptic gauze.

Gauze and cotton batting can each be made antiseptic, after the removal of the oily matters contained in their texture, if they be placed into a solution of bichloride of mercury 10 parts, water 2,240 parts, glycerin 250 parts, and allowed to stand for ten or twelve hours, then wrung out and dried.

It should not be forgotten that the bichloride of mercury is thought to be a somewhat unstable component, and it therefore becomes necessary to use the freshly prepared combinations of it. If a small amount of common salt be added to the solution, its stability is said to be better maintained.

Bichloride of Mercury Dressing.—By this method, the dangers attending the use of carbolic acid and iodoform are avoided, at the same time, a cheap and inoffensive substance is utilized. It is used with the spray (1-1,200) or as a wash for a wound (1-2,000-10,000). Sponges, ligatures, and sutures are soaked in solutions of it, varying in strength from 10 to 75 grains to the pint of water or alcohol, the latter being used for the ligatures and sutures, in which they are kept for three or four hours, thence removed to a much weaker one. Cat-gut can be treated in substantially the same manner, by allowing it to remain ten or twelve hours in the alcoholic solution, from which it is to be taken and introduced into a weaker one (one half of 1 per cent), containing a drachm or so of glycerin.

The protective dressing can be saturated with a strong solution (50 grains to the pint), and applied in the same manner as before. It is well to remember that if this variety of protective be applied directly to the skin, especially of a child, it is very liable to cause an erythematous irritation.

Instruments can be purified with it, although it lessens their cutting power. This dressing is recommended as one possessing efficiency and safety. The soluble compressed tablets containing a definite amount of bichloride of mercury are very convenient for the minor requirements of general practice. They should not, however, become in any way associated with the compressed tablets employed for internal medication, for obvious reasons.

Thiersch's Fluid, composed of one grain of salicylic acid and six of boracic acid to an ounce of water, is a good antiseptic solution. It does not produce the cathartic influence upon the tissues, so characteristic of the strong carbolic and bichloride of mercury solutions, and therefore the tissues to which it is applied retain their normal appearance.

Alcohol, thymol, eucalyptol, and the essential oils have been recommended for their antiseptic virtues, but with insufficient testimony to warrant their employment in 'place' of the other well-established agents.

The Patient should be kept Quiet.—Absolute quiet of the patient,

and of the part bearing the wound, is not the least of the elements necessary to secure a satisfactory result. A careful record of the pulse, temperature, and respiration should be kept. If the temperature rises to 102° F., and remains thus longer than two or three days, the dressing should be removed, the drainage carefully examined, and the parts inspected, after which, if no contra-indications exist, it is again dressed as before. The same antiseptic precautions should be employed with the redressing of the wound as with the operative procedure itself.

The Common Preparations for an Antiseptic Operation.—*Operating-Table.*—The table should be well covered with blankets and by a rubber cloth, so arranged that if the table be slightly tilted all the fluids employed will be quickly discharged into a suitable-sized receptacle placed on the floor.

The Patient.—All portions of the body not to be operated upon should be carefully excluded from draughts of air, and also from contact with antiseptic fluids, by wrapping them around and isolating them from the immediate field of operation by suitably arranged rubber cloths.

The parts to be operated upon, together with their contiguous surroundings, must be made entirely aseptic by shaving, and by scrubbing them with a stiff brush and soap and water, after which they should be rinsed in the strong solution of carbolic acid or chlorine water, and wrapped in towels saturated by a strong antiseptic fluid. A saturated ethereal solution of iodoform may be poured over the immediate site of the operation, and the antiseptic wraps omitted if the operation is to be commenced in a few moments.

The surroundings, for a foot or two outside the immediate field of the operation, should be isolated from it by towels, saturated by strong antiseptic fluid, with which they are kept thoroughly wet, and, when soiled, they should be replaced by clean ones.

The forearms, hands, and nails of the *operator*, and of *others* who are brought in contact with the wound or with the instruments, together with the *instruments*, must be made as thoroughly aseptic as the parts to be operated upon.

Douching.—An attentive assistant should have the care of the douching fluid, discharging it more or less constantly on the cut surfaces during the entire operation. This fluid may be used either hot or cold, according to the requirements of the individual cases. If, for any reason, the fluid becomes exhausted, or the operation be temporarily suspended, the incised surfaces must be at once enveloped by towels saturated by an antiseptic fluid.

The Wound.—All bleeding points requiring a ligature should be tied with catgut, the wound itself closed with catgut, when practicable, and thoroughly drained. Iodoform can be dusted on and

around the seat of the wound, after which the kind of dressings are applied that have been selected to complete the antiseptic treatment. These dressings should be removed as soon as the discharges from the wound have soiled their external surface. Furthermore, care must be taken that the external dressings be kept closely in contact with the surface of the patient for a considerable distance from the operation-wound; otherwise, unfavorable atmospheric influences may be admitted to the wound.

Open Dressing.—The so-called open dressing consists in washing the wound cavity with the strong carbolic-acid solution at the completion of the operation, after which it is placed upon a suitable cushion of oakum, and over it is laid a thin piece of gauze, which is kept moistened with a solution of carbolic acid. The wound is washed two or three times daily by gentle irrigation with a carbolic solution, after which balsam of Peru is poured into it. All the dressings are to be kept clean. If antero-posterior coaptation be desired, the anterior angle of the wound is drawn together by two or three stitches to prevent exposure of the bone, otherwise no mechanical agents are applied to the wound.

The success which is said to have attended this method in the hands of the late Prof. James R. Wood, can but cause the skeptical surgeon to wonder at the necessity of the details of the Lister and other methods.

PRECAUTIONARY REQUIREMENTS.

These requirements, and their importance, were stated some time previously.

Stimulants, of which brandy, whisky, champagne, ammonia, nitrite of amyl, digitalis, etc., are examples, enter into common use. Some one or more of these should be at hand during an operation, irrespective of its length or requirements.

For purposes of administration, the hypodermic and Davidson's syringes are most convenient. Under no circumstances must fluids be administered by the mouth, if the patient be unconscious, except by the medium of a stomach-tube.

Tenaculum.—Its use has been sufficiently emphasized to render the importance of its presence evident.

Electric Battery.—This must always be thought of when the nature of the operation, or condition of the patient, may give rise to the subsequent failure of the circulatory or respiratory powers.

Tracheotomy Tube.—Although this is not necessary to the performance of tracheotomy or laryngotomy, when indications suddenly arise calling for either, yet it is better to be provided with one. The surgeon must not overlook the fact that the death of a patient due to the absence of a tube, or to the loss of time consumed in seeking for one, is unpardonable.

Elastic Bandages.—These are not only important in preventing the loss of blood, but, as heretofore stated, doubly important, when applied to the limbs, in forcing the blood contained in them into the center of circulation, as in cases of impending death from shock due to the loss of blood. They are, in my opinion, of greater practical utility for immediate use, than the more elaborate instruments employed in transfusion. They will certainly bridge over, better than any other expedient, the interval of time necessary to prepare for the use of the transfusion apparatus.

Artificial Respiration.—No one can be safely intrusted to administer an anæsthetic, or to attempt any operative procedure, who is not familiar with the manipulations necessary to the proper performance of this means of resuscitation. It is, in fact, the only one of the requirements which can, and should, be continuously employed until the safety of the patient is assured, or until death is an established fact.

Transfusion.—If the operation be of such a nature that a great loss of blood is assured, arrangements should be perfected for the rapid performance of this measure.

Finally, a surgeon should not begin an operation, be it of greater or lesser magnitude, without having carefully rehearsed its various steps in his mind, together with the possible complications that may arise, and the best means of combating them.

Precautions of this kind serve to distinguish the careful and conscientious surgeon, who places a proper value upon human life and a just professional reputation, from the one who operates only because the opportunity is offered, and considers the details tedious or worthless, because he has not had sufficient patience or faith to practice them. He trusts to luck, and often attributes his results to an inscrutable Providence; more especially when the patient succumbs.

SPECIAL EMERGENCIES.

While the scope of this work will not admit of an extended consideration of these emergencies, still it is the author's earnest desire to sufficiently emphasize their importance, that those desiring more extended information will seek it from other and more extended sources. Unexpected emergencies not infrequently occur during the course of an operation, even though it be of a minor character. The anæsthetic given to relieve pain may, from unknown reasons, prove a treacherous ally, and, by its unexpected depressing influence, surround the case with greater gravity than that of the condition demanding the operation. This emergency, together with the suffocation that may be caused by the solid contents of an incautiously fed stomach finding their way into the air-passages, has been quite fully considered in the preceding pages.

Shock.—The symptoms of this important nervous state especially demand a careful study on the part of those who contemplate practicing surgery. It may exist before, occur during, or follow an operation; and, in either instance, may depend on loss of blood, or be the result of a physical injury, or both combined. Shock may be slight in degree, or be characterized by *syncope*, which may be followed by *collapse*. Shock due to the loss of blood has characteristics somewhat distinctive from that dependent on mutilation of the soft parts. In the former, the cold, clammy surface, feeble, fluttering pulse, extreme pallor of the mucous surfaces, great restlessness, and sighing respiration are especially prominent.

Treatment of Shock.—The severity as well as the cause will very much modify the treatment. If the shock be slight, lower the head, admit fresh air, and administer a stimulant. If collapse be impending, to the preceding should be added hot stimulating enemata, heat to the body by means of bottles filled with hot water, or hot plates placed upon the abdomen and chest, hypodermic injections of brandy or ether, and inhalation of amyl nitrite. Small doses of opium can be cautiously administered if nervous irritation be marked, or the shock be due to loss of blood. Transfusion, either sanguineous or saline, and the application of Esmarch's bandage to the extremities, comprise the additional means to be employed when the collapse depends on the loss of blood.

Air in the Veins.—This accident is associated with operations upon the portions of the body where the venous circulation is markedly influenced by the force of aspiration, as, in the regions of the neck, chest, and axillæ, where, if a vein connected with a morbid growth, be nicked while on the stretch, or otherwise divided, it may remain open sufficiently to admit the sucking in of air, by reason of the tension of its walls.

Symptoms.—The local symptoms are a bubbling or hissing sound at the seat of hemorrhage, sometimes attended with air-bubbles. The patient suddenly utters a cry, becomes pallid with anxious facies, labored breathing, and livid lips. Rapid insensibility or convulsions may be the principal features. Sudden death not infrequently occurs.

Treatment.—The treatment must be quick, decisive, and persistent. Close the opening at once with the finger and tie the vessel. Artificial respiration and stimulation as applied to shock must be thoroughly employed.

Preventive Treatment.—This consists in taking such measures as shall tend to prevent the entrance of air. 1. Pressure upon the vein by the fingers at its proximal portion during an operation. 2. Avoid incisions during inspiration, especially when in the vicinity of large veins, and when the veins may be held open by disease of their coats

or of the surrounding tissues. 3. If a vein be cut, compress it at once, and then apply a ligature to it.

If the means here given be carefully applied, the danger of this complication need not annoy the surgeon.

CHAPTER IV.

LIGATURE OF ARTERIES.—GENERAL CONSIDERATIONS.

ARTERIES are ligatured in their continuity or at their divided extremities. Under this heading, however, will be considered the ligaturing in their continuity only. Nearly all arteries to which ligatures are thus applied can, from their association with the soft and hard parts, be said to possess certain guides, which, when carefully adhered to, indicate with precision their position beneath the surface.

The guides to ligaturing arteries in the living subject are practically four in number : 1. The linear guide. 2. The muscular guide. 3. The contiguous anatomical guide. 4. The pulsation and color of the vessel.

The linear guide to an artery is a line drawn upon the external surface so as to correspond with the established course of the vessel beneath. Its extremities are usually indicated by the relations which the vessel bears to fixed bony prominences.

The muscular guide is based upon the relation which the vessel bears to some portion of a well-developed superficial or deep muscle, the outline of which can be quite readily traced if the muscle be placed upon the stretch. If the border of a muscle be given as the guide, it must not be forgotten that, in case it be unusually developed, or have a broader origin and insertion than common, it will overlap the vessel, and thus may lead the surgeon astray. Under these circumstances he must direct his attention unerringly to the *contiguous anatomical guides*, which include the relations that a vessel bears to its immediate surrounding parts, and, when taken in connection with its pulsation, lead directly to it. *The contiguous guides* may be *muscular*, if a muscle be ascertained to bear an established relation to it ; or *bony*, when a bony prominence is in close contact with it ; or *nervous*, when a certain nerve is known to lie in a definite relation with it ; or *vascular*, when vessels of an established arrangement exist. And, *finally*, the sheath of the vessel itself becomes a valuable guide when it is present and considered in connection with the others. Some of the large vessels, of which the common carotid and femoral arteries are the most striking examples, possess well-developed sheaths, while

the smaller arteries are surrounded by a greater or lesser amount of areolar tissue. The larger arteries, as the popliteal, femoral, and subclavian, are each accompanied by a single vein which commonly runs in a definite relation with them. The smaller ones, those of the extremities, etc., are attended by satellite veins, known as the *venæ comites*, usually two in number; however, that is not invariable, since three or more are often seen. The vessels are distinguished from each other by the darker color of the veins and the lighter or pinkish color of the artery. If three vessels are seen, the middle one is almost certain to be the artery; if more than three exist, the third vein usually rests upon the artery; if pressure be made upon them, the veins are distended, and the artery is collapsed on the distal side of pressure. If to these facts be now added the pulsation of the artery, its location is assured. The operator who relies exclusively upon the arterial impulse as a guide may be led astray by the transmitted pulsations of other vessels, or by the functional movements of parts in which the artery is located.

Having determined the anatomical details, the portion of the body in which the vessel is situated, is placed in position to afford all available room and the best possible light; the part of the vessel is then selected, at which the surgeon feels best assured of the absence of a branch of sufficient size to interfere with formation of an internal clot. The primary incision is made, the center of which should, if possible, correspond to the portion of the vessel to which the ligature is to be applied. The length of the incision will depend upon the depth of the vessel, and should always be of sufficient extent to afford easy access to it. If the thumb and finger be employed to make tense and to steady the integument, great care must be taken to make the traction equal on the respective sides (Fig. 91). Otherwise, after the tissues are released, the incision will be outside the line of the vessel, which, if not noticed, will lead the surgeon astray; besides, its irregularity will interfere with the necessary space and light, as well as the subsequent drainage. The external incision should be made with one sweep of the knife, rather than by repeated incisions, which tend to chop the tissues, increasing the danger of suppuration, and correspondingly lessening the prospects of union by first intention.

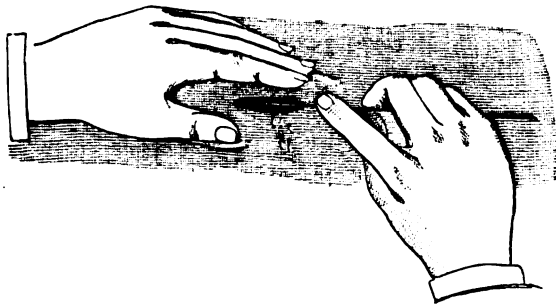


FIG. 91.—Primary incision.

The fascia is pinched up by the thumb-forceps, or tenaculum, carefully nicked with a scalpel, after which a grooved director is cautiously passed beneath it, upon which it is then divided. The fascia should not be incised the full length of the integumentary cut. The nearer the approach to the vessel, the shorter should be the line of the separation of the tissues, so that when the vessel is reached, the bottom of the wound will somewhat resemble an inverted triangle, with its apex corresponding to the artery.

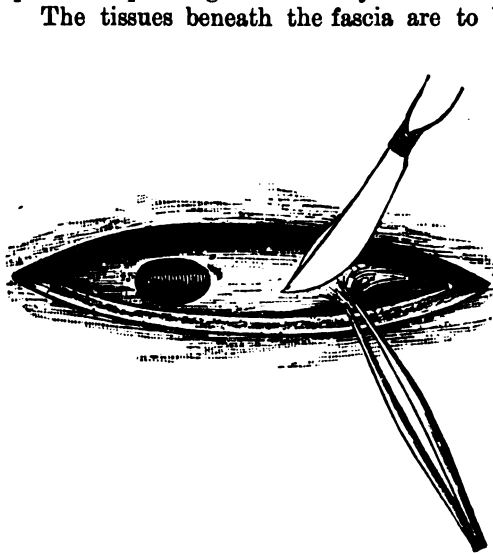


FIG. 92.—Opening sheath of vessel.

The tissues beneath the fascia are to be gently separated by the fingers, handle of the scalpel, or director; using the knife only when necessary, until the sheath of the vessel is reached, when a small opening is made into it—about one fourth of an inch being ample—of sufficient size to pass the needle with ease. This opening is made by picking up the sheath or condensed tissue with the thumb-forceps, and with the scalpel at, or nearly at, right angles with the forceps, carefully cutting out a button-hole-shaped piece of a suitable size (Fig. 92).

The borders of the opening in the sheath are then to be separately raised, to inform the operator if deeper tissues still surround the vessel; if so, they should be incised in a similar manner. When the pe-

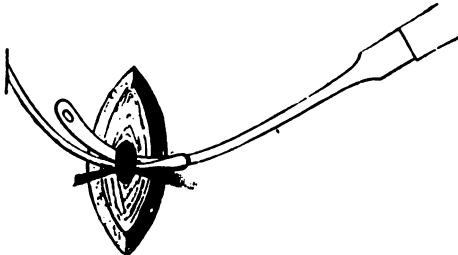


FIG. 93.—Passing aneurism needle.

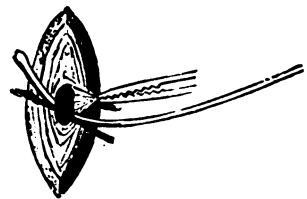


FIG. 94.—Passing probe.

culiar pinkish white appearance of its coats are seen, the side of the cut in the sheath nearest to the contiguous vein should be grasped and raised by the forceps, and the aneurism needle, or probe, armed with

a ligature, carefully passed around the vessel, being carried from the contiguous vein (Fig. 94). When the advancing end of the ligature appears at the opposite side of the vessel, it may be seized and brought through by forceps, and the aneurism needle withdrawn. If the vessel be sufficiently superficial, the ligature can be passed through the eye of the needle after its passage beneath the artery (Fig. 93). If now all doubts be settled as to the identity of the vessel, the ligature is tied by making either the surgeon's, or the reef-knot. If it be of catgut, cut both ends short and dress the wound; if silk, cut one extremity short and allow the other to hang from its most dependent part. This extremity should be secured, so that it will not be unnecessarily drawn upon when the wound is dressed. The length of time the ligatures are to remain depends upon the size of the vessel. If tied with catgut, this element of the operation is eliminated.

Instruments required to Ligature Arteries.—An ordinary scalpel, a flexible grooved director, thumb-forceps, tenacula, retractors, and an aneurism needle armed with a ligature are required.

Retractors vary in size and shape. The ones recommended by Profs. Mott (Fig. 95) and Parker (Fig. 96) are appropriate for all practical purposes. If neither be at hand, one can be devised by bending the handle of the common table-spoon to the necessary angle.



FIG. 95.—Mott's retractor.

Aneurism Needle.—These differ in size, shape, and arrangement. The simplest form is combined with a director (Fig. 97); another in common use has a broader extremity with a suitable handle (Fig. 98); still another with adjustable points for the purpose of securing deep-seated vessels. The points must be securely screwed into position, else the turning and twisting often necessary to pass it may loosen them, causing it to become a source of annoyance instead of an advan-




FIG. 96.—Parker's retractor.



FIG. 97.—Combined director and aneurism needle.

tage (Fig. 99). Also one with a lateral curvature may be employed. Fig. 100 is a representation of the safest needle with movable points

now in use. It is known as the "Movable Immovable Aneurism Needle," and also as the "Student's Aneurism Needle." It was devised by Dr. S. W. Fletcher, of Pepperell, Mass., while a student; hence the name sometimes given to it.

OPERATIONS ON SPECIAL ARTERIES.

Ligature of the Abdominal Aorta.—

This vessel can be ligatured at its lower two inches—that is, below the

origin of the inferior mesenteric—by two or three methods.

Contiguous Anatomy.—The omentum, intestines, peritoneum, sympathetic nerves, and mesentery lie in front; the left lumbar veins, receptaculum chyli, thoracic duct, and vertebral column behind; on the right the inferior vena cava, vena azygos, and thoracic duct. At the left no structures are liable to be injured.

The Linear guide to the vessel is the linea alba.

Operation.—First Method (Cooper).—With the patient on the back and the legs flexed, make an incision, three or four inches in length—straight or curved—to the left of the umbilicus, to which the center of the incision may correspond (Fig. 102, *a*), downward through the various tissues comprising

the abdominal wall at this point, to the peritoneum, dividing each on a director. Check all oozing and carefully incise the peritoneum, se-

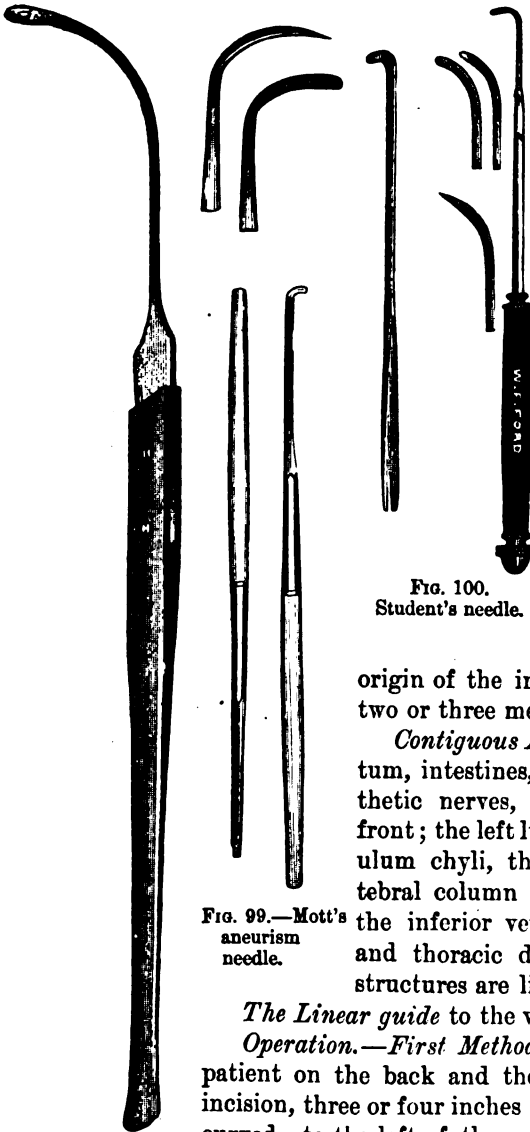


FIG. 98.
Syme's needle.

FIG. 99.—Mott's
aneurism
needle.

FIG. 100.
Student's needle.

curing its borders to prevent them from retreating outward behind the abdominal walls.

Turn the patient toward the right side, or tilt the table in that direction, to aid the displacement of the intestines to one side; scratch through the peritoneum covering the vessel carefully at its left side, pass the needle from the vena cava from behind forward, closely hugging the vessel and carefully avoiding the sympathetic nerves and inferior vena cava. This operation should be done with strict antiseptic precautions. If it be possible, the temperature of the operation-room should be 85° F. at least, and the room should have been thoroughly disinfected. If it be necessary to remove the intestines from their cavity, they must be kept wrapped in antiseptic gauze wet with warm water. Linen cloths wet with a warm, though weak, solution of carbolic acid, or bichloride of mercury (1-10,000), may be substituted for the antiseptic gauze.

Second Method (Murray).—This leads to the vessel without opening into the abdominal cavity.

Linear Guide to the Operation.—A line drawn from the apex of

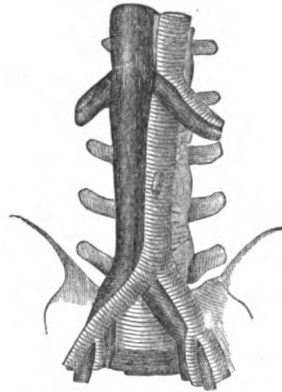
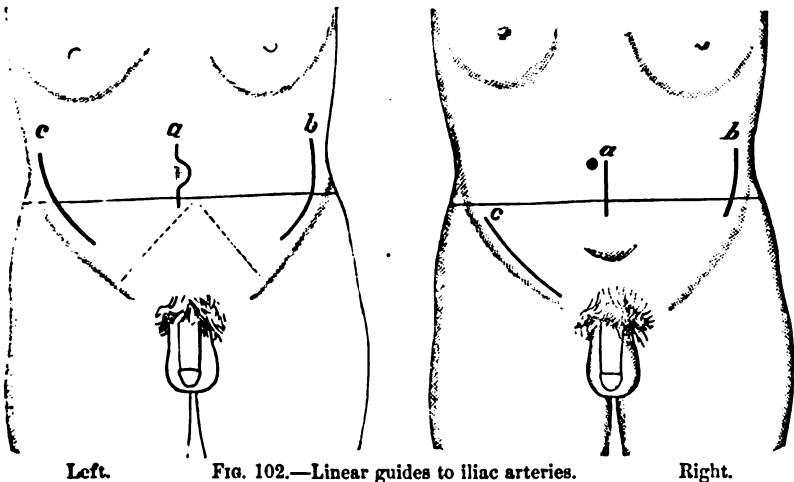


FIG. 101.—Inferior vena cava and abdominal aorta.



Left.

FIG. 102.—Linear guides to iliac arteries.

Right.

the tenth rib downward and forward, to within about one inch of the anterior superior spine of the ilium (Fig. 102, b, right).

Contiguous Anatomy.—The ureter lies to the outer side. In other respects the relations of the vessel are similar in both methods.

Operation.—Divide the various tissues on a grooved director down to the peritoneum; the hand is then inserted into the wound, and the peritoneum, intestines, and ureter are raised carefully upward and inward, readily exposing the vessel to view. The artery is then raised with the finger and the ligature passed as before. It can be reached through an incision extending from the end of the last rib to the anterior superior spinous process of the ilium.

Results.—It has been ligatured ten times, and in every instance has proved fatal, death occurring from within three or four hours to ten days.

Ligature of the Common Iliac Arteries.—These vessels average about two inches in length, and should be ligatured at a point nearest to their middle. They commonly begin at the left of the middle of the body of the fourth lumbar vertebra, and pass downward and outward to the sacro-iliac synchondroses.

Linear Guide to the Vessels.—A line drawn between the highest portions of the iliac crests corresponds very nearly to their point of origin. Two lines drawn a little to the left of the center of this one, and carried downward and outward between, but a little nearer the pubes, than to the anterior spinous process of the ilium, mark the course of the vessels downward (Fig. 102, left).

There are two general methods of access to them; one by entering the abdominal cavity in front, the other by raising the peritoneum through an incision made at the side of the abdomen.

First Method.—At this time this method is not generally accepted as a substitute for the latter, except in cases where the latter is of doubtful expediency. If the surgeon be able to command complete

asepsis, the advisability of the latter operation is greatly enhanced; if otherwise, it should not be attempted unless the situation of the disease calling for it renders the former impracticable. The outer border of the rectus muscle, or more properly the linea semilunaris, is the best *superficial guide* to the vessel in this method. The linea semilunaris extends from the lower portion of the seventh rib in a slightly outward arched direction downward to the spine of the pubes. In a normal abdomen these lines are about

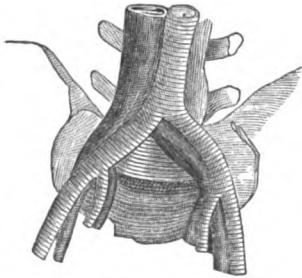


FIG. 103.—Venous relations of iliac arteries.

three inches from the umbilicus. An incision through the linea alba below and even extending a little above the umbilicus, may be employed likewise (Fig. 102, *a*, right). The relations of the common iliac arteries and veins are intricate and dissimilar (Fig. 103), and should be carefully memorized.

PLAN OF THE RELATIONS OF THE COMMON ILIAC ARTERIES.—(GRAY.)

In front.

Peritoneum.
 Small intestines.
 Sympathetic nerves.
 Ureter.

In front.

Peritoneum.
 Sympathetic nerves.
 Rectum.
 Superior hæmorrhoidal artery.
 Ureter.

Outer side.

Right
common
iliac
artery.

Vena cava.
 Right common
 iliac vein.
 Psoas muscle.

Inner side.

Left common
 iliac vein.

Outer side.

Left
common
iliac
artery.

Psoas muscle.

Behind.

Right and left common
 iliac veins.

Behind.

Left common
 iliac vein.

Operation.—An incision, five inches in length, and three inches to the left of the median line, is carefully made into the abdominal cavity; the intestines are pushed aside, a small opening is scratched through the peritoneum, and the vessel ligatured by passing the needle from without inward on the right and from within outward on the left side. That is to say, pass it *from* the vein nearest the vessel. The external wound is then closed as in ovariectomy.

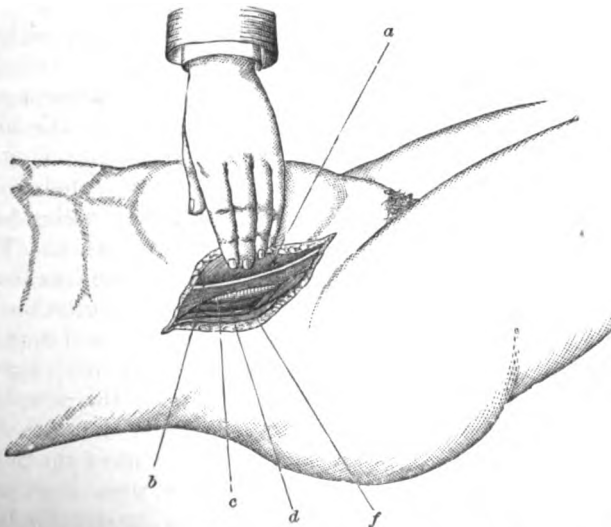


FIG. 104.—Incision for ligaturing common iliac artery. *a.* Peritoneum. *b.* Ureter. *c.* Common iliac artery. *d.* Common iliac vein. *f.* Psoas muscle.

If it be necessary to remove the intestines from the abdominal cavity, they should be protected the same as in the ligaturing of the

abdominal aorta, and under all circumstances the most rigid antiseptic care must be enforced.

Results.—They are, thus far, sufficiently satisfactory to warrant the employment of this method when other methods are of a questionable utility.

Second Method.—Without opening into the abdominal cavity.

Linear Guide to Operation.—First (Crampton). A line drawn from the apex of the last rib, downward and a little forward nearly to the crest of the ilium, then carried forward parallel with it to a little below the anterior superior spine (Figs. 102, *c*, left, and 104).

Second (McKee). A line drawn downward from the tip of the eleventh rib to one and a half inches within the anterior superior

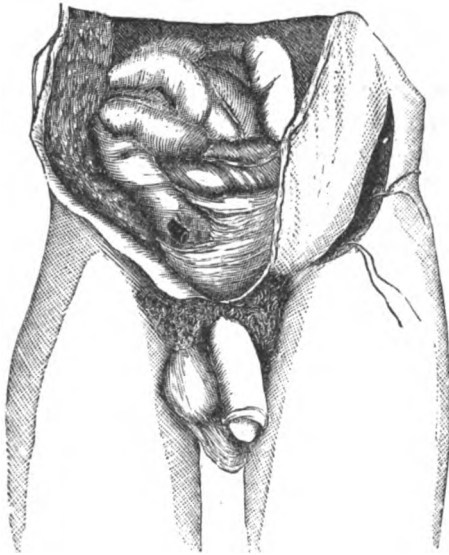


FIG. 105.—Ligature of primitive iliac artery.

spine, then carried downward and forward and curved upward, abruptly terminating above the internal abdominal ring (Figs. 102, *b*, left, and 105).

Muscular Guide.—There is no superficial muscular guide to the common iliac artery except the rectus in the median operation. The inner border of the psoas magnus is, however, an undeviating and markedly prominent deep muscular guide. The contiguous anatomy is indicated by the plan of the preceding method.

Operation.—Place the patient on the back, the body inclined to the opposite side, and with the thighs flexed sufficiently to relax the abdominal walls. By repeated divisions on the grooved director, the various layers of the tissues composing the abdominal walls are divided down to the fascia transversalis, which is cautiously raised from the peritoneum at the upper end of the wound, where it is less dense and less firmly attached, and a small opening made into it, through which the finger or a large grooved director can be passed, and upon which the fascia is divided to the full extent of the wound. The hand of an assistant, who should stand on the opposite side of the body, should then be introduced into the wound and the peritoneum raised gently upward and inward, while the operator, by the aid of the finger or handle of the scalpel, separates it carefully

from the tissues beneath. When the psoas magnus is reached, the surgeon will then know the exact location of the artery. If the external iliac artery be first felt, it is to be followed upward to the common iliac; when the common iliac is reached, the areolar tissue surrounding it is scratched aside by the finger or a director, and the needle passed, the one with the adjustable end being preferable.

Dangers.—The dangers attending this operation are of considerable magnitude. The peritoneum may be lacerated, the ureter included in the ligature, or the veins punctured by the needle. The assistant who raises the peritoneum should keep the fingers closely approximated, using both hands, if necessary, and being careful that the fingers do not become too much flexed, else they may lacerate it. If the patient struggle, vomit, or cough, the peritoneum should be permitted to return to its normal site until quiet is again restored. The traction necessary to separate and elevate it can not be made too carefully, and it is better if it be done during the acts of expiration, since at this time less downward pressure will be made by the abdominal contents. Large, broad retractors are sometimes employed for this purpose, but they are much less reliable than the hands of an intelligent assistant.

The ureter crosses the artery at its point of bifurcation; but it is in little danger, since it is usually raised together with the peritoneum and its subjacent tissue. The veins can be avoided by always remembering to pass the needle from them. This will be somewhat difficult on the right side, owing to the large venous trunks in close contact with it. If the vein obscures the arterial trunk, pressure upon it below the point to be ligatured will diminish its size, by obstructing the venous return, which will permit the easy exposure of the artery.

Fallacies.—The external iliac artery may be mistaken for the common iliac artery. The relation of the sacro-vertebral prominence to the external iliac artery should settle this doubt. The ligature may be applied too near the bifurcation, owing to the difficulty of finding it, on account of obscure light and the intimate relation of the vessels. Care only will prevent this with certainty.

Results.—This vessel has been ligatured sixty-eight times, with sixteen recoveries, giving a rate of mortality of about seventy-seven per cent.

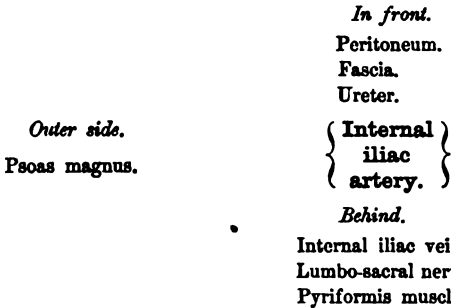
Ligature of Internal Iliac Artery.—This vessel is about an inch and a half in length, extending from the bifurcation of the common iliac downward and forward to near the upper border of the great sacro-sciatic foramen.

Methods of Operating.—Two or three incisions are given with a view of reaching this vessel. Either of the incisions employed in the ligature of the common iliac will easily lead to it; or, an incision five inches in length, parallel with the epigastric artery; or, a semicircular

incision about seven inches in length, two inches to the left of the umbilicus, with its convexity outward, and ending just to the outer side of the external abdominal ring. It can be easily tied through an incision made into the abdominal cavity in the median line below the umbilicus.

This vessel possesses no practical linear or muscular guide other than it lies to the inner side of the psoas magnus.

PLAN OF THE RELATIONS OF THE INTERNAL ILIAC ARTERY.—(GRAY.)



Operation.—The tissues are successively divided in the line selected for the primary incision, as in the operation for ligaturing the primitive iliac; the peritoneum is elevated in the same cautious manner, the connective tissue scratched away, and the ligature carried from within outward, taking care to avoid the ureter, and the external iliac vein as it lies at the angle of bifurcation of the primitive iliac artery.

Fallacies.—The internal might be mistaken for the external iliac artery; this doubt, however, can be quickly settled if the course of the latter vessel be considered.

Results.—Of twenty-six cases, eighteen terminated fatally, making a rate of mortality of about seventy per cent.

Ligature of the Gluteal Artery.

—This vessel passes out of the pelvis at the upper border of the great ischiatic notch, above the pyriformis muscle.

The Linear guide is a line extending from the posterior superior spinous process of the ilium, to the trochanter major, when rotated inward. The artery is beneath the junction of the upper and middle thirds of this line (Fig. 106, *a*)

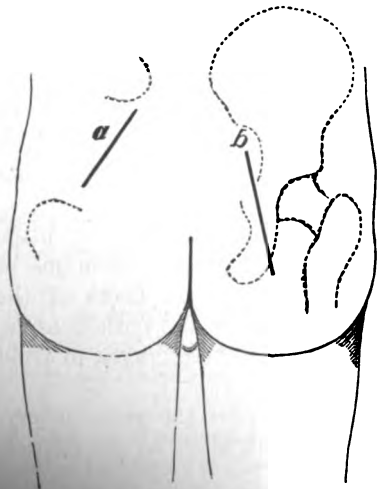


FIG. 106.—Linear guides to gluteal and sciatic arteries.

Anatomically it lies in the upper border of the notch, which is a guide to it ; it is accompanied by its venæ comites, and is covered by the gluteus maximus muscle.

Operation.—Place the patient on the abdomen, with the thigh extended and rotated inward ; make an incision five inches in length in the course of the line indicated. The direction of the incision will correspond to the course of the fibers of the gluteus maximus, which can be separated with the handle of the scalpel ; liberate the artery from its accompanying veins and pass the ligature in the most convenient manner (Fig. 107).

Fallacies.—It may be mistaken for either of its venæ comites ; otherwise no fallacy will occur.

Results.—The operation itself implies but little danger to the patient.

Ligature of the Sciatic Artery.—This vessel escapes from the pelvis below the pyriformis muscle, and passes downward in the interval between the tuberosity of the ischium and the trochanter major.

The Linear guides to the vessel are two in number, one of which is drawn parallel with the linear guide to the gluteal artery, only about an inch and a half lower down. A second extends from just below the posterior superior spinous process of the ilium to the outer side of the tuberosity of the ischium (*b*, Fig. 106).

Its *deep muscular guide* is the lower border of the pyriformis, beneath which it descends from the pelvis.

Contiguous Anatomy.—It is covered by the gluteus maximus ; the sciatic nerve accompanies it, and it is posterior to the pudic artery.

Operation.—An incision is made three or four inches in length on one of the lines indicated, the fibers of the gluteus maximus separated, the nerves and veins are pushed aside, and the ligature is carried around the vessel, care being taken to avoid the vein which lies to its outer side (Fig. 108).

Fallacies.—This artery might be mistaken for the pudic artery, which lies internal to it ; however, the direction taken by the respective vessels should make the distinction easy.

Results.—The prognosis to life is always good so far as the operation itself is concerned.



FIG. 107. — A. Gluteus maximus. B. Gluteal artery. C. Gluteal veins.



FIG. 108. — Ligature of sciatic artery. Passing needle.

Ligature of the Internal Pudic Artery.—This vessel escapes from the pelvis through the greater sacro-sciatic foramen below the pyriformis muscle, lying internal to the sciatic artery; it then enters the pelvis through the lesser sacro-sciatic foramen, and runs along the inner surface of the ramus of the ischium and pubes, till it divides into its terminal branches.

It may be ligatured in two situations: 1. At the greater sacro-sciatic foramen. 2. In the perineum. In the first situation, the in-

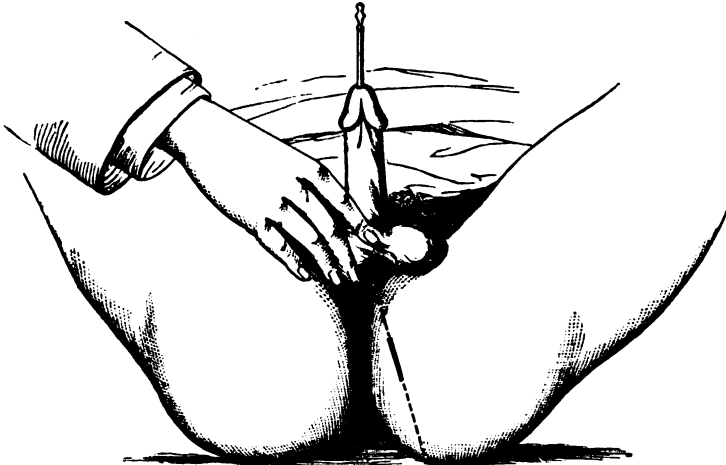


FIG. 109.—Linear guide to pudic artery in perineum.

cision for ligaturing the sciatic artery is sufficient, the pudic being found internal to that artery, and lower down, accompanied by its veins and the pudic nerve. In the perineum, *the linear guide to the operation extends from the arch of the pubes to the inner border of the tuber ischii* (Fig. 109). The artery is situated about an inch and a quarter above the margin of the tuber ischii.

Contiguous Anatomy.—It runs along the outer side of the ischio-rectal fossa, resting upon the obturator internus muscle, covered by the obturator fascia, and accompanied by the pudic veins and the internal pudic nerve.

Operation.—The patient is placed in the lithotomy position, and an incision is made about four inches in length in the course of the line indicated; the tissues are carefully divided down to the vessel, which is then isolated from its veins and nerves and tied (Fig. 110). If care be not taken the crus penis will



FIG. 110. — Passing needle around pudic artery.

be cut. The introduction of a sound into the urethra will so positively define its outlines, that the danger of wounding the parts unnecessarily will be obviated.

Ligature of the Dorsalis Penis Artery.—This artery may be tied on the dorsum of the penis by making an incision an inch in length at either side of the dorsum of the penis, and on a line parallel to the center of its long axis. It is superficial, and is attended by its veins and nerves, which should be carefully avoided in passing the needle.

Ligature of the External Iliac Artery.—This vessel is about four inches long, and passes obliquely downward and outward, nearly corresponding to a line drawn from the left side of the umbilicus to midway between the anterior superior spinous process of the ilium and the symphysis pubis. It is ligatured at about the middle of its course. It has no superficial muscular guide; however, the psoas magnus, at the inner border of which it lies, is a most important deep muscular guide.

Contiguous Anatomy.

PLAN OF THE RELATIONS OF THE EXTERNAL ILIAC ARTERY. (GRAY.)

In front.

Peritoneum, intestines, and iliac fascia.

Near Poupart's Ligament.	{	Spermatic vessels. Genital branch of genito-crural nerve. Circumflex iliac vein. Lymphatic vessels and glands.
--------------------------------	---	---

Outer side.

Psoas magnus.
Iliac fascia.

{ External
iliac
artery. }

Inner side.

External iliac vein and vas
deferens at femoral arch.

Behind.

External iliac vein.
Psoas magnus.
Iliac fascia.

Operation.—Before beginning the operation evacuate the contents of the bladder and rectum of the patient, place him in a recumbent position, with the thigh slightly flexed, and the body inclined to the opposite side. A curvilinear incision is then made, with the convexity downward, beginning about an inch above Poupart's ligament, and immediately to the outer side of the external abdominal ring, and terminating on a level with, but about two inches internal to, the anterior superior spinous process of the ilium (Fig. 111, c). The superficial fascia, aponeurosis of the external oblique, the muscular fibers of the internal oblique, and the transversalis are separately divided upon a grooved director. The fascia transversalis is now carefully picked up with the thumb-forceps, a small opening made through it, into which the director is introduced, and the fascia divided. The peritoneum and its subserratus muscle are then carefully raised from the iliac fossa, and pressed forward until the outer border of

the psoas magnus is ascertained, when, after a little further separation, the vessel is felt pulsating at its inner margin.

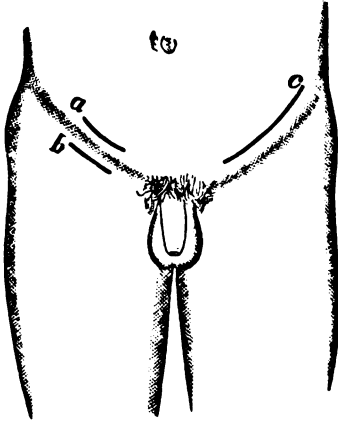


FIG. 111.—Linear guide to external iliac, epigastric, and femoral arteries.

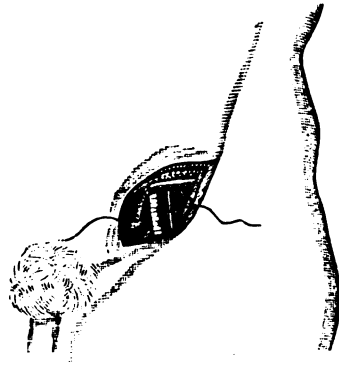


FIG. 112.—Ligature of external iliac.

The condensed areolar tissue constituting its sheath is then opened, and the needle carefully inserted between the vein and artery, from within outward (Figs. 112 and 113). If the incision be made only

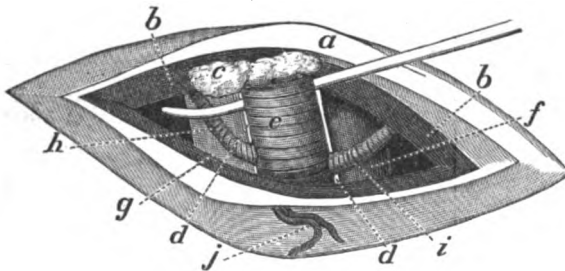


FIG. 113.—Ligature of external iliac. *a.* Aponeurosis of external oblique muscle. *b.* Internal oblique and transversalis fibers. *c.* Ganglion sometimes found on artery. *d.* Borders of sheath of vessels. *e.* Iliac artery. *f.* Iliac vein. *g.* Psoas magnus muscle. *h.* Deep circumflex artery. *i.* Deep epigastric artery. *j.* Superficial branches.

about a third of an inch above Poupart's ligament (Fig. 102, *c*, right), it will come upon the iliac fascia without coming in contact with the peritoneum, since the latter is reflected upward and backward into the pelvis a little above this point.

Fallacies.—The external oblique aponeurosis may be mistaken for the deep layer of fascia. The muscular fibers of the internal oblique will then be mistaken for those of the external oblique. If, however, the direction of the fibers of the respective muscles be recalled, and, furthermore, that the external oblique has no muscular fibers in this situation, the mistake will be quickly rectified. The fascia transversalis may be mistaken for the peritoneum; this fallacy is easily detected by following it downward, when, if it be attached to Poupart's ligament, or pass beneath it, it can not be the peritoneum, and must

before be the transversalis fascia. If its relations to the previously united tissues be taken into account, together with its density and elasticity, this mistake can hardly occur.

The iliac fascia may be mistaken for the subserous tissue, and be raised together with the peritoneum. Under such circumstances the wound will be raised upward together with the peritoneum and iliac fascia, and will be felt pulsating in the roof rather than the floor of the operation wound. This mistake can be avoided by remembering that the iliac and psoas muscles are covered by a dense fascia, which passes across the pelvis beneath Poupart's ligament to which it is attached, and that the artery does not lie beneath it.

If an irreducible inguinal hernia exist, or the vein be adherent to the artery, then much difficulty may be experienced in properly directing the ligature without injury to the intestines or the vein. After ligaturing, the wound must be thoroughly closed by carrying the sutures deeply down and close to the peritoneum, the superficial tissues (integument and fascia) being united separately. If this be not done, the patient will be exposed to the danger of the occurrence of a hernial protrusion due to the weakening of the abdominal walls. This is a precaution which should always be taken in operations involving the separation of the peritoneum.

Results.—This vessel has been ligatured one hundred and seventy-nine times, with sixty-one deaths; which have arisen from various causes connected either with the operation itself, or the conditions calling for it.

Ligature of the Epigastric Artery.—This vessel is ligatured in one situation only. It arises from the lower portion of the external iliac (i, Fig. 113) and runs upward toward the umbilicus, between the peritoneum and the fascia transversalis. It lies at the inner border of the internal abdominal ring.

Linear Guide.—A line extending from the umbilicus to the middle of Poupart's ligament corresponds to the course of the vessel. The guide to the first incision is the upper border of the middle of Poupart's ligament (a, Fig. 111).

Operation.—An incision is made, about three inches in length, parallel with and about one inch above Poupart's ligament. The various layers of the abdominal wall are then divided separately upon a grooved director until the fascia transversalis is reached, which is opened over the artery, the veins separated from it, and the ligature properly placed.

The wound should then be carefully closed, and the patient kept quiet in a recumbent posture until the tissues are firmly united, else a weak point in the abdominal walls may follow.

Ligature of the Deep Circumflex Iliac Artery.—This vessel may be secured in two situations: 1, at the internal abdominal ring; 2, near

the anterior superior spinous process of the ilium. In the first situation it may be tied through the same incision as for the epigastric artery (*a*, Fig. 111). In the second it may be secured through an incision made parallel to Poupart's ligament and just above it to the outer side of the course of the epigastric artery, through the various tissues anterior to the transversalis fascia, which is then opened, the artery isolated and tied.

Ligature of the Femoral Artery.—The femoral artery extends from Poupart's ligament to the lower extremity of Hunter's canal, at the junction of the middle and lower thirds of the thigh, where it terminates in the popliteal. It is ligatured in three situations: 1, Just below Poupart's ligament; 2, at the apex of Scarpa's triangle or about four inches below the ligament; 3, at its lower third or in Hunter's canal. The most favorable situations are at the apex of Scarpa's triangle and in Hunter's canal. However, circumstances often arise which necessitate its being tied, irrespective of the stereotyped situations.

The linear guide to the artery, throughout its whole course, is a line drawn from midway between the anterior superior spinous process of the ilium and the symphysis pubis to the inner condyle of the femur (Fig. 114).

A line drawn from the origin of the adductor longus to the insertion of the adductor magnus tendon into the internal condyle of the femur also corresponds to the femoral artery at its lower third (Fig. 114, *a*).

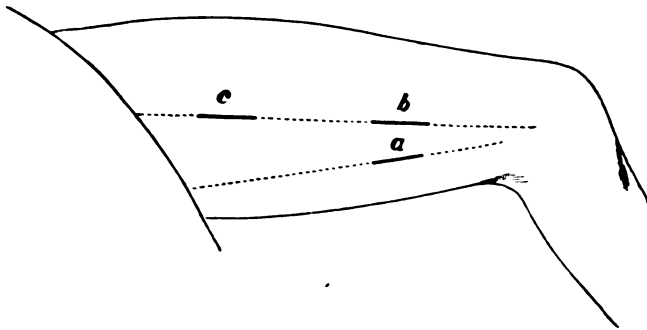


FIG. 114.—Linear guides to femoral artery.

The Muscular Guide.—The sartorius is given as its muscular guide; the artery is at its inner border in the upper third, behind it in its middle, and at its outer side in its lower third. The better guide to the lower third is the inner border of the tendon of the adductor magnus. This tendon can be quite easily felt, but care must be taken, otherwise it will be mistaken for one of the ham-string tendons.

Contiguous Anatomy.

PLAN OF THE RELATIONS OF THE FEMORAL ARTERY. (GRAY.)

In front.

Fascia lata.
 Branch of anterior crural nerve.
 Sartorius (middle part).
 Long saphenous nerve.
 Aponeurotic covering of Hunter's canal (lower part).

Inner side.

Femoral vein (at upper part).
 Adductor longus.
 Sartorius.

{ Femoral }
 { artery. }

Outer side.

Vastus internus.
 Femoral vein (at lower part).

Behind.

Psoas muscle.
 Profunda vein.
 Pectineus muscle.
 Adductor longus.
 Femoral vein (middle part).
 Adductor magnus.

*Operation—First Situation, Common Femoral (Fig. 115).—*The vessel can be ligatured immediately below Poupart's ligament through

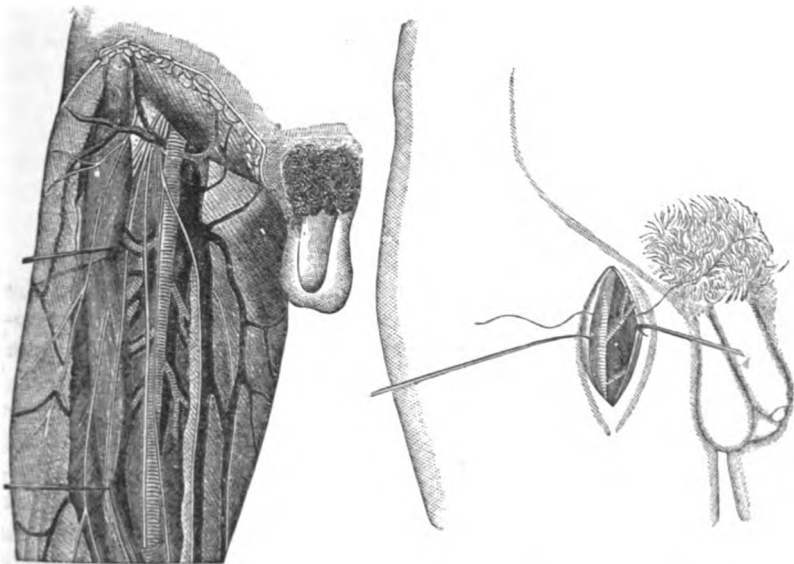


FIG. 115.—Relations of femoral artery.

FIG. 116.—Ligature of upper third of femoral artery.

two incisions: one made in the long axis of the vessel, the other parallel with the lower border of the ligament (*b*, Fig. 111). The former is, however, the better method. The patient is placed upon his back,

and the thigh flexed and rotated outward. The pulsation of the artery is noted by the finger, then an incision about three inches in

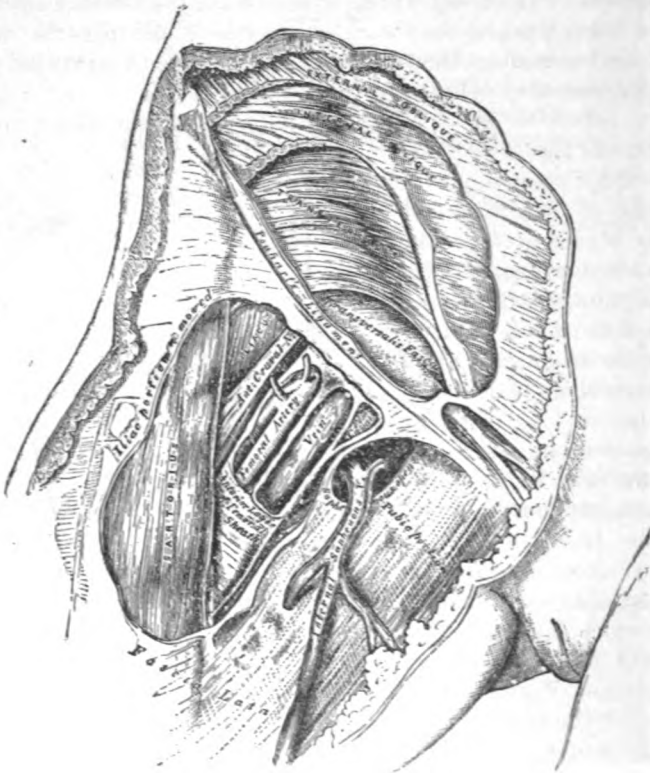


FIG. 117.—Relation of femoral vessels.

length is made through the integument and subcutaneous tissues ; the fascia lata is divided on a director in the usual manner, and the arterial sheath, which is very dense, is opened and the needle passed from within outward (Fig. 116). The vein will be noticed at its inner side, inclosed in a common sheath with it, but separated from the artery by a fibrous partition (Fig. 117). The attention of the surgeon should be directed to the pinkish-white pulsating vessel rather than to seeking for the vein. If the attention and manipulations be directed toward the artery, the vein will remain uninjured within its compartment. The lymphatic glands which are encountered should be drawn aside.

Second Situation.—This is at the apex of Scarpa's triangle, or about four inches below Poupart's ligament. The saphenous vein runs along the inner side of this region ; its location can be determined by pressing it above, which will cause it to be distended. Place the limb as in the preceding operation, and make an incision about four inches in

length along the inner border of the sartorius muscle; divide the tissues down to the fascia lata, draw the sartorius to the outer side, and the pulsations of the vessel will be seen beneath the fascia; cautiously open the fascia lata and the sheath of the vessel, and pass the needle from within outward. The vein lies to the inner side, somewhat more posteriorly than above (Figs. 118 and 119).

Third Situation or in Hunter's Canal.—Flex the thigh on the pelvis and the leg on the thigh, with the thigh rotated outward; an incision is then made along the outer border of the tendon of the adductor magnus, beginning at a point a little below the junction of the middle and lower thirds of the thigh, and extending upward (Fig. 114, *a*), about four inches in length, through the integument and fascia, when the tendon will be readily felt. If the sartorius be in the way, it should be drawn to the inner side. Any intervening soft parts are pushed aside, and the fibrous canal in which the artery is contained will be exposed, formed by the tendon of the adductor magnus with the inner border of the vastus internus and the fibrous reflections extending between them. The canal is cautiously

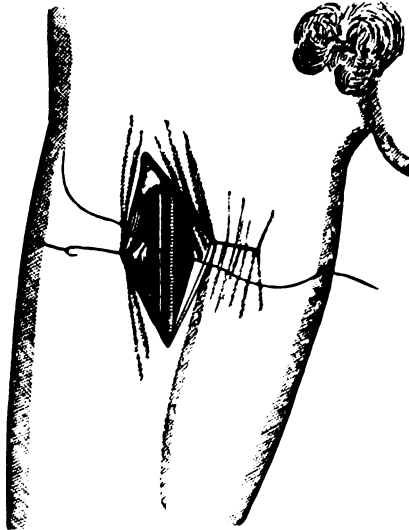


FIG. 118.—Ligature of femoral artery at apex of Scarpa's triangle.

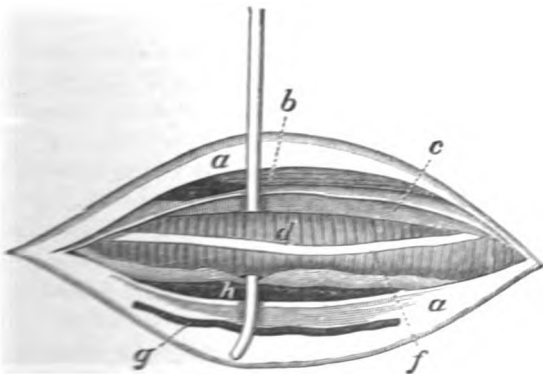


FIG. 119.—Ligature of femoral artery at apex of Scarpa's triangle. *a*. Superficial spongiois. *b*. Inner border of sartorius. *c*. Sheath of artery. *d*. Femoral artery. *f*. Long saphenous vein. *g*. Internal saphenous vein. *h*. Femoral vein.

opened, and the long saphenous nerve is seen resting upon the vessel; this is drawn aside and the needle passed from without inward, the vein now being located posteriorly and externally (Figs. 120 and 121). The vessel can be ligatured in this situation by making an incision of a similar length on the linear guide before repre-

sented (Fig. 114, *b*). It is not so easily secured, however, as by the method just stated.

Fallacies.—The sartorius may be mistaken for the other muscles lying in its course. If, however, it be recollected that no other muscles run in the same direction on the anterior surface of the thigh, and that it is superficial throughout its whole course, no great confusion can arise from this fallacy. The lymphatic glands that lie over the sheath of the vessel in the upper portion of its course may be mistaken for the vessel itself, owing to their color and to the transmitted




FIG. 120.—Ligature of femoral artery in Hunter's canal.

pulsation. These are irregular, movable, and can be raised upward, when their apparent pulsation will cease; moreover, the artery is beneath the fascia lata, and they are above it.

The tendon of the adductor magnus may be mistaken for the tendon of the semimembranosus or semitendinosus. This mistake will be avoided if the tendon be traced

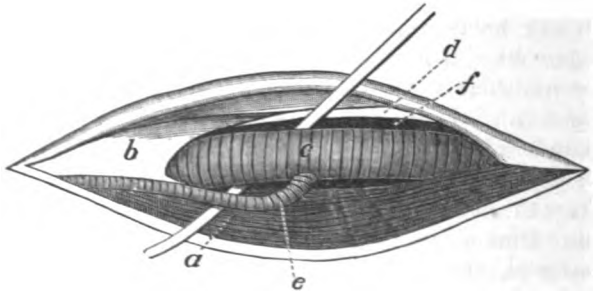


FIG. 121.—Ligature of femoral artery in Hunter's canal. *a*. Sartorius muscle, pushed outward. *b*. Aponeurosis of Hunter's canal. *c*. Femoral artery. *d*. Long saphenous nerve pushed backward and outward. *e*. Anastomotica magna. *f*. Femoral vein.

by palpation downward; the two latter will pass behind the internal condyle, while the former will be found inserted into it. Care must be taken in ligaturing the artery at the apex of Scarpa's triangle not to make the incision too low down. The width of the hand below Poupart's ligament is a good practical guide to its apex. In ligaturing the artery in Hunter's canal, it should be remembered that the canal is located but a little below the middle third of the thigh, otherwise the incision will be made too low down, and the upper portion of the popliteal artery secured instead.

In a very small number of cases (four) the femoral has been double; in a like number it passed behind instead of in front of the thigh. If

it be double, the portion found will be smaller than normal, and the object for which the ligature is applied will not be accomplished. If the vessel be not found in its common location it will be necessary to seek for it elsewhere. Deep pressure may enable one to detect the site of its anomalous situation.

Results. — The common femoral has been ligatured eight times for aneurism, with a rate of mortality of twenty-five per cent. The superficial femoral has been tied two hundred and four times, with a mortality of fifty cases.

Ligature of the Deep Femoral Artery, or the Profunda.

—This vessel usually comes off from the common trunk one or two inches below Poupart's ligament. It may arise above or even four inches below this ligament. There is no known manner of determining its site prior to an operation. It arises from the outer side of the common femoral, running slightly outward, then downward and inward, passing behind the superficial femoral, accompanied by its vein, which lies in front of it (Fig. 122).

Operation.—This vessel can be tied through the incision for the ligation of the common femoral, and is to be sought for at its outer side. When found it should be carefully isolated, in order that the ligature may be applied a proper distance from where the profunda gives off its circumflex branches.

Fallacies.—It may arise from the inner, or back portions of the common femoral. If not found in the usual place, it should be sought in these latter-mentioned situations.

Ligature of the Popliteal Artery.—This vessel may be ligatured in two situations: at its upper and lower portions. It is continuous with the femoral, beginning at the junction of the middle and lower thirds of the thigh, at the termination of Hunter's canal, and passes with a slight obliquity downward and outward to the lower border of the popliteus muscle.

Linear Guide.—The linear guide begins a little to the inner side

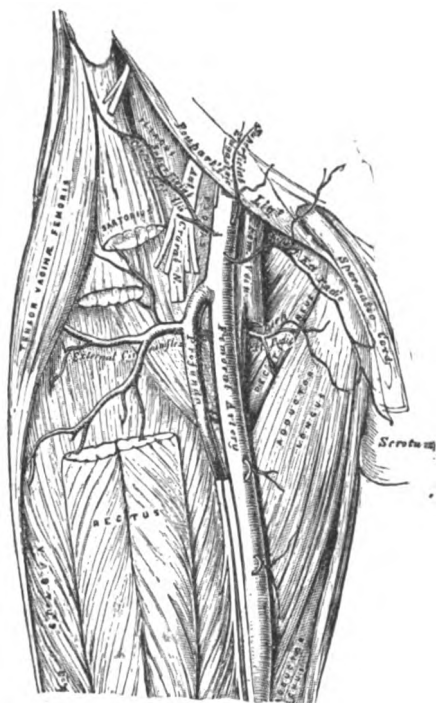


FIG. 122.—Relation of the deep to the superficial femoral.

of the middle of the upper portion of the popliteal space, and terminates below between the heads of the gastrocnemius muscle, passing midway between the condyles of the femur (Fig. 123).

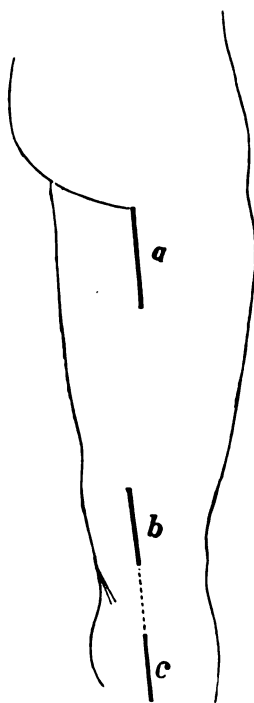


FIG. 123.—Linear guides to popliteal artery and great sciatic nerve.

Muscular Guide.—The artery in its upper third lies to the inner border of the semi-membranosus; at its lower, midway between the heads of the gastrocnemius.

Contiguous Anatomy.—In the upper third the internal popliteal nerve is more superficial than the vein and artery. The vein lies in close contact with the artery, and between it and the nerve. The artery is the innermost of the three; and is the most deeply situated, resting on the posterior surface of the femur. In the lower third, the nerve is still the most superficial, but lies upon and to its inner side. The vein in this situation is to its inner side, and more superficial than the artery, which rests upon the popliteus muscle. This vessel should not be tied at its middle third, on account of the large number of branches given off at this point, together with its contiguity with the knee-joint.

Operation in the Upper Portion (Fig. 123, *b*).—The patient can be placed upon the face, or, while on the back, the thigh can be well flexed and rotated outward. The former position is more convenient for the surgeon, but is objectionable on account of danger to the patient. The patient may be placed on the side corresponding to the limb to be operated upon, with that thigh extended and the opposite one flexed on the pelvis, when the safety and comfort of both will be consulted.

An incision is made, about four inches in length, along the inner border of the semi-membranosus through the integument and fascia, and is deepened by separating the areolar tissue with the handle of the scalpel or the fingers. The nerve will no doubt be first seen, and, when drawn outward, the vein will be found lying more deeply and internal to it; if this be now carefully isolated and drawn in the same direction, the artery will be seen at its inner side, which

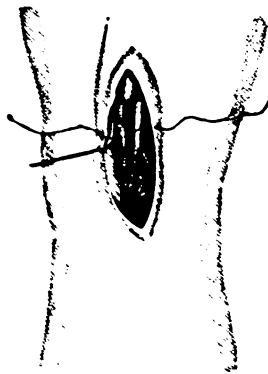


FIG. 124.—Ligation of popliteal, upper third.

must be separated from the surrounding tissues, and the needle carried from without inward (Fig. 124).

Operation in the Lower Portion (Fig. 123, c).—Make an incision midway between the heads of the gastrocnemius, carefully avoiding the external saphenous vein and nerve, as they escape between the heads of that muscle; separate the connective tissues with the handle of the scalpel, draw the vein and nerve to the inner side, and pass the needle from within out-

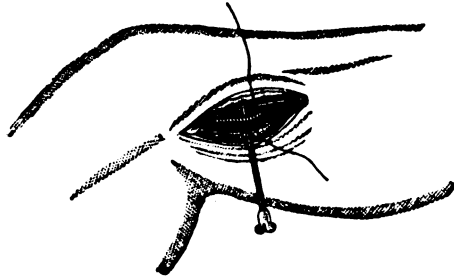


FIG. 125.—Ligation of popliteal, lower third.

ward. Its lower third may be tied below the inner tuberosity of the tibia.

The linear guide in this situation is continuous with that of the posterior tibial (Fig. 132), and the limb should be placed in a similar position as for ligaturing the posterior tibial.

Fallacies.—The tendon of the semitendinosus may be mistaken for the tendon of the semimembranosus. At this situation the semimembranosus has a large fleshy belly, which extends much nearer to the median line of the popliteal space than the semitendinosus. Sometimes there are two popliteal veins, one on either side of the vessel.

Results.—It is seldom ligatured unless it be ruptured, when both ends must be tied. Of the three or four cases thus reported, all terminated unfavorably, due, however, to the nature of the injury.

Ligature of the Anterior Tibial Artery.—It arises from the popliteal, just below the lower border of the popliteus muscle, passes forward between the bones of the leg, above the interosseous membrane, then downward on its anterior surface to the ankle-joint, where it becomes the dorsalis pedis. This vessel can be tied in three situations: at its upper, middle, and lower thirds; but, two: the middle and lower, are more than sufficient for all practical purposes.

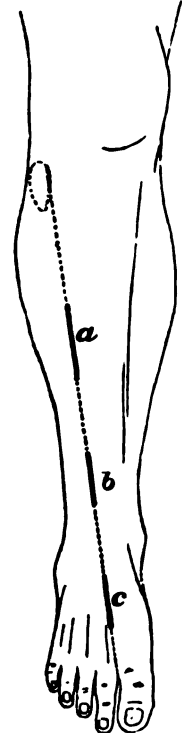


FIG. 126.—Linear guides to anterior tibial and dorsalis pedis arteries.

The linear guide of the vessel is drawn on anterior surface of leg from the inner border of the head of the fibula to midway between the malleoli (Fig. 126).

The muscular guide is the outer border of the tibialis anticus muscle (Figs. 127 and 128).

Contiguous Anatomy.

PLAN OF THE RELATIONS OF THE ANTERIOR TIBIAL ARTERY. (GRAY.)

In front.

Integument, superficial and deep fascia.
 Tibialis anticus (overlaps it in the upper part of leg).
 Extensor longus digitorum } (overlap it slightly).
 Extensor proprius pollicis }
 Anterior tibial nerve.

Inner side.

Tibialis anticus.
 Extensor proprius pollicis } **Anterior** }
 (crosses it at its lower } **tibial artery.** }

Outer side.

Anterior tibial nerve.
 Extensor longus digitorum.
 Extensor proprius pollicis.

Behind.

Interosseous membrane.
 Tibia.
 Anterior ligament of ankle-joint.

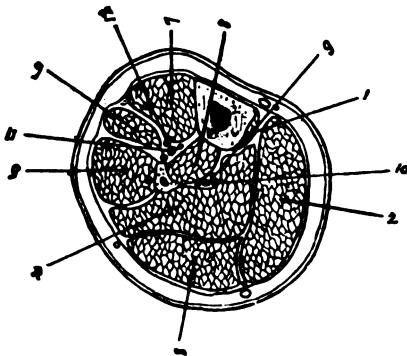


FIG. 127.—Transverse section, upper third.
 1. Popliteus. 2, 3. Gastrocnemius. 4. Soleus. 5. Peroneus longus. 6. Extensor longus digitorum. 7. Tibialis anticus. 8. Tibialis posticus. 9. Posterior tibial artery and venæ comites. 10. Posterior tibial nerve. 11. Anterior tibial artery and venæ comites. 12. Anterior tibial nerve.

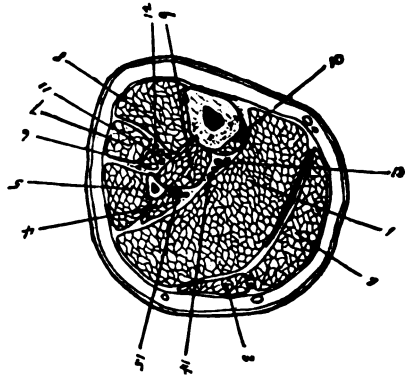


FIG. 128.—Transverse section, middle third.
 1. Soleus. 2, 3. Gastrocnemius. 4. Flexor longus pollicis. 5. Peroneus longus and brevis. 6. Extensor longus pollicis. 7. Extensor com. digitorum. 8. Tibialis anticus. 9. Tibialis posticus. 10. Flexor longus digitorum. 11. Anterior tibial artery and venæ comites. 12. Anterior tibial nerve. 13. Posterior tibial artery and venæ comites. 14. Posterior tibial nerve. 15. Peroneal artery and venæ comites.

Operation.—*Upper Third* (Fig. 126).—The great depth of the vessel in this situation renders the tying of it one of the most tedious of operations. Unless circumstances demand it, the ligaturing in this situation should not be attempted. Fig. 127 shows the deep relations of the vessel. The *linear* and *muscular guides* are similar to those of the middle third.

Middle Third (Fig. 126, a).—The artery in this situation lies quite deep, and a good light must be had to see the bottom of the operation

wound. Place the patient on the back with the thighs extended, the leg turned inward, and the foot forcibly extended to mark the outlines of the tibialis anticus muscle. Make an incision four or five inches in length on the line indicating the course of the artery, down to the fascia, which is then divided on a director. The aponeurosis is then divided along the line of apposition between the tibialis anticus and the extensor longus digitorum; it should likewise be divided transversely to admit of the wider separation of these muscles. The foot is now flexed, and, with the finger, or handle of the scalpel, the line of separation is extended directly down to the vessel; separate the surfaces of the wound with spatulæ, when the artery, with its nerve and veins, will be seen, the nerve being in front and to the outer side; separate the veins from the artery, draw the nerve aside, and pass the ligature from without inward (Fig. 129).

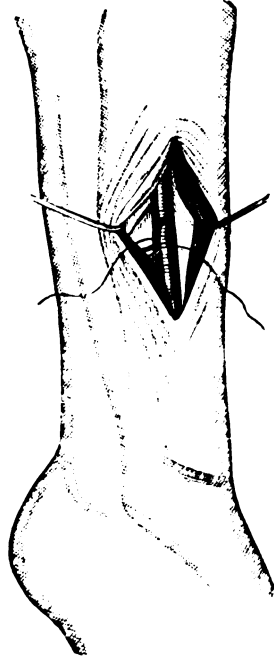


FIG. 129.—Ligature of anterior tibial, middle third.

Operation at the Lower Third (Fig. 126, *b*).—With the limb as in the preceding instance, extend the foot to mark the course of the tendon of the tibialis anticus; make an incision along the external border of the tendon

on the linear guide about three inches in length. Divide the fascia on a director, and seek with the finger for the space between the tibialis anticus and the extensor proprius pollicis which has crossed to the inner side of the vessel; flex the foot, separate these muscles, and the artery will be seen accompanied by its veins and nerve, the latter lying in front and a little to the outer side; isolate the artery, and place the ligature by passing it from without inward.

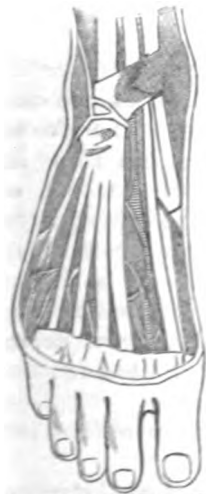

FIG. 130.—Dorsalis pedis artery.

Fallacies.—The outer surface of the head of the tibia may be mistaken for the head of the fibula, which will bring the linear guide too far to the inner side of the leg, and cause the incision to be made over the belly of the tibialis anticus muscle. To avoid this it must be remembered that the head of the fibula is more posteriorly, and constitutes the most external bony prominence at this point.

The septum between the tibialis anticus and the

extensor longus digitorum may be indistinct or absent ; then the outer border of the tibialis anticus can be determined, 1, by forcible extension of the tarsus ; 2, by determining its limits by the resistance to lateral pressure ; 3, the line indicating the interspace may be seen at the lower extremity of the incision when not visible above.

The vessel may be rudimentary or absent ; it may run more superficially than common. So long, however, as it keeps in the proper line its pulsations will lead to its detection.

Ligature of the Dorsalis Pedis Artery.—This vessel is a continuation of the anterior tibial (Fig. 126, c), beginning at the ankle-joint and passing downward between the metatarsal bones of the great and second toes. It is tied in *one situation*, and on a line which is a direct continuation of the linear guide to the anterior tibial.

The muscular guide is the outer border of the tendon of the extensor proprius pollicis (Fig. 130).

Contiguous Anatomy.

PLAN OF THE RELATIONS OF THE DORSALIS PEDIS ARTERY. (GRAY.)

In front.

Integument and fascia.

Innermost tendon of extensor brevis digitorum.

Tibial side.

Extensor proprius pollicis.

{ Dorsalis }
{ pedis artery. }

Fibular side.

Extensor longus digitorum.
Anterior tibial nerve.

Behind.

Astragalus.

Scaphoid.

Internal cuneiform,
and their ligaments.



FIG. 131.—Ligature of dorsalis pedis.

Operation.—Extend the tarsus and forcibly flex the great toe to make prominent the tendon of the extensor proprius pollicis ; make an incision about three inches in length along its outer border, commencing from the bend of the ankle ; divide the fascia on a director, when the fleshy inner portion of the extensor brevis digitorum will be seen ; this should be drawn outward, when the artery and its satellite veins will appear ; separate the artery from them, and pass the needle as best suits the convenience of the operator (Fig. 131).

Fallacy.—It may pass outside of the line indicating its proper course.

Ligature of the Posterior Tibial Artery.—This is an artery of considerable size which

comes from the popliteal at the lower border of the popliteus muscle ; it passes obliquely to the tibial side of the leg, goes down between the superficial and deep layers of muscles to a point midway between the

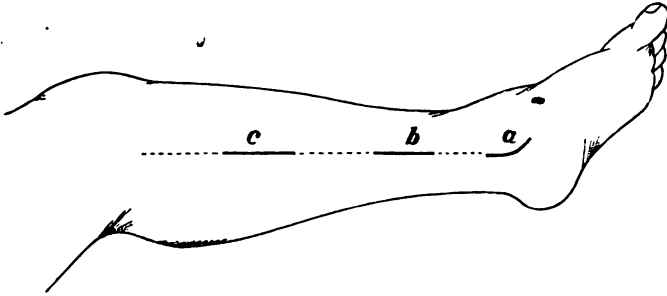


FIG. 132.—Linear guide to posterior tibial.

internal malleolus and inner tuberosity of the os calcis, where it terminates a little further on in the external and internal plantar arteries. *It may be ligatured in three situations* : at its middle third, at its lower third, and as it passes behind the inner malleolus.

The linear guide of this vessel is drawn from the middle of the popliteal space to midway between the inner malleolus and tuberosity of the os calcis. This guide is not a feasible one, since to reach the artery by cutting upon it necessitates the division of the fibers of the muscles of the calf of the leg.

The linear guide to the operation is made by drawing a line three fourths of an inch behind the posterior border of the tibia in the upper and lower thirds, and from its upper to its lower extremity (Fig. 132).

The Muscular Guide.—At its middle third it lies beneath the soleus ; at its lower third to the outer border of the flexor longus digitorum.

Contiguous Anatomy.

PLAN OF THE RELATIONS OF THE POSTERIOR TIBIAL ARTERY. (GRAY.)

In front.

Tibialis posticus.
Flexor longus digitorum.
Tibia.
Ankle-joint.

Inner side.

Posterior tibial nerve,
upper third.

{ Posterior }
{ tibial artery. }

Outer side.

Posterior tibial nerve,
lower two thirds.

Behind.

Gastrocnemius.
Soleus.
Deep fascia and integument.

Operation at its Middle Third (Fig. 132, *c*).—Place the patient on the back, flex the leg on the thigh and the thigh on the pelvis, so that

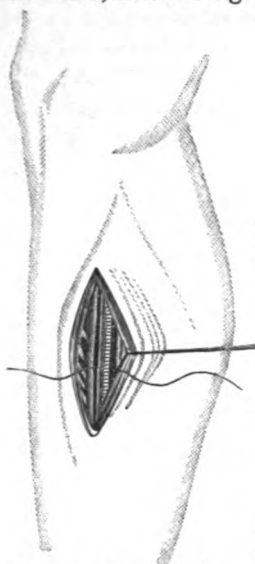
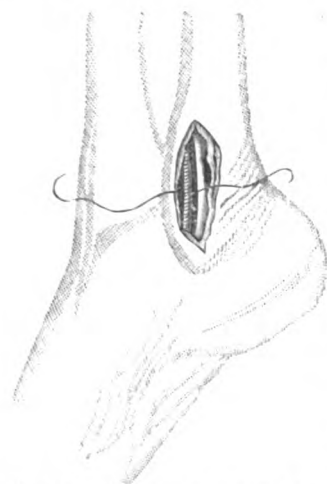


FIG. 133.—Ligature of posterior tibial, middle third.

the leg will lie on the outer side. Make an incision on the linear guide to the operation, about four inches in length; divide the deep fascia, recognize the inner border of the gastrocnemius, beneath which will be seen the fibers of the soleus, which should be divided on a director, down to the pale yellow aponeurosis on its under surface; separate the fibers of the soleus and make an opening through its aponeurosis, about one inch from the inner border of the tibia, of sufficient size to expose the artery, which is found beneath, attended by its veins and the posterior tibial nerve (Fig. 133); draw the nerve to the outer side, separate the vessel from the veins, and pass the needle from without inward (Fig. 134).



* FIG. 135.—Ligature of posterior tibial, lower third.

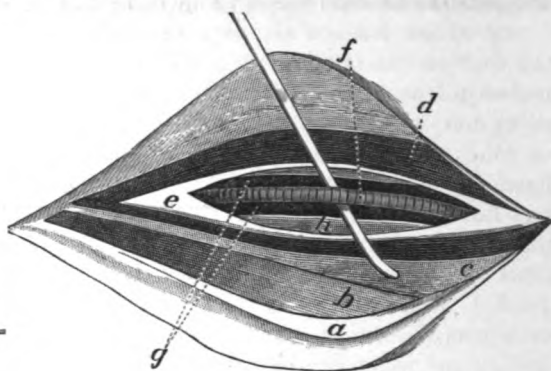


FIG. 134.—Ligature of posterior tibial, middle third. *a.* Fascia and fat. *b.* Gastrocnemius muscle. *c.* Cellular tissue. *d.* Soleus muscle and its aponeurosis. *e.* Sheath of vessels. *f.* Posterior tibial artery. *g.* Venae comites. *h.* Posterior tibial nerve.

Operation at the Lower Third (Fig. 132, *b*).—Place the limb as before; make an incision in the course of the linear guide about three inches in length; divide the integument and fascia in the usual manner; separate the borders of the wound, then divide the aponeurosis (which binds down the deep layer of muscles) at about one inch from the posterior border of the tibia, push aside the fat, and the vessel, with its

nerve and veins, will be found at the outer border of the flexor longus digitorum. Separate the vessel, push the nerve to the outer side, and pass the needle from without inward (Fig. 135).

Operation between the Os Calcis and Internal Malleolus.—Place the foot on the outer surface and make a curved incision about three inches in length, with the concavity uppermost, and its center at a point midway between the malleolus and the inner tuberosity of the os calcis (Fig. 132, a). Divide the fascia and the internal annular ligament on a director, using caution with the director, since the artery lies beneath the ligament; isolate the vessel from the veins and pass the needle from without inward. In passing through the superficial tissues, some small branches of the long saphenous vein may be divided, unless caution be used. In old people both these and the venæ comites often become varicose, which increases the difficulty of finding and isolating the artery. It is better not to attempt to ligature it in this situation if evidences of varicosities exist.

Fallacies.—The posterior tibial may be rudimentary or absent. In either instance the peroneal is usually increased in size.

Ligature of the Peroneal Artery.—It arises from the posterior tibial about an inch below the popliteus muscle, passes obliquely outward to the inner border of the fibula (Fig. 128), along which it descends to the lower third of the leg, and is finally distributed to the outer side of the ankle. It may be ligatured at the middle third of the leg.

The linear guide is a line drawn from the posterior border of the head of the fibula to the external border of the tendo Achillis at its insertion.

Contiguous Anatomy.

PLAN OF THE RELATIONS OF THE PERONEAL ARTERY. (GRAY.)

In front.

Tibialis posticus.
Flexor longus pollicis.

Outer side.

Fibula.

{ Peroneal }
{ artery. }

Behind.

Soleus.
Deep fascia.
Flexor longus pollicis.

Operation.—Extend the foot and make an incision about four inches in length along the line indicated, parallel with the external border of the fibula. Separate the attachments of the soleus and the flexor longus pollicis from each other, when the artery will be found at the inner side of the flexor longus pollicis close to the fibula.

Fallacies.—It may be absent; this is, however, very rare. It may be overlooked, and the posterior tibial found instead. If its close relation to the fibula be remembered, this mistake will not occur.

Ligature of the Innominate Artery.—The innominate artery arises from the beginning of the transverse arch of the aorta in front of the left common carotid, passes obliquely upward and outward to the upper border of the right sterno-clavicular articulation, where it divides into the right common carotid and right subclavian. It has no practical *linear or muscular* guides.

Contiguous Anatomy.

PLAN OF THE RELATIONS OF THE INNOMINATE ARTERY. (GRAY.)

In front.

Sternum.
Sterno-hyoid and sterno-thyroid muscles.
Remains of thymus gland.
Left innominate and right inferior thyroid veins.
Inferior cervical cardiac branch from right pneumogastric nerve.

Right side.

Right vena innominata.
Right pneumogastric nerve.
Pleura.

{ **Innominate** }
{ **artery.** }

Left side.

Remains of thymus.
Left carotid.

Behind.

Trachea.

Operation.—Numerous incisions have been given for gaining access to the vessel. The one which is best calculated to afford the requisite amount of room was employed by the late Valentine Mott

(Fig. 136, *d*). Place the patient on the back, with the shoulders somewhat raised, and the head turned to the opposite side. An incision is then made three inches in length, extending along the upper border of the clavicle to opposite the center of the episternal notch. This is joined by another of a similar length directed

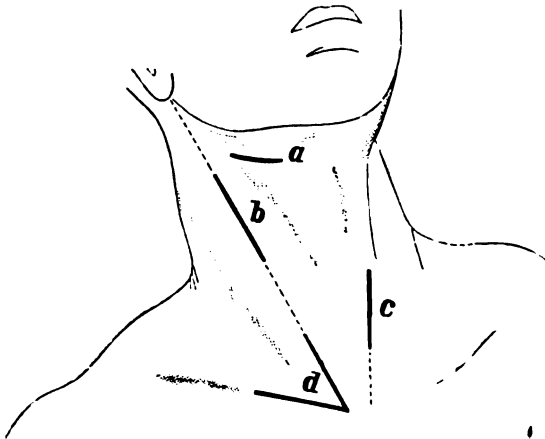


FIG. 136.—Linear guides to arteries of neck.

along the anterior portion of the sterno-mastoid muscle. This triangular flap, consisting of the integument, superficial fascia, and pla-

tysma, is turned upward and outward. The portions of the sternocleido-mastoid, corresponding to the horizontal incision, and the sterno-hyoid and sterno-thyroid muscles, are divided on a director and turned aside. The inferior thyroid veins, if they now come into view, must be carefully drawn aside, the deep cervical fascia must be carefully torn or cut through, when the sheath containing the common carotid artery, pneumogastric nerve, and internal jugular vein is brought into view. Open the sheath, draw the vein and nerve to the outer side, and follow the carotid down to the subclavian, the origin of which should be exposed. The upper portion of the innominate is then to be separated from its important connections by the finger or a blunt director; the left vena innominata is depressed, and the right vena innominata, right internal jugular, and pneumogastric nerve are carried to the right, and then the aneurism needle is passed from below upward, and from behind, forward and inward, in close contact with the vessel. It is suggested to remove a sufficient portion of the upper end of the sternum to admit of the direct opening into the sheath of the innominate. It is thought that this measure will the better preserve the nutritive integrity of the coats of the vessel by leaving its vascular connections with the sheath undisturbed above.

Fallacies.—If the innominate be shorter than usual, the lower extremity of the common carotid may be tied instead. If the aorta arches to the right side, the innominate will be on the left side, instead of the right.

The necessity of treating all the veins and the pleura with most judicious care is emphasized by the knowledge of the fact, that, nearly all the fatal cases thus far have died from pleuritis or secondary hemorrhage.

Results.—This vessel has been ligatured seventeen times, with two recoveries.

Ligature of the Subclavian Artery.—The subclavian artery, on the right side, arises from the arteria innominata, opposite the junction of the right clavicle with the sternum; on the left side it arises from the arch of the aorta. These vessels must, therefore, differ in the first part of their course in length, direction, and with relation to their contiguous anatomical structures. This vessel can be ligatured in three situations: between the inner border of the scalenus anticus and its origin; behind the scalenus; between its termination at the lower border of the first rib and the outer border of the scalenus anticus.

Ligature of the First Portion, Left Side.—This portion has no definite *linear* or *muscular guide*. The inner border of the scalenus anticus is important as leading to and limiting its extent. Owing to its origin from the arch of the aorta, it is of great depth, almost beyond the reach of a ligature; while its close relation to very

important structures—injury to which, of itself, may be more grave than the condition for which the vessel is to be tied—render it exceedingly difficult to perform, and of questionable expediency.

Contiguous Anatomy.

PLAN OF RELATIONS OF FIRST PORTION OF LEFT SUBCLAVIAN ARTERY. (GRAY.)

In front.

Pleura and left lung.
Pneumogastric, cardiac, and phrenic nerves.
Left carotid artery.
Left internal jugular and innominate veins.
Sterno-thyroid, sterno-hyoid, and sterno-mastoid muscles.

Inner side.

Œsophagus.
Trachea.
Thoracic duct.

{ **Left subclavian artery,** }
{ **first portion.** }

Outer side.

Pleura.

Behind.

Œsophagus and thoracic duct.
Inferior cervical ganglion of sympathetic.
Longus colli muscle and vertebral column.

Operation.—Place the patient on the back with the head extended and turned to the opposite side; the left shoulder should be well depressed; make an incision three inches and a half in length along the inner border of the sterno-cleido-mastoid down to the sternum; another, two inches and a half in length along the inner extremity of the clavicle, meeting the former near the trachea. It is seen that this incision is substantially the same as that for the ligaturing of the innominate artery (Fig. 136, *d*). The flap, consisting of the integument, superficial fascia, and platysma, is turned aside; one half of the clavicular portion of the sterno-mastoid and its whole sternal portion are then divided on a director, bringing into view the sterno-hyoid, sterno-thyroid muscles, and, to the outer side, the omo-hyoid. The sterno-thyroid and sterno-hyoid should be divided with great care, after being liberated from the fascia which covers them. The inner edge of the scalenus anticus muscle is now sought for; when found, it will guide the finger directly to the vessel. The important contiguous structures are now drawn inward and pressed away from the artery, using great caution to avoid the thoracic duct, which will be in the line of search, as it passes behind the jugular vein at its junction with the left innominate vein. The needle is carefully passed from before backward. The great depth of the vessel will make it exceedingly difficult to pass the needle, which should be the one with the adjustable extremity.

Results.—Tied by Dr. J. Kearney Rogers, 1845; patient died from secondary hemorrhage on the fifteenth day.

Ligature of First Portion, Right Side.—The inner border of the anterior scalenus leads to it upon this, as upon the left side.

Contiguous Anatomy.

RELATIONS OF FIRST PORTION OF RIGHT SUBCLAVIAN ARTERY. (GRAY.)

In front.

Clavicular origin of sterno-mastoid muscle.
Sterno-hyoid and sterno-thyroid muscles.
Internal jugular and vertebral veins.
Pneumogastric, cardiac, and phrenic nerves.

{ Right subclavian artery, }
{ first portion. }

Beneath.
Pleura.

Behind.

Recurrent laryngeal nerve.
Sympathetic nerve.
Longus colli muscle.
Transverse process of seventh cervical or first dorsal vertebra.

Operation.—The position of the patient, primary incisions, and dissection are substantially the same as the preceding. The internal jugular should be pressed aside and the needle passed from below upward and from before backward, carefully avoiding the pleura, recurrent laryngeal and phrenic nerves. The ligature of the vertebral and internal mammary arteries at the same time will lessen the danger of secondary hemorrhage.

Fallacies.—This vessel may arise from the arch of the aorta, when it will be more deeply situated, often passing behind the œsophagus or between it and the trachea.

Results.—It has been ligatured thirteen times; all the cases proved fatal, of which eight died of hemorrhage.

Ligature of the Second and Third Portions.—The linear guide to the operation is drawn just above the upper border of the clavicle, extending between the posterior border of the sterno-cleido-mastoid and the anterior border of the trapezius, and should be about four inches in length (Fig. 137, a).

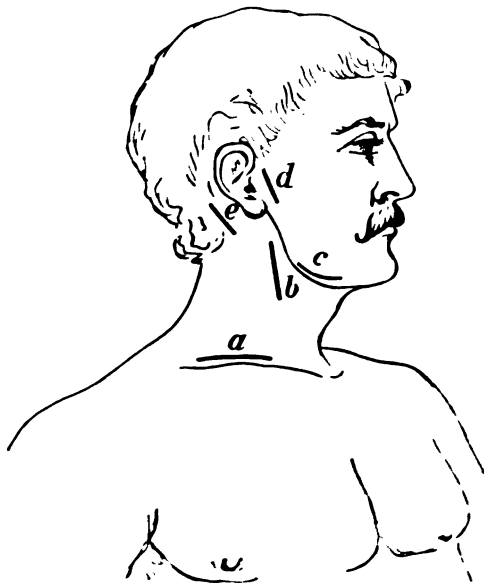

FIG. 137.—Linear guides to arteries of neck and face.

Muscular Guides to the Artery.—This vessel has no superficial muscular guide. *The deep muscular guide* is the outer border of the

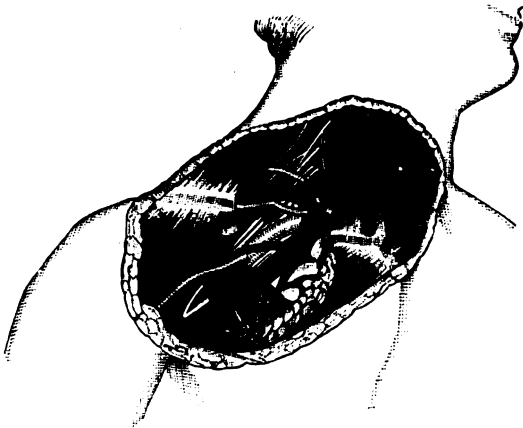


FIG. 138.—Surgical anatomy of subclavian.

scalenus anticus. The posterior belly of the omo-hyoid, while not in close contact with it, serves an important purpose in directing the attention of the surgeon toward it. The situation of the outer border of the scalenus anticus is well indicated by the posterior border of the sterno-cleido-mastoid, provided the latter muscle be not uncommonly developed. The

junction of the inner two inches of the clavicle with its outer portion is a far more unvarying indication of the approximate deep location of the outer border of the scalenus anticus than is the former.

The tubercle on the first rib, into which the scalenus anticus is inserted, is the guide to the vessel, the artery being directly behind it (Fig. 138).

Contiguous Anatomy.

RELATIONS OF THIRD PORTION OF SUBCLAVIAN ARTERY. (GRAY.)

In front.

Cervical fascia.

External jugular, supra-scapular, and transverse cervical veins.

Descending branches of cervical plexus.

Subclavius muscle and supra-scapular artery and clavicle.

Above.

Brachial plexus.

Omo-hyoid.

{ Subclavian artery, }
{ third portion. }

Below.

First rib.

Behind.

Scalenus medius.

Operation—Third Portion.—Place the patient on the back with the shoulders elevated from the table, head bent backward and turned to the opposite side. Draw the shoulder of the corresponding side firmly downward to the side of the patient, and retain it in that position. Compress the external jugular vein above the clavicle, long enough to cause its distention, thereby indicating its exact situation. The integument is then drawn evenly downward and incised upon the

clavicle, and will, when allowed to retract, carry the incision upward to its proper situation—one-half inch above the clavicle. The superficial fascia and platysma are then divided upon a director, being careful not to sever the external jugular, which can be either pulled aside or divided between two ligatures. The supra-scapular and transverse cervical veins should be treated in the same manner. The omo-hyoid is now sought for and drawn upward, if necessary, and the supra-scapular artery avoided.

The deep cervical fascia is torn asunder by the finger-nail or a director, and the outer border of the scalenus anticus felt for on a line with the outer margin of the sterno-cleido-mastoid, if the latter have not been divided; if so, it should be located as described under the head of "Muscular Guides to the Artery."

If the head be turned forcibly to the opposite side, the scalenus anticus will be made tense and more prominent. When found, it should be followed downward to its insertion, when the finger will

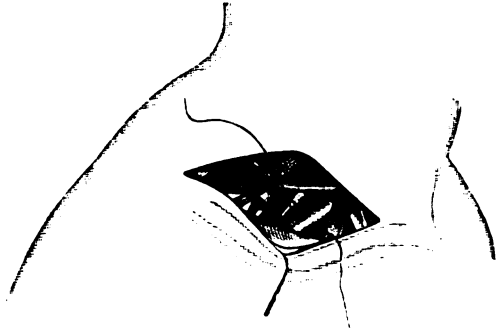


FIG. 139.—Ligature at third portion of subclavian.

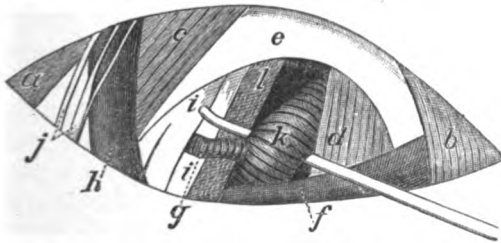


FIG. 140.—Ligature of subclavian artery, third portion. *a.* Anterior border of trapezius muscle. *b.* Sternocleidomastoid muscle. *c.* Omo-hyoid muscle. *d.* Scalenus anticus muscle. *e.* Aponeurotic tissue. *f.* Subclavian vein, partly behind clavicle. *g.* Occasional origin of the supra-scapular artery. *h.* External jugular vein. *i.* Inner cords of the brachial plexus. *j.* Superficial descending branches of brachial plexus. *k.* Subclavian artery. *l.* Connective tissue.

rest upon the tubercle of the first rib, immediately behind which the pulsation of the artery will be felt. The vessel is now carefully exposed and the needle passed from before backward (Fig. 139). Great caution should be taken not to interfere with the subclavian vein, which lies in front of, and on a lower plane than the artery (Fig. 140).

Fallacies.—The sternocleidomastoid may have an unusual breadth of origin from the clavicle, thereby causing the incision to be made too far posteriorly. The clavicular measurement will prevent this error. The tubercle on the anterior surface of a transverse process of one of the lower cervical vertebræ may be mistaken for the tubercle of the first rib. This, however, is easily recti-

fied by remembering that the rib is located downward and backward, that no contiguous pulsation is found, and that the outline of the scalenus anticus is absent. The tubercle may be absent, and the muscular insertion into the rib must then be relied upon.

The artery may be in front of the tubercle and the vein behind it. The pulsation as well as the anatomical appearances will determine the interchange of situations. The inner cord of the brachial plexus may be mistaken for the artery. A little attention to the distinctive physical characteristics between nerves and arteries will quickly settle this doubt.

Results.—Two hundred and fifty-one cases are tabulated, of which one hundred and thirty-four, or fifty-three per cent, died.

Ligature of the Second Portion.—All the muscular and linear guides are practically similar to those of the preceding.

Contiguous Anatomy.

PLAN OF RELATIONS OF SECOND PORTION OF SUBCLAVIAN ARTERY. (GRAY.)

	<i>In front.</i>	
	Scalenus anticus.	
	Phrenic nerve.	
	Subclavian vein.	
<i>Above.</i>	{ Subclavian artery, }	<i>Below.</i>
Brachial plexus.	{ second portion. }	Pleura.
	<i>Behind.</i>	
	Pleura and middle scalenus.	

Operation.—The steps essential to arrive at the proper site in this instance, are not varied from those given for the third portion, until the outer border of the scalenus anticus is well determined; the phrenic nerve and subclavian vein should then be pushed aside and the muscle divided (Fig. 140, *d*), when the retraction of its fibers will expose the artery to view. The needle is then passed as before, closely hugging the artery, to avoid the pleura below and posteriorly.

Fallacies.—The vein and artery may be transposed.

Results.—Thirteen cases are reported, of which nine, or sixty-nine per cent, were fatal.

The subclavian should always be tied in the third portion when possible; if impossible, then the second should be selected. The ligature of the first portion is unwarranted in view of the results heretofore obtained.

Ligature of the Vertebral Artery.—This artery arises from the upper and back part of the first portion of the subclavian, passes directly upward along the anterior surface of the vertebral column, and enters the foramen in the transverse process of the sixth cervical vertebra. It ascends through the foramina in the transverse pro-

cess of all the vertebræ above this, inclining outward and upward between the transverse processes of the axis and atlas, and finally runs in a deep groove on the upper surface of the posterior arch of the atlas before it ascends to pierce the posterior occipito-atloid ligament. It may be ligatured in three situations: 1, before entering the vertebral canal; 2, between the atlas and axis; 3, between the atlas and the occipital bone.

1. *The linear guide* to the artery in the first situation is drawn from the junction of the inner fourth with the outer three fourths of the clavicle, to the posterior border of the mastoid process. *The deep guides* are the tubercle of the transverse process of the sixth cervical vertebra, and the space between the borders of the longus colli and the scalenus anticus.

Contiguous Anatomy.

In front.

Internal jugular vein and its sheath.
 Inferior thyroid artery.
 Thoracic duct (left side).
 Aponeurosis between longus colli and the scalenus anticus.
 Vertebral vein.

<i>Outer side.</i>	} Vertebral }	<i>Inner side.</i>
Scalenus anticus.	{ artery. }	Longus colli.

Behind.

Cervical nerves.
 Vertebral column.

Operation.—1. The head should be turned to the opposite side and an incision about three inches and a half in length made along the anterior border of the sterno-cleido-mastoid, terminating at the upper border of the sternum. The fascia and the connections between the sterno-mastoid and sterno-hyoid are divided and these muscles separated, which exposes the common sheath of the internal jugular vein, common carotid artery, and pneumogastric nerve. This sheath is now carefully separated from its connections with the sterno-thyroid and longus colli muscles and drawn outward. The parts are now relaxed by raising the head, the inferior thyroid artery displaced, the thoracic duct avoided, and the aponeurosis covering the vessel torn through, the vein pushed aside, and the ligature passed from within outward.

Mr. Alexander, whose experience in tying these vessels on the living subject is greater than that of any other surgeon, describes his method of operating in the following language: "An incision three or four inches long is made in an upward and outward direction along the hollow which exists between the scalenus anticus and the sterno-mastoid muscles. The incision should begin just outside

and on a level with the point where the external jugular vein dips over the edge of the sterno-mastoid muscle, or, if the vein is invisible, about half an inch above the clavicle. The external vein is drawn inward with the sterno-mastoid muscle. The connective tissue now appearing, the wound is opened by a blunt director, until the scalenus anticus muscle, the phrenic nerve, and the transverse cervical artery are seen. It can not be too well remembered that the pleura is at the inner side of the wound, while below lies the subclavian artery. It is now only necessary to separate the edges of the scalenus anticus and the longus colli muscles to see the vertebral artery lying in the space between them. The artery is generally completely covered by the vein, which is drawn aside and the artery is then ligatured."

2. In this position the artery is in a triangular space formed by the rectus posticus major and superior and inferior oblique muscles. It is covered by the rectus posticus major and complexus.

Operation.—With the head turned to the opposite side and inclined forward, make an incision three inches in length along the posterior border of the sterno-mastoid, beginning half an inch below the mastoid process. A second incision is then made, beginning at the upper fourth of the first one and carried backward and downward one inch. The splenius muscle appears in view as soon as the integument and fascia are divided and pulled aside. The fibro-muscular structure of the splenius is divided, its borders separated, the layer of fat that now appears is pushed aside by the finger or handle of the scalpel, and the vessel is seen; its branches are drawn aside together with those of the second cervical nerve, the artery isolated, and the needle passed from without inward.

3. The incisions are the same as in the preceding, except that the first one begins half an inch above the mastoid process. The skin, fascia, and splenius are divided as before, the occipital artery appears at the upper angle of the wound, and is held aside; divide the aponeurosis and cellular tissue, separate the borders, enter the triangle, separate the fatty tissue, and the artery will be exposed. Pass the needle from behind forward.

Fallacy.—The vertebral arteries may enter the transverse processes of the fifth cervical vertebra, instead of the sixth.

Results.—These vessels have been ligatured forty-two times, in thirty-six of which three died; one each from hemorrhage, embolism, and pleurisy. When done for the cure of epilepsy, about twenty per cent were benefited, some of which ultimately recovered. The permanent benefit derived thus far in such cases has not been sufficiently ample to warrant the general adoption of this measure for the treatment of epilepsy.

Ligature of the Internal Mammary Artery.—The internal mam-

mary arises from the first portion of the subclavian. It descends behind the internal jugular and subclavian veins to the inner surface of the anterior wall of the chest, resting upon the costal cartilages about half an inch from the margin of the sternum. It may be ligatured in any of the five upper intercostal spaces.

Linear Guide.—About one-half inch to the outer side of the sternum is a fair indication of its locality. It has no muscular guide.

Operation.—Make an incision two inches in length along the upper border of the costal cartilage and rib. The integument, fascia, and pectoralis major muscle are divided down to the intercostal muscles. Beneath the internal intercostal muscle, surrounded by the connective tissue, the artery, accompanied by the venæ comites, will be found. The vessel is isolated, and the needle carefully passed to avoid penetrating the pleura. If the vessel be tied in the uppermost intercostal space, a single vein will attend it.

Ligature of the Inferior Thyroid Artery.—This vessel arises from the thyroid axis, and passes in a somewhat irregular course upward and inward behind the sheath of the common carotid and internal jugular vein to the thyroid gland.

The linear guide to the operation is along the anterior border of the sterno-mastoid, as in ligaturing the common carotid. The body of the fifth cervical vertebra, opposite to which it enters the gland, is an approximate *bony guide* to the vessel.

Contiguous Anatomy.—In front, the common carotid sheath and its contents, and the sympathetic nerve; the recurrent laryngeal and the œsophagus; if low in the neck, carefully avoid the thoracic duct. The respective tissues are pulled aside and the needle passed. No dangers attend the ligaturing other than those incurred by the manipulation necessary to arrive at the vessel.

Ligature of the Axillary Artery.—This vessel begins at the lower border of the first rib and extends to the lower border of the tendon of the latissimus dorsi. It may be tied in three situations: 1, above the pectoralis minor; 2, behind; 3, below that muscle. The first and last, however, are the only ones at which the vessel can be practically secured.

First Portion.—There is no linear guide to the vessel. The *linear guide to the operation* is located about one-half inch below the lower border of the clavicle, extending from within an inch or so of the sternal extremity, outward three or four inches.

The muscular guides are superficial and deep. The former is the space between the border of the deltoid and pectoralis major muscles. The latter is the pectoralis minor, its upper border corresponding to the first portion, etc., as before stated.

Contiguous Anatomy.

RELATIONS OF THE FIRST PORTION OF THE AXILLARY ARTERY. (GRAY.)

In front.

Pectoralis major.
 Costo-coracoid membrane.
 Subclavius.
 Cephalic vein.

Outer side.
 Brachial plexus.

{ **Axillary**
artery,
first portion. }

Inner side.
 Axillary vein.

Behind.

First intercostal space, and intercostal muscle.
 First serration of serratus magnus.
 Posterior thoracic nerve.

In this situation the artery lies deeply, and it is better, if possible, to ligature the third portion of the subclavian.

Operation (Fig. 141).—Place the patient upon the back with the head turned to the opposite side; elevate the shoulder and carry the arm a little distance from the side of the chest. Make an incision about four



FIG. 141.—Ligature of first portion of axillary.

inches in length on the linear guide given above, down through the integument, fascia, and platysma; separate the fibers of the pectoralis major, or divide them the full length of the wound; tear apart the underlying fascia, when the pectoralis minor muscle will be brought in view; bring the arm to the side to relax this muscle, which is then drawn to the outer

side; displace the areolar tissue carefully with the finger or a director, when the vein will be seen, which should be carried upward and inward with a blunt hook, and the artery will be noticed beneath it, and in close contact with the inner cord of the brachial plexus, which lies to its outer side and above. The needle is then passed from below upward. The cephalic vein, which empties into the axillary vein, should be cautiously avoided, as it passes between the borders of the pectoral and deltoid muscles to its termination (Fig. 142).

Fallacies.—The inner cord of the brachial plexus may be mistaken for the artery. Before tightening the ligature, pressure should be made upon the vessel, and the effect upon the radial pulse noted.

The vessel may be reached by making an incision between the borders of the deltoid and pectoral muscles about three inches in length, which should connect with the one previously made below the lower border of the clavicle. The fat and cellular tissue can then be removed or displaced as in the previous instance.

Results.—No definite records are given of the results of this operation.

Ligature in the Third Portion.—*The linear guide to the artery is*

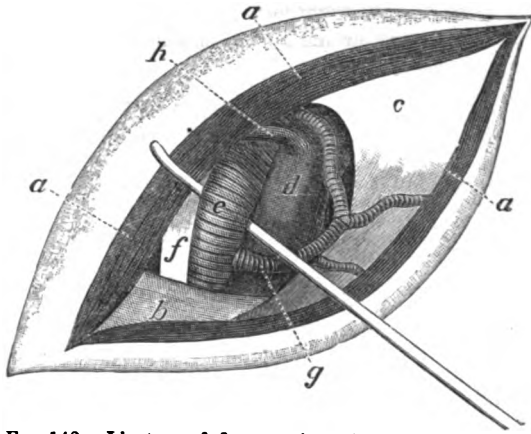


FIG. 142.—Ligature of first portion of axillary artery. *a.* Pectoralis major, divided in course of fibers. *b.* Upper border of pectoralis minor. *c.* Deep fascia (costo-coracoid membrane). *d.* Axillary vein. *e.* Axillary artery. *f.* Inner cord of brachial plexus. *g.* Acromio-thoracic branch. *h.* Cephalic vein.

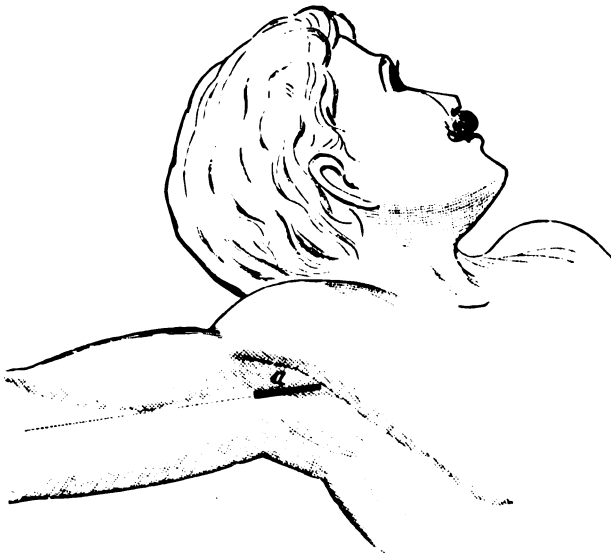


FIG. 143.—Linear guide to axillary, third portion.

a line extending upward into the axilla corresponding to the junction of its anterior and middle thirds (Fig. 143, *a*).

Muscular Guide.—The inner border of the coraco-brachialis.

Contiguous Anatomy.

RELATIONS OF THE THIRD PORTION OF THE AXILLARY ARTERY. (GRAY.)

In front.

Integument and fascia.
Pectoralis major.

Outer side.

Coraco-brachialis.
Median nerve.
Musculo-cutaneous nerve.

{ **Axillary**
 artery,
 third portion. }

Inner side.

Ulnar nerve.
Internal cutaneous nerve.
Axillary vein.

Behind.

Subscapularis muscle.
Tendons of latissimus dorsi and teres major.
Musculo-spiral and circumflex nerves.

Operation (Fig. 144).—The arm should be abducted and rotated outward. Make an incision three inches in length along the inner

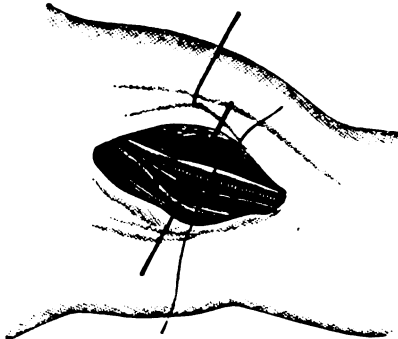


FIG. 144.—Ligature of third portion of axillary.

border of the coraco-brachialis in line of the arterial pulsation, observing that its center be above the anterior fold of the axilla; cautiously divide the tissue upon a director, drawing the median nerve to the outer, and the axillary vein to the inner side; pass the needle from within outward.

Fallacies.—Large branches may be given off at this situation, which will confuse the operator. Pressure upon the vessel prior to the tightening of the ligature will

determine the influence upon the circulation beyond.

Results.—The operation implies in itself no particular danger to the patient.

Ligature of the Brachial Artery.—The brachial artery extends

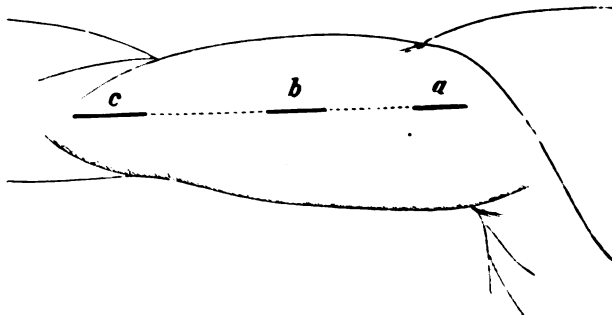


FIG. 145.—Linear guide of brachial artery.

from the lower border of the tendon of the latissimus dorsi to about one inch below the bend of the elbow-joint.

The linear guide is drawn from the junction of the middle and anterior thirds of the axilla to midway between the apices of the bony condyles of the humerus (Fig. 145).

Muscular Guide.—At its upper third it lies at the inner border of the coraco-brachialis; in the middle third, at the inner border of the biceps; in the lower third, at the inner border of the biceps tendon. It may be ligatured in three situations: at its upper, middle, and lower thirds.

Contiguous Anatomy.

PLAN OF THE RELATIONS OF THE BRACHIAL ARTERY. (GRAY.)

In front.

Integument and fasciæ.
Bicipital fascia, median basilic vein.
Median nerve.

Outer side.

Median nerve.
Coraco-brachialis.
Biceps.

{ Brachial }
artery. }

Inner side.

Internal cutaneous and
ulnar nerve.
Median nerve.

Behind.

Triceps.
Musculo-spiral nerve.
Superior profunda artery.
Coraco-brachialis.
Brachialis anticus

Operation—Upper Third (Fig. 145, a).—Abduct the arm, and rotate it outward; make an incision about three inches in length along the inner border of the coraco-brachialis. The artery, being very superficial, is quickly reached. The median nerve is drawn to the outer, and the ulnar nerve and basilic vein to the inner side; separate the artery from the vein, and pass the needle from within outward.

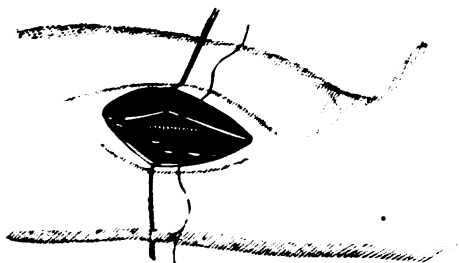


FIG. 146.—Ligature of brachial in middle third.

Operation in the Middle Third (Fig. 145, b).—Place the arm as before; make an incision three inches in length along the inner side of the biceps muscle (Fig. 146). The median nerve is found lying upon and a little to its outer side; push it aside, isolate the artery from the venæ comites, and pass the needle in the same direction as before (Fig. 147).

Operation in the Lower Third (Fig. 145, c).—Abduct the arm and

supinate the forearm. Compress the arm above to distend the median basilic vein ; make an incision about three inches in length along

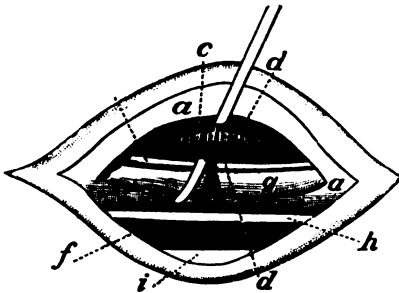


FIG. 147.—Ligature of brachial artery, middle third. *a.* Sheath of vessels and nerves. *c.* Brachial artery. *d.* Venæ comites. *f.* Basilic vein. *g.* Median nerve, pulled to inner side. *h.* Internal cutaneous nerve. *i.* Ulnar nerve.

the inner border of the tendon of the biceps ; draw aside the median basilic vein, when the artery will be felt pulsating beneath the bicipital fascia ; a suitable-sized opening is now cut through this fascia, the forearm partially flexed, the vessel separated from its veins, and the needle passed from within outward (Figs. 148 and 149).

Fallacies. — The arteries of the forearm may be given off from the axillary, or the brachial may bifurcate high up, thereby increasing the number of the large

vessels in the arm. This is determined by the comparative size of the brachial, and the influence of pressure on the circulation on the distal side of the proposed ligature. The brachial may run to-

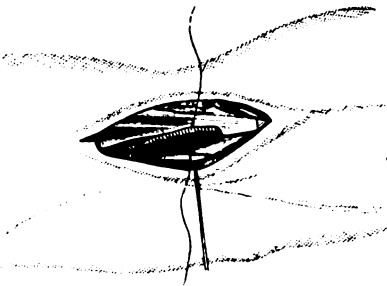


FIG. 148.—Ligature of brachial artery at lower third.

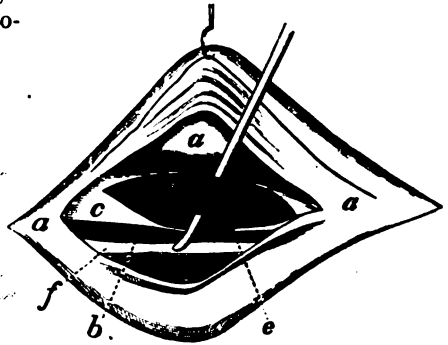


FIG. 149.—Ligature of brachial at lower third. *a.* Aponeurosis divided and turned back. *b.* Brachialis anticus muscle, inner border. *c.* Sheath of artery. *d.* Brachial artery. *e.* Collateral vein. *f.* Median nerve.

gether with the ulnar nerve behind the inner condyle. If it be not in its normal site, deep pressure may detect its pulsations elsewhere, which, together with its effect on the circulation beyond, will determine the size and site of the vessel. The incisions in the upper two thirds may be made too far inward, leading the surgeon to mistake the ulnar nerve for the median. If the forearm be flexed and traction be made upon either, its course will be determined and the mistake corrected.

The median nerve may pass behind the artery instead of in front,

when, if the circulation from above be obstructed, the artery may escape notice. The artery not unfrequently lies deeply between the brachialis anticus and biceps muscles.

Anomalous muscular slips and unusual muscular development may obscure the artery in its normal course. In such instances the pulsation will determine its location.

Occasionally, especially in female subjects, when the upper extremity is markedly concave on its outer surface, due to an unusual length of the internal condyle, the primary incision may be made to the outer side of the vessel. If, however, it be made midway between the *tips* of the bony condyles, irrespective of the overhanging soft parts, this error will not arise.

Results.—It has been ligatured seventy-six times for hemorrhage, with fifty-five recoveries.

Ligature of the Radial Artery.—This artery arises from the brachial, is an apparent continuation of it, and is superficial in its entire course. It may be ligatured in any portion of its course; it is, however, usually ligatured in three situations—at the upper and lower thirds, and at the wrist.

The linear guide (Fig. 150, *a, b*) to this vessel is drawn from midway between the tips of the bony condyles of the humerus to the inner side of the extremity of the styloid process of the radius.

The muscular guide, at its upper portion, is the inner border of the belly of the supinator longus muscle, beneath which it lies. At the lower portion of its course it lies at the inner side of the tendon of the same muscle. The almost universally recognized pulsation of the vessel at the wrist is the best practical guide to it in this location. In fact, it is only when abnormalities of size or situation of it occur at this position that the other guides to it are taken into consideration in the living subject, and under these circumstances they are of but little aid to the operator. This same statement will apply with equal force to all arteries that are similarly associated with the superficial structures of the body.

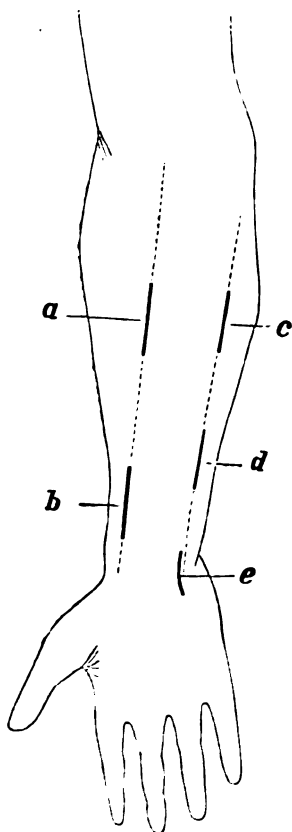


FIG. 150.—Linear guides to radial and ulnar arteries.

Contiguous Anatomy.

PLAN OF THE RELATIONS OF THE RADIAL ARTERY.

In front.

Integument—superficial and deep fasciæ.
Supinator longus.

Inner side.

Pronator radii teres.
Flexor carpi radialis.

{ Radial artery }
{ in forearm. }

Outer side.

Supinator longus.
Radial nerve (middle third).

Behind.

Tendon of biceps.
Supinator brevis.
Pronator radii teres.
Flexor sublimis digitorum.
Flexor longus pollicis.
Pronator quadratus.
Radius.

Operation—Upper Third (Fig. 151).—Supinate the forearm; press upon the arm above to distend the superficial veins; make an incision about three inches in length along the linear guide to the vessel (Fig. 150, *a*). After going through the fasciæ, the inner edge of the supinator longus will be found extending beyond the line and overlapping the artery; separate and pull this outward, when the artery will be seen lying between its veins, with the nerve to the outer side; separate the artery, and pass the needle from without inward (Fig. 152).

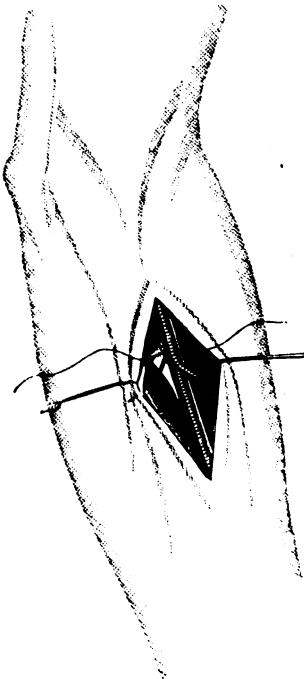


FIG. 151.—Ligature at upper third of radial.

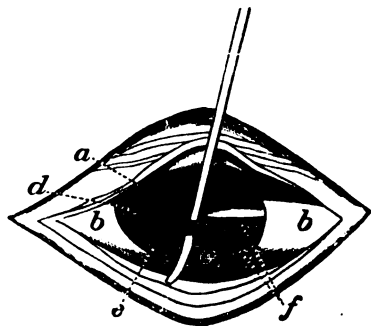


FIG. 152.—Ligature of radial artery, upper third. *a*. Inner border of supinator longus. *b*. Deep aponeurosis. *c*. Pronator radii teres. *d*. Flexor sublimis digitorum. *e*. Radial artery. *f*. Venæ comites.

Operation in the Lower Third (Fig. 153).—In this situation the

vessel is very superficial, its well-known pulsation being the best guide to it; with the arm placed as in the preceding position, make an incision two inches in length along the course of the vessel (Fig. 150,

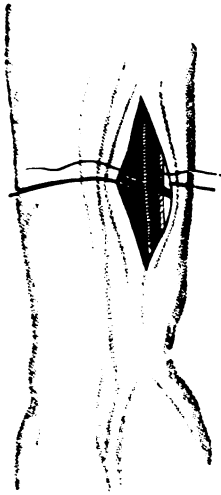


FIG. 153.—Ligature at lower third of radial.

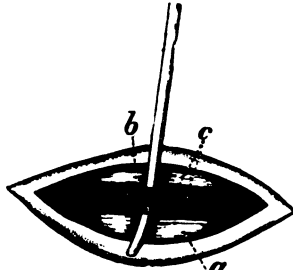


FIG. 154.—Ligature of radial artery, lower third. *a.* Flexor carpi radialis muscle. *b.* Radial artery. *c.* Venæ comites.

b). After the division of the integument and fasciæ, the artery will be seen surrounded by loose areolar tissue, accompanied by its veins, and lying to the inner side of the tendon of the supinator longus. Separate the tissues and ligature the artery, passing the needle from the nerve (Fig. 154).

Operation at Apex of Styloid Process (Fig. 155).—In this situation the vessel is found in a triangular-shaped space, bounded internally by the tendon of the extensor primi internodii pollicis; externally by that of the secundi internodii pollicis, and the base corresponding to the apex of the styloid process of

the radius. If the thumb be forcibly extended, the outlines of the space will be well marked.

Operation.—Place the hand midway between supination and pronation, and, having ascertained the exact situation of the tendon of the extensor primi internodii pollicis, make an incision along its outer border about an inch in length; use care not to divide the superficial veins. The areolar tissue and the ex-



FIG. 155.—Ligature of radial at apex of styloid process.

tensor primi internodii pollicis are pushed aside, and the vessel found somewhat deeply situated. The needle can be carried in either direction.

Fallacies.—The radial artery may lie upon the fascia and supinator longus instead of beneath them; it may pass over the extensor tendons of the thumb instead of beneath them. The artery may be mistaken for a radical of the radial vein. The latter is superficial, and has likewise other characteristics of a vein.

Results.—During the late war it was tied twenty times, with four fatal results.

Ligature of the Ulnar Artery.—This vessel is larger than the radial. It is given off from the brachial about one inch below the bend of the elbow, passes, obliquely inward and downward, deeply beneath the superficial flexors of the forearm, and gains the ulnar side a little above its middle; becoming superficial, passes along the outer side of the flexor carpi ulnaris to the radial side of the pisiform bone, where it terminates in the superficial palmar arch. It may be ligated in three situations: 1. At the junction of the upper and middle thirds. 2. At the lower third. 3. At the wrist. It can be ligated at its upper third, but such a step has no practical utility except when called for by a direct tying of this portion of the vessel, when, of course, as in all cases, a ligature should be applied at both sides of the bleeding point.

The linear guide is drawn from the extremity of the internal condyle to the pisiform bone (Fig. 150, *c, d, e*).

The muscular guide is the outer border of the flexor carpi ulnaris.
Contiguous Anatomy.

PLAN OF RELATIONS OF THE ULNAR ARTERY IN THE FOREARM.

<i>In front.</i>			
	Superficial layer of flexor muscles.	} Upper half.	
	Median nerve.		
	Superficial and deep fasciæ, lower half.		
<i>Inner side.</i>			<i>Outer side.</i>
Flexor carpi ulnaris.	} Ulnar artery } in forearm. }		Flexor sublimis digitorum.
Ulnar nerve (lower two thirds).			
<i>Behind.</i>			
	Brachialis anticus.		
	Flexor profundus digitorum.		

Operation—Junction of Middle and Upper Thirds (Fig. 156).
—Supinate the forearm and make an incision about three inches in

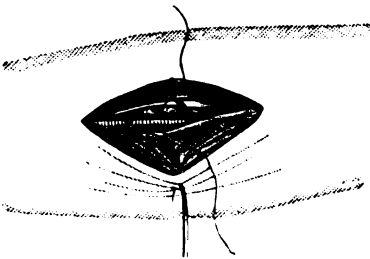


FIG. 156.—Ligature of ulnar artery, junction of middle and upper thirds.

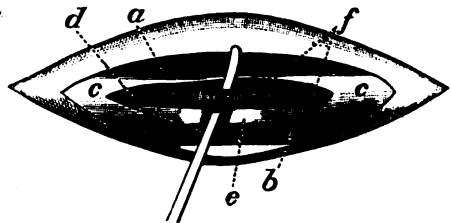


FIG. 157.—Ligature of ulnar, junction of middle and upper thirds. *a.* Flexor sublimis digitorum. *b.* Flexor carpi ulnaris. *c.* Sheath of artery. *d.* Ulnar artery. *e.* Ulnar nerve. *f.* Venæ comites.

length, beginning about four finger-breadths below the internal condyle, on the linear guide to the vessel (Fig. 150, c). Divide the fascia on a director; seek for the line of connection between the borders of the flexor carpi ulnaris and the flexor sublimis digitorum. It is of a yellowish-white color. Divide it on a director, and pull the muscles apart, when the ulnar nerve will be seen, to the outer side of which will be found the artery with its accompanying veins;




FIG. 158.—Ligature at lower third of ulnar artery.

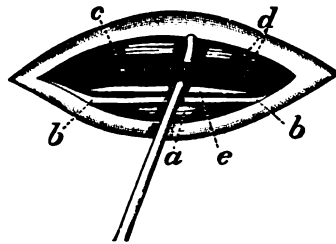


FIG. 159.—Ligature of ulnar artery, lower third. *a.* Flexor carpi ulnaris muscle. *b.* Deep aponeurosis. *c.* operation; ext- Ulnar artery. *d.* Venæ comites. *e.* Ulnar nerve.

separate the artery and pass the needle from within outward (Fig. 157).

Operation in the Lower Third (Fig. 158).—

Place the arm as in the preceding operation; extend the hand to make the tendon

of the flexor carpi ulnaris tense; make an incision about three inches in length along the radial border of this muscle down to the fascia (Fig. 150, d), which should be divided on a director, exposing the tendon of the flexor carpi ulnaris, which should be drawn inward, and the artery is seen beneath it. Isolate the vessel from its veins and pass the needle from within outward (Fig. 159).

Operation at the Wrist (Fig. 160).—Place the hand on its dorsal surface and make an incision about two inches in length along the radial side of the pisiform bone, with its convexity outward (Fig. 150, e); carry it downward along the side of that bone through the fascia and fatty tissue to the vessel. Flex the hand and pass the ligature from within outward.




FIG. 160.—Ligature of ulnar artery at wrist.

Fallacies.—Between the upper and middle thirds (150, e), the interspace between the flexor carpi ulnaris and flexor sublimis may be mistaken for the space between the flexor carpi ulnaris and the palmaris longus, or flexor carpi radialis. If the hand and fingers be moved alternately, the proper muscles can be ascertained.

In the upper third the vessel runs inward to meet its linear guide ; therefore an attempt to find the artery by the linear guide, in this situation, will be futile. The artery may run beneath the fascia, or otherwise vary in its course ; if not in its normal situation, deep pressure may define it.

Results.—The ulnar artery was ligatured during the war ten times, with three deaths.

The **Superficial Palmar Arch** can be tied at the seat of injury. It must be remembered that beneath it lie the tendons of the flexors of the fingers and the divisions of the median and ulnar nerves.

Linear Guide (Fig. 161).—Extend the thumb at nearly a right angle to the carpus, and draw a line transversely across it corresponding to its palmar border ; this will denote the lower limit of the arch.



FIG. 161.—Linear guide to superficial arch and flexor tendons.

Operation.—Make an incision half or three quarters of an inch in length at the seat of the injury, through the

integument, palmaris brevis muscle, and palmar fascia, down to the vessel. Ligature all bleeding points, and also all uninjured branches arising close to the seat of the injury of the main vessel, to avoid the possibility of secondary hemorrhage.

Ligature of the Common Carotid Artery.—

The right common carotid arises from the innominate artery, and the left from the arch of the aorta. The left is consequently longer and more deeply situated in the chest. The left, after leaving the aorta, passes obliquely upward to a point opposite the left sterno-cla-

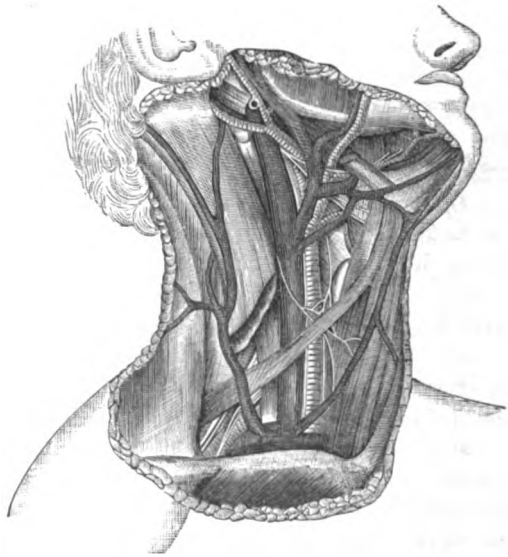


FIG. 162.—Surgical anatomy of the common carotid.

vicular articulation ; and, from this point upward, the right and left common carotids maintain substantially the same course to the upper border of the thyroid cartilage, where each divides into the internal and external carotids.

Each vessel may be ligatured in three situations : 1. At the root of the neck. 2. Below the omo-hyoid muscle. 3. Above the muscle. The last two are the situations commonly selected, the first not being employed except under forced circumstances.

The linear guide to the vessel is a line drawn from the sterno-clavicular articulation to midway between the angle of the jaw and mastoid process (Fig. 136).

The muscular guide to the operation is the anterior border of the sterno-cleido-mastoid.

Contiguous Anatomy.

PLAN OF THE RELATIONS OF THE COMMON CAROTID ARTERY. (GRAY.)

In front.

Integument and fascia.
Platysma.
Sterno-mastoid.
Sterno-hyoid.
Sterno-thyroid.

Omo-hyoid.
Descendens noni nerve.
Sterno-mastoid artery.
Superior thyroid, lingual, and facial veins.
Anterior jugular vein.

Internally.

Externally.

Internal jugular vein.
Pneumogastric nerve.

{ Common }
{ carotid }
{ artery. }

Trachea.
Thyroid gland.
Recurrent laryngeal nerve.
Inferior thyroid artery.
Larynx.
Pharynx.

Behind.

Longus colli.
Rectus capitis anticus major.

Sympathetic nerve.
Inferior thyroid artery.

Recurrent laryngeal nerve.

Operation below the Omo-hyoid (Fig. 163).—Place the patient on the back, with the shoulders slightly elevated, and the head turned to the opposite side ; make an incision three inches in length, beginning a little above the cricoid cartilage, on the line stated, and carry it downward along the anterior border of the sterno-mastoid (Fig. 136, c) ; divide the superficial fascia, platysma, and deep fascia on a director, thus exposing the anterior border of the sterno-mastoid muscle. If the sterno-mastoid artery be divided, ligature it. If not injured, push it aside, together with the thyroid vein ; draw the sterno-mastoid muscle outward, and the sterno-thyroid and hyoid muscles inward, when the lower border of the omo-hyoid will be seen above ; divide the fascia beneath these muscles and draw it apart, when the descendens noni nerve will be seen resting upon the inner portion of the

common sheath of the carotid, internal jugular vein, and the pneumogastric nerve, the artery being to the inner side, the nerve behind

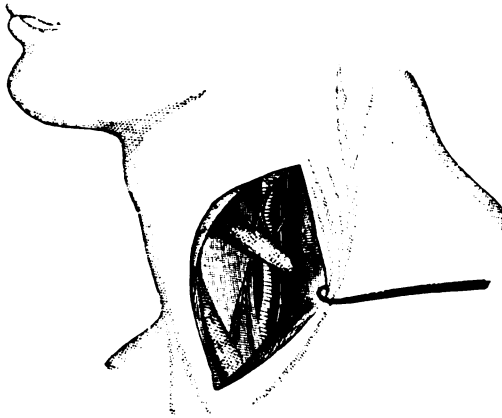


FIG. 163.—Ligature below omo-hyoid.

and between the two and out of sight. Place the finger upon the sheath, to ascertain the exact location of the artery; raise the portion of the sheath, at its inner side corresponding to the site of the artery, with a tenaculum or the thumb-forceps, cut a small opening into it, and pass the needle from without inward, cautiously insinuating it between the vessel and its sheath (Fig. 164). This ma-

nipulation should be carefully done, else either the vein, pneumogastric, or recurrent laryngeal nerves may be injured.

Operation above the Omo-hyoid.—The vessel is more superficial in this situation, which is sometimes denominated “The site of election” (Fig. 136, *b*).

Place the patient as before, and make an incision along the anterior border of the sterno-mastoid, beginning at about the angle of the lower jaw, and extending it a little below the cricoid cartilage; divide the superficial fascia, platysma, and deep fascia on a director, carefully avoiding the small veins; expose the anterior border of the sterno-mastoid, and slightly flex the head to relax the tissues of the neck; draw the edges of the wound apart, and the artery will be felt pulsating in its sheath. If the jugular vein overlap it, it should be emptied by pressure above and below, and be drawn outward; then care-

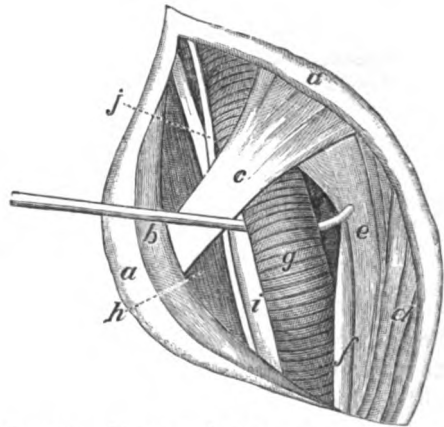


FIG. 164.—Ligature of the common carotid. *a*. Platysma myoides muscle and fascia. *b*. Sterno-mastoid, drawn outward. *c*. Omo-hyoid, crossing the artery. *d*. Sterno-hyoid muscle. *e*. Sterno-thyroid muscle. *f*. Sheath of the vessels. *g*. Common carotid raised from its sheath. *h*. Jugular vein, pushed back. *i*. Pneumogastric nerve, abnormally prominent. *j*. Descendens noni nerve—sometimes in the sheath.

fully done, else either the vein, pneumogastric, or recurrent laryngeal nerves may be injured.

fully open the sheath as before, avoiding the descendens noni nerve ; pass the needle carefully from without inward. It is well to observe the upper border of the omo-hyoid muscle before opening the sheath, that the exact location to apply the ligature be assured.

Fallacies.—The artery may bifurcate at the cricoid cartilage, and even lower ; however, this is extremely rare ; under such circumstances both branches should be secured. If the vessel be pressed upon before the ligature is tied, it will determine the influence of the ligaturing upon the branches above.

The jugular vein may be much dilated, overlie and receive the impulse of the artery, and therefore be mistaken for it. This fallacy may be avoided if that vessel be emptied of its blood in the manner before described. The thyroid gland may be enlarged and obscure the artery by displacing or overlapping it. Under these conditions it should be pushed aside. It is reported that the omo-hyoid muscle has been mistaken for the artery ; the fact of its being muscular, taken in connection with the direction of its fibers, together with its anatomical relations, should eliminate any danger of this mistake. If branches arise from the main trunk, they may be mistaken for the external carotid. The comparative size of the vessel and the influence of pressure on the circulation of the internal carotid will effectually solve the question. If branches be given off from the common carotid near the site of the proposed ligaturing, they should be tied also.

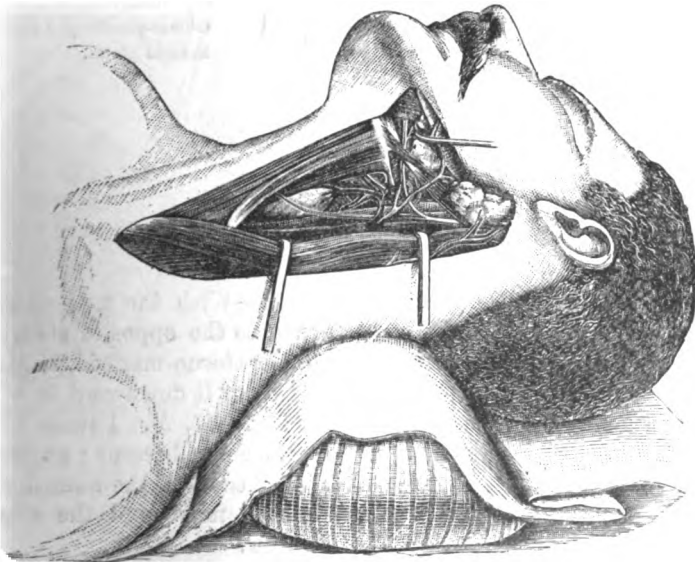


FIG. 165.—Surgical anatomy of external carotid.

Its.—This vessel has been tied seven hundred and eighty-nine

times, for various reasons, of which three hundred and twenty-three, or about forty-one per cent, have died.

Ligaturing of both common carotids, either simultaneously or at variable intervals, has been done thirty-six times. The shortest interval between the operations in which recovery has taken place is four and one half days. Instances where the interval varied from thirteen to thirty days are reported, with recovery of the patients.

Ligature of the External Carotid Artery.—This artery arises from the common carotid at or just above the upper border of the thyroid cartilage. It ascends in a slightly curved course, with the convexity forward, to a point midway between the neck of the condyle of the lower jaw and the external auditory meatus. The upper part of its course lies in the substance of the parotid gland (Fig. 165).

This artery may be tied in two situations: 1, between the posterior belly of the digastric and its origin; 2, above the belly of the digastric. The former situation is the one to be selected, if possible.

The *linear* and the *muscular guides* are substantially the same as for the common carotid.

Contiguous Anatomy.

PLAN OF THE RELATIONS OF THE EXTERNAL CAROTID. (GRAY.)

In front.

Integument, superficial fascia.
Platysma and deep fascia.
Hypoglossal nerve.
Lingual and facial veins.
Digastric and stylo-hyoid muscles.
Parotid gland, with facial nerve and temporo-maxillary vein in its substance.

{ External
carotid
artery. }

Behind.

Superior laryngeal nerve.
Stylo-glossus.
Stylo-pharyngeus.
Glosso-pharyngeal nerve.
Parotid gland.

Internally.

Hyoid bone.
Pharynx.
Parotid gland.
Ramus of jaw.

Operation below the Digastric Muscle.—With the patient on the back, head slightly extended and turned to the opposite side, make an incision along the anterior border of the sterno-mastoid, beginning opposite the angle of the lower jaw, and carry it downward to a point nearly opposite the cricoid cartilage (Fig. 137, *b*). Divide the superficial fascia, platysma, and deep fascia on a director; expose the anterior border of the sterno-mastoid. The edges of the wound should be drawn apart, when the hypoglossal nerve and the digastric and stylo-hyoid muscles will come into view.

The end of a grooved director should now be employed to separate the stylo-hyoid muscle on the inside the lingual and facial veins, together with the areolar tissue and lymphatic glands that rest upon the vessel. Expose the

artery and pass the ligature from without inward. The internal jugular vein oftentimes overlaps the vessel, and should be carefully drawn aside, or treated as recommended in ligaturing the common carotid.

Before the ligature is tied the following facts should be carefully observed : 1. If it be the external carotid around which the ligature is passed, this can be ascertained by pressing upon the vessel and observing its effect upon the circulation of the facial. 2. The distance of the seat of the ligature from collateral branches ; this can only be determined by carefully exposing the vessel for half an inch above and below the seat of the ligature. If vessels be found within this extent, they too should be ligatured to destroy the possibility of any interference with the formation of the internal clot. 3. That the ligature be not carried around the external and internal carotids at, or just above, their point of bifurcation ; if it be around both, pressure will check the pulsation of both ; if but one, it will have a like effect on the circulation of the vessel pressed upon.

Other Fallacies.—Enlarged lymphatic glands resting on the vessel may be mistaken for it. They need cause but momentary thought, since their circumscribed outline and mobility will determine their nature. If enlarged, they should be removed, otherwise they can be pushed aside. The superior thyroid branch may be confounded with the lingual. If the course of the respective vessels be observed, they can be readily distinguished ; the superior thyroid arises nearest the bifurcation, arches upward and forward, then passes quite directly downward. The lingual does not arch downward, but passes upward and inward to gain the upper border of the great cornu of the hyoid bone, which can be easily outlined by the finger.

Operation above the Digastric.—Make an incision from the lobe of the ear to the greater cornu of the hyoid bone, along the anterior border of the sterno-mastoid, carefully avoiding the parotid gland. Divide the superimposed tissues as before, down to the digastric muscle ; pull it, together with the stylo-hyoid, downward, and if the jugular vein be in the way, push it outward, and pass the ligature from without inward.

Results.—The external carotid has been ligatured seventy-eight times, with four deaths from the operation.

Ligature of the Internal Carotid Artery.—The internal carotid begins at the bifurcation of the common carotid, at or a little above the upper border of the thyroid cartilage, and passes perpendicularly upward in front of the transverse processes of the three upper cervical vertebræ, to the carotid foramen in the petrous portion of the temporal bone, through which it enters into the cranial cavity. At its origin and in the lower portion of its course it lies *externally* and *posteriorly* to the external carotid artery. It may be ligatured in any part of the course between its origin and the angle of the lower jaw.

The *linear* and *muscular guides* of the external carotid artery are suitably adapted to properly locate the internal carotid.

Contiguous Anatomy.

PLAN OF THE RELATIONS OF THE INTERNAL CAROTID ARTERY IN THE NECK. (GRAY.)

In front.

Skin, superficial and deep fasciæ.
Parotid gland (above the angle of the jaw).
Stylo-glossus and stylo-pharyngeus muscles.
Glosso-pharyngeal nerve.

Externally.

Internal jugular vein.
Pneumogastric nerve.

{ **Internal carotid** }
artery. }

Internally.

Pharynx.
Ascending pharyngeal artery.
Tonsil.

Behind.

Rectus capitis anticus major.
Sympathetic.
Superior laryngeal nerve.

It may become necessary to ligature this artery on account of a penetrating wound received from without or from within the mouth. Ulcerations of and operations on the tonsils have been complicated with injuries to this vessel that have caused death from hemorrhage. It is therefore very important to recall the relations of the tonsil and pillars of the pharynx to this artery, in connection with all injuries and morbid processes of their structures. The angle of the jaw is located directly externally to the tonsil, and it therefore may become a practical guide to the incision for ligaturing the artery in this situation.

Operation.—The position of the neck of the patient and the location of the primary incision are similar to those for the ligaturing of the external carotid. The respective tissues are carefully divided on a director down to the muscles, which are then pulled aside, and the ligature is passed from without inward, carefully avoiding the jugular vein and the pneumogastric nerve at the center, and the pharynx at the inner side.

Fallacies.—The internal carotid may arise from the arch of the aorta, and when this occurs hemorrhage from it can be checked only by ligaturing the internal carotid itself. If but one ligature be applied to the internal carotid for hemorrhage, or if the common carotid be ligatured alone for the same reason, the collateral circulation may cause a continuation of the bleeding. A ligaturing of the internal carotid at both sides of the bleeding point is the only certain means of arresting the hemorrhage permanently. The internal carotid may lie internal to the external carotid. It may be tortuous, or even be absent.

Results.—This vessel has been tied alone three or four times ; with

either the common or external carotid, or both, fifteen times. Only six of these patients died, and from the causes calling for the procedure.

Ligature of the Superior Thyroid Artery.—This vessel comes from the external, or from the common carotid near the point of its bifurcation. It passes upward and forward, at first quite superficially, then runs downward and less superficially to enter the thyroid gland.

Operation.—Make an incision about three inches in length along the anterior border of the sterno-mastoid, its center corresponding to a point opposite the thyro-hyoid space. The carotid sheath should be exposed as in the ligaturing of that vessel, and the artery sought for along its inner border.

Ligature of the Lingual Artery.—This vessel arises from the external carotid opposite the hyoid bone, and runs upward and inward to about one quarter of an inch above the upper border of its greater cornu, and passes horizontally parallel with it, resting upon the middle constrictor of the pharynx, and is covered first by the digastric and stylo-hyoid muscles, and more internally by the hyo-glossus. It then ascends between the hyo-glossus and genio-hyo-glossus muscles and terminates in the ranine artery.

It has no superficial muscular guide ; a linear guide may be drawn parallel with, and a fourth of an inch above, the greater cornu of the hyoid bone (Fig. 136, *a*) ; practically, however, the upper border of the greater cornu of the hyoid bone marks its situation. It may be ligatured in three situations : 1. At the apex of the greater cornu. 2. Between the cornu and the posterior belly of the digastric. 3. In the triangle made by the digastric and mylo-hyoid muscles, and hypoglossal nerve.

Operation between the Digastric and the Greater Cornu.—Place the patient on the back, and turn the head to the opposite side ; carefully define the greater cornu of the hyoid bone. If the neck be fleshy, this will be somewhat difficult. It can be made more prominent on the side of the operation by pushing against its body on the opposite side, being careful to press it directly toward that point, otherwise it may mislead the operator. After the patient is thoroughly anæsthetized to prevent spasmodic movements of the muscles attached to the hyoid bone, make an incision about two or three inches in length parallel with the upper border of the cornu, which should pass downward and outward to nearly the anterior border of the sterno-mastoid (Fig. 136, *a*). Divide the superficial fascia, platysma, and deep fascia on a director ; draw upward the submaxillary gland and divide the deep aponeurosis, when the digastric and stylo-hyoid muscles and the hypoglossal nerve will be exposed. Accurately locate the greater cornu with the finger and fix it with a tenaculum, draw up the digastric and the stylo-hyoid muscles and hypoglossal nerve with a blunt hook, push

aside the lingual vein if seen, and pick up the fibers of the hyo-glossus with a pair of forceps, and incise them in the direction of the external incision about one quarter of an inch above the greater cornu ; beneath

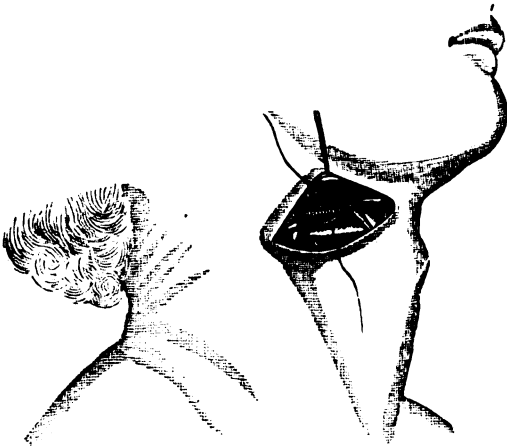


FIG. 166.—Ligature of lingual artery.

them will be found the vessel, sometimes accompanied by the lingual vein (Fig. 166). Pass the needle from the vein. Before tying the ligature, ascertain if pressure will stop the pulsation of the artery.

Ligature in the Third Situation.—This is often called “the place of election.” Make an incision transversely two inches long, concavity upward, and its center just within the

middle of the cornu of the hyoid bone. Divide the integument, superficial fascia, and platysma, carefully avoiding the superficial veins ;

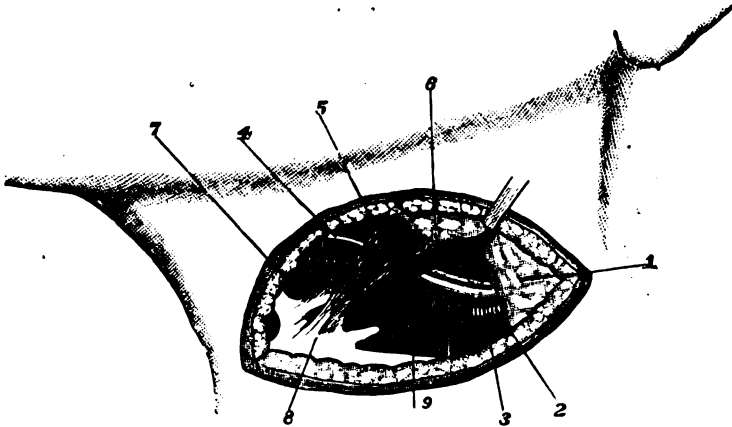


FIG. 167.—Surgical anatomy of the lingual artery. 1. Submaxillary gland. 2. Lingual artery. 3. Lingual vein. 4. Hypoglossal nerve. 5. Stylo-hyoid muscle. 6. Digastric muscle. 7. Mylo-hyoid muscle. 8. Hyoid bone. 9. Hyo-glossus muscle.

divide the deep fascia and pull upward the submaxillary gland, when the posterior belly of the digastric will come into view, as also the posterior border of the stylo-hyoid muscle and the hypoglossal nerve, accompanied usually by the lingual vein. Carefully outline the triangle before mentioned, pinch up the fibers of the hyo-glossus, and divide them midway between the hyoid bone and the nerve, when the artery

will be seen beneath (Fig. 167). Separate it from the vein, if the vein lie beneath the muscle and has not been seen before, and pass the ligature.

Ligature in the First Portion.—In this situation the vessel is tied between the point of its giving off and the tip of the greater cornu of the hyoid bone.

Operation.—Make an incision three inches in length running obliquely downward and backward, its center corresponding to the greater cornu. The various tissues are carefully divided as before, and the hypoglossal nerve is exposed. The numerous veins located in the course are now pushed aside, and the artery carefully sought for at the point of the cornu, and ligatured. This operation, on account of the absence of a definite deep guide to the location of the vessel, and the uncertainty of its point of origin, together with the great number of large veins in the course of the search, is much less feasible than either of the other two.

Fallacies.—The hypoglossal nerve may be mistaken for the artery. The nerve rests on the hyo-glossus; the artery runs beneath it. This, together with the pulsation of the artery and other distinctive anatomical features, should render the discrimination easy. It is well to know, however, that the movements of the tissues dependent on the acts of respiration make it somewhat difficult, and often impossible, to detect the arterial impulse. If, however, the supposed artery be carefully isolated, the ligature passed around it, and a good light thrown into the wound, its tortuous outline will be noticed with each pulsation. The pulsation can be seen best in the interval of the respiratory acts, when the tissues are quiet.

The lingual vein may be mistaken for the artery. This vessel sometimes runs with the artery behind the hyo-glossus; more frequently, however, it rests on this muscle. It has the characteristic color of a vein, and is larger than the artery. The lingual artery may be absent on one side. After the division of the fibers of the hyo-glossus, the search for the vessel must be conducted cautiously to avoid opening into the pharynx.

Results.—It has been tied repeatedly with great advantage, for the purpose of controlling hemorrhage from the tongue, and delaying a morbid growth of the same.

Ligature of the Facial Artery.—The facial is one of the large branches of the external carotid. It arises from it just above the tip of the greater cornu, or about one inch from the bifurcation of the common carotid, passes forward and upward beneath the ramus of the lower jaw, going through the substance of the submaxillary gland, and gains the external surface of the maxilla at the anterior border of the orbicular muscle, lying in the groove between the maxilla and the orbicular muscle, a distance of one inch from the tip of the greater cornu.

guide in a portion of its course. It may be *ligatured* in *two situations*: in the neck, and as it crosses the ramus of the jaw, the latter being the better. In the former, the head is turned to the opposite side, and an incision of about three inches in length is made obliquely downward and forward a little in front of the anterior border of the sterno-mastoid, its center being at a point about one third of an inch above the tip of the greater cornu. The dissection is carefully made as in ligaturing the lingual at this first portion, pushing aside the facial and other contiguous veins, drawing up the digastric and passing the ligature.

Operation at the Ramus of the Jaw.—Place the patient as before, draw the skin upward over the ramus, so that when retraction of the tissues occurs the cicatrix will be beneath the jaw; make an incision about two inches in length along the border of the jaw, divide the tissues on a director (Fig. 137, c), down to the vessel; isolate it, and pass the ligature. If a resulting cicatrix be of no moment, the primary incision can be

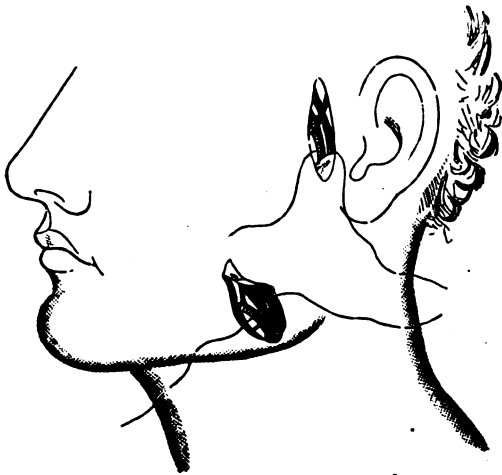


FIG. 168.—Ligature of facial and temporal arteries.

made in the long axis of the vessel along the anterior border of the masseter muscle (Fig. 168).

Fallacies.—At its origin this vessel may be mistaken for the lingual. Interruption of the circulation will easily determine the difference.

Ligature of the Temporal Artery.—The temporal is one of the terminal branches of the external carotid. It begins in the substance of the parotid gland between

the neck of the lower jaw and the external meatus and passes upward across the root of the zygoma, subcutaneously, where its pulsation can be distinctly felt. About two inches above the zygomatic process it divides into its terminal branches.

The zygomatic process is the bony guide to it.

Operation (Fig. 137, d).—Make an incision in the line of the vessel, as indicated by its pulsation, about one fourth of an inch in front of the tragus and one inch in length. Divide the skin and fascia; expose the vessel and pass the ligature as to avoid the vein and nerve (Fig. 169).

—This artery arises from the

external carotid a trifle above the facial, and passes upward and outward to the interval between the transverse process of the atlas and the mastoid process of the occipital bone. It then passes over the posterior portion of the skull midway between the external occipital protuberance and the mastoid process (Fig. 137, *e*). It has no muscular guide. It may be tied at its origin or behind the mastoid process.

Operation at its Origin.—Make an incision along the inner border of the sterno-mastoid, about three inches in length, its center corresponding to a point a little above the apex of the greater cornu of the hyoid bone. Divide the superficial tissues carefully on a director; separate the areolar tissue with its blunt extremity; push aside the veins and find the posterior belly of the digastric. A little below this will be seen the ninth pair of nerves, winding around the object of search. Pass the needle from the nerve.




FIG. 169.—Ligature of occipital artery.

Operation behind the Mastoid Process (Fig. 169).—Make an incision about two inches in length one-half inch behind and a little below the mastoid process. Divide the integument and attachments of the sterno-mastoid and the splenius muscles; feel for the pulsation at the bottom of the wound. Isolate the artery and pass the ligature.

CHAPTER V.

OPERATIONS ON VEINS, CAPILLARIES, ETC.

Ligature of Veins.—Veins, like arteries, may be ligatured in their continuity or at their divided extremities. Large venous branches, when divided in the course of an operation, should always be tied, otherwise they may give rise to an objectionable amount of oozing, which will interfere with the rapidity of the union of the divided surfaces, and possibly require the re-opening of the wound to secure the bleeding points. If a large vein be nicked during an operation—as the internal jugular, during the removal of growths from the neck—ligatures may be thrown around it, above and below the opening, rather

than to tie the nicked portion. The latter procedure is liable to be followed by secondary hemorrhage. The practice of ligaturing the opening, or of sewing its divided borders by fine catgut, is highly extolled by many writers. If it be determined to tie the vessel, it should be done above and below the wound of the vessel, else the return circulation will cause secondary hemorrhage. If it be possible at the onset to surround the patient with the degree of surveillance necessary to detect and treat secondary hemorrhage, I am of the opinion that the practice of sewing the nick with the continuous or other suitable form of suture—such as is used for intestinal wounds—offers the better opportunity for rapid recovery. Aside from the ligaturing of veins on account of traumatism, they are ligatured in their continuity for the purpose of causing their occlusion in those cases in which they are in a dilated or varicose condition.

Operations for Varicose Veins.—When the veins of the lower extremities become too much distended to be amenable to palliative measures, it is often necessary to resort to operative interference, which has for its object the occlusion of the distended canals. Injection, acupressure, and ligaturing are the common means employed.

Injection.—The vein is compressed by the fingers above and below the proposed point of injection—leaving an intervening space of an inch or less—or by small pads confined in position with adhesive plaster, the latter being the better plan. Into the isolated portion twenty or thirty drops of a twenty-per-cent solution of liquor ferri subsulphatis and water are then slowly injected. Almost immediately the contents of the vessel become coagulated, when the pressure can be removed. The limb should be kept quiet for a few days, and any tendency to undue inflammation combated.

The results of this operation, while not so favorable as other expedients, are, nevertheless, very satisfactory. Of the one hundred and three cases some time since reported, seventy-nine were cured, one died, and of the remainder, sixteen were failures.

Acupressure.—This is substantially the same as the application of acupressure for arresting the circulation of arterial trunks. It consists simply of carrying thoroughly purified needles or pins, which may or may not have been constructed for the purpose, beneath the vein at intervals of an inch or so, and compressing the superimposed tissues by means of carbolized silk or cotton yarn wound over the protruding ends of the pins. The pins are removed on the sixth or seventh day, depending on the degree of ulceration produced. Caution should be observed that the pins be not passed through instead of beneath the vein, otherwise a serious phlebitis may follow.

Subcutaneous Ligaturing.—This is accomplished by passing a carbolized needle, armed with a fine wire or a catgut ligature, in front of and across the vein, after which the direction is changed so as to

carry it beneath the vessel and out at the point of entrance. If wire be used it is then twisted and cut short, and the opening closed antiseptically. Should catgut be employed, it is tied, and cut, and the opening treated in the same manner. Three or four of these constrictions may be applied at intervals of an inch. If the blood in the intervening spaces becomes necrosed, giving rise to fluctuation, it should be evacuated, as absorption is then impossible. In the subcutaneous ligaturing of varicose veins—such as the long and short saphenous veins—that are accompanied by nerves, the nerves may be accidentally included by the ligature. It is safer, in such instances, to expose the vein and pass the ligatures, as in arterial ligaturing, after which the included portion of the vein can be excised, or simply divided. Thorough antiseptics should be practiced in such cases.

Hemorrhoids.—A varicose condition of the hemorrhoidal veins causes a disease denominated hemorrhoids or piles, for the cure of which various radical measures are recommended. The patient is prepared by a saline cathartic, which should be followed by an enema, a few hours prior to the operation. He should then be etherized, placed upon a table of suitable height, with the buttocks drawn down to the edge; the thighs are then elevated, drawn apart, and the nates separated. *If the growths be of the external variety*, and not inflamed, they can be nipped off with a pair of scissors, being careful not to cut them too closely, else the resulting cicatrization may cause a narrowing of the anal orifice. Local anæsthesia is sufficient to overcome the pain attending this operation. If the hemorrhoid be distended, tender, and painful, it is generally necessary to employ general anæsthesia. The tumor should be taken between the thumb and finger, raised up, drawn out, transfixed near the base, and cut outward; gentle pressure will then evacuate its contents, after which a pellet of fine oakum saturated with balsam of Peru, marine lint, or iodoform gauze, should be placed in the bottom of the sack, and the operation is completed. To facilitate union, the transfixing incision is made in the direction of the radiating folds of the anus.

Operations for Internal Hemorrhoids.—These are quite numerous, but the following are believed to secure the best results:

Excision.—This method is reckoned among those which secure the best results in selected cases. It causes little after-pain, and recovery takes place within a week or ten days. It is applicable to those cases where but three or four tumors exist, which are not very large, and have well-defined bases. The sphincter should be well dilated and the anus opened with a speculum or retractor. The pile is then seized at the base with a volsella, and cut off with a pair of scissors above the point grasped, which should be held till all arterial hemorrhage is stopped by twisting the bleeding points. After it has ceased, pledgets of lint saturated with tannin and water, or with liquor ferri subsul-

phatis, are applied to the cut surfaces, and the patient kept quiet for twenty-four to forty-eight hours.

Results.—This method of operating has been frequently performed, and with eminent success.

Crushing.—This method consists in crushing the pedicle of the growth by an improvised instrument or one especially constructed for that purpose (Fig. 170). It is not suitable for universal application, but rather to those tumors which



FIG. 170.—Allingham's screw crushing instrument for hemorrhoids.

possess well-defined bases. The integument, if it be connected with the tumor, should be incised, otherwise too great pain will be caused.

Operation.—The patient being prepared as in the preceding instance, the pile is pulled between the bars of the instrument by the aid of a hook or a volsella, after which the screw is turned tightly against it. The projecting portion is then cut off. The instrument is retained in position for half a minute or so, to insure against the danger of hemorrhage. While this method may be classed among the satisfactory ones, it possesses no superiority over the treatment by ligature, and as a rule causes more pain, less speedy recovery, and exposes the patient to the possible danger of subsequent hemorrhage.

Ligaturing.—This method may be employed with or without incision, the latter being preferable. The treatment without incision is to pass a needle, armed with a double ligature of stout carbolized silk or catgut, through the base of the growth, tying each half separately, after which the pile is cut off below the ligature. If strong catgut be used, the ends should be divided close to the pedicle, while with silk, one end may be allowed to hang from the anus.

Ligature with incision consists in drawing down the tumors by aid of forceps or volsella to the anus, or beyond it, and with a pair of curved scissors dividing them from their connection with the sub-mucous membrane from below upward, parallel with the bowel, far enough to leave the pile connected only by a slim pedicle, around which a strong ligature should be cast and securely tied. The ligatured portion is then cut off and the parts returned. The vessels connected with the growth enter it from above downward, parallel with the gut, and are therefore secure from injury, if ordinary caution be observed.

Injection.—The injection of carbolic acid and astringent agents, together with the application of caustics, is hardly entitled to the dignity of being considered an operation. Nor are the results, notwithstanding the claims of some to the contrary, on the whole better than by ligature, either with or without incision. The occasional severe inflammatory reaction, often followed by abscesses and gangrene, detract from that which might otherwise become an extremely satisfactory remedy. The full explanation of these methods can be found in systematic treatises upon the subject.

Varicocele.—This is caused by a varicose condition of the spermatic veins (Fig. 171). The treatment of the varicose veins of the cord,

like that for varicose veins in other situations, is divided into the *palliative* and *radical* methods, the object of the latter being to obliterate the lumen of the vessels. The same dangers appertain to operations upon these veins as upon those of other portions of the venous system. Erysipelas, phlebitis, pyæmia, to which may be added a consequent atrophy of the testicle depending upon the occlusion of the vein or artery, may follow; therefore, radical mea-

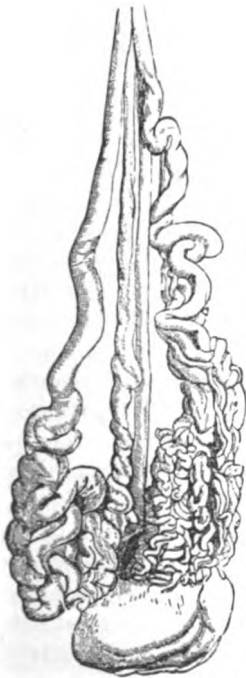


FIG. 171.—Varicose spermatic veins.



FIG. 172.—Morgan's suspensory.

asures directed to the vessels should not be entertained, except in old age, until the disease becomes a source of discomfort and even distress. The *palliative* treatment consists in shortening the cord by raising the scrotum and its contents, which lessens the weight of the column of blood contained in the vessels. This is achieved by the various forms of suspensories, as Morgan's (Fig. 172), or the one in ordinary use. Should these serve to relieve the urgent symptoms, the patient may not deem it desirable to submit to an operation of any kind. If, however, the characteristic symptoms recur or continue,

then the palliative operation for shortening the scrotum should be made.

Excision of the Scrotum.—The instruments required for this simple operation are the scrotal clamp—the one devised by Dr. Henry being in every way suitable (Fig. 173)—a sharp bistoury, needles

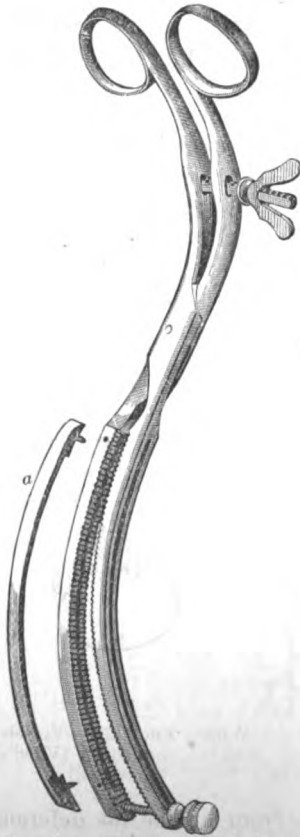


FIG. 173.—Henry's scrotal clamp.

armed with silver wire or carbolized silk, artery forceps, and catgut ligatures. The scrotum should be thoroughly cleansed and the patient anæsthetized; the clamp is then applied to the side afflicted by drawing the bottom of the scrotum between the blades, which should be applied as nearly as possible parallel with the raphé; all danger of including the testicle is obviated by pressing it upward to the external abdominal ring. When a sufficient amount of tissue is grasped to meet the indication, the blades are tightened to cut off all circulation, at the same time to securely hold the scrotal tissue; the protruding portion is then transfixed, on a level with the adjustable bar (Fig. 173, *a*), by a sharp, narrow-bladed bistoury, and cut off. Before the blades are loosened it is better to pass the sutures, which should be at least ten inches in length, through the divided borders. Having adjusted them, remove the clamp, tie the bleeding points, and close the wound. Care must always be taken to stop all bleeding points before the edges of the wound are united; else, owing to the looseness of the scrotal tissues, an ordinary oozing may cause the formation of large bloody clots, which must be removed. If

a drainage-tube be introduced throughout its course and allowed to protrude at its most dependent extremity, this danger will be further avoided. Place the patient in bed, elevate the scrotum, and dress the wound antiseptically. It usually heals quickly, and affords sufficient relief to amply recompense the patient for the annoyance incurred from the operation. If the instrument just described be not at hand, the operation should not be rejected for this reason. A clamp of practical utility may be extemporized from long-handled forceps, or by adjusting two narrow bars of metal or stiff wood, the latter can be firmly held by the hands of an assistant.

Radical Treatment for Varicocele.—The means employed to obliterate the dilated vessels are quite numerous. They all, however, accomplish the result by compression. Only such as are considered practically consistent with the safety of the patient are here described. In all the operations great care must be exercised to avoid the vas deferens and artery. They lie posteriorly to the enlarged and worm-like congeries of vessels, around which the compression is to be applied. If the patient be caused to lie down with the hips elevated, the blood will return from the varicose veins into the general circulation, after which the vas deferens and the artery can be easily isolated and separated from the veins. If the patient then assume an erect position the veins will again become distended, when, if pressure be maintained upon the cord at the external ring, the vessels can be distinctly outlined if the patient be again placed in the recumbent position. The operator having thus carefully located the vas deferens and the artery, the patient can be etherized and the operations proceeded with.

Compression by Pins (Fig. 174).—This consists simply of passing

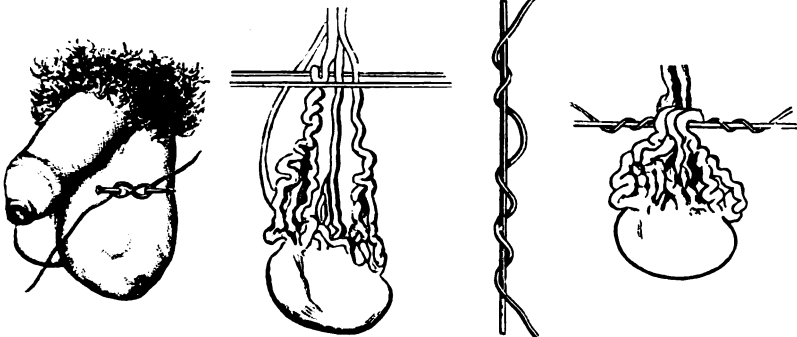


FIG. 174.—Occlusion by pins.

FIG. 175.—Wires in position. (Videl's operation.)

FIG. 176.—Wires twisted. (Videl's operation.)

FIG. 177.—Vessels occluded. (Videl's operation.)

a strong pin through the scrotal tissues in front of the vas deferens and the artery, and throwing around its protruding extremities an elastic ligature, or cotton yarn, drawn sufficiently tight to cut off the circulation. This procedure should be repeated at about one inch from the first application. The pins can be withdrawn at the end of three or four days.

Compression by Wires (Videl's).—This is done by passing a stout wire in front of or behind the veins, preferably the latter, then passing a smaller one at the opposite side, but through the integument (Fig. 175). They are then twisted together (Fig. 176) and the veins are thoroughly compressed and rolled around them (Fig. 177).

Ligaturing.—This is accomplished by carrying a

needle armed with a silver wire between the veins and the remaining vessels of the cord, returning it at the point of entrance, going in front of the veins. The wire is then twisted firmly. A strong silk

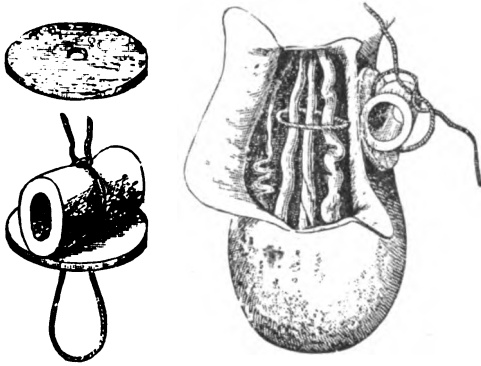


FIG. 178.—Elastic traction.

ligature can be applied in a similar manner. The amount of tissue in their grasp renders the separation somewhat tedious. The process of separation can be hastened by tying the ligature over a small cylinder of elastic tubing (Levis), the resistancy of which will exercise a constant traction (Fig. 178). If this be done, a button should be introduced between

the tissues and tubing to protect the skin (Pancoast).

Strong catgut ligatures, or antiseptic silk, can be carried around the dilated veins, an inch or so apart, by means of an ordinary needle—or by an instrument especially devised for the purpose—and caused to emerge at the point of entrance, tied, ends cut short, and permitted to remain until they are absorbed. The veins may be divided subcutaneously between the ligatures after they have been tied.

The expedient advised by Prof. E. L. Keyes for passing the ligatures is not only ingenious but also simple. A needle with a fixed handle, having two eyes at its point (Fig. 179), is armed with two antiseptic ligatures—one carried through each eye. The ends of the




FIG. 179.—Keyes' needle.

posterior ligature are tied to form a loop; the anterior ligature is permitted to hang loosely, with an equal portion at each side of the needle. The enlarged veins are isolated, and the point of the needle is pushed through the scrotal tissues in close contact with posterior surfaces. One end of the untied ligature is then passed through the tissues with forceps, and caused to remain in this position, while the needle is withdrawn sufficiently to permit its point to be carried in front of the distended veins, out through the scrotal point of exit, when the distal end of the untied ligature is passed through the advanced portion of the looped one and drawn by it through the point of entrance to the scrotal tissues by the

complete withdrawal of the needle. The deposited ligature is then freed from the scrotal tissues by making one or two sharp pulls upon it, tied firmly around the veins, its extremities cut short and allowed to disappear within the scrotum. If thorough antiseptic precautions be observed, the ligatures will rarely cause subsequent local trouble.

The Double-Loop Compression of Ricord (Fig. 180).—This is an excellent plan, and can be readily executed by passing a needle armed with a silk ligature between the veins and the *vas deferens*; to this is fastened a double ligature, which is drawn through and left in position. The needle with its silk ligature is then passed in front of the veins in the opposite direction, entering and emerging at the points previously made. A second double ligature is then drawn through and left in position. The extremities on the respective sides are now tucked through the loops on the same side and drawn tight, and tied over a narrow roller or piece of elastic tubing. The ligatures will cut their way through in five or six days. The methods of cure by



FIG. 180.—Ricord's loops.

exposure, division, and excision of the vessels are more dangerous, and have infrequently resulted in death from pyæmia.

Venesection.—While the withdrawing of blood from a vein can hardly be classed as an operation of much moment in a surgical sense, yet the infrequency of its employment at the present time is quite apt to render the details connected therewith somewhat uncertain in the minds of a majority of the practitioners of the present generation. The veins selected for the procedure are the internal saphenous at the ankle,

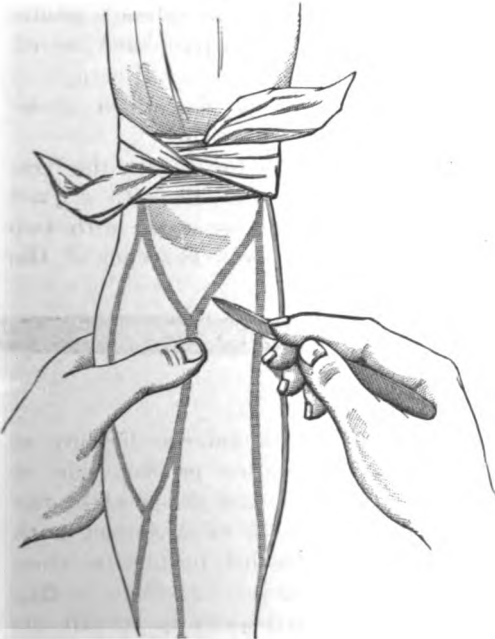


FIG. 181.—Opening the vein with scalpel.

the **median basilic**, or **median cephalic** at the bend of the elbow, and **external jugular** in the neck. The instruments required are the or-

dinary thumb-lancet, or a curved or straight sharp-pointed bistoury ; the first, however, possesses the greater number of traditional virtues. Should the lancet be not at hand, either of the others can be used as satisfactory substitutes. If the region of the elbow be selected, the median cephalic vein is preferred on account of its greater distance from the brachial artery. The arm should be constricted by a bandage drawn sufficiently tight to obstruct venous return, without interfering with arterial circulation : this will cause the veins to become prominently distended, unless the patient be very fleshy. The veins should be well defined by the finger, and held in position by the thumb or finger placed just below the point for incision, which is made obliquely to the transverse diameter, and of sufficient depth to freely open the vessel without severing it (Fig. 181). The flow may be increased by causing the patient to firmly grasp a stick or broom-handle ; it may be impeded by the interposition of the subcutaneous fat, which should be pushed aside. The amount drawn will be governed by the strength of the patient, as well as his position. If standing or sitting, its effects will be felt sooner than if in a recumbent posture. Usually, however, from half a pint to a pint will suffice. The flow is arrested by removing the bandage above and applying the finger to the bleeding point, after which a small compress is placed over the incision, and confined in position by adhesive plaster, so arranged as not to impede the venous return.

These directions will apply with equal force to venesection in all situations other than the external jugular. If this vein be selected, the compress is placed just above the clavicle, and confined in position by a bandage carried under the opposite axilla. The finger is then placed above the point of proposed incision, and the vessel opened at a right angle with the fibers of the platysma myoides muscle. The finger must always be placed on the opening before the compress is removed, in order to prevent the entrance of air into the circulation.

Transfusion.—This is a means sometimes employed to overcome the exhaustion produced by disease or the loss of blood, the latter being the only condition to which it can, thus far, be said to be practically adapted. It consists in conveying the blood from one person to another, either directly, or by collecting it in a suitable receptacle, removing the fibrin, and introducing the remaining plasma and corpuscles. The dangers to be avoided are, the introduction of air, blood-clots, and too great a quantity of blood into the patient's veins, which might overpower an already weakened heart. From six to eight ounces are usually sufficient, and should be thrown in slowly and carefully, watching the effects upon the circulation, respiration, and sensorium of the patient. If its introduction cause a depression of the pulse, or give rise to nervous tremors, or difficulty in breathing, it should cease at once. The blood to be transfused should be taken

from a person of strong physique, and free from any constitutional taint.

Direct Transfusion from Arm to Arm.—The requirements for this are an apparatus for the transmission of the blood, together with a pair of forceps and a scalpel to open the vessels, and a basin of water or saline solution, at a temperature of about 100° F., into which the apparatus should be laid to impart to it the requisite degree of warmth, and to exclude the air. The arm of the donor and receiver are constricted above the point for incision, as in

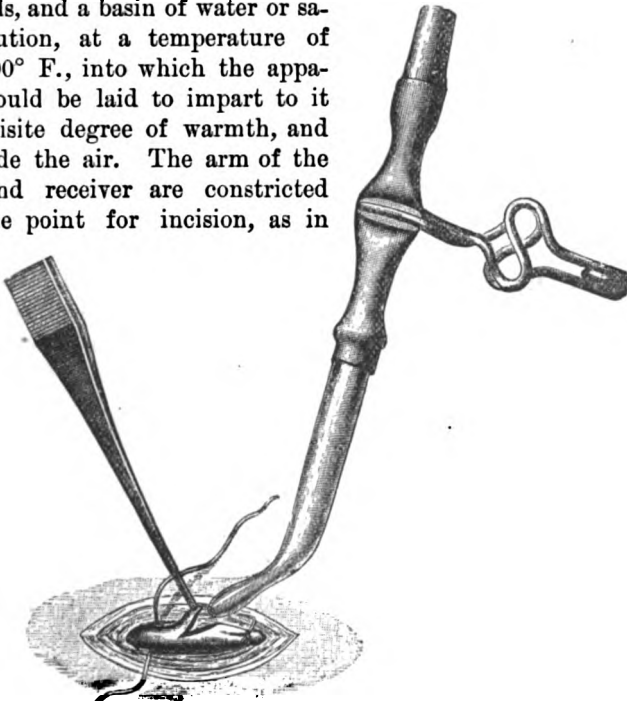


FIG. 182.—Introducing the tube in transfusion.

phlebotomy; the skin covering the distended vessels is pinched up, transfixed, and cut through, leaving the veins exposed at the bottom of the wounds; they are then seized with a pair of forceps, and a V-shaped opening made with the scissors for the purpose of introducing the tube (Fig. 182). The tube A (Fig. 183) is then taken from the bottom of the basin, and, with the thumb applied to its larger extremity to keep it filled, it is inserted into the opening in the vein of the receiver; the tube B is inserted in like manner into the vein of the donor, after which the propelling power—the apparatus—likewise filled with fluid and kept so by turning the stop-cocks, is attached to the two tubes; the cocks are now opened, and the fluid contained in the instrument is thrown into the circulation by squeezing the bulb C, while the tube D' is compressed. After the bulb C is emptied, and before it is permitted to expand, the compression should be changed from D' to D. If the bulb be now allowed to expand, it will become filled with the

blood of the donor, which can be injected into the circulation as in the preceding instance. The bulb should be allowed to fill slowly,

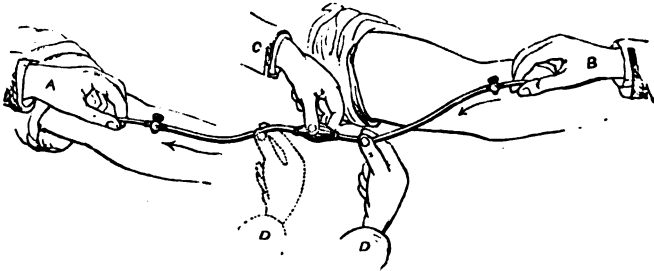


FIG. 183.—Direct transfusion.

and the amount introduced is estimated by counting the number of times it is emptied. After the operation is completed, the incisions are treated the same as in phlebotomy. The instrument devised by Fryer (Fig. 184) differs from the former in being cast whole, with an

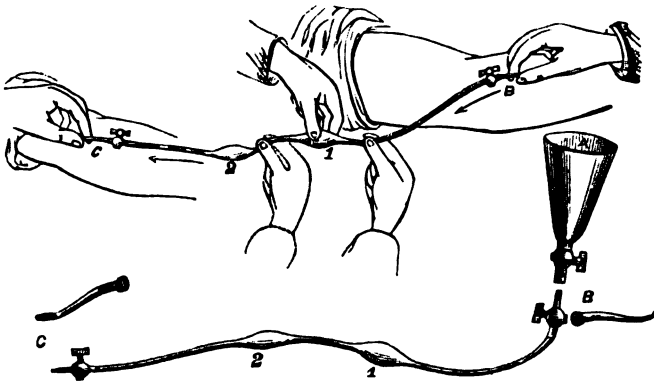


FIG. 184.—Fryer's transfusion apparatus.

additional bulb, which does away with the metallic couplings, and presents a continuously smooth surface to the blood current; and, moreover, the additional bulb saves time by producing an almost continuous current. It will be seen that a funnel is added to this instrument which allows it to be employed in mediate transfusion.

Mediate transfusion is collecting the blood from the arm of the donor and injecting it into the circulation, either with or without the removal of the fibrin. For this purpose the instrument devised by Collins (Fig. 185) can be especially recommended. It consists of a pump attached to a funnel in such a manner as to carry the blood easily and without danger of coagulation or the introduction of air.

It can be used equally well with the defibrinated or with the un-whipped blood; with the latter it is particularly convenient, since the blood can be caught in the funnel and injected while flowing from the donor, which saves time, and avoids the blood-changes induced by exposure. In

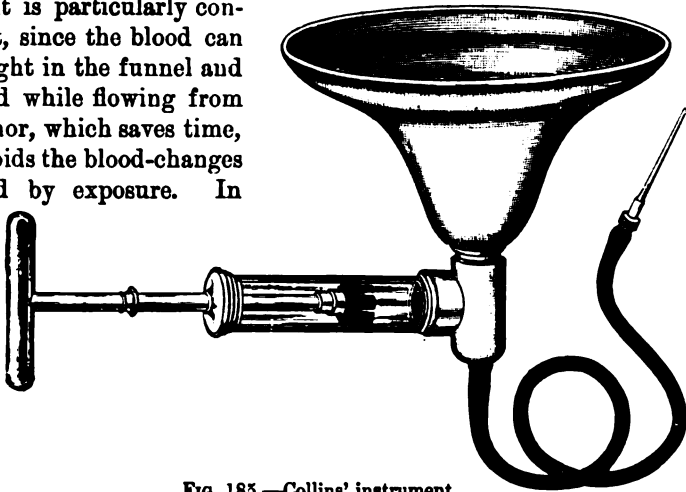


FIG. 185.—Collins' instrument.

the use of this, and all other implements brought in contact with the blood, the temperature of the instrument, and of the blood injected, should be kept at about 100° F. by means of warm water, or a warm saline solution.*

If defibrinated blood be employed, it should be prepared by agitation (Fig. 186), after being collected in a vessel of the temperature stated, then strained into the funnel of the instrument and pumped into the system.

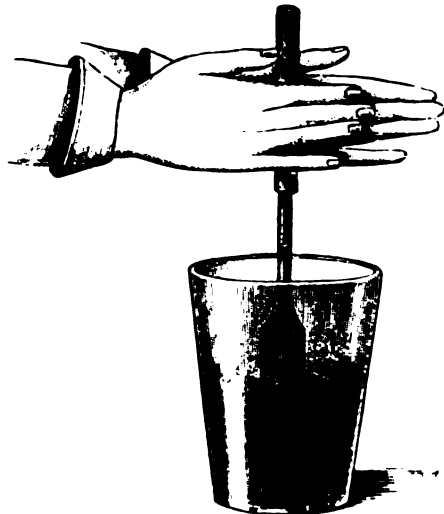

FIG. 186.—Removing fibrin.

The introduction into the funnel, or into the bulbs, of two or three ounces of a saline solution, or of a carbonate of ammonia solution, four to six grains to the

- * R Chloride of sodium..... 3 j.
- Chloride of potassium..... gr. vj.
- Phosphate of soda..... gr. iij.
- Carbonate of soda..... 3 j.
- Aquæ..... ʒ xx.

M.—Heat to 100° F.

ounce, prevents the entrance of air into the instrument, and also has a stimulating effect upon the patient.




FIG. 187.—Bull's apparatus for injection of saline solutions.

Injection of Saline Solutions.—The introduction into the veins, and the arteries, of various solutions, the chief ingredients of which are common salt and carbonate of soda, is highly recommended. The following is the formula of Schwartz : Distilled water, 32 ounces ; common salt, $1\frac{1}{2}$ drachm ; officinal solution of soda, 2 drops, raised to 100 or 104° F.

Szumann recommended the following : Water, 32 ounces ; common salt, $1\frac{1}{2}$ drachm ; carbonate of soda, 15 grains. The saline solution on page 129 is suitable for this purpose. The amount of fluid to be injected will depend on the condition of the patient, also upon its effect. It is seldom that less than eight ounces are used, frequently eighteen or twenty, and even more may be advisable. The introduction of the fluid should be made slowly, occupying fifteen or twenty minutes, by means of the apparatus already figured, or by an extemporized siphon. If an aspirating needle a sixteenth of an inch in diameter be attached to a small rubber tube, connected with a receptacle containing the solution, and raised three or four feet above the patient, no trouble will be experienced in carrying the fluid into the general circulation. The vein is exposed, distended, and punctured under complete antiseptic precautions, if possible. The apparatus devised by Dr. W. T. Bull, of this city, for this purpose, is admirable, owing to its simplicity, and being accompanied by the saline ingredients necessary to charge the instrument (Fig. 187). These fluids seem to meet the indications quite as well as blood, are easily obtained, and

do not expose the patient to the dangers attendant on the use of the latter.

Intra-venous injection of milk has been done to counteract the conditions similar to those calling for the use of blood. The milk should be freshly drawn from the cow and covered with a fine gauze, through which it is strained into a transfusion instrument, which can be extemporized by joining a glass funnel to one end of a rubber tube, and to the other a small conducting canula.

If the canula be introduced into the vein, and the funnel be raised after having been filled with six or eight ounces of milk, the force of gravity will become the propelling agent.

Arterial transfusion has been advocated on the basis that it conveys the blood more equably to the heart, with less danger of exciting undue disturbance of the circulation.

The admission of a small amount of air does no harm, and the danger of phlebitis is avoided. The vessel selected should be the radial at the wrist, or the posterior tibial at the ankle, either one of which is exposed, and three ligatures are placed around it; the distal one is ligatured and the proximal one tightened sufficiently to interrupt the circulation in the vessel. The vessel is now opened and the tube inserted and tied in position by the third or middle ligature, then the proximal one is loosened and the fluid injected into the circulation. It is better to inject the fluid against than with the natural flow of the blood current, to avoid over-distention of the capillaries. As soon as the injection of the fluid is completed the proximal one is tied, and the intervening portion of the vessel removed with the tube. The vein may be tied in venous transfusion with two ligatures in the following manner: Tie the distal one, open the vein, introduce the tube, then tie the proximal one, including the tube; this will prevent all loss of blood.

Operations on the Capillaries.—This system of vessels, like the venous, may undergo dilatation of sufficient size to create distinct but slowly developing and painless deformities, or tumors. The morbid

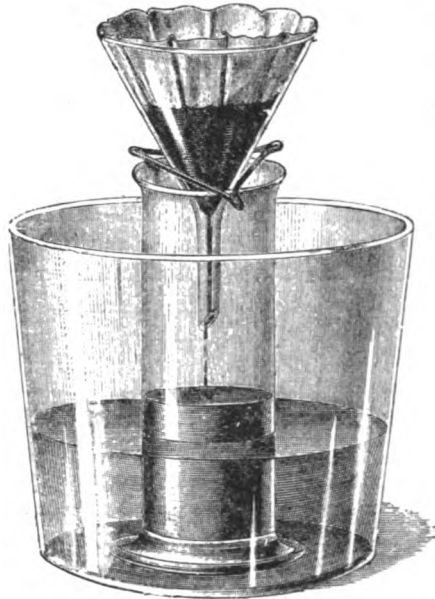


FIG. 188.—Straining the blood.

process may be, and usually is, limited entirely to the capillaries of the integument; however, the larger vessels are not infrequently involved, in the beginning, or during their development; they likewise vary in size, shape, and color. The simplest form is known as the "Mother's mark," "Birth-mark," etc.

A birth-mark can be treated by pressure, caustic, hot needles, vaccination, etc., depending upon its size and situation. It is not well to interfere with it at all except by simple means, unless it increases rapidly in size. The majority of these growths will disappear of themselves before their presence becomes a source of annoyance or regret to the possessor. There are, however, several simple means which will often hasten their departure—the use of simple compresses, repeated application of collodion, or vaccination, if the birth-mark be located suitably therefor. The following method, introduced by Dr. Squire some time since, which bade fair at one time to meet the desired end, can be employed:

The "mark" is frozen with an ether spray, and numerous parallel incisions are made about one sixteenth of an inch apart and extending the same depth, and the whole covered with blotting-paper, held upon it with sufficient force to prevent any gaping of the cuts and escape of blood; after fifteen or twenty minutes the paper is thoroughly wet with water and removed. Sometimes a thin underlying clot of blood will be found; this must be carefully washed away with water and a soft brush. It is sometimes necessary to repeat the operation, when the incisions should be made at right angles to the previous incisions. If proper care be taken, in suitable cases a perfect cure is secured without any scarring. The injection of ergot, liquor ferri subsulphatis, or various other astringents, has been recommended. They are, however, uncertain in their action, and are liable to be followed by inflammation, ulceration, and sometimes by embolism. The solutions can be injected by aid of the ordinary hypodermic syringe, three or four drops at a time, in various portions of the growth, or, red-hot needles can be introduced at different points. The application of red heat around the base and over the surface of the growth by means of the Paquelin cautery is an admirable method, provided it involves the skin alone or only the capillaries in the tissue immediately beneath it. It is usually followed by more or less disfigurement, depending upon the extent of the cauterization.

Subcutaneous Ligaturing.—If the nævus be of large size, persistent, of a dark color, and markedly elevated, it is suitable for this measure, which is done in several ways, depending upon the size and shape of the tumor, and fancy of the operator.

Fig. 189 represents a simple method. In it the needle, armed with a strong, well-carbolized hemp or silk ligature, is thrust through the integument at its base, carried as far as possible around the base,

and passed out, to be again introduced at the point of exit, and carried still farther around, and pushed through as before, and so on until it is caused to emerge at the first point of insertion ; the ends are then tied in a firm, hard knot.

In Fig. 190 a double ligature is carried through the base and

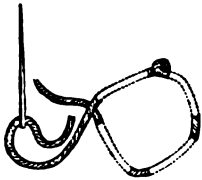


FIG. 189.—By a single ligature.

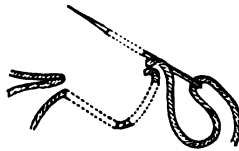


FIG. 190.—By a double ligature.



FIG. 191.—Ligation in quarter sections.

divided ; each portion is then carried around its half of the base as before, and tied. This is applicable to those having a larger base. Fig. 191 represents the application of the ligature to quarter-sections of the base. It is employed when the growth is large. Pass a double ligature through the center of the base, cut the loop near to its center, leaving one end of the divided thread in the eye of the needle ; then, after threading the needle with the other end of the portion of the ligature which was liberated by the division of the loop (Fig. 192), pass the needle through the base at right angles to its primary course. The ends are then to be firmly tied after the integument has been incised, to allow the ligature to sink deeply into the base, as well as to avoid the pain and ulceration incident to the constriction of the in-

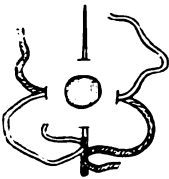


FIG. 192.—Quarter sections, second step.

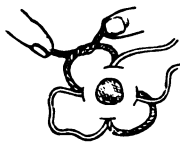


FIG. 193.—Tying ligature.

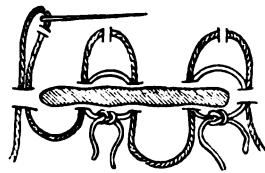


FIG. 194.—Ligation of elongated base.

tegument (Fig. 193). It will simplify the selection and uniting of the proper extremities if one half the ligature be colored before its primary introduction. Fig. 194 represents the ligation of a growth with an elongated base. In this the double ligature is required, and should be colored as suggested above ; pass it through the base from side to side, commencing and terminating just outside of the extreme limits of the growth ; if the white loops be now divided on one side and the black on the other, independent sets of ligatures will be had, which should be tied ; the skin coming within the grasp of each ligature is incised

as in the preceding instance. The separation of the growth is hastened by the use of an elastic or rubber ligature, applied in a similar manner.

Division and Ligation.—Cirsoid growths of the scalp can be successfully treated by making a free incision nearly around and outside of them, down to the periosteum, leaving that portion of the growth that contains the largest vessel undisturbed to form a pedicle to nourish the flap. The flap is raised and all bleeding points are tied, after which it is kept separated from its former bed by antiseptic gauze until the new surfaces granulate. The granulating surfaces are then placed in contact, and soon unite, thereby destroying the growth without loss of substance. If the pulsations in the flap continue for four or five days, the dilated vessel entering it should be tied at a distance from the pedicle. The hemorrhage is, to a degree, controlled during the primary operation by passing a strong rubber band around the head, beneath which compresses are placed corresponding in situation to the course of the vessels that supply the scalp. The bleeding points can also be closed by direct pressure against the underlying bone; yet, notwithstanding these means, the loss of blood may be quite severe, and the operation should not be attempted if the patient be already exsanguinated or otherwise debilitated. Care should be taken to form a pedicle of sufficient width to nourish the flap; from half an inch to an inch, depending on the size of the flap, has, in my experience, been ample for the purpose. If the dressing be applied too firmly, the integrity of the flap will be endangered.

CHAPTER VI.

OPERATIONS ON THE NERVOUS SYSTEM.

THE brain, spinal cord, and the nerves arising from the cerebrospinal axis, owing to the various morbid processes and injuries to which they, together with their coverings, are subjected, are often the seat of common and yet important surgical procedures.

Hydrocephalus.—Tapping for the removal of the superfluous fluid is the only practical surgical procedure to which this condition is amenable. This may be done with a small aspirating trocar, or, what is better, with an aspirator. In either instance the puncturing agent is introduced through the anterior fontanelle, close to its outer border, and passed perpendicularly into the fluid accumulation, cautiously avoiding the brain substance as far as possible. The fluid must be slowly

withdrawn, accompanied by moderate and equable pressure upon the external surface by means of a skull-cap bandage. Whenever any manifestations referable to the circulatory or nervous centers appear, the needle should be withdrawn and the puncture carefully closed with a catgut suture and dressed antiseptically. Often the removal of less than three or four ounces will cause feebleness of the pulse, contraction of the pupil, and evidences of approaching convulsion. After the withdrawal of the fluid, gentle and uniform pressure should be maintained by aid of bandages, adhesive plaster, or a tightly-fitting perforated rubber cap. Care is necessary, else the combined pressure of the reaccumulating fluid and external dressing will cause alarming symptoms.

Meningocele is a protrusion of the meninges of the brain, caused often by an accumulation of the hydrocephalic fluid within the cranium, and must of necessity occur before the closure of the fontanelles. It may be present at any point of separation between the cranial bones, although it occurs more frequently at the posterior fontanelle than elsewhere. As a rule, little can be done, other than to protect the tumor from external irritation. If it have a well-defined pedicle, this can be clamped and the fluid withdrawn, either by incision or with a small trocar. The clamp must be applied with caution, else the pressure caused by it may produce convulsions or other nervous phenomena. If it be determined to puncture it, a small amount of fluid may be withdrawn, when the clamp can be the more readily adjusted. As long as the pedicle is open, any operative interference is liable to be followed by death from a resulting meningitis. If the pedicle be occluded, the sac may be incised and the tumor removed. In all instances where it is removed, sufficient integument should be left to insure a complete and proper closure of the divided surfaces.

Hydro-rachis.—This is a congenital defect, comprising a cleft in the laminae of the vertebrae, and a protrusion of the membranes of the spinal cord. It occurs most frequently in the lumbar region, although it is found in the other portions of the spinal column. Various operative expedients have been employed to cure the defect, nearly all of which have, at one time or another, resulted in occasional cures.

The two methods which have secured the best results are : 1. Repeated punctures with a small needle at various points through the sides of the sack, followed by gentle and uniform pressure over the surface. 2. Consists of injecting into the sack, after having been partially emptied of its fluid, one or two drachms of the iodo-glycerin solution, which is made by dissolving ten grains of iodine and thirty grains of iodide of potassium in one ounce of glycerin. Exercise caution that none of the fluid escapes after the operation. This must be

repeated from time to time, always allowing the irritation due to the previous operation to subside before it is again repeated.

Results.—The latter method has been very successful. Of forty-four cases treated, thirty-five were cured.

Trephining the Cranium is an operation which is, without doubt, performed more frequently than the requirements of many of the cases




FIG. 195.—
Crown tre-
phine.

FIG. 196.—
Handle of
trephine.

FIG. 197.—Galt's
trephine.

FIG. 198.—
Elevator.

FIG. 199.—
Elevator.

FIG. 200.
—Eleva-
tor.

warrant. In every instance, before attempting it, the indications should be most carefully studied.

The special instruments required for the operation are the trephine (Figs. 195, 196, 197), the conical, or Galt's, being by far the safer; an elevator (Figs. 198, 199, 200) and rongeur (Fig. 201), sequestrum for-



FIG. 201.—Rongeur.

ceps (Figs. 202 and 203), gouges and mallets (Figs. 204, 205, 206, 207, 208). The traditional toothpick, and the brush, to remove the dust from the track of the trephine, while not

absolutely necessary, have, nevertheless (especially the former), become so closely associated with the operation as to be entitled to a most respectful consideration. The patient is prepared by shaving the head

for a considerable distance around the seat of the proposed operation.

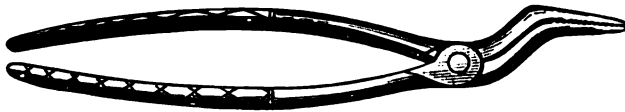

FIG. 202.—Van Buren's sequestrum forceps.

If unconscious, an anæsthetic is unnecessary. Strict antiseptic precautions should be enjoined.

Operation.—Make an incision of an oval shape through the scalp




FIG. 203.—Ferguson's sequestrum forceps.

down to the bone, expose the portion of the cranium be perforated upon, and at the same time avoid large vessels and secure good drainage when possible. Lay back the integumentary flap, together with the




FIG. 204.—
Straight
gouge.

FIG. 205.—
Curved
gouge.

FIG. 206.—Szy-
manowsky's
gouge.

FIG. 207.—Hoffman's
gouge forceps.

FIG. 208.—Lead
mallet.

periosteum covering the portion of bone to be removed. Lower the center-pin a little below the teeth of the trephine, and fasten it firmly in position by means of its adjusting screw; place the point of the center-pin as nearly as practicable upon that portion of the solid and undeformed bone which, when removed, will allow the best opportunity of elevating that which is depressed, provided, however, that it be not placed, when avoidable, over the course of the middle meningeal artery, or a large sinus (Fig. 209). The trunk of the

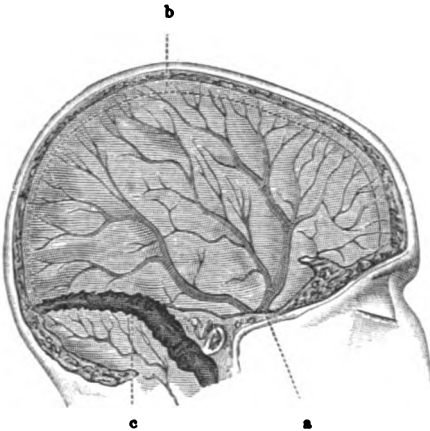


FIG. 209.—Course of arteries and sinuses.

middle meningeal artery (Fig. 209, *a*) is located an inch and a half behind the external angular process of the frontal bone, and the same distance above the zygoma. The median line of the skull, from the root of the nose to the occipital protuberance, corresponds to the superior longitudinal sinus (Fig. 209, *b*). The course of the lateral sinus (Fig. 209, *c*) is indicated by a line drawn from the occipital protuberance to the anterior border of the mastoid process. Bear firmly upon the instrument, at the same time turn it quickly from right to left, till a suitable track is established to retain it in position (Fig. 210). The center-pin is then withdrawn and fastened back in place, otherwise it may perforate the membranes.

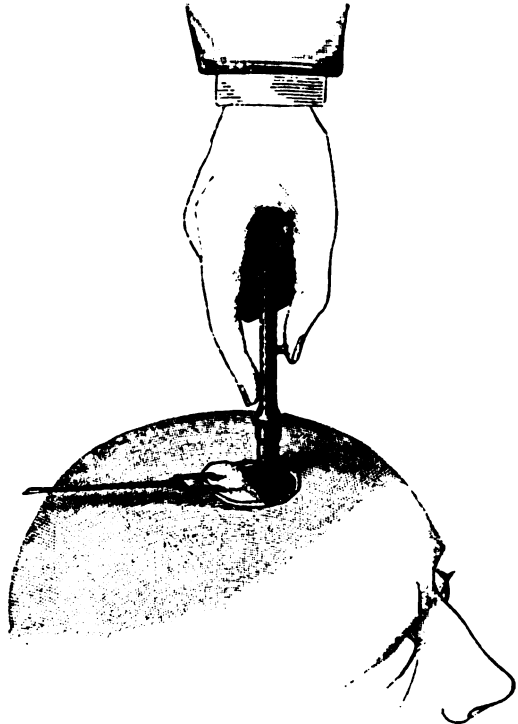


FIG. 210.—Applying the cylindrical trephine.

The instrument must be held perpendicularly to the point of section, and the pressure evenly distributed ; if not, one side of the circle will be penetrated more quickly than the other, thereby jeopardizing the integrity of the membranes. During the process the trephine must be frequently raised from the track, that it may be cleared of bone-dust, the color of which should be carefully noticed ; at first it is of a pale white, but as soon as the diploë is reached it becomes reddened ; from this time on the tooth-pick must be frequently used to clear out the track as well as to detect the first point of complete section. But little pressure is now allowable, since to use it might force the crown of the instrument through the membranes and into the brain structure itself, especially if the trephine be of a horizontal pattern. Galt's, or the conical trephine (Fig. 197), is far safer than the crown pattern, since, as soon as the inner table is divided, it is converted into a screw and becomes immovably fixed in the opening. If the button of bone be percussed with the handle of a scalpel or forceps, it will emit a low-pitched sound, and vibrate when a considerable portion of the circle is cut through ; moreover, it can, probably, be raised from its bed at this time by the aid of the elevator. As soon as the button is removed, the elevator is inserted beneath the depressed portion, and it is raised to its proper level.

This is sometimes difficult to accomplish, owing to the dovetailing of the fragments. The solid bone is used as a fulcrum when much force is necessary. If great force be employed, and a fragment be suddenly loosened, its distal, sharp, or jagged border may cut through the membranes ; it is therefore necessary that force be used in a guarded manner.

All detached fragments are removed ; those that will retain their position when elevated, owing to continuity of structure, may be allowed to remain. All projecting points of bone must be cut away with the rongeur, else the pulsation of the brain may cause them to perforate the dura mater. Clots of blood and pus are likewise to be cleared out by a stream of antiseptic fluid. If the compressing agents be below the dura mater, it may be opened sufficiently to admit of their escape ; before this is done, however, their presence should be clearly established. If the dura mater be lacerated, it may be closed by fine catgut sutures, especially when the opening is large enough to predispose the formation of hernia cerebri. If the middle meningeal branches be divided or a sinus opened, the hemorrhage is controlled by antiseptic compresses, so applied as not to exert undue pressure on the brain. If the membranes be lacerated, the fragments of bone removed must be fitted to each other, in order that the absence of any osseous portion may be ascertained and it be sought after. The opening in the skull made by the trephine can be enlarged more rapidly and safely by the rongeur (Fig. 201) than by repeated applications of the trephine.

The wound should now be thoroughly cleansed with carbolic acid, the flaps adjusted, suitable drainage established, and the antiseptic dressing applied. It is often possible to elevate the fragments without the use of the trephine, an expedient that should always be tried, if a reasonable prospect of success be apparent.

Results.—The nature of the cause calling for the operation, the length of time intervening prior to its performance, and the ability to secure complete drainage and asepsis, are the chief factors that modify the prognosis. A death-rate of from four to fifteen per cent. is a fair estimate in civil practice.

The advance which is being made in cerebral localization is worthy of the closest scrutiny of the operating surgeon. Not only should he operate on the skull in the accepted sense of the term, but he should also note the exact seat of the lesion calling for his action. The variations in the symptoms, before and after the procedure, should likewise be carefully scrutinized. The precise seat of an operation can be determined by measurements made from established points, as from the external auditory meatus, the external angular process of the

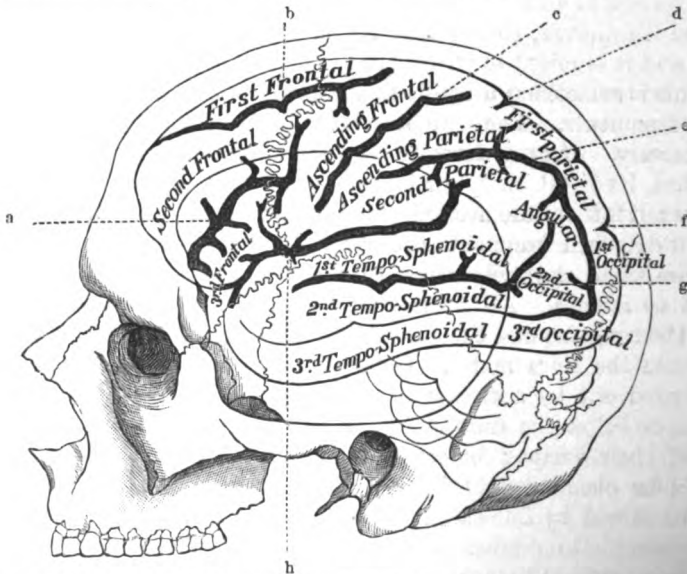


FIG. 211.—Relation of chief fissures and convolutions to external surface of skull. *a.* Inferior frontal fissure. *b.* Superior frontal fissure. *c.* Fissure of Rolando. *d.* Callosomarginal fissure. *e.* Inter-parietal fissure. *f.* Parieto-occipital fissure. *g.* Parallel fissure. *h.* Fissure of Sylvius.

frontal bone, various sutures, etc. Fig. 211 shows the relations borne by important convolutions and fissures of the cerebrum to the sutures, and to other external points on the skull. Fig. 212, showing the exterior of the skull, is of especial importance when studied

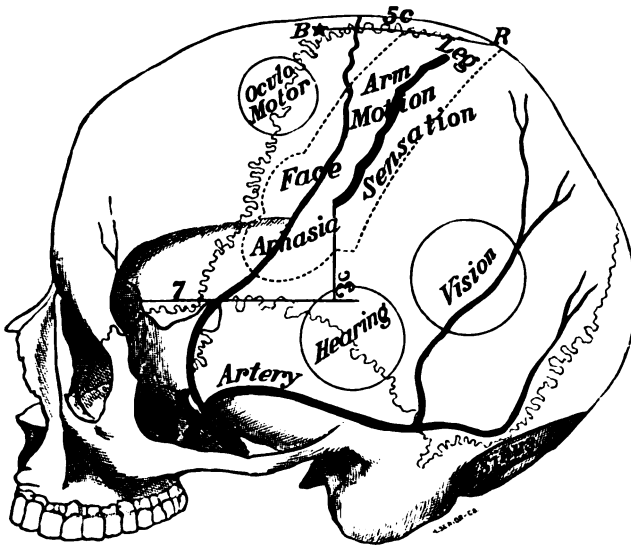


FIG. 212.—Location of fissure of Rolando (R) and the special areas.

in connection with the preceding figure; upon it are indicated the measurements necessary to properly locate the underlying convolutions with which definite functions have been found to be associated.

Operations on the Nerves of the Cranium.—It may become necessary, owing to neuralgia, spasm, tremor, etc., after all ordinary means have failed, to operate upon the trunk of the nerve involved, either by division, excision, or stretching. The first method can afford but temporary relief, since the divided extremities will speedily unite.

If *excision* be done, not less than two inches, if possible, should be removed from the continuity of the trunk; otherwise, at a greater or lesser period, the extremities will become united. If the nerve be a small one, the tendency to union is less, but the rule to remove a long piece must not be deviated from. *Stretching* consists in cutting down on the affected nerve, seizing it with the fingers, and making firm and steady traction for from half a minute to a minute. It is applied more properly to the large nerves, and those which can not be divided without the sacrifice of important functions.

Supra-Orbital Nerve.—This may be divided or excised at its exit from the supra-orbital foramen or notch at the junction of the inner and middle thirds of the supra-orbital arch. It is covered by integument, fascia, and the combined fibers of the orbicularis oculi, occipitofrontalis, and corrugator supercillii muscles.

To divide it, locate the notch by the fingers of the left hand when

pass the point of a narrow bistoury beneath the integument, from its inner to its outer side ; turn the edge backward, and cut firmly down and across the opening upon its inferior wall.

Excision and Stretching.—The nerve can be found by elevating the brow and making an incision between it and the lid, one inch in length, through the tissues down upon the site of the nerve ; the connective tissue is then displaced by a director and its branches are sought for, and excised or stretched, as seems better. The nerve may be pulled out with a small blunt hook from the roof of the orbit, and excised before it enters the foramen ; or it may be stretched and allowed to remain.

The Infra-Orbital Nerves are the terminal branches of the supra-maxillary division of the fifth pair ; they escape from the infra-orbital foramen.

The infra-orbital foramen is about four lines below the lower edge of the orbit, and nearly on a line extending from the bicuspid teeth to the supra-orbital foramen. The nerve may be divided through the mouth by first recognizing the location of the foramen, and placing the finger upon it ; then make a narrow incision, beginning at the fold of the cheek and maxilla, carrying it upward in the line before indicated, till within a short distance of the foramen, when with a sharp-pointed pair of scissors the nerves are divided as they emerge. They may also be divided through an external incision made directly down upon the foramen.

In the latter the incision should be crescentic with the concavity upward, and be located about one-half inch below the lower border of the orbit ; the muscles and cellulo-adipose tissue are displaced, nerves isolated from the vessels and divided. The nerves may be divided subcutaneously at this situation by a slender-bladed knife passed in the line of their emergence, and its edge directed toward the inferior wall of the canal.

The Superior Maxillary Nerve.—This may be excised, divided, or stretched in its course along the floor of the orbit, or at its exit from the foramen rotundum. It may be reached on the floor by passing a tenotome about an inch backward in the line of its course, turning the edge downward, and cutting upon and through the thin floor of the orbit. Its termination at the infra-orbital foramen can then be exposed, and the severed portion pulled out (Langenbeck). Through a narrow incision of the soft parts, in this situation, a blunt hook can be introduced, the nerve caught up and stretched. The whole of the nerve can be removed from the canal, and sometimes farther posteriorly, if an incision is made about an inch and a half in length along the lower border of the orbit, the tissues elevated and the nerve isolated. It may be raised on a hook and divided ; or by pulling it out in section, either by a ligature previously applied, or

with a pair of forceps. If the more formidable operation of its division, as it escapes from the foramen rotundum, be attempted, the initiatory incision through the soft parts should be of a shape and extent to best expose the site of the proposed operation; the V, +, U, T shaped ones are selected, according to the wish of the operator. In either instance its central portion should correspond as nearly as possible to the infra-orbital foramen. After the flap is raised, the crown of a large trephine or drill is applied to the bone so as to open into the antrum along the course of the nerve, which is carefully followed backward to the sphenomaxillary fossa by cutting away the floor of the canal with a sharp, delicate chisel. It is then carefully isolated from the tissues in the fossa back to the foramen of exit, and divided with a pair of curved scissors (Carnochan). The internal maxillary artery runs through the fossa, and should be carefully avoided. If it be cut, it should be ligatured if possible; not infrequently firm pressure will check the hemorrhage; when other means fail, ligaturing of the external carotid will become necessary.

The posterior wall of the antrum is quite vascular, and, when broken, or cut through by the small trephine, it often bleeds vigorously. There seems to be good ground for the belief that quite as good results follow an excision made anterior to Meckel's ganglion as behind it. In either instance the operation ought not to be attempted unless a strong light can be thrown upon the field of action.

The second and third branches of the fifth pair can be exposed at their exit from the skull by the ingenious method of Prof. Pancoast.

Operation.—Make an incision the entire width of the perpendicular ramus of the lower jaw near where it joins the body; connect to its extremities two parallel incisions carried upward to the zygoma and malar bone, carefully exposing Steno's duct (Fig.



FIG. 213.—Pancoast's lines of incision.

this flap down to the bone, its upper border remaining at the zygoma. The coronoid process is now sawn off, detached, and removed. The temporal muscle beneath the zygoma. The fatty matter now exposed is

removed, and the internal maxillary artery within it is ligatured. The upper head of the external pterygoid is detached from the greater wing of the sphenoid bone by the finger, and all hemorrhage checked, when the nerves within the zygomatic fossa are readily seen, and can be easily excised.

If it be desired to expose the second branch as it crosses the sphenomaxillary fossa, extend the incisions upward and seek the sphenomaxillary fissure at the anterior lacerated foramen. The nerve should now be carefully isolated and a strong ligature passed around it. This last step is often attended with difficulty, especially when the fissures leading to it are narrow. If more room be necessary, the posterior wall of the antrum can be crushed in.

The Inferior Dental Nerve.—This nerve may be *divided, excised, or stretched*, before it enters the jaw, in its course through it, and at its exit from the mental foramen. In the first situation an incision is made about an inch and a half in length along the anterior border of the vertical ramus of the jaw, within the mouth down to the anterior fibers of the internal pterygoid muscle; the connective tissue between this muscle and the inner surface of the ramus is now pushed aside, and the nerve detected as it enters the canal. The small spine surmounting the opening for the entrance of the vessel and nerve can be quite readily located, and will be a valuable guide to the nerve as it enters the dental canal. It can now be isolated, hooked up, and divided. About an inch and a half can be easily excised in this situation, if after its isolation a strong ligature be thrown around it and tied. It is then divided by curved scissors as it enters the canal; traction by means of the ligature can then be made, which will not only draw the nerve down to admit of the division of the proximal end, but also add the good that may be derived from the stretching process.

It may be approached in this situation from without, by making an incision from the sigmoid notch to the angle of the jaw. The parotid gland is turned aside, and the masseter muscle detached from the ramus sufficiently to allow the application of a trephine at a point three fourths of an inch behind the last molar tooth. When the button of bone is removed, about half an inch of the nerve can be isolated, exposed, and excised.

The nerve may be exposed in its course through the body of the jaw, by raising the soft parts, by means of an incision through them, about two inches in length, beginning in front of the facial artery. After the bone is thoroughly exposed, a trephine is applied in two or more situations, and the bone removed down to the canal, when the intervening portions may be chiseled out, and the whole nerve removed; or it may be excised at each of the openings. The former is the surer method.

It may also be divided *if it emerges* from the mental foramen by turning the lower lip up and making an incision about an inch

in length at the junction of the buccal fold, downward three fourths of an inch, in the line of the bicuspid teeth, when a careful search will disclose the filaments as they escape from the opening. Seize them with the forceps, draw them slowly and carefully out, and cut them off.

The Lingual Nerve.—This may be reached in *two situations*: 1. As it passes just below the insertion of the pterygo-maxillary ligament. 2. Beside the tongue and sublingual gland.

In the former, the mouth is opened widely, and the fold of mucous membrane covering the ligament is readily seen behind the last molar tooth. The nerve can be felt just below the insertion of the ligament, close to the tooth. Make an incision backward from the tooth over the course of the nerve, about one inch in length, carefully push aside the submucous tissue, and the nerve will appear in the wound, when it can be raised and cut. It has been successfully divided on several occasions near this situation by entering the point of a curved bistoury, three fourths of an inch behind, and below the last molar, cutting downward and outward to the bone in an imaginary line extending from the angle of the jaw to the last molar tooth.

In the second situation, the tongue is drawn forward and to the opposite side, and an incision made about one inch in length, parallel with the tongue, and about one fourth of an inch from the attachment of the mucous membrane to it; then push aside the submucous tissue, and the nerve will be readily seen.

The Facial Nerve.—This escapes from the cranium at the stylo-mastoid foramen, passes through the parotid gland and divides into the temporo-facial and cervico-facial branches.

Operation.—Make an incision about two and a half inches in length along the anterior border of the mastoid process and sterno-mastoid muscle. After the division of the integument and fascia, the parotid gland is pushed forward with the handle of the scalpel, and the wound carefully deepened by the same instrument. At about three fourths of an inch from the surface the nerve will be seen passing forward and outward from its foramen of exit. At about a fourth of an inch to the inner side of its foramen the jugular foramen is located; for this reason caution is essential to avoid wounding the jugular vein. The search should be carefully conducted in order not to injure the parotid gland. The nerve is somewhat deeply situated, being separated from the bone by connective tissue. The temporal branch can be divided where it crosses the condyle of the jaw through an oblique incision extending from the zygoma to the posterior border of its ramus.

Operations on Spinal Nerves.—*Great Occipital Nerve.*—This is a large branch of the posterior cervical plexus arising from the internal division of the second nerve. It pierces the complexus and trapezius muscles near their attachment and supplies the integument as far forward as the vertex of the skull.

Operation.—Locate the occipital protuberance and make an incision one inch and a half in length downward, forward, and outward at its outer side, beginning about an inch above the protuberance; carefully separate the tissues in the line of the incision and the nerve will be exposed where it escapes from beneath the trapezius muscle.

Auricularis Magnus Nerve.—This nerve is one of the ascending branches of the cervical plexus. It emerges at the posterior border of the sterno-mastoid muscle near its middle, and ascends on that muscle to the lobule of the ear.

Operation.—Make an incision two inches in length obliquely upward and backward, its center corresponding to the lower extremity of the lobule of the ear. On dividing the skin and fascia the nerve will be found resting on the sterno-mastoid muscle, from which it can be raised with a hook and stretched or cut.

Spinal Accessory Nerve.—This nerve is excised to overcome spasmodic actions of the muscles which it supplies with filaments. It can be found through an incision made behind (De Morgan, Fig. 214), or in front of (Sands) the sterno-mastoid muscle. The latter is the better plan.

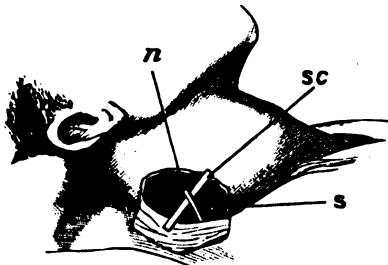


FIG. 214.—De Morgan's operation. *sc.* Sterno-cleido-mastoid muscle. *n.* Spinal accessory nerve. *s.* Splenius muscle.

Operation.—Make an incision three inches in length along the anterior border of the sterno-mastoid, beginning close to the mastoid process; expose the sterno-mastoid, pull it backward, and the nerve will be found beneath as it crosses the jugular vein, which should be cautiously avoided; close and dress the wound antiseptically.

Branches of the Brachial Plexus.—It may become necessary, on account of a severe neuralgia involving the branches of this plexus, or located in a painful stump, to excise or stretch the cords near their origin. It is best done prior to its division into its three terminal cords; that is, where only two cords are found. Place the patient upon the back, raise the shoulders, and turn the head backward and to the opposite side. The course of the external jugular is determined by pressure just above the clavicle. Make an incision along the posterior border of the sterno-mastoid, three inches in length, extending down to the clavicle; a second incision of the same length is now made outward from this point, along the upper border of the clavicle, carefully avoiding the external jugular; turn the flap upward and seek for the posterior belly of the omo-hyoid; when found, draw it upward with a hook or ligature, push aside the loose connective tissue, and the

two cords will appear located above and to the outer side of the third portion of the subclavian artery, which should be carefully avoided. The inner cord is cautiously hooked up, and a ligature applied to it, by which it can be raised from its bed and divided with a pair of scissors near the outer border of the scalenus anticus muscle, being careful to avoid the muscle and the phrenic nerve. If gentle traction be made upon the ligature, the distal extremity will be raised, and can be again divided an inch or so from the point of the first section, and removed. The second or outer cord is then divided in the same manner.

Musculo-Cutaneous Nerve.—This can be exposed in two situations : 1. As it escapes from the axilla. 2. Near to the elbow joint.

Operation.—To excise it in the first situation, carry the arm from the body and rotate it outward ; make an incision three inches in length along the outer border of the coraco-brachialis muscle ; divide the skin and fascia on a director, draw the muscle inward, and the nerve will be easily found at its outer border.

In the second situation it is found by making an incision two and one half inches in length, between the biceps and the supinator longus, through the integument, fascia, and aponeurosis ; separate the muscles and the nerve will be readily seen.

Musculo-Spiral Nerve.—This can be exposed in two situations : 1. By making an incision about four inches in length, between the outer border of the triceps and the brachialis anticus muscles, beginning it two and one half inches above the external condyle. Divide the fascia on a director, separate the connective tissues with the handle of a scalpel or by the finger, and the nerve will be easily found. 2. Make an incision, three inches in length, in the space between the supinator longus and the brachialis anticus muscles ; divide the fascia, separate the connective tissue beneath it, and the nerve will be readily exposed.

Median Nerve.—It can be easily exposed in its course along the arm and lower half of the forearm by modifying either of the incisions for ligaturing the brachial to correspond to the relations of the nerve to that vessel.

In the forearm, by making an incision about three inches in length, along the inner border of the tendon of the flexor carpi radialis, beginning about two inches above the wrist-joint. Divide the tissues in the usual manner. Separate the tendons of the flexor carpi radialis and palmaris longus, when the nerve will be discovered emerging from beneath the fleshy fibers of the flexor sublimis digitorum.

The Radial and Ulnar Nerves—like the median in the arm—can be reached readily through the same incisions employed to ligature the vessels bearing similar names.

Branches of the Sacral Plexus.—*Great Sciatic Nerve.*—This is best exposed just after its escape from beneath the lower border of the

gluteus maximus. Place the patient on the abdomen and make an incision three or four inches in length, beginning at the gluteal fold, at a point midway between the tuber-ischii and the trochanter major (Fig. 123, *a*), or the vertical may be joined by a short horizontal incision (Fig. 215); divide the integument and fascia on a director, separate the

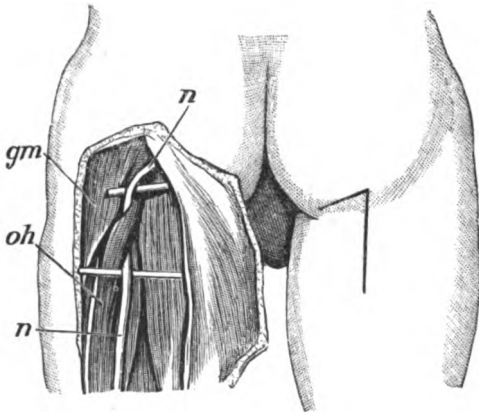


FIG. 215.—Great sciatic nerve exposed. *n, n.* Sciatic nerve. *gm.* Gluteus maximus. *oh.* Outer hamstring muscle—biceps flexor cruris.

connective tissue with the fingers and handle of the scalpel down to the nerve. It can then be stretched by passing one or two fingers around it, and making firm and steady traction upon it. Division or excision can be done easily through the same opening. The wound should be carefully closed and dressed under antiseptic precautions.

Bloodless Stretching of the Sciatic.—Administer an anæsthetic and place the patient on the back.

Extend the leg fully on the thigh, and hold the pelvis firmly. Flex the thigh on the pelvis, while full extension of the leg on the thigh is continued. This causes extreme tension of the muscles and other structures on the posterior surface of the thigh, thereby stretching the nerve. The manipulation must be firmly yet cautiously made to attain the object, and at the same time not tear asunder the hamstring muscles.

Results.—Obstinate sciatica has been relieved, and even apparently cured, by this simple manipulation. Not infrequently the degree of the resulting ecchymosis indicated rupture of the muscular structures.

Internal Popliteal Nerve.—This can be reached by the same method and with the same caution as the popliteal artery. It is, however, less deeply situated and somewhat nearer the center of the popliteal space than the vessels. Extreme caution should be exercised in operating upon it, on account of its nearness to the popliteal vein, which lies beneath it and to its inner side.

External Popliteal Nerve.—It can be easily reached by making an incision, two or three inches in length, along the inner side of the tendon of the biceps cruris, when the nerve is readily found beneath the fascia, surrounded by fat.

The Small Sciatic, Anterior *Nerves* can be

exposed through the incisions adopted in ligaturing the vessels of the same names.

The Plantar Nerves.—These are the terminal branches of the posterior tibial, and are given off just after the nerve winds around the internal malleolus. They can be exposed by making an incision about three inches in length, beginning just in front of the center of a line extending from the anterior border of the internal malleolus to the inner tuberosity of the os calcis, and extended forward along the external border of the abductor pollicis. If the space between the short flexor and the abductor be now opened at the posterior portion, the nerves will be found accompanied by the arteries of similar name.

Perineal Nerve.—This may be exposed in the perineum of the male by making an incision along the rami of the pubes and ischium in the same manner as directed for ligaturing the pudic artery at this situation. In the female perineum the nerve may be exposed either by an incision made without or within the vagina. In the former, make it through the superficial tissues, about three inches in length, in the groove between the labium and the perineum, just inside the rami of the pubes and ischium. The nerve is surrounded by connective tissue, and it is difficult to find it in this situation; however, if the blade of the knife be turned inward and the outer coats of the vagina be divided down to the inner one, the nerve will not escape section.

It is more easily severed from within the vagina. If the finger be introduced an inch or more, and lateral pressure be made, the nerve will be felt, cord-like in character and sensitive to touch. Make a vertical incision through the coats of the vagina, and the nerve will be exposed for division or excision.

Branches of Lumbar Plexus.—*Anterior Cru-ral Nerve.*—This nerve is the largest branch of the lumbar plexus, and enters the thigh beneath Poupart's ligament, about three fourths of an inch to the outer side of the femoral artery (Fig. 216).

Operation.—Make an incision three inches in length, one inch above Poupart's ligament, and the imposed layers of

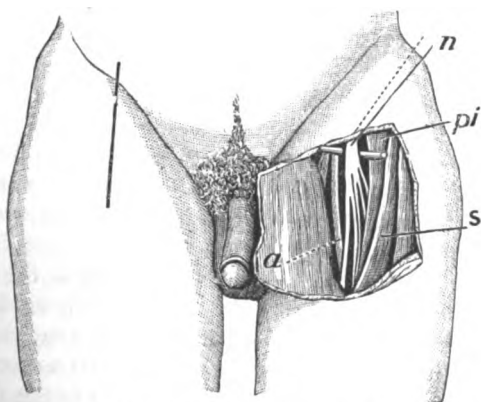


FIG. 216.—Anterior crural nerve exposed. *a.* Femoral artery. *n.* Anterior crural nerve. *pi.* Psoas and iliac muscles. *s.* Sartorius muscle.

directly downward, beginning about an inch above Poupart's ligament, and in the line of the nerve. The superficial layers are carefully divided on a director down

to the groove between the iliac and psoas muscles, in which it rests. The pulsations of the femoral artery will always suggest the location of the nerve.

The Internal or Long Saphenous Nerve is given off from the anterior crural and supplies the inner surface of the leg. It is accompanied by a vein of the same name in its course along the leg. It can be reached easily in many situations, but practically, however, it is best exposed at the inner side of the knee, where it escapes beneath the sartorius, and at the middle of the leg. In the former situation recognize the tendon of the sartorius. Press upon the internal saphenous vein above this point to distend it, make an incision two inches in length close to and parallel with the vein, draw it aside, and the nerve will be found emerging from beneath the tendons of the sartorius and gracilis. At the middle of the leg make an incision three inches in length, parallel with the properly distended vein, which should then be pulled aside, and the nerve will be found beneath it.

The External or Short Saphenous Nerve arises from the internal popliteal, escapes between the heads of the gastrocnemius, pierces the fascia below the middle of the leg and becomes subcutaneous, passes down on the fibular side of the posterior surface to the malleolus, accompanied by the external saphenous vein. Distend the vein by pressure, make an incision close to and parallel with it, near the border of the tendo Achillis; pull the vein aside, and the nerve will be seen beneath.

Suturing of Nerves.—This is a procedure of modern introduction, employed to unite the extremities of divided nerves. The earlier the attempt is made the better, provided the tissues surrounding the nerve be not inflamed. Every antiseptic precaution should be taken; if possible, it should be done under the douche of the bichloride solution.

Operation.—A free incision is made down upon the ends of the nerves to be united, being careful not to disturb unnecessarily the surrounding soft parts. The extremities are refreshed by the removal of a small portion, drawn in contact with each other, and retained in apposition by fine antiseptic catgut passed through their respective sheaths and tied. It is wise, owing to the easy absorption of the catgut, to re-enforce it by one or two horse-hair or fine silk asepticized sutures. If it be necessary, a fine catgut suture can be passed through the nerve structure and tied, in order to properly oppose and maintain the extremities. If the distance between the extremities be too great to allow a ready apposition of them, something may be gained by making traction on them and by the relaxation of their associated soft parts. If a sufficient amount of the nerve be present to admit of it, the splicing should be made obliquely, since it offers a better opportunity to securely unite the ends. After the ends are united, close the wound, dress antiseptically, and place the part in an easy position.

Results.—The results thus far point to the entire feasibility of the operation ; it hastens the resumption of nerve action by lessening the distance between the divided extremities, and in no instance has it been followed by neuritis or other untoward symptoms.

Nerve Transplantation.—Nerve transplantation is, as yet, limited to experimentation. Sections of nerves can be transplanted and union will readily take place ; but nervous influence is not quickly established. Future experimentation in this line will no doubt secure some great practical advance in the surgery of the nervous system.

CHAPTER VII.

OPERATIONS ON TENDONS, FASCLE, AND MUSCLES.

Tenotomy consists in making a subcutaneous division of the tendons of muscles to overcome or alleviate a deformity. In order to accomplish this successfully, the exact location of the offending structure must be known, together with its important contiguous vessels, nerves, etc. Many of the large tendons are easily located by their natural prominence. Others that ordinarily lie concealed become apparent if contraction has occurred, and still more conspicuous if they be placed upon the stretch. The principles governing tenotomy should be well considered ere a tendon be divided, otherwise an expedient of great good becomes mischievous and even destructive in its results. Muscles and fasciæ, either singly or conjointly, are also the direct causes of, or may be indirectly connected in, causing deformities. They, too, are amenable to a similar treatment.

The instruments employed are few in number and simple in character. Fig. 217 represents the tenotomes used by Prof. L. A. Sayre. They are excellent instruments for the purpose. Fig. 218 represents the ordinary tenotome found in the pocket-cases of the day. It is too fragile to be safely employed in the division of tissues requiring any outlay of force. A detailed description of either is unnecessary, since they can be ordered from the instrument-maker by simply naming the designer.

The blade of the tenotome used for dividing fasciæ and muscles (Fig. 219) is of necessity much longer than either of the former ; the




FIG. 217.—Tenotomes.

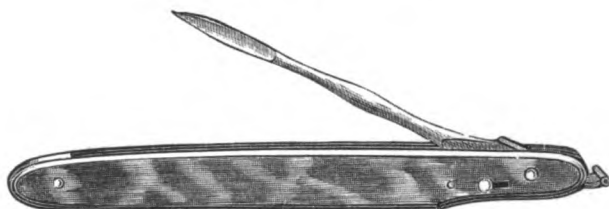


FIG. 218.—Tenotome.

principles embodied in it, however, are substantially the same. A cocaine solution may be injected near the point of division. An observance of the following simple rules will obviate the possibility of doing violence to other than the tissues directly concerned in the operation : 1. Mark the handle to indicate the direction toward which the cutting edge looks. 2. Carefully note the length of the blade, that it may be inserted only far enough to divide the contracted tissues. 3. Place the structure to be divided upon the stretch (Fig. 220). Pinch up, or press aside the skin over the part to be cut, so that when it is released, after the completion of the operation, the opening will not correspond to the divided tissues. 4. The blade should be made aseptic before being used. 5. Pass the knife-blade *from* important vessels and nerves. 6. Insert the blade on the flat, close to the surface of the tissue to be divided ; turn the edge toward it, and carefully sever it by a guarded sawing motion, aided by pressing the tendon upon the cutting surface of the knife. If unguarded force be used, the tendon and its superimposed tissues may be divided, which will seriously complicate the recovery. 7. Withdraw the blade upon the flat, follow it by firm pressure upon the parts with the thumb, which should finally rest



FIG. 219.—Fasciatome.

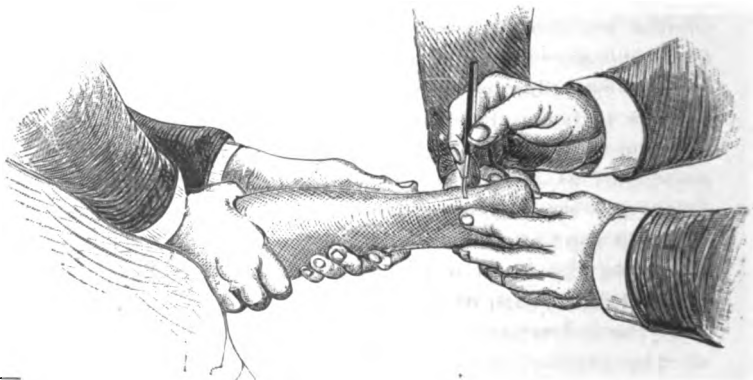

FIG. 220.—Dividing a tendon.

upon the incision ; this will press out all blood and exclude the air. 8. Seal the wound carefully with adhesive plaster or collodion ; or stitch it with aseptized silk, and apply the antiseptic dressing. 9. Rectify the deformity and confine the part to which the tendon is attached until repair shall have commenced. 10. Avoid the division of a tendon as it passes through its sheath, if possible. 11. Divide the offending tissue at the point of greatest forced prominence, provided it be consistent with its relation to important structures. If reflex spasm results from "point pressure," the tendon should be divided, and at the pressure-point inciting the reflex action. Cocaine injections act admirably.

Tenotomy—Upper Extremities.—The tendons of the *flexor sublimis* and *flexor profundus digitorum* may be divided by a transverse, subcutaneous incision carried through them down to the bone at about the middle of the first row of anatomical phalanges. Antiseptic precautions should be observed carefully in this instance, otherwise severe inflammation of the sheaths of the tendons may follow. After the division of the tendons reduce the deformity and keep the parts quiet for five or six days, till the danger from inflammation has subsided, when they may be cautiously moved.

Extensor Communis Digitorum.—The tendons of this muscle can be readily divided as they pass along the carpus or upon the dorsum of the phalanges. In the former instance, pinch up the skin, pass the knife beneath the tendon as before directed, and cut toward the surface. They may be divided by passing the blade above the tendons and cutting down upon the bone. On the dorsum of the phalanges the blade should be passed beneath the skin, and the tendons divided upon the bone. In the division of the tendons of both flexor and extensor muscles, the joints and palm of the hand above the transverse line should be avoided, also the course of the vessels and the spaces between the metacarpal bones.

The Extensor Primi Internodii, Secundi Internodii, and Osis Metacarpi Pollicis Tendons can readily be made prominent by forcible extension of the thumb in the living subject, with the forearm midway between supination and pronation. The *primi internodii* and *osis metacarpi pollicis* tendons form the inner boundary of the "snuff-box," at the apex of the styloid process of the radius, the *osis metacarpi pollicis* being the innermost of the two. The tendon of the *extensor secundi* forms its outer boundary. They can be divided in this situation by first making them as prominent as possible, then introducing the knife beneath from the anterior surface of the wrist and cutting toward the integument. The radial artery is to be avoided as it passes beneath them, and likewise the radicle of the radial vein as it crosses the intervening space.

Flexor Carpi Radialis.—The tendon of this muscle is situated

immediately to the inner side of the radial artery, at the lower third of the forearm, and can be readily divided by passing the knife from the artery beneath the tendon.

Flexor Carpi Ulnaris.—This is the most internal tendon on the anterior surface of the forearm, and has the ulnar artery at the outer border. It can be easily cut by passing the knife beneath it, from without, inward.

Biceps Muscle at the Forearm.—The tendon of insertion of this muscle may be divided either above or below the giving off the bicipital fascia. The former is the safer. Make the veins in the region prominent by constricting the arm above, extend the forearm to make the tendon prominent and tense; enter the knife at its inner border, pass it cautiously between it and the brachial artery, and cut upward, being careful not to injure the distended veins.

Tenotomy—Lower Extremities.—*Tibialis Posticus*.—The tendon of this muscle is intimately associated with the deformity of talipes varus. It runs along the inner border of the tibia, behind the internal malleolus, in a separate sheath, being the innermost tendon at this situation; after leaving the internal malleolus, it passes beneath the calcaneo-scapoid articulation to its insertions.

In the normal foot it lies well concealed within its closely fitting groove; but it can be readily outlined between the tip of the malleolus and the calcaneo-scapoid articulation.

In talipes varus it is raised from its groove and becomes more prominent above the tip of the internal malleolus, as well as below it. It can be divided in either situation, but it is better done at a point about an inch and a half above the tip of the malleolus in the adult, and one inch in the child or infant. The tendon is made tense by strongly abducting the foot, and the knife is passed with the usual precautions between the posterior border of the tibia and the tendon; the division is made by cutting outward.

The section between the tip of the malleolus and the calcaneo-scapoid articulation is not advised, on account of the contiguity of the ankle-joint and the internal plantar artery; if, however, it be thought advisable to operate at this situation, the foot should be strongly abducted, and the point of the tenotome carefully insinuated beneath the tendon, and between it and the internal plantar artery; the handle is then depressed so as to carry the point away from the joint, and the section made from within outward.

Flexor Longus Digitorum.—The tendons of this muscle are sometimes productive of contraction of the toes, after the correction of the deformity of the tarsus caused by the tibialis posticus. It lies immediately posterior to the tendon of that muscle, behind the internal malleolus, and is often divided by the same cut which severs the tendon of the tibialis posticus. It can, however, be divided independently.

If, after the division of the posticus tendon, the influence of the flexor longus digitorum be objectionable, it may be divided by introducing the tenotome beneath it through the same incision, and cutting toward the surface as before. The posterior tibial artery and its venæ comites, which in the adult are often varicose in this situation, must be carefully avoided by pressing them outward with the finger. If from contraction of the toes, unassociated with deformity due to the tibialis posticus, it be deemed advisable to sever its tendon, the posterior tibial vessels must be first detected, pushed outward by the thumb, which should then be pressed firmly between them and the tendons at the inner side; pass the tenotome perpendicularly through the integument, midway between the posterior margin of the tibia and the end of the thumb; carefully insinuate it between the tendons of the posticus and the flexor longus digitorum down to the bone, turn the edge upward, and carefully divide it toward the surface.

Flexor Longus Pollicis.—It may become necessary to divide the tendon of this muscle, on account of the crippled action of the foot in walking, dependent upon undue flexion of the great toe.

The toe should be forcibly extended, and the knife carefully inserted beneath it at the point of its greatest prominence, which will be at the anterior and inner side of the foot. The instrument must always be passed from the internal plantar artery.

The Tendo Achillis is the most prominent tendon of the human system, and should be divided at its narrowest portion. The posterior tibial artery is at the front and inner side, but sufficiently remote to be secure, if ordinary care be exercised. The short saphenous vein lies superficially and closely to its outer border.

It can be readily divided if the foot be forcibly flexed, to render it tense; pinch up the skin, push it outward to protect the vein, enter the knife beneath it from within outward, turn the edge toward the tendon and carefully sever it with a sawing motion while the foot is firmly flexed and the tendon pressed upon the edge of the knife by the finger. Great care is necessary, else a sudden giving way of the tendon may cause the knife to sever the superimposed tissues. All the precautions enjoined in tenotomy should be carefully observed in this instance.

Peroneus Longus and Brevis.—Their tendons pass in a common groove behind the external malleolus, and are inclosed by the same sheath, the latter passing the most anteriorly. It leaves its fellow after passing behind the malleolus, and is inserted into the base of the metatarsal bone of the little toe on the outer side. The longus, after passing behind the malleolus, gains the sole of the foot, enters the calcaneo-cuboid groove, and is inserted into the base of the metatarsal bone of the great toe at its outer side. The tendon of either may be divided in two situations: 1. About one and one half inch above the

tip of the malleolus. 2. Three fourths of an inch in front of it. They are commonly divided in the former situation. They can be severed connectedly or singly in either situation.

If it be decided to sever both simultaneously above the malleolus, seek the anterior and external border of the fibula, about an inch and a half above its tip, pass the knife between the bone and tendons, turn the edge outward and cut toward the surface. The short saphenous vein should be pushed inward to avoid injury.

If either is to be divided separately, push the integument backward with the thumb, to protect the vein, then push the thumb firmly down to the bone behind the tendons; pass the tenotome perpendicularly midway between the end of the thumb and the external border of the fibula, carefully insinuate it between the tendons, after which it is passed outward or inward, as the case may be, beneath the tendon to be severed, the edge turned upward, and the division made as in the preceding instances.

If the division be made below the malleolus, make the tendons tense, enter the knife about one half or three fourths of an inch in front of the tip of the malleolus, between the tendons, when either or both may be divided.

Tibialis Anticus.—This muscle, like the posticus, is of importance in connection with the deformity of talipes varus.

It is the innermost tendon of the leg and foot on its anterior surface, and can be easily outlined unless the foot be fat and chubby, when some difficulty may be experienced.

In well-marked cases of talipes varus it is displaced considerably to the inner side, and, if the foot be abducted, will become quite prominent. It is best divided about one inch above its insertion into the internal cuneiform bone. Make the tendon tense, pass the knife from without inward, to avoid the dorsalis pedis artery.

Extensor Proprius Pollicis.—As it passes across the dorsum of the foot, it can, like the preceding, be quite easily distinguished. It may become necessary to divide it after the division of the extensors of the tarsus, on account of its causing undue extension of the great toe. The toe should be forcibly flexed, and the tenotome carried beneath it from without inward, to avoid the dorsalis pedis vessels.

Extensor Longus Digitorum.—The tendons of this muscle may not only cause an obstinate extension of the toes, but aid in maintaining the tarsus in a state of forced flexion. They can be divided separately, as they pass along the dorsum of the foot, provided either be it. If all be cut at once, it is done by flexing the toes, entering the knife beneath them, a little below the bend of the ankle, from without inward, to avoid the dorsalis pedis vessels.

Peroneus Tertius.—This may be divided together with the extensor longus digitorum, of which it is a part; or it can be done separately

before its insertion into the dorsum of the metatarsal bone of the little toe, by extending the tarsus, and passing the knife beneath it, from without inward. It is the most external tendon on the dorsum of the foot, in front of the external malleolus.

Biceps of the Leg.—This tendon forms the *external hamstring*, and is inserted into the head of the fibula and the outer tuberosity of the tibia. The external popliteal nerve is located immediately at its inner side. To divide it, the leg should be extended, and the tenotome passed from within outward, beneath the tendon about an inch and a half above the head of the fibula.

The inner hamstring tendons are the *semi-tendinosus*, *semi-membranosus*, *gracilis*, and *sartorius*; the two first, however, are the ones principally concerned. The tendon of the semi-tendinosus is felt as the longest, smallest, and nearest to the median line of the popliteal space; that of the semi-membranosus is internal to it, somewhat less superficial, and runs parallel with it. Either of these tendons can be divided by extending the leg to make it tense, and entering the knife beneath and from the outer side, at the most prominent portion, and cutting toward the surface. Their division to relieve forced flexion of the leg will not always admit of complete extension, due, among other things, to the contraction of the heads of the gastrocnemius, which are inserted into the condyles of the femur. The forced extension of the leg under these circumstances often causes a tearing asunder of the attachments of this muscle, especially in the inner head, which is larger, stronger, and inserted higher than the external. The hemorrhage resulting therefrom may be severe enough to infiltrate the calf of the limb, even extending throughout the popliteal space. The liability to this rupture and consequent bleeding may be lessened, if not obviated, by first dividing the tendo Achillis; or, what is perhaps better, by first dividing the hamstring tendons, when, if, on attempting to straighten the limb, the foot becomes extended, the tendo Achillis can then be divided.

Gracilis and Sartorius.—They may be divided, after forcible extension of the leg. Pass the tenotome close at the inner side of the tendon of the semi-membranosus, between it and the gracilis, depress the handle outward or inward, as the case may be, and divide these structures toward the skin.

The Quadriceps Extensor Tendon may be divided above the patella by making an incision down to the tendon parallel with the base of the patella; enter the point of the knife above it cautiously, and with a sawing motion divide the tendon. A careful and continuous attempt should be made to flex the leg while the tendon is being cut, that its deepest fibers may be ruptured, thus avoiding, as far as possible, entering the synovial extension of the knee-joint, which lies beneath it. However, the limb should not be flexed farther than is

necessary for this purpose, and after the division should be placed in a comfortable position till repair is well advanced.

Pectineus.—This muscle, which acts as a flexor and adductor of the thigh, may require division on account of malposition of the limb. The pelvis is steadied, thigh extended and abducted, which causes the fibers to become tense and prominent. A long-bladed tenotome is then introduced at the outer border, about an inch below its origin, and carried inward and upward, till the division is complete. The internal circumflex artery, which runs between the psoas magnus and the outer border of the pectineus, is the only vessel of any size exposed to injury. The danger to this is obscure, unless it arises higher than usual. If the division be made downward and inward the femoral vessels will be less exposed than when made in the opposite direction.

The Adductor Longus is situated farther to the inner side of the thigh than the preceding, forming the inner border of Scarpa's triangle. It is, however, located on about the same plane as the pectineus. It is tendinous at its origin from the pubes, and can be easily divided, when made tense, by passing the knife beneath its outer border, and cutting upward and inward.

The Tensor Vaginæ Femoris can be severed without difficulty by introducing a long-bladed tenotome beneath it, from either border of the muscle, about an inch below its origin, and cutting toward the surface.

The Sartorius forms the outer boundary of Scarpa's triangle, and can be divided by making its fibers tense, by strong abduction; then introducing a long tenotome beneath it, at its inner border, two or three inches from its origin, and cutting upward toward the surface.

Muscles of the Trunk.—*The Multifidus Spinæ* lies on either side of the spinous processes, in the groove formed by the spines and transverse processes, from the sacrum to the axis. This muscle is quite superficial in the sacral region, opposite to the posterior superior spinous process of the ilium. Raise a fold of skin parallel with the long axis of the muscle; pass a long-bladed tenotome from the spine outward to the outer border of the muscle, and cut toward the spine.

Latissimus Dorsi.—The tendon of this muscle may be divided separately at the lower border of the axilla, or conjointly with that of the teres major, a short distance below their insertion into the humerus.

In either instance the arm is forcibly raised to render them tense and prominent, and a long, narrow-bladed tenotome is inserted along the outer border, and they are carefully severed by a sawing motion.

likewise be divided at the lower angle of the scapula. The muscle tense as before, pass a long, strong tenotome beneath it, and cut carefully outward; close the opening with a compress.

The Erector Spinae forms the principal portion of the muscular prominence on either side of the spine to be seen in the lumbar region. This is a thick, strong muscle, which arises from the sacrum and contiguous structures, and divides at the lower border of the last rib into the *longissimus dorsi* and *sacro-lumbalis*, which are inserted into the angles of the ribs and the transverse processes of the dorsal vertebrae. The *erector spinae* can be divided by a long tenotome passed from within outward, to the outer border of the muscle, just below the last rib, and carried downward and inward toward the spine.

Trapezius.—This is a muscle possessing an extensive origin. The portion which arises from the inner third of the superior curved line of the occipital bone is often divided, on account of abnormal deviations of the head.

This is readily accomplished by making the muscle tense, and severing it with a tenotome entered beneath it, just below the occipital protuberance, the edge turned toward the integument.

Sterno-cleido-mastoid.—Division of this muscle is often necessary in cases of wryneck dependent upon abnormal muscular force. It is divided at its lower extremity, either at its sternal or its clavicular attachment; often at both. For the division at either, the muscle is put on the stretch by turning the head, and the blunt-pointed tenotome passed beneath it from the outer side, about half an inch above its insertion, and divided toward the surface. The division of the clavicular portion may be ample to correct the deformity; if not, the sternal portion should be severed in the same manner. It is necessary to closely hug the under surface of the portions to be divided, else the deep-seated and important vessels may be injured. It is not safe to attempt a subcutaneous section of the muscle above this point, on account of its relation to the common carotid artery and the internal jugular vein.

Plantar Fascia.—This tissue is an exceeding dense, white fibrous membrane of great strength, with the fibers arranged longitudinally. It is divided into three portions, the middle and two lateral. The former is the one especially concerned in those deformities requiring division. It is narrow behind and attached to the inner tubercle of the *os calcis*; broader and thinner in front, and divides into five processes opposite the middle of the metatarsal bones, being one for each of the toes. Each of these processes divides opposite the metatarsophalangeal articulations into two slips, which embrace the sides of the flexor tendons, and are inserted into the sides of the metatarsal bones and the transverse metatarsal ligament. It likewise sends prolongations between the groups of the plantar muscles. This fascia serves the important function of assisting in maintaining the integrity of the plantar arch.

It is divided by placing it upon the stretch, and passing a tenotome beneath the inner border of the most prominent portion, and cutting toward the sole. The deformity is then overcome as much as is practicable, and the foot is placed and fixed in the corrected position.

Palmar Fascia.—Like the plantar fascia, this is divided into three portions—two outer and a middle part, the middle division being one of special significance. It is narrow above, and attached to the lower border of the annular ligament; below it is broad and thinner, and opposite the heads of the metacarpal bones divides into four slips, one for each finger. Each slip subsequently subdivides into two processes,

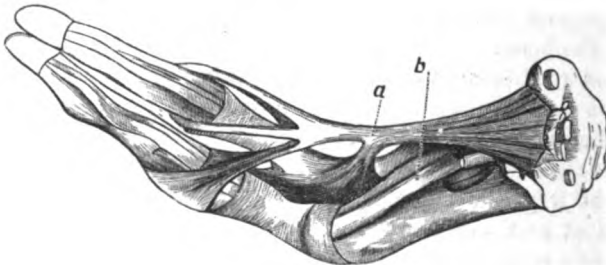


FIG. 221.—Fascial contractions. *a.* Fascial contractions. *b.* Flexor tendons.

which inclose the tendons of the flexor muscles, and are attached to the sides of the first phalanx, and to the glenoid ligament, and extends upward over the flexor tendons nearly to the tip of the finger. This fascia is intimately connected with the integument of the palm, and sends vertical septa between its muscles. From various causes it may undergo structural changes, which result in contractions of the fingers on the palm, as well as shortening of the palm itself. The anatomical arrangement of the fascia fully explains the mechanism of the deformity.

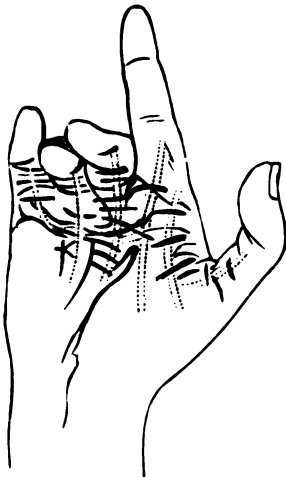


FIG. 222.—Transverse incisions for Dupuytren's contraction.

Dupuytren's Contraction.—This deformity depends upon the contraction of the prolongations of fascia of the palm, connected with the digits; the morbid process more frequently manifests itself in the ring and little fingers, causing them oftentimes to become opposed to the palmar surface of the hand.

Operation.—Anæsthetize the patient; render the restricting bands tense by a firm extension of the affected digits, and then, under anti-

septic precautions, divide the restraining bands at short intervals, subcutaneously, with a narrow-bladed knife, its edge being directed from the surface of the palm. When sufficiently liberated the digits can be freely extended, in which position they are to be confined by dorsal splints until repair is completed. Passive motion and forcible extension until the tendency to contraction is overcome, comprise the important elements of the after-treatment. Goyraud made longitudinal incisions over the tense digital prolongations of fascia, dissected the integument from them, after which they were divided sufficiently to admit of extension of the digits; the integumentary incisions were closed and the fingers confined in a straight position until healed. His success was gratifying.

Fallacy.—This deformity may be confounded with that dependent upon contraction of the flexor tendons. An examination of Fig. 221 will enable the surgeon to make a clear distinction between the two conditions.

The fascia in other situations may become contracted, as the fascia lata, at its upper or lower extremities. Whenever these contractions cause a persistent deformity they should be divided, and upon the same principles as like tissues in other portions of the body. The employment of an anæsthetic is advisable in tenotomy, especially when the section is to be extensive, or contiguous to important structures. In all instances antiseptic precautions should be taken.

Tendon Suture.—The uniting of divided tendons by catgut or by fine silver wire is an accomplished fact. Hereafter the practical surgeon, instead of assigning as a reason for the permanent immobility of an extremity, that "The tendon was cut," should first make an earnest effort to unite its extremities. The especial functions of the divided tendons can be determined by causing movements of the carpus and fingers, independently of each other, and watching the effects of these movements on the distal extremities of the divided tendons. Some difficulty is often experienced in finding the respective ends of the severed tendons, since they—especially the ends connected with the muscular belly—are notably drawn into their sheaths.

Operation.—Under full antiseptic precautions, flex the part so as to produce the greatest relaxation of the muscles associated with the divided tendons; if necessary, open their sheaths sufficiently to catch their extremities, draw them down and unite them by an oblique splice, if possible, with catgut or fine silver wire, close the wound, dress antiseptically, and confine the extremity in the position best calculated to cause muscular relaxation and quiet during the healing process.

Fallacy.—If great care be not taken, in case more than one tendon be divided, the tendons of muscles acting diversely will be united, with manifest results.

CHAPTER VIII.

OPERATIONS ON BONES.

THE injuries and diseases to which bones are liable, although not differing in any essential particular from the same conditions when occurring to the soft parts, require an independent consideration, on account of the dissimilarity of the function and structure of the osseous system. Tendons, muscles, nerves, and fasciæ are divided and excised; so are bones. The integument and soft parts generally, become the seat of inflammation, ulceration, and gangrene. Bony tissue is likewise preyed upon by the same morbid processes, named, however, quite differently; ulceration of the soft parts being comparable to caries of bone, necrosis of bone finds its synonym in gangrene of soft parts. To preserve the function of a tissue unimpaired is the greatest end that can be attained by surgery. To relieve a patient of the local effects of an injury or disease constitutes conservative surgery in its fullest sense.

The functions of bones being, in a practical sense, to support the body, protect important organs, and act as levers for purposes of prehension and locomotion, we have but to act with a knowledge of these purposes, and of the methods to maintain them, to give to the patient the full benefit of our art.

The operations upon bone are denominated gouging, sequestrotomy, excision, osteotomy, and osteoplasty.

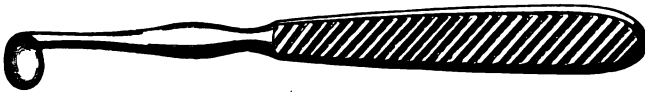

FIG. 223.—Volkmann's scoop.



FIG. 224.—Hebra's Scoop.

Gouging is applied to the removal of carious bone, and should not be attempted until the process has become chronic.



FIG. 225.—Chisel.

The instruments required to meet the exigencies of a case are gouges (Figs. 204, 205, 206, 207), scoops and chisels (Figs. 223, 224,

and 225), of various sizes and shapes, together with a suitable mallet (Fig. 208).

Operation.—Having arranged the patient in a position suitable for the convenience of the operator, administer an anæsthetic, apply



FIG. 226.—Marshall's osteotrite.

the elastic bandage if practicable, carrying it lightly over the site of the disease, and make a free incision down upon the carious bone; separate the soft parts with retractors; then, with the drills, gouge, osteotrite, etc., remove all the diseased structure.

It is important to be able to determine the line between the healthy and diseased bone; and this is often very difficult. If the portions removed, when washed, present a whitish, grayish, or blackish appearance, and are porous and fragile, instead of being vascular, red, and tough, then the operation should be continued. If the gouged surfaces bleed freely from numerous points, and have a normal firmness and color, then the operation should cease.

It is important in gouging the extremities of bones to use extreme caution, or the joint cavity may be opened directly, or become secondarily involved. After the removal of the elastic constriction, all hemorrhage should be arrested, the wound washed thoroughly with a suitable antiseptic solution, good drainage secured, the soft parts united, and dressed antiseptically.



FIG. 227.—Liston's straight forceps.

Sequestrotomy.—This operation is employed to remove dead bone *en masse*, and is therefore applicable to necrosis. The additional instruments necessary are small crown trephines, bone-cutting forceps of various shapes (Figs. 227, 228, and 229), gnawing forceps, small



FIGS. 228, 229.—Liston's curved forceps.

saws (Figs. 241, and 242, 230, 231) and periosteal elevators (Figs. 232 and 237), etc. There are two methods employed, depending on the nature of the case—viz., direct and indirect.

The Direct Method.—Having detected the situation of the necrosed bone, and being satisfied, either from the long course of the disease, or by movement of the dead portion, that detachment has occurred, apply the elastic bandage, using care not to force deleterious matters



FIG. 230.—Lente's saw.

into the circulation, select a strong scalpel (Fig. 234), and connect the fistulous openings with each other, down to the bone ; choosing



FIG. 231.—Langenbeck's key-hole saw.

such openings, of course, as will cause the connecting incision to be consistent with good drainage, easy access to the diseased parts, and safety to the underlying structures. The surfaces of the incision



FIG. 232.—Sayre's periosteotome.

FIGS. 233, 234.—Strong scalpels.

FIG. 235.—Retractors.

should now be separated with retractors (Fig. 235), to fully expose the openings in the involucrum. If the sequestrum can be drawn out of the opening with suitable forceps, it should be done carefully ; otherwise the reparative tissue upon which it rests will be injured, and the process of recovery deterred. If it be too large, or be interlocked with healthy bone, the opening must be enlarged sufficiently to admit of its withdrawal ; or, if this be impracticable, an incision through

the periosteum should be made, corresponding to the long axis of the sequestrum. The periosteum should be carefully raised upon either side of the incision to permit the application of a small crown trephine, with which the involucrum should be perforated a sufficient number of times to admit the easy removal of the dead portion, either with or without the chiseling away of the irregular borders.

The gnawing forceps, chisels, the mallet, and even small saws, may be used in lieu of or in conjunction with the trephine.

Should there be but one sinus, and evidences of disease exist above and below it, the center of the incision should correspond to the sinus, if the anatomical relations will admit of it. It is necessary to use great caution in making these incisions in the vicinity of joints, or their synovial pouches will be opened. After the removal of the dead bone, the wound, through its whole extent, should be thoroughly cleansed, suitable drainage provided, the lips of the wound closed, and antiseptic dressing applied; or, after washing, it can be lightly filled with oakum saturated with balsam of Peru, or carbolic acid and oil, and the whole confined in place by a mass of carbolized oakum, held in position by a roller bandage. In the latter instance it should be dressed frequently to secure proper cleanliness. If the antiseptic plan be employed, the rules applicable to the method should be strictly observed. When the portion of bone removed is large, or the remaining part is small and fragile, the limb must always be supported by a splint; otherwise it may bend or break, and thereby complicate the ultimate result.

If the sequestrum be as yet unseparated from the healthy bone, it should be allowed to remain until the process of separation is completed, when it can be removed.

The indirect method is preferable when the bone is superficial and its disease progressive, as in osteitis of the lower jaw, clavicle, bones of the arm, forearm, or tibia; in fact, all the long and many of the flat bones can be reproduced by this method. It consists in making a free incision down upon the diseased bone, through the surrounding periosteum, and separating the membrane by means of the handle of a scalpel, spatula, periosteal elevator, or any instrument of a like character. This must be done at intervals, and not extend beyond the diseased portion; the length of the intervals will depend entirely upon the rapidity of the morbid process. This plan is necessarily tedious, both in detail and in time; yet sooner or later the dead bone can be raised from its new osseous trough, which will soon become filled, and oftentimes serve the purposes of its predecessor. The free incision necessary to expose the dying bone will provide good drainage; nothing is necessary other than this, than to keep the wound clean by ordinary means.

Excision.—Excision of bone is a conservative operation, directed

to the extraction of such portions of it as are inconsistent with its future usefulness or the symmetry of the part, together with the removal of the condition directly demanding the operation. It is employed in lieu of the more radical measure—amputation. It may be directed to the articular extremities or to the shaft of a bone ; and, in either instance, it may be *partial* or *complete*. The articular extremities or joints are excised on account of injury, disease, or ankylosis in a faulty position. In estimating the prognosis for life, the surroundings of the patient, his previous habits, present condition, and the existence of constitutional taints, must be considered ; also the nature and extent of the cause demanding it. The prospective usefulness of the limb will depend on the ability to leave the muscular attachments intact ; and also upon the condition of the nerves that animate, and the blood-vessels that nourish them. If the patient be a manual laborer, or be one over-sensitive of a deformity, it is well then to consider if additional advantages can be derived from artificial limbs and appliances, when it may be deemed the wiser to sacrifice the offending member for the relief afforded by amputation. The incisions preparatory to the necessary exposure of the parts to be removed should be free, and, when possible, be made in the long axis of the bone. They are often, however, varied, to suit the peculiar demands of the individual cases. They are likewise varied for the different joints, being in one instance longitudinal, in another U, H, or == shaped, according to the proposed extent of the operation and the contiguous anatomy of the part. In every instance, however, they should be made with a view to good drainage, when the same incision will render the parts accessible, and not expose adjacent important structures to unwarranted danger. Future usefulness being one of the most important factors to be gained, the insertion of all muscles, having especially defined functions, as flexion or extension, must, if possible, be carefully avoided. If it be necessary to divide tendons, they should be incised obliquely, the better to facilitate subsequent union. Should it be necessary to remove the bony surfaces, into which they or the ligaments are inserted, the periosteum covering these surfaces should be carefully peeled off, together with all tendinous attachments. All diseased and loose pieces of bone should be removed, together with irregularities and isolated portions of articular cartilages. The synovial membrane should be preserved, unless it be diseased, and its diseased portions cut or scraped off. The removal of the entire shaft of a bone may be necessary on account of injury or disease, notably the latter. In such cases the incision should be free, and made over its most superficial aspect, provided that important structures do not intervene ; the periosteum is then elevated proportionately to the extent of the disease, gradually or rapidly, as the circumstances indicate, and the diseased bone removed, leaving, if possible,

the epiphyseal extremities. If the epiphyseal cartilage be destroyed, the growth of the bone in its long axis will be interrupted. This is very important to observe in operations upon the bones of adolescents, since to destroy this cartilage will cause a subsequent shortening of the limb. The consultation of any standard work on anatomy will enable the surgeon not only to accurately locate the epiphyseal junctions, but likewise inform him of the age at which the shafts become united to their epiphyses.

The time of operating must be governed by the condition of the patient, and also by the part to be operated upon. If the patient be

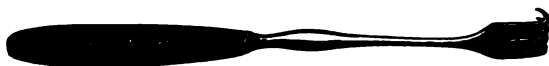

FIG. 286.—Retractor.

suffering from shock, reaction should take place prior to operative interference. Should inflammation

of the bone have occurred, good drainage should be established, and the operation deferred until the acute symptoms subside. If the operation be for necrosis, the diseased bone should be allowed to separate before the attempt is made.

The instruments required for excision are varied in number and shape, and must be selected according to the peculiarity of the case.

The knives should be broad and strong (Figs. 233, 234). The retractors (Fig. 235) must likewise

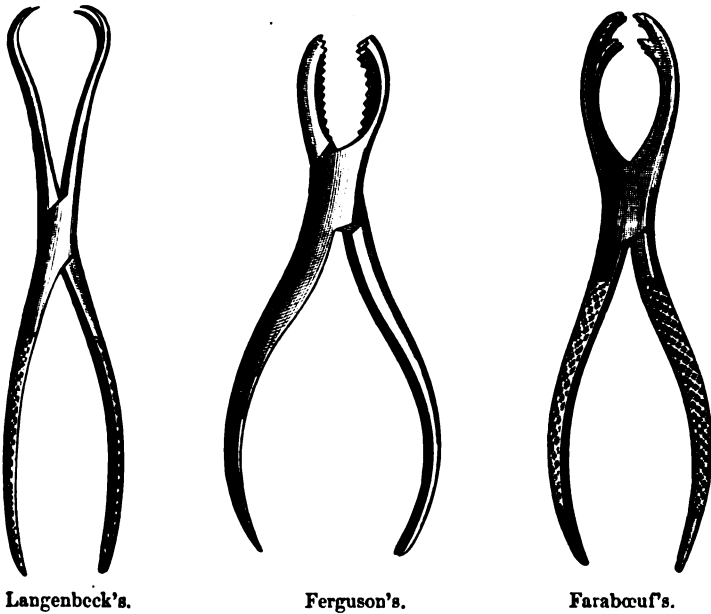


FIG. 237.—Sands' periosteotome.

be strong, and possess a hook-like curve, otherwise they will slip from the wound. A sharp-hooked retractor may be employed (Fig. 236). The periosteotomes, or elevators (Figs. 237, 232), vary in shape, but should possess a blunt, non-cutting edge; and if compactness be desired, the elevator may be connected with the handle of the knife (Fig. 234). However, it is not so handy or efficient as the independent instrument. These instruments must be used with care, otherwise the function of the periosteum will be destroyed, and may even be followed by sloughing. The bone-cutting instruments are forceps, and saws of various sizes and shapes. The straight bone forceps are the most available for general purposes. The blades should fit accurately, and be sufficiently sharp to make as clean a cut as possible. In order that bone intricately located may be reached, the blades are bent at various angles (Figs. 227, 228, 229). The gnawing forceps or rongeur are of inestimable value in removing bony projections.

Bone-holding Forceps (Fig. 238) vary somewhat in their grasping and holding powers; consequently the surgeon will be governed in his selection of an instrument by its suitability for the purpose. The varieties of saws are numerous, among which are the chain-saw (Fig.

239), the straight saw, with an adjustable back (Fig. 241), and the curved, for right and left sawing. These are of use in removing por-



Langenbeck's.

Ferguson's.

Farabœuf's.

FIG. 238.—Bone-holding forceps.

tions of thin bones from flat surfaces. The chain-saw, as the name indicates, is composed of numerous links or sections, having a handle




FIG. 239.—Chain-saw.

for working it attached to each extremity. To apply the saw, remove the handle from the hook and carry it beneath the bone, with the cut-

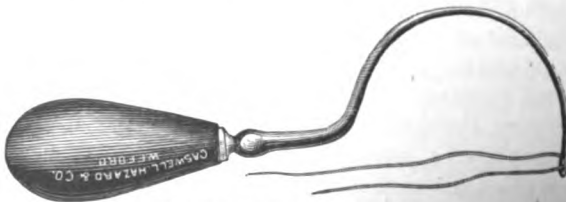

FIG. 240.—Chain-saw carrier.

ting edge upward, by means of a thread and curved needle, or an instrument known as the "chain-saw carrier" (Fig. 240) may be employed



FIG. 241.—Lifting-back metacarpal saw.

instead ; readjust the handle, and draw it from side to side at an angle of about 45° with the bone. It should not be jerked, or be allowed to kink, but should be kept taut while being used, for fear of clamping or breaking it. This instrument is employed in dividing those bones which are nearly surrounded by the soft parts. Fig. 242 represents a saw of great practical worth. The blade is adjustable, and its cutting surface can be turned in any direction ; it has therefore a universal application, which renders it superior to the chain-saw, except in isolated cases. The gouges, chisels, and mallet are required to thoroughly remove all diseased bone. They vary in size and shape, in order that the intricacies of the wound may be reached. The instruments to seize the fragments of bone are also variously shaped, to be better able to grasp them.

The Surgical Engine.—This is the outcome of the dental engine, the former being the stronger and associated with suitably constructed knives, trocars, burrs, and saws. These instruments are connected by a hand-piece which is attached to a flexible wire cable that permits the easy holding and directing of their rapidly revolving surfaces. The rapidity of their action—two to three thousand revolutions per minute—lessens the pain and the injury done to important parts. The engine can be used with advantage in bone surgery. It is expensive and somewhat cumbersome, and therefore better fitted for hospital use than for general practice.

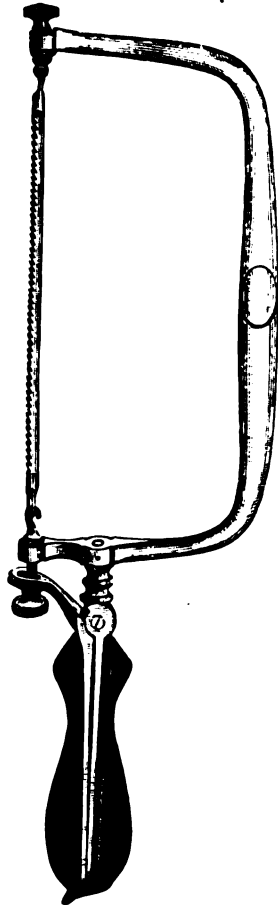


FIG. 242.—Szymanowski's saw.

The treatment of excision wounds is in nearly all instances substantially the same. Rest and thorough drainage, together with strict antiseptic measures, constitute the basis of the future treatment.

Rest can be secured by the various forms of splints, either movable or immovable in character. The older dressings of these wounds consisted of oakum, lint, marine lint, or a fine silken oakum, either with or without saturation with carbolic acid and oil, or balsam of Peru. If treated by this method, they should be dressed with sufficient frequency to prevent any septic infection, once daily being usually enough. If the antiseptic methods be adopted, the rules governing the readjustment of the dressings should be enforced.

Excision of the Upper Jaw.—This operation is done for various diseases, connected either with the bone structure itself or the cavities with which it is associated. In all instances the periosteum should be preserved, except those in which it is invaded by malignant disease.

The special instruments requisite—in addition to those already enumerated for excisions—are a trephine, or a bone-drill and a strong pair of forceps to turn or twist the bone out of its cavity, together with forceps to draw the teeth in the line of section. The patient is anæsthetized and placed upon the back, either with the head slightly raised or markedly depressed. In the latter position the blood does not escape into the larynx, but into the upper and posterior part of the pharynx. This position, however, impedes respiration by undue stretching of the tissues of the anterior cervical region. However, this may be obviated, in a great degree, if the foot of the table be raised, as for the reduction of the abdominal contents by taxis. If the head be elevated, the blood can, with care, be kept from the larynx, either by constant sponging or tamponing the pharynx around a large catheter or rubber tube, or permitting the patient to be sufficiently conscious to dislodge it. Still another method is to confine the patient in a rocking-chair, which can be tipped forward or backward as circumstances require. The surest of all is to perform a preliminary tracheotomy, and then tampon the floor of the pharynx. This is not as a rule necessary unless the operation be complicated with a very vascular morbid process requiring a separate removal. If the important associated anatomy be carefully considered before beginning the operation, it will save much time and not a little blood.

In complete removal, the bony connections which must be divided are : 1. With the malar, below the outer angle of the orbit. 2. With the fellow of the opposite side in the roof of the mouth. 3. The nasal process of the bone, with its body below the inner angle of the orbit. 4. The slight connection between it and the palate bone and pterygoid processes of the sphenoid. The internal maxillary artery in the sphenomaxillary fossa and the branches of the facial artery running through the external soft parts are the only vessels that will cause troublesome hemorrhage. Steno's duct must be avoided, as it runs from the parotid gland to empty into the mouth opposite the second molar tooth, the line extending from the lobule of the ear to midway between the

border of the lip and the ala of the nose. The superior branches of the seventh pair of cranial nerves may be divided unnecessarily if the course

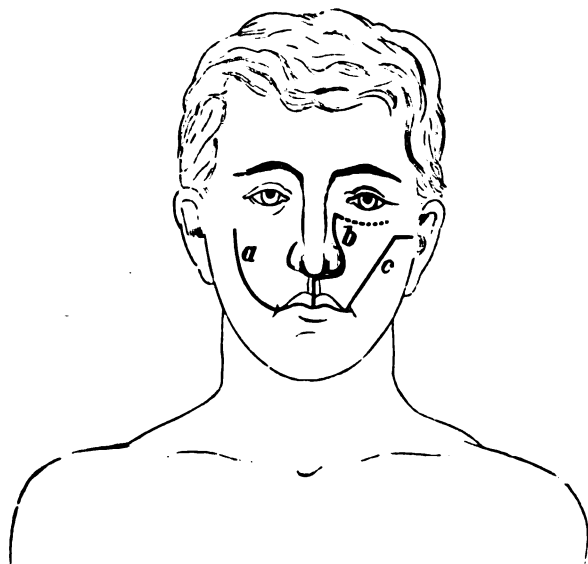


FIG. 243.—Linear guides for removal of upper jaw.

or extent of the incisions be too great. All anticipated complications should be carefully studied, and provisions made for their treatment. Loss of blood, however, is the only one in addition to the shock common to all operations that requires close attention. Hemorrhage from the facial and internal maxillary arteries, while often profuse, can be easily controlled.

The Lines of Incision.—They may be made within or without the buccal cavity.

To attempt the removal from within is too tedious, the space being limited and the ability to control hemorrhage entirely inadequate. At the present time external incisions only are practical. These can be classed as the outer, and the median. The former (Lizar's) commencing at the angle of the mouth and passing in a curved course upward and outward to the malar process (Fig. 243, *a*); if more room be needed it may be supplemented by an incision through the upper lip to the nostril, also by extending the first. This incision exposes Steno's duct and the branches of the seventh nerve to injury, and is followed by a conspicuous scar.

Liston made an incision from below the external angular process of the frontal bone to the angle of the mouth; if necessary, a second was also made along the zygoma joining the first (Fig. 243, *c*), and even a third from the nasal process of the maxilla downward to

the lip in the median line. Velpeau, like Lizar, made a single curved incision with the convexity downward from the angle of the mouth to the malar bone, and even to the angle of the orbit if necessary. The last (Ferguson's), and an admirable one, is made at the middle of the upper lip, and, following the furrows between the cheek and nose, terminates about half an inch below the inner angle of the eye (Fig. 243, *b*). To this may be added an incision of an inch or so in length, extending outward half an inch below the orbit, and at a right angle with the vertical one, or it may be extended to the external angle of the orbit and the zygoma if necessary. In this incision the coronary and angular arteries only are divided.

Operation by the Median Incision, with Removal of the Whole Bone.—The middle incisor tooth corresponding to the side to be operated upon is drawn, and the facial artery compressed on both sides by an assistant. The incision is begun at the border of the lip, and in order to prevent blood from entering the mouth, it is not carried through it until later, from the upper attachment of the lip, through the remainder of the course, the incision is rapidly made down to the bone, and the flap dissected outward as far as the malar bone above, and the tuberosity of the maxilla below; during the dissection the bleeding points are controlled by the fingers of the assistant or by the serrefine forceps. All vessels should be ligated with catgut before the bone is removed. The cartilage of the nose is separated from the bone and turned inward, the edge of the orbit gained, and the periosteum on the floor separated

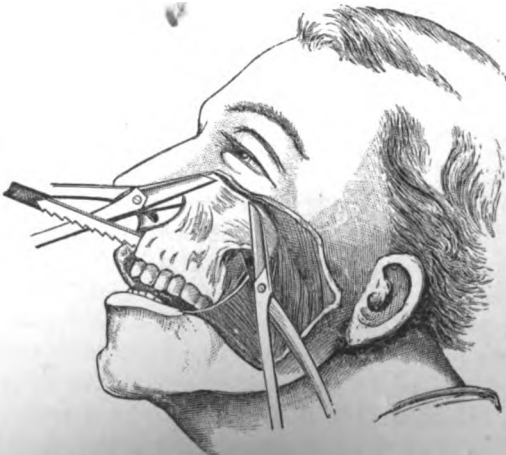


FIG. 244.—Division of processes of superior maxilla.

and pushed backward and upward by means of an elevator or handle of a scalpel to the border of the sphenomaxillary fissure. The malar process is now divided by sawing, or cutting through it with bone-forceps, from the outer extremity of the sphenomaxillary fissure. The thin floor of the orbit is divided with a scalpel from the sphenomaxillary fissure obliquely forward and inward,

and the nasal process severed with forceps (Fig. 244). The mucous membrane of the roof of the mouth is then divided transversely inward to the center, on the side of the last molar tooth, then from the

center forward, in the median line, to the incisor teeth. The hard palate is divided at the side of the septum, corresponding to the bone to be removed, by a saw or bone-forceps, and the bone seized and pressed downward to break up its posterior connections, after which it is raised and twisted slightly from side to side and pulled out, bringing with it some portions of the palate bone and pterygoid process of the sphenoid, together with the muscular fibers connected with them. If the mucous membrane of the mouth be not diseased, it can be saved by making an incision through it along the alveolar border, and pushing it inward together with the periosteum to the median line. After the removal of the bone the periosteum can be stitched to the side of the cheek.

Excision Below the Floor of the Orbit.—After the exposure of the external surface of the superior maxilla, as in the preceding method, perforate the anterior wall of the antrum with a drill or trophine; then, with the bone forceps or saw inserted into the opening, divide the bone through into the nasal fossa, and separate it from its outer connections by sawing or cutting through the malar bone. Aside from this the steps of both are similar.

After the operation the wound is washed with carbolic acid, and all bleeding points checked either by ligature, pressure, or cautery, the first being the best. The external incision is then closed with sutures or pins, and readily unites in three or four days. The raw surfaces within should be kept thoroughly cleansed while repair is taking place. These cases make a satisfactory recovery from the operation, although some deformity always remains.

The stitches are removed from the soft parts the third or fourth day, union, as a rule, being complete.

The results of this operation are good, so far as immediate loss of life is concerned. About one in five or six die. If the removal be done for malignant growths, the prognosis for ultimate recovery is unfavorable.



FIG. 245.—Subperiosteal excision of upper jaw.

is can be done with any of the median incisions, but an

external one is preferred by some (Fig. 245). The external incision is made from the middle of the malar bone to a point on the upper lip, one third of an inch from the angle of the mouth (Ollier). It is sometimes necessary to make a second incision from the middle of the lip upward to the nose (dotted line, Fig. 245), as in the preceding operation. The mucous membrane on the external surface of the alveolar process is divided down to the bone; beginning at the line of junction between the lateral incisor and canine teeth and carried backward to and around the posterior molar to the inner surface of the alveolar process, forward parallel with the external incision to a point opposite the commencement of the external incision, then obliquely backward and inward on a line corresponding to the intermaxillary suture of that side, to the median line. The anterior extremities of the external and internal incisions are now connected with each other by a transverse incision, carried on a line extending between the lateral incisor and canine teeth. The periosteum is then peeled off from the external and orbital surfaces of the bone, and also from the inner surfaces of the alveolar process, and the hard palate of that side. The nasal and malar processes are divided as before, the canine tooth drawn, and the intermaxillary bone separated, together with the hard palate of the maxilla to be removed, from the contiguous bone, by the chisel, saw, or forceps. The maxilla is then twisted out, and the periosteum from the inner and outer surfaces of the alveolar process united.

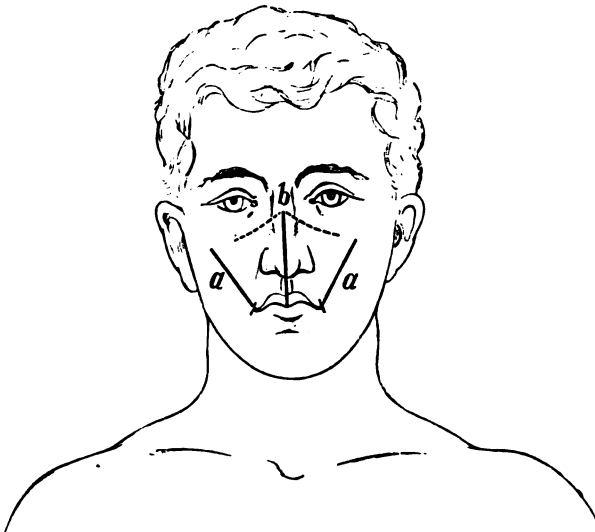


FIG. 246.—Removal of both superior maxilla.

The superior maxilla may be removed simultaneously by either of two methods. 1. Make an incision from each angle of the mouth

to the middle of the malar bone on the respective sides (Fig. 246, *a*), and dissect upward the intervening flaps; or, 2, make a vertical one (Fig. 246, *b*) along the ridge of the nose through the lip, beginning at a point one fourth of an inch below the lower border of the orbit (Dieffenbach). To this may be added a transverse incision one fourth of an inch below, and extending to opposite the middle of each orbit, across the upper end of the vertical incision (dotted line, Fig. 246); the outer bony attachments are divided as in the single operation; the nasal processes are divided either by forceps or the saw, and both bones removed at once—not separately. In all operations for the complete removal, the superior maxillary nerve should be divided as far back as possible. The bones may be removed separately in the manner described for the removal of a single superior maxilla.

Results.—About thirty per cent die from whom both bones are removed simultaneously.

Excision of the Inferior Maxilla.—The operations on the lower jaw require no additional instruments; the precautions referable to the patient are almost of equal importance, and the contiguous anatomy is even more important than for the upper. The facial artery runs beneath and across its lower border and on its outer surface at the anterior border of the masseter muscle; the parotid gland lies behind the ramus, and often overrides it. The external carotid artery, as it passes through the gland, is closely associated with its posterior border. The internal maxillary artery runs closely behind and to the inner side of the neck of the condyle. The inferior dental artery runs along the inner surface of the ramus to enter its canal. The superior division of the seventh pair of nerves passes across the outer border of the neck of the condyle. Steno's duct passes across the masseter muscle to its opening opposite the second molar tooth, on a line parallel with and about an inch below the lower border of the zygoma. The lingual nerve runs along the inner surface of the ramus, close to the bone just below the last molar tooth.

The genio-hyo-glossus muscle is attached to the superior genial tubercles, and, if incautiously detached, will permit the tongue to fall backward and close the glottis. It is very important, when possible, to preserve the attachments of the muscles of mastication, on account of their action on the resultant tissues. The operation may be directed to a complete or partial removal of the bone. A partial removal may include any fractional portion of it.

The incisions for the removal may be made within the mouth or on the external surface. If the whole or a lateral half is to be removed, an external incision must be made. The portion in front of the molar teeth, and even in front of the ramus, can be excised by internal incisions alone; the latter is, however, often attended by vexatious difficulties, and is hardly warrantable, except in selected cases.

The ramus and portions of the body behind the teeth can be removed through an external incision without opening into the buccal cavity, provided the periosteum be carefully raised from its surface. In the same manner the body, or any portion of it, may be taken away if the teeth be absent. If the teeth be present, the periosteum may be carefully detached, and the bone with the teeth removed, after which the openings of the buccal cavity, caused by the withdrawal of the teeth, can be closed by sutures applied internally. If the jaw be the seat of phosphoric or other necrosis, it may be gradually enucleated, through an external opening, from its surrounding involucrum, by the indirect method, and the teeth may even remain in the new growth. Unfortunately, however, when processes of a malignant nature call for the operation, these conservative methods are of no avail, since the operation must be directed to the removal of all the diseased tissues. When possible, the incision in the buccal lining should be closed, and the wound drained externally. This will keep the mouth clean, and prevent swallowing the discharges.

Excision of the Central Portion.—Pass a stout ligature through the tongue well behind its tip, to prevent tearing out, and tie the ends to form a loop, which will be convenient for keeping it from falling backward. The assistant stands behind the head of the patient, holds the loop firmly, at the same time compressing the facial arteries where they pass across the jaw; or seizes the lower lip at the angles between the thumbs and fingers, rendering it tense, and at the same time arresting its circulation. The operator, standing in front, makes a vertical incision through the median line down to the bone, extending to the lower border of the symphysis mentis, raises the periosteum from its surfaces, if practicable, to the extent of the proposed section, draws a tooth at each point where the bone is to be divided, saws it at these points, and draws the fragment forward and separates the attachments of the muscles as closely as possible to their insertion. The flaps are then united with silver wire, extending through the mucous membrane. The vermilion border of the lip is carefully adjusted, and united with pins or silver sutures. If the tongue fall backward, its severed muscular attachments can be drawn forward, and connected with the incision in the median line by a deep suture passed through the lip. The bone can be easily reached through a curved incision made along its lower border, or by an internal one corresponding to the fold of the buccal membrane. The lip is depressed over the symphysis mentis, and the bone is removed.

Excision of the Lateral Portion of the Body.—Make an external incision along the under border of the portion to be removed, down to the bone. If necessary, the incision may be turned upward at a right angle toward but not through the lip. If the condition of the parts will permit, the periosteum is reflected off, the bone divided in front,

external to insertion of the genio-hyo-glossus muscle, and if possible turned outward, and the tissues separated back to the point of posterior section ; it is then removed with a chain-saw, and dressed as before.

Excision of Half of the Lower

Jaw.—Commence the incision about an inch and a half below the arch of the zygoma, and carry it downward along the posterior border of the ramus, and beneath the body of the jaw to the symphysis mentis, carefully exposing the facial artery and tying it. If the operation be for necrosis, this incision will be sufficient ; if for other disease, the lower lip is cut perpendicularly through its center to meet the longitudinal incision (Fig. 247). The bone is exposed in front by peeling off the periosteum or otherwise, and sawn through just to the outer side of the insertion of the genio-hyo-glossus muscle if possible, the end pulled outward, and the remaining attached tissues separated either by cutting or by a periosteotome, back to the beginning of the incision. Depress the fragment forcibly, and if possible

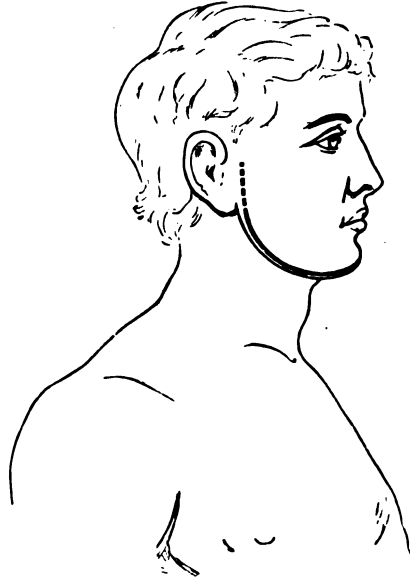


FIG. 247.—Linear guide for removal of half the lower jaw.

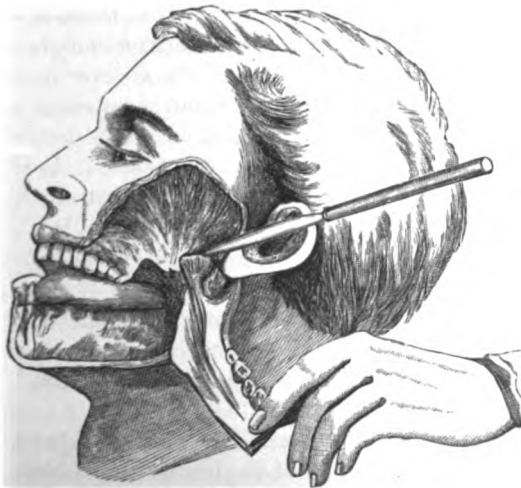

FIG. 248.—Severing connections of inferior maxilla.

detach the temporal muscle with scissors or the periosteotome, then turn the bone outward, and divide the insertions of the pterygoid muscles in the same manner, carefully avoiding cutting the lingual nerve, draw the bone forward forcibly and twist it from its socket (Fig. 248).

If it be impossible to accomplish its removal in this manner, extend the incision upward to the neck of the

bone (dotted line, Fig. 247), avoiding if possible the division of Steno's duct and the cervico-facial branch of the seventh pair of nerves, and enucleate the condyle. In this situation the condyle must be closely followed, otherwise the internal maxillary artery may be injured, as it passes immediately behind it. If the primary incision be sufficient to expose the bone above the seat of the disease, it should be sawn through at this point and the upper portion allowed to remain.

Excision of the Entire Lower Jaw.—Remove the left half first, or the right if it best suits the convenience of the operator, in the manner before described. A ligature is then passed through the tongue, given to an assistant, and the remaining half of the bone excised in a similar manner. Arrest all hemorrhage, and close the wounds with sutures in such a way as to accurately coaptate the divided buccal borders.

In all situations, when the nature of the disease will permit, the periosteum should be reflected by a careful yet vigorous use of the elevator. The insertions of ligaments and tendons will offer the only obstacle, and these should be carefully detached by a sharp knife, that a continuity of the periosteal and fibrous tissues may remain.

The periosteum in young subjects may reproduce enough bony material to give a fair outline to the face and serve an important function in mastication.

If bone be not reproduced, the periosteum will furnish a firm fibrous base, which may be utilized for artificial appliances. If the anterior portion of either or both sides be removed, the gap may be filled in by an artificial dental appliance, which will often happily maintain the symmetry of the face and become useful in mastication.

Excision of the Alveolar Process.—When the extent of the disease will permit, the alveolar process can be removed down to the body of the jaw through either an external or internal incision, the former being the better. The diseased part is then removed, and the wound closed as before. After recovery, the body of the jaw will form an excellent foundation for a compensatory dental appliance. Whenever the disease is malignant, the periosteum should be removed with the bone, and care taken that none of the diseased membrane remains in the wound. It is also necessary in such cases to remove all associated structures when diseased—such as glands, floor of the mouth, and even the tongue itself.

Results.—Out of two hundred and forty-six excisions in the continuity, forty-six died. Of one hundred and fifty-three disarticulations of one half the bone, thirty-six died. In twenty operations for removal of the entire jaw, one died. It will be seen that death has followed in twenty per cent. of all the cases. Pyæmia, erysipelas, and exhaustion were the principal causes.

Operation for Anchylosis of the Inferior Maxilla.—This consists in establishing a false joint in front of the cause of the immobility, which is usually dependent on cicatricial contraction, irreducible dislocation,

or ankylosis. The removal of a wedge-shaped piece from the lower border of the jaw, or from the alveolar process, has been practiced; or a transverse section of the ramus with a sharp chisel introduced through the mouth, or even fracture of the neck when the condyle is involved, has relieved the condition.

*Operation for Removal of a Wedge-shaped Piece (Esmarch).—*Make an incision two inches in length down to the bone, along the lower border of the jaw, beginning at or in front of its angle, depending upon the location of the cause of the immobility. Avoid or tie all important vessels in the course of the incision; expose both surfaces of the bone up to the summit of the alveolar process, and pull a tooth if necessary. Divide the bone with a chain-saw at one extremity of the exposed surface, force the other extremity through the wound, and remove the wedge-shaped piece with the rongeur or saw, the base of which should not exceed a third or half an inch. While the patient is still under the influence of the anæsthetic and before the wound is closed, ascertain the distance the liberated portion can be separated from the upper jaw with moderate force. Provide suitable drainage, close the wound, and prevent union of the bones by passive motion.

Rizzoli, of Bologna, recommends a simple section of the bone instead of the removal of a wedge-shaped piece; however, the results of this method do not warrant its substitution for the former. If the cause of the immobility be due to ankylosis of the temporo-maxillary articulation, the condyle should be removed, or the ramus be so divided as not seriously to impair the functions of the masseter muscle, that is, divided beneath that muscle. The division of the neck of the bone by a straight chisel introduced through the mouth (Grube) has been practiced. After either operation it may be necessary to divide the masseter muscle before the full benefit can be experienced from the division or the removal of the bone. If it be determined to remove the condyle, a curvilinear incision, corresponding to the location of the portion of bone to be removed, is made down to it, when, by means of a chisel, saw, or forceps, the neck of the bone is divided at the proper place, the fragment turned outward by forceps, its attachments divided, and the bone removed. Passive motion should follow the same as before.

Excision of the Sternum.—No definite plan for this operation can be outlined. The form and length of the incisions must be governed by the location and extent of the disease. The diseased bone should be freely exposed, and removed in the usual manner. Care must be observed, else the pleural cavity will be opened. When possible, subperiosteal excision should be done, as the bone is quite readily reproduced. The entire sternum is reported to have been removed by König on account of a sarcomatous tumor involving its structure, and, even though the pericardium and pleural cavity were opened, the patient ultimately recovered.

Results.—Partial excision, cautiously done, results most favorably; only one in eighteen died.

Excision of a Portion of a Rib.—This may be done for the removal of necrosed bone, or to make a permanent opening into the thorax for the escape of pus. If for diseased bone, make an incision in the middle of the long axis of the rib of sufficient length to include the diseased portion. This may be crossed at the middle by a transverse incision. Separate the periosteum along with the superimposed tissues, liberate the bone, and raise it from its bed. If the sequestrum be not loose, time should be allowed for its separation. If the operation be for pyo-thorax, select the sixth or seventh rib; make an incision in a line with the axilla about two or three inches in length down upon the middle of the rib, through the periosteum; bisect this by a horizontal one of the width of the rib, expose the bone on both surfaces by raising the periosteum together with its surrounding tissues, being careful as yet not to open into the pleural cavity; excise one half or three fourths of an inch of the bone, dividing it with a chain-saw. If the intercostal artery, which lies beneath its lower border, be cut, tie it; then make a suitable opening through the intervening structures into the pleural cavity.

It is well to make the first incision corresponding to the long axis of the rib, and thus the more surely avoid the intercostal vessels and nerves. The wound should be dressed antiseptically.

Excision of the Clavicle.—This operation is performed for necrosis and for morbid growths of the clavicle. The patient is placed on the back, with the shoulders elevated from the table and the head turned to the opposite side.

Contiguous Anatomy.—The muscular and ligamentous attachments of the clavicle must be carefully studied, for it is by a knowledge of them that the surgeon is enabled to raise the bone safely from its more important relations.

In front.

Attachments of—

Pectoralis major muscle.

Sterno-mastoid muscle.

Trapezium and deltoid muscles.

Above.

External jugular vein.

Branches of thyroid axis.

Subclavian artery.

Brachial plexus.

} Clavicle. }

Below.

Cephalic vein.

Behind.

Internal mammary artery—sternal half.

Subclavian vein,

External jugular vein.

Innominate vein at the right.

— " " " " "

— " " " " "

— " " " " "

— " " " " "

— " " " " "

— " " " " "

— " " " " "

— " " " " "

— " " " " "

— " " " " "

The intimate association of the clavicle to important arteries, veins, nerves, etc., surrounds its removal with great difficulties and dangerous complications; especially, if it be attempted for a well-developed malignant or other morbid growth. With the patient in the proper position for the operation, the foregoing plan shows the important anatomical relations of the clavicle.

The whole or a portion of the bone can be removed. If the whole bone is to be removed, it may be raised by its scapular extremity, or divided at its middle, and each half taken away separately.

Excision of the entire Clavicle.—Anæsthetize and place the patient in the position above described; if the operation be for necrosis, make an incision the whole length of the bone parallel with its long axis. If necessary, a short transverse incision is added; expose the clavicle, divide the periosteum, and with the elevator enucleate the diseased bone from the surrounding tissues. The clavicle can be divided through the center and each half removed separately, or the acromial end can be detached and the entire bone raised from without inward. In either instance, the articular ends and their connecting ligaments should be preserved if possible.

If the involucrum be weak and liable to bend or break after the bone is removed, the shoulder must be held outward, backward, and upward by means of the method employed in treatment of fracture of that bone. The indirect method of sequestrotomy can be performed in some instances.

If the operation be for the removal of a tumor of this bone, especially of one acutely malignant, and involving any considerable portion of its surrounding tissues, it is certain to be an exceedingly tedious and bloody procedure.

The smaller the size of the tumor and the less its vascularity, the easier will be its removal.

Operation.—Make an incision in the long axis of the bone, from its sternal to its acromial extremity; if necessary, this is crossed by a vertical incision, extending from the posterior border of the sternomastoid muscle to the upper third of the pectoralis major muscle. Make these incisions as deep as the nature of the growth will permit, and dissect the flaps from the tumor; separate the insertions of the deltoid and the trapezius muscles on a director, cutting them either with a knife or strong curved scissors, being careful to avoid the cephalic vein which lies at the inner border of the deltoid muscle. Divide the coraco- and acromio-clavicular ligaments; raise the acromial extremity of the clavicle, and thus elevate the morbid growth, which should then be cautiously separated from the surrounding tissues. The nearer the approach to the sternal extremity of the clavicle, the greater will be the necessity for caution, since the growth may be connected with the important structures located in this situation;

finally, divide the insertions of the sterno-mastoid and the pectoralis major muscles, and rhomboid ligament, and carefully disarticulate the sternal extremity while the tumor is lifted upward and inward together with the clavicle.

Either extremity of the clavicle may be excised by making a crucial incision down to the bone corresponding to the portion to be removed, exposing and dividing it with a chain-saw, and removing the fragment with the same precautions as before described.

The results of the operation of complete excision have been quite favorable; of thirty-four cases, six proved fatal. Exhaustion, due to loss of blood, erysipelas, etc., were the principal causes of death.

Partial excisions give a death-rate of about eight per cent from all causes.

During the operation the entrance of air into the veins of the neck is especially to be guarded against.

Excision of the Scapula.—This bone is excised on account of gunshot injuries, necrosis, and morbid growths.

The whole bone may be removed, or its body, angles, and spine may be removed separately. Its contiguous anatomy is extensive, but not of the dangerous character of that associated with the clavicle. To its spine, borders, and surfaces numerous and powerful muscles are attached.

At the upper border are found the supra-scapular vessels and nerves; the posterior scapular artery passes down its vertebral border; while at the axillary border the subscapular, and dorsalis scapulæ arteries, and even the axillary artery itself, and the brachial plexus, are in close connection with the bone.

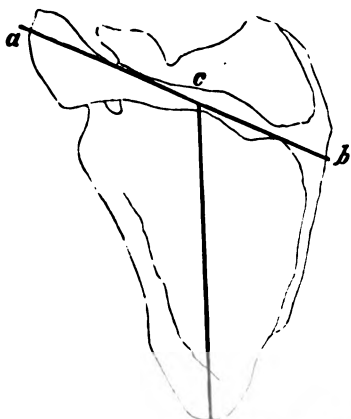

FIG. 249.—Excision of entire scapula.

Excision of the entire Scapula (Fig. 249).—Make an incision from the tip of the acromion process along the posterior border of the scapula, *a, b*. Join it by a second incision extending from near the middle of the spine, *c*, to the inferior angle of the bone; dissect up and turn aside the flaps thus formed.

Divide the attachments of the deltoid and trapezius; disarticulate the acromio-clavicular articulation; secure the subscapular artery; divide

the ligaments and tendons around the glenoid cavity; raise the coracoid process and carefully sever its ligaments and muscular attachments; raise the scapula by the inferior angle and divide its remain-

ing muscular attachments with a knife or strong pair of scissors, carefully avoiding the subscapular and posterior scapular vessels; tie all the bleeding points; wash with an antiseptic solution; thoroughly drain and close the wound, and dress antiseptically. Sir W. Ferguson and Mr. Pollock thought it better to raise the vertebral border of the scapula first, that the subscapular artery might be the better controlled. Spence thought that the anterior angle should be raised first, the better to control the subclavian artery. All danger of hemorrhage during the operation is easily obviated by pressure on the subclavian artery above the clavicle by means of a short crutch or a large key, also by direct pressure on the subclavian after the anterior angle of the scapula is elevated.

The results of this operation are good. Of sixty-six cases of complete excision, fourteen died. The rate of mortality from the operation is about eight per cent; it is greater when due to traumatic causes than when due to disease.

Excision of the Body of the Scapula (Fig. 250).—Make an incision the whole length of the spine, *a, b*; begin a second incision at the posterior superior spine, and carry it along the posterior border of the bone to its inferior angle, *c, d*; dissect the resulting triangular flaps from their corresponding fossæ, carefully avoiding the supra-scapular artery and nerve; saw through the acromion process close to the body, divide the muscles attached to the anterior and superior borders of the scapula; raise the bone upward and saw through the anterior superior angle behind the coracoid process, turn the bone outward and sever its posterior connections with a knife or strong scissors.

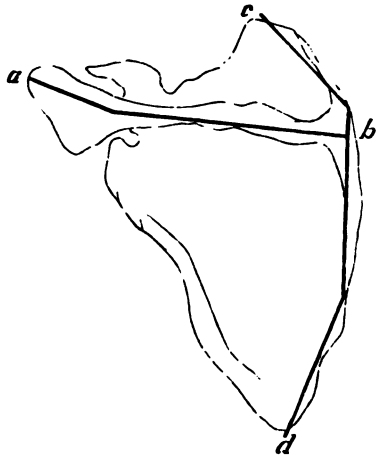

FIG. 250.—Excision of body of scapula.

The Acromion Process and Angles of the Scapula may be separately removed. To remove the former, make an incision, which may be curved if necessary, along its upper border—expose the process, divide the muscles attached to it, and with a pair of bone-forceps remove the desired amount. This process can be removed by making a curved or crucial incision over it; exposing its upper surface, dividing the muscles connected therewith, disarticulating the clavicle, and removing the requisite amount with a chain-saw.

To remove an angle, make a V-shaped incision over it, dissect off

the flaps, separate the muscles from the bone, and divide the exposed portion with the bone-forceps.

Subperiosteal Excision of the Scapula (Ollier) (Fig. 251).—Make an incision from the outer extremity of the acromion process along the spine of the scapula to its posterior border, *a, b*. Make a second incision from the posterior superior angle of the scapula along its posterior border, crossing the former, to the inferior angle, *c, b, d*. Sever the muscular attachments to the acromion process and spine; divide the periosteum at the posterior border of the scapula between the attachments of the rhomboideus major and infra-spinatus muscles, and separate it from the infra-spinous fossa. Remove the muscular attachments of the superior border of the scapula. The periosteum is then raised from the supra-spinous

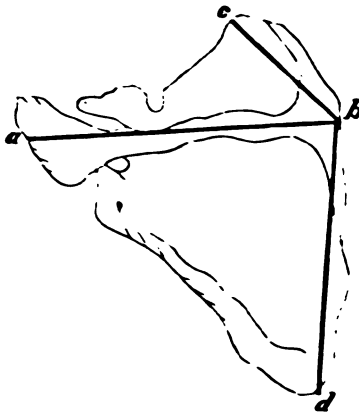


FIG. 251.—Subperiosteal excision.

fossa, being careful to not injure the supra-scapular vessels, as they pass in close contact with the supra-scapular notch; disconnect the muscles attached to the borders of the scapula, closely hugging the bone; raise it upward by its inferior angle, denude the subscapular fossa, leaving its periosteum connected with the subscapularis muscle; liberate the posterior border, allowing its cartilaginous portion to remain—when present. Turn the bone upward and forward, and remove the remaining periosteum from its under surface up to the neck of the scapula, and divide the neck with the chain-saw. If the extent of the disease will not permit this, the neck can be enucleated, leaving the ligaments connected with the periosteum.

Excision for Malignant Growths.—Make an incision from the posterior superior angle to the lower border of the tumor, carrying it downward, forward, and inward, with the convexity posteriorly. A second incision, beginning five inches or so in front of the preceding incision, is carried downward and backward, crossing the other at or near its middle, and terminating at the lower border of the growth. The flaps are then reflected from the tumor, and the muscular attachments separated from the spine of the scapula, and the acromion process through behind the clavicle; expose the superior borders of the scapula, and free them of their attachments to the bone upward and forward by its posterior border, separating the serratus magnus muscle from it; free the neck of the bone and divide the neck of the bone with a saw, if prac-

ticable. When necessary, complete the entire removal by disarticulation.

It is not possible to lay down definite rules to govern the number, extent, or direction of the incisions; each of these must depend on the size and situation of the growth, together with the amount of bone to be removed, and the ease and safety with which it can be done. After the removal, arrest hemorrhage, provide good drainage, unite the cut surfaces, and dress antiseptically.

The results of the operation are flattering: nineteen per cent died from entire removal of the scapula due to disease. The mortality was twenty-six per cent in partial excisions for disease, and about twenty per cent when done for injury.

Excision of the Humerus.—The humerus can be removed entirely or in part.

The Important Associated Anatomy.—The insertions of the muscles acting upon the upper end of the bone, the course of the superior profunda and circumflex arteries, the relations of the circumflex, musculo-spiral, and ulnar nerves; the points of insertion of the ligaments of the joints, together with the connections of the important muscles, must be carefully considered before attempting the operation. This operation has been done for the relief of old dislocations, caries, necrosis, gunshot injuries, arthritis, malignant disease, etc.

Excision of the Upper End of the Humerus (Langenbeck).—Place the patient upon the back, with the shoulders raised; make an incision about four inches in length downward from the anterior border of the acromion process, close to its articulation with the clavicle, in the line of the bicipital groove (Fig. 252). The bone at this region is quite superficial; liberate the long head of the biceps tendon from the groove, by carrying the point of the knife upward in the groove at the outer side, through the capsule to the acromion, and raise the tendon out of the groove (Fig. 253); rotate the arm outward, and divide the subscapular tendon; divide the inner portion of the capsule; rotate the arm inward,

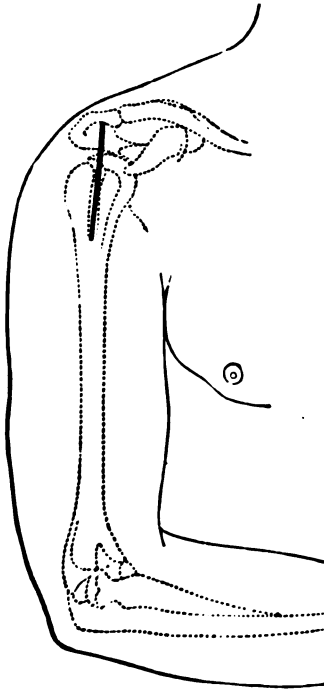


FIG. 252.—Excision of upper end of humerus.

and cut the external rotators

and posterior portion of the capsule (Fig. 254); force the head of the bone through the opening in the soft parts (Fig. 255), seize it with a strong pair of forceps, divide the inferior portion of the capsule, and remove the head of the bone with a chain- or a small straight saw.

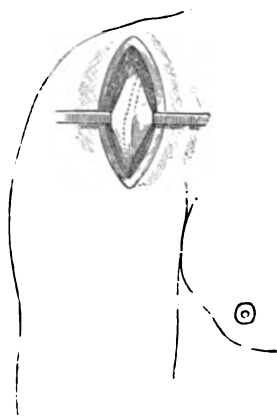


FIG. 253.—Raising tendon.



FIG. 255.—Sawing head of humerus.

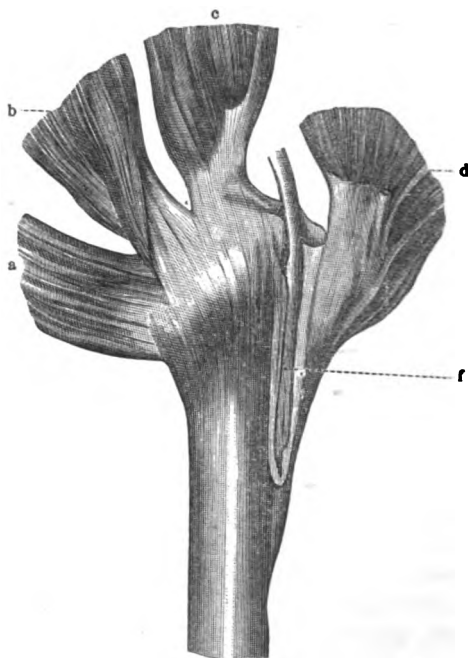


FIG. 254.—Attachments to tuberosities of humerus. *a.* Teres minor muscle. *b.* Infra-spinatus muscle. *c.* Supra-spinatus muscle. *d.* Subscapularis muscle. *f.* Tendon of long head of biceps muscle in the groove.

Subperiosteal Excision of Head of Humerus (Langenbeck).—Expose the bicipital groove and split up the capsular ligament as in the preceding operation. Divide and raise the periosteum from the inner border of the bicipital

groove, passing inward and separating it together with the subscapularis and the fibrous capsule from the lesser tuberosity. Rotate the humerus outward and complete the separation to the required extent with the elevator and knife; rotate the arm inward, displace the tendon of the biceps to the inner side of the head of the humerus, and separate the periosteum from it in connection with the capsule and the insertions of the external rotators, being very careful not to sever its connection with the bone below. To force the head of the bone

through the external opening is practically impossible without destroying the periosteal connections; it is necessary, therefore, to divide the bone in its position with a chain or narrow-bladed saw.

Partial removal of the upper extremity of the humerus is often necessary on account of disease or injury. The variety and extent of the incisions to reach the part must be governed by the amount of the disease.

Either the vertical, V- or U-shaped incision can be selected as best suits the exigencies of the case.

Excision of the Glenoid Angle of the Scapula.—This operation is only applicable to those conditions of injury or disease that are limited to the glenoid articular surface of the scapula. If a penetrating wound exist, its course should be followed to reach the bone; if not, then a curved incision is made around the posterior border of the acromion process dividing the fibers of the deltoid, and exposing the posterior and upper surface of the joint (Fig. 256). A second incision is then made, commencing at the center of this one, at the upper margin of the glenoid cavity, and, passing downward through the capsule,

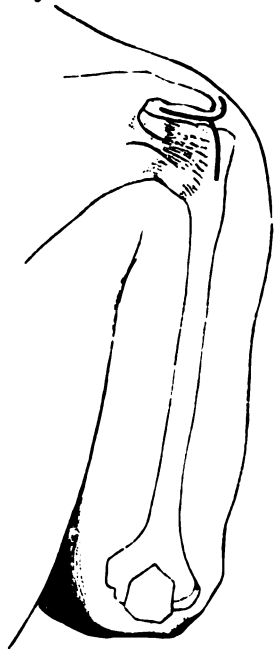

FIG. 256.—Excision of glenoid angle.

upon the center of the greater tuberosity, between the tendons of the supra- and infra-spinatus muscles through the deltoid in the direction of its fibers. Open the wound widely by means of retractors and divide the tendons of the biceps at their origin; separate the periosteum from around the neck of the scapula, if possible leaving the attachments of the capsular ligaments. Cut through the exposed bone with a chain-saw, and remove it carefully to avoid injury to the periosteum.

Excision of the Shaft of the Humerus.—In this operation, unless great caution is observed, the musculo-spiral nerve and the superior profunda artery will be injured in their course along the musculo-spiral groove, as well also as the circumflex nerves and vessels, if the incision be extended (Fig. 257) upward too far. The upper portion of the shaft is easily exposed by making an incision of sufficient length through the outer surface of the deltoid, commencing at its lower third and dividing it carefully upward, to avoid the circumflex nerve and artery; the bone is then denuded of its periosteum, or the morbid growth connected with it is circumscribed and removed. If the lower portion of the shaft is to be operated upon, make the incision along

the outer border of the brachialis anticus muscle, carefully avoiding the musculo-spiral nerve ; expose the bone and remove it as before.

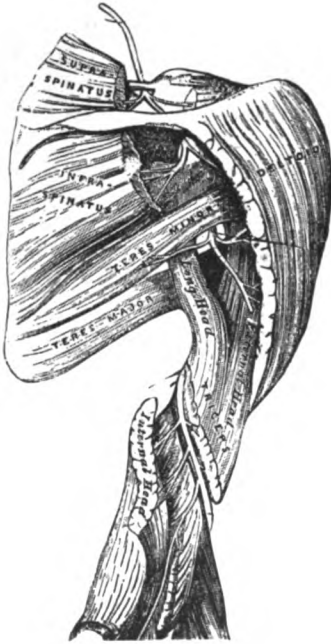


FIG. 257.—Musculo-spiral and circumflex nerves.

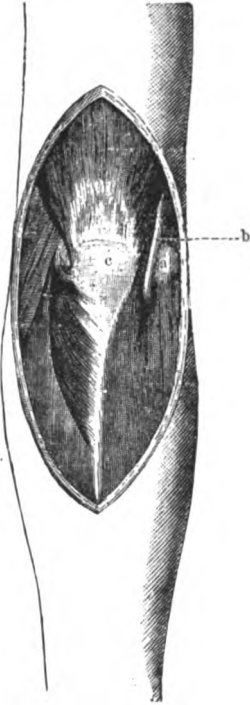


FIG. 258.—Relation of ulnar nerve to elbow-joint. *a.* Inner condyle of humerus. *b.* Ulnar nerve. *c.* Olecranon process.

Excision of the Lower Extremity of the Humerus.—The relation of the ulnar nerve (Fig. 258, *b*) to the internal condyle, *a*, and of the brachial artery to the anterior surface, must not be forgotten. Make an incision on the posterior and external surface of sufficient length to thoroughly expose the bone ; elevate the periosteum and divide the bone with a chain-saw ; pull the upper end of the fragment downward and disarticulate it from without inward.

If it be necessary to *remove the entire humerus*, make incisions as if to remove the upper and lower portions, observing the same precautions relative to the anatomy of these parts. The musculo-spiral nerve in this operation is to be most cautiously avoided.

In all the preceding operations, substantially the same after-treatment is required : arrest the hemorrhage, irrigate the exposed surfaces with an antiseptic solution, provide drainage, close the lips of the wound, envelop the entire limb with antiseptic dressing, and place it

upon a splint affording an easy support at the proper angle. Extension is often necessary to maintain the limb at a suitable length during the healing process.

The results depend much upon the nature of the injury, the period of the operation, and the employment of antiseptics. Of gun-shot wounds of the shoulder-joint requiring excision, about thirty-five per cent die; the rate of mortality being increased when the inflammatory stage exists at the time of operation. When excised for disease eighty-two per cent recovered, of which the limb was useful in three fourths of the cases. Thorough antiseptics will lessen this death-rate at least fifty per cent.

Excision of the Elbow-Joint (Hüter).—With the forearm extended make a slightly curved incision about an inch in length down upon the tip of the internal condyle, and carefully separate the muscular and ligamentous at-

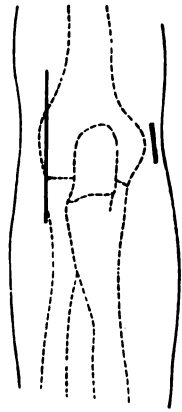


FIG. 259.—Hüter's incision.

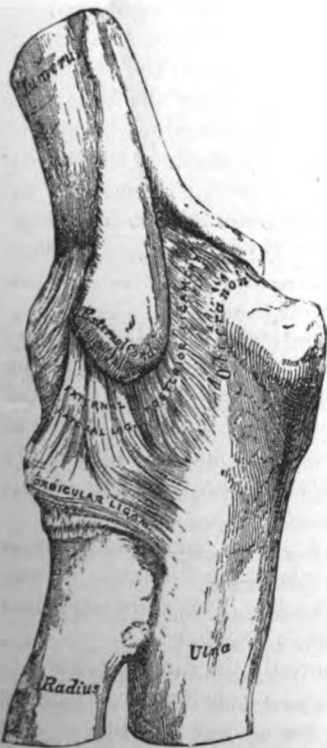

FIG. 260.—Ligaments of elbow-joint.

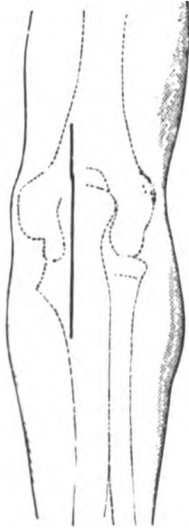


FIG. 261.—Langenbeck's incision.

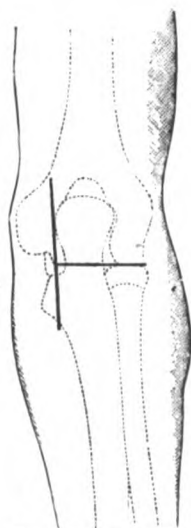


FIG. 262.—Liston's incision.

tachments to the condyle; make a second longitudinal incision from three to four inches in length down to the head of the radius (Fig. 259). Draw aside the soft parts and cut the external lateral and orbicular ligaments (Fig.

260). Expose the head of the radius and cut it off with a saw or bone-forceps. Separate the capsular ligament from its attachments on the anterior and posterior surfaces of the humerus; force the extremity of the bone out of the external wound. This movement admits of its division, and at the same time raises the ulnar nerve from its bed and away from the bone. Saw off the lower end of the humerus, and carefully expose and remove the olecranon.

Subperiosteal Excision of Elbow-Joint (Langenbeck).—Make a longitudinal incision down to the bone, three or four inches in length, a little to the inner side of the middle of the olecranon process, about two thirds of its length extending below the tip of the olecranon, carefully avoiding the ulnar nerve (Fig. 261). Remove the periosteum from the portion of the olecranon process and ulna at the inner side of the incision. Separate by short parallel incisions the attachments of the inner half of the triceps tendon to the olecranon process. Push the tissues at the internal condyle, together with the ulnar nerve, inward toward the tip of the condyle, and elevate the periosteum from the inner condyle sufficiently to separate the internal lateral ligaments and the attachments of the muscles from the bone, and leave them connected with the periosteum. The liberated tissues are now permitted to return to their former position, and the outer portion of the tendon of the triceps is drawn outward and disconnected from the olecranon process by short transverse incisions, closely hugging the bone and allowing it to remain continuous with the periosteum which is reflected upon the inner surface of the olecranon and shaft of the ulna; expose the external condyle by separating the capsular ligament at its attachment, above the trochlea and capitulum; the tissues, including the detached periosteum and tendon of the triceps, are separated well from the bone by retractors. Flex the forearm and force the extremities of the bones through the opening; saw off the head of the radius, then the lower end of the humerus, and finally the olecranon process. It is necessary to remember in all cases of excision about the elbow-joint, to respect the insertions of important muscles, such as those of the brachialis anticus, biceps, triceps, etc. To unnecessarily destroy the power of one of these, is to be guilty of an unpardonable oversight. Various forms of incisions, other than the longitudinal, have been employed; as the H, with the horizontal portion corresponding to the articulation; the T, with the horizontal on a line with the condyle; U-shaped or semilunar, with the convexity downward.

Excision of the Elbow-Joint by the T-Shaped Incision (Liston, Fig. 262).—Flex the elbow to an obtuse angle, the operator facing its posterior surface, open the capsule between the olecranon process and internal condyle by a longitudinal incision about four inches in length along the inner border of the olecranon, dissect and draw the soft parts over the internal condyle with the thumb (Fig. 263), increasing

the flexion gradually till the condyle is fully exposed, divide the internal lateral ligament, extend the arm and carry a transverse incision

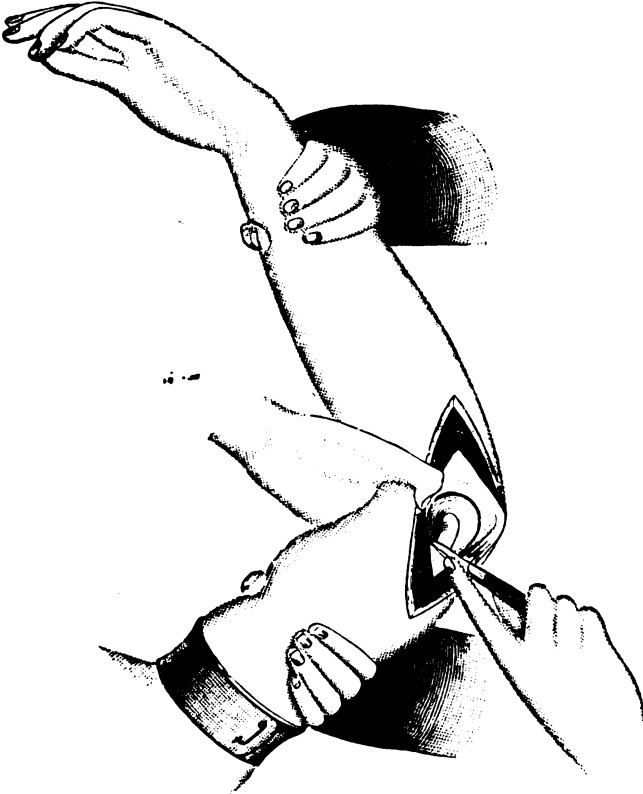


FIG. 263.—Exposing internal condyle.

from the point of articulation of the radius with the humerus directly across to the center of the former incision.

The periosteum on the inner surface of the olecranon process and ulna is raised and left connected with the tendon of the triceps, which is carefully separated from the bone. Open the flaps wide and divide the external lateral ligament, flex the forearm, and the articular surfaces will separate. Seize and saw off the lower extremity of the humerus, the olecranon process, and finally the head of the radius.

Results.—Excision of the elbow-joint has been performed with such good success that its high rank is thoroughly established. Although when due to injury the rate of mortality is about twenty per cent, when due to disease it is less than eleven per cent. Partial excisions are followed by better results, so far as motion is concerned, than complete excisions.

It would appear that the saving of the synovial membrane exerts a more conservative influence upon the usefulness of the joint than the saving of bone; provided, of course, that the bony insertions of the muscles acting directly upon the joint be respected. The amount of bone removed will determine the usefulness of the joint. If too little, the movement will be limited and insufficient; if too great, it will dangle, and be of little use except for prehension. If the operation be for traumatism, remove the fragments; if for disease, remove the diseased portion; in both conditions trim the extremities of the bones so as to afford symmetrical support to opposed bony surfaces. The wounds should be washed with a suitable antiseptic solution, closed with proper drainage, dressed antiseptically, and kept extended until repair is begun; when the limb should from time to time be placed at various angles for a day or so. By this course the newly formed tissue will thereafter conform more readily to the various movements of the joint.

Excision of the Ulna.—An incision is made along its posterior surface of sufficient length to expose the diseased bone, the periosteum is pushed aside, and section is made at the requisite point and the diseased bone is removed.

If it be a partial excision of its upper extremity, expose that portion by an incision in the same line, as for removal of the entire bone, elevate the periosteum, leaving, if possible, the attachments of the brachialis anticus and triceps muscles, and avoid the ulnar nerve, at the inner condyle.

Excision of the Radius.—Make an incision, extending from the styloid process of the radius, along the outer border of the anterior surface of the forearm to the radio-humeral articulation, through the integument and fascia. Seek the outer border of the supinator longus, pass upward, separating it from the flexor longus pollicis, and going down to the bone, divide the supinator brevis, also the periosteum in the long axis of the radius; elevate the periosteum; divide the bone in the center, and remove each half separately. The insertion of the biceps and pronator radii teres should be carefully preserved. If an extremity of the bone is to be excised, expose the portion to be removed by an incision made in the same line as the preceding; raise the periosteum with equal caution, and remove the diseased portion.

The results of this operation are good; a patient seldom dies, and fair use of the extremity is secured.

Excision of the Lower Extremities of the Bones of the Forearm (Bourgary).—Make an incision two inches in length along the inner border of the ulna on the dorsal surface, from just below the apex of the styloid process (Fig. 264). Divide the periosteum at the interspace between the extensor and flexor carpi ulnaris muscles in the same line, and reflect it from the dorsum of the bone inward to the interosseous membrane. A second longitudinal incision is made along

the outer side of the radius from just below the apex of the styloid process two or three inches upward; the periosteum is divided through the same incision, the attachment of the supinator longus separated, and the periosteum raised on the dorsal surface together with the sheaths of the extensor tendons.

The periosteum is then elevated from the like portions of the palmar surface of the lower ends of both bones around to the interosseous membrane. Protect the soft parts carefully while the bones are being sawn through. The operation can be extended to the bones of the carpus if necessary, by continuing the lateral incisions downward.

Excision of the Wrist-Joint.—This joint properly consists of the radius, articulated with the outer two of the first row of carpal bones. In cases where excision is necessary, it is not usual to find the disease or injury limited entirely to these structures. It, therefore, becomes necessary to remove all bony structures involved, even though they include the two rows of carpal and the contiguous extremities of the metacarpal

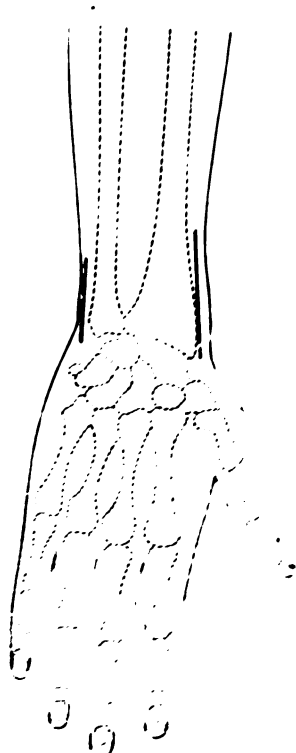


FIG. 264.—Lateral view of wrist.

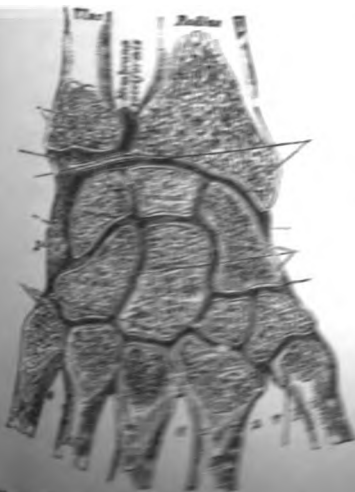


FIG. 265.—Dorsal view of carpal bones.

bones. The intimate relation existing between the carpal bones and the continuity of their synovial surroundings, renders them especially liable to progressive disease as well as to inflammatory processes (Fig. 265). They are intimately bound together by strong ligaments admitting of but limited movement between their surfaces (Figs. 266 and 267). Since these bones are in close relation to the tendons of important muscles, the sheaths of which should be scrupulously preserved together with themselves, this operation is surrounded with difficult and tedious details.

All diseased or detached bone

should be removed. If a portion of a carpal bone be diseased, it is better that the entire bone be removed. The insertions of all muscles acting on the carpus should be preserved, if possible.

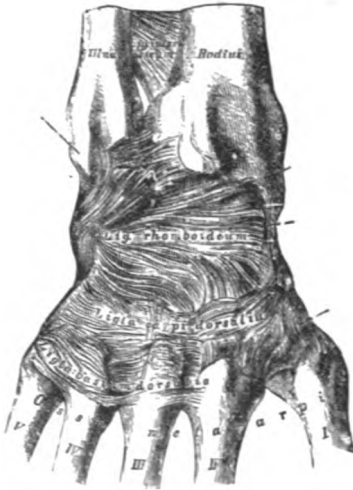

FIG. 266.—Ligaments of dorsal surface of carpus.

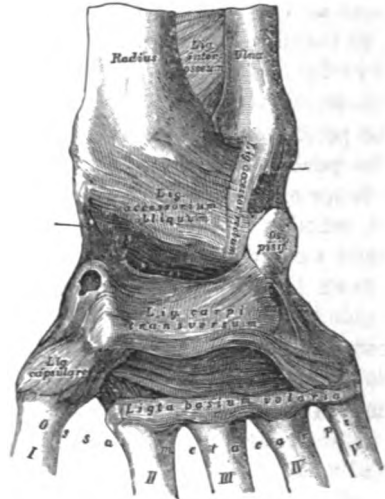


FIG. 267.—Ligaments of palmar surface of carpus.

A tendon is not to be divided, except it forms an insurmountable obstacle to the incision necessary to the removal of the bones, and it should afterward be sutured. If the tendons be divided at a distance from the immediate seat of the operation, and subsequently sutured, the chances of union will be enhanced. The radial and ulnar arteries and the branches associated with the carpus should be cautiously avoided.

Complete Excision of the Wrist-Joint (Langenbeck).—Place the forearm and hand of the patient with the palm downward on a table of convenient height for the operator and his assistant. An incision is then made through the integument, beginning at the middle of the metacarpal bone of the index-finger at its ulnar border, and extending longitudinally to three fourths of an inch above the lower extremity of the radius, at its middle (Fig. 268). The deeper course of the incision passes to the radial side of the extensor indicis without opening its sheath, upward, over the tendon of the extensor carpi radialis brevis, to the inner side of its insertion; then, if the tendons going to the index-finger be pushed to the ulnar side, the incision extends upward to the beginning of the tendons of the extensor secundi interodii pollicis and the extensor indicis, dividing the lower portion of the posterior annular ligament. Draw the tissues apart with suitable retractors and separate from the bone with a periosteal elevator the

fibrous sheaths of the extensors of the carpus on the posterior surface of the radius; the insertion of the supinator longus muscle, and the annular and capsular ligaments are then disconnected and drawn to the radial side together with the periosteum; the tendons, ligaments, and periosteum on the posterior surface of the ulna are separated in the same manner and drawn to the ulnar side. Open well the radio-carpal joint, flex the carpus and expose the articular surfaces, and separate the bones of the first row from their connection with each other, leaving the periosteum if possible. Liberate the scaphoid from the trapezium and trapezoid, the semilunar from the os magnum, and the cuneiform from the unciform; lift them out, leaving their periosteum—if possible—together with the trapezium and pisiform bones. The bones of the second row are taken out after severing the connections between the trapezium and trapezoid, and the heads of the metacarpal bones. The extremities of the radius and ulna can now be forced through the wound, carefully exposed and sawn off, avoiding the radial and ulnar vessels. The divided tendons should be sutured and the resulting wound treated by antiseptic measures. Continuous extension from the fingers should be early and constantly employed during the after-treatment.

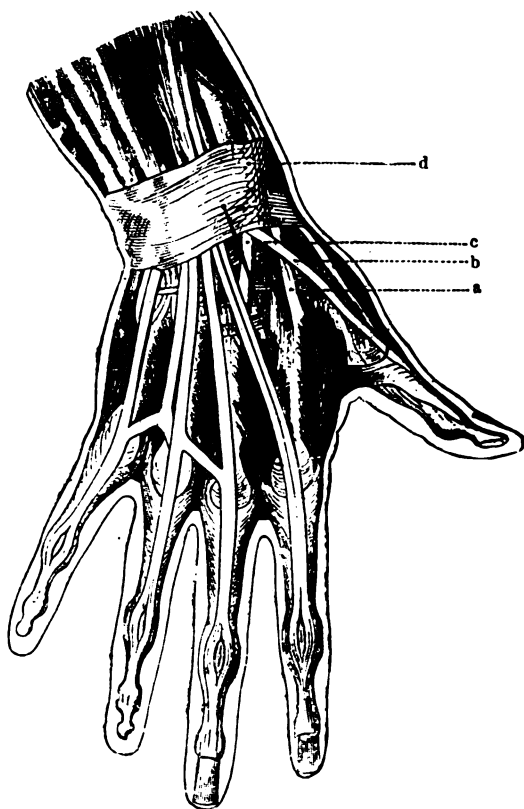


FIG. 268.—a. Extensor carpi radialis longior. b. Extensor longus pollicis. c. Extensor carpi radialis brevior. d. Posterior annular ligament. f. Langenbeck's incision.

There are other incisions intended to meet the indication (Lister): Begin the incision on the dorsal aspect of the radius, opposite the styloid process, and carry it toward the inner side of the metacarpal articulation of the thumb parallel with the secundi internodii pollicis

tendon (Fig. 269, *a*). When at the radial border of the second metacarpal bone, carry the incision along one half the length of that bone ;

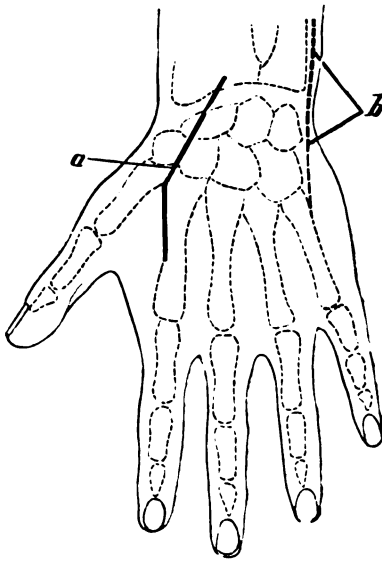


FIG. 269.—Lister's incisions.

separate the soft parts on the radial side, divide the tendon of the extensor carpi radialis longior at its insertion, raise it, together with the extensor carpi radialis brevior and secundi internodii pollicis tendons, open the wound well, and disconnect the trapezium from the remaining bones, which are to be taken away. Extend the carpus and separate the soft parts on the dorsum at the ulnar side of the incision.

Make a second incision along the *anterior* and internal border of the forearm on the inner side of the flexor carpi ulnaris, beginning it about two inches above the styloid process and extending it to the middle of the metacarpal bone of the little finger (Fig.

269, *b*). Expose the dorsum of the ulna, divide the tendon of the extensor carpi ulnaris at its insertion, separate it from the groove in the ulna, raise the extensors of the fingers from the carpus, leaving their attachments to the radius intact ; expose the anterior surface of the ulna, hugging the bone closely ; separate the pisiform bone with the flexor carpi ulnaris ; flex the hand and separate the flexor tendons in the same cautious manner ; divide the remaining ligaments connecting the bones of the forearm with the carpus ; separate the process of the unciform bone, also the carpus from the metacarpus with cutting forceps ; expose the extremities of the radius and ulna through the ulnar incision, remove with the saw or forceps the diseased portions, carefully avoiding the grooves for the passage of the tendons ; remove the trapezium without injury to the tendon of the flexor carpi radialis. All articular surfaces of bones—metacarpal bones, pisiform, and between lower extremities of radius and ulna—should be removed, as well as all diseased portions of bone. Many other incisions may be made through which to effect the removal of the wrist-joint ; but only such as admit of it being done through longitudinal incisions are advisable, since transverse incisions may sacrifice the tendons which impart usefulness to the remaining portion of the carpus.

All hemorrhage having ceased, suture the divided tendons, close the wound, allowing the most dependent incision to remain open for

drainage. Envelop the limb in antiseptic dressings, causing the whole to be properly supported by a splint. The subsequent treatment consists in cleanliness, extension, and passive motion.

Results.—Ten per cent die after excision for disease, and fifteen per cent for gun-shot injuries without antiseptic treatment. In about thirty-three per cent of those who recover, the operation has been of no service ; in about eleven per cent, entirely satisfactory ; in the remainder, useful. The prognosis for usefulness is better when excision is performed for injury than for disease.

Excision of the Metacarpo-phalangeal Joints.—This operation can readily be done by making an incision about one inch and a half in length at one side of the extensor tendons and along the dorsum of the bones composing the joint. The tissues in contact with the bone are carefully raised and turned aside, the joint exposed, and the requisite amount of bone removed by the chain-saw, cutting forceps, or dental engine.

Excision of the Phalangeal Joints.—These articulations may be approached either through a longitudinal incision made along the side of the joint, or by a curved incision at the same situation with the convexity downward. In either instance separate the tissues carefully down to the extremities of the bones, which, when properly exposed, can be caused to protrude through the incision by lateral flexion and the extremities can then be removed.

The after-treatment consists in placing the fingers in an immovable position properly protected by an antiseptic dressing, and when repair begins passive motion is made and continued until the recovery is complete.

Excision of the Joints of the Lower Extremities.—The phalangeal joints of the tarsus are removed in a similar manner to those of the upper extremity.

The Metatarso-phalangeal Joints are removed through longitudinal incisions, made over the dorsal surface of the bones constituting the joints, at either side of the extensor tendons, which are pushed aside together with the remaining surrounding soft parts, the bones exposed, and their extremities severed by the chain-saw or bone-forceps. The removal of the metatarso-phalangeal articulation of the great toe can be and often is done by a different method. Make a curved incision with the convexity downward, of sufficient length to

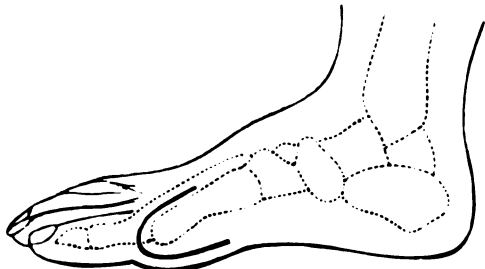


FIG. 270.—U-shaped incision.

freely expose the bones to be removed, at the inner side of the joint, its center corresponding to the joint center (Fig. 270). Dissect the soft parts from around the bones, carefully pushing aside the tendons; expose and remove the necessary amount of the articulation with a chain-saw or forceps. If the operation be done for the correction of the deformity caused by prominence of the head of the metatarsal bone, enough bone should be removed from its extremity to permit the easy return of the displaced toe to its natural position; where it is to be retained quietly till repair is well advanced, and then passive motion is to be commenced.

The Tarso-metatarsal Joints can be excised through a straight incision or by raising a semilunar flap over their dorsal surfaces, avoiding division of the extensor tendons, which are raised and pushed aside, while the dorsal ligaments connecting the bones are divided and the joint cavity exposed by forced flexion, after which the bones of the distal row can be divided with a saw or bone-forceps. The corresponding extremities of the tarsal bones can be treated likewise.

Tarsal Joints.—When separate tarsal joints become involved by disease or traumatic violence, they can be removed by making an incision over the injured or diseased portions, often following in the line of the course of the violence, or in the tracks of sinuses leading from the disease.

This treatment is, however, better adapted to those joints having a limited synovial membrane, than to those where that membrane extends between several contiguous bone surfaces; in the latter case it is often better to remove the bones entire by aid of the chisel, saw, or gouge. In either instance curved incisions are preferable, provided they do not divide important tendons and vessels.

Excision of the Calcaneum.—It is important that as much as possible of this bone be saved, as it forms the posterior pillar of the arch of the foot, and also gives attachment to the tendo Achillis, which exerts a powerful influence in locomotion. When gouging fails to remove the diseased bone, excision becomes the final resort. A horse-

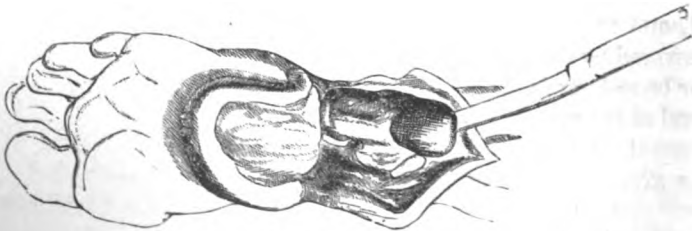


FIG. 271.—Excision of os calcis.

shoe-shaped incision is begun a little in front of the calcaneo-cuboid articulation and carried around the base of the os calcis along the side

of the foot to a corresponding point on the opposite side. This flap, with the knife hugging the bone, is dissected up, exposing the entire under surface of the os calcis (Fig. 271). A second perpendicular incision about two inches in length is then made through the middle of the tendo Achillis down to the preceding one; the resulting flaps are dissected off close to the bone, and the posterior articulation between the calcaneum and the astragalus opened, the ligamentous connections severed, together with those between it and the contiguous bones, the os calcis taken away, and any additional diseased bone removed.

Results.—A large majority of these cases recover with useful limbs.

Excision of the Astragalus.—This is accomplished through a semi-lunar opening, with the convexity downward, extending between the malleoli in front. The tendons of the extensor muscles must be carefully pushed aside; its ligamentous connections with the tibia, fibula, and os calcis are severed, finally, those with the scaphoid; then, with the foot extended, the bone is pulled from its site and the calcaneum placed in the resulting gap between the malleoli.

Results.—About seventy-five per cent of these cases recover with useful limbs.

Excision of the Ankle-Joint.—This articulation is a hinge-joint, having no lateral movement, except the foot is well extended, and then it is very limited. The indications calling for the operation are numerous, and should be well considered before it is attempted. As in all excisions those incisions which best preserve the tendons, vessels, nerves, and periosteum are to be adhered to, consequently those of a longitudinal character are the best to be employed.

Operation, Subperiosteal (Langenbeck).—Make an incision, about three inches in length, along the posterior border of the lower extremity of the fibula down to the bone (Fig. 272), carrying it forward in a hooked shape around the lower end and then upward along its anterior border about an inch. The periosteum is reflected from the bone together with the tissues in contact with it, thereby exposing the lower extremity of the fibula without opening the tendinous grooves of the peronei muscles (Fig. 273). The fibula is then divided at the upper end of the incision with a narrow saw, pulled outward, and the ligamentous attachments along its inner border and surfaces severed (Fig. 274), and the bone removed. An incision is then made about an inch and a half in length down to the bone,

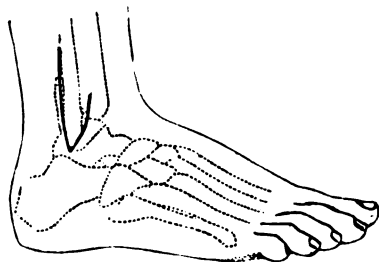


FIG. 272.—Excision of ankle-joint.

around the lower end of the inner malleolus (Fig. 275). A third and vertical one is next made about two inches in length, down to the

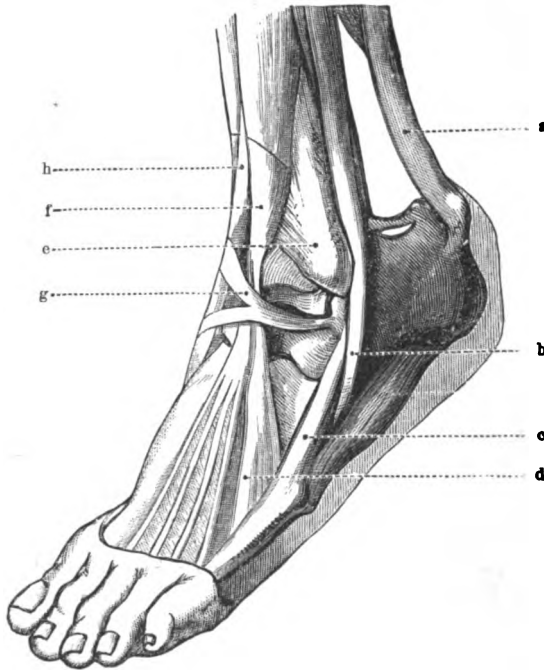


FIG. 273.—Outer side of ankle. *a.* Tendo Achillis. *b.* Peroneus longus. *c.* Peroneus brevis. *d.* Peroneus tertius. *e.* External malleolus. *f.* Extensor longus digitorum. *g.* Crucial ligament. *h.* Extensor longus pollicis.

bone through the center of the tibia, connecting with the semicircular one first made. The triangular flaps, including the periosteum, are turned aside with the elevator, using care to raise the sheaths of all tendons from their grooves (Fig. 276), and, pushing them aside, the tibia is divided at the upper end of the cut with a chain-saw, the fragment pulled outward with the forceps, freed from the interosseous membrane, and removed. If it be necessary to remove the articular surface of the astragalus, it can be done through either incision; the better, however, through the internal one, on account of the greater amount of room. If the excision is to be performed for chronic disease of the ankle and contiguous points, Vogt recommends, with the view of getting a more extended insight into the diseased portions, that an incision be made anteriorly, midway between the tibia and fibula, beginning about two inches above the articulation of the ankle and extending downward to

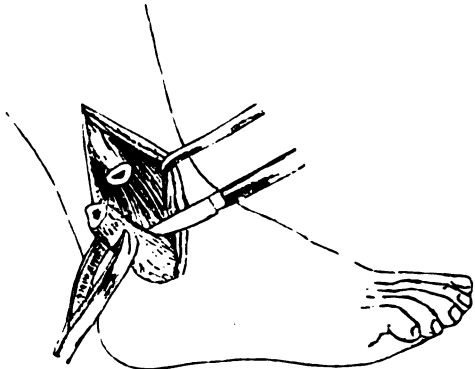


FIG. 274.—Removing lower end of fibula.

vertical one is next made about two inches in length, down to the bone through the center of the tibia, connecting with the semicircular one first made. The triangular flaps, including the periosteum, are turned aside with the elevator, using care to raise the sheaths of all tendons from their grooves (Fig. 276), and, pushing them aside, the tibia is divided at the upper end of the cut with a chain-saw, the fragment pulled outward with the forceps, freed from the interosseous membrane, and removed. If it be necessary to remove the articular surface

the medio-tarsal joint on the dorsal surface of the foot. The long extensor tendons are carefully drawn to the inner side, the tendons of the short extensor are divided and drawn to the outer side; the blood-vessels carefully tied between two ligatures and the capsule of the joint opened by a vertical incision; then detach the anterior ligament and expose the head and neck of the astragalus. If the superior astragalo-scapoid ligament be divided, the anterior and inner surfaces of this bone will be better exposed. A transverse incision is now made at right angles to the primary one, extending out-

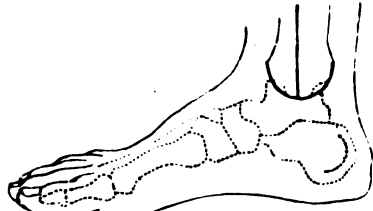


FIG. 275.—Internal incisions.

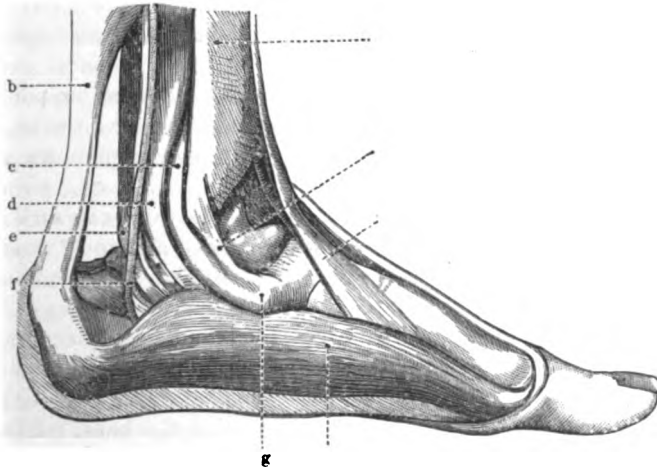


FIG. 276.—Inner side of ankle-joint. *a.* Tibialis anticus muscle. *b.* Tendo Achillis. *c.* Tibialis posticus muscle. *d.* Flexor longus digitorum. *e.* Flexor longus pollicis. *f.* Posterior tibial artery. *g.* Tuberosity of scaphoid bone.

ward to the tip of the external malleolus, leaving the tendons behind it intact. Divide the three fasciculi of the external lateral ligament close to the malleolus, also cut the interosseous or internal calcaneo-astragaloid ligament, force the articular surface of the astragalus outward, seize it with lion-tooth forceps, separate its remaining connections, and remove it. All diseased portions can now be easily examined and removed with a minimum degree of disturbance of the healthy tissues.

The method recently practiced by Busch is a very ingenious one, serving as it does to remove the diseased joint without impairing its tendons or their sheaths. It is open to the objection, however, of

weakening the arch of the foot, on account of the division of the long calcaneo-cuboid ligament and the plantar fascia.

Busch's Operation.—An incision is made down to the bone, across the sole of the foot, from one malleolus to the other; the sides of the joint are exposed by drawing the tissues forward. The os calcis is now sawn through from below upward and forward to the anterior margin of the calcaneo-astragaloid articulation, and pulled backward after the division of the opposing ligamentous structures. The entire astragalus can now be removed through the opening, and also the lower extremities of the tibia and fibula.

After the removal of the dead bone and the establishment of good drainage, the fragments of the os calcis are placed in position and held there by silver wire. The wound should be dressed antiseptically and no weight allowed upon the foot until the tissues are firmly united.

The after-treatment for excision of the ankle-joint consists in applying an immovable dressing around the joint under antiseptic precautions.

Results.—When done for disease, about ten per cent die; for gunshot wounds, about twenty-seven per cent; for other injuries, about thirteen per cent. The results are better from complete than from partial excision.

The prognosis for life is most favorable between one and fifteen years of age; most unfavorable between thirty and forty years. A large proportion of the recoveries from this operation results in a more or less useful limb; about nine per cent being useless.

Excision of the Bones of the Leg.—If it be desired to remove, by excision or otherwise, portions of either of the bones of the leg, the external incision is governed, as to its location and extent, by the situation and degree of the injury or disease of the bone. The bone should, however, be reached by the shortest course, which usually is *between* the individual muscles, rather than through their structures. After its removal, which should always be subperiosteal, the limb must be so confined as to permit the new structure, when completed, to fulfill the functions of its predecessor. The patient must not be permitted to bear weight on the limb till the new bone becomes firm, else distortion or fracture will occur.

Excision of the Knee-Joint.—This joint can be excised with comparative safety to the patient, and with a fair prospect of recovery with a useful limb. As in the preceding, the nature of the cause demanding the operation exercises a marked influence on the result.

The mortality, when due to disease, is about thirty per cent dependent upon injury, about forty per cent; when antiseptic precautions, the rate is less than fifteen per

If it be for a gun-shot injury, the mortality is increased to seventy-five per cent. The age of the patient is a consideration not to be underestimated; the results are best from five to ten years of age, when due to injury or disease; fifteen to twenty per cent die when done for gun-shot wounds. Partial excision gives a higher rate than complete, when due to disease. The removal of about three inches of bone insures the best prognosis for life. A lesser or greater amount increases the percentage of deaths. The removal of the patella, when not diseased, increases the rate of mortality slightly. The usefulness of the limb after the operation can be briefly summed up as follows:

When due to disease, fourteen per cent were perfect, forty-two were useful, and the remaining useless, of which eighteen per cent were amputated.

For injuries, about eighteen per cent were perfect, about sixty-five per cent useful, and about twelve per cent were amputated.

When due to gun-shot injuries, about sixty per cent were useful and twenty-four per cent were amputated, the remaining not accounted for.

When done for deformity, nineteen and a half per cent of the results were perfect, and about sixty-eight per cent of the patients had useful limbs; the remainder not reported.

It appears that the degree of usefulness does not depend upon the amount of bone removed.

The removal of the patella seemed to increase the degree of usefulness of the limb. In excision of the knee-joint for all causes, before the growth of the patient is completed, great care should be taken to preserve intact, if possible, the epiphyseal cartilage, especially of the lower end of the femur (Fig. 277). This precaution markedly lessens

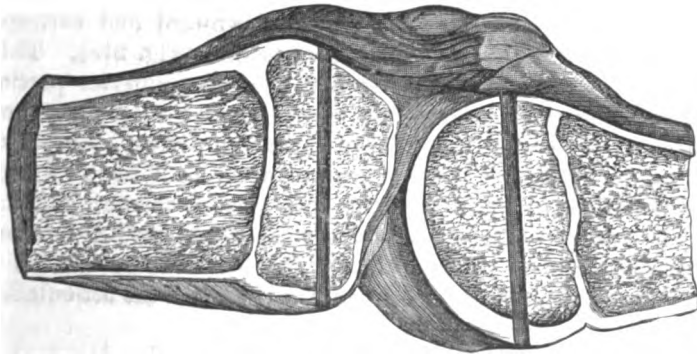


FIG. 277.—Epiphyseal cartilage and line of section in excision of knee-joint.

the failure of the development of the length of the femur upon the diseased side thereafter, because this epiphyseal junction provides for much more than its proportionate share of the growth of the length of the femur normally.

Contiguous Anatomy.—The articular vessels and those which occupy the popliteal space are the ones to be preserved. The latter are removed from all danger by the dense and unyielding ligamentum posticum Winslowii. The former can be avoided by limiting the incisions to the space between the origin and insertion of the lateral ligaments. There are two well-known methods of excising this joint: 1, the non-subperiosteal, or the ordinary method; and 2, the subperiosteal. The former is employed when the tissues are too extensively destroyed or diseased to admit of the saving of the periosteum.

Non-subperiosteal Excision of the Knee-Joint (Mackenzie).—Flex

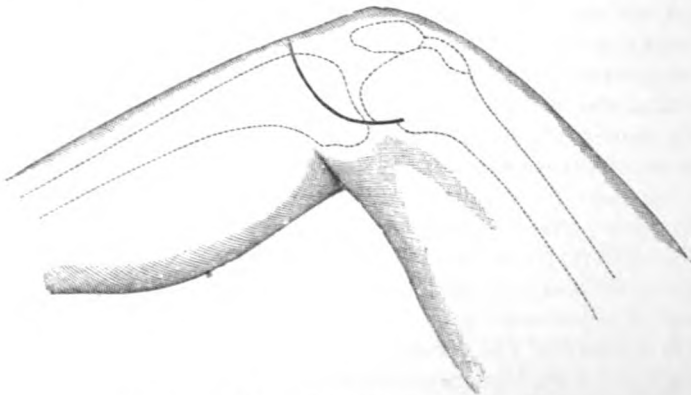


FIG. 278.—Mackenzie's anterior curved incision.

the leg to a right angle and make a curved incision, from the posterior border and upper portion of one condyle, around to the same point on the outer, with the convexity downward and corresponding to the insertion of the ligamentum patellæ (Fig. 278). This incision divides the tissues down to and opens the anterior portion of the capsular ligament. The limb should now be still more strongly flexed and the lateral and crucial ligaments divided. A retractor is then passed between the ligamentum posticum Winslowii and the posterior surface of the femur, the bone pushed forward and cut off on a line parallel with the articular surface, provided the extent of the diseased bone will admit of it. The head of the tibia is then treated in the same manner, being careful to avoid the articulation of the fibula.

In this operation it is better to remove the patella, since its means of attachment (the ligamentum patellæ) has been severed. All inflamed or degenerated synovial membrane should be dissected away.

The bony surfaces should be limited by passing two annealed iron or silver wires from the anterior to their posterior borders. The wound is then dressed with carbolic or a bichloride solu-

tion and a drainage-tube passed from side to side through the joint behind the bones; the whole enveloped in the antiseptic dressing, and the limb immovably fixed in a bracketed plaster splint, and properly suspended. In sawing through the exposed extremities of either bone, the line of incision can be made to include the whole of the diseased osseous tissue. If carious bone or an abscess cavity extend in an isolated manner into the sawn extremity of the femur or tibia, it can be scooped out and the resulting cavity drained by making an opening through its bottom with a bone-drill to the external surface of the limb, thereby saving the surrounding healthy bone-tissue and contributing to the length of the diseased limb. Deeply congested cancellous bone-tissue should

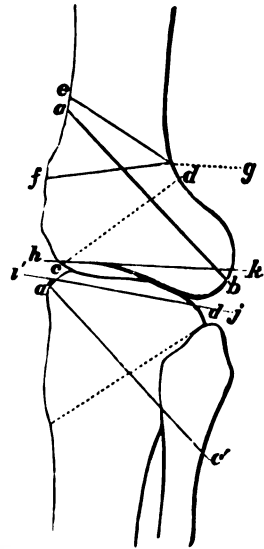


FIG. 279.—Corresponding lines of division.

be preserved if to remove it be to impair the epiphyseal cartilage, since it not infrequently makes a good recovery, but offers in addition thereto the only opportunity of preserving the normal growth of the femur. The line of section through the bone last sawn must correspond in direction to, and be parallel with, the line of section through the bone to which its sawn surface is to be applied (Fig. 279), otherwise the union of the sawn surfaces will cause an angular deformity. This applies more particularly to those cases where ankylosis in the straight position is sought. If for any reason it be thought better to ankylose the limb with slight flexion, then the thicker portion should be taken from the posterior parts of the bones.

Subperiosteal Excision of Knee-Joint (Langenbeck).—Extend the limb and make a curved incision on the inner side five or six inches in length, with the convexity downward, corresponding to the posterior border of the condyles, and its center to the articulation, commencing at the inner border of the rectus femoris and terminating below at the crest of the tibia

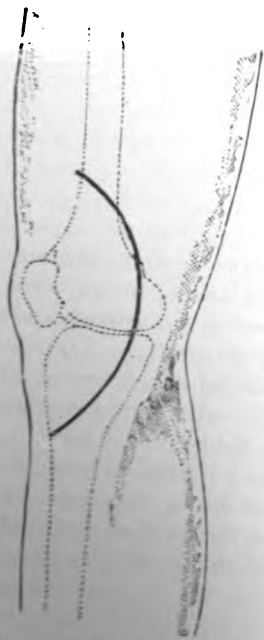

FIG. 280.—Langenbeck's incision.

ward, corresponding to the posterior border of the condyles, and its center to the articulation, commencing at the inner border of the rectus femoris and terminating below at the crest of the tibia

(Fig. 280). If the flap be now raised, the vastus internus muscle and the tendons of the adductor magnus and sartorius will be seen (Fig.

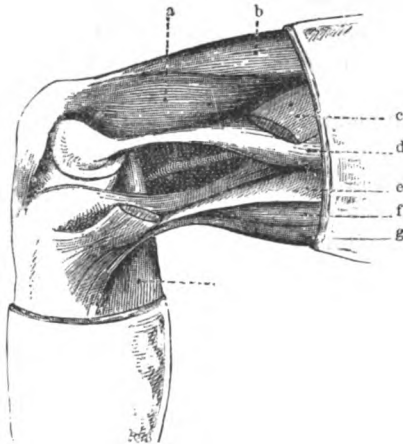


FIG. 281.—Tendons at inner side of knee-joint. *a.* Vortus internus muscle. *b.* Rectus femoris muscle. *c.* Sartorius muscle. *d.* Adductor magnus muscle. *e.* Gracilis muscle. *f.* Semi-membranosus muscle. *g.* Semi-tendinous muscle. *h.* Gastrocnemius muscle.

281), and should be carefully avoided. Divide the internal lateral ligament on a line with the articulation; with the periosteal elevator, separate the capsular ligament and the periosteum from the anterior and posterior surfaces of the inner condyle of the femur, and the tibia outward to the median line of the bones together with the internal semilunar cartilage; flex the leg, then extend it slowly, and at the same time dislocate the patella outward by the thumb applied to the inner border; divide the crucial ligaments, also the external lateral, and the corresponding portion of the capsular ligament by a semilunar incision carried a few

lines below the tip of the external condyle. Remove the periosteum and its associated tissues from the outer portion of tibia and femur, the same as at the inner side. Divide the posterior portion of the capsule and force the extremities of the femur and tibia successively through the wound, and saw them as before. The patella remains unmolested, except it be diseased, when the diseased portion is removed with a gouge, or the bone can be enucleated from the periosteal surroundings by the elevator and scalpel. A small opening should now be made at the outer and inner sides of the joint posteriorly, for the purpose of establishing thorough drainage. A drainage-tube can be passed through the upper synovial pouch, or firm compression be made thereon to prevent the collection of inflammatory products within it. The surfaces are then cleansed, all hemorrhage arrested, the flaps united, and the limb surrounded by antiseptic dressing, and immovably fixed till future dressings become necessary.

The Subperiosteal Excision of Ollier is made through an incision commencing two inches above and to the outer side of the patella, carried down to its upper and outer angle, along the outer border to the apex and to the outer side of the ligamentum patellæ, below its insertion, through the soft parts (Fig. 282). The outer condyle of the femur is denuded of its periosteum together with the lateral and capsular ligaments and the outer head of the gastrocnemius; the anterior

and internal surfaces of the femur are denuded, the crucial ligaments cut, patella displaced inward over the inner condyle, the leg is then flexed and carried inward, causing the femur to protrude, when it is isolated and sawn off. The upper end of the tibia is then denuded of its periosteum from above downward, pushed through the opening and likewise divided. If the patella be diseased, remove it, leaving its periosteum behind.

Excision by a Transverse Incision.—Ascertain the line of junction of the articulation with the limb extended, if the joint will permit; make a transverse incision from one condyle directly across to the other, passing across the middle of the patella or at its apex; if the former, saw the patella through in the line of the incision, remove the fragments, after which the joint surfaces are exposed and removed as in the preceding operations. This incision affords good drainage, and exposes the joint by a minimum injury of the soft parts. In all instances the diseased synovial membrane should be carefully dissected away before the wound is closed. In all forms of excision of this joint care must be taken to prevent the soft parts posterior to the bones from being caught between their sawn surfaces, since this will hinder union by preventing a proper contact of their surfaces. If the two wire sutures be carried through to the posterior borders of the bones, this accident can not occur. If the patella be permitted to remain, its severed ligament may be united by suturing, or, if the bone have been sawn across, the bony fragments may be united by strong catgut or silver wire. It is thought, in cases of imperfect union of the tibia and femur, that the presence of the patella gives greater stability to the limb.

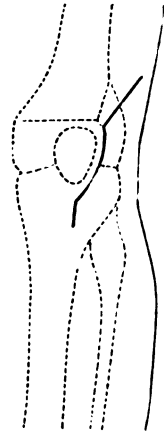


FIG. 282.—Ollier's incision.

Excision of the Patella.—It may be necessary, on account of necrosis or injury, to remove the patella independently of the tibia and femur. In such cases the deep incisions must correspond in extent to the diseased bone, for if they be greater, the synovial cavity may be opened. The periosteum should be raised, and the dead bone carefully removed, if possible, without entering the joint. When the joint is not involved, recovery will be speedy and satisfactory, if the limb be confined in the extended position till sufficient repair has taken place to warrant flexion without fracture of the bone.

The results in eleven cases are two deaths and nine recoveries, of which eight were complete and three partial excisions.

Excision of the Great Trochanter.—This is occasionally required on account of caries. A longitudinal or curved incision is made down upon the bone, and the diseased portion removed with the usual instruments. The branches of the circumflex vessels and the capsular

ligament are to be avoided. The periosteum should be saved when possible.

Excisions of the Hip-Joint.—It is well before attempting this operation to give a brief survey of the important ligamentous and muscular attachments to be respected. The extent of this book is too limited to describe them in detail, and even to do so would hardly be in keeping with the scope of the work.

The ilio-femoral, capsular, cotyloid, and even the teres ligaments, should be carefully considered in connection with their origin and insertion, in order that their relations to the involucrum or periosteum may be maintained. Those muscles which are connected with the trochanters major and minor should likewise be preserved intact, in order that their association with the new bone-growth may give to the new joint, so far as possible, the normal functions of the old.

The results of this operation are substantially as follows: When done for gun-shot injuries, about ninety-two and a half per cent die from the primary; about ninety-one per cent from the intermediary, and ninety and a half from the secondary operation. When done for disease, the mortality is reported variously from thirteen (Sayre) to forty-five per cent. The most favorable age is between five and ten years; the best results are said to occur when the disease has existed several months. The rate is about three per cent greater from complete than partial excisions. The rate of mortality is but little improved by the removal of the trochanter major, and the upper portion of the shaft; it is diminished, however, from the head of the femur downward, in proportion to the amount of diseased bone removed, and is increased in proportion to the extent of the disease of the ilium. About ninety-four per cent secure useful limbs, when excised for disease. Complete excision is followed by a more useful limb than partial excision.

The hip-joint may be removed with or without the preservation of the periosteum, by two quite distinct methods of operating: 1. *The simple*, when no effort is made to save the periosteum, and the muscular and ligamentous attachments about the joint are freely sacrificed. This method is applicable for malignant disease of the bone, and for injuries causing extensive comminution and laceration. 2. *The conservative*, in which conscientious care will often be repaid in peeling off the periosteal tissue and muscular attachments worthy of preservation. Under all circumstances the acetabulum should be closely scrutinized for the presence of dead bone, which should, in all instances, be removed with care, otherwise the pelvic contents may be injured by the manipulation.

Operation (White).—The simple method is performed by placing the patient on the healthy side, and making a deep curved incision (Fig. 283), commencing at a point midway between the anterior superior spinous process of the ilium and the trochanter major, and pass-

ing backward around the top of the trochanter major, down its posterior border about three or four inches, with a strong knife; then dividing the insertions of the muscles connected to the great trochanter (Fig. 284), drawing them aside with a spatula, and exposing the posterior surface of the neck of the femur and the acetabulum. The exposure will be still more complete if the femur be rotated strongly inward. If the cotyloid and capsular ligaments be now divided, and the

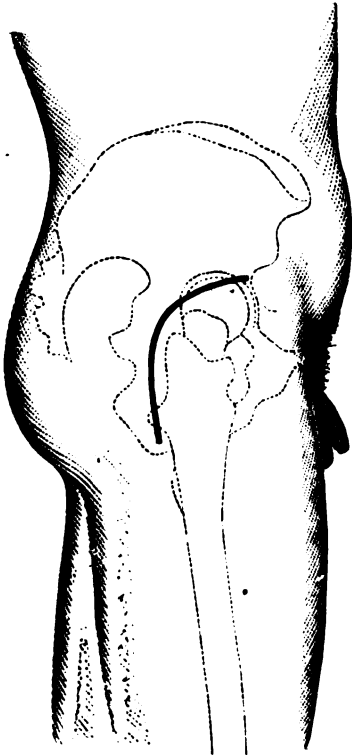


FIG. 283.—White's posterior curved incision.

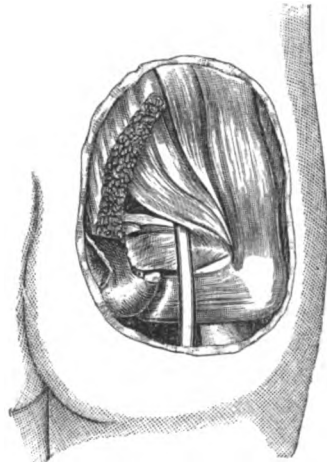


FIG. 284.—Sciatic nerve and external rotator muscles.

thigh be flexed and adducted, the head of the bone will be raised from the acetabulum sufficiently to admit of the division of the ligamentum teres, when the complete escape of the head of the femur will take place. The soft parts are then protected by a spatula, the bone exposed the required extent, and sawn off (Fig. 285).

Subperiosteal Excision of the Hip-Joint (Langenbeck).—Place the patient on the sound side with the thigh flexed at an angle of 45° ; make an incision five or six inches in length in the long axis of the great trochanter (Fig. 286) upward and backward toward the posterior superior spine of the ilium, through the fibers of the gluteus maximus, fascia lata, and periosteum of the trochanter; separate the surfaces of the wound with retractors, and with the elevator and knife raise the periosteum and the attachments of the muscles inserted into the trochanter major and the contiguous surfaces, being careful to

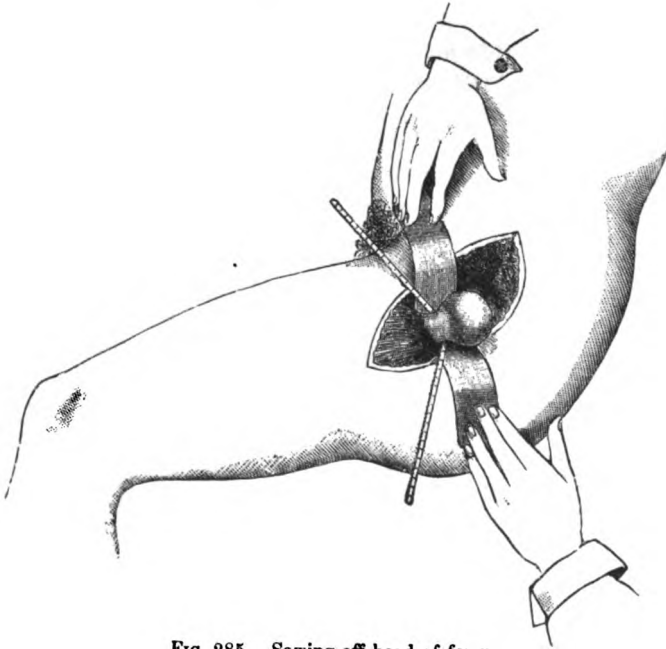


FIG. 285.—Sawing off head of femur.

preserve their connections with each other; next make a longitudinal incision along the neck of the femur, through the capsular ligament and the periosteum. The periosteum of the neck is then separated in connection with the attachments of the capsular ligament and the obturator externus in a careful manner. If an incision be now made through the cotyloid ligament, and the thigh be rotated outward and adducted, the head of the bone will be elevated from the floor of the acetabulum sufficiently to admit of the division of the ligamentum teres, when the head of the bone can be pushed through the opening and sawn off.

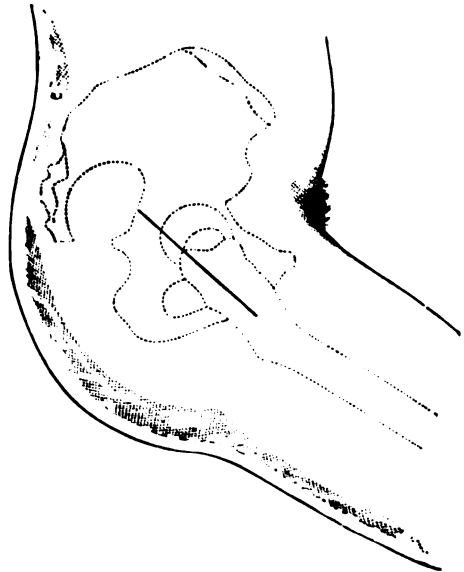


FIG. 286.—Langenbeck's longitudinal incision.

Sayre's Operation.—The following admirable method of excision is recommended by Professor Lewis A. Sayre. It is subperiosteal in all essential particulars, and possesses an advantage over the one just described in that the primary incision is better fitted for drainage. Place

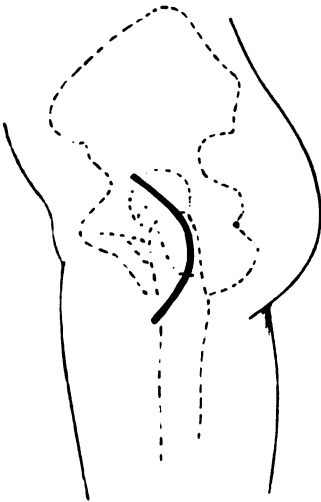


Fig. 287.—Sayre's line of incision.

the patient on the sound side and make an incision with a strong knife down to the bone, commencing at a point midway between the anterior superior spinous process of the ilium and top of the trochanter major; carry it in a curved course upon the bone to the top of the great trochanter midway between its posterior border and center; complete it by carrying the knife forward and inward, making the length of the incision from four to six or eight inches, depending upon the size of the thigh (Fig. 287). If it be not certain that the periosteum of the trochanter has been divided by the first incision, the knife should be carried along the same line a second, and even a third time if need be. The soft parts are now drawn apart, exposing the great trochanter, when, with a narrow, thick

knife, a second incision is made through the periosteum only, at right angles with the first, about an inch or an inch and a half from the top of the trochanter. At the junction of the periosteal incisions introduce the blade of the elevator, and carefully peel the periosteum from either side as far as possible, together with the ligamentous attachments, until the digital fossa is reached. The insertions of the rotators into the trochanter major and digital fossa are so firm that it will be impossible to peel them off; they must, therefore, be carefully separated by short parallel cuts, so directed as to remove the periosteum with which they are blended. After the separation of the tendinous insertions, continue to elevate the periosteum upon either side of the neck, using great care not to rupture it. Its integrity is important to prevent infiltration into the surrounding tissues, provide attachments for the important ligaments and muscles, also as the basis for the reproduction of bone which it is hoped will take place, each of which will exert an important influence in the preservation of a useful joint. Having separated the periosteum as far as can be done safely, adduct the thigh carefully, raise the head of the bone from the acetabulum, and the remaining portion can be detached. Adduct and depress the head being careful not to tear the periosteum, lift the head far enough to admit of a division just above the tro-

chanter minor. Care should be taken not to expose a greater surface than is necessary, since necrosis will follow and hinder recovery. It is better to remove the trochanter major, even though it be not diseased, since it will impede the escape of discharges, and is not essential to a useful limb if its periosteal covering and muscular attachments have been preserved. In all cases after the operation, the wound should be well irrigated with a strong solution of carbolic acid, thoroughly smeared with balsam of Peru, and loosely filled with fine, well-shaken oakum; good drainage provided, and extension applied to the limb either by the Buck's apparatus or the wire breeches.

Excision of the Coccyx.—This is oftentimes done, though sometimes ineffectually, for the relief of coccydynia. The operation exposes the patient to no danger, and can but remove a comparatively useless appendage.

Operation.—Place the patient on the side and expose the bone by a straight incision in the middle of its long axis; isolate it carefully and remove it with bone-forceps.

OSTEOTOMY.

In a liberal acceptation, osteotomy may be defined as a section of bone.

In a limited sense, however, it is applied to the divisions of bone that may be made for the relief of deformities dependent on ankylosis, rickets, badly united fractures, etc. It may be performed either with or without antiseptics. The former, however, is by far the safer plan.

The Instruments employed consist of especially designed saws, chisels, osteotomes, mallets, scalpels and blunt hooks, and sand-pil- lows.

There are variously formed saws employed, named usually after the one who designed them, as Langenbeck's (Fig. 288) and Adams'



FIG. 288.—Langenbeck's saw.

saws (Fig. 289). The blades are short and strong; one fourth of an inch in width and an inch and a half in length, connected to the handle by a strong shank three inches long. The deviations from

these are to meet especial indications, rather than to abrogate their use.

The objections to the use of the saw not only apply to the danger

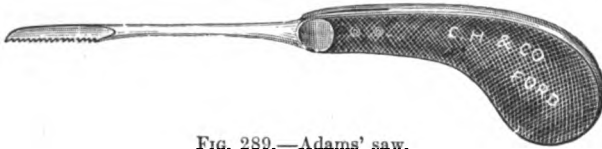


FIG. 289.—Adams' saw.

of lacerating the contiguous tissue, but more forcibly to the retention in the wound of the bone-dust, which, failing to be absorbed, is apt to be followed by suppuration. The saw devised by Dr. George F. Shrady, of this city, is the best, and is described by himself as follows :

Figs. 290 and 291. "The instrument consists of a trocar (1) and a staff (2), with a handle and blunt extremity. A portion of this

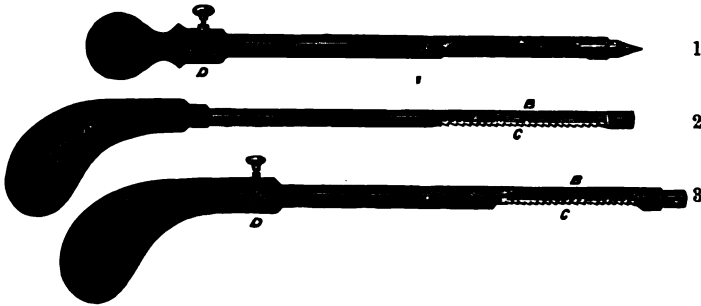


FIG. 290.—Shrady's saw.

shaft at a short distance from the extremity is flattened, one edge (B) being made into a knife-blade, and the other (C) being provided with saw-teeth. This shaft is intended to replace the trocar in the canula after the latter is introduced. When in position (3) either the saw (C) or the knife-edge of the shaft, according to the way the latter is turned, corresponds with the opening of the canula. The saw or

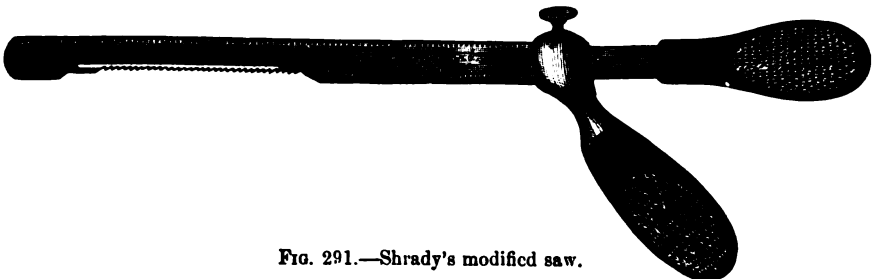


FIG. 291.—Shrady's modified saw.

knife can then be worked to and fro within the canula by a piston-like movement, the canula being steadied by grasping the flange (D) at its base. If it be necessary to work the instrument as an ordinary blunt-pointed sheathed saw or knife, the shaft can be fixed in the canula, and made into one piece by a thumb-screw in the handle. The portion of the canula at the back of the opening is made extra strong, and is of the same thickness as the blade, so that in sawing there is no stoppage of the passage of the instrument through any thickness of the bone. The soft parts are protected from injury, no matter which way the instrument may be worked. The saw-blade is blunt at its extremity, and is guarded on all sides except in its limited cutting surface. The same may be said of the knife. The working of the saw to and fro in the canula is sufficient in sweep to insure the division of any bone having a diameter less than the cutting edge. Still, as this process is much slower than when the saw is used in the ordinary way, it is perhaps better to restrict its employment to operations on the smaller bones, to cramped localities, and to situations where there is special danger of wounding some neighboring vessels. All that is necessary in using this saw is to thrust the trocar and canula into the limb, the fenestrum of the canula being alongside of the bone upon which the operation is to be performed. The trocar is then withdrawn, the staff introduced in its place, and worked as already described."

Since the above description was written, the instrument has been slightly modified by lessening the size of the fenestrum through which the teeth of the saw are seen; this strengthens the canula and facilitates its progress through the bone (Fig. 291).

The Chisel is like that of the carpenter in form, but differs from it in temper; it has two parallel sides extending to its cutting edge. The cutting surface has one side straight and the other beveled, and should be one eighth of an inch thick at the base of the bevel; if thicker, it may splinter the bone. The breadth varies according to the size of the bone; half an inch is suitable in the majority of cases. For narrow bones one fourth inch is better (Fig. 292). The width should always be less than the bone to be operated upon.

The temper given to the tools of the hard-wood or ivory turner is best suited for the purpose, and its efficacy should be tested upon the thigh-bone of an ox or like animal before using the instrument.

The chisel should be sharp, and leave a smoothly cut surface. This instrument is employed only to remove a wedge-shaped piece from the bone, since the shape of its cutting extremity will, like that of the carpenter's chisel, cause it to go awry if a straight section be attempted.

The Osteotome.—This instrument is beveled on both edges, resembling a slender wedge; the handle and the blade forming one piece.

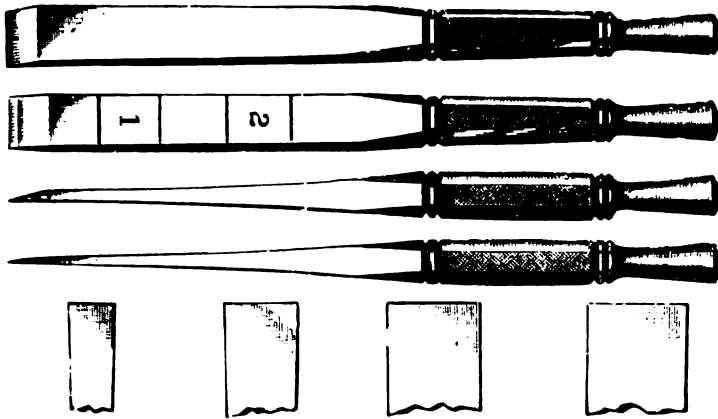


FIG. 292.—Chisels and osteotomes.

The top should have a round head, against which the thumb is pressed to steady it. One border of the blade should be delicately marked in inches to determine the depth of the incision. The edge should be sharp enough to cut the finger-nails, and the temper of a character to withstand the strain required. It can be tested upon the thigh-bone of the ox, when, if it neither turn nor chip, it is calculated to withstand the test of human bone. Osteotomes vary in thickness, in order that a section begun by one of a given thickness may be continued on its withdrawal, by the substitution of another of a less thickness.

The Mallet is made of hard wood, and can be constructed for the purpose; or, an extemporized one may be employed.

The Scalpel is an ordinary one, with a sharp point suitable for penetrating at once to the bone. *Blunt hooks* are employed to draw the edges of the incision apart without force.

The Sand-Pillow.—Its dimensions are usually about eighteen inches by twelve; made of stout cloth, and filled with sufficient fine sand to permit its contents being moved from one part of the bag to another, without leaving any portion empty. It should be dampened before being used, covered with carbolized cloth, and the limb laid upon, or rather imbedded in it. It forms an efficient support, and prevents the force imparted to the bone by the mallet injuring the soft parts.

The opening through the soft parts leading down to the point of proposed section should be limited in extent, and so located as to avoid the division of vessels, or injury to a joint. It should be made when practicable in the long axis of the fibers of the muscle through which it passes down to, but not through, the periosteum. The blade of the scalpel should remain in the incision till the danger of muscular contraction ceases, and then the chisel or osteotome is passed into

the incision by the side of it, as a guide, after which the blade can be withdrawn.

It is better that the wound be large enough to admit the finger, or even to permit inspection of the bone, than that the tissues around a small incision be treated with violence, in the effort to accomplish the purpose.

If chips of bone are to be removed, a larger incision is required than if a simple section be intended. The patient should in all instances be anæsthetized and the limb rendered bloodless by the elastic bandage of Esmarch or Martin. All cutting instruments employed must be rendered aseptic, and in all other respects the operation must be performed with antiseptic care.

Subcutaneous Division of the Neck of the Femur (Adams).—Place the patient upon the side, with the bone to be operated upon uppermost. Introduce a long slender scalpel or tenotome above the top of the great trochanter, straight down to the neck of the femur; divide the muscles and open the capsule freely on the anterior and upper surface; pass the small saw by the side of the knife along the track down to the anterior surface of the neck, which is then sawed transversely through (Fig. 293) from before backward sufficiently to be easily broken. The limb is then placed in position, the wound irrigated with an antiseptic solution, to render it aseptic and to wash out the bone-dust; hemorrhage is checked, a small drainage-tube introduced, the remaining portion of the incision closed, the whole enveloped in antiseptic dressing, and the limb placed in an immovable apparatus. The tendinous contractions, that prevent the limb being placed properly, should be divided subcutaneously.

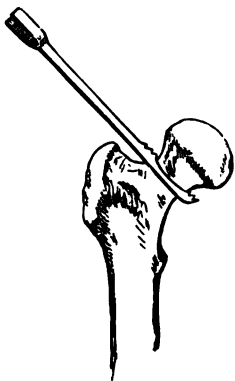


FIG. 293.—Sawing neck of femur.

Results.—This operation has been successful in thirty-one out of thirty-four cases.

Maunder, Billroth, and others have used the chisel for forcible fracture with good results. Another method (Volkman) consists in forming a false joint in the following manner:

Make an incision along the posterior surface of the great trochanter four or five lines in length down to the bone. The femur is then cut through about an inch below the point of the great trochanter, with a chisel, the wall of the cervix femoris broken, and this portion of the bone removed. The thigh is then adducted to make the upper end of the femur more accessible then it is cut across and rounded off to fit the new socket which is made by chiseling out the head of the femur, thus enlarging the area of the acetabulum by the same

process, being careful not to open into the pelvic cavity. The upper end of the femur is placed in the newly-formed cavity, and extension is applied to the limb to keep the cut surfaces sufficiently separated to prevent bony union. Early passive motion should be made. Volkmann has performed this operation several times, resulting in useful limbs in each instance.

Inter-trochanteric Osteotomy.—This operation consists in exposing the anterior, outer, and posterior surfaces of the femur through an incision about six inches in length, beginning just above the tip of the trochanter major, and carried longitudinally through the center of its outer surface. A short, transverse incision is then joined to the center of the posterior lip of the first; the respective surfaces are then exposed with an elevator until the trochanter minor can be felt, when a chain-saw is passed around the bone immediately above this process. The uppermost or curved section (Fig. 294) is made by first sawing upward and outward, until the bone is half severed, then changing the direction downward and outward and completing the section.

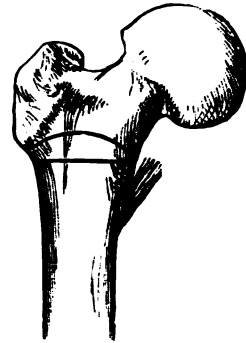


FIG. 294.—Sayre's lines of section.

The second section is made by sawing directly through the bone in its transverse axis, removing a piece one eighth of an inch thick at its outer and posterior border, and three fourths of an inch of its central part.

The upper end of the lower fragment is then rounded to fit the concavity above. The limb is straightened out and the wound treated like a compound fracture.

This method was practiced by Professor L. A. Sayre some time since with eminent success.

The removal of a disk of bone in this situation has been quite frequently done, but with indifferent success. Out of the seventeen cases reported, seven died. While this method displayed great ingenuity and resource on the part of the originator, the fatality attending it, together with the introduction of the chisel and osteotome, render it at the present time impracticable.

The modification introduced by Volkmann in 1873 consists in making an incision along the posterior surface of the great trochanter and removing the periosteum from two thirds of its circumference, when with chisels and gouges a triangular piece is taken from just below the trochanter (Fig. 295), the bone broken, straightened, and placed in position until union takes place.

Twelve operations thus performed, all recovered.

Ankylosis of Knee-Joint (supra-condyloid).—

Make a longitudinal incision, sufficient to admit the osteotome, at the outer side of the rectus tendon, one finger's breadth above the upper portion of the outer condyle. The osteotome is introduced, and turned so that its cutting surface corresponds to the transverse axis of the bone at the point to be divided; with the limb resting upon the sand-bag, the bone is two thirds divided and the remainder broken or bent. If performed from the inner aspect, the incision is made along the anterior border and half an inch in front of the tendon of the adductor magnus, beginning one inch above its insertion. The remaining steps of the operation are similar to the preceding. It may be necessary to supplement the section of the femur with that of the tibia, in order to sufficiently correct the deformity. This is done by making an incision through the skin over the tibial crest just below the tuberosity. Through

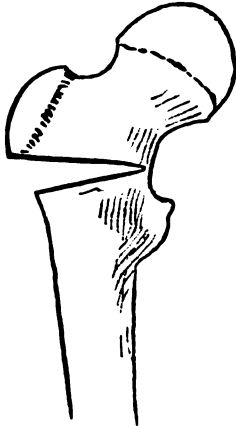


Fig. 295.—Volkmann's section.

this opening, the subcutaneous and posterior surfaces of the tibia are divided sufficiently to admit of a fracture of the bone and the consequent correction of the deformity. The fibula, owing to its mobile association with the tibia, does not require division at this situation. It is often necessary, however, to cut the hamstring tendons before the deformity can be properly corrected.

Supra - Condylloid Osteotomy for Genu Valgum (Macewen) (Fig. 296).—In this operation care is taken to avoid the popliteal vessels, anastomotica magna, superior internal articular arteries, and the synovial pouch of the knee-

joint on the anterior surface of the femur. The incision in the soft parts is made at the inner side of the limb, beginning a finger's breadth above the insertion of the tendon of the adductor magnus into

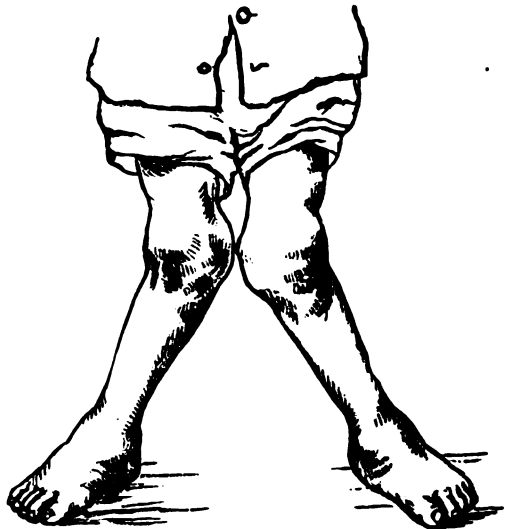


Fig. 296.—Genu valgum.

the spine at the upper portion of the internal condyle and half an inch in front of it, and carrying it up sufficiently to admit the osteotome ; or, its lowest limit is made to correspond to a line drawn transversely across the limb in front, beginning an inch above the external condyle, which will, if the internal condyle be much elongated, prevent the osteotome being driven into the external condyle, instead of above it. The course of this incision avoids as far as possible any interference with the anastomotica magna and the articular arterial branches. The osteotome may be applied to the bone transversely at the point indicated by the faint transverse undotted line in Fig. 297, and so directed that its course will correspond to a line extending across the posterior surface of the femur to a point one finger's breadth above the external condyle. The extent of the osseous incision will depend upon the density of the bone ; if the subject be young, and if the bone be cut through two thirds of its diameter, it can be bent or broken. If it be dense, it will be necessary to carry the incision to the outer wall. The posterior and inner surfaces of the bone are first cut, when, if necessary, a thinner chisel is employed to

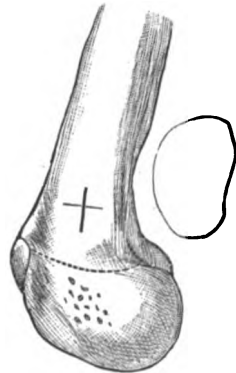


FIG. 297.—Line of bone section.

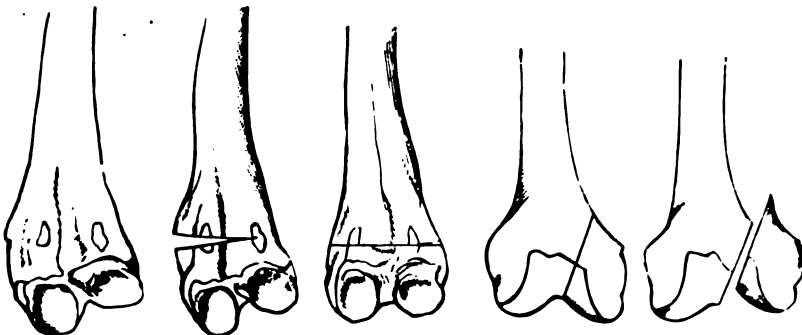


FIG. 298.

FIG. 299.

FIG. 300.

FIG. 301.

FIG. 302.

FIGS. 298, 299, 300.—Macewen's method.

FIGS. 301, 302.—Ogsten's method.

complete the operation. When the bone is sufficiently divided, the limb is straightened, all hemorrhage arrested, and the limb treated as before indicated. The above figures will aid in explaining the method.

Fig. 298 shows a long internal condyle in genu valgum ; Fig. 299, a section through about three fifths of its diameter ; Fig. 300, the appearance of the bone with the limb placed in position, showing the

curvature rectified. The prognosis of this operation, with reference to usefulness of the limb, cure of the deformity, and danger to life, is most flattering.

Results.—In about six hundred and fifty supra-condyloid osteotomies, but three fatal cases are reported that can be attributed to the operation; one each from septicæmia, hemorrhage, and carbolic-acid poisoning. All the patients were benefited, and many were able to take an active part in affairs from which they had been debarred.

Osteo-Arthrotomy (Ogsten).—This method consists in dividing the elongated condyle of the femur by sawing (Ogsten), or cutting (Reeves), sufficiently to admit of the rectification of the deformity (Figs. 301, 302).

Operation by Sawing.—Place the patient in the dorsal position; administer an anæsthetic; flex the leg upon the thigh, fully. At a point two or three inches above the tip of the inner condyle, introduce a tenotome upon the flat, carry it downward, forward, and outward until its point can be felt in the inter-condyloid space. The cutting edge is then turned downward and the tissues divided down to the bone as it is withdrawn. A small Adams' saw is then introduced along the course of the incision and the condyle is sawn, from above downward, through about three fourths of its thickness. If the limb be now straightened, the remaining portion is fractured and the deformity is rectified.

Results.—In forty-six operations two patients have died of septicæmia.

Operation by Cutting.—By this method the elongated condyle is divided or loosened with a chisel or osteotome; the intention being to divide the condyle to the greatest depth without opening into the joint. Even though the cut be made to meet this indication, the joint is no doubt involved (except possibly in the very young) by the displacement upward of the fragment necessary to correct the deformity.

Chiene's Method.—Mr. Chiene, instead of sawing or cutting off the condyle, corrected the deformity by the removal of an oblique transverse wedge of bone from the body of the condyle which, when pressed upward by straightening the limb, remained attached by its apex to the shaft. Not infrequently, however, the fragment is detached by this manipulation, and the joint opened into. The details attending this method are omitted, since it can not be compared favorably with the much simpler and equally efficient one, supra-condyloid osteotomy.

Osteotomy for Genu Varum.—In this deformity the operative proceedings are directed to the outer instead of the inner side of the bones of the leg and thigh. The procedure, precautions, and treatment are similar. The division of the bones through a small external opening can be made almost indiscriminately in such as present this

deformity, always remembering that thorough and complete antiseptic precautions should be taken. The results are most flattering, and commend it to the consideration and practice of the profession.

Bow-Legs.—*Genu varum* may depend on an outward curvature of the bones of the leg, wholly or in part. In either instance the deformity can be corrected by a subcutaneous osteotomy of the tibia. If the patient be young enough, a green-stick fracture of the fibula will obviate the use of the osteotome upon it.

Operation.—Cleanse the part thoroughly with soap and brush; apply the elastic bandage; place the limb on the sand-bag, and at the point of the greatest curvature make a longitudinal incision down to the periosteum, midway between the borders of the subcutaneous bone at the point of proposed division, of ample length to admit the osteotome, which is then turned so as to divide the bone transversely, sufficiently to admit of its being fractured. Cut or bend the fibula, correct the deformity, close the wound in the soft parts with catgut, dress antiseptically, and confine the limb in a temporary dressing until all danger of hemorrhage, inflammation, etc., has subsided, when it may be placed in an immovable plaster-of-Paris dressing, and retained until union has taken place. If a double section is to be made at different points, an antiseptic sponge should be bound over the incision in the soft parts of the first while the second operation is being made. This affords an opportunity to determine the severity of the hemorrhage and the ease with which it can be controlled. If it be necessary to divide one bone in two situations to correct a deformity, the second division should be deferred until the former has healed, when it should be done at the remaining point of greatest convexity. If the bones be much curved, it may become necessary, in order that the deformity be properly corrected, to remove a wedge-shaped piece (cuneiform osteotomy). For this purpose the chisel alone should be employed. In all instances when the bichloride gauze is to be applied, the skin must be protected from its irritant effects by smearing it with a mixture of glycerin and salicylic acid, or by placing between the bichloride gauze and the skin one or two thicknesses of carbolic-acid gauze; the latter plan is the better.

All osteotomies should be performed under strict antiseptic precautions, and the incision of the soft parts closed with a catgut suture. The limb must be immovably fixed and the patient kept quiet; in fact, the measures applicable to a compound fracture are in order, since it resembles that condition more nearly than any other.

Results.—The results of all osteotomies performed with antiseptic precautions are extremely flattering. As yet, I have no personal knowledge of a death from the operation, and of fourteen hundred osteotomies but about one per cent are reported to have died in consequence of it.

Hallux Valgus.—This deformity is practically limited to the great toe, and is usually caused by improperly fitted boots and shoes. Fig. 468 represents the condition more graphically than words can do it. The first phalanx (anatomical) articulates with the inner portion of the distal extremity of its metatarsal bone and is rotated inward on its long axis. The principal portion of the head of the metatarsal bone projects inward, and its extremity is surrounded by a sensitive bunion. The indication is to place the toe in its normal axis and retain it in that position. If the deformity be great, little else than an operation on the bone will be of any practical value. Two methods can be recommended :

1. The removal of the head of the metatarsal bone, with enough of the shaft to permit the great toe to be easily returned and held in its normal axis (Fig. 270). Under strict antiseptic precautions this operation results in quick recoveries and useful toes.

2. The deformity can be corrected by removing a V-shaped piece from the inner portion of the distal extremity of the metatarsal bone, as near the head as possible without involving the joint cavity. This, too, must be done under strict antiseptic precautions, and is accomplished through an incision made along the inner side of the metatarsal bone. The soft parts are retracted and the V-shaped piece of the bone is removed, without dividing more than three fourths its diameter. The thickness of the base of the triangular piece to be removed is estimated by the degree of the deflection of the toe from its normal position ; it should correspond as nearly as practicable to about one third the distance which the extremity of the toe will traverse to regain its normal relation to the foot.

The wedge can be removed by means of a saw or chisel and the toe brought into position, which will fracture the inner undivided portions of the bone. Horse-hair drainage and immobility under antiseptic dressing will be followed by speedy union and a satisfactory recovery.

Osteoplasty, or transplantation of bone, has not gained the prominence as a surgical expedient that the knowledge of the laws governing the growth of bone bids fair to attain for it.

Bone associated with its periosteal and fibrous connections, has been transferred, as in the case of the operation on the hard palate for the closure of the fissure, also the closure of the spaces between the ununited fragments of bone, by filling them with freshly sawn sections from the main shaft. The conditions necessary to a successful issue of this operation are exceedingly numerous and exacting, the chief one of which is a most rigid adherence to the antiseptic methods. The feasibility of bone transplantation as a practical measure is not, as yet, sufficiently established to warrant its being considered an accomplished fact.

CHAPTER IX.

AMPUTATIONS.—GENERAL CONSIDERATION.

AMPUTATION consists in the removal of a limb either in its continuity or at its articulation, although the latter is often termed disarticulation. The aims sought to be gained by an amputation are : 1. The saving of the life of the patient. 2. The securing of a serviceable stump.

If the prospects of recovery be annulled by the presence of a badly diseased or mangled limb, it is no opprobrium upon the art to remove it. If a limb be so badly injured or diseased as to require removal, it is entirely proper that the ability of the designer of compensative appliances be considered, that the patient may reap the combined benefit of the art of the surgeon and the ingenuity of the mechanic. A stump, to be serviceable, should be sound, unirritable, with a good circulation and abundant leverage. The first three qualities depend, all things being equal, very largely upon the length, shape, and vascular supply of the flaps ; the last depends entirely upon the length of the bone. The flaps should be movable over the extremity of the stump after healing is completed, not tightly drawn and smooth like a base-ball cover. Flaps that are tightly drawn at the initial dressing soon become more so, on account of the inflammatory action. The increased tension causes pain, and early and rapid ulceration at the seat of the ligatures, followed by separation of the flaps, union by granulation, and finally a troublesome stump ; or, the normal shrinkage of the integument draws the flaps against the end of the bone, to which they, together with the cicatrix, become immovably united, and cause a similar difficulty. The proper length of the flaps, then, becomes an important point in estimating the prospective usefulness of the limb and comfort of the patient. In cases where each flap can be made of a similar length, its extent should correspond to about one fourth the circumference of the limb at the point where the bone is to be divided. If one flap only be employed, it should be made double the length of each flap when two are employed. Any increase in the length of one flap should be accompanied by a proportionate decrease in the length of the other. The shape of the flaps largely controls the site of the cicatrix. It is advisable that the cicatrix be so placed as not to be subjected to pressure or friction. If, however, the flaps be made of sufficient length to admit of the formation of a non-adherent or movable cicatrix, its location is a matter of secondary importance. The length and location of the flaps also largely control their circulation. If they be too long, the circulation will be enfeebled ; if, on the contrary, they be too short, the tension will become an impediment, causing a blue, cold, and shiny surface, sensitive

to the slightest injury. The circulation in the normal limb, or a portion of it, may be such as to predispose to a small and sluggish blood-supply in flaps constructed from it.

Flaps are classified, according to the tissues entering into them, as the cutaneous, integumentary or skin flaps, musculo-cutaneous, and periosteal, either variety of which may be made either single or double. The integumentary variety is commonly employed in this country.

Flaps are also classified, according to their shape, into circular, modified circular, oval, rectangular, hood, etc. The oval may be either unilateral, bilateral, anterior, or posterior. Many of the preceding forms may be composed of integument alone, or combined with muscular tissue, and even with periosteum.

Circular Method (Fig. 303).—This method is followed by an ad-

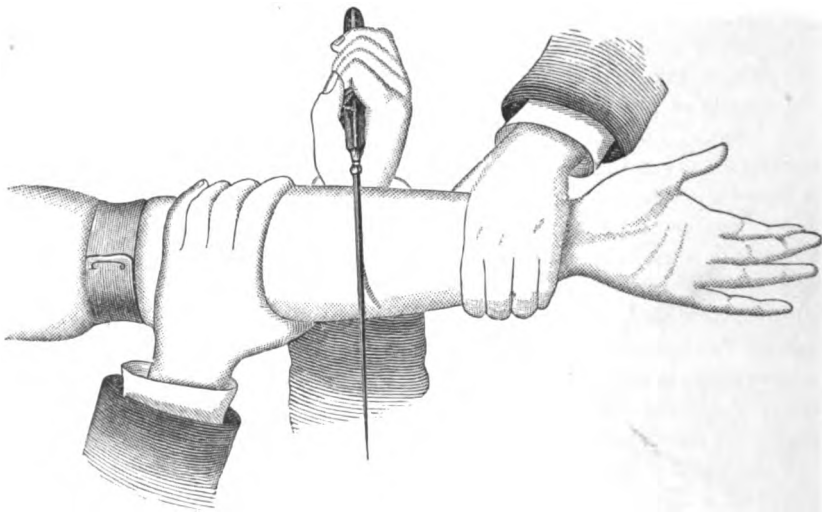


FIG. 303.—Circular method.

mirable stump, is easiest of performance, and consequently very frequently practiced. It is especially to be recommended in the field operations of military surgery, since the lightness of the flaps permits the transportation of the wounded with the minimum degree of disturbance of the seat of the amputation. It is done by making a circular incision transversely around the long axis of the limb, through the integument and subcutaneous tissue down to the muscles, at a distance below the proposed division of the bone, corresponding to about one fourth the circumference of the limb at that point. The flap is then dissected up from the muscles with an ordinary scalpel; the edge of the knife being directed toward the muscles (Fig. 304) rather than

parallel with them (Fig. 305), as the latter severs the capillary connection between the integument and the deeper tissues. The dissec-

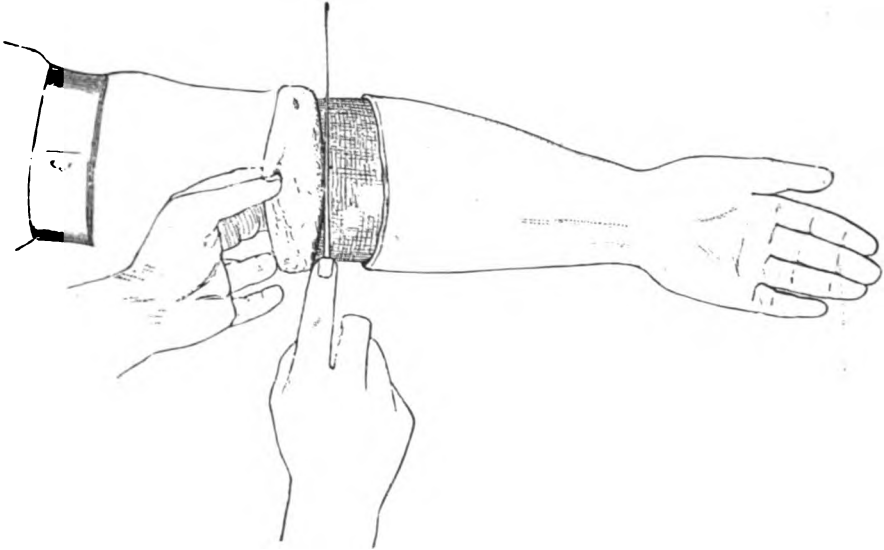


FIG. 304.—Dissecting up the flap.

tion should be done by circular sweeps, rather than by mincing cuts, which hack the tissues and provoke suppuration. This careful man-

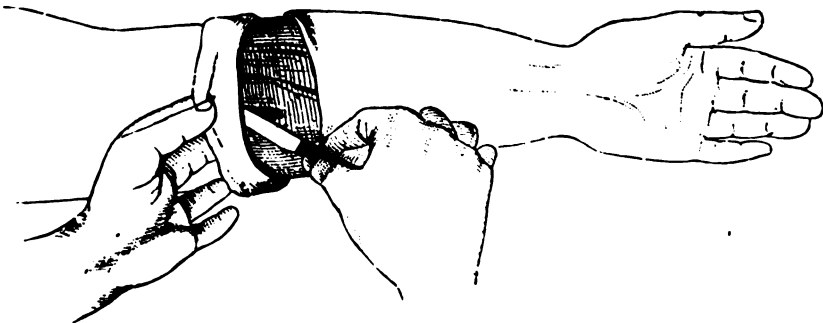


FIG. 305.—How not to do it.

ner of raising the flap applies equally to all the varieties which involve the separation of similar tissues.

If the limb be conical, much difficulty will be experienced in turning over the sleeve of integument; this, however, can be obviated by a longitudinal cut made usually at the most dependent portion of the flap.

The flap should be turned upward to the point where the bone is to be divided; then with suitable knife make a circular division of the

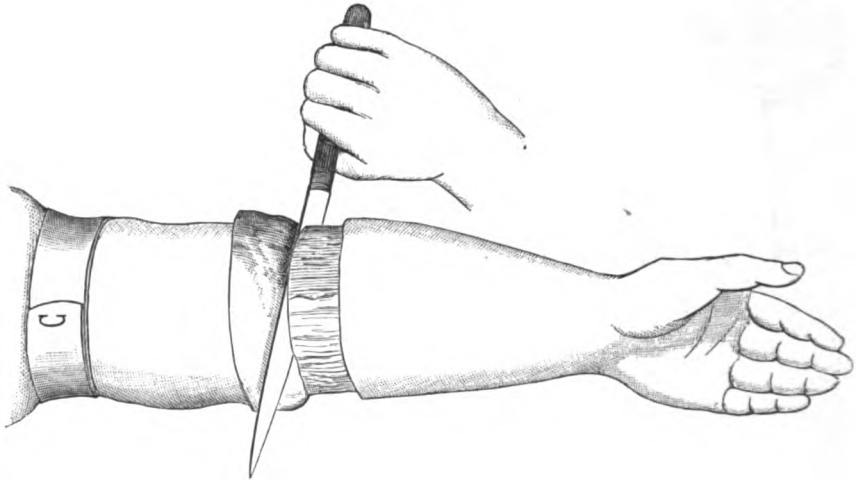


FIG. 306.—Circular division of the muscles.

muscles down to the bone, beginning far enough *below* the reflection of the flap to allow for the retraction of the divided muscles. No definite law can be assigned to this element, still they will contract according to their size, length, degree of irritability, etc. The suitable points of section will be stated in connection with the description of the special amputations. Not infrequently the muscles are cut just below the reflection of the flap, as in Fig. 306; this is not, however, as good a plan as the former, since sensitive stumps are more liable to result therefrom. The bone should be sawn at its highest point of exposure.

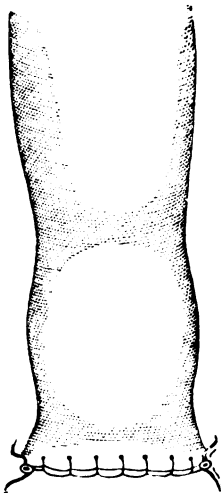


FIG. 307.—Stump after the circular operation.

The Modified Circular Method (Fig. 308).—This plan was suggested by Mr. Liston, who made semilunar flaps, which he dissected up to their point of junction with each other, at which point the muscles and bone were divided, as in the circular method. This method was afterward modified by Mr. Syme, who dissected a short distance above the point of juncture of the flaps, and divided the muscles and bone, as before. In either instance, however, it amounts to slitting up the cuff of a circular flap, and trimming off the angles caused thereby.

The Oval Method.—This is in reality a modified circular amputation, the flap being slit up at one side and the angles trimmed off. It




FIG. 308.—Modified circular flap.

is employed principally in disarticulations, and will be described in connection with those operations.

The Single-Flap Method.—This is adapted to those cases where the tissues of one side of the limb only are suitable for the purposes of a flap; as in the case of lacerations, ulcerations, etc. This flap may be composed of the muscular tissues and integument, or of integument alone; and can be made either by transfixion, or division from without. If possible, a short convex flap is made on the opposite surface of the limb.

The Double-Flap Operation is performed by transfixion, and includes the muscles down to the bone on either side of the limb (Figs. 309 and 310). The tissues to be transfixed are raised slightly by the left hand of the operator, who then enters the point of the knife at the side nearest himself, pushing it through slowly, in close contact with the anterior surface of the bone, slightly raising the handle as it passes in front of the bone, thereby causing its point to emerge at the opposite side of the limb at a point exactly opposite to its entrance; the flap is then made by cutting obliquely upward with a sawing motion. It is pulled backward by an assistant, and the knife is reinserted at the original point of entrance, carried behind the bone, handle depressed to cause the point to emerge at the same situation as at the anterior transfixion, and the posterior flap made by cutting obliquely downward. Each flap should correspond in length to at least one half the diameter of the limb. The retractor is then applied, and all

the soft tissues are drawn well upward ; the remaining fibers in contact with the bone are severed by a circular sweep of the knife, and

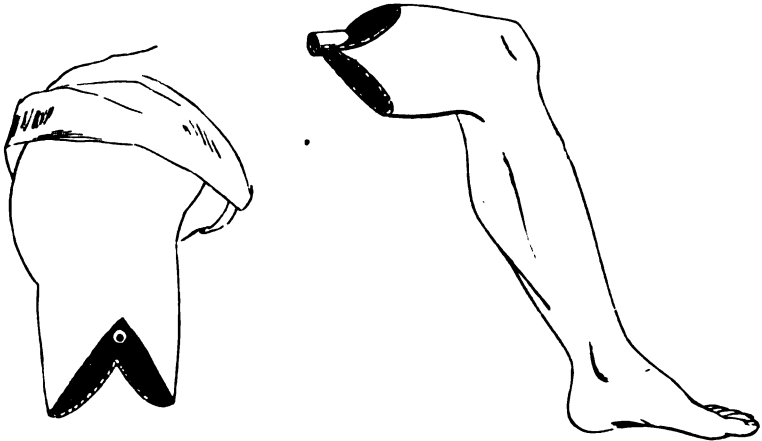


FIG. 309.

FIG. 310.

FIGS. 309, 310.—Flap by transfixion.

the bone is carefully sawn through. If lateral flaps be made, the outer should be formed first. The flap containing the large vessels is to be divided afterward.

The Mixed Double Flap is a modification of the preceding, and sometimes called Sédillot's method. The flaps are made by transfixion, as before, but are more superficial, the knife not being brought in contact with the bone. The remaining muscles and vessels are divided by a circular incision, and the amputation completed as before described. In this instance the flaps are thinner and shorter than in the preceding.

Langenbeck's Method.—This differs from the last only in the manner of obtaining the result ; the flaps being cut from the surface toward the center of the limb, which affords a better opportunity to shape them. Another modification of the method consist in cutting the anterior flap from the surface, and making the posterior flap by transfixion.

The Rectangular Flap, or Teale's Method (Figs. 311 and 312).—In this two rectangular flaps are employed, one being four times longer than the other ; both flaps include the structures down to the bones. The longer flap is taken from the side of the limb, where the bone is most superficial. The shorter contains the important vessels. The length and breadth of the long flap correspond to half the circumference of the limb at the point of proposed amputation. The width of the short flap is a half, and its length an eighth, of the circumference of the limb. Both flaps should be carefully marked out before begin-

ning the operation. This method makes an admirable stump, but sacrifices fulcrumage, and brings the bone section nearer the body

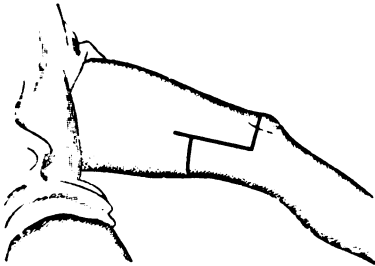


FIG. 311.

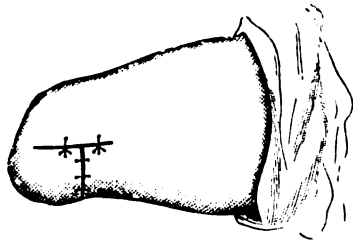


FIG. 312.

FIGS. 311, 312.—Teale's method.

than is consistent with the additional dangers incurred. Mr. Lister recommends that the longer flap be made a third and the shorter flap a sixth of the circumference of the limb, which brings the cicatrix at the edge of the stump. Also that the posterior flap shall consist of the integument and subcutaneous tissues alone. This, like Teale's, may be employed when the loss of tissues is greater upon one side than upon the other.

The Hood Flap.—There is no substantial difference between this and the circular method, if the latter be slit up at the most dependent part, and the resulting corners rounded off. This method meets the indications requisite to form a good stump as well as any other variety of flap.

Equilateral Flaps (Fig. 313) consist of equilateral skin-flaps, oval in outline, the posterior angle being made somewhat farther up the limb, to improve the drainage. The muscles are cut by a circular sweep at a suitable distance below the point of reflection of the integumentary flaps, and the bone is sawn above the anterior point of junction of the flaps.

Periosteal Flap.—This is made by raising the periosteum in conjunction with the tissues which rest upon, or are attached to it, sufficiently to cover the end of the divided bones, when it is allowed to fall into place. It is best adapted to those bones subcutaneously located, like the tibia, and will be again referred to in connection with amputations of the leg.

A periosteal flap will, if it becomes adherent to the end of the bone, preserve it from atrophy, and lessen the danger of the formation of a conical stump; it likewise prevents the adhesion of the cicatrix to the stump, thereby forming the basis for a movable cicatrix.

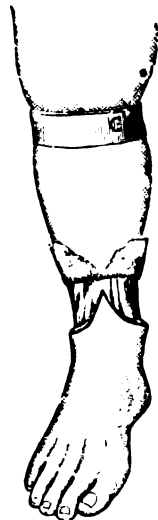

FIG. 313—Equilateral flaps.

If the patient be young, new bone may be developed; this lessens the sensibility and increases the usefulness of the stump. It is claimed by some that the bony spiculæ often shoot into the soft tissues on the end of the stump, and require a second operation for their removal. It is my opinion, however, that if the periosteum be removed entire and in connection with its superimposed tissues, and be so placed that the force of gravity will aid in holding its bone-producing surface in contact with the divided extremity, this danger will be obviated.

Comparative Merits of Different Forms of Flaps.—The ends sought to be gained in making flaps are: 1. To secure good drainage. 2. To make them of suitable length, that the circulation and movement of the integumentary cushion at the end may be unrestrained. 3. To place the cicatrix beyond the point of friction, and prevent its adhesion to the end of the bone. 4. To guard against any danger of undue sensibility, by making the flaps of proper length, and by drawing down and cutting off the cutaneous and other nerves of larger size that may exist in them.

With these aims in view, it will be seen that the old-fashioned circular flap affords equal advantages to the others, and is further commendable for its simplicity. It is true that in this method the scar will fall on the end of the stump, but with proper precautions as to the length of the flaps and suitable surgical attentions, any danger from this source is reduced to a minimum.

The Agents required for an Amputation may be classed as those for arresting hemorrhage; for the division and trimming of the soft parts and the bone; and those for uniting and dressing the wound. The preparation of the patient for the operation; the agents for controlling and arresting hemorrhage, together with the various methods of securing and maintaining the coaptation of the cut surfaces, drainage, and various forms of dressing, antiseptic and otherwise, have herein been previously considered; therefore, there remain to be enumerated, under this heading, only those instruments especially adapted to the requirements of the operation.

Amputating Knives (Fig. 314).—The modern amputating knives can be used for making circular flaps, or, for those made by transfixion. They should be double-edged (catlin) entirely or for an inch or two from the point. The length of the knife selected will depend upon the size of the limb to be operated upon, and should be about one and a half times its diameter. It may be inconsistent with good taste, but it is entirely consistent with good judgment and economy, to amputate an arm or forearm with the knife intended for the thigh, and the result will be equally satisfactory.

The Manner of grasping the Amputating Knife, prior to and during the division of the soft parts, adds much to the optical effect of an operation. It should be, at first, lightly grasped, with the edge for-




FIG. 314.—Amputating knives.

ward, between the thumb and first two fingers, near enough to the shank to admit the upper end of the handle to play between the heads of the metacarpal bones of thumb and finger, when it is swung backward and forward (Fig. 315). There are two methods employed of carrying it entirely around the limb: 1. Stand with the left side toward the patient, seize the limb above the point of intended operation with the left hand, an assistant holding its distal extremity; place the left foot forward, slightly bend the right knee, and with the catlin held by the right hand, as before described (Fig. 315), stoop downward and forward sufficiently to carry the knife and arm *under*, and the knife *over* the limb, placing its heel as near to the upper surface of the limb as is convenient, when, with a sawing motion, it is drawn toward the operator beneath the limb, then upward between it and the operator, and so on around, until it joins the beginning of the cut, making a complete circle (Fig. 316). If the knife be properly grasped, it will pass readily between the thumb and forefinger, as the hand passes around the limb; enabling the surgeon to make the section with perfect ease, and without the least manifestation of stiffness. 2. The method may be reversed by passing the hand and knife over instead of under the limb (Fig. 317); otherwise the manipulations are the same. The latter, however, is less natural, besides which it exposes the arm of the operator, and the integument to be divided last, to the flow of blood. Still, either of these methods is far superior to the one commonly employed and figured in text-books (Fig. 318).

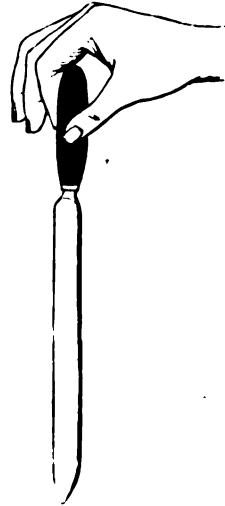


FIG. 315.—How to grasp the amputating knife.

The *Catlin* (Fig. 321).—This is chiefly employed to divide the tissues in the interosseous space, in amputations of the leg and forearm. It can be readily supplemented for this purpose by the single-edged narrow knife, provided the latter be withdrawn to complete the divis-




FIG. 316.—How to carry the knife around the limb.

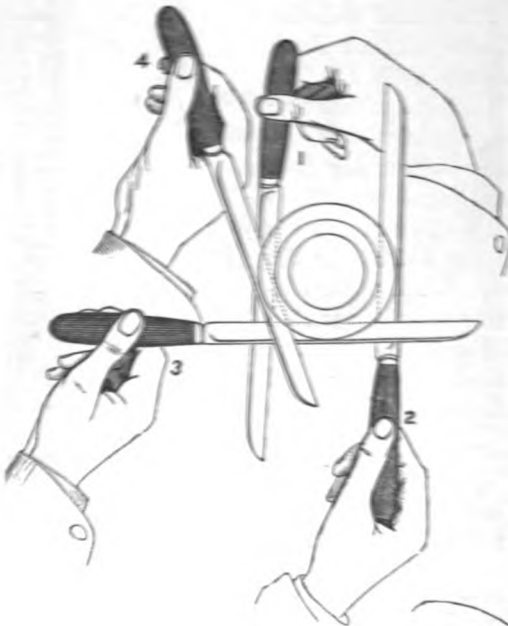


FIG. 317.—Another method.

ry broad-bladed saw (Fig. 320) and the bow-backed (Fig. 322) are in common use. The first meets all requirements except in certain excisions, when either the chain-saw (Fig. 239) or Butcher's saw (Fig. 323) must be employed. The narrow, movable-backed saw

ion of the interosseous tissues, instead of changing the direction of the cutting edge, while it remains between the bones. The latter act will bruise and tear the interosseous tissues.

Two or three ordinary scalpels should be added for raising the integument, etc.

A knife with a long, narrow blade is the better for amputating at the phalangeal articulations (Fig. 219).

Saws.—The ordina-

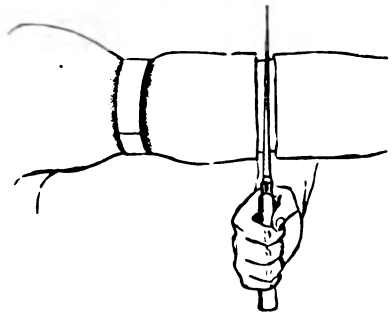


FIG. 318.—A common method.




FIG. 319.—
Metacarpal
knife.

FIG. 320.—Broad-bladed
saw.

FIG. 322.—Common bow-saw.

FIG. 321.
—Catlin.

(Fig. 241) is of use in sawing small bones and removing spiculæ.

The Proper Method of using a Saw should be given some attention (Fig. 324). After the division of the soft parts,

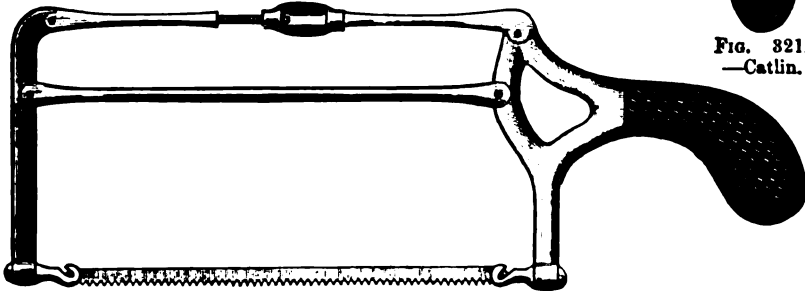


FIG. 323.—Butcher's bow-saw.

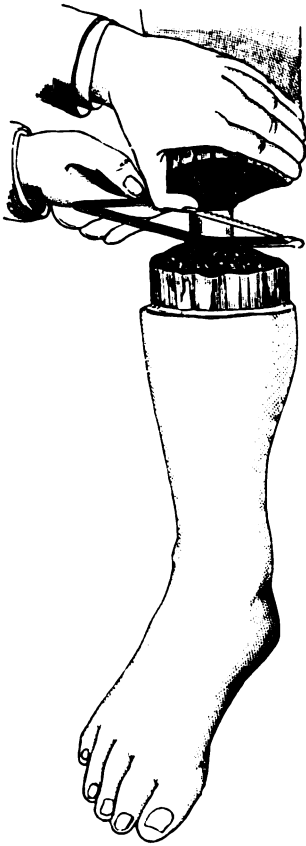


FIG. 324.—Sawing the bone.



FIG. 325.—Ferguson's lion-jaw forceps.

the surgeon grasps the saw firmly, places its heel close to the border of the retracted muscles, in a line made through the periosteum by the knife, and, while guided by the thumb-nail, slowly and carefully draws it toward himself along the first four or five

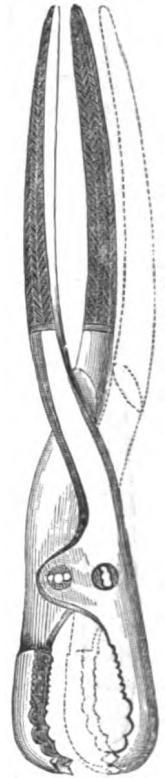


FIG. 326.—Farabeuf's forceps.

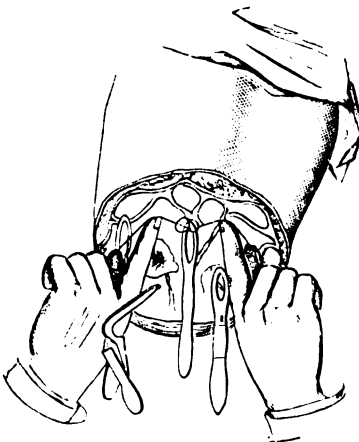


FIG. 327.—Catching bleeding points.

inches of its edge, raises it from the track, and places it as before; repeating the operation until a track of sufficient depth is made to retain it during the to-and-fro movements of sawing, which should be done by quick, sharp strokes, until the bone is nearly severed, when care must be taken, or the saw will be clamped and the remaining portion be broken off. If the handle of the saw be raised and the remaining portion be divided at a different angle with the bone, the danger of breaking is lessened. When two bones are to be sawed off,

the saw should be started in the less movable bone, and then turned so as to include both. If the movable one clamp the saw, cut off the more solid one first, then complete the other. The proximal and distal portions of the limb should be supported and steadied during the sawing of the bone.

Bone-Forceps.—Liston's cutting forceps (Fig. 227) are used for trimming off rough prominences. Ferguson's lion-jawed (Fig. 325) and Farabœuf's forceps (Fig. 326) are excellent instruments for grasping the bone to steady the part. They are also used for removing bone by twisting, when great force is required.

How to operate.—Before beginning an amputation, the operator should rehearse in his mind, at least, the entire procedure as he contemplates it; by doing this he will be confident, and be certain to anticipate the unimportant as well as the important details. The preparation of the patient and administration of the anæsthetic, and methods of dressing, are given on the pages in the fore part of this work. The surgeon should always plan his work with careful precision, even to marking out upon the limb the outlines of the flaps, and such other incisions as may be required. I am aware that this is seldom practiced, even by the most experienced surgeons; but, within my own observations, had it been done more frequently better results might have been secured. The young surgeon, too, often fancies that to do this announces him as ignorant and inexperienced; such, however, is not always the case; it rather serves to emphasize his cautious and painstaking qualities. An operation should be done without haste, when the safety of the patient will permit, remembering that it is done quickly when done well.

The operator should stand in such a relation to the patient that the left hand can readily control any undue hemorrhage by compressing the artery, or otherwise.

The primary incision should be so located, if possible, that the escaping blood will not obscure the course of the incisions to be subsequently made.

The incision which will divide the important vessels should be made last when practicable.

In circular amputations the tissues should not be retracted until after the division of the integument.

In flaps by transfixion, the tissues to constitute the flap can be raised or depressed, according to the aspect of the limb from which they are to be made.

After the limb is removed, the open mouths of the vessels should be caught by serrefines, forceps, etc. The tourniquet, or Esmarch's band, is then loosened slowly, and all bleeding points controlled by suitable means (Fig. 327). The surgeon can then proceed carefully to ligature the vessels thus secured.



FIG. 328.—Retractor for two bones.




FIG. 329.—Retractor for one bone.

The Retractor is made of linen, or ordinary muslin, torn according to the size and anatomical arrangement of the limb to which it is to

be applied. If for two bones, one extremity of the retractor should be torn into three strips (Fig. 328), the middle one to pass between the bones (Fig. 330). If for one bone, the retractor is torn partially through the middle (Fig. 329), and applied as shown in Fig. 331.

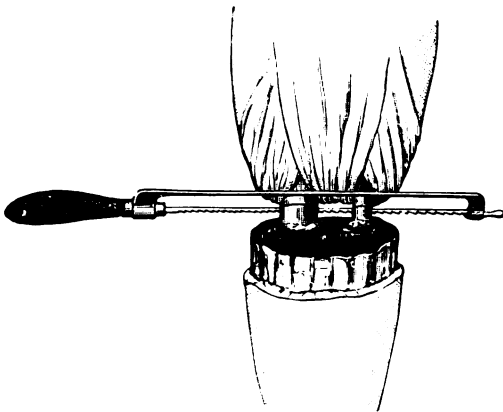


FIG. 330.—Three-tailed retractor applied.

AMPUTATIONS OF UPPER EXTREMITIES.

General Remarks.—

In all the amputations of the hand and fingers, it is important to remember that usefulness and symmetry are the ends to be attained. If strength and usefulness be desiderata, all those points should be preserved into which the muscles and ligaments are inserted, which endow the part with important functions.

It therefore becomes imperative for the surgeon to carefully study the functions of the muscles associated with the hand, and to preserve as carefully as possible their points of insertion. It is a well-established principle that every portion of the hand of a laboring man which possesses motion and can become of service to him should be saved. In the case of one whose circumstances or avocation will permit, the sacrifice of usefulness to symmetry may be made with the concurrence of the patient.

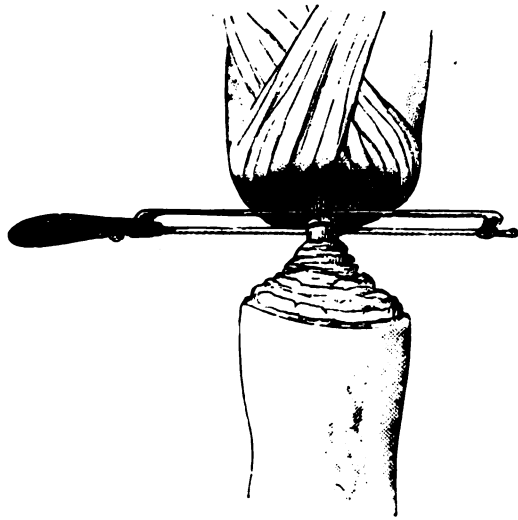


FIG. 331.—Two-tailed retractor applied.

Amputation at the Phalangeal Articulations.—*Surgical Anatomy.*—The first row of surgical phalanges is flexed by the terminal insertions of the flexor profundus digitorum; the second, by the flexor sub-

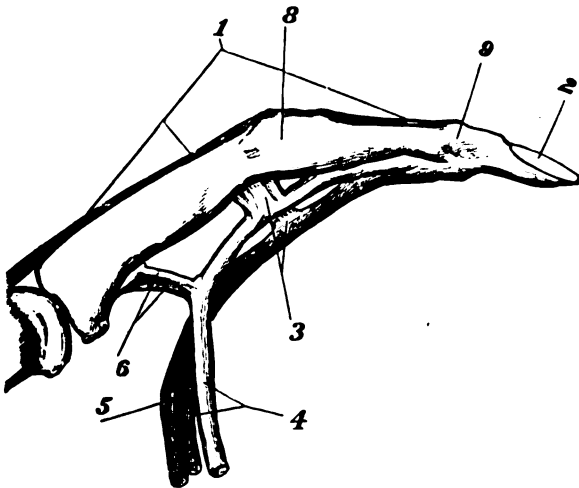


FIG. 332.—Attachments of tendons to phalanges. 1. Extensor communis digitorum. 2. First surgical phalanx. 3. Fibrous bands between common flexor tendons and distal extremity of the third surgical phalanx. 4. Tendons of flexor sublimus digitorum. 5. Tendon of flexor profundus digitorum. 6. Vincula accessoria tendinum. 7. Head of metacarpal bone. 8. Joint between second and third surgical phalanges. 9. Joint between first and second surgical phalanges.

limis digitorum ; the third, by the flexor sublimis, through the *vincula accessoria tendinum* ; by dense fibrous bands connecting the tendons of the flexor sublimis with the distal extremity of that phalanx as it passes across it ; also by the secondary action of the lumbrical muscles (Fig. 332).

The Terminal Phalanx is amputated by seizing and flexing it to a right angle with the second (Fig. 333) ; a transverse incision is then

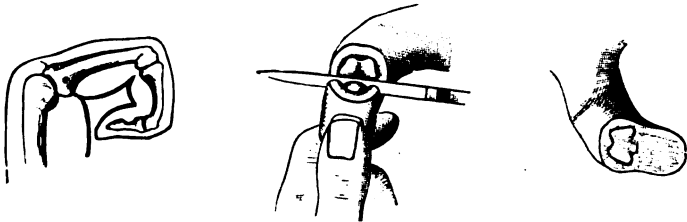


FIG. 333.—Flexed phalanx.

FIG. 334.—Making flap.

FIG. 335.—Flap completed.

made on its dorsal surface, on a line corresponding to the center of the long axis of the second phalanx, which will open the joint ; divide the lateral ligaments with the point of the knife, separate the articular surfaces, and pass the blade between them, then cut along the under surface of the phalanx to be removed, close to the bone (Fig. 334), far enough to make a palmar flap of sufficient length to easily cover the end of the bone (Fig. 335). The rule previously given regarding the length of flaps will enable the operator to meet this requirement. If the attached extremity of the flap be commenced by dividing the tissues at each side of the phalanx, for three or four lines, down to the bone, the knife can follow its under surface without the danger of making the attached end of the flap too narrow, owing to the extremities of

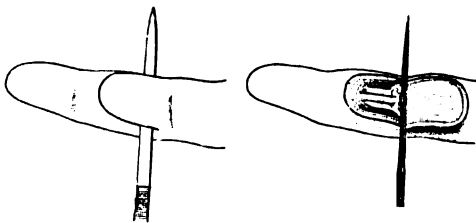


FIG. 336.—Flap by transfixion.

FIG. 337.—Opening joint.

the phalanges being thicker than their bodies. If any of the tissue of the flexor tendon be in the flap, it should be removed. Tie the vessels, place and retain the flap in position by two or three fine sutures and adhesive strips ; or dress antiseptically.

Amputation of the Second Row can be done in precisely the same manner as at the first, or, with the finger extended, by making a palmar flap first by transfixion through the palmar surface opposite the joint, and cutting downward until a well-rounded flap is formed (Fig.

336). Then carry the knife upward between the articular surfaces and through the soft parts on the dorsum (Fig. 337).

Either of the phalanges may be amputated at the center by a short posterior and a long inferior or palmar flap. If the third surgical (first anatomical) phalanges be amputated at the center, the power of flexion is limited to the lumbrical muscle, and the vincular tendons connecting them with the flexor sublimis digitorum (Fig. 332). When symmetry is a secondary consideration, this amputation may be made. In the case of the thumb, the index and little fingers, everything possible adding to the length of the digit should

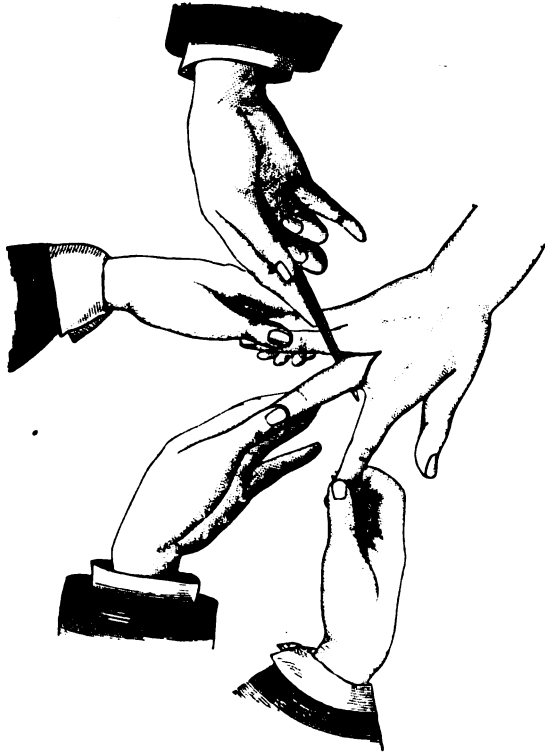


FIG. 338.—Amputating middle finger, oval flap.

be saved, as the range of motion of the thumb and little finger is more extensive than the others, and the presence of the index-finger or its stump greatly aids the crippled thumb in the performance of its functions.

Amputation at the Metacarpo-phalangeal Articulation.—It is recommended by some that this operation be practiced in lieu of amputation at the middle of the third phalanges (surgical) of the second and third fingers, or even disarticulation between their second and third phalanges. I am satisfied, however, that the hand will be far stronger if the stumps be allowed to remain, since they soon become easily flexed and extended, and the continuance of these motions serves to stimulate and nourish the common muscles engaged in them, and thereby strengthens the power of the remaining fingers.

Amputation of the Second or Third Finger.—This is done by the oval flap, which should be marked out before the operation is com-

menced (Fig. 338). The flaps must be taken from the finger to be removed, and should be of generous dimensions. The limit of the incision above corresponds to the head of the metacarpal bone, the lower limit to the transverse line of the palm joining the fingers to the web. Separating widely the contiguous fingers, the surgeon seizes the condemned finger, extends it well, and carries the incision transversely along the line beneath, then in a curved direction upward, along the side of the finger to the head of the metacarpal bone. This incision is repeated on the opposite side; the tissue carefully divided, and the finger removed (Figs. 338, 339). Better drainage will be secured if this flap be reversed by forming its retiring angle on the palmar instead of the dorsal surface of the hand (Fig. 340).

Lateral-Flap Operation.—This is best adapted to the thumb, index, and little fingers (Fig. 340); it can, however, be employed at the ring and middle fingers. The limit of the dorsal incision is the same as in the preceding. The lower limit, after crossing the trans-

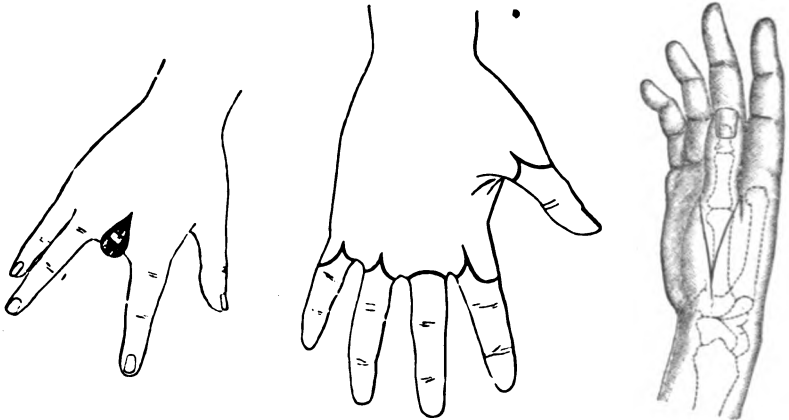


FIG. 339.—Finger removed.

FIG. 340.—Lateral-flap method.

FIG. 341.—Oval method.

verse line of the web, extends toward the palm about a third of an inch. The flaps are taken from the sides of the finger to be removed.

In the case of the middle and ring fingers the flaps should be equilateral. For the thumb, index, and little finger, that portion of each against which pressure is most liable to be brought should be covered by a longer flap, which is taken from the outer surface of the index-finger, from the inner surface of the little finger, and from the palmar aspect of the thumb, the base of the flap being on a level with the joint. The longer one is dissected off, after which the smaller one is made. Divide the ligaments and tendons, and remove the member.

Amputation of the Thumb at the Carpo-metacarpal Articulation.
—*Oval Method.*—This can be employed equally well upon the thumb,

index, and little fingers. The limit of the dorsal incision in either instance is the proximal extremity of the metacarpal bone to be removed. Its palmar limit is the transverse line at the junction of the finger with the palm. Begin the first incision at the base of the metacarpal bone of the thumb (Fig. 341), carrying it along in a slightly curved direction to the outer side of the metacarpo-phalangeal articulation; then inward through the line of the web. The second one joins the first near the base of the metacarpal bone, and takes a corresponding course along the inner side, meeting the former at the inner extremity of the transverse line of the web. The flaps are dissected off, and the articulation between the metacarpal bone and the trapezium is opened from the ulnar side, to avoid injuring contiguous joints (Fig. 342). The union of the flaps leaves a linear cicatrix (Fig. 343).

The Lateral-Flap Method (Fig. 344).—This method can be more quickly and easily performed than the former, but leaves the cicatrix in a less advantageous situation. Abduct the thumb and enter the knife between the first and second metacarpal bones; carry it up between them with a sawing motion, till the head of the first is reached.

Cautiously disarticulate it from within outward; increase the abduction, and carry the blade through the joint and along the outer side of the metacarpal

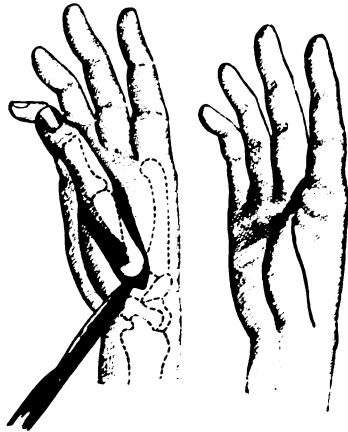


FIG. 342.—Opening joint. FIG. 343.—Flaps united.



FIG. 344.—Lateral-flap method.

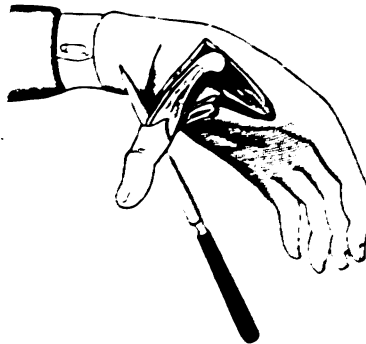


FIG. 345.—Making outer flap.

bone, making the outer flap, which should terminate opposite the web of the thumb (Fig. 345).

The bases of the metacarpal bones of the index, middle, and little fingers should be preserved in all possible instances, as they afford attachment to the important extensor and flexor muscles of the carpus.

Amputation through the Metacarpal Bones.—In amputation through two or more of these bones, the principal flap should be taken from the palmar surface, although it may be taken from the border and palm of the hand (Fig. 346). If through but one bone, the

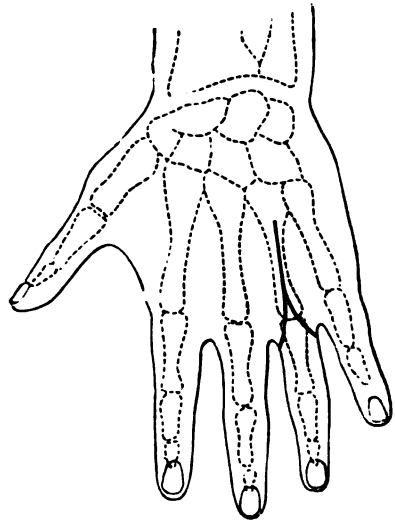
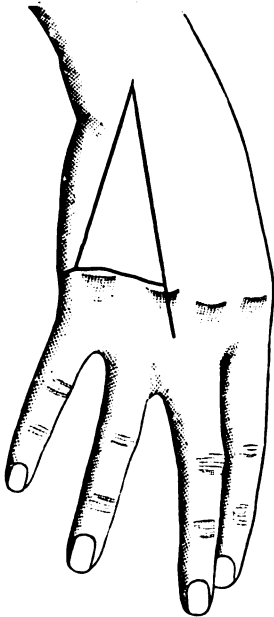


FIG. 346.—Amputation through fourth and fifth metacarpal bones.

FIG. 347.—Amputation through one metacarpal bone.

incisions are the same as those for amputation at the metacarpo-phalangeal articulation by the oval method, the only difference being that their upper limit will correspond to the point of proposed section of the bone (Fig. 347). The bone is exposed by reflection of the soft parts upon the point of proposed section, after which it is sawn through with either a chain- or metacarpal bone-saw, separated from its palmar connections and removed with the finger attached. If a saw be not convenient, the cutting bone-forceps (Liston) can be used, although with some risk of splintering the bone. This operation is often performed in preference to disarticulation at its head, in order to give symmetry to the hand (Fig. 348).

The division of the transverse ligament, which extends between the heads of the metacarpal bones, lessens the strength of the grip.

This operation is, therefore, not to be recommended except in those of sedentary habits.

Amputation of the Last Four Metacarpal Bones (*Disarticulation*). (Fig. 349).—Make a semilunar flap from the palm by a curved incision, beginning at the web of the thumb and terminating at the ulnar border of the fifth metacarpal bone. This flap can be made by transfixion, if desired (Fig. 350). The dorsal incision (Fig. 351) begins

at the same point of the web of the thumb, and is carried to the upper third of the metacarpal bone of the index-finger, and

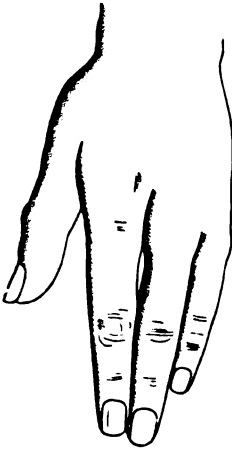


FIG. 348.—Appearance of hand after amputation through third metacarpal bone.

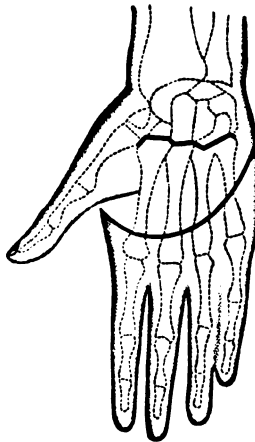


FIG. 349.—Line of palmar flap.

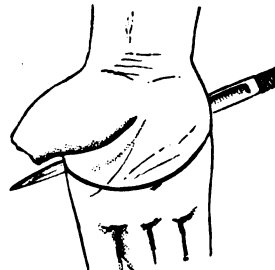


FIG. 350.—By transfixion.

from there transversely across until it meets the ulnar extremity of the first incision. The flaps are now reflected up to the carpo-metacarpal joint, the hand strongly abducted, and the carpo-metacarpal joint opened from the ulnar side, using great caution not to injure the trapezium and the metacarpal bone of the thumb. Without the thumb this operation would be of little avail in securing a useful stump. Unite the flaps with interrupted sutures, introduce a drainage-tube (Fig. 352), and treat antisepsitically.

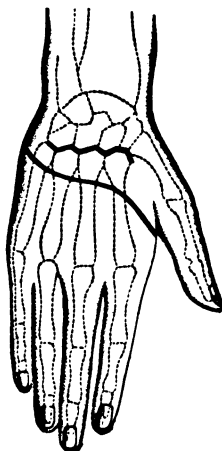


FIG. 351.—Line of dorsal flap.

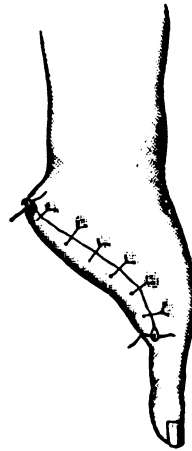


FIG. 352.—Appearance of stump.

The results of amputations of the thumb and

fingers are favorable ; only three to six per cent, and even less, with antiseptic precautions, die.

Amputation at the Wrist (*Disarticulation*).—The bones entering directly into this articulation are the radius, scaphoid, and semilunar. The location of the joint can be determined, 1, by forcibly bending the carpus backward, when the summit of the angle on the dorsal surface formed by the hand and forearm indicates the radio-carpal joint ; 2, by drawing a line transversely from one styloid process to the other—the joint is about one fourth of an inch above it. This operation can be done by either the circular, single palmar or radial flap, or by the double-flap method.

The Circular Method.—Ascertain one fourth of the circumference

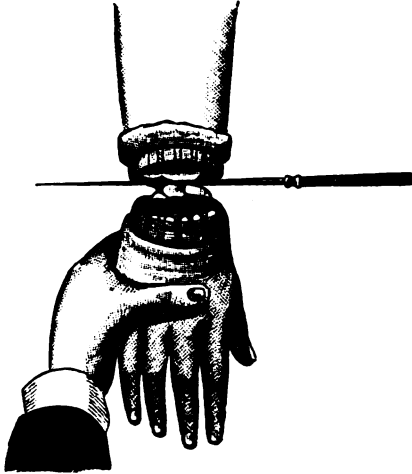


FIG. 353.—Circular method.




FIG. 354.—Flaps united.

at the articulation. Measure this distance downward from the articulation, and divide the soft tissues at that point by a circular incision ; dissect up the sleeve of integument until opposite the joint ; pronate and forcibly flex the carpus, and open the wrist-joint on the dorsal surface by an incision extending between the styloid processes ; divide the lateral ligaments, pass the blade through the articulation, and sever the remaining structures (Fig. 353). Unite the flaps in the long axis of the joint, introduce drainage-tubes and sutures, and dress antiseptically (Fig. 354).

Double-Flap Method (Ruysch).—Mark out the distal limits of the circular method ; flex and pronate the hand ; carry a circular incision over its dorsum, beginning at the styloid process of the radius and extending to the circular line indicating the dorsal extension of the flap, terminating at the radial styloid process (Fig. 355).



FIG. 355.—Making dorsal flap.




FIG. 356.—Making anterior flap.

Dissect up the flap, allowing the tendons to remain; flex the carpus firmly, and open the articulation, as in the circular method; carry the blade of the knife through the articulation (Fig. 356) and make the anterior flap by cutting outward.

Single Palmar Flap.—This method is easily performed, and makes as serviceable a stump as any. Mark out a flap on the palmar surface, semilunar in shape, and about three inches and a half in length, its base being located just below the apices of the styloid processes (Fig. 357); reflect it upward; divide the remaining tissues in front of the articulation; open it, passing the knife through, and making a short dorsal flap. The dorsal flap can be made first, the joint opened from behind, and the long anterior flap cut from the joint outward.

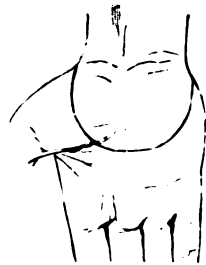


FIG. 357.—Single palmar flap.

Radial Flap (Dubrueil).—Mark out a flap, semilunar in shape, the base of which shall embrace the radial third of the carpus, corresponding to the base of the second phalanx of the thumb (Fig. 358). Separate the thumb-flap, then connect the extremities by an incision carried transversely around the ulnar side, draw the skin upward, open the joint as before, remove the carpus, and properly adjust the flaps and drainage-tube (Fig. 359).

Results.—The rate of mortality in amputation at the wrist-joint is from fifteen to thirty per cent for gun-shot wounds, being about eight per cent greater than for amputation through the forearm.

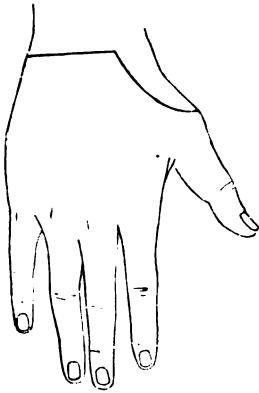

FIG. 358.—Radial flap.

It therefore follows that amputation at the wrist-joint can not be recommended, on the ground of safety to the patient. There are other objections of less importance, which, with the one just stated, should place the operation in disfavor with the surgeon. It makes a stump which, owing to the feebleness of the circulation in the flaps, becomes cold and even chilblained; in addition, its extremity is bulbous, thereby interfering with the application of the properly fitting sockets connected with artificial appliances.

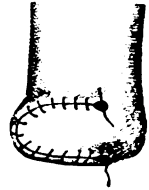


FIG. 359.—Appearance of stump.

Amputation of the Forearm.—The forearm is best amputated by the circular-flap method; although the equilateral skin, and musculo-cutaneous flaps are often employed.

Circular Amputation.—Carefully lay out the length of the proposed flap, based on a fourth of the circumference. Divide the tissues by a circular incision down to the fascia surrounding the muscles; the integumentary cuff is then dissected upward by repeated incisions directed toward the fascia surrounding the muscles.

If the cuff be too small to be turned up readily, its most dependent part when dressed can be slit up. After the flap is reflected sufficiently, the muscles are divided half an inch or so below the line of its reflection by a circular sweep of the knife down to the bone, the bone sawn off, and the wound dressed in the usual manner. The interosseous membrane and its vessels should be divided a short distance below the point of proposed bone section and its borders separated from those of the contiguous bones up to the point of section. This avoids the risk of cutting the vessels too short, as when they are divided at a level with the bones, which permits them to retract above the point of easy access. These remarks apply with equal force to amputation of the leg.

The Equilateral Skin-Flaps are raised from the anterior and posterior, or internal and external surfaces of the forearm; the latter being by far the most frequently adopted. Their length is determined in the same manner as in the circular; in fact, if the circular be first done, and the angles of the cuff trimmed off down to near the site of the muscular section, the lateral flaps will be formed. It is better, however, to mark out their outlines before beginning them; since, to make each with the same curve and same breadth of base is not an

easy task without this precaution. The remaining procedures are the same as those of the circular method.

The Musculo-Cutaneous Flaps are made by transfixion and cutting outward; in other respects the steps do not differ from the preceding operation.

Results.—The rate of mortality in amputation of the forearm is about fifteen per cent for all causes.

Amputation at the Elbow-Joint (*Disarticulation*).—The methods commonly employed are the circular and the single flap. Before operating, carefully define the most prominent portions of the condyles. Just below the outer, is felt the movable head of the radius; about an inch below the inner, the ulna joins the inner condyle; the articulation is therefore oblique, the inner portion being about half an inch the lower, owing to the inner condyle being that much longer than the outer.

Circular Method.—Lay out the flaps in the usual manner, measuring around the condyles. Divide the superficial tissues down to the

fascia surrounding the muscles, as before; dissect the flap upward to a level with the joint,

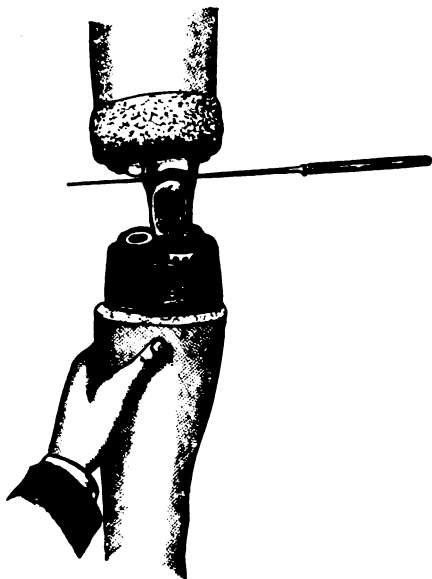


FIG. 360.—Amputation at elbow-joint.




FIG. 361.—Circular amputation at elbow.

the bony indications to which should be carefully determined. Forcibly extend the arm and make an incision on the line of the articulation (oblique) down to and into it; sever the internal and external lateral ligaments, and press the arm still farther backward; draw the

olecranon process forward into the wound, and sever its connection to the triceps (Fig. 360). Unite the borders of the flap as indicated in the figure (Fig. 361). The flaps can also be united from before backward, which causes the cicatrix to fall *between* the condyles, and likewise increases the drainage facilities—two very important indications.

The Single-Flap Method.—This flap can be made either of integument and subcutaneous tissue alone, or be musculo-cutaneous, and formed by transfixion. In either instance it should be taken from the anterior surface of the forearm. If made by transfixion (Fig. 362), supinate and flex the forearm slightly, raise the soft parts in front of the joint, and enter the knife an inch below the inner condyle, pass it in front of the bones obliquely outward, causing it to escape about one inch and a half below the outer condyle. Cut the anterior flap downward and outward, making it about three inches and a half in length; dissect and draw the flap up to a level with the joint in front. Make the posterior flap by connecting the extremities of the first incision by a transverse one (Fig. 363), and dissect this up, after which the joint is opened in front; the lateral ligaments divided, olecranon process displaced forward, and the triceps cut off. It is advisable, when possible, to saw off the olecranon, allowing it to remain with the triceps attached. The stump will be stronger if it be possible to sever the ulna below the insertion of the brachialis anticus, allowing the fragment to remain along with its muscular attachments. In amputations near the elbow, the tubercle of the radius, together with the biceps tendon inserted into it, should be carefully preserved.

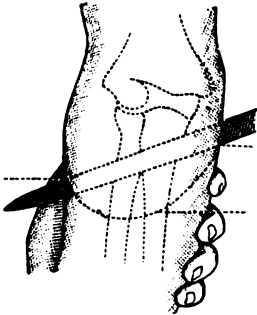


FIG. 362.—Flap by transfixion.

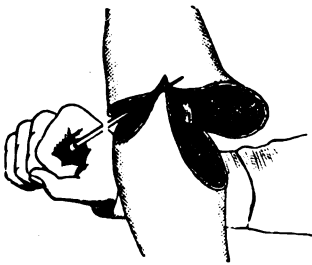


FIG. 363.—Making posterior flap.

Results.—The deaths from this amputation vary from thirteen to twenty per cent without antiseptic treatment.

Amputation of the Arm.—Either the circular, double flap, or the single circular incision method of Celsus can be employed. The former is usually preferred. In the second, the flaps may be antero-posterior, or lateral; integumentary alone, or combined with muscular tissue. The single circular operation is seldom employed at the arm.

Circular-Flap Method.—Plan the length of the flap upon the cir-

cumference of the limb at the point of proposed section. Divide the superficial tissues down to the muscular fascia, and turn the flap up as elsewhere ; then divide the muscles down to the bone, about an inch below the reflection of the flaps. Apply the two-tailed retractor, saw through the bone opposite the point of reflection of the flap, and unite the flaps in the direction best calculated to provide dependent drainage.

Unequal Double-Flap Method.—If skin alone be used, the flaps should be carefully mapped out upon the integument of the arm, in the general manner before described. Dissect them up, and make a circular section of the muscles down to the bone ; unite the flaps, and dress the stump as before.

If Musculo-Cutaneous Flaps (Langenbeck) be desired, they can be made by transfixion from within outward, or with a scalpel from without inward. The latter plan secures the more uniformity of outline

in the flap. If they are to be made from without inward, first mark them out carefully, then with a sharp scalpel form them as planned (Fig. 364) ; when dissected up the desired

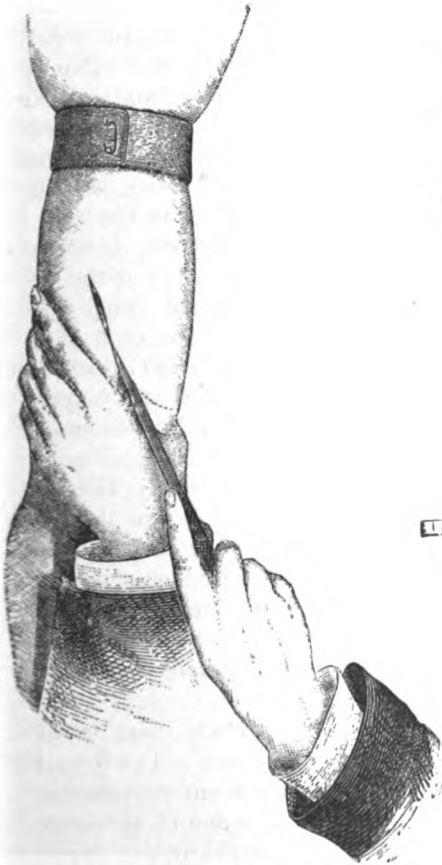


FIG. 364.—Langenbeck's method.

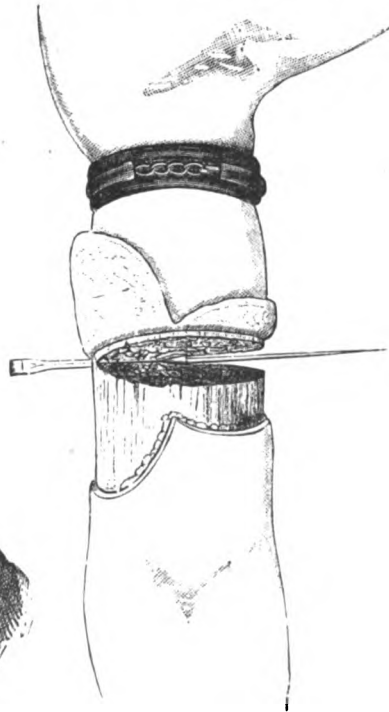

FIG. 365.—Unequal skin-flaps.

distance, complete the operation by dividing the muscles as before.

Large Anterior and Small Posterior Skin-Flaps are sometimes

made (Fig. 365), also a large anterior one, with a posterior circular incision (Fig. 366). They possess the advantage of good drainage, and of placing the cicatrix where it is well removed from irritation. The outline of these flaps can be easily estimated on the same basis as if they were to be equal in length—viz., if one be proportionately increased in length, the other is to be shortened.

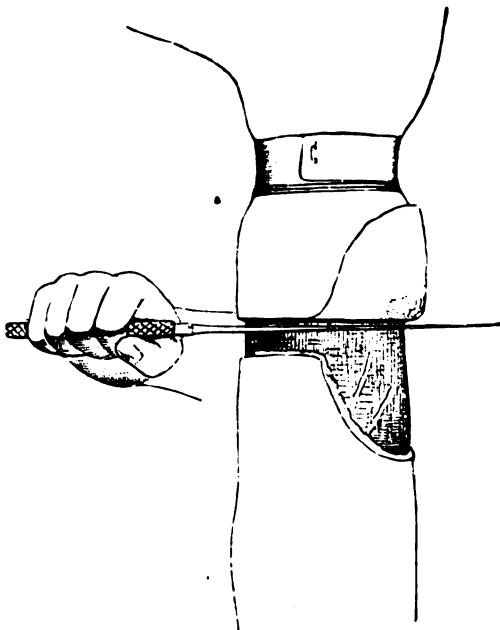


FIG. 366.—Long anterior flap.

Results.—The death-rate from amputation of the arm varies somewhat according to the seat of the operation. It is about eighteen per cent when done in the *upper* third, sixteen per cent at the

middle third, and about twenty-six per cent at the *lower* third—the greater per cent in this situation being due, no doubt, to the greater degree of injury calling for it at this point. If done for disease, the percentage would no doubt be reversed.

Amputation at the Shoulder-Joint (*Disarticulation*).—There are various methods recommended for amputation at this joint. It is hardly necessary to enter into the details of more than two or three of those commonly recognized and employed. The remainder, while ingenious in many instances, do not present differences of enough practical worth to be introduced into a hand-book of operative surgery.

Amputation by Internal and External Flaps (Dupuytren).—Place the patient on the edge of the table, partially upon the healthy side, with the body raised. An external oval flap is made by an incision extending from the coracoid process downward and outward to the insertion of the deltoid; then upward and backward, terminating at the junction of the acromion process with the spine of the scapula (Fig. 367). The flap, including the deltoid muscle, is now raised as far as the acromion, turned back, and the capsule of the joint exposed,

the head of the humerus pushed upward, capsule divided above ; then the arm is rotated outward and the subscapularis severed ; then inward, followed by the rapid division of the external rotators attached to the greater tuberosity. While the arm is rotated internally, the capsule is still further divided, together with the tendon of the long head of the biceps, the head of the humerus tilted outward, and the blade of the knife passed beneath it (Fig. 368) ; the head of the bone is then seized and drawn outward, and the knife carried along its inner surface until within about four inches below the axillary fold, when its edge is turned inward and the flap completed. The last sweep of the knife severs the principal vessels, and this flap should be



FIG. 367.—Disarticulation of shoulder-joint.

seized by an assistant and tightly grasped before it is completed. The vessels in this operation are controlled by either pressure upon the third portion of the subclavian, or by the elastic band arranged as

shown in the illustration. The appearance of the wound after the operation is apparent from Fig. 369.

Amputation by Circular Incision.—Control the circulation as before. Abduct the arm and make a circular incision entirely around it through all the tissues, down to the bone, at a point corresponding to the insertion of the deltoid. Saw off

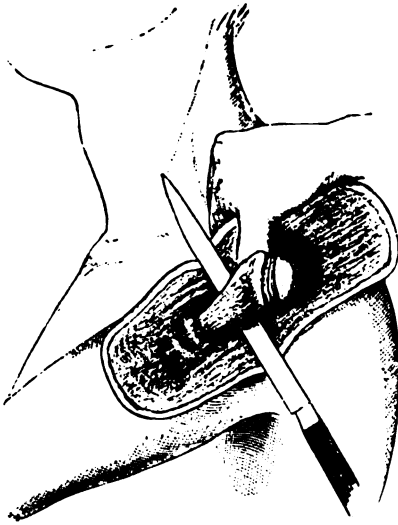


FIG. 368.—Making inner flap.

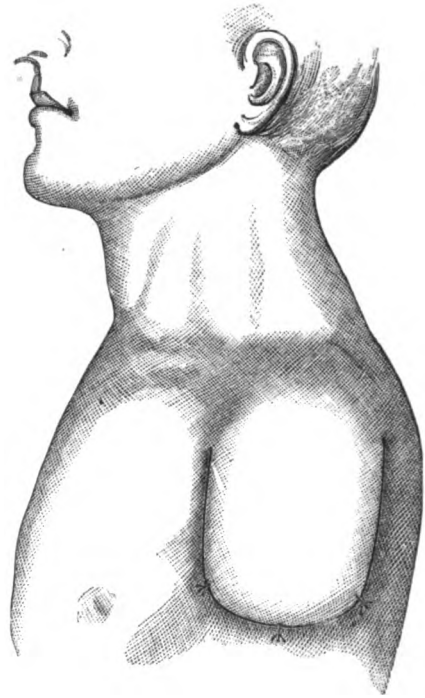


FIG. 369.—Flaps united.

the bone and ligature the vessels. Make a second incision longitudinally, from the anterior border of the acromion, the whole length of the stump, down to the bone. The bone is then held firmly and the soft parts separated from it (Fig. 370), after which it is rotated outward, then inward, to admit of the division of the muscular and fibrous attachments to its head, when it can be removed. This is a good operation and well calculated to provide favorable drainage (Fig. 371), and is done with a minimum amount of injury to the soft parts. If the periosteum be separated from the bone without disturbing the surrounding soft parts, there will be less danger of the extension of inflammatory action beyond the line of the longitudinal incision; moreover, a greater degree of firmness will be given the stump, even though new bone be not produced.

Oval Method (Larrey).—This method is well thought of, and is performed by making a vertical incision from the extremity of the acromion process, with the arm extended, about three inches in

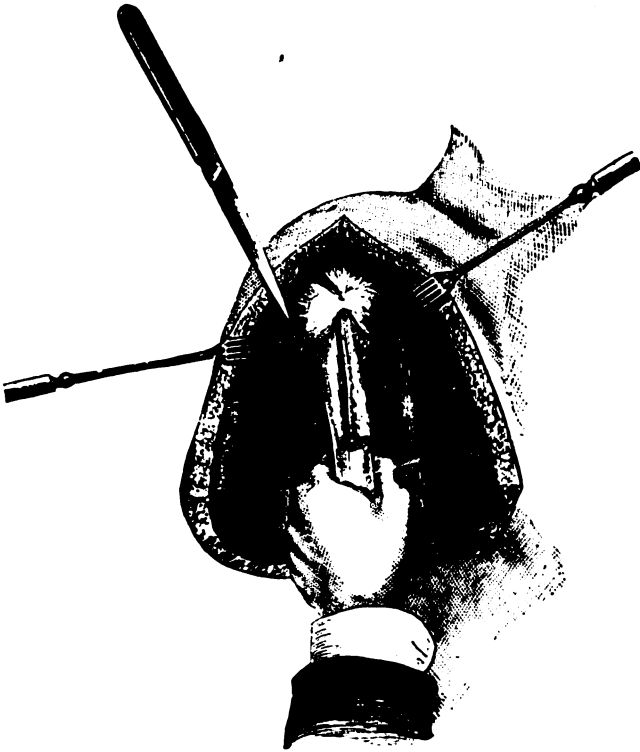


FIG. 370.—Removing the bone.

length down to the bone ; this incision should terminate about one inch below the head of the humerus. Two oblique incisions are then made, each beginning near the middle of the vertical cut, one on the anterior and the other on the posterior aspect of the limb ; these, when carried through the structures composing the anterior and posterior walls of the axilla, to the lower border of each, divide their attachments to the humerus (Fig. 372). The soft parts at the inner side of the humerus still remain undivided. The borders of the wound are now drawn apart, the joint exposed and opened above ; the bone drawn downward to separate the joint surfaces, and the blade of the knife passed between them, behind the luxated bone, and the operation completed by cutting the remaining tissues at the inner side of the humerus intervening between the lower extremities of the incisions previously made (Fig. 373).

Spence's Method has attracted considerable attention, and is certainly entitled to additional consideration.

It does not possess any practical advantages over the method by circular incision. It is done in the following manner : Abduct the

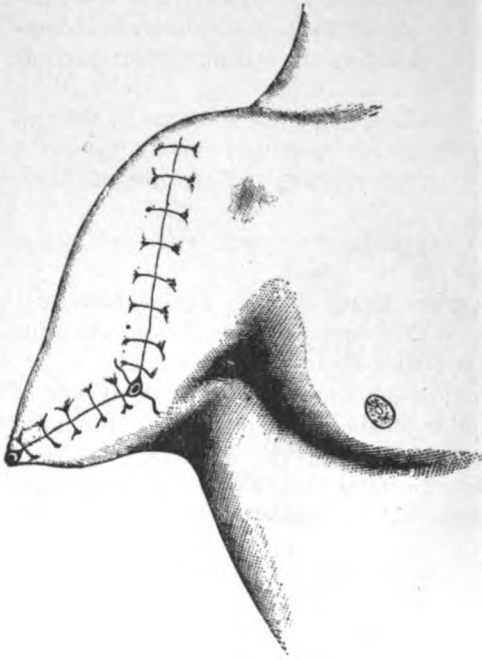


FIG. 371.—Flaps united.

arm slightly; rotate the humerus outward; cut down upon the head of the bone, beginning immediately external to the coracoid process, thence directly downward through the fibers of the deltoid and pectoralis major to the lower border of the latter, which is divided; carry the incision with a gentle curve outward across and through the lower fibers of the deltoid, to, but not through, the posterior border of the axilla (Fig. 374). Begin the inner incision at the lower extremity of the vertical one, carry it around the inner side of the arm, through the skin and fat only, to meet the one made at the

outer side. If the fibers of the deltoid have been thoroughly divided,

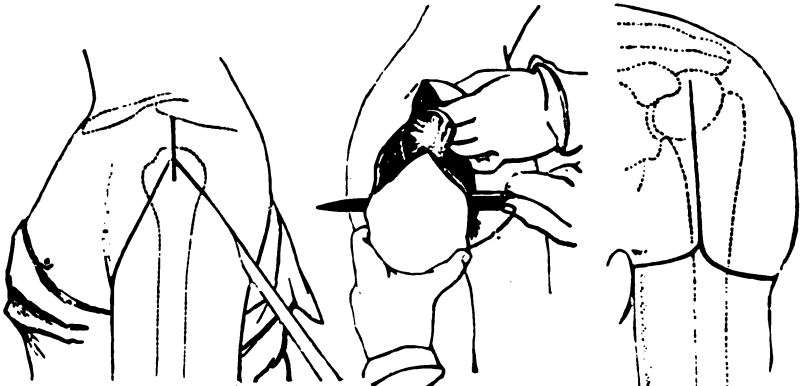


FIG. 372.—Larrey's method.

FIG. 373.—Forming inner flap.

FIG. 374.—Spence's method.

the flap, together with the posterior circumflex artery, can be easily separated by the finger from the bone and joint, and drawn upward

and backward until the head of the bone is exposed ; then the ligaments and muscular attachments are divided, disarticulation accomplished, and the limb removed by dividing the remaining soft parts at the axillary aspect.

In very muscular subjects, a redundancy of that tissue in the flap can be avoided by dissecting the integument and subcutaneous tissues a short distance upward over the deltoid, and dividing its fibers high up.

Results.—The rate of mortality varies from twenty-five to thirty-eight per cent for gun-shot injuries.

Amputation above the Shoulder-Joint.—It may become necessary, on account of malignant growths and severe injuries, to amputate the scapula together with a portion or the whole of the clavicle.

The operation is often tedious and attended with great loss of blood. Inasmuch as the situation of the disease or injury calling for it will modify the location and direction of the incisions, no definite plan can be prescribed. However, the aim should be always to save enough healthy integument to cover the wound and to avoid hemorrhage.

Results.—Fifty-one cases are reported, with a mortality of twenty-five and a half per cent.

CHAPTER X.

AMPUTATIONS OF THE LOWER EXTREMITY.

No better or more comprehensive statement can be made bearing on the duty of the surgeon in amputations of the lower extremity, than that "under all circumstances, except where poverty, advanced age, and confirmed dissolute habits so combine in the individual as to render it certain that mechanical appliances would be of little service, give the patient the stump best adapted to the most useful artificial limbs. In all amputations of the lower extremity, the surgeon should be governed in the selection of the point of operation and the method to be adopted by the mortality of the operation in question ; by the adaptability of the stump to the most serviceable artificial limb for locomotion."*

Amputation of the Phalanges in their Continuity, or through the articulations, is done by the same rules as those applied to amputation of the fingers. In the case of the toes, however, it is often difficult

* From report of Drs. Valentine Mott, Gurdon Buck, John Watson, A. C. Post, Willard Parker, Ernst Krackowizer, W. H. Van Buren, and Stephen Smith.

to open the joints on account of the changes induced in them, and in the contour of the bones, by the pernicious influence of illy fitting boots and shoes. The flaps are made from the plantar surface. In amputation at the metatarso-phalangeal articulations, remember the relation of the web to the joints in question, the former being a considerable distance below the latter (Fig. 375).

Amputation of Single Toes (*Disarticulation*).—They can be removed by the oval or by the lateral-flap method. The former is the better, and is done by first grasping the condemned toe, while the assistant pulls aside its fellows. Commence the incision on the dorsum over the joint, carry it downward along the side of the phalanx to be removed, beneath

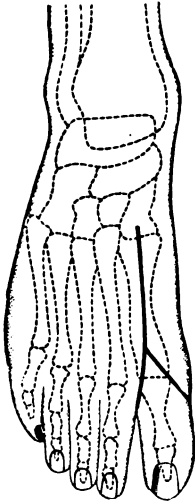


FIG. 375.—Incision for amputation at metatarso-phalangeal articulation.

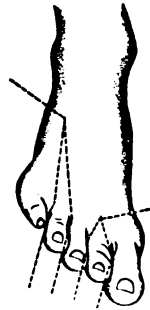

FIG. 376.—Removal of single toe.

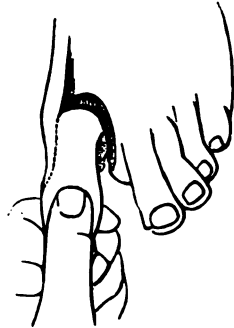


FIG. 377.—Lateral-flap method.

the toe through the line of the web to the sole of the foot. A second incision is then made of a similar extent and outline on the opposite side of the toe, down to the bone (Fig. 376). The ligaments are divided, the tendons are cut off, and the bone removed by cutting from below. If the extremities of the divided tendons remain exposed, they are pulled down and severed on a level with the divided border of the soft parts.

The removal of either the second, third, or fourth toes can be effected by making a transverse incision on the dorsum over the joint, and passing the knife through it and along the under surface of the bone a sufficient distance to make the necessary plantar flap, which is turned upward and united. If it be required to remove the whole or part of the metatarsal bone of either of these toes, the dorsal incisions of the oval flap for disarticulation have only to be extended upward on the dorsal surface of the bone to be removed, to the point of intended section (Fig. 376).

The lateral flap is better for the disarticulation of the great and

le toes (Fig. 377), and is made by abducting the toe and entering a knife vertically between it and the contiguous toe, and cutting through the web of the foot along the line of circulation is reached, when the knife is turned outward on the median line of the foot, the incision is opened, the blade passed through it, and the lateral flap made of sufficient length by cutting

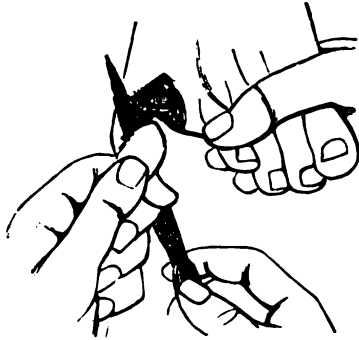

FIG. 378.—Completion of operation.

along the opposite side of the toe (Fig. 378) to be removed. The importance of the great toe as a lever in propelling the body, requires that amputation through its phalanges be practiced when possible. With the remaining toes, however, it is not a matter of so much importance.

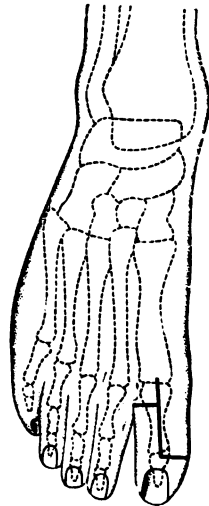


FIG. 379.—Square-flap method.

The prominent head of the metatarsal bone of the great toe, which remains after disarticulation, has so frequently become the seat of painful bunions, that many surgeons of prominence advise that the bone be amputated behind its head by either a transverse or oblique section of its shaft. Of one fact there can be no doubt: if that portion of the boot or shoe in contact with this stump be not fitted to it and kept elevated by some means, the leather will in a short time press upon it, cause great annoyance, and cripple the patient unnecessarily.

The great toe can be amputated by a large square internal flap (Fig. 379) and by the oval method (Fig. 375). Begin the longitudinal incision at the outer side of the extensor tendon a little below the joint; carry it through the tissues down to the first phalanx (surgical); make a transverse incision from the termination of this one around the inner side of the toe to a point opposite, on the plantar surface; extend the toe and make another incision from the termination of the last toward the foot along the outer side of the tendon of the flexor longus pollicis to the web; connect this with the center of the dorsal one by a transverse cut carried around the outer side of the base of the toe; dissect off the flaps and divide the ligaments and the remaining soft parts from within outward. The oval method is performed in a similar manner to the same method when applied to the fingers.

Amputation of Two Adjoining Toes.—Begin the dorsal incision between the metatarsal bones of the toes to be removed, just below

the joint, where the bones are to be divided ; carry it to the outer side of one of the toes to be removed, taking a good-sized flap from it, thence through the digito-plantar fold to the outer side of the remaining toe, back to the point of starting. Remove each toe separately in the usual manner, and close the wound.

Amputation of all the Toes at the Metatarso-phalangeal Joint (Disarticulation). —

Forcibly extend the toes with the left hand, and make a curved incision on the plantar surface from the inner side of the articulation of the great toe, to the outer side of the corresponding joint of the little toe, carrying it through the groove between the sole of the foot and the base of the toes (Fig. 380). Flex the toes and join the first incision by a similar one across the dorsum (Fig. 381). Dissect up the flaps, expose the joints, and remove each toe separately, allowing the sesamoid bones of the great toe to remain. If the flaps be too short, the heads of the metatarsal bones should be cut off sufficiently to permit proper adjustment, and the

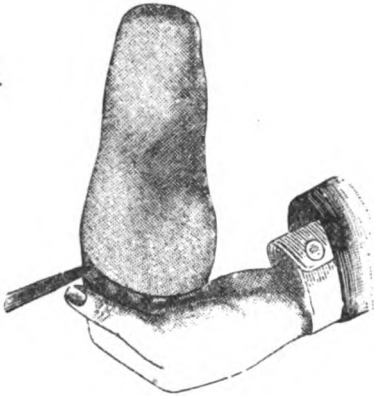


FIG. 380.—Plantar incision.

main. If the flaps be too short, the heads of the metatarsal bones should be cut off sufficiently to permit proper adjustment, and the

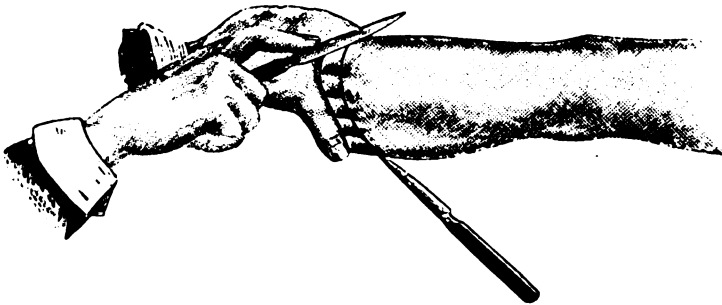


FIG. 381.—Dorsal incision.

divided surfaces united. When recovery takes place, the foot presents the following appearance (Fig. 382).

Amputation through all the Metatarsal Bones.—This is best done by a short dorsal and a long plantar flap. Make the plantar flap first, dissecting the tissues backward down to the bones, from the junction of the toes with the sole, to the point of amputation. A short dorsal flap is then made with the convexity downward, its extremities being united to those of the preceding. Divide the interosseous tissues with

a sharp, narrow-bladed knife; introduce a carbolized six-tailed retractor (Fig. 383), draw the soft parts upward, and divide the bones

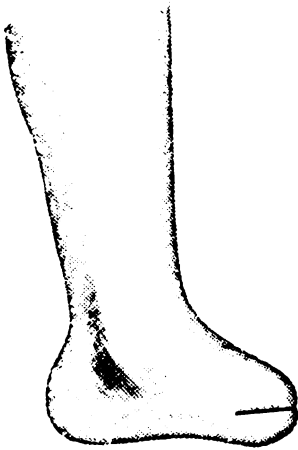

FIG. 382.—Appearance of stump.

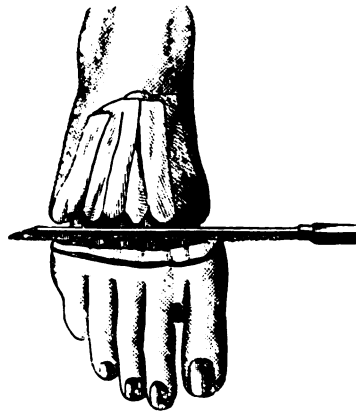


FIG. 383.—Sawing the bones.

with a fine saw, and turn the plantar flap upward and unite it in the usual manner.

Amputation of the Great Toe with its Metatarsal Bone.—This is best done by the oval method (Fig. 384), which is similar to that for removal of the thumb. It is recommended, on account of the width of the base of the metatarsal bone, to make a short transverse incision across it at the joint; remove the flap, thereby exposing the whole length of the bone; open the joint on the dorsal aspect, separate its remaining connections, and remove it.

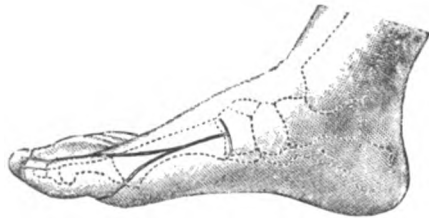


FIG. 384.—Amputation at proximal end of metatarsal bone.




FIG. 385.—Amputation of little toe and metatarsal bone.

Amputation of the Fifth Toe, with the Metatarsal Bone.—This can be done by either the *oval* or *lateral-flap* method; the steps of the former being in all respects substantially similar to those for the removal of the great toe.

The lateral-flap method is done by separating the

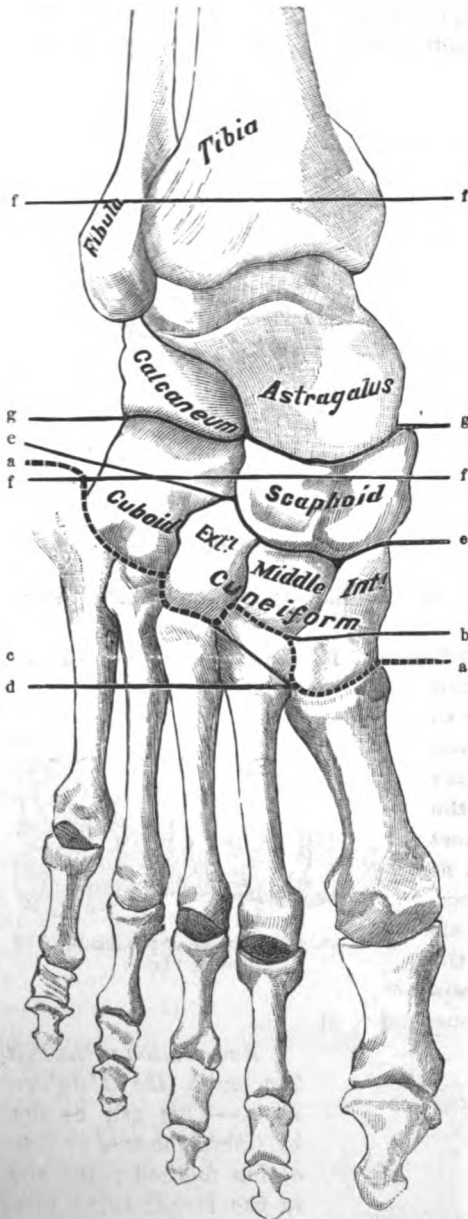


FIG. 386.—*a*, *a*. Line of Lisfranc's amputation. *b*. Line of Hey's modification of Lisfranc's amputation. *c*. Line of Skey's modification of Lisfranc's amputation. *d*. Line of Baudens' modification of Lisfranc's amputation. *e*, *e*. Line of Forbes' amputation. *f*, *f*; *f*, *f*. Lines of Miculicz's amputation. *g*, *g*. Lines of Chopart's amputation.

fifth from the fourth toe, at the same time carrying a narrow-bladed knife upward between the metatarsal bones from the web, until it is obstructed, when the knife is withdrawn and the incision prolonged upward on the dorsal and plantar surfaces in a straight line about one inch. Strongly abduct the metatarsal bone to be removed, separating it from its fellow and from the cuboid; carry the knife around the base to the outer side, and so on downward to the metatarso-phalangeal articulation (Fig. 385); remove the bone, and the tongue-shaped flap just made will fit the intermetatarsal incision.

Amputation at the Tarso-metatarsal Joints (Lisfranc's).—It will very much expedite matters, save considerable annoyance to the operator, and preserve the edge of his knife, if the relations of the bones entering into the joints be fully noted before attempting to open them (Fig. 386). The articulation between the cuboid and the fifth metatarsal is seen to be to the inner side of its tuberosity.

The joint of the internal cuneiform and the metatarsal bone of the great toe is about an inch

and a half in front of the tuberosity of the scaphoid, and the head of the second metatarsal bone is lodged between the three cuneiform bones. In every instance these joints must be carefully located.

Operation.—Raise the foot and mark out a large semilunar flap on the plantar surface, the base of which shall correspond to the distance between the joints just indicated, and its distal extremity to the heads of the metatarsal bones. Extend the foot, and make a short dorsal flap with the convexity forward, and its base corresponding to that of the plantar flap (Fig. 387). Draw the small dorsal flap upward, and commence the disarticulation at the outer side of the tarsus; strongly extend and adduct the bones, which will better mark the outlines of the articulation; separate the fifth, fourth, and third articulations; skip the second and open the first. The articulation of the second with the cuneiform bones is peculiar, in that it is about two fifths of an inch higher (Fig. 388);

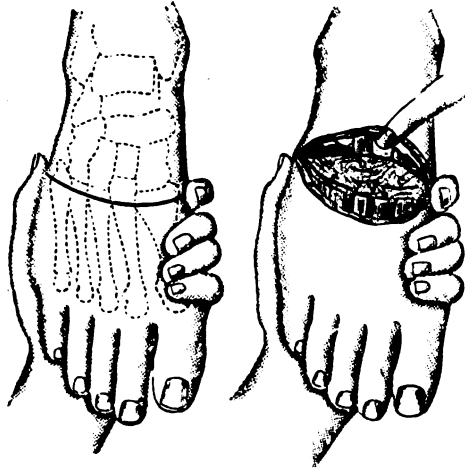


Fig. 387.—Dorsal flap. Fig. 388.—Articulation of second metatarsal.

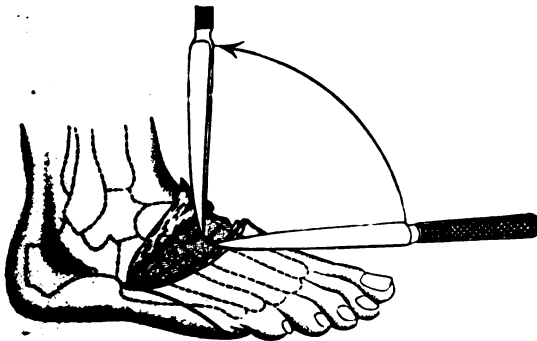


Fig. 389.—Separating second metatarsal.

however, with the bones depressed, a short transverse incision liberates its dorsal connections with the middle cuneiform, after which it is disconnected from the internal and external cuneiform bones, as well as its contiguous metatarsal, by cutting upward (Fig. 389). Open the joint well, divide the ligaments on the side and plantar surface, carry the knife along the sole, and make the plantar flap as previously laid out (Fig. 390). If all the muscular tissues of the sole be removed, it will be too bulky; a part should therefore be omitted from it.

The plantar flap may be made by transfixion, before the articulations are opened ; this method can not be recommended, however, as

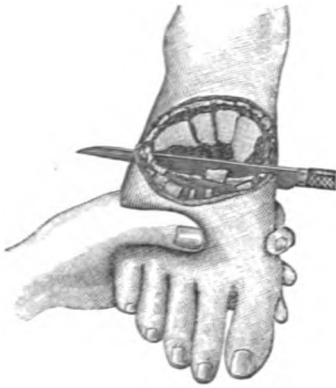

FIG. 390.—Making plantar flap.

the flaps thus formed must await the completion of the operation without facilitating it. Moreover, if the plantar flap be made by transfixion, before disarticulation, the transverse arch of the foot will be intact, causing the center of the flap to be made thin, since the knife can not come sufficiently close to other than the first and fifth metatarsal bones. After the removal of the part, the flap appears as seen in Fig. 391. This method has been variously modified, the modifications, in some instances, becoming confused with the original method. Hey sawed off the projecting

portion of the internal cuneiform ; this, however, is not expedient, as it lessens the attachment of the tibialis anticus and shortens the leverage of the foot.

Skey sawed off the base of the second metatarsal, leaving it in the mortise. This adds nothing to the usefulness of the stump, and exposes the remaining fragment to the danger of necrosis.

Baudens proposed that the first metatarsal bone only should be disarticulated, and the remaining ones sawn off transversely on a level with the internal cuneiform.

Reported as Results.—The rate of mortality in amputation of the toes is about six per cent.

Amputation through the Medio-tarsal Joint (Chopart's).—The me-

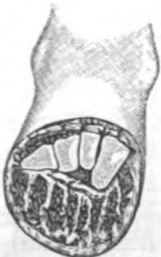

FIG. 391.—Appearance of flap (after Lisfranc's amputation).

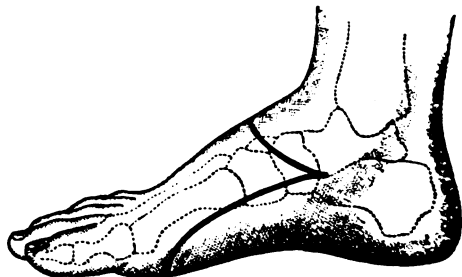

FIG. 392.—Inner flap.

dio-tarsal joint is formed by the astragalus and os calcis behind, and the scaphoid and cuboid bones in front.

The articulation can be located by drawing a transverse line across

the dorsum of the foot, beginning just behind the tuberosity of the scaphoid; the outer extremity will be about one inch behind the tuberosity of the fifth metatarsal bone. The foot is raised and a curved incision is carried over the sole, extending from the articulation of the scaphoid with the astragalus (Fig. 392), forward to within a thumb's breadth of the heads of the metatarsal bones (Fig. 393), then across the sole and backward to the outer extremity of the articulation of the cuboid and os calcis (Fig. 394). Forcibly extend the foot and make a slightly curved incision,

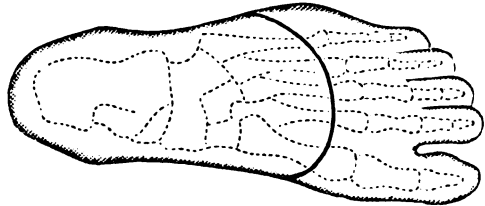


FIG. 393.—Inferior aspect.

through the skin only, the convexity downward, across the dorsum, connecting the upper extremities of the plantar incision (Fig. 395).

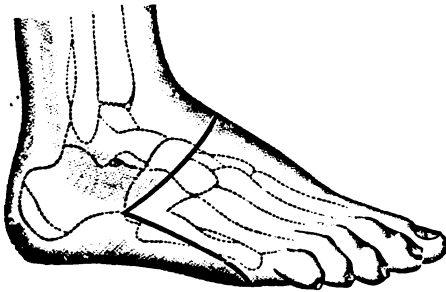

FIG. 394.—Outer aspect.

Turn the dorsal flap upward, open the joint on the dorsal surface; beginning from within, bend the metatarsal bones toward the heel, and sever the ligamentous connections thus made tense. Finally, pass the knife through the articulation to the plantar surface, turn the edge toward the toes, and complete the plantar flap (Fig. 396). Fig.

397 represents the stump after the flaps are united.

This operation is objected to on account of the liability of the stump to become extended, causing the patient to walk on the cicatrix at its anterior extremity. The division of the tendo Achillis at, or subsequent to, the operation is made to counteract this tendency; but frequently, however, without success. If the foot-stump

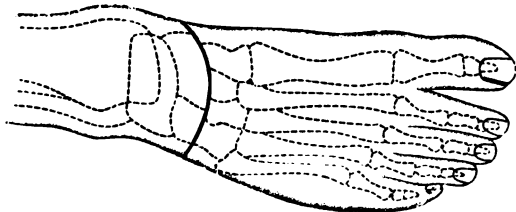


FIG. 395.—Dorsal aspect.

is a flexed the healing, and for a time afterward, there is less becoming extended. This operation can not be recom-

mended as a substitute for those that are to follow, in point of comfort and usefulness. Better execution is done with an artificial limb-appliance after the Syme's amputation than after this operation.



FIG. 396.—Removing the foot.

Results.—The mortality is about eight per cent.

Forbes' Modification.—This is made through the same incisions as Chopart's. After the cuneiform bones have been separated from the scaphoid, the cuboid is sawn through on a line with them. Inasmuch as this

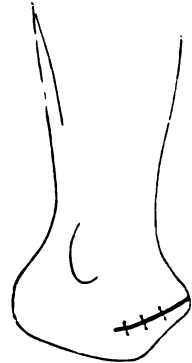

FIG. 397.—Appearance of stump.

operation offers no additional power of flexion by reason of its muscular attachments, its stump may become subjected to the same annoyance as the former.

In this, as in the medio-tarsal amputation, the after-treatment exercises a most important influence upon the results.

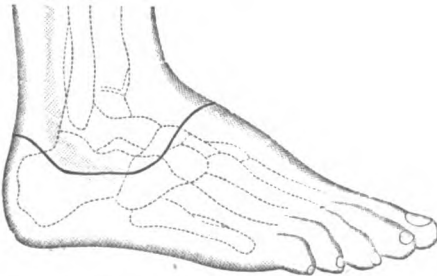

FIG. 398.—External incision.

Sub-astragaloid Disarticulation (De Lignerolles).—Make two lateral flaps by an incision beginning immediately above the tuberosity of the os calcis on the outer side, which divides the tendo Achillis, and is carried along the outer side

of the os calcis in a curved manner, convexity downward, below the external malleolus, thence extending obliquely upward across the middle of the cuboid to the dorsum of the foot (Fig. 398); then vertically downward across the inner border of the scaphoid (Fig. 399) till it reaches the center of the sole of the foot; it is then turned directly backward at a right angle with the preceding cut, and joins the beginning of the incision at the inner border of the tendo Achillis (Fig. 400).

Dissect up both flaps till the lateral surface of the os calcis and the talo-scaphoid joints are exposed, being careful not to injure the tibio-tarsal joint; remove the bones

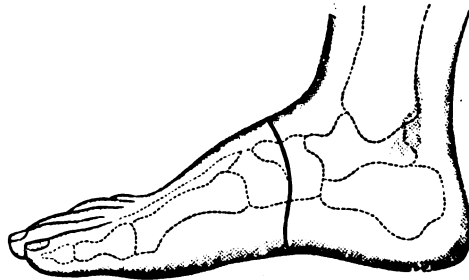


FIG. 399.—Internal incision.

in front of the medio-tarsal junction; seize the anterior extremity of the os calcis with bone-forceps, depress and turn it inward, and divide the external lateral ligaments with a narrow knife about a third of an inch below the tip of the malleolus; then divide the interosseous

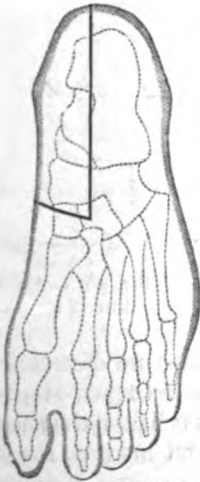

FIG. 400.—Plantar incision.

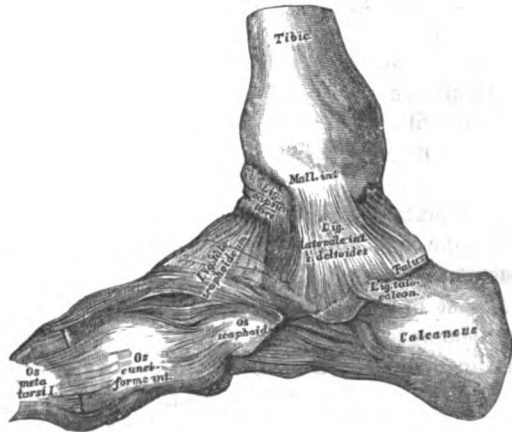


FIG. 401.—Internal ligaments.

ligament between the os calcis and astragalus; finally, the talo-calcanean ligament is divided an inch below the internal malleolus (Fig. 401). The os calcis is then removed (Fig. 402), and the flap united in its proper position. Fig. 403 shows the appearance of the stump after union of the flaps.

backward on the posterior flap, at the same time liberating it from the outer surface and sides of the os calcis, back to near the insertion of the tendo Achillis. An incision is now made down to the bone on the anterior line, and the joint opened in front; the foot well extended, lateral ligaments divided, and foot removed by liberating the remaining tissues attached to the posterior surface of the os calcis, including the tendo Achillis; always remembering to closely hug the bone, else the flap may be perforated and its integrity impaired.

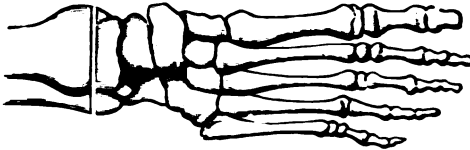


FIG. 406.—Bones of leg sawn through.

After the removal of the foot, dissect up the soft parts around the malleoli a sufficient distance to permit the articular ends of the bones to be sawn off (Figs. 406 and 407); cut off the extremities of the tendons

even with the cut surface of the soft parts, bring the flap into position, unite it in front (Fig. 408), and dress with antiseptic precautions.

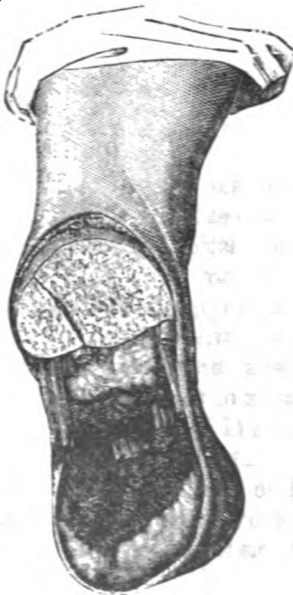

FIG. 407.—Heel flap.

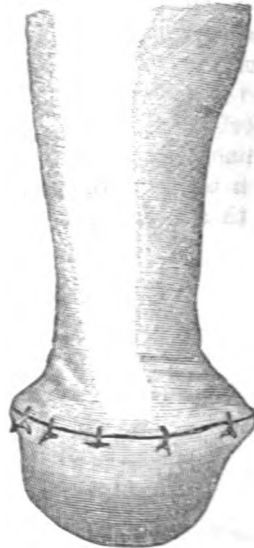

FIG. 408.—Flaps united.

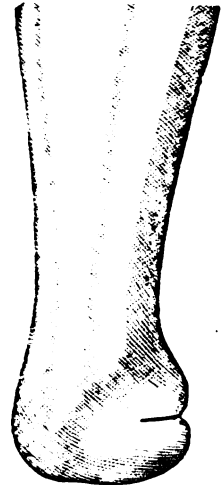


FIG. 409.—Side view.

Modifications.—Sawing the malleoli obliquely (Fig. 410)—instead of removing them together with a thin transverse section, that includes the articular surface of the tibia, as recommended by Mr. Syme—is a modification which has been long and somewhat extensively practiced. It is believed to give a better-shaped stump, and to be attended with

less danger to life, than if the bony canals of the tibia be extensively opened, as in the case of transverse section.

Many surgeons, after making the plantar incision, open the joint in front, as before described, disarticulate, and dissect the heel-flap from behind forward.

This affords more room and leverage to aid in the removal of this flap, but increases the danger of cutting it. The removal of the periosteum from the sides and the posterior surface of the os calcis, including the insertion of the tendo Achillis, has been practiced. If it can be done without too much laceration of its structure, it is a commendable modification.

By some, the articular cartilage remaining on the extremity of the tibia is scraped off; this procedure is thought to hasten the healing process. Many methods, adapted to various forms of injury to the soft parts, have been devised to modify the construction of the flaps to cover the end of the stump. When the heel-flap is impossible, tissues can be taken from all or either of the three remaining aspects of the foot to supply it; being ever cautious to avoid injuring the posterior tibial artery, as it lies below the inner malleolus.

Fallacies.—The incision across the instep lies below the line of articulation between the astragalus and the tibia; therefore, unless care be taken to locate the joint, the operator will cut down upon the neck of the astragalus, and, not finding the joint, will become much confused; or he may even open the articulation between the scaphoid and astragalus. If the plantar flap be made too long, it will be impossible to carry it over the point of the heel; therefore, if it be necessary to make a long heel-flap, the joint should be opened at once from before backward, and the heel-flap dissected off from above downward.

Results.—The rate of mortality from Syme's operation is from five to nine per cent.

Roux's Operation.—Begin the incision at the outer side of the tendo Achillis, a little above the insertion; carry it straight forward beneath the outer malleolus (Fig. 411), then in a curved line across

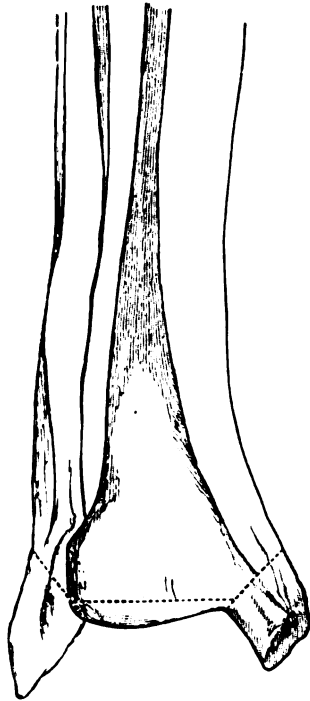


FIG. 410.—Oblique division of malleoli.

the instep half an inch in front of the articular edge of the tibia backward and downward, in front of the inner malleolus, to the sole (Fig. 412); then obliquely backward to near its outer border;

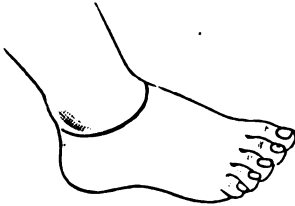

FIG. 411.—Outer incision.

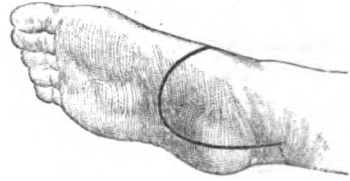


FIG. 412.—Inner incision.

backward and upward over the heel to the point of beginning. Dissect up the edges of the flaps, open the joint at the outer side, and complete the internal flap after disarticulation of the foot. The bones should then be divided, as in Syme's method; flaps united and dressed antiseptically.

Pirogoff's Amputation.—This is osteo-plastic in character, and consists in the application of the sawn surfaces of the posterior portion of the os calcis (Fig. 416) to the sawn surfaces of the bones of the leg. The length of the limb is well preserved, and, without the use of an

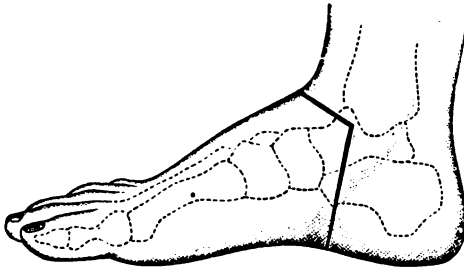


FIG. 413.—Inner incision.

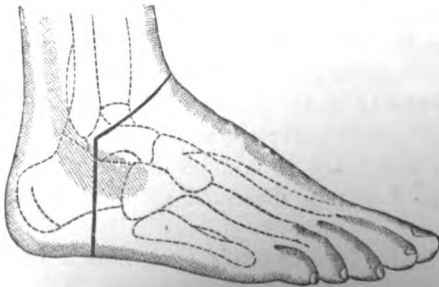

FIG. 414.—Outer incision.

artificial appliance, the stump is often superior to that of Syme's operation.

Operation.—Flex the foot at a right angle with the leg; make an incision down upon the bone, from the tip of the internal malleolus directly across the sole, its lowermost portion being a little in front of the long axis of the tibia (Fig. 413), around the foot to a point in front of the apex of the external malleolus (Fig. 414).

The extremities of this are connected by another carried down to the bone, half an inch in front of the lower extremity of the tibia. Open

the joint in front, divide the lateral ligaments, disarticulate the

head of the astragalus (Fig. 415), and with a narrow saw divide the os calcis obliquely downward and forward in the line of the plantar incision. Raise the anterior flap, dissect up the tissues around the lower ends of the bones, and saw

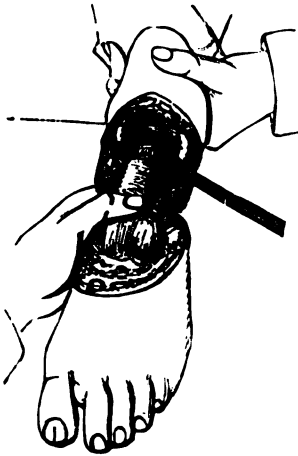


FIG. 415.—Separating articular surfaces.




FIG. 416.—Lines of section of os calcis.

through the lower extremities of the tibia and fibula, just above their articular surfaces. If any of the divided tendons be below the edge of the wound, cut them off on a level with it.

The cut surface of the os calcis is then brought forward and placed in contact with that of the tibia; the wound united and dressed antiseptically.

Fallacies.—If the posterior border of the os calcis be cut too long, the divided bone surfaces can not be properly apposed without force which will cause the fragment to tilt backward. This can be remedied by removing more bone from this border, or by dividing the tendo Achillis. Whenever this tendon inclines to tilt the bone, it should be divided. The fragment can be united to the tibia by silver wire to retain the sawn surfaces in apposition. The os calcis has been sawn at different angles to that bone (Fig. 416), but the one just considered has given the most satisfactory results. Fig. 417 shows the appearance of the stump after Pirogoff's operation.

Results.—The death-rate from this operation is about ten per cent.

Modifications of Pirogoff's Operation.—Fergusson's modification consists in not removing the malleoli, unless they are diseased, but in dividing the tendo Achillis, and placing the

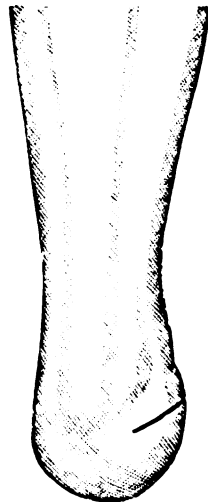


FIG. 417.—Appearance of stump.

sawn end of the os calcis between them. Dr. Turnipseed and others have practiced this modification and recommend it.

Le Fort's Modification.—The incisions for the flaps are similar to those in Roux's modification of Syme's amputation. The ankle-joint is exposed by raising the dorsal flap, keeping close to the bone so as not to injure the posterior tibial artery. Divide the external lateral ligament, and the ligaments between the astragalus and os calcis. Turn the foot inward, and remove the anterior portion of the foot at the medio-tarsal joint. Seize the astragalus with strong forceps, make tense the ligaments connecting it with the bones above, which should then be cut and the bone removed. Push down the os calcis, and with a narrow saw remove its upper third from behind forward, beginning just above the insertion of the tendo Achillis. Saw off the malleoli and the articular surface of the tibia, as in Pirogoff's opera-

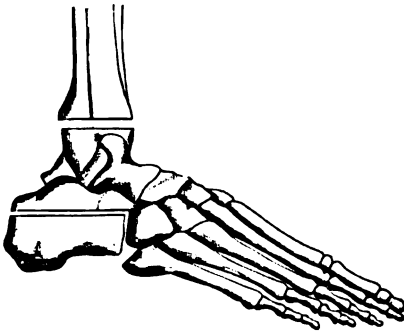


FIG. 418.—Sawn bones in Le Fort's method.

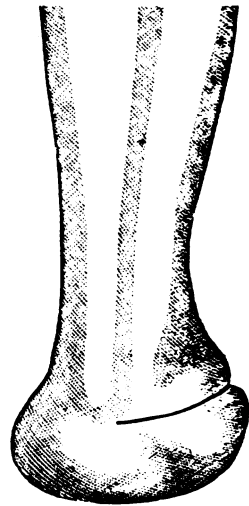


FIG. 419.—Appearance of stump in Le Fort.

tion (Fig. 418); place the sawn surfaces in apposition, and dress in the usual manner. This modification permits the reserved fragment

of the os calcis, when placed in position, to maintain the same relative axis to the end of the stump that it held to the foot; consequently the direct pressure is received upon the integumentary covering already adapted to the purpose (Fig. 419).

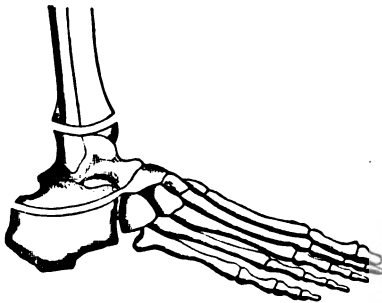


FIG. 420.—Brun's modification.

Brun's recommended that the sawn surfaces of the os calcis be made concave, and the tibia convex (Fig. 420).

Esmarch's Modification of Le Fort's operation consists of two incisions : one across the sole, the other across the dorsum of the foot. The former commences about four fifths of an inch below the tip of the external malleolus, and with the convexity forward (Fig. 421), runs under the cuboid and scaphoid bones (Fig. 422), ending at the inner side, one inch below and in front of the internal malleolus (Fig. 423). The curved dorsal incision (Fig. 424), with its concavity forward to the tuberosity of the scaphoid, connects the extremes of the plantar one. Dissect up the dorsal flap to the tibio-tarsal joint, which should be opened, the foot bent downward, and the upper surface of the os calcis exposed sufficiently to apply a small saw behind the upper margin of the tuberosity of the os calcis and the bone sawn, as before described (Fig. 418).

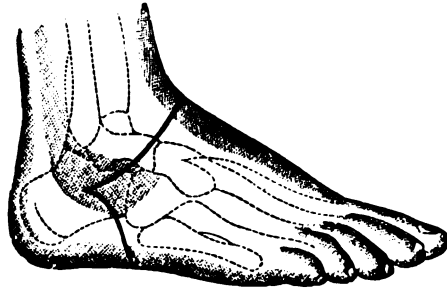


FIG. 421.—Outer incision.

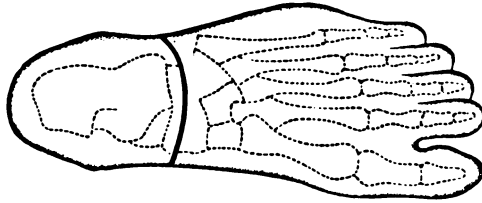


FIG. 422.—Plantar incision.

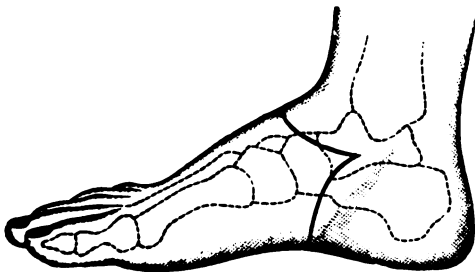


FIG. 423.—Inner incision.

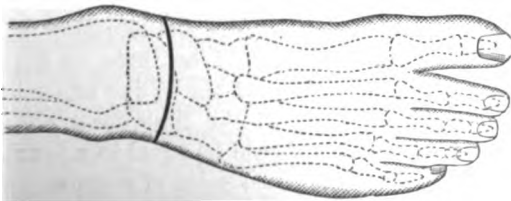


FIG. 424.—Dorsal incision.

The flaps are then united, drained, and dressed antiseptically.

Osteoplastic Amputation of Heel and Ankle (Mikulicz).—

This operation is specially indicated in cases in which the tissues composing the posterior part of the foot have been destroyed.

Operation.—Select a strong scalpel and make an incision from just in front of the tubercle of the scaphoid directly across the

sole of the foot, down to the bone, terminating just behind the base of the fifth metatarsal bone. From each extremity of the plantar incision, one is carried upward and backward to the bone of the corresponding malleolus, and the upper extremities of these incisions are connected by a fourth, passing directly transversely behind the limb and carried through the tendo Achillis. The lateral ligaments of the joint are divided, the joint opened from behind, and the calcaneum and the astragalus are carefully dissected out and removed by disarticulation at the medio-tarsal joint. The malleoli, including the articular surface of the tibia, are sawn off transversely, and also the cuboid and scaphoid bones are sawn transversely through on a line corresponding to the middle of the latter bone. The sawn surfaces of bone are then placed in contact with each other, and wired or pegged in position.

AMPUTATIONS OF THE LEG.

Supra-malleolar Amputation.—This operation resembles more nearly a Syme, in location, than any other that can be performed upon the leg; but, owing to the comparatively high rate of mortality resulting, it is not to be recommended in preference to a higher amputation. The flaps must always be made from the firmest and best-nourished tissues accessible.

Operation.—Two semilunar incisions, one external and one internal, are made, each beginning posteriorly at the posterior border of the malleoli, and passing forward beneath them, then around upon the dorsum of the foot, an inch in front of the ankle-joint, where they join each other. Their posterior extremities are then united by a curved transverse incision, with the convexity downward. The flaps are dissected upward, and the bones of the leg divided transversely about an inch above the articular surfaces.

Amputation of the Leg at the Lower Third.—When possible, the leg must always be amputated at this situation. It gives a long fulcrumage for an artificial limb, and admits of the formation of a symmetrically tapering stump, which can be closely adjusted to the socket of the artificial appliance.

Three methods can be employed: the circular, the bilateral, and the hood flaps, embracing only the integument and subcutaneous tissues, or combined with the periosteum covering the subcutaneous surface of the tibia.

Circular Method with Periosteal Reflection.—If the situation can be selected for the site of the operation, it should be three or three inches and a half from the lower extremity of the tibia; or, more definitely, at the point where the tapering of the limb from above downward ceases. The length of the flap should be equal to a fourth of the circumference of the limb at the proposed point of section.

Operation.—Prepare the patient in the usual manner; make a cir-

cular incision through the integument and subcutaneous tissue down to the muscular fascia and the subcutaneous surface of the tibia. Dissect the sleeve for about an inch all around, then divide the periosteum on the subcutaneous surface of the tibia, by a transverse incision at the point of reflection of the flap; divide it also longitudinally at the outer and inner borders of the surface of the tibia a sufficient distance—one fourth of an inch—to allow the periosteum to be reflected upward while attached to the inner surface of the flap. These longitudinal incisions are repeated as often as it becomes necessary to detach the periosteum and keep pace with the turning up of the flap at the remaining portions of its circumference. That is, instead of dissecting the flap from the tibia, its periosteum is detached from its subcutaneous surface, and pushed up to the point of proposed section while still adherent to, and forming a limited lining to the flap. Fig. 425 shows the extent of the reflection of the periosteum,

which, however, in the operation, remains attached to the inner surface of the corresponding portion of the flap. The tibia is sawn carefully through at the highest point of the periosteal reflection, the fibula

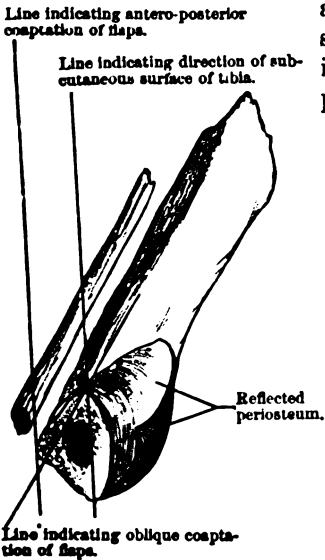


FIG. 425.—Reflection of the periosteum.

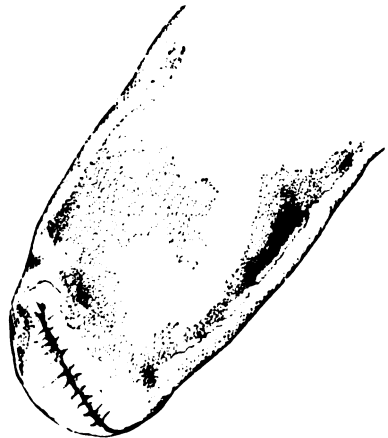

FIG. 426.—Oblique coaptation.

exposed one fourth of an inch higher and divided separately by sawing toward the tibia. The flaps are then united obliquely, so that not only will the line of union fall between the two bones, but that—which is more important—the periosteal lining of the inner portion of the flap will fall and lie smoothly across the divided extremity of the tibia, since the subcutaneous surface of the tibia lies parallel with the line of oblique coaptation (Fig. 426). It will be necessary, in order

to reflect the sleeve-flap, that it be divided longitudinally; this is done at such a point as will become lowermost when the flaps are obliquely joined. The limb should be dressed antiseptically, using caution to maintain the oblique direction of the flaps till the healing process is complete. The periosteal flap grows to the end of the bone, preventing it from becoming atrophied, and likewise preventing the adhesion

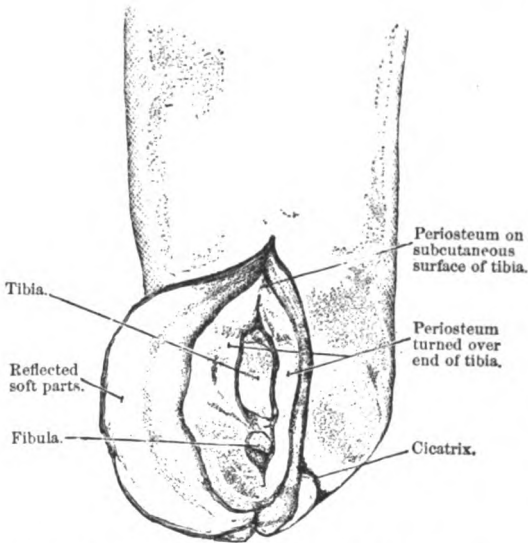


FIG. 427.—Dissected specimen showing the relation of parts.

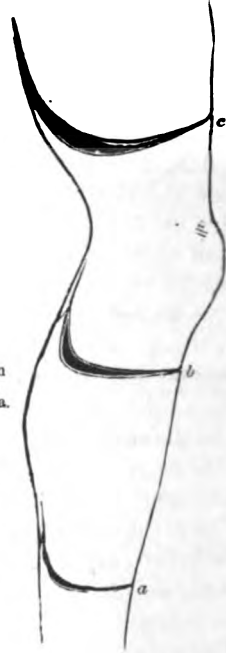

FIG. 428.—Bilateral flaps.

of the cicatrix to the end of the tibia. Fig. 427 shows a longitudinal section through the flap three months after this operation had been done.

Results.—Of the eight cases done by myself all have resulted in exceptionally serviceable stumps. In no instance have bony spiculæ appeared, and in each the stump has given entire satisfaction to the patient.

The Bilateral Flap Method (Fig. 428, *a*) consists of equilateral flaps constructed from the integument and subcutaneous tissue at the outer and inner surface of the limb. The operation may be performed by this method either with or without the periosteal lining. The circular, with oblique coaptation, is by far the better method if the periosteum be raised; since in antero-posterior coaptation, the periosteal flap will be tilted, and become more liable to eversion and the production of bony spicular growths.

The bilateral flaps are made by first ascertaining the circumference of the limb at the point of the proposed amputation. The base of each flap is then made equal to half, and the length to one fourth of this circumference. Each one is nearly semicircular, and their points of junction should be at the center of the limb, anteriorly and posteriorly, which will bring the anterior point of union to the inner side of the crest of the tibia; it should also be a little below the point of the proposed section of the tibia. The posterior point of junction is made above that of the anterior, to provide for suitable drainage (Fig. 428, a). When properly outlined, each flap is dissected upward to near the point where the bone is to be divided; the muscles are divided by a circular incision, then pushed upward above the anterior point of union of the flaps, and the bones sawn off—the fibula a fourth of an inch the shorter—on a line corresponding to the junction of the flaps posteriorly. If there be an undue amount of muscular tissue behind, it can be trimmed off until it admits of the ready union of the divided borders of the flaps. Suitable drainage, antero-posterior coaptation, and an antiseptic dressing, comprise the immediate attention to the case.

The Hood, or Oval Flap Method is a modification of the circular, the skin-cuff being slit up posteriorly to the point at which the bone is to be divided, and the corners trimmed off to resemble the outlines of the lower portions of the bilateral flap. This flap is then reflected upward, and the muscles and bones divided as before. The line of union is made antero-posteriorly.

The advantages claimed for this method are: its perfect drainage; the location of the cicatrix on the posterior surface; and the carrying of the integument over the end of the bone, thus preventing the adhesion of the cicatrix to it. Like the bilateral, it can be employed in connection with the periosteal flap; still, as it is joined to form an antero-posterior line of union, it is open to the same objections as the former with reference to the periosteum.

Results.—The rate of mortality from amputation in the lower third is variously estimated at from thirteen to twenty-two per cent; this being, however, less than at any other part of the limb.

Amputation through the Middle Third.—The limb can be amputated at this point by the same methods employed at the lower third of the leg. The principles applicable to the lower third have an equal force at this situation. The presence of the calf offers an additional difficulty in obtaining the oblique coaptation, but does not interpose an insurmountable obstacle to it. Care in dressing the stump will maintain the obliquity of the line of coaptation in the periosteal flap method. The bilateral and hood flap methods, either with or without the periosteal lining, present to the surgeon the means of making a most serviceable stump. If other than the preceding be desired, the

long external and short internal flaps are to be preferred, instead of either the long anterior or the long posterior, since either of these impede drainage, and both by their weight exert undue traction across the crest of the tibia.

The Unilateral Flap Method, combined with a semicircular incision on the opposite side, offers good drainage, and carries the cicatrix beyond the point of pressure.

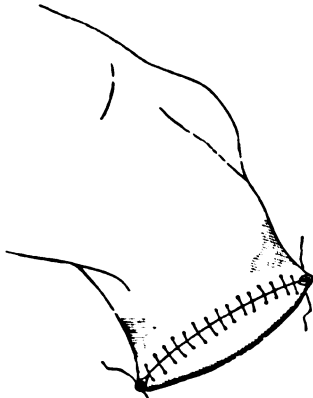


FIG. 429.—Long external flap.

These flaps may be muscular or integumentary; the former are made by transfixion, the latter by external incision with the ordinary scalpel, and circular section of the muscles with the long knife. The principles controlling the length of the flaps are the same as previously stated. The long flap should be made from the outer side of the leg, having a base somewhat less than one half the circumference of the limb. The inner, or short flap, is semicircular in shape (Fig. 429).

The bones are sawn off just above the anterior point of junction of the flaps, which are then to be united, and the wound dressed as before.

Results.—The rate of mortality of amputations in this portion of the limb is about twenty-seven per cent.

Amputation at the Upper Third.—Either of the methods employed in the middle third is applicable at this situation. The fibula should not be removed, as the superior tibio-fibular articulation sometimes communicates with the knee-joint. The tibia is sawn below the insertion of the ligamentum patellæ.

Results.—The mortality is about forty-three per cent.

Amputation at the Knee-Joint (*Disarticulation*).—The bilateral, the circular, the long anterior, and the hood flaps are the ones best constituted to meet the indications. The stump resulting from either has an early sustaining power with a broad point of support, which, however, later in life becomes somewhat lessened in size. The joint surface is not to be molested in any other way than by scraping off the articular cartilage.

The patella, unless diseased, should be allowed to remain. It will be found to rest just above the condyles, where it affords a good point of attachment for the quadriceps extensor. The ligaments should be divided close to the femur, the semilunar cartilages remaining attached to the tibia. The popliteal artery is tied, only after sufficient isolation to admit of the application of the ligature above the articular branches. The popliteal vein also should be isolated and tied.

Bilateral Method.—This, without doubt, is the best method. It provides two well-nourished flaps, which, when united, locate the cicatrix between the condyles posteriorly, thereby affording admirable drainage.

Operation.—With the thigh elevated and the leg extended, begin the anterior incision of either flap, one inch below the tuberosity of the tibia, cutting through the skin and subcutaneous tissues and muscles. Carry it downward and forward below the curve of the leg, thence inward and backward to the middle of the under surface of the leg, then directly upward to the middle of the popliteal space (Fig. 428, *b*). The opposite flap is made in a similar manner; remembering, however, that the flap at the inner side must be made the longer, on account of the greater length and size of the inner condyle. Raise the flaps until the articulation and the apex of the patella are reached; divide the ligamentum patellæ; open the joint in front; divide the crucial ligaments; draw the head of the tibia forward, and pass a long knife behind it; extend the leg somewhat and cut the remaining tissues directly downward. Before severing these tissues be careful to ascertain if perfect control be had of the femoral artery. After removal of the leg the flaps present the appearance shown in Fig. 430. The flaps are united and suitable drainage provided. A not in-

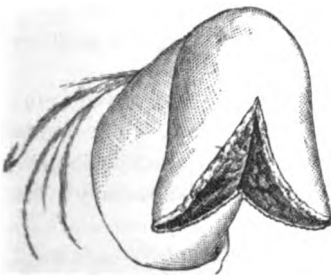


FIG. 430.—Appearance of the flaps.



FIG. 431.—Appearance of the stump.

frequent sequel to this operation is the formation of an abscess beneath the quadriceps extensor, due to the collection of pus at the upper end of the synovial pouch of the joint; the elevation of the stump causing it to gravitate to that point. This can be avoided by the division of the lateral synovial bands commanding the entrance to it, and the introduction of a drainage-tube to the uppermost portion; or by carrying the tube through the uppermost extremity to the anterior surface of the thigh. Sometimes compression firmly and continuously applied over the pouch will answer the purpose. When healed the stump presents the appearance shown in Fig. 431. If care be not taken in the application of the dressings, undue pressure will be made on the tissues covering the condyles of the femur, causing ulceration and even sloughing.

Fallacy.—It has, however, one fallacy, which has been the cause of much chagrin to surgeons on rare occasions—the danger of making the flaps too short, followed by the necessity of removing the patella, or sawing off the condyles before the flaps can be properly united. If the semilunar fibro-cartilages be permitted to remain connected with the femur, they will lessen the degree of retraction of the soft parts; however, when thus allowed to remain, they not infrequently slough away.

Circular Method.—Extend the leg and make a circular incision around it, about four inches below the patella, through the integument and subcutaneous tissues. Dissect it up to the edge of the patella; flex the leg and divide the ligamentum patellæ at its apex; then open the joint in front, and divide the lateral ligaments close to the




FIG. 432.—Circular flap method.

femur, so that the semilunar cartilage will remain connected with the tibia. Flex the leg and cut the crucial ligaments. Pass a long knife between the bones, extend the leg, and sever the posterior connections as before (Fig. 432). The flaps can be united from before backward

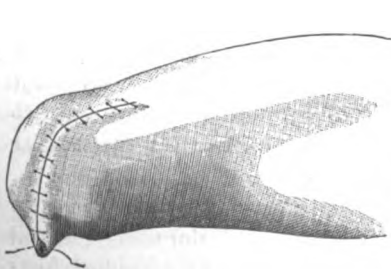


FIG. 433.—Anterior-posterior coaptation.

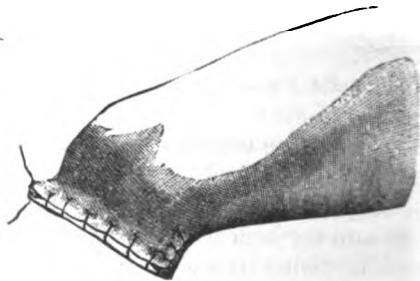


FIG. 434.—Transverse coaptation.

(Fig. 433), or transversely (Fig. 434), the former being the better method, for obvious reasons.

Long Anterior, with a Short Posterior Flap.—Flex the leg and make a longitudinal semicircular-shaped flap, beginning a little below the center of the inner surface of the internal condyle, extending around in front five inches below the patella to a similar point on the external condyle (Fig. 435). Dissect the flap upward to the patella, open the joint as before; draw the head of the tibia forward and pass a long knife behind it, making the short posterior flap from above downward, beginning the incision at the upper borders of the anterior flap. When united the cicatrix is well protected and good drainage afforded (Fig. 436).

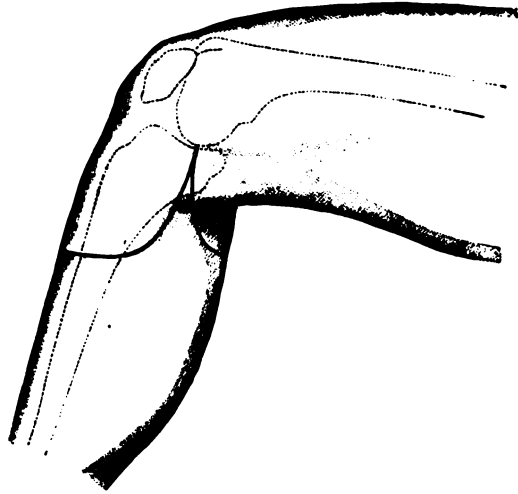


FIG. 435.—Line of incisions.

Hood Flap.—This varies but little from the bilateral; having a somewhat oval outline in front, instead of a retiring angle.

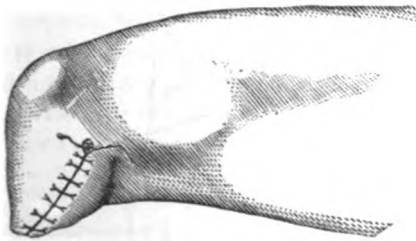


FIG. 436.—Appearance of stump.

Results.—The rate of mortality from amputation through the knee-joint varies but little from amputations of the lower limb, as a whole, averaging in the latter about thirty-four per cent; in the former, thirty-two per cent. Amputation through the

knee-joint offers, as a rule, a better chance for life than through the upper third of the leg.

Amputation through the Condyles.—This measure possesses no advantage over the one made through the articulation. The rate of mortality is somewhat increased, being reported at about forty-eight per cent, although this would be, without doubt, much lessened by the employment of antiseptic measures; and the usefulness of the stump is decidedly in favor of the latter. However, as conditions sometimes arise rendering the disarticulation imprac-

licable, amputation through the condyles becomes a valuable expedient.

Carden's Amputation.—Extend the leg, seize the joint with the left hand, the end of the thumb and index-finger resting as nearly as possible over the center of each condyle. With a stout scalpel make an anterior semilunar flap, commencing at the point indicated by the end of the index-finger, passing around in front about two inches be-

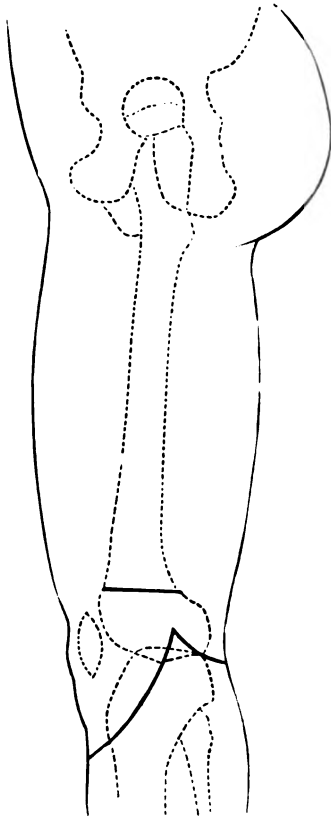


FIG. 437.—Carden's method.

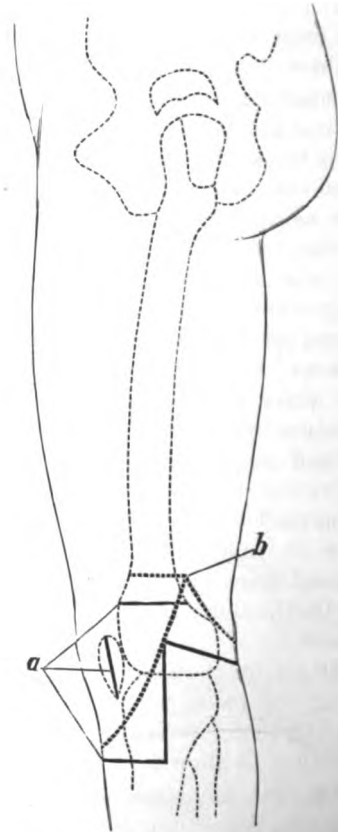


FIG. 438.—Gritti's and Stokes' method.

low the patella to the end of the thumb on the opposite side. If the question of amputation or excision be undecided, reflect the anterior flap first; then, if the condition of the parts require amputation, connect the extremities of the anterior flap by a short posterior one carried directly down to the bone (Fig. 437). Reflect both flaps upward to the base of the condyles; flex the leg to draw down the patella, and divide the remaining tissues surrounding the condyles down to the

bone; then saw off the condyles at their base, secure the vessels as before described, and unite the divided parts.

Results.—The rate of mortality as reported by Carden was about seventeen per cent.

Gritti's Amputation (Fig. 438, *a*).—Extend the leg and make a rectangular flap, extending from the center of the condyles to the tuberosity of the tibia. Divide the ligamentum patellæ at its insertion and dissect up the flap containing it. Divide the integument on the posterior surface by a circular incision. Remove the synovial membrane from its attachments to the femur in front, and saw the bone just above the articular cartilages. Introduce a long knife and cut the remaining tissues from within outward. Saw off the articular surface of the patella. Allow the anterior flap to fall into position, causing the sawn surface of the patella to come in contact with the divided end of the femur. This operation is osteo-plastic in character, being allied to Pirogoff's.

Stokes' Modification of Gritti's method consists in making an anterior oval instead of a rectangular flap—the posterior flaps being made one third its length; and the femur is sawn off an inch above the condyles (Fig. 438, *b*), instead of through their base. The cartilaginous surface of the patella is scraped off, and it is then united to the extremity of the femur by strong catgut passed through the soft tissues immediately behind the bone.

Results.—The rate of mortality for Gritti's operation and Stokes' modification is reported at about thirty per cent.

Amputation of the Thigh.—The muscles surrounding the thigh are of large size and many of them of great length. Those on the posterior and many on the anterior surface extend from the pelvis to the leg. On the inner side their length is but little less and their bulk is increased.

The greater the length of a muscle from its origin to the point of division, the more marked will be its retraction, other things being equal. It therefore happens, in amputation of the thigh, unless care be exercised to allow for the greater degree of contraction of the long muscles, that the bone protrudes, or presses too strongly against the flap, giving it an undue concavity, or otherwise distorting the stump. The position in which the limb rests during the healing process has an influence on the muscular retraction. For instance, if the limb be extended during the division of the muscles, the posterior ones, on account of their greater length and tension, retract the most, and if to this be added the additional retraction due to placing the stump in a semi-fixed position—on a pillow, or by swinging—during the healing process, the tendency to cause tender, painful, and otherwise troublesome stumps is increased. To avoid this, the limb should be held as nearly as possible at the same angle with the body, when the

muscles are being divided, as that in which it will be placed when the dressing is completed and during the process of recovery.




FIG. 439.—Periosteal flap.

In all amputations of the thigh an anterior rectangular, or oval periosteal flap should be made, its outer surface remaining associated with the tissues connected with or springing from it (Fig. 439, *a*). If an amputation be made close to the band of a tourniquet or the elastic bandage of Esmarch, the muscles will be held too firmly to admit of the natural retraction until after the bone is sawn and they are liberated; this is a fault which must be recognized and corrected by cutting the muscles lower than would otherwise be done.

Bilateral Flap Method (Fig. 428, *c*).—This is admirably adapted to both the middle and lower thirds of the thigh.

The outlines of the flaps are integumentary, and are dissected up from the muscles two inches, or about half their length. The muscles are divided by a circular sweep of the knife, and the bone sawn off at the same situation. In the circular division of the muscles, accompanied by the circular or equilateral flaps, it is advisable that the first sweep of the knife should divide only the superficial layer, which will then retract or can be drawn upward and the second layer be severed at a higher point, causing the open stump to present a conical cavity, the sawn bone corresponding to its apex (Fig. 440). The end of the bone is then seized by strong forceps, the soft parts on its posterior surface and sides pushed up, and with a small, sharp-pointed knife an oval or rectangular-shaped flap of periosteum is marked out and pushed upward from the anterior surface of the bone, together with the soft parts resting upon it (Fig. 439, *a*). The base of the periosteal flap must correspond to the point of secondary division of the bone, which will be about two inches above the primary section. The bone is sawn again and removed. The portion of the flap having the periosteum is allowed to fall into its proper position across the end of the divided femur; the edges are united, and stump dressed as desired.

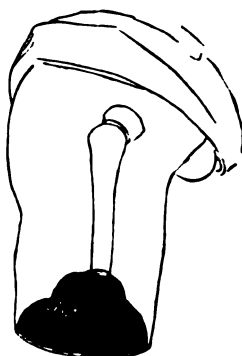


FIG. 440.—Conical cavity.

Vermale recommended that these flaps be musculo-integumentary. Although these are favorable for drainage, their weight is liable to lead to exposure of the bone at the upper angle of the wound.

Antero-posterior Musculo-integumentary Flaps.—These flaps include all of the tissues down to the bone, and are made by transfixion usually, although the anterior one may be made by cutting from without and the posterior by transfixion at the upper limit of the former. The length of each flap should be about one fourth the circumference of the limb. When both flaps are to be made by transfixion, the tissues should be raised somewhat by the left hand of the operator, who then enters the point of the knife at the side nearest himself, pushes it through in close contact with the anterior surface of the bone, and raises the handle a little as it passes to cause the point to emerge at the opposite side of the limb, exactly opposite the entrance. This flap is then formed by cutting obliquely upward with a sawing motion, and when completed is pulled backward by an assistant assigned for that purpose. The knife is reinserted at the original point of entrance, carried behind the bone, point elevated so as to emerge at the same situation as before, and the posterior flap is made by cutting obliquely downward. The remaining muscular fibers around the bone are cut by a circular sweep of the knife, retractors applied and the bone divided. In flaps of this structure the skin retracts more than the muscles, causing the lower ends of the latter to be exposed. To avoid this, Agnew recommends that the flaps be formed first from the integument, reflected up an inch and a half, and the muscles be divided by transfixion; the point of the knife being pushed through at the junction of the reflected integumentary flaps.

The Circular Integumentary Flap method can be employed upon the thigh, and with admirable results. The principles governing its construction are similar to those applicable to this method in other situations. The division of the muscles should be at a point not less than two inches below the reflected flap, and their respective layers should be divided independently, as seen in Figs. 440 and 441.

The Single Circular Incision Method (Celsus).—Control the circulation, and with a long knife divide all the soft parts by a circular sweep down to the bone (Fig. 442), which is then sawn off.

The end of the divided bone is now seized by strong forceps, the



FIG. 441.—Amputated portion.

surrounding soft parts drawn upward, the bone exposed, when, if desirable, an oval periosteal flap can be made, its base corresponding to

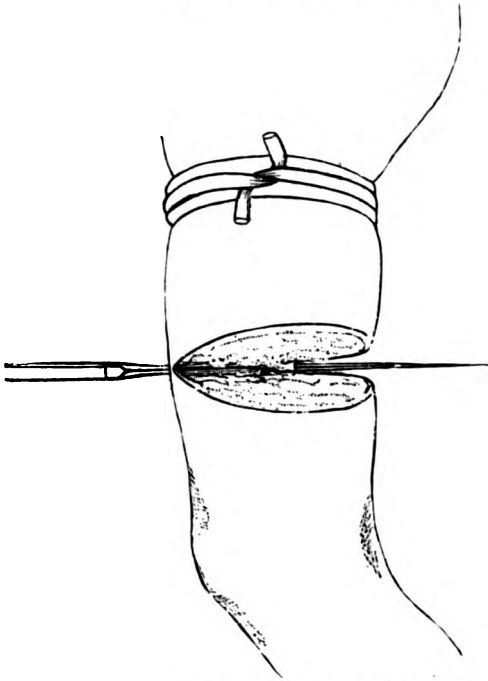


FIG. 442.—Celsus' single circular incision.

the site of secondary section of the bone (Fig. 439). Saw the bone a second time close to the periosteal flap, and allow the parts to fall into position. They can be united transversely (Fig. 443) or the reverse; the former holds the periosteal flap in position the better.

liquely, upward and backward, not making the flap too thick. The tissues on the posterior portion of the limb are divided transversely down to the bone, which is then exposed about two inches higher and sawn off.

Results.—The rate of mortality, in amputations of the lower third of the thigh for gun-shot injuries, is fifty-five per cent; at the middle third, sixty-five per cent; and at the upper third, seventy-eight per cent. About thirteen per cent more recover with expectant treatment, in gun-shot injuries, than after

Long Anterior Flap Method (Sedillot).—This can be employed in any portion of the thigh. Mark out on the anterior surface of the limb a flap, the length of which is equal to one third, and its base to two thirds of the circumference. Divide the tissues, ob-

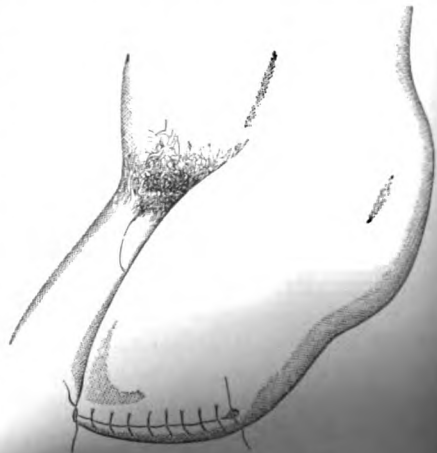

FIG. 443.—Appearance of stump.

amputation. The rate of mortality after primary amputations is twenty-one per cent greater than after secondary. The results are considerably more favorable when done in private practice, or with antiseptic precautions, irrespective of the cause.

Amputations at the Hip.—The causes of death from this amputation are, loss of blood, shock, and septicæmia. Various plans to limit the loss of blood have been suggested — compression of the abdominal aorta by the fingers of a hand introduced into the rectum by an assistant; combined with digital pressure upon the femoral as it crosses the pubis. In all instances, when abdominal pressure is to be applied, the intestines should be evacuated. Various forms of tourniquets have been designed for the purpose, as Pancoast's (Fig. 444), Esmarch's (Fig. 445), and Lister's (Fig. 447). Fig. 446 shows Esmarch's elastic tourniquet in position.

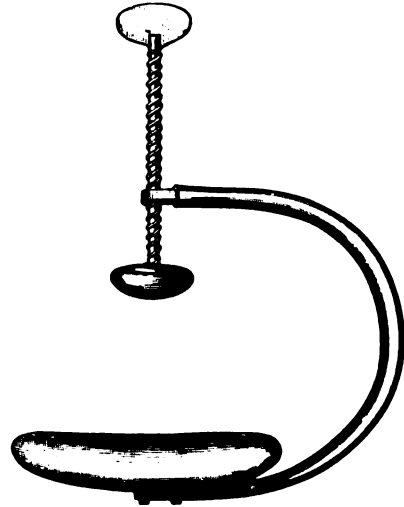


FIG. 444.—Pancoast's tourniquet.

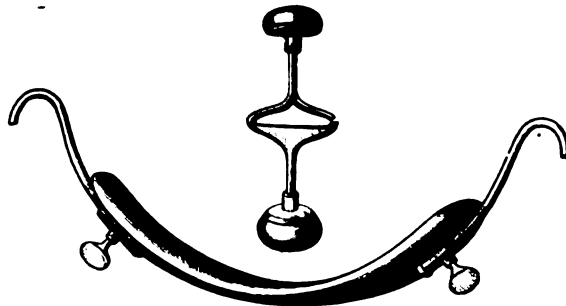


FIG. 445.—Esmarch's tourniquet.

If a tourniquet be not at hand, a pad may be substituted, made by winding a linen bandage about three inches wide and twenty-five feet in length around a stout rod or stick, one inch or so in diameter, and twelve inches long. This is placed immediately below the umbilicus and held in position by an assistant.

It can be confined in position, or the pressure still further increased by several turns of a rubber bandage carried over it and around the body (Fig. 448).

If the elastic traction around the body be objectionable, a longer stick can be substituted, and the compress secured in position by rubber bands carried over the ends of the stick and under the table (Fig. 449).

Davy's lever (Fig. 43) is a useful agent to control bleeding in this situation.

It is open to the objection of being easily disturbed by the struggles of the patient, as well as the danger of injuring the intestines, especially when carried to the right side of the body.

Trendelenburg's Rod (Fig. 44), which has also been previously mentioned, is of unquestionable utility. It is a steel rod, fifteen or sixteen inches long, about one fourth of an inch broad, biconvex on

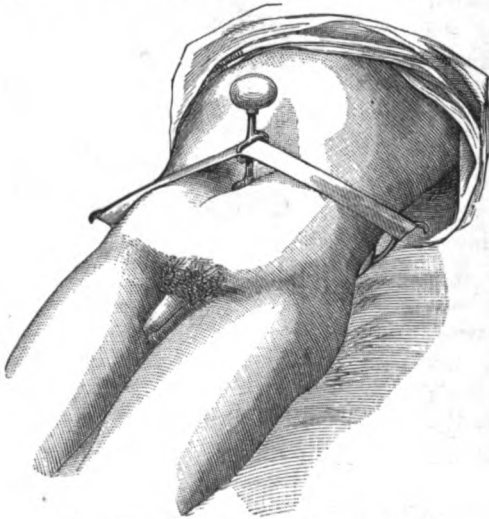


FIG. 446.—Esmarch's tourniquet applied.

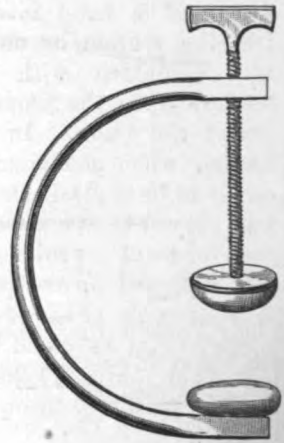


FIG. 447.—Lister's tourniquet.

transverse section, and a twelfth of an inch thick at the center, with blunt edges; but provided with a movable lance-shaped point two

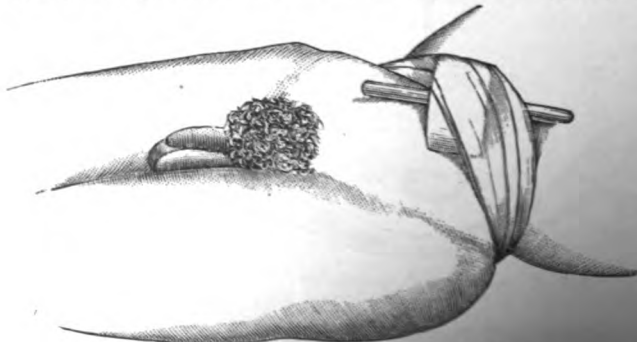


FIG. 448.—Compression pad and elastic band.

inches in length. The rod is passed through the soft parts in front of the joint; entering an inch and a half below the anterior superior spinous process of the ilium, passing across

femoral artery, emerging at the posterior scroto-femoral junction. The point is removed and a strong elastic tube or band is wound firmly, like the figure 8, around its ends, passing in front of the thigh.

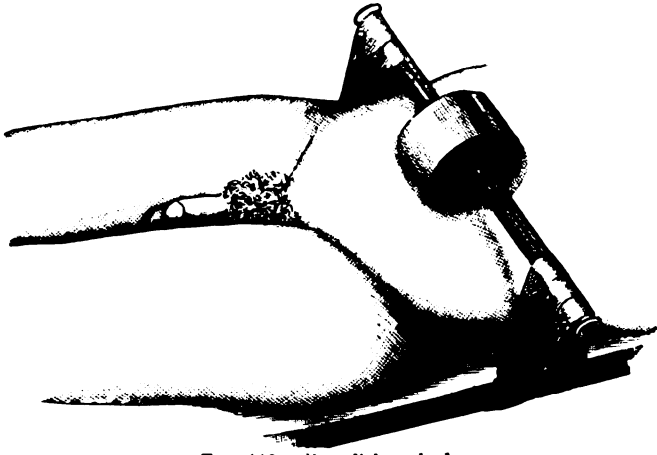


FIG. 449.—Brandis' method.

A long knife is then inserted in the course of the rod about half an inch below it, and the anterior flap made in the usual manner, and the vessels ligated. The rod is then withdrawn, the hip-joint disarticulated, and the posterior flap made in a similar manner. Dr. Varick, of Jersey City, N. J., who first employed the rod in this country, did not disarticulate until he had transfixed a second time behind the neck of the femur, including as much of the soft parts on the posterior surface as possible; compression was then applied as before, and the tissues were divided by a posterior semicircular incision down to the bone. The amount of blood lost was trifling, and the patient made a speedy recovery. The rod can be employed in the various forms of flaps, and therefore has an element of universality. It has not as yet been enough used to be esteemed more than a rational expedient.

A seemingly admirable method of controlling hemorrhage in amputation at the hip-joint has recently been described (Lloyd):

“A strip of black india-rubber bandage, two yards long, is to be doubled and passed between the thighs, its center lying between the tuber ischii of the side to be operated on and the anus. A common calico thigh roller must next be laid lengthwise over the external iliac artery. The ends of the rubber are now to be firmly and steadily drawn in a direction upward and outward, one in front and one behind, to a point above the center of the iliac crest of the same side. They must be pulled tight enough to check pulsation in the femoral artery. The front part of the band, passing across the compress, oo-

cludes the external iliac artery, and runs parallel to and above Poupart's ligament. The back half of the band runs across the great sacro-sciatic notch, and, by compressing the vessels passing through it, prevents bleeding from the internal iliac artery. The ends of the elastic band can be held by the hands of an assistant, or bandages may be tied to its extremities, and passed across the opposite shoulder and tied; care should be taken to prevent the compression rollers from slipping. This device has been employed on several occasions with entire satisfaction."

Amputation at the hip-joint may be done by the single-flap method, anterior or internal; the double flap, either lateral or antero-posterior; the oval and the circular forms.

These general methods have been modified almost indescribably, and certainly, in many instances, impracticably.

Amputation by a Long Anterior and Short Posterior Flap (Manec).—Place the patient on a table so that half the pelvis, on the side to be operated upon, projects beyond the edge; draw the scrotum to the opposite side by a towel (Fig. 450). Exsanguinate the limb by the elas-

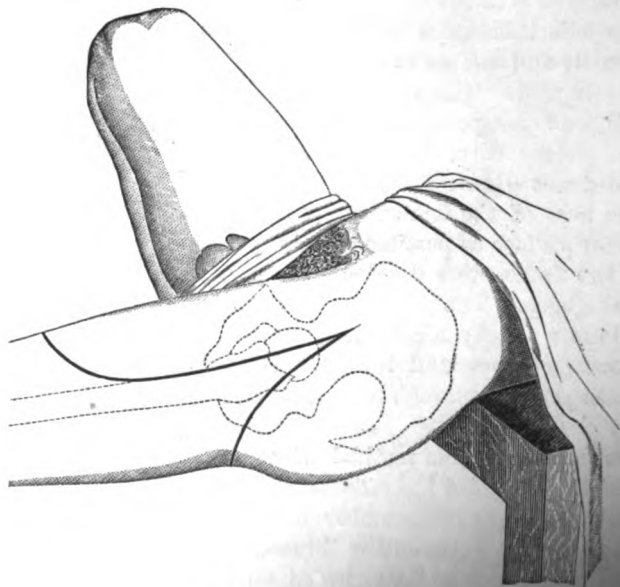


FIG. 450.—Manec's method.

tic bandage; after which control the hemorrhage from above by the form of arterial compression selected. Then remove the elastic bandage; the limb to be amputated is held by one assistant, and another is instructed to control the circulation in the femoral artery.

the pubes, and to catch the anterior flap and compress it before it shall have been severed from below.

The operator then introduces the point of a long knife, midway between the anterior superior spinous process of the ilium and the trochanter major, pushing it down to the bone parallel with Poupart's ligament; draws it back and lowers the handle; at the same time the assistant holding the leg flexes the thigh slightly, and the point is passed through the anterior surface of the capsular ligament; the point is then turned downward and made to pass out at the inner side of the thigh, an inch or so from the perineum, and as far posteriorly as it can be carried easily (Fig. 451). It is then carried downward, in con-

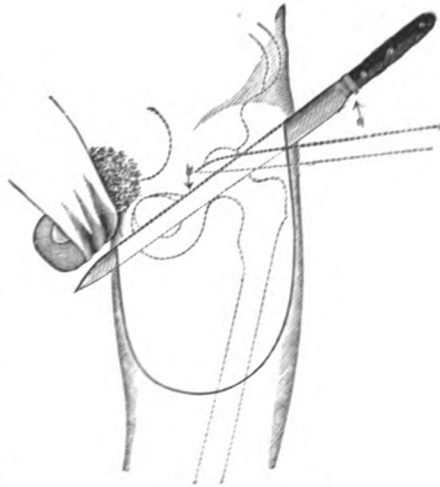
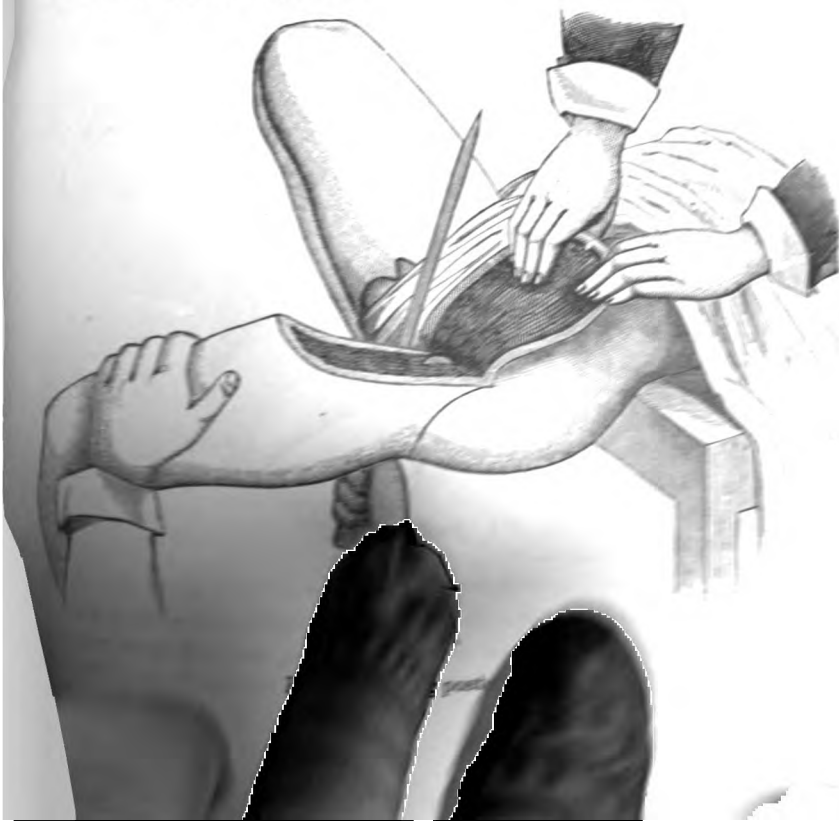

FIG. 451.—Transfixing.



tact with the bone, with long, sawing strokes, forming an anterior flap six to eight inches in length. This is caught by an assistant, who at the same time compresses the main vessel within it, and raises it upward. The knife is then brought under the thigh to the opposite side (Fig. 452), connecting the sides of the base of the anterior flap by a posterior

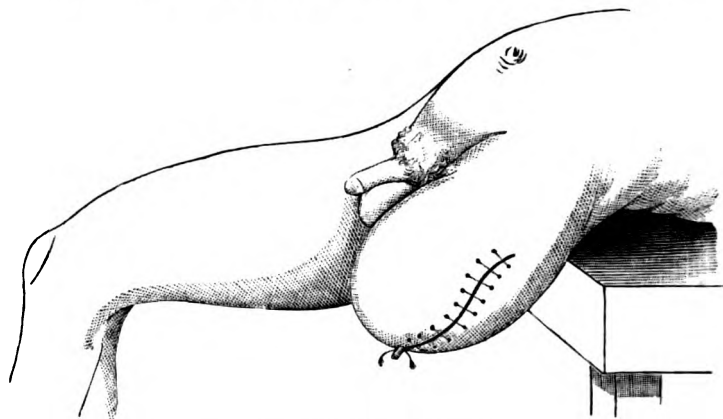


FIG. 453.—Flaps united.

incision extending a little below the gluteal fold, and carried down to the bone; after which the bone is disarticulated, by dividing the capsular ligament and the muscular attachments to the greater and lesser trochanters.

Bring the flaps into position, unite with sutures, and insert a long, large drainage-tube into the acetabulum, allowing it to protrude at the center of the flaps (Fig. 453).

Circular Method (Dieffenbach's).—Control the hemorrhage as be-

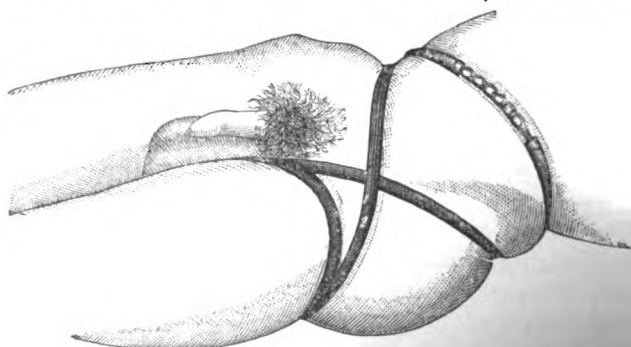


FIG. 454.—Elastic ligature.

fore, or by means of the elastic ligature (Fig. 454), and with a long knife make a circular incision down to the bone, which is then sawn through. Tie all vessels, veins included. If it be impossible to em-

ploy the bloodless method, the femoral vessels should be secured by forceps, or ligatures at the base of Scarpa's triangle, in two situations, and the vessels be divided between them, the proximal end allowed to remain until the operation is completed (Fig. 455). Remove the elastic ligature, secure all bleeding points, and insert a knife two inches above the great trochanter, at its outer side ; carry it down to the bone, over the middle of the trochanter, along the outer surface of the femur to the circular incision.

Then seize the bone with a strong pair of forceps, separate the edges of the vertical incision, and remove the periosteum with a suitable instrument down to the points of muscular insertion. These must be separated by a knife with the edge directed toward the bone. Remove the periosteum in this

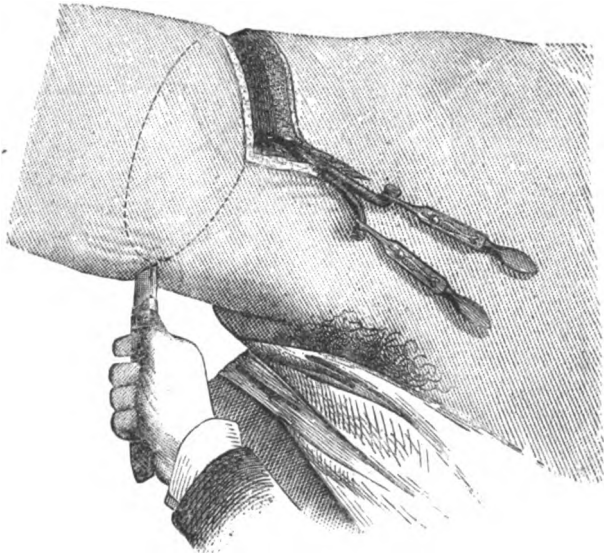


FIG. 455.—Dieffenbach's circular method.

manner up to the capsule (Fig. 456), which is opened and the head dislocated. The last step of the operation is attended with but slight loss of blood. Fig. 457 shows the appearance of the parts after their coaptation. An additional drainage-tube is inserted at the lower extremity of the wound. If the muscles are large, the flaps can be variously modified by employing either the ordinary circular or the long anterior flap, with a posterior circular incision below the gluteal fold.

If there be a deficiency of tissue on the anterior surface of the thigh, the long posterior flap can be supplemented by a transverse incision below Poupart's ligament, remembering to pass a large drainage-tube in the course of the retreating extremities of the divided psoas and iliacus tendons.

Single-Flap Method (Malgaigne).—This admits of rapid execution, and, were it not for the available anæsthetic, would be the proper operation to select, in view of the additional shock caused by the more methodical procedures advocated elsewhere.

Having controlled the circulation, place the patient on the table, with the hip overhanging the edge. The surgeon, standing at the outer

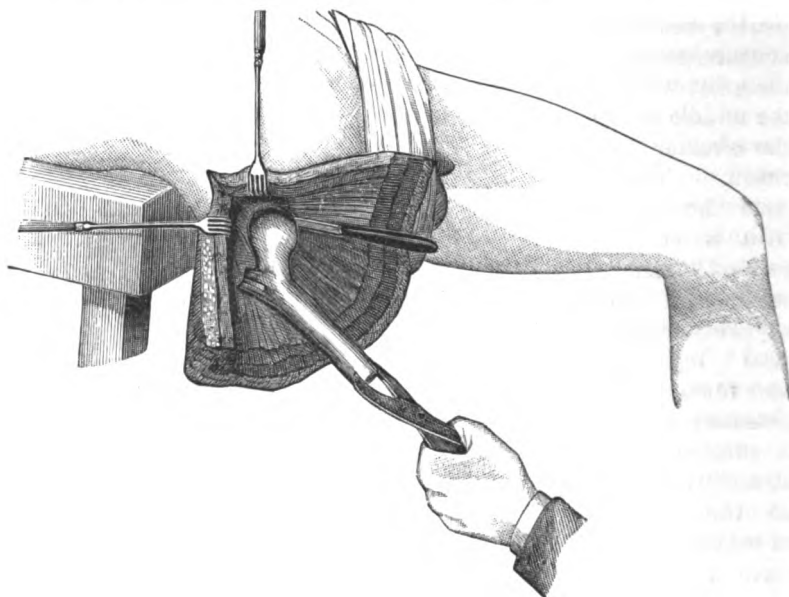


FIG. 456.—Removing the bone.

side of the limb, which is slightly flexed and separated from its fellow, introduces the point of a long knife midway between the anterior superior spinous process

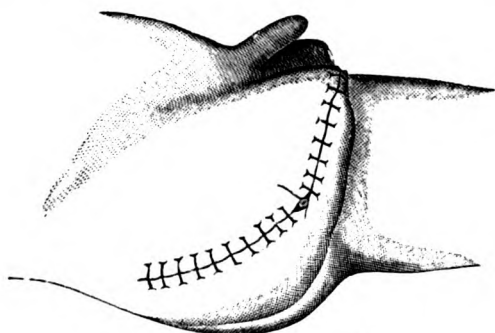


FIG. 457.—Wound closed.

of the ilium and the top of the trochanter major, directing it in the course of Poupart's ligament down to the bone, from which it is carefully withdrawn, and the handle depressed sufficiently to permit the easy passage of the point of the knife across the neck of the femur, and through the anterior portion of the capsule.

If the handle be depressed before the point is raised, the point may be broken. The handle is then raised and pushed onward until the point emerges an inch below and in front of the tuberosity of the ischium (Fig. 458).

The flap is then made by carrying the blade downward six or eight inches along the anterior surface of the bone, parallel with its line of entrance, when it is brought directly to the surface (Fig. 430). Before the vessels are divided an assistant seizes the flap, by inserting the hands into the incision, above the knife, compresses the vessels, and, when severed, carries it upward on the abdomen (Fig. 459) at the same time the surgeon divides the remaining anterior portion of the capsule with the point of the knife; another assistant rotates the thigh inward, that he may sever the attachments to the great trochanter, then quickly rotates it outward and abducts it, causing the head of the bone to escape sufficiently to expose the ligamentum teres, which the surgeon divides with the point of the knife, and as the head slips from its cavity he passes the blade behind it (Fig. 459, 460), seizes the head

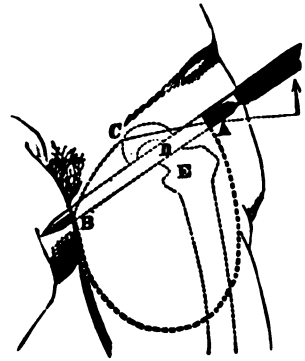


FIG. 458. — Maigne's method. A. Point of entrance of knife. B. Point of exit of knife. C. Poupart's ligament. D. Knife passing through capsule. E. Trochanter major.

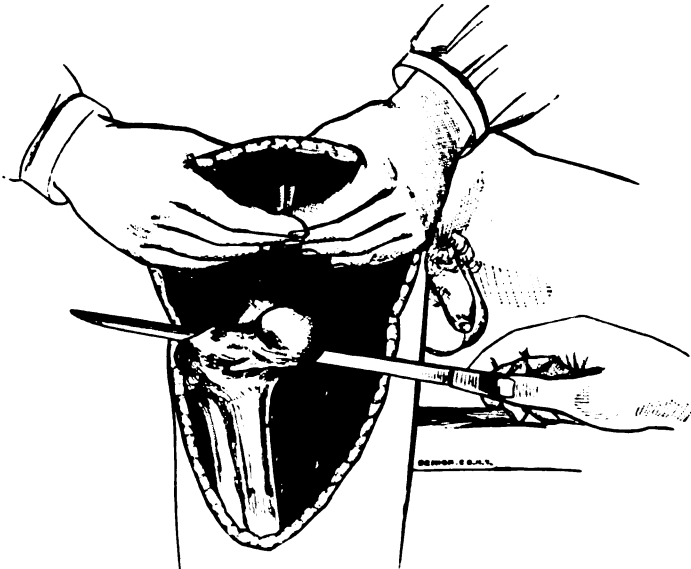


FIG. 459.—Compressing femoral vessels.

of the bone with the left hand, and quickly severs the posterior tissues by an incision directed downward and a little forward.

The lateral-flap method offers no advantages over the antero-posterior, excepting, perhaps, easier drainage. This point, however important it may have been before, like the drainage-tube of the present time, can not now be said to be of such marked significance.

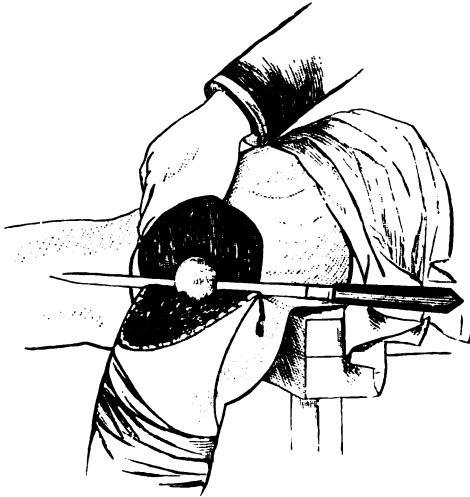


FIG. 460.—Passing blade behind head of bone.

Continue it outward, transversely across the base of the great trochanter, to the gluteal fold, and along this to the inner side of the thigh; then obliquely upward two inches below the genito-crural fold, to the lower end of the vertical incision. Isolate the femoral artery and ligate it above and below the bifurcation of the profunda, and likewise ligate the latter a little distance from its origin. If no intervening branches exist, divide the femoral between the ligatures, isolate the femoral vein, ligature it and divide in the same manner. Carry the incision through the muscles, from whichever aspect of the limb is most convenient, seeking for and ligating all bleeding points as soon as apparent. Open the capsule in front, divide its posterior portion as closely as possible to the neck of the femur, together with the remaining tendons inserted into the head of the great trochanter. Depress the thigh, causing the wound to gape widely, and divide the muscles on its inner and posterior surface, in the same manner as those preceding. Finally, draw down the sciatic nerve, and cut it short enough to be above the border of the flap.

The tissues left are not sufficient to close the wound, which is dressed with a thin layer of tarletan in contact with the cut surface, upon which charpie saturated with some antiseptic solution is placed, and the whole covered with cotton batting surrounded by oiled silk, which is held in position by a simple bandage. The wound is kept moist with the antiseptic solution.

Anterior Oval Method (Verneuil).—Apply the elastic bandage as far up as consistent with the proposed incision. Control the aorta and make an incision through the integument and fascia, commencing an inch below Poupart's ligament, in the course of the femoral vessels, two inches in length; con-

Results.—The rate of mortality is governed by the cause calling for the operation.

In immediate amputation in military practice, ninety-three per cent die.

In civil practice, the mortality after the primary amputations reaches eighty per cent. Secondary amputations offer better results; sixty per cent recover in the civil and military combined.

The results are more favorable in non-traumatic cases, being less than forty-one per cent. Taken together, the rate is a little over sixty-four per cent, being a trifle more than for amputation in the continuity of the thigh, which is about sixty-three and a half per cent.

CHAPTER XI.

DEFORMITIES.

DEFORMITIES may be either congenital or acquired, and in either case they can be referred to the soft or hard parts, either individually or conjointly.

The acquired deformities calling for operation in a special sense depend on ankylosis of joints, distorted shafts and extremities of bones, irregular or unequal muscular contraction, and the congenital fusion of parts. To overcome the deformities dependent upon ankylosis, we resort to forcible movement, if it be fibrous; and the division of the bone, or joint structure, if it be bony.

The forcible breaking of an ankylosed joint, while not an operation in the accepted sense of the term, is nevertheless often associated with consequent complications, which entitle it to a greater degree of prominence than many accepted operative procedures.

Brisement Forcé, as it is sometimes called, should be preceded by subcutaneous section of all the tendons, muscles, and fascia upon which "point pressure" causes reflex action.

The incisions having united, place the patient upon a hard table, administer an anæsthetic, and while the portion of the limb between the joint and the body of the patient is held firmly by assistants, the surgeon seizes the distal portion and forcibly flexes it, employing steady and persistent force. As soon as moderate movement follows flexion, it is then forcibly extended, and by repeated flexion and extension the range of motion of the joint is re-established.

If the knee be the one in question, the patella must be loosened before it is attempted. After the operation, support the toes and band-

age the limb from the toes to the knee firmly, having first applied adhesive plaster for the purpose of extension. Pad the popliteal space with cotton, and compress the knee-joint with strips of adhesive plaster. Continue the roller over the knee and up the thigh, applying pressure to the femoral artery by means of a small piece of wet sponge, applied over its course and held in position by the ascending bandage.

Place the patient in bed, apply extension, with the foot of the bed elevated, also ice-bags to the knee, the limb being immovably confined. At the end of five or six days the dressings are opened and again replaced, after slight motion is made. The sponge over the femoral artery is omitted.




FIG. 461.—Barton's operation.

If the *anchylosis be bony*, the deformity can be relieved by osteotomy above the condyles, and, if necessary, below the head of the tibia at the same time, or by excision of the joint, or by the removal of a triangular piece above the joint, having the same angle as that formed by the junction of the tibia and femur in the popliteal space. The same principle can be applied above the knee as practiced by Barton (Fig. 461).

Boring the joint and other expedients

have been resorted to. The most satisfactory of all, however, is osteotomy above the condyles, which is described under that heading.

In all joints, anchylosis is amenable to the same procedures as previously stated.

Deformities caused by distortion of the long bones can be best corrected by osteotomy, associated with the antiseptic dressing.

Curvature of the Spine.—A popular method of treatment at the present time is the application of the plaster-of-Paris dressing. The body of the patient is first surrounded by a closely-fitting knit jacket, between which and the region of the stomach is introduced a wedge-shaped "dinner-pad," with the point downward; composed of several thick-

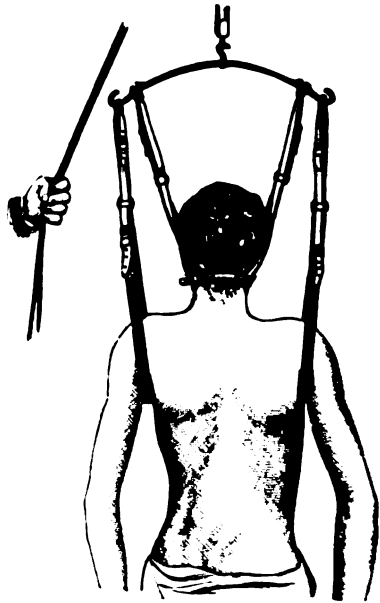


FIG. 462.—Apparatus applied.

nesses of cloth, or cotton wadding surrounded by it. All sensitive parts and projecting points should be relieved from direct pressure by spongio-piline, cotton, or other similar material. The same can be placed over the iliac spines and the adjoining portions of the crest.

“The mammary glands in the female should be protected, and suitable space be provided by the introduction of properly shaped pads.

“Tie the shirt over the shoulders and fasten it between the legs. Then the patient is drawn up by the extending apparatus (Figs. 462, 463, and 464) gently and slowly until he feels perfectly comfortable, *and never beyond that point.* A prepared, saturated plaster-of-Paris roller having been

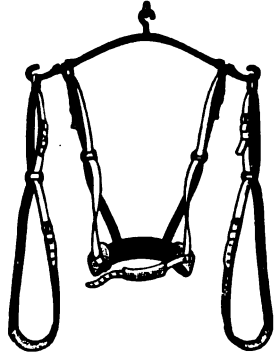


FIG. 463.—Extension apparatus.



FIG. 464.—Body extended.

gently squeezed, so that all surplus water is removed, is now applied around the smallest part of the body, and is carried round and round the trunk downward to the crest of the ilium and a little beyond it; afterward in a spiral direction from below upward, until the entire trunk from the pelvis to the axillæ has been incased.

“The bandage should be placed smoothly round the body, and must not be drawn tight; it should be simply unrolled with one hand while the other follows and brings it into smooth close contact with all irregularities of the trunk.

“After one or two thicknesses of bandage have been placed around the body in the manner described, narrow strips of roughened tin can be placed parallel with each other on either side of the spine, if the case requires it, with intervals of two or three inches, and in number

sufficient to surround the body. Over these another plaster bandage is applied. In a very short time the plaster sets with sufficient firmness, so that the patient can be removed from the suspending apparatus and laid upon his face or back on a hair mattress, or, what is preferable, especially when there is much projection of the spinous processes or sternum, an air-bed. Before the plaster has completely set, the "dinner-pad" is removed, and the plaster gently pressed in with the hand, in front of each anterior iliac spinous process, for the purpose of molding the case over the bony projections.

"While the jacket is drying it is necessary, sometimes, to wet it with a little water and dust it with more plaster. The surgeon often leaves some weak spots that need strengthening in this manner." The preceding is a description as recorded by Dr. Sayre, to whom the profession is indebted for the prominence which has been given this method.

The Deformities dependent upon Perverse Muscular Action are, in an operative sense, relieved by subcutaneous division, called myotomy and tenotomy, which has been before considered.

Deformities due to Fusion of the parts and supernumerary attachments, like webbed fingers and toes, and supernumerary digits, although not common, are, nevertheless, entitled to some consideration.

Webbed Fingers.—The operative treatment will depend very much upon the extent as well as the thickness of the attachments; whether the connections be limited to the soft parts alone, or the bones be fused. Digits that are united by their extremities only can easily be separated by the division of the tissues which connect them. If they

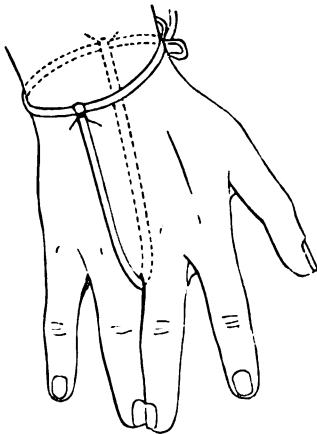


FIG. 465.—Webbed fingers.

be united their entire length, even then an incision in the median line of their attachments, down to the line of the normal web, may be sufficient to effect a cure, if the tissues connecting them be not too thick; if such be the case, great difficulty is often experienced in healing the divided surfaces, owing to the tendency to reunion at their point of junction. To obviate this, various expedients have been recommended, one of which is to introduce a rubber seton at the base of the malformation, on a line with the normal web of the hand, and allow it to remain until the opening becomes permanent (Fig. 465), when the remaining portion is divided

and the borders united by sutures. Another plan is to make a triangular flap from the posterior portion of the web, the base to remain

attached, and to correspond in shape and size to the space between the knuckles.

Its apex is of course directed to the free edge of the abnormal attachment. The flap having been raised, the remaining portion of the attachment between the fingers is divided, and the triangular flap adjusted to the base of the cleft, and kept in position until union takes place. The remaining borders of the wound are united by sutures the same as before.

It has been suggested to make two such flaps, one on the palmar and one on the dorsal aspect, in the same situation ; to cut off their extremities and unite them at the cleft, when the remaining portion can be divided longitudinally.

Another, a very effectual and ingenious method, is best described by M. Nélaton, its designer : "A longitudinal incision is made in the center of the phalanx of one finger on the dorsal aspect, for the posterior flap ; on the palmar aspect of the other for the dorsal flap, the length of the incision will correspond with the depth of the web. From either extremity of the longitudinal incision, a small transverse one is to be made toward the phalanx of the connected finger (Fig. 466, B). The lower transverse incision will correspond to the free edges of the web ; the upper one will cross the cleft between the fingers.

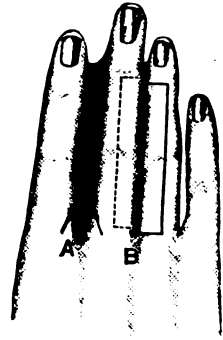


Fig. 466.—Nélaton's method.

Each flap is now to be dissected back toward the contiguous fingers. In doing this the two folds of the web will be separated from each other, one entering into the formation of the posterior flap, the other into the formation of the anterior. Each flap will now be found to be attached by one edge only, and is to be wrapped around the denuded surface of the finger to which it is attached. The flaps are to be adjusted by strips of adhesive plaster, and by sutures."

Annandale says : "The principal objection to this ingenious operation appears to me to be that it necessitates cutting into the palmar and dorsal aspects of the fingers in order to get a flap to cover their sides." If the web or fold of the skin be loose, he deems it preferable "to make the longitudinal incision along the sides of each finger instead of along the center of the dorsal and palmar aspects." Triangular flaps may be made at the base of the web, and the remainder cut directly through (Fig. 466, A). If Nélaton's operation be performed, care must be taken in uniting the flap, or sloughing will follow. When the joints of the digits are fused, it is not wise, as a rule, to attempt their separation, since, though it be accomplished, the remaining digit may have its function greatly impaired ; however, this course is not so imperative now, since the advent of antisepsis. If

a supernumerary digit possess an independent articulation, it can be removed without any great danger to its associate.

Ingrowing Toe-nail.—This is quite a common affliction, to the relief of which various palliative measures have been directed. As a rule, however, they have been found inadequate to effect a cure. This condition is largely induced by improperly fitting boots and shoes, although in some persons there exist additional predisposing causes. Going barefooted would in a majority of cases bring about a speedy cure, but, since this is impracticable, operative measures are often necessary.

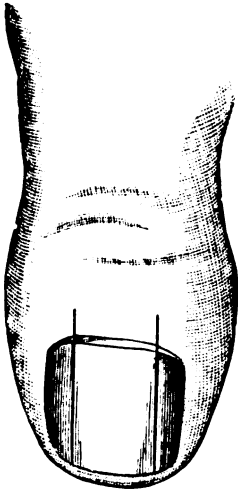


FIG. 467.—Ingrowing nail.

Operation.—When the affection is fully established, administer an anæsthetic, and with a sharp-pointed scalpel divide the nail its whole length on a line with its ingrowing portion (Fig. 467), which portion can then be quickly and easily removed by a thin-bladed pair of forceps, or a narrow spatula passed beneath it. If the other side be affected, it too should be removed in the same manner. Cauterize the exposed matrix and apply a hot anodyne poultice at once. The patient must keep quiet until the tenderness has in a measure subsided. In no instance ought the entire nail to be removed, unless it be diseased.

Bunion.—This affliction is accompanied in a large proportion of cases by malposition of the great toe (Fig. 468), and an increase in the normal size of the bursa, or the development of an adventitious one. The operative means for relief consist either in the excision of the bursa, or its subcutaneous division into numerous fragments by means of a narrow tenotome. If these means fail, a sufficient amount of the metatarsal bone should be excised to admit of the toe being returned to its normal position, or the operation described on page 222 can be performed, after which the toe is confined in place until recovery is established.



FIG. 468.—Bunion with hallux valgus.

Flat Foot.—*Ogston's Operation.*—With the foot lying on its outer side, an incision an inch and a quarter in length is made parallel with the sole down to and at the inner side of the bones forming the astragalo-scapoid articulation. The ligamentous structures are detached from the bones for half an inch at either side of the wound, with a knife and periosteal elevator. As

soon as the contiguous articular surfaces of the scaphoid and astragalus are well exposed, they are denuded of their cartilage and of a sufficient amount of bone to permit the correction of the deformity and the perfect coaptation of the cut surfaces. The surfaces are then fastened together by ivory pegs or by wiring. If the motion between the internal cuneiform and scaphoid bones be unusually free, their contiguous surfaces can be treated in a similar manner instead.

Results.—If performed with strict antisepsis, the danger to life is slight. The ankylosed arch gives the patient a useful foot. Stokes' operation, it is claimed, corrects the deformity, which if true makes it much the more preferable operation, as it does not involve the joint.

Astragaloid Osteotomy (Stokes).—This operation is recommended to relieve the deformity of flat foot, and should only be conducted under strict antiseptic precautions.

Operation.—Make an incision an inch and a half in length along the inner side of the foot, the center of which should correspond to the prominence caused by the head of the astragalus; at the center of this another is made about three fourths of an inch in length at right angles to it, and situated a little behind the medio-tarsal joint. The triangular flaps thus formed are dissected back half or three fourths of an inch. A wedge-shaped piece of bone is then removed from the head and neck of the astragalus with an osteotome; the foot adducted and supinated, in which position it is retained until recovery takes place.

Results have thus far been satisfactory, but as yet there are not sufficient data upon which to estimate a mortality record.

Tarsectomy.—In old and obstinate cases of talipes varus and equino-varus, this method of treatment has been performed with varying success for a long time.

Operation.—Place the foot on its inner side and make an incision parallel to the sole down upon the outer border of the cuboid bone, its entire length, and expose its upper and lower surfaces by means of a knife and periosteotome, carefully protecting the surrounding soft parts from injury. A triangular piece of bone, with the base outward, is then removed from the cuboid of sufficient dimensions to admit of the correction of the deformity. In extreme cases the entire cuboid and even portions of the contiguous bones may be included in the base of the wedge. As soon as the deformity can be reduced, the bony surfaces are wired together, the limb dressed antiseptically, and the foot confined in the corrected position until recovery takes place.

Results.—When cautiously done, the dangers to life do not contraindicate the measure, and the usefulness of the limb is very much enhanced.

CHAPTER XII

PLASTIC SURGERY.

THIS form of operative surgery relates to the various means adopted to overcome or alleviate the deformities of aspect and function resulting from congenital defects, disease, and accidents.

Inasmuch as the successful issue of these operations depends far more on the careful attention to the details and small matters connected with them than anything else, it is well for the operator to understand at once that there is no precaution too trifling to be treated with indifference.

Preparation of the Patient.—The patient ought to be in a vigorous physical condition, his appetite and functions normal, and the surroundings of such a character as to combine quietude of mind with close and gentle attention. No association can be allowed with putrefactive processes, or diseases known to engender changes derogatory to union and repair. Prior to the operation, the part should be purified by a solution of carbolic acid or other suitable agent.

Size of the Flap.—The shape and size of the flap must be ascertained by careful measurement. A pattern of the deformity to be repaired is to be carefully cut out and used to outline the tissues to be employed in filling the gap, since the contractile power of the normal tissues, when loosened from their underlying attachments, causes enough shrinkage to require undue force to maintain proper coaptation of the borders. The reparative flaps must always be made large enough to admit of at least three lines of shrinkage to each inch of their surface.

In choosing the material to form the flap, it is necessary that it consist of sound, healthy skin; and under no consideration can cicatricial tissue possessed of a pale, glossy surface be employed; for, when its subcutaneous connections are severed, it is almost certain to slough, especially when the result of a burn. The thickness of the flap should be sufficient to include all the vessels that normally afford it nourishment. The relation which cicatricial tissue bears to a flap is all-important. If it exists at its base, sloughing is quite certain to occur. Cicatricial tissue at the border of a flap is quite certain to die, and its presence must not be estimated in computing the area of the new flap. When the new flap is to be surrounded on three sides by cicatricial formations, its base must be large, vascular, and but little twisted, as the medium of supply at its sides will be very much lessened by its new association. The long axis of the flap should correspond to the course of the vessels from which it derives its nourishment, and its base must be located as nearly as possible to the nutrient vessels. All hemorrhage must be checked before the flaps are united, since it

not infrequently happens that a thin clot of blood prevents union. The direction of the flap should be such that it can be placed with the least twisting of the pedicle. The silver wire and carbolized silk, or horse-hair, make efficient sutures, which should not be drawn tightly. To avoid the danger of ulceration at the pressure points, small squares of carbolized, bibulous, or unglazed paper, having a diameter of half an inch or less (Fig. 469), with small holes through the center, or punctured through the center by the pin or needle carrier at the time of carrying the ligature, can be used to tie them upon. The edges of flaps may be beveled; this increases the width of the opposed surfaces, and, when combined with undercutting of the other borders, increases the chances of union. A small slip of the aseptic bibulous paper can be placed between the sutures and the edges of the wound at the point of crossing. The use of carbolized cotton yarn, which is to be frequently changed, in connection with the plastic pins, offers a soft and otherwise admirable retaining agent.

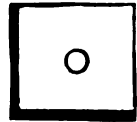


FIG. 469.—Paper protective.

If small pins be inserted to indicate the extent of flaps, the incisions will be made more accurately than if they be formed by the aid of the eye alone.

Methods of Transfer.—The methods of transfer may be classified into six general forms, with their subdivisions: 1. Sliding in a direct line. 2. Sliding in a curved line. 3. Jumping. 4. Inversion, or eversion. 5. The Taliacotian. 6. Grafting.

Sliding in a Direct Line.—*The first and simplest variety* of this method consists in uniting the lips of an ordinary incision, and is sometimes called “simple approximation of divided surfaces.”

The second variety is called “undercutting,” and consists in cutting under the edges of the incision at each side, and drawing them together.

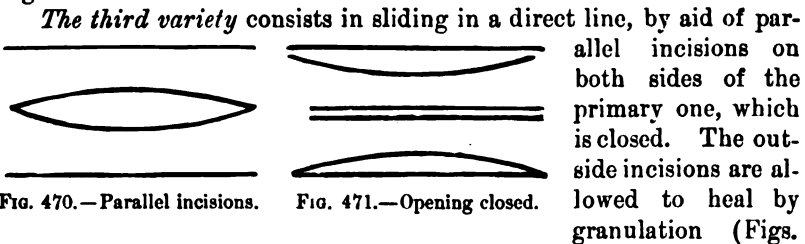


FIG. 470.—Parallel incisions.

FIG. 471.—Opening closed.

Undercutting in this method lessens the tendency to separation of the parallel lines.

In the fourth method the liberating incisions are made transversely, that is, at right angles to the extremities of the oval opening, and undercutting is employed (Figs. 472 and 473) to enable this opening to be closed. The uppermost curve is undercut, and the lowermost is

liberated by a combination of undercutting and sliding by the aid of the transverse incisions. If this method be applied to those parts which can not resist the traction of the displaced tissue, a second deformity is liable to follow.

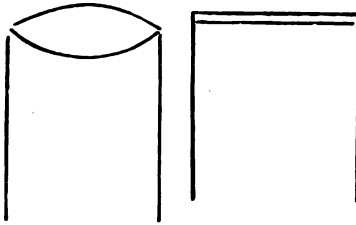


FIG. 472.—Transverse incision. FIG. 473.—Opening closed.

Sliding in a Curved Line.—This operation can be done with flaps having either curved or angular borders. In the former instance, the space from which the flap is taken is filled by undercutting its borders and drawing them together. In the latter, the space is usually allowed to granulate.

Jumping.—Jumping, as the name implies, consists in “jumping a flap connected by a pedicle over intervening undetached tissues.” It can be done with or without the pedicle being twisted.

If the flap be not moved more than a quarter of a circle, twisting of the pedicle is not necessary. Undercutting is employed in this operation when necessary to adjust the parts properly.

The plan of operation without twisting the pedicle is shown in Fig. 474. When the flap is moved more than a quarter of a circle, the pedicle will be twisted, and the degree of twisting will depend on the distance the flap is moved.

If the pedicle be too much twisted, the circulation of the flap will be impeded, and sloughing may ensue.

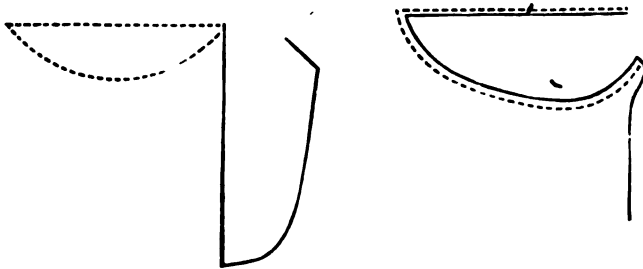


FIG. 474.—Jumping method.

Inversion or Eversion.—These methods relate simply to the employment of integument in the repair of mucous membrane, or *vice versa*. Tubular formations may be constructed by either of these methods, as in the formation of new canals, like the urethra, vagina, and the closure of an extroverted bladder.

The Taliacotian Operation.—This operation is familiarly known as the dissection of a flap from another and distant portion of the

body, allowing it to granulate, and applying it to the part to be repaired, as is done in the ordinary operation for the construction of a new nose.

Grafting.—This method is but little employed, and the operation is performed by entirely removing a flap from one place to the locality to be repaired.

Skin-grafting, in the common acceptation of the term, is employed to cause the healing of extensive granulating surfaces, when of a healthy character. It is performed by first making small punctures in the granulating surface with the sharp end of the common pocket-probe, half an inch or so apart; and, second, by placing over the open mouths of these shallow punctures small pieces of integument, a line or two square, with the fresh surface downward. They are then pushed into the openings of the punctures, by the same probe, in such a manner as to cause a close contact between the raw surfaces of the small "grafts" and those of the punctures in the granulating surface. Small pieces of lint are placed over each "graft," and the whole is confined in position by narrow strips of adhesive plaster. The part should be carefully redressed at the end of three or four days.

Rhinoplasty.—This operation consists in the reproduction of a part or the whole of the nasal organ. The present ability of the surgeon to arrest the diseases causing deformities of the nose has lessened the frequency of this operation. Ingenious contrivances of ivory, rubber, etc., have been made to fit the nose, and to thus supply a substitute for the lost parts. These contrivances, when tinted to conform to the complexion of the wearer, often prove quite deceptive to the observer; but, being unaffected by the various contingencies of the weather and the emotions, they are apt at times to cause the wearer to present a ludicrous appearance. In operating on the nose, save all that is possible of its cartilaginous and bony tissues, for they will each afford important supports for the new structure. The cartilages of the alæ should, when possible, constitute the free border of the new structure.

The deformities of this organ may be due: 1, to a loss of the superficial soft parts, which may vary in extent and degree; 2, to a loss of the bony or cartilaginous septum, with or without loss of the nasal bones; 3, to a loss of both combined. The soft parts may be restored by either of the five methods before named. The extent of the deformity and its situation will determine the choice of a method. When the loss of the integument is small and does not involve the alæ and the deeper structures, the deformity may be remedied by the direct approximation of its borders, aided, of course, by a free undercutting with or without parallel incisions. The French method, by transverse incisions combined with undercutting, can be employed (Fig. 475) when the former is deemed inadequate. If the extremity of the nose or the alæ be involved, the second method, or "sliding in a curved

line," the flap having either curved or angular borders, is recommended. Fig. 476 represents the restoration of the alæ by a flap taken



FIG. 475.—Closure by transverse incisions.

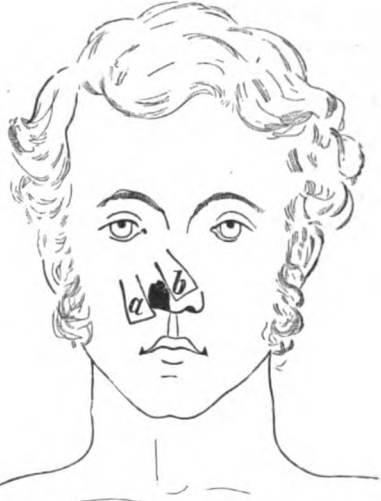

FIG. 476.—Repair by sliding.

from the cheek (*a*). It must be of sufficient size to allow at least one fourth for its contraction, otherwise, when united in position, it will displace the axis of the nose, thereby substituting one deformity for another.

Langenbeck repaired a similar deformity by taking a flap from the opposite side of the nose (*b*). As in the preceding method, the dissection must be carefully made down to the cartilaginous frame-work. The border of the new ala, although freshly cut, heals in a satisfactory manner. Fig. 477 shows the line of incision employed to repair

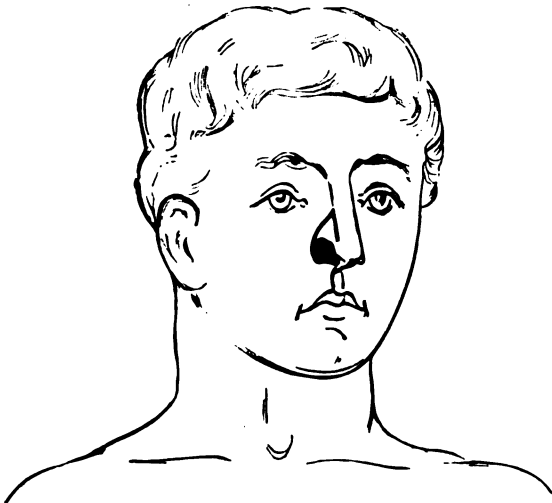

FIG. 477.—Repair by sliding.

the deformity with a flap possessing an already cicatrized border.

The vascular supply of this flap is not active, and every precaution should, therefore, be taken to provide against the danger of sloughing. If either ala be absent, and the resulting gap be a large one, the material for its repair can be taken from the forehead, as shown in Figs. 478 and 479. It will be seen that the pedicles are admirably located to receive ample nourishment. The loss of an ala or of the end of the nose may be repaired from the tissue of the upper lip (Fig. 480) or the cheek.

If the columna be absent, it may be replaced by structures taken from the upper lip. In this operation it is better to include the whole thickness of the lip, tipping the flap directly upward into place, than to make an integumentary flap, the adjustment of which will require a smart twisting of the pedicle. In the former instance the cuticle is dissected off

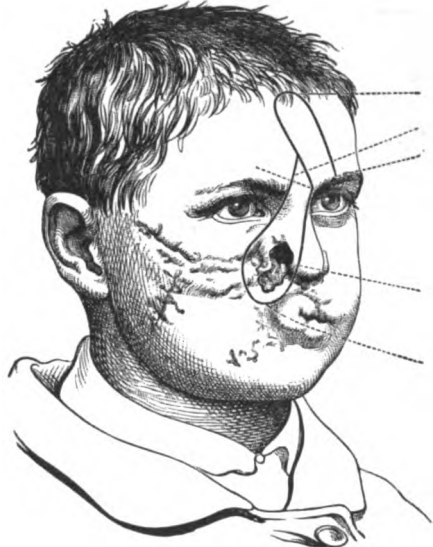

FIG. 478.—Repair by jumping.

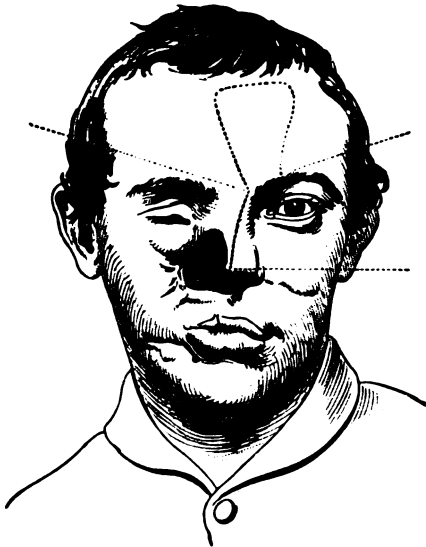


FIG. 479.—Repair by jumping.

and the raw surface carried directly into its position. The mucous surface of the flap soon assumes integumentary characteristics. If the lip be deficient at the point of selection, a flap can be taken from beneath either ala and carried into place.

Loss of the Bony or Cartilaginous Septum, with or without Loss of the Nasal Bones.—The loss of the cartilaginous portion of the septum, the other tissues remaining intact, causes a flattening of the end of the nose, or a depression at the lower end of the nasal bones. The operation of sliding the tissues may

temporarily relieve the deformity ; but traction of the flap and various interferences from without soon reproduce it.

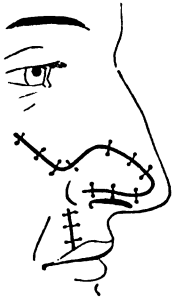


FIG. 480.—Repair by jumping.

Mechanical ingenuity bids fair to afford more relief for this deformity than surgical, especially if the defect be associated with an opening through the hard palate. If the nasal bones be intact, the loss of the bony septum is not manifested by any external deviation of the organ. If both the septum and nasal bones be gone, it then becomes necessary, in order to relieve the deformity, to elevate and maintain in position the tissues composing the soft parts of the nose. To accomplish this requires an internal support of some sort, although much may be gained by dissecting up the soft parts on each side of the nose, and raising them in the line of the bridge by approximating their bases in position by means of pins passed through them, and confining them until union of the flaps takes place. In 1829 Dieffenbach published a method of performing an operation by which he overcame the deformity resulting from the loss of the nasal bones and the septum. An incision was made with a narrow-bladed knife along the outer side of the sunken border of each nostril, the intervening strip being three times broader at its connections with the upper lip than above where it joined the forehead. At the outer side of each of these incisions, another was made down to the bone, which began a few lines below, and to the outer side of the first, and was carried obliquely downward, parallel with the primary one, and external to the side of the nose, around into the nostril, thereby separating the ala. The columella was elongated by short parallel incisions in the upper lip, and the cheeks were dissected up from their bony attachments, through the lateral cuts, sufficiently to render them freely movable. The flaps were then raised, their borders were pared obliquely, reunited and fastened with pins and sutures, and retained in position by drawing the de-



FIG. 481.—Dieffenbach's method.

tached portions of the cheeks toward the median line of the nose, where they were fixed by two long pins passed through their borders, under the nose. In this instance the pins were passed through two narrow strips of leather, which equalized the force and prevented the production by the pins of premature ulceration. A quill surrounded by oiled lint was then introduced into each nostril. The accompanying figure illustrates the proceeding, with its result (Fig. 481).

Superimposed superficial flaps were successfully employed by Verneuil. In this case the *alæ* and tip of the nose were uninjured, but

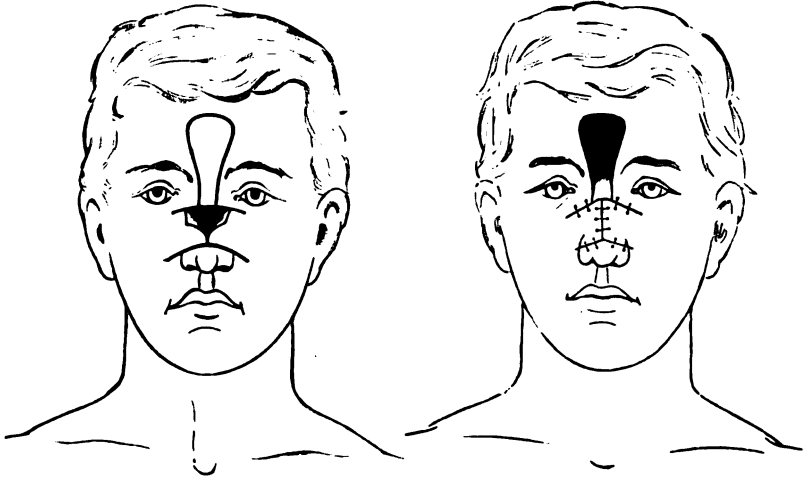


FIG. 482.—Verneuil's method.

were flattened by loss of the support of the septum. He made a longitudinal incision along the median line of the nose at the center of the depression, and a transverse one extending from each end of the first to just beyond the contour of the nose (Fig. 482), and dissected the flaps freely from their attachments. An oblong flap of suitable size was then raised from the forehead, its pedicle being located directly between the eyes; this flap was turned downward, bringing its raw surface uppermost. The lateral flaps were then drawn inward and placed upon it and united in the median line.

The Indian Method (483).—This was at one time the prevailing method of operation when the septum and a large proportion of the soft parts of the nose were absent, and was employed even when the lower extremities of the nasal bones had sustained a loss. The tendency to atrophy and sliding down of the flap after union had taken place, accompanied by closure of the nostrils and danger to the life of the patient from the operation, caused the substitution for it of more

satisfactory measures. A flap was made from the integument of the forehead of the same shape, but of one fourth larger size than the

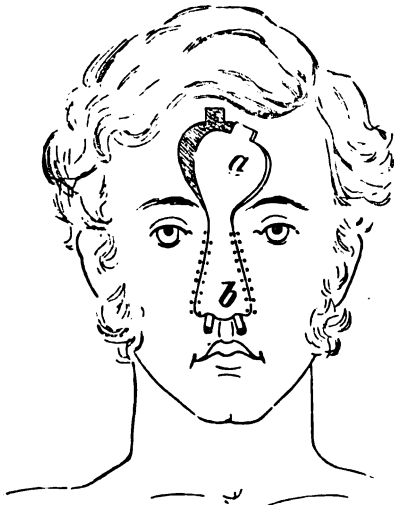


FIG. 483.—Indian method.

gap to be filled; its base was half an inch broad, and located between the eyebrows. The flap was therefore substantially the shape of the ace of spades, and included all the tissues down to the periosteum (Fig. 483, *a*), the stem above being intended to form the columna. The edges of the gap were freshened, and the flap, with the raw surface undermost, was twisted on its pedicle and attached to the margins of the gap. The flap was then made prominent, *b*, by the aid of greased plugs introduced into the nostrils, and also by drawing the cheeks toward the median line, where they were fastened by means of pins passed

through them beneath the nose. The tendency of the flap to slide downward has been combated in various ways—such as connecting the pedicle with a longitudinal incision at the side of the nose, the attachment of its whole length to a newly formed raw surface at its base, and grafting the sharpened pedicle into the integument at its base.

Italian Method.—This old method has many virtues, and, were it not for the great difficulty of keeping the parts in position, would be much more employed. The flap is taken from over the biceps, with its apex toward the shoulder. It is first dissected up, and its extremities allowed to remain attached, until suppuration is established, when the proximal end is separated and the dressing continued until the flap is well shrunken and the under surface cicatrized. It is then applied to the gap after the borders of both have been freshened (Fig. 484). When

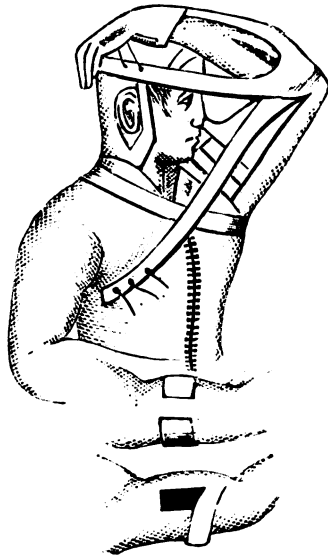


FIG. 484.—Italian method.

union is completed, the pedicle is cut, and the flap is fashioned so as to relieve the deformity in the best possible manner.

Osteoplastic Rhinoplasty.—The periosteum has been removed frequently from a part of the frontal bone, in connection with the flap, and consigned to the gap, with the hope that the formation of new bone might occur, so as to give solidity as well as prominence to the new nose. The removal of the periosteum from the frontal bone is not by any means devoid of danger. Osteo-myelitis has arisen therefrom, followed by pyæmia and death. The periosteum may be used to form a portion of the flap first applied, in the double-flap method, illustrated in Fig. 485. It is true that the relation of its surfaces will be reversed, but this can not change its bone-producing value; moreover, if bone be formed, it can be easily shaped by manipulation to suit the proposed outline of the organ.

Ollier's Method. — An operation was performed some time since by Ollier, for a deformity caused by the loss of the alæ, columna, cartilages, lobe, and a portion of the septum, due to lupus. The nose was not more than an inch long, due to arrest of develop-

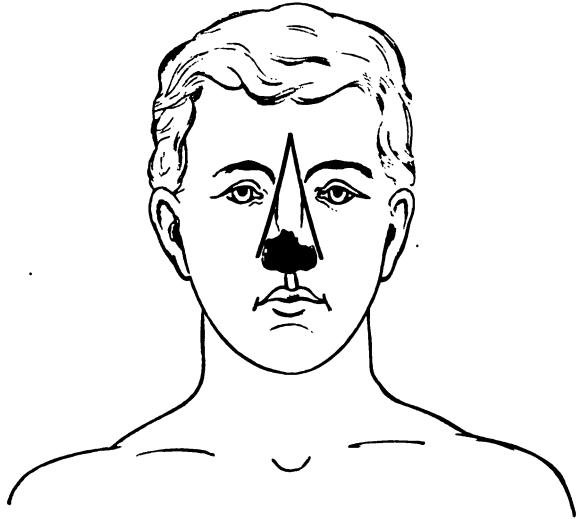


FIG. 485.—Ollier's method.

ment of the ossa nasi, to which was attached a strip of cartilage. The integument of the lip and cheeks had been involved, and could not therefore be depended upon for flaps.

Ollier commenced two diverging incisions in the median line of the forehead, two inches above the eyebrows, and carried them downward to a fourth of an inch from the outer side of the nasal orifice (Fig. 485). The upper portion of the triangular flap included the corresponding portion of periosteum down to the upper end of the nasal bones. The dissection was continued along the right nasal bone, omitting the periosteum, down to its lower end, from which the cartilage was separated; but it remained attached to the flap. The left nasal bone was separated from its bony connections with a chisel,

leaving it attached to the flap by its anterior surface ; the cartilaginous septum was then divided from before backward and downward with scissors, and left attached by its base to the cutaneous cartilage, that a central support might be provided for the new structure. The whole flap was then drawn downward, until the upper border of the loosened nasal bone (left) came opposite to the lower border of the right one, when they were fastened together with a metallic suture. The sides of the flap were then united to the cheek and the frontal incision closed above its apex.

In this case, the space left by the removal of the left nasal bone was filled by bone developed from the periosteum that had been slid down from the forehead.

This variety of deformity has also been relieved by attaching a finger to the sides of the nasal chasm. The nail was first removed and the palmar surface of the finger was denuded, by the formation of lateral flaps, down to the distal third of the first phalanx. The finger was then fastened into position upon the freshened borders of the deformity, by means of sutures passed through the lateral flaps, and, when union was sufficient to sustain the nutrition of the part, the finger was amputated at the juncture of the middle and distal thirds of the third surgical phalanx, and the distal end turned downward to form the end of the nose and its columna.

The detail essential to the proper description of this operation, which was lately done with success by Prof. T. T. Sabine, is too extensive to be considered here. A full account of this very interesting case can be found in the April number of the "Illustrated Quarterly of Medicine and Surgery," 1882.

Subcutaneous Method.—This method consists in the subcutaneous division of the depressed tissues, so that they are separated from their bony connections, as was done by Prof. Pancoast in 1842, and can be best described in his own language :

"A long, narrow-bladed tenotomy-knife was introduced on either side by a puncture through the skin over the edge of the nasal process of the upper maxillary bone. The knife was pushed up under the skin to the top of the nasal cavity, and then brought down, shaving the inner side of the bony wall, so as to detach the adherent and inverted nose upon either side. The point of the nose could now be brought out. The nose still remained adherent to the top of the nasal chasm. The knife was a third time introduced under the skin, in a direction corresponding nearly to the long diameter of the orbit of the eyes, and the adhesions separated from the nasal spine and the internal angular processes of the os frontis. The soft parts and the cheeks were loosened, by sweeping the knife outward along the surface of the bone, so far as to divide the infra-orbital nerve and artery on each side, down toward the median line,

and held together with sutures passed through the cavity of the nose."

As before mentioned, mechanical appliances can be employed to support the soft parts of the nose, provided an opening exist through the roof of the mouth. Fig. 486 shows a lever sometimes employed to raise and support the parts in proper position.

In this instance, however, the lever is attached to an apparatus intended to relieve an additional deformity. "The processes E E pass into the nose, and support the sunken portion. The nasal elevator must be so arranged as to fall back of the line B B, to be introduced, and then must extend into its position.

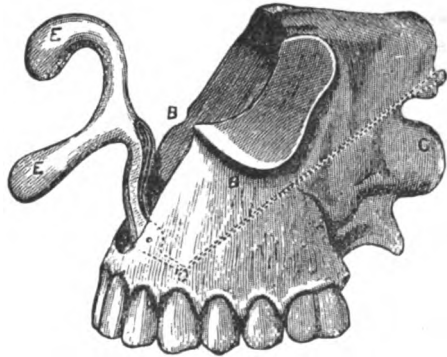


FIG. 486.—Kingsley's nasal lever.

This is accomplished by attaching the elevator to the denture by a joint, as seen in the engraving, and also by extending an arm of the elevator within the shell, and terminating it with a hook." The dotted lines show the lower end of the lever and the elastic attachment which retains it in position. The irritation consequent upon the pressure of the lever is not severe, and can be lessened by covering the ends with lint, cerate, etc.

The degree of elastic tension can be regulated at the will of the patient, and even be entirely removed during the night.

Hare-lip.—This deformity constitutes a large proportion of the congenital defects calling for operations upon the face.

Operations for its relief can be performed at any age, but the best time is as soon after birth as the infant becomes well educated to take its food and enabled to bear the loss of blood. If the infant be plump and robust, it can be performed earlier than if weak and puny. The exceptions are rare when it is not admissible at three months of age. It is important to have complete control of the patient during the operation. For this purpose, an anæsthetic should always be given, chloroform being usually selected. The arms of the patient are placed at the sides, and are held in position by a napkin surrounding the body and pinned sufficiently tight to prevent their withdrawal.

One assistant takes the child in his lap, while another stands behind the former and holds the infant's body. The head is firmly held between the hands of the first assistant, so that he is able not only to control the movements of the head, but likewise the circulation in the facial and coronary arteries, and to bend the head for-

ward, that blood may escape from the mouth. He can also administer the anæsthetic with a small sponge held between the index-fingers. The success of the operation will depend in a very large degree upon the entire absence of tension when the parts are placed in position. To prevent tension, it is often necessary to separate the lip and cheeks to a considerable extent from their bony connections. In some instances, owing to the difficulties of the case, the loss of blood will be considerable, unless every precaution to prevent it be taken. The coronary vessels usually supply the bleeding points, but they can be easily controlled by grasping the lip at both sides of the incision, between the thumbs and fingers.

By this procedure, the same force that puts the part upon the stretch also checks the flow of blood. The fingers of the assistant often hinder the operator, especially if the cleft be a large one, but their action can readily be supplemented by passing through the lip, at each side of the proposed cut, a strong silk ligature, which, when looped, makes it possible to keep the parts on the stretch without inconvenience. The ligature can be so placed that when the parts are put upon the stretch the coronary vessels will be compressed. Either Milne's artery compression forceps or Langenbeck's serrefines (Figs. 55 and 58) will control the hemorrhage admirably if one of them be fixed at the angle of the mouth on each side. If the blades of the ordinary dressing forceps be surrounded by adhesive plaster and closed upon the lip by rubber bands passed around the handles, a useful substitute will be had for the instruments just mentioned. The additional instruments needed are a strong pair of scissors, two scalpels—

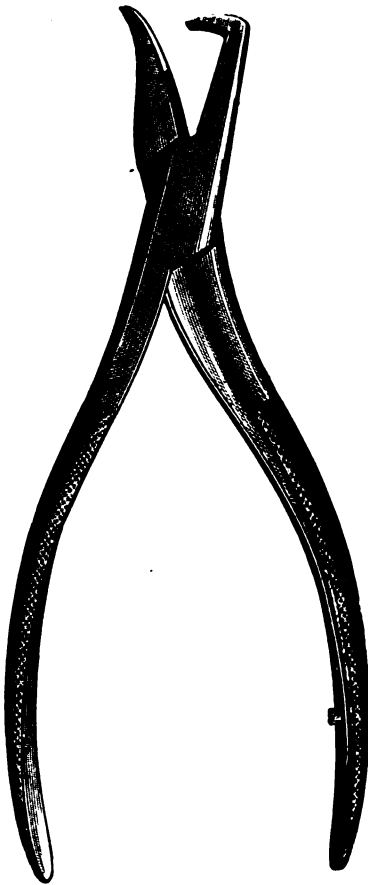


FIG. 487.—Butcher's bone pliers.

one sharp pointed—and Butcher's bone pliers (Fig. 487), if the case be complicated with a projecting intermaxillary bone. The projecting

portion may be pressed into position often by direct manual force. A liberal supply of hare-lip pins, Buck's needle-carrier (Fig. 48), silver sutures, and needles and needle-holder are required. The variety of suture to be employed and the degree of tension allowable have been already considered under the heading devoted to that purpose. The borders may be pared with a sharp-pointed scalpel, strong scissors, or the triangular cataract-knife; the latter is a very useful instrument for this purpose. It is not permissible to sacrifice the parings taken from the free borders of the cleft, except in cases with but little deformity; they should remain attached and be utilized in filling in the gap, this being the only satisfactory manner of avoiding the occurrence of the objectionable notch often seen after operations for hare-lip. The points of the pins should perforate the flaps at least a third or fourth of an inch from the borders of the wound, and even farther, if there be any degree of tension. One or two pins will be sufficient in the majority of cases. Neither pins nor sutures are passed through the flaps, but are passed near to their under surface. The sutures may be inserted nearer to the edge of the wound than the pins, and in sufficient number to properly connect its lips. The latter are removed within two or three days; the former may remain longer. If ulceration begin around the pins, they should be removed after others have been inserted at new points to receive the strain.

Simple Hare-lip.—This variety of deformity can be treated by paring and uniting directly the borders of the cleft, or by uniting them after incisions extending more deeply, which likewise sacrifice the borders of the cleft (Fig. 488), and also by the single and double flap method.

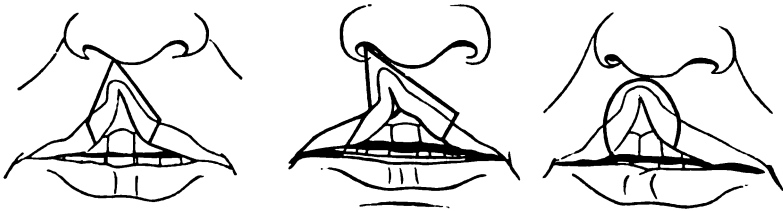


FIG. 488.—Incisions for direct union.

The simplest method consists in refreshing the borders of the cleft, loosening the labial connections to the bones, and bringing the edges directly into contact. Care should be taken to secure an accurate coaptation of their vermilion borders. Unless the operation is carefully performed, this method is often followed by a notch at the border of the lip where the flaps are joined.

Single Flap (Fig. 489).—Draw down both borders of the cleft and freely sever their connections with the bone; pare the border of the

longer portion, *c*, and make the flap on the shorter, *b*; approximate and unite them, as before described.

Double Flaps.—Pass a silk ligature through each angle of the fissure (Fig. 490, *c*); divide the sublial connections, make one side


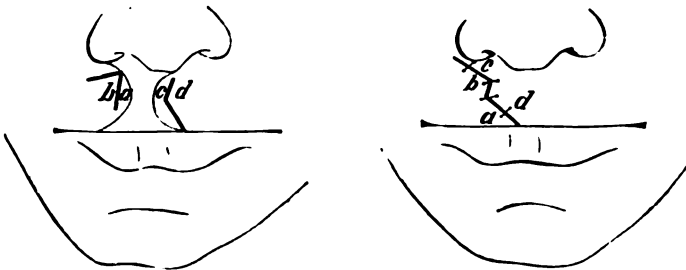


FIG. 489.—Single-flap method.

FIGS. 490, 491.—Double-flap method.

tense, transfix it near the border of the lip, and cut upward to the apex of the cleft; repeat the operation on the opposite side of the fissure; draw both flaps downward, bringing their cut surfaces in contact with each other (Fig. 490, *d*); close the cleft with a pin or suture passed near to the vermilion border, and insert another above if necessary; unite the everted flaps by a fine silken thread or horsehair, *e*; cut off their extremities obliquely, leaving enough tissue to form a permanent projection at the margin of the lip, in order to obviate the formation of a notch. If the cleft be shallow (Fig. 491, *a*), the flaps should remain connected above and be turned downward and united, as before (Nélaton) (Fig. 491, *b*).

Double Flaps, Giraldes' Method.—This method is principally employed only when the deformity extends into the nasal cavity, and the flaps are constructed so as to provide a floor to its entrance (Fig. 492).



FIGS. 492, 493.—Giraldes' method.

When the flap *c* is carried upward to repair the floor of the nostril, the angle of the cut *b a* is then brought in contact with the angle of the border *d*, and their cut surfaces are made of a similar length. The border *b* then comes in contact with *d*, and the point of the flap *a* rests upon the undermost cut, in which position they are united (Fig.

493). This operation is an admirable one, and should be employed on all occasions where an extensive deformity exists.

Double Hare-lip, simple.—Pare the central portion (Fig. 494, *c*) on both sides; make lateral flaps with their attachments below (Fig. 494, *a b*); liberate the labial attachments, and approximate the raw surfaces by the aid of pins and sutures.



FIG. 494.—Double hare-lip.

Complicated Hare-lip.—Hare-lip is often complicated by a fissure through the alveolar process, which sometimes extends to the hard palate, and even beyond, to the soft parts. For a time before the operation, it is well for the parents or nurse to make gradual pressure upon the more prominent bony portion, combined with outward traction on the depressed side, endeavoring thereby to cause the alveolar arch to assume as nearly as possible a normal outline. A reasonable degree of patience in making these painless manipulations will in time effect a more satisfactory result than the application of sudden force by means of forceps. The practice of forcing the alveolar extremities into position, paring and wiring them, is a pernicious one, since to do it still further shortens the outline of the arch of mastication of the superior maxilla, and does not result in a bony union of the extremities. The gentle but constant traction exerted by the united lip will in time as certainly reduce the bones as the more vigorous measures.

It is better to allow the deformity of the hard parts to remain unmolested until the teeth appear, when the outline of the biting surface of the upper jaw may be compared with that of the lower jaw, and made to meet it by rectifying the upper, and introducing, if necessary, additional teeth upon a plate to fill the gap in the biting surface. Giraldes' method offers the best opportunity of closing the fissures in the lip in these cases.

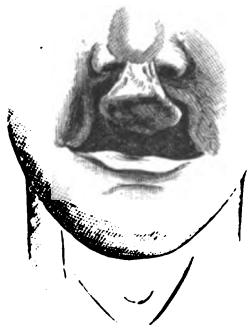

FIG. 495.—Complicated hare-lip.

The fissure may be double, and involve both the hard and soft parts, back to and through the soft palate. The intermaxillary bone in this connection may project freely, and even be adherent to the soft parts covering the end of the nose (Fig. 495). If such be the case, after the division of the vomer, or the removal of a triangular piece from the septum, the projecting portion is forcibly pressed into position, its borders refreshed, and the soft parts united, as in the simpler forms; except, perhaps,

it may not be prudent to unite both sides simultaneously, for fear of causing too great traction.

When the protruding portion is connected to the nose, it should be

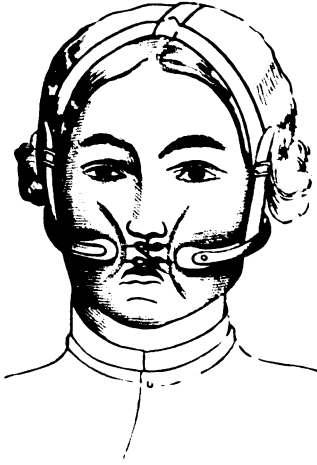

FIG. 496.—Hainsley's compressor.

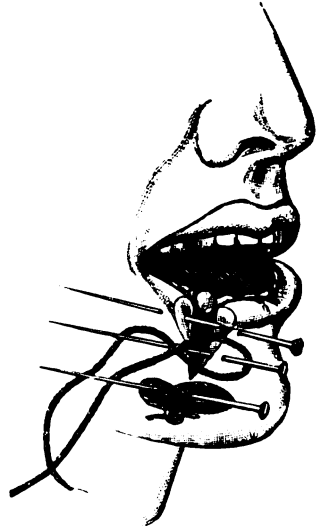


FIG. 497.—Operation by V-shaped incision.

separated from this with care, or the columna will be impaired. The parings are utilized in correcting the upper lip, when practicable.

The cheek-compressor, designed by Hainsley, may be employed to hold the parts in position when the conditions require it (Fig. 496).

Cheiloplasty is an operation directed to the restoration of deformities of the lips dependent on disease or congenital defects.

Deformity of Lower Lip, V-Incision.

—This incision is employed for the removal of epitheliomata, or other morbid growths, that do not require the removal of

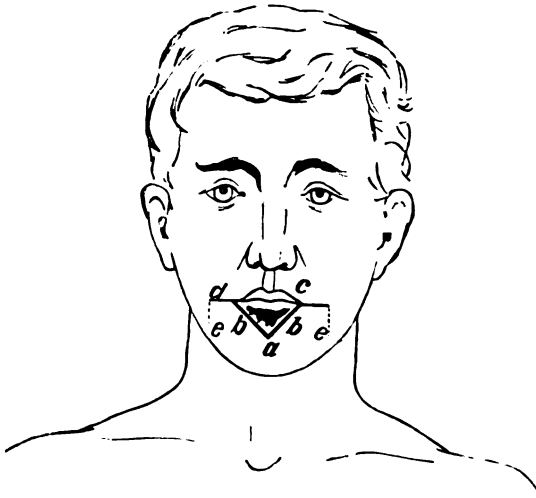


FIG. 498.—Celsus' method.

mata, or other morbid growths, that do not require the removal of

more than one third of the lip. The whole thickness of the lip is divided ; the length of the arms of the V being increased proportionately to the width of its base. The usual liberating incisions may be required, and the cut surfaces are united by the same means, and cared for in the same manner, as in operations for hare-lip (Fig. 497).

Method of Celsus. — When the morbid growth involves the whole or half of the lip, the broad-based V incision is supplemented by trans-

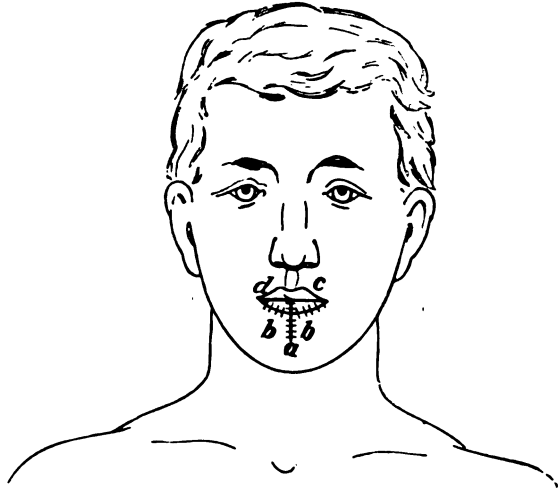


FIG. 499.—Celsus' method.

verse ones extending outward, from each angle of the mouth, a sufficient distance to admit the easy joining of the V borders after the

tissues have been freely liberated from their bony attachments (Figs. 498 and 499). If difficulty be experienced in sliding the flaps, it may be overcome by making short vertical incisions through the cheek at the outer extremities of the horizontal ones (Fig. 498, e, e). The most ingenious feature of this method consists in dividing the buccal mucous

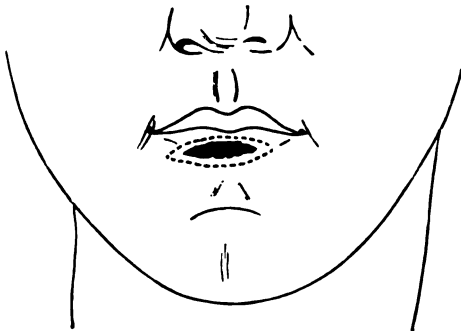

FIG. 500.—Horizontal incision.

membrane at least a fourth of an inch above the incision made through the cheek and parallel with it, so that when the outward cuts are completed, and the parts joined in the median line to form the lip, its raw upper borders can be covered by turning the processes of mucous membrane over them, thereby forming an excellent vermilion border. The angles of the mouth are also to be formed by stitching the membrane and buccal cuts to each other.

Horizontal Incision (Fig. 500).—When the morbid process does

not involve the free border of the lip, it can be removed by an oval incision, and the gap closed in the usual manner. If the space be too large to admit of closure, it can be left to heal by granulation, or be remedied by the sliding process, either with or without parallel or transverse incisions.

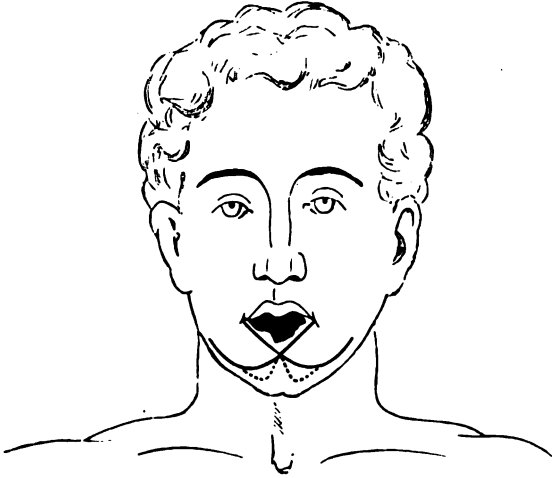


FIG. 501.—Syme's method.

Syme's Method (Fig. 501).—In this method the operation is performed by continuing the sides of the V downward and outward in a curvilinear direc-

tion for about two inches, dissecting up the flaps in the usual manner, raising them up to form the lip, uniting them in the median line, and allowing the remaining portion to heal by granulation. The mucous membrane should then be stitched to the integument, to provide a suitable border. Buchanan's method differed from Syme's in making the extremities of the flaps straight, as shown by dotted lines (Fig. 501). In other respects, no radical difference exists between these methods.

Buck's Method.—He first removed the morbid growth by the V-shaped incision, and united the parts in the usual manner. After union had taken place, the short lower lip was overhung by the upper, giving to the patient a sucker-mouthed appearance (Fig. 502). The steps taken to relieve this deformity can best be described in Dr. Buck's own language: "In order to insure precision in making the requisite incisions, their course should first be designated by pins, temporarily inserted erect in the skin at certain points, as shown

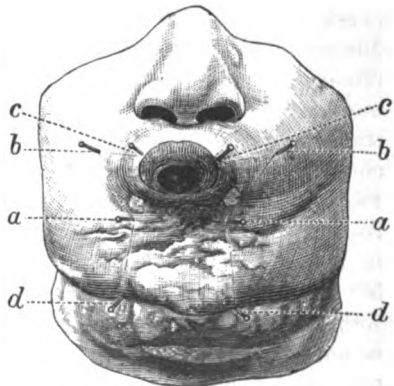


FIG. 502.—Operation for contracted lower lip.

by Fig. 503. Letters *aa* represent two pins inserted at one finger's breadth below the under-lip border, one on either side of the chin, a little to the outside of the angle of the mouth, and both equidistant from the median line; *bb* are also two pins inserted, one on either side, into the upper lip at the margin of the vermillion border, both equidistant from the median line, and at such a distance apart as to include between them sufficient length of lip border with which to form a new upper lip. The steps of the operation are then the following: with the forefinger of the left hand placed on the inside of the mouth, the cheek is held moderately on the stretch, while with a sharp-pointed knife it is transfixed at the point *a*, as marked by the lower pin in the side of the chin. An incision is then carried through the entire thickness of the cheek upward and a little outward a distance of one inch and a half to a point *c*, near the middle of the cheek. The upper lip should next be transfixed at the point *b*, marked by a pin on the vermillion border, and the incision carried through the lip and cheek outward and a little upward to join the first incision at its terminus *c* in the middle of the cheek. A triangular patch, *b, c, a*, will thus be formed, which will include the entire thickness of the cheek, with its apex free and disconnected, while its base remains attached toward the mouth. The next step is to transfer the patch from the cheek to the side of the chin.



FIG. 503.—Buck's incision.

For this purpose an incision should be made on the side of the chin from the starting-point of the first incision *a*, vertically downward to the edge of the jaw and to the depth of the periosteum (Fig. 503). The edges of this incision retracting wide apart, afford a V-shaped space for the lodgment of the triangular patch, which is now to be brought around edgewise and adjusted by sutures in the new location. By this transfer the portion of the upper-lip border that formed a part of the base of the patch, is brought into a transverse line, continuous with the upper lip, and forms an extension of it. The space upon the cheek from which the triangular patch was taken is closed by bringing its edges together and securing them by sutures. By this adjustment a new and naturally shaped angle

formed for the mouth at the point *b*, where the lip was transfixed in commencing the second incision of the cheek. The incisions must be made with the utmost precision, and special care taken that the mu-

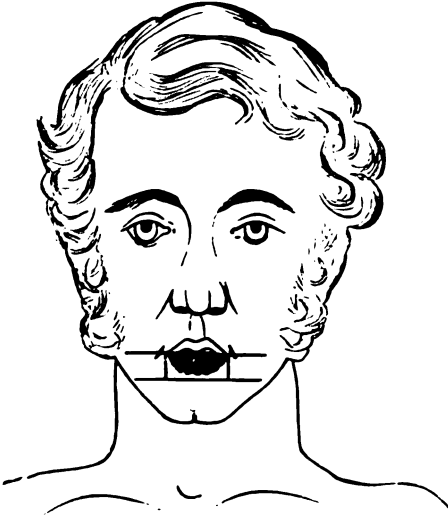


FIG. 504.—Malgaigne's method.

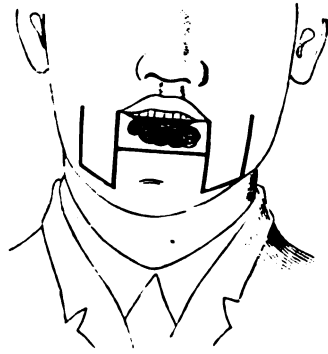


FIG. 505.—Sédillot's method.

cous membrane is divided exactly to the same extent as the skin. The same procedure may be applied to the other side of the mouth and executed at the same operation."

Malgaigne's Method (Fig. 504).—The growth is removed by means of one horizontal and two vertical incisions. The vertical incisions begin at the angles of the mouth, the horizontal one is located between them and below the disease. Two additional horizontal incisions are subsequently made on each side, to permit the closure of the gap by the sliding method. The flaps are freely separated, brought forward, united in the median line, and the mucous membrane of their upper borders stitched to the integument. The mucous membrane can in this instance be taken with the cheek-flap to form the vermillion border, as in Celsus' method.




FIG. 506.—Buck's method.

Sédillot's Method (Fig. 505).—The diseased portion is removed as in the preceding method, after which the vertical incisions are extended

to the lower border of the jaw, then backward far enough to make flaps of sufficient width to fill the gap; thence directly upward to a point opposite the angle of the mouth. These flaps are dissected up, and united in the median line by the usual means.

Deformities of the Upper Lip.—If the deformity here be slight, it can be remedied by the simple means employed upon the lower lip.

Intero-lateral Flap (Buck).

—This operation was done to restore one half of the upper lip and the adjacent portion of the cheek (Fig. 506). Divide the under lip where it joins the cheek by a vertical incision, *a, b*, at right angles to its border, and one inch in length. Make a second incision, *b, c*, one inch and a

half in length, beginning at the lower end of the first, *a, b*, and running forward parallel with the border of the lip. An oblique incision, *c, d*, about half an inch in length, is then made upward and forward from the end of the horizontal one, leaving the flap with a good attachment at this point. Pare the edges of the deformity and the end of the half-lip above; separate the half-lip from its bony attachments by free section of the underlying tissues directed upward toward the orbit; the under-lip flap is then tipped endwise, and its upper extremity connected by sutures with the end of the upper half-lip. The remaining space between the flap and the cheek is closed by sutures. Fig. 512 shows the result of this operation.

Entire Loss of the Upper Lip.—This deformity may be repaired by semicircular or vertical flaps.

Semicircular-Flap Method (Buck).—Commence an incision at the median line, on a level with the floor of the nasal cavity on each side; carry it outward and downward in a semicircular manner below the lower lip, to a point corresponding to its middle third, *a, b* and *a, c* (Fig. 507). These incisions are to be carried through the entire thickness of the cheeks and lips at a uniform distance of an inch and a quarter from the border of the opening. Dissect up the remaining portions of the cheeks freely from their attachments beneath, that they may be easily brought forward. The upper extremities of the semicircular flaps are

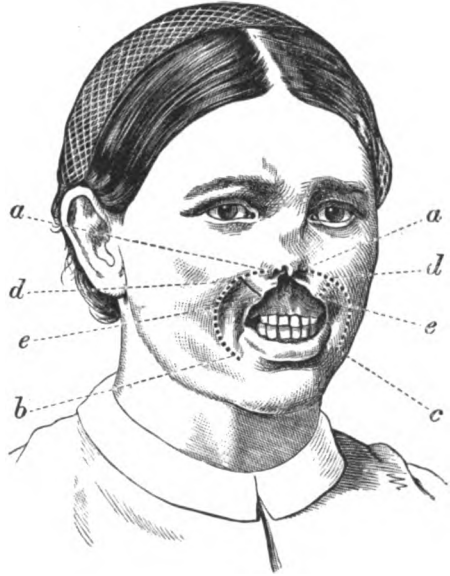

FIG. 507.—Semicircular-flap method.

longer porti
and unite th
Double
fissure (Fig

incision in the mouth at the points A where the lip was transfixed in
commencing the second incision of the cheek. The incisions must be
made with the greatest precision, and special care taken that the mu-



Fig.

tense, t
apex o
fissure
contac
satur
if ne
hair,
form
viat
the
uni

pl
fls




FIG. 504.—Malgaigne's method.

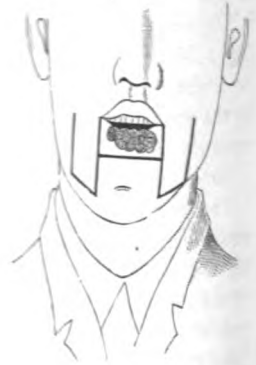

FIG. 505.—Sédillot's method.

ous membrane is divided exactly to the same extent as the skin.
The same procedure may be applied to the other side of the mouth
and executed at the same operation."

Malgaigne's Method (Fig. 504).—The growth is removed by means
of one horizontal and two vertical incisions. The vertical incisions
begin at the angles of the mouth, the horizontal one is located between
them and below the disease. Two additional horizontal incisions are



FIG. 506.—Buck's method.

subsequently made on each side, to
permit the closure of the gap by
the sliding method. The flaps are
freely separated, brought forward,
united in the median line, and the
mucous membrane of their upper
borders stitched to the integument.
The mucous membrane can in this
instance be taken with the cheek-
flap to form the lip, as in Celsus

Th
in
th

to the lower border of the jaw, then backward far enough to make flaps of sufficient width to fill the gap; thence directly upward to a point opposite the angle of the mouth. These flaps are dissected up, and united in the median line by the usual means.

Deformities of the Upper Lip.—If the deformity here be slight, it can be remedied by the simple means employed upon the lower lip.

Intero-lateral Flap (Buck).
—This operation was done to restore one half of the upper lip and the adjacent portion of the cheek (Fig. 506). Divide the under lip where it joins the cheek by a vertical incision, *a, b*, at right angles to its border, and one inch in length. Make a second incision, *b, c*, one inch and a

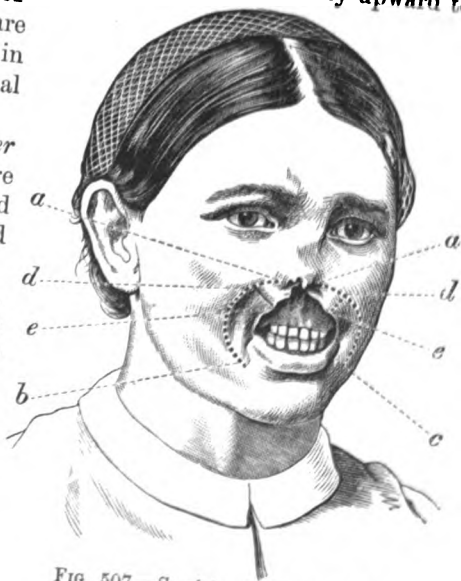


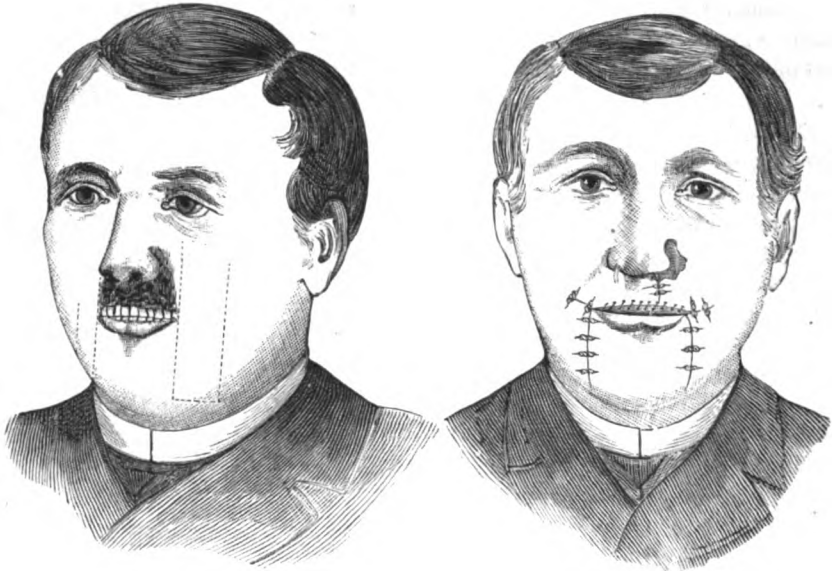
FIG. 507.—Semicircular-flap method.

half in length, beginning at the lower end of the first, *a, b*, and running forward parallel with the border of the lip. An oblique incision, *c, d*, about half an inch in length, is then made upward and forward from the end of the horizontal one, leaving the flap with a good attachment at this point. Pare the edges of the deformity and the end of the half-lip above; separate the half-lip from its bony attachments by free section of the underlying tissues directed upward toward the orbit; the under-lip flap is then tipped endwise, and its upper extremity connected by sutures with the end of the upper half-lip. The remaining space between the flap and the cheek is closed by sutures. Fig. 512 shows the result of this operation.

Entire Loss of the Upper Lip.—This deformity may be repaired by semicircular or vertical flaps.

Semicircular-Flap Method (Buck).—Commence an incision at the median line, on a level with the floor of the nasal cavity on each side; ward and downward in a semicircular manner below the point corresponding to its middle third, *a, b* and *a, c* (Fig. incised through the entire thickness of and a quarter from ing portions of the flaps are

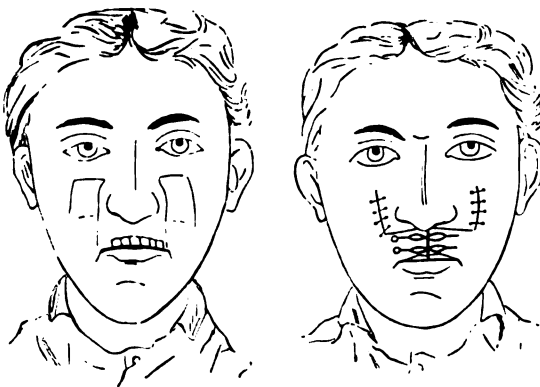trimmed off at a proper angle, *e, d*, after which they are united in the median line by the usual means. The interval between the cheeks and the newly constructed mouth is closed by sutures.



FIGS. 508, 509.—Sédillot's vertical-flap method.

Vertical-Flap Method (Sédillot).—The bases of the flaps in this method may be made either upward or downward, the former being the better plan.

They should comprise the entire thickness of the cheeks; their length and width corresponding to the dimensions of the proposed new lip, plus the one-fourth allowance for its shrinkage. They are carried into position, and united in the median line.



FIGS. 510, 511.—Dieffenbach's method.

The gaps in the cheek may be closed by sutures, or allowed to heal by granulation.

Dieffenbach's Method.—Freshen the lower border of the remaining

portion of the original lip, then raise two S-shaped flaps, one at each side of the nose, turn them across the space in front of the alveolus, unite them to each other, and also to the freshened border beneath the nose (Figs. 510 and 511).

Stomatoplasty.—This operation is employed to increase the size and regulate an abnormally shaped mouth, when resulting either from disease or from previous operations.

The deformity can be corrected by an operation already described (Fig. 502), when the lower lip is the contracted portion. The angles of the new mouth may be formed by means of transverse incisions, made at the proper situation. Whenever this is done the mucous membrane must be stitched over the raw surfaces, to prevent them from becoming united to each other.

The operation described by Buck for restoring the angles of the mouth is simple and effective (Fig. 512). An incision is made with great exactness along the line of the vermilion border, circumscribing the circular half of the mouth, and extending to an equal distance in the upper and lower lips, *a* to *b*.

This incision should only divide the skin, and not involve the mucous membrane. A sharp-pointed double-edged knife is inserted



FIG. 512.—Stomatoplasty.

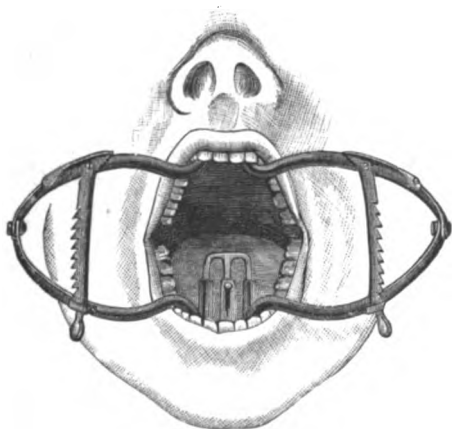


FIG. 513.—Whitehead's mouth-gag.

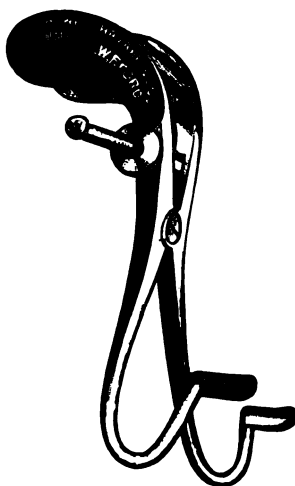


FIG. 514.—Mason's mouth-gag.

at the middle of this curved incision, and directed toward the cheeks, flatwise, between the skin and mucous membrane, so as to separate

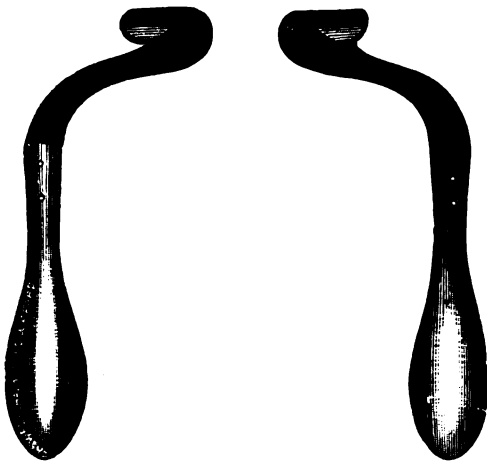
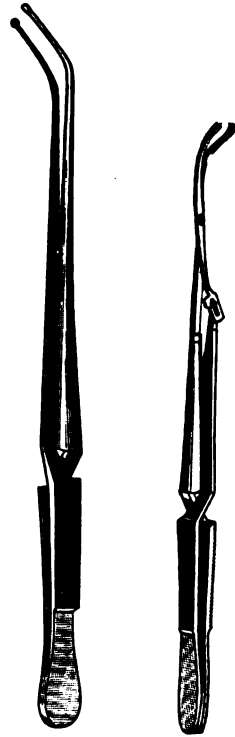


FIG. 515.—Cheek-retractors.



FIGS. 516, 517.—Whitehead's forceps.

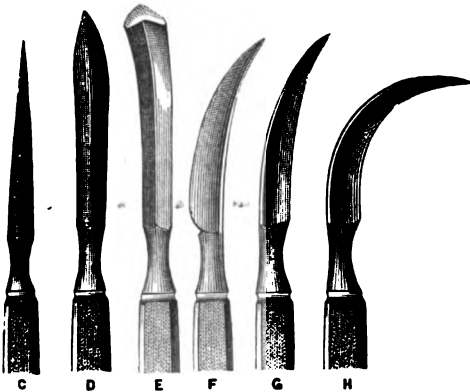


FIG. 518.—Langenbeck's knives.

them from each other as far as the new angle of the mouth requires to be extended.

The skin alone is next divided outward toward the cheeks, on a line with the commissure of the mouth, *d* to *c*. The underlying mucous membrane is then di-



FIG. 519.—Tenaculum.

vided in the same line, but not so far outward. The angles at the outer ends of the two incisions are accurately united by a single-thread suture. The freshly cut edges of skin and mucous membrane, above and below, that are to form the new lip-borders, are to be shaped by

paring first the skin, and then the mucous membrane, in such a manner that the latter shall overlap the former after they have been secured together by fine-thread sutures at short intervals.

Operations upon the Palate.—The operations employed to relieve the deformities of the hard and soft palate are denominated *staphyloplasty*, *staphylorrhaphy*, and *uranoplasty*. The instruments required are the gag, for the purpose of holding the mouth well opened (Figs. 513 and 514); cheek-retractors (Fig. 515); seizing forceps (Figs. 516 and 517); variously shaped knives for refreshing the borders of the deformity (Fig. 518); tenaculum employed in holding the flaps, etc. (Fig. 519); curved scissors (Fig. 520); periosteotomes (Figs. 521 and 522); spiral needle




FIG. 520.—Curved scissors.



FIG. 521.—Sayre's periosteotome.



FIG. 522.—Goodwillie's periosteotome.



FIG. 523.—Whithead's spiral needle.



FIG. 524.—Sims' suture-adjuster.



FIG. 525.—Sims' wire-twisting forceps.

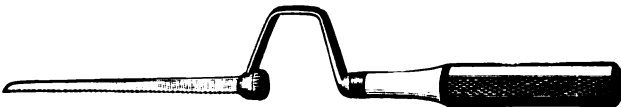

FIG. 526.—Goodwillie's oral saw.

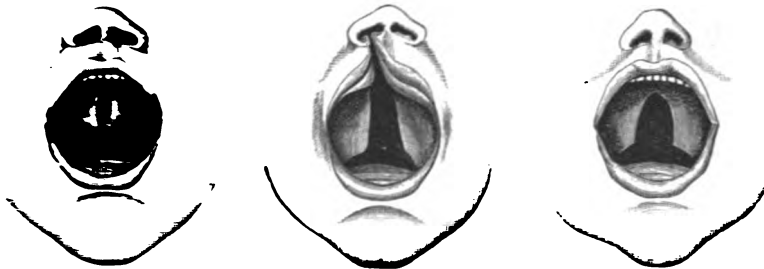for sutures (Fig. 523); suture-adjuster (Fig. 524); forceps for twisting wire sutures (Fig. 525); oral saw (Fig. 526); hoe for dividing the mucoparietal membrane (Fig. 527); sponges, sponge-holders, etc.



FIG. 527.—Whithead's hoe.

Staphylorrhaphy consists in closing an abnormal opening in the soft palate by bringing its freshened borders in contact with each other. The

openings vary from a simple cleft of the uvula to a complete fissure of all the soft parts (Figs. 528, 529, and 530). Some time prior to



FIGS. 528-530.—Degrees of the deformity.

the operation, the patient should be instructed by manipulation to control properly the fauces, so that the surgeon may handle the parts without causing involuntary movements of them. If the fissure be a small one, it can be closed by the aid of a solution of cocaine without further preparation.

If the cleft extend through the whole of the soft palate, even encroaching somewhat upon the hard portion, it will be necessary, especially if the gap be a wide one, and the muscles controlling it be active, to destroy their influence before attempting to unite the cleft. The tensor- and levator-palati muscles, together with palato-glossi and palato-pharyngei, are the ones that exercise contraction on the part, and if they be properly severed, the velum will remain motionless and flaccid. The accompanying illustration shows their relations to the surrounding parts (Fig. 532).

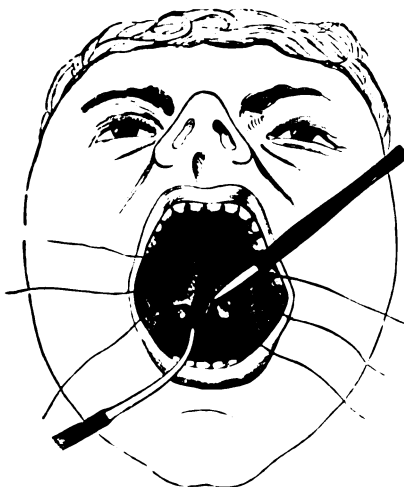


FIG. 531.—Freshening the borders.

The palato-pharyngei mus-

cles should be cut, with a pair of blunt-pointed scissors, by dividing the posterior pillars of the fauces, of which they form the principal part. The palato-glossi muscles, comprising the anterior pillars, may be cut in the same manner. The remaining muscles are divided after first passing a silken thread through the velum at a point corresponding to the origin of the uvula, on each side of the cleft; the extremities of the thread are looped and a tenaculum is used to make the velum tense, while the following muscles are divided:

Tensor Palati.—Recognize the hamular process around which the tendon tensor palati runs, a little behind and internal to the posterior molar tooth. Make tense that segment of the velum by the suture just introduced, and enter the point of a narrow-bladed knife a little

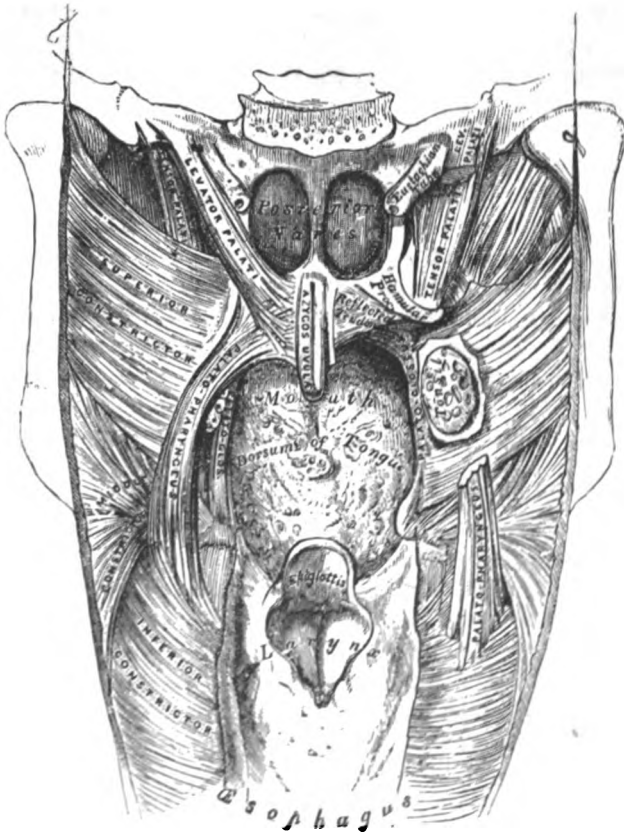


FIG. 532.—Muscles of the soft palate.

below and at the inner side of the process, with the edge upward; carry it upward, backward, and inward, until the point is seen through

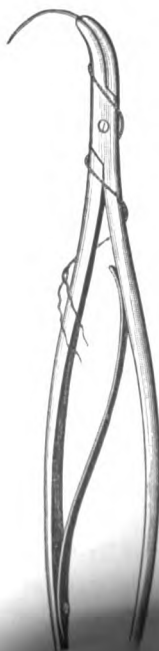the gap ; this divides almost the entire width of the velum, with the main, if not the entire portion of the tendon of the tensor palati.

Levator Palati.—Many of the lowermost fibers of this muscle will be cut by the preceding incision. If a greater section be required, depress the handle of the knife and carry it outward, so as to make an oblique incision on the posterior surface of the velum as it is withdrawn. It is well to allow two or three days to elapse before attempting the union of the cleft, so as to permit hemorrhage and inflammatory action to subside, and to determine more clearly whether further section will be required. This muscle, if it be made tense by drawing the velum toward the incisor teeth by means of the silken thread, may be cut with blunt scissors under direct observation, especially if the cleft be a deep one.

Operation of Staphylorrhaphy.—There are *three steps* to the operation of staphylorrhaphy : 1. Freshening the edges of the cleft. 2. Passing the sutures. 3. Coaptating the divided borders, and tying the sutures. First apply a solution of cocaine to the palate, and then place the patient in a chair which will permit the head to be thrown well back so as to expose the parts to a strong light. The lower point of

the cleft is then seized with the forceps, made tense, and the border freshened from below upward (Fig. 531), or the reverse if desired. Treat the opposite side in a similar manner.

The patient is allowed to rest after the completion of the first step, until the hemorrhage ceases and self-control is regained. The sutures should be one yard in length, and doubled before passing, and thoroughly antiseptic. Either silk, horse-hair, silk-worm gut, or metallic sutures can be employed. Three or four are usually sufficient. The first should be introduced in the middle, the second at the lower extremity of the gap, while the remaining ones close the space between. They can be passed from before backward, or from behind forward on the other side. For this purpose the needle-holder and the ordinary sharp needle (Fig. 533), or in the following manner, Whitehead's spiral needle (Fig. 534) may be used. On one side of the cleft with a pair of forceps, pass the needle through it at the lower extremity, and draw it backward ; draw one end of the thread through the borders of the cleft, and pass the needle through with another suture, and so on, until the gap is closed in the same manner as before, leaving the patient at rest.



inserted, through the loop, which is then drawn out, carrying the single thread through the opposite side.

The remaining sutures are passed in a similar manner. Each one is then tied somewhat loosely, to allow for the swelling, with a reef-knot, or, what is better, the slip-knot held in place by a second knot over it. Perforated shot may be passed over the sutures, and held in position by compressing them, or by the ordinary knot. If silver wire be used, it must be very fine and flexible, and applied with an adjuster. The sutures are left sufficiently long in either case to admit of their easy removal, which is done at the end of a week. The diet should be plain, and all conversation interdicted. The sponging during the operation must not be done with any form of antiseptic fluid that possesses a poisonous nature, since the patient may swallow a certain portion of it, with an unfavorable if not an unfortunate result.



FIG. 534.—Looped suture.

Results.—The prospect of union of the parts is very favorable, scarcely more than five per cent of the operations being failures. The time necessary to acquire a distinct voice is variable, and often this is not attainable.

Uranoplasty.—This operation is performed to close a fissure in the hard palate. It should not be attempted on a patient under two years of age, and not then unless the patient is in all respects in perfect health. It can be completed at one sitting, or may require several, depending on the obstacles to be overcome.

If the deformity in the hard palate be complicated with a complete cleft of the soft palate, each one should be treated separately. If, however, the cleft of the soft palate be partial, it can then be operated on at the same sitting. The soft portion should be united first, in the manner before described, to prevent it from being obscured by the blood associated with the operation on the hard palate.

This operation consists of four stages: 1. The paring of the edges of the fissure. 2. The making of a longitudinal curvilinear incision along the alveolar process close to the teeth (Fig. 535). 3. The raising of the muco-periosteal flaps from the roof of the mouth. 4. Their union along the median line. The patient is anesthetized, placed in a chair facing a good light, the gag introduced, and the first step is performed easily with an ordinary knife and forceps. The flaps are made by beginning the incision at the posterior border of the last molar tooth, or, more practically, in front of the hamular process, and carrying it down through the periosteum and forward along the inner margin of the alveolar process to the line of junction between the lateral and middle incisors. If the curvilinear incision be made

at the base of the alveolar process, or be carried forward to the central incisors, the posterior and anterior palatine vessels will be divided.

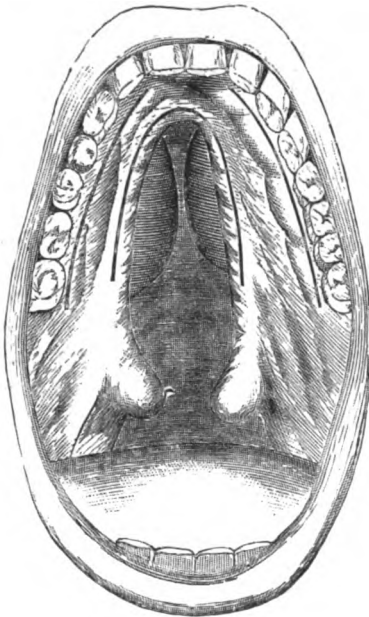


FIG. 585.—Uranoplasty.

These flaps are now to be carefully detached by a periosteotome from without inward and from before backward until the edges of the fissure are reached; they are then carried toward the median line, and, if no degree of traction be noticed, united throughout to each other by silver sutures. The displaced periosteum fills in the gap and often develops sufficient bone to produce an admirable degree of firmness. The sutures are allowed to remain in position ten days or two weeks, the patient is fed on liquid food, any cough is relieved by anodynes, and the parts are kept clean.

Langenbeck closed the fissure by two flaps, which were formed by an antero-posterior division of the hard palate on either side of it; freshened their contiguous borders and pushed them against each other at

the median line, where the mucous membrane was united by sutures, the anterior and posterior extremities of the osseous flaps being still connected with the soft parts.

Ferguson divided the hard palate with a chisel. *Mears* uses Adams' saw after drilling an opening for its entrance, and claims less injury is done to the bone than by any other means. The hemorrhage is quite severe during the removal of the periosteal flaps, but it is readily controlled by pressure and cold. When the osseous flaps are made, the bleeding is usually still greater. If the fissure be not in the center, the flap is generally taken from the side of the hard palate which has the greatest width.

Lannelongue closed the opening by taking a properly shaped flap of the mucous membrane from the septum, its base being lowermost, and stitching its upper border to the opposite side of the chasm.

Mechanical means are employed to fill the opening in the hard and soft parts, and to provide even an artificial uvula. This apparatus is made of vulcanized rubber, and is held in position by being attached to a plate fitted to the roof of the mouth. An expert dental surgeon ought to be consulted, since he is, as yet, the only one fully competent to treat the cases by this method. The ability to speak and to

otherwise control the action of the throat and pharynx with this contrivance is very satisfactory ; in the majority of instances equaling, if not exceeding, the best results from an operation.

Staphyloplasty consists in filling in the gap of the soft palate, and as much as possible of the hard, by a flap taken from the posterior wall of the pharynx. The degree of success attending this operation is sufficient to warrant its adoption when the conditions demanding it are present.

Operation.—Anæsthetize the patient, perform a preliminary tracheotomy, and introduce the tampon-canula into the trachea. The flap from the posterior wall of the pharynx is made with the base downward, and the apex is carried as far upward as possible to permit its introduction into the cleft without the least tension. The width and shape of the flap must be determined by the size and outline of the deformity, plus its normal shrinkage. It should consist of the mucous lining of the pharynx, along with the subjacent muscles. The fibromucous coverings of the hard palate are dissected up until its tissues and those of the velum are freely movable. The borders of the cleft are freshened, and the flap brought in place and united by several sutures. The tampon-canula can be removed as soon as hemorrhage has ceased, or, at the farthest, on the day following the operation. The parts should be cleansed frequently and carefully with a mild antiseptic fluid, to wash away the abundant secretions. The sutures should be removed on the sixth or seventh day following the operation.

Elongated Uvula.—An elongated uvula is easily shortened by causing the patient to withdraw the tongue by aid of a dry towel ; seizing the end of the uvula with forceps and removing the required amount with scissors. The little pain that may be caused by the operation can be relieved by the application to the part of a solution of cocaine.

CHAPTER XIII.

OPERATIONS ON THE MOUTH, PHARYNX, AND ŒSOPHAGUS.

Salivary Fistula.—With this morbid condition the saliva is discharged on the external surface of the cheek instead of into the mouth. The object of an operation is to establish an internal communication so that the external opening can heal.

The cure may first be attempted by passing the ends of several long silken threads through the external opening directly into the

mouth, or through the internal opening of the duct, and bringing them out at the angle of the mouth and tying their extremities (Fig. 536). The internal communication is easily established in eight or ten days ;

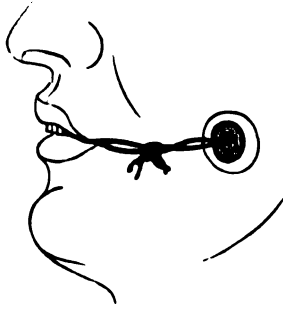


FIG. 536.—Seton in position.

then the seton can be removed and the borders of the external opening freshened and closed. The patient should be advised to chew upon the opposite side during the healing of the external opening, to limit as much as possible the flow of saliva on the diseased side. Another method consists in passing a good-sized thread of silk into the mouth, through the fistula, from without inward, and leaving it there ; removing the needle and attaching it to the end of the thread remaining outside, and carrying it through the tissues into the mouth in the same direction as the former, but

not exactly in the same track. The needle is then removed, and the extremities of the thread are firmly tied within the mouth. A fine rubber ligature can be substituted for the silk. The loop cuts its way through the tissues grasped, forming an internal opening, which permits the healing of the external one.

The method recommended by Dr. Horner, which is employed in obstinate cases, consists in the introduction of a wooden spatula into the mouth, opposite the site of the fistula, upon which, by means of a saddler's or other suitable punch, the diseased tissues, duct and all, are removed (Fig. 537). The external opening is closed, a cold, dry dressing is applied, and quiet ordered. The end of the duct can be dissected up and passed through a small incision made through the mucous membrane into the mouth, after which



FIG. 537.—Horner's method.

the external opening is closed (Van Buren). A small probe should be introduced into the duct from without to prevent it from being cut during the dissection ; when turned inward, the borders of the

open extremity can be confined to the edge of the incision by a stitch of catgut or horse-hair.

Excision of the Tonsils.—This operation can be done with an ordinary tenaculum and bistoury, or with curved scissors. The various forms of tonsillotomes, while they simplify the operation by giving the operator a perfect control over the cutting edge, are not necessary to its execution.

To remove the Tonsil with the Knife or Scissors.—If the patient be young or unable to retain self-control, give an anæsthetic or apply a strong solution of cocaine. Cause a bright light to shine into the open mouth, depress the tongue, seize the tonsil with the tenaculum or forceps, draw it inward from between the pillars of the fauces, and with scissors curved on the flat or the probe-pointed bistoury, or an ordinary bistoury with the point guarded by adhesive plaster, sever the gland from below upward. It is not necessary at first to remove the entire tonsil, since a curative influence is often established by its incomplete removal. Among the forms of tonsillotomes in common use are Tiemann's (Fig. 538), Hamilton's (Fig. 539), Mackenzie's (Fig. 540),

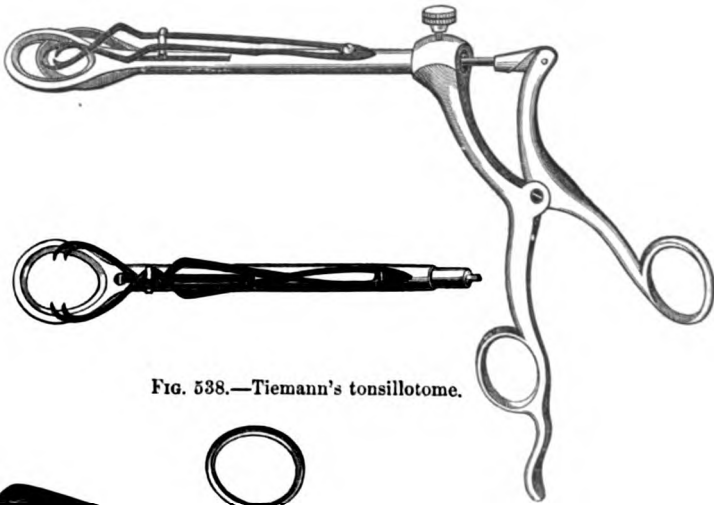


FIG. 538.—Tiemann's tonsillotome.

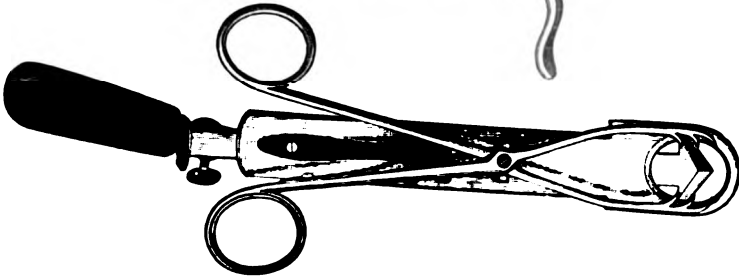


FIG. 539.—Hamilton's tonsillotome.

and others, the majority of which combine the ability to seize, hold up, and sever the growth. The patient is placed as before stated, and

with the index-finger the ring of the instrument is adjusted around the tonsil properly, and the tonsil elevated with a tenaculum, and

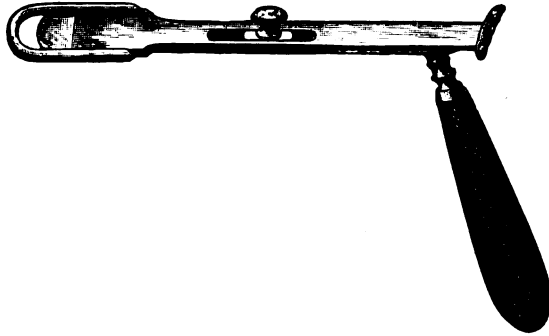


FIG. 540.—Mackenzie's tonsillotome.

severed by pressing the knife against it. Any undue hemorrhage can be controlled by ice, pressure, and astringents; actual cautery is rarely needed. In four instances the internal carotid artery has been wounded by recklessness in cutting the tonsils.

OPERATIONS ON THE TONGUE AND ŒSOPHAGUS.

It is often necessary to remove the tongue in part or entirely on account of hypertrophy, and malignant and other growths of its structure. The arteries supplying it are the *dorsalis linguæ*, *ranine*, and branches from the ascending pharyngeal. The *ranine* is the principal branch, and runs along the under surface of the tongue, from its base to the apex. The buccal, sublingual, and submaxillary glands are closely associated with this organ in a surgical sense. The facial and sublingual arteries will not be endangered, unless the floor of the mouth is operated upon in conjunction with the tongue. It should be remembered that the circulation in the opposite sides of the organ does not communicate freely, and consequently ligaturing of the lingual artery of one side will permit of free incision on that side with but trifling hemorrhage.

Tongue-tie.—This condition depends on an undue extension forward of the *frænum linguæ*, either with or without an abnormal shortening of it. If the condition be severe enough to call for treatment, the end of the tongue is pressed upward by passing the first two fingers beneath it, palm downward, bringing the tense *frænum* between them on the palmar surface, when it can be divided with a blunt-pointed scissors at a little distance from, but parallel with its under surface, care being taken not to sever the *ranine* artery.

Ranula.—The closure of the ducts of the sublingual and other glands in this situation causes a cystic distention of the ducts, and

even of the glands themselves. If it be not possible to find and probe the duct-openings, it will be necessary to evacuate the contents at the floor of the mouth below the tongue, or, if the tumor be of large size, this must be done in the median line externally, close to the hyoid bone. In either instance it may be necessary to pack the cavity with lint and liquor ferri sulphatis, or cauterize the sack with nitrate of silver, and even to dissect it partially or entirely away.

Excision of the Tongue.—The tongue may be removed with the *knife, scissors, galvanic cautery, écraseur, or ligature*. The last method should be excluded, as the time required and the pain caused by it is greatly in excess of that by the other methods. If the diseased portion be small, it may be taken away by the form of incision best calculated to accomplish the object, since it is not a good plan to secure symmetry at the expense of future safety. If the hypertrophy involves the apex, or if a tumor be located at this situation, it can be excised by removing a V-shaped piece in the following manner :

Operation.—Anæsthetize the patient, place him in a chair in a strong light with the mouth well opened by a special gag, or any suitable instrument, forced, with a string attached, between the posterior molars. If the patient be in the recumbent posture, the head is turned to one side, to collect the blood in the hollow of the cheek. Pass a stout ligature through each side of the tongue, just outside of the intended site of the apex of the V-incision ; loop them and give each to an assistant with instructions to pull the tongue forward ; seize the tip with a pair of forceps, or between the thumb and finger, and with a sharp-pointed, narrow-bladed knife transfix the organ posteriorly from below upward at the point of the V, cutting outward and forward through its borders ; check the points of severe hemorrhage with forceps, and make the incision on the opposite side in a reverse direction backward

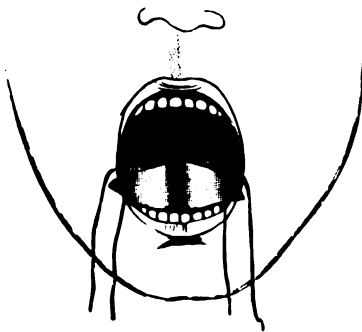


FIG. 541.—Removal of a V-shaped piece.

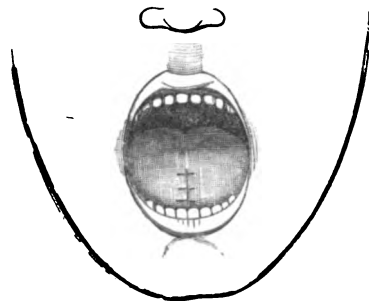


FIG. 542.—Flaps united.

to join the first incision (Fig. 541). Ligature the bleeding points and unite the flaps by sutures in the usual manner (Fig. 542). A method

has been recommended by Langenbuck to control the hemorrhage when but half or two thirds of the anterior portion of the tongue is to be removed by cutting. A long, well-curved needle, armed with a strong ligature, is entered at the left of the median line of the tongue, behind the portion to be removed, and passed through to the right side and under surface of the organ, so as to carry the ligature beneath the branches of the lingual artery. The ligature is then carried through the right border of the tongue and firmly tied. A similar procedure is repeated on the opposite side of the tongue. These ligatures can then be used to draw the tongue forward. Dr. Howe, of this city, has devised a "safety-pin clamp," with which he proposes to control the hemorrhage by passing the pin above the arteries and screwing the clamp into position against the intervening tissues. Heath highly commends the drawing of the stump of the tongue forward by the finger passed into the pharynx. This traction not only renders the bleeding point more accessible, but the hemorrhage is also directly checked by means of the pressure necessary to draw the tongue forward.

Hypertrophy of the Tongue (Fig. 543), involving its entire structure, can be treated by the removal of a V-shaped piece in the manner just described.

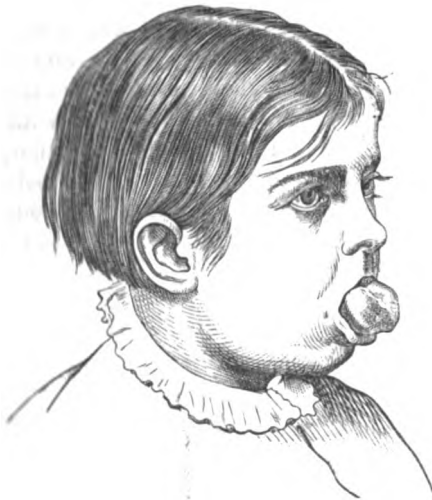

FIG. 543.—Hypertrophy of the tongue.

This will shorten its transverse diameter and diminish its length. The flaps are then united, and, after union has taken place, the thickness of the tongue can be diminished in the following manner: A strong ligature is passed laterally through the organ near to the base, and by this it is drawn forward and held while a wedge-shaped piece is removed by transfixing laterally as far back as possible and midway between its upper and lower surfaces. The under

flap is first made by cutting downward and forward through the under surface of the organ, then the upper flap is formed by applying the knife to the tissue above the last incision. The bleeding points should be ligatured, and the flaps united with sutures.

Half of the organ can be removed by first ligating the lingual artery corresponding to that half, after which two long stout ligatures are passed through it near the tip, one on each side of the median

line, by these the tongue is drawn forward and upward; the frænum and the mucous membrane beneath the tongue are cut with scissors back to the base of the organ; the tongue is then divided in halves, from before backward, with a knife or scissors, its deeper tissues are separated by tearing with the finger or handle of the knife, and the portion to be removed is finally separated with scissors. The remaining half can be removed in a similar manner. If the lingual arteries have not been tied, the *écraseur* can be employed, or if it be divided by scissors the bleeding points should be secured as soon as possible.

Removal of the entire Tongue.—This can be done either through the mouth or beneath the inferior maxilla, or by division of the lower jaw at the symphysis, or on either side of it. It can be removed through the mouth by the knife, scissors, the galvano-cautery, or the *écraseur*. When the knife or scissors are to be employed, it is a wise precaution to ligature both lingual arteries to prevent the profuse hemorrhage which must otherwise occur. A stout thread is then passed through the tongue at the juncture of the middle and anterior thirds, and by this the organ is drawn forward and upward, and detached from its connections with the jaw and pillars of the fauces. The muscles of the tongue are then divided by scissors back to near the larynx, as closely to its under surface as the disease will permit. The glosso-epiglottidean folds are now brought under control by passing a long ligature through each. These ligatures are allowed to remain *in situ*, in order that the floor of the mouth may be drawn forward by them in the event of secondary hemorrhage. The excision is then completed, and all bleeding points are checked. The surface is permitted to heal by granulation.

Mr. Whitehead, of Manchester, has frequently operated in this manner with great success, without previously ligating the lingual arteries, but by tying the bleeding points as they presented themselves. The *écraseur* offers an admirable means of removing the whole organ, with less danger from hemorrhage than by the use of the knife or scissors; the results, too, are quite satisfactory. This instrument may be applied through the mouth, or by way of a free puncture made with a stout, sharp-pointed knife introduced from without between the hyoid bone and the jaw, a little nearer the latter,

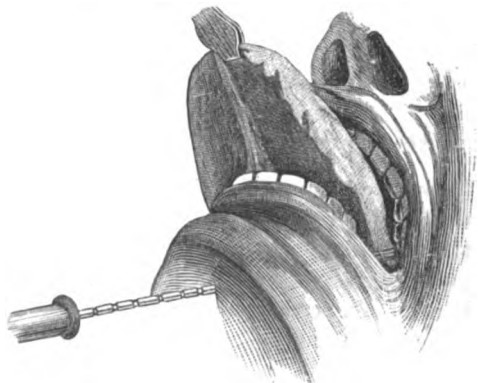


FIG. 544.—Écraseur in position.

and caused to enter the floor of the mouth, near the frænum (Fig. 544). The wire or chain is passed through this opening, around the base of the tongue, in which position, after the tongue is well drawn forward, it is confined by means of three or four stout hare-lip pins passed at short intervals through its base from side to side; after which the organ is slowly and carefully severed. If the tongue be drawn forward in the usual manner and freely detached from its connections with the jaw and floor of the mouth, the same instrument can be quite as readily applied without the submental puncture. The use of the *écraseur* for complete ablation can be recommended with confidence; and it should, if accessible, be selected in preference to galvano-cautery, which is much more likely to be followed by secondary hemorrhage.

The removal below or through the jaw does not offer the chances of success enjoyed by the former methods. The operation devised by Regnoli affords easy access to all portions of the tongue, except its base, and also furnishes good drainage, but creates a large and somewhat dangerous wound.

Operation.—A crescentic-shaped incision is carried along the base of the lower jaw (Fig. 545), extending from in front of its angles. A vertical incision is then made from the center of this to the median line of the hyoid bone. The flaps are reflected, and the attachments of the lingual and hyoid muscles divided from the surface of the lower jaw. The tongue is then drawn through the opening and severed by the knife or *écraseur*, the bleeding points being secured as fast as they appear. The flaps are united, and the remaining raw surfaces allowed to heal by granulation.

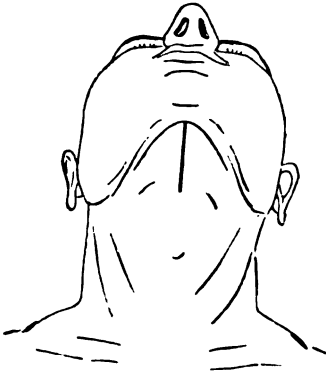


FIG. 545.—Regnoli's incision.

Knox made a vertical incision through the lower lip down to the hyoid bone, extracted a tooth and sawed through the symphysis mentis. The mucous membrane and the muscular attachments of the tongue were then divided, the lingual arteries cut and tied, and the tongue removed close to the hyoid bone. Mr. Heart employed the *écraseur* instead of the knife. Sédillot made an <-shaped section of the bone to prevent the fragments from sliding after approximation. Billroth divided the jaw between the canine and last molar teeth, corresponding to the diseased side of the tongue, and wired the fragments after the removal of the diseased portion.

If the floor of the mouth be involved in addition to the tongue, Bill-

roth made an incision about one inch below the border of the lower lip from one facial artery to the other; at the ends of this incision he made two vertical ones extending to a point about four fifths of an inch below the border of the inferior maxilla; at the juncture of these vertical incisions with the jaw, he divided the bone and turned it downward along with the soft parts, thereby affording ample room to reach the diseased parts within. If the portion to be removed be extensive and the danger from hemorrhage great, a preliminary tracheotomy is advisable. This measure not alone prevents the blood from obstructing respiration, but lessens the dyspnœa frequently caused by a wide separation of the jaws.

Kocher recommends the following plan if the floor of the mouth, the pharynx, and contiguous glands be involved along with the tongue. After a preliminary laryngo-tracheotomy and thorough cleansing of the parts, a triangular flap is made, with the base upward, its lower boundaries corresponding to the course of the digastric muscle, and its apex being at the point of connection of this muscle with the hyoid bone (Fig. 546, *c*, *e*, *d*, *b*). The posterior incision may also be made

from this point directly to the anterior border of the sterno-mastoid muscle, thence upward along its border to the angle of the jaw, so as to afford a greater space than is afforded by the former line of incision. These flaps cover the region of the jaw and neck occupied by the facial artery and the submaxillary gland posteriorly, and the lingual artery and sublingual gland anteriorly. The flap is dissected up, the arteries are tied, and the glands, if involved, are removed. This exposes the

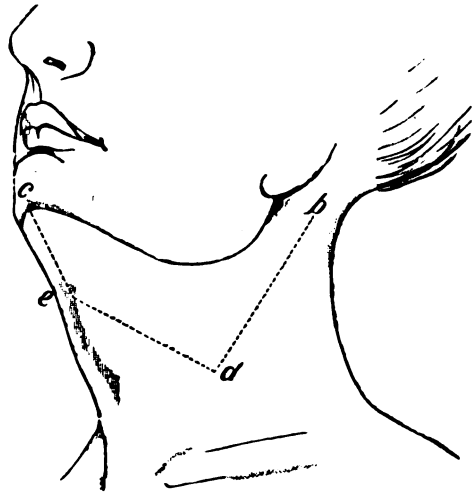


FIG. 546.—Kocher's operation.

side of the tongue and floor of the mouth for easy inspection and manipulation. The larynx and pharynx are then protected from the entrance of blood by a large sponge to which a string should be attached, and the myo-hyoid muscle is divided close to the jaw, exposing the tongue freely. The organ is now drawn through the opening, split, and the half of it corresponding to the flap is removed, including, if necessary, the floor of the mouth, pillars of the fauces, and pharynx down to the hyoid bone. The remaining portion can be removed in a similar manner, through a triangular opening on the side corresponding to it, or

through the primary opening, if the extent of the disease will permit. As before remarked, the operation, which involves the bone and soft parts around it, results less favorably than when the tongue is removed through the mouth by the methods described for that purpose. The after-treatment consists in keeping the mouth cleansed, while to the raw surfaces iodoform and iodoform gauze, or other suitable antiseptic dressings, are applied. The tracheotomy-tube should not be removed until all dangers from inflammation and the discharges are ended.

Results.—The rate of mortality from removal of the tongue by all of the methods described is considerable, sixty-six out of two hundred and forty-four cases having died.

Œsophagotomy.—It sometimes becomes necessary to open the œsophagus on account of obstruction due to foreign bodies lodged in its cervical portion. In this connection it is well to recall the relations of the œsophagus. It begins opposite to the cricoid cartilage, and is located, in this region, somewhat to the left of the median line. The situation of the foreign body is usually marked by a greater or lesser prominence on the left side, below the cricoid cartilage; or, if this be not manifest, the exact site of the canal can be determined by the introduction into it, through the pharynx, of a good-sized bulbous or other form of probang. The following are the important surgical relations of the œsophagus in the cervical region: In front, with the trachea, above, and with the thoracic duct and the thyroid gland below; behind, with the vertebral column and longus-collis muscle; at the sides, especially the left, with the common carotid and inferior thyroid arteries, and thyroid lobes. The recurrent laryngeal nerves lie between it and the trachea.

Operation.—Always employ an anæsthetic; place the patient on the back, with the chest and shoulders elevated and the head turned to the opposite side; feel for the foreign body, and, when it is found, make the incision directly at that point.

If the foreign body be not discernible, make an incision about four inches in length on the left side, between the sterno-mastoid muscle and the trachea, beginning at the upper border of the thyroid cartilage. The platysma and fascia are divided on a director; the borders of the wound are separated, the omo-hyoid is drawn outward, and the sterno- and thyro-hyoid muscles inward; this exposes the sheath of the carotid, which is drawn outward and retained; the lobe of the thyroid gland is raised and drawn inward; the larynx carefully outlined and drawn forward and held while the location of the foreign body is sought for; if not present or distinguishable, the bulbous probang is then introduced to mark the outline of the tube, the wall of which is raised with a tenaculum and opened sufficiently to admit the finger, care being taken to avoid the recurrent laryngeal nerve. The site of the obstruction is located by passing the finger into the tube, and the cause

is removed by suitable forceps, aided by manipulations from without, and by lengthening the incision if necessary. The opening in the œsophagus may be closed with fine catgut, the external incisions united in the usual manner and dressed antiseptically, and liquid food introduced through a tube for a few days. Or the entire wound may be left open, a feeding-tube introduced through it into the stomach, and allowed to remain three or four days at a time; then it is removed, to be cleaned. As soon as the cut surfaces become granulated, the tube may be removed from the opening, and a smaller one employed, which is passed into the stomach through the nostril. The patient is fed through this until the œsophageal opening has completely closed.

Fallacies.—The foreign body may be mistaken for an enlarged gland on external examination. The œsophagus may be confounded with the longus-collis muscle at first; however, a moment's examination will serve to dispel the doubt. If the probang be introduced through the pharynx, its exact location will be established. The respiratory movements of the œsophagus, distending and collapsing alternately, are important aids in determining its identity.

Results.—Eighty-two cases are reported, of which nineteen died; but from causes independent of the operation in many instances. The rate can be placed at about twenty-two per cent, which will surely be lessened in the future if the operation be done as early as it should be.

Stricture of the Oesophagus.—This condition depends upon a circumscribed inflammatory action or other morbid process, involving one or more coats of the tube, and causing a narrowing of its caliber, which manifests itself proportionately to the degree of constriction. It may be limited to one side, or involve the whole circumference of the tube. The most frequent site is opposite the cricoid cartilage, where the pharynx and œsophagus become continuous with each other. The stricture can be treated by dilatation, for which purpose various forms of dilators have been constructed (Fig. 547). These and all other

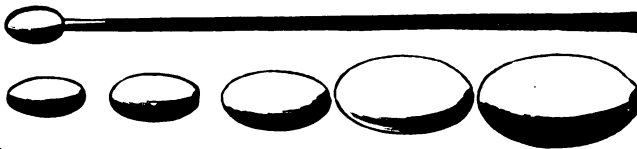


FIG. 547.—Oesophageal dilators.

forms should be introduced as often as necessary by extending the neck and passing the instrument carefully downward in contact with the posterior portion of the pharynx, guided by the index-finger of the disengaged hand. No force should be employed, for fear of causing a false passage. The surgeon should always eliminate the possibility

of aneurismal constriction of the tube before an attempt is made to overcome the obstruction. The sponge extremity of the probang can be used where unusual caution is desirable in exploring this passage.

Retrograde Divulsion.—In 1883 Loretta, of Bologna, opened the stomach, passed a divulsor through the opening into the lower third of the œsophagus, and ruptured a stricture at this point sufficiently to allow the passage of food. He has since repeated the operation on two occasions, and in each case it was followed by satisfactory results.

Internal Œsophagotomy.—This operation is performed by an appropriately constructed instrument (Fig. 548), sometimes so arranged as to be passed upon a guide, as in internal urethrotomy, and has been successfully practiced on several occasions. However, the contiguity of important anatomical structures, and the inability to comprehend the exact relations of the stricture to the outer wall of the tube, make the operation an exceedingly hazardous one. If it be attempted, the constriction should be incised only sufficiently to admit a bougie, by the means of which the treatment should be continued.

Strictures of the cervical portion of the œsophagus may be divided from without. The stricture is first located by a bougie introduced into the tube, and is then cut down upon through an incision similar to that for œsophagotomy.

Results.—Internal œsophagotomy has been performed, in all, about nineteen times, of which one third died in sixteen days from results associated with the operation. Of the remainder, three are said to have recovered, while the others survived for a period from one month to several years. About one third of the cases required one or more repetitions of the operation.

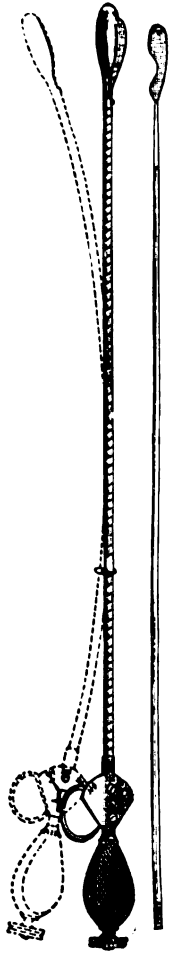


FIG. 548.—Sands' instrument for internal œsophagotomy.

Œsophagectomy.—Œsophagectomy consists in excising a portion of the cervical œsophagus through an incision made in the same manner as for œsophagotomy, for the removal of a cancerous growth. The upper end of the lower portion of the tube is then raised forward and united to the wound; thereby forming an opening through which food may be introduced by means of a tube.

Results.—Only five or six cases have as yet been reported. In two of these, life was prolonged for months; the remainder died soon

after the operation. There is reason to believe that life can be more prolonged by feeding through a tube in the usual manner, than by this procedure.

Oesophagostomy.—This procedure is employed to establish a fistu-

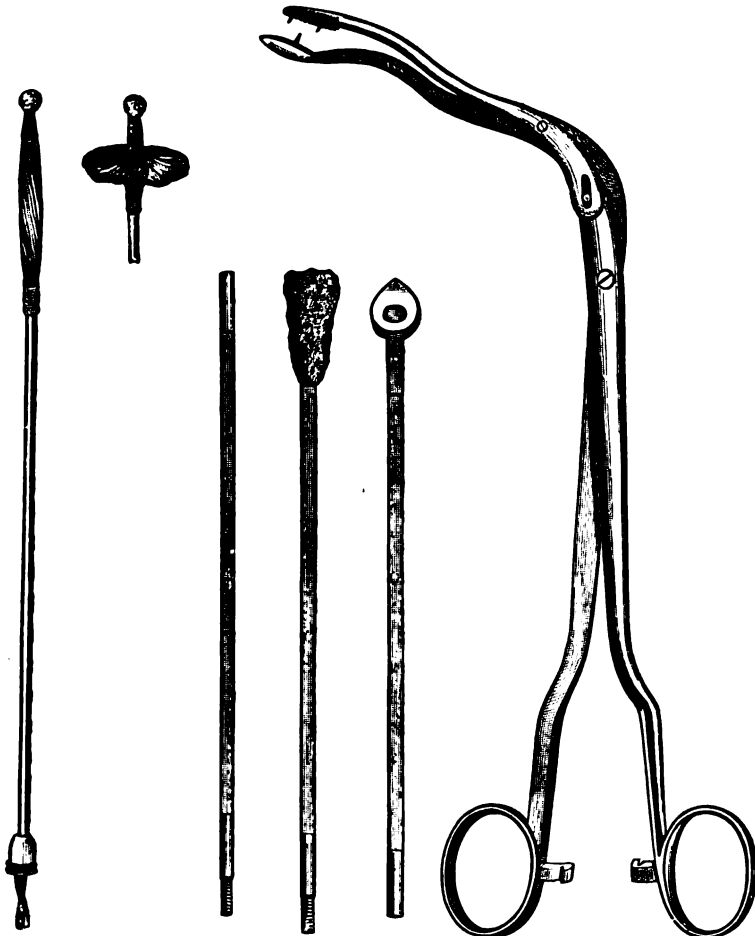


FIG. 549.—Bristle probang.

FIG. 550.—Sponge and bucket probang.

FIG. 551.—Cusco's throat-forceps.

lous opening, with the tube, below the point of an incurable, impassable constriction. It provides for the introduction of food into the stomach, and serves as a temporary palliative measure.

Results.—It has been performed thirty-two times, in which about sixty per cent of the patients perished. Of this number, twelve died from the operation directly or from its sequels.

The removal of foreign bodies from the oesophagus is accomplished

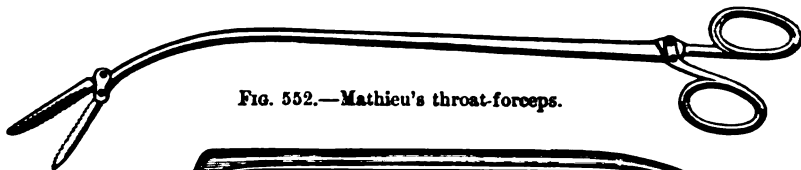


FIG. 552.—Mathieu's throat-forceps.




FIG. 553.—Burge's throat-forceps.

by probangs (Figs. 549 and 550) and various forms of long forceps (Figs. 551, 552, and 553).

CHAPTER XIV.

OPERATIONS ON HOLLOW VISCERA IN CONTACT WITH SEROUS SURFACES.

THE injuries of these organs which require surgical treatment may result either from external violence, or become part of the procedure necessary for the removal of obstructions in the intestinal tube, or of malignant growths from the duodenum, stomach, or intestines. In these operations it is important : 1, to avoid all unnecessary hemorrhage ; 2, to prevent the escape of irritating matter into the abdominal cavity ; 3, to unite the divided surfaces so that they shall remain properly opposed, and be followed by perfect union ; 4, to avoid all unnecessary shock and septic or irritating influences. *The first indication* is met by carefully avoiding any incisions through the line of the established course of vessels, and by the use of needles which do not possess cutting edges (as when their points somewhat resemble those of the ordinary sewing-needle), but enter the tissues by causing their separation. To meet *the second indication* requires a great degree of caution irrespective of the knowledge of any established measures. The lips of the wound should always be kept uniformly and well raised by means of forceps ; or, by strong ligatures passed through their borders at suitable situations. If the nature of the case will permit, the contents of the viscus should be removed before the operation is commenced, and at all times the serous surfaces must be protected from contact with irritating matters, by means of broad, thin, antiseptic sponges or other suitable agents moistened in a warm, mild, antiseptic fluid.

To fulfill *the third indication*, sutures of various forms and methods of application are employed ; the aim of all being to bring the serous surfaces in contact, and maintain them so until firm union is

established. To do this, it is necessary to roll the borders of the wound inward, since the mucous surfaces will not unite to each other (Fig. 554). The size of the wound has to do with its treatment. If it be of large size, it may be advisable to connect it with the opening in the abdominal walls, and allow the resulting fistulous opening to close spontaneously. When it is possible, however small the wound of the intestine may be, it should be closed, or it may permit the escape of irritating matters into the abdominal cavity. *The fourth indication* is very important, especially if the operation be prolonged and tedious, or if the intestines be removed from the cavity of the abdomen. The room in which operations on the abdominal contents are performed should be thoroughly cleansed and fumigated when possible, and in every way made aseptic. If its temperature can be raised to about 90° F., and the atmosphere moistened with antiseptic vapors, the surroundings will be much improved, especially if the abdominal contents are long exposed. If the intestines be removed from the cavity, they must be surrounded by cloths saturated with antiseptic fluids, and kept warm and moist by repeated applications of the same until they are replaced. The "toilet" of the abdominal cavity must be cautiously and perfectly made before it is closed, and suitable provisions for drainage established, if pernicious secondary local processes be apprehended. As a rule, the sutures should not include the mucous surface, but should extend down to it. They should not be more than two lines apart, nor include more than one line of the intestinal substance, and should be cut short.

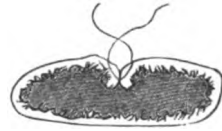

FIG. 554.—Lembert's suture.

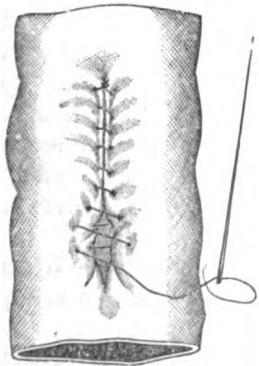


FIG. 555.—Continuous suture.

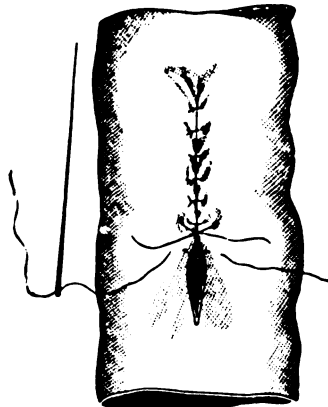


FIG. 556.—Lembert's suture.

Continuous Suture. — The name defines its method of arrangement. It is exceedingly useful in joining the borders of long cuts of either a serous or cutaneous surface. In the latter the stitches are further apart than when applied to serous surfaces, and the cut surfaces of the wound are brought directly

in contact with each other (Figs. 555 and 80).

Lembert's Suture (Figs. 554 and 556).—This form of suture is an admirable one, easy of comprehension and of application. It can be

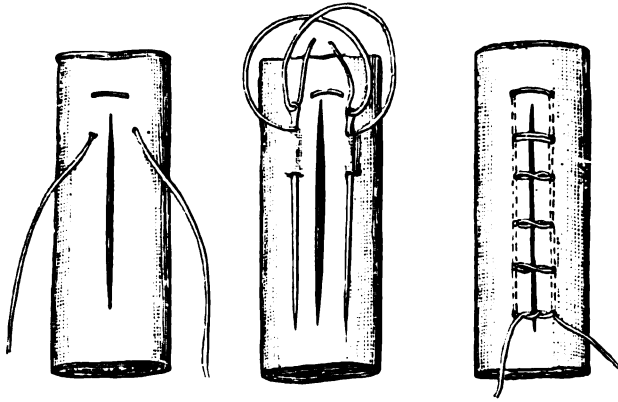


FIG. 557.—Gely's suture, external appearance.

used indiscriminately in all wounds of serous membranes, either in the continuous or interrupted forms.

Gely's Suture (Fig. 557).—In this variety a long suture is selected and armed with a needle at each end. The needles are inserted near the angles of the wound, about two lines from the edges, and carried along the interior of the bowel for a sixth of an inch, then brought out precisely on the same level, so as to again appear on the peritoneal surface. The sutures are then crossed, the right needle being passed through the puncture made by the left, and conversely. If a knot be

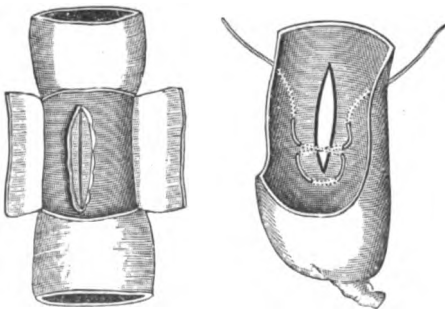
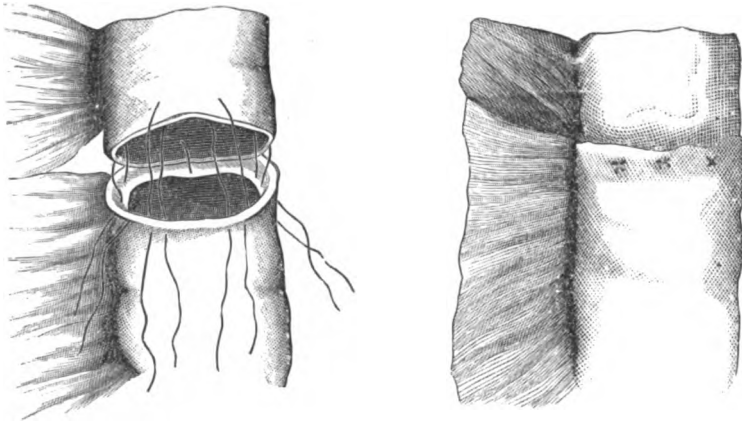


FIG. 558.—Gely's suture, internal appearance.

made at each crossing, slipping of the sutures will be prevented. The number of the crossings will vary with the size of the cut. By this method the edges of the wound are thoroughly inverted (Fig. 558), and all danger of extravasation is prevented.

Jobert's Method.—When the intestine is completely divided transversely, its lower end is turned or tucked in for a short distance, the upper end pushed within it, and their serous surfaces are united by fine sutures (Fig. 559). It will be necessary to separate the mesentery from each extremity of the intestine for a short distance in order to permit the coaptation just described (Fig. 560). If the mesentery



FIGS. 559, 560.—Jobert's method.

be separated unnecessarily, sloughing of the intestine is likely to occur.

Czerny-Lembert Suture.—Two rows of sutures are employed in this method, neither of which, however, is passed through the mucous membrane (Fig. 561). The first series brings the edges of the

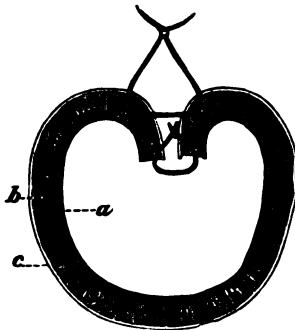


FIG. 561.—Czerny-Lembert suture. a. Mucous coat. b. Muscular coat. c. Serous coat.

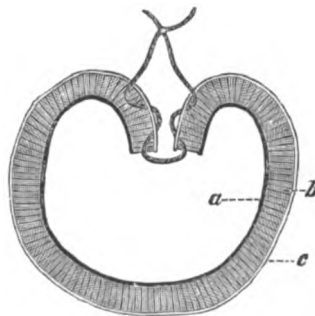


FIG. 562.—Gussenbauer's suture. a. Mucous coat. b. Muscular coat. c. Serous coat.

mucous membrane together; the second, or external series, unites the serous surfaces of the bowel. Owing to the eversion of the intestinal structures, the first row can be introduced without difficulty.

Gussenbauer's Suture.—By means of this form of suture the mucous and serous structures of the intestine may be brought together by one suture (Fig. 562). However, this stitch is complicated and somewhat tedious, and affords no additional security to repay for the delay and difficulty attending its use.

OPERATIONS ON THE STOMACH.

It sometimes becomes necessary to open into the cavity of the stomach in order to remove foreign bodies, or to establish a permanent communication with it through the abdominal walls, for the purpose of supplying alimentation. It is therefore very important to understand its relations to the abdominal walls, and likewise to other contiguous parts. It lies principally in the epigastric and left hypochondriac regions. Its anterior surface is directed upward and forward, and is in relation to the diaphragm and the under surface of the left lobe of the liver, and, unless empty or adherent posteriorly, comes in contact with the abdominal walls in the epigastric region. It is altered in its

position and relations by the act of respiration, descending with inspiration and ascending with expiration; when empty, it retires posteriorly and is covered by the left lobe of the liver. The convexity of the stomach seldom rises above a line extending between the cartilages of the ninth ribs. The transverse colon lies at its lower border when the stomach is moderately distended.

The identity of the stomach is established by the knowledge of its relation to the under surface of the liver and diaphragm, by its pale color and great

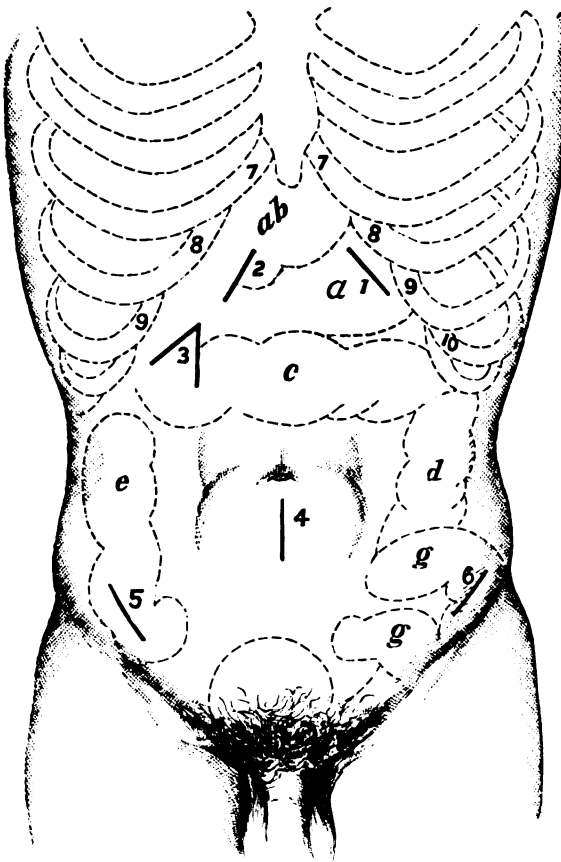


FIG. 563.—*a, b.* Left lobe of the liver. *a.* Cardiac end of the stomach. *c.* Transverse colon. *e.* Ascending colon. *d.* Descending colon. *g, g, g.* Sigmoid flexure.

size, and by the arrangement of the gastro-epiploic vessels.

Gastrostomy.—This term is applied to the operation of opening the stomach through the abdominal wall and establishing a permanent fistula to it.

Antiseptic precautions should be taken, and anæsthesia produced by chloroform, as ether is more likely to cause vomiting.

Operation.—Place the patient on the back, and make an oblique incision on the left side, about two and one half inches in length, from right to left, parallel with and one inch below the lower border of the cartilage of the eighth rib, and terminating opposite to the ninth cartilage (Fig. 563, 1). The tissues composing the walls corresponding to this incision are divided successively on a director, down to the peritoneum. All bleeding points must now be closed and the peritoneum opened, and its divided borders caught and drawn outward with long ligatures, or forceps, which are permitted to lie on the external surface, to prevent its retraction. The lower border of the left lobe of the liver can now be seen. The thumb and forefinger of the left hand are then introduced, and, guided by the under surface of the liver, readily grasp the stomach. If possible, a portion of it should be brought through the opening, or, guided by the thumb and finger, forceps may be introduced and its anterior surface grasped and drawn through the opening. It is very important at this time to be certain that the portion drawn through be not the colon or some other organ. The dense white appearance of the stomach, the arrangement of its superficial vessels, and its size should serve to distinguish it from any other viscus. Often, as soon as the peritoneum is divided, the entrance of air into the abdominal cavity causes the stomach to retire upward and backward, thereby interposing an annoying obstacle to grasping it. To obviate this difficulty it has been recommended to pump air into the stomach just before the beginning of the operation through a tube carried down to the obstruction, or to cause the entrance of carbonic-acid gas, produced by chemical action at the time, or to introduce the fumes of ether by means of a tube. These expedients are, however, hardly of sufficient practical importance to merit the trouble incident to their utilization.

As soon as the surgeon is satisfied that the stomach is within his grasp, it is drawn into the opening and fixed, by passing through it in opposite directions two or three long stiff needles (Fig. 564), allowing their extremities to rest upon the external surface of the abdomen; or, a strong ligature is passed through the center of the protruding portion, is looped and given to an assistant. The parietal layer of peri-

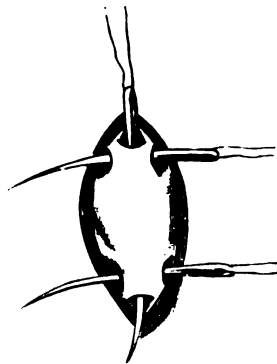


FIG. 564.—Needles in position.

toneum previously grasped and drawn outward should now be carefully stitched with antiseptic silk or catgut sutures to the visceral layer on the stomach, being careful not to carry the sutures entirely through the wall of the stomach. Still further security is given to the opposed surfaces by putting a row of stitches of strong antiseptic silk through the whole thickness of the abdominal walls, and also through the serous and muscular walls of the stomach. Two other stitches may be introduced, so as to transfix the end of the wound only, care being taken not to include the peritoneum. Finally, a ligature is passed through the serous and muscular walls of the center of the exposed portion of the stomach (if this was not done in the first instance), and left hanging to be used as a future guide to opening the organ in case the condition of the patient will admit of four or five days delay, sufficient to permit adhesive union to take place between the serous surfaces. If not, then the operation should be completed at once. This is done by making a vertical incision about half an inch in length through its coats into the cavity, care being taken to prevent the escape of its contents. If troublesome hemorrhage be apprehended from this incision, the opening can be made by a thermo-cautery. The wound in the abdominal wall is reduced in size to correspond to that of the stomach by stitches carried through its entire thickness. The lips of the opening into the stomach are then united to those of the abdominal opening, by antiseptic silk carried through the entire thickness of both, being careful to oppose the mucous lining of the stomach to the integument of the abdomen.

Fallacies.—The colon may be mistaken for the stomach. However the difference in color, extent, and muscular arrangement, together with the difference in mobility, and the fixed relation of the stomach to the under surface of the liver, should make the distinction easy. Confusion may arise in distinguishing the cartilage of the eighth rib from the contiguous ones. The seventh articulates with the sternum; the first one below it will therefore be the eighth.

Other external incisions differently located and variously shaped may be employed; such as, a curvilinear one with the convexity toward the median line, extending from the seventh costal cartilage downward and outward for nearly four inches, one through the left linea semilunaris, or one along the outer side of the rectus, etc. That which has been described in detail seems the most favorable from an anatomical basis.

The results, however, are of necessity very unfavorable, since the conditions calling for the measure are often of themselves speedily fatal; moreover, the delay in resorting to it frequently renders the patient unable to withstand the shock of the procedure. Two hundred and seven gastrostomies are reported, from which sixty-one deaths have resulted directly. In about one hundred and seventy of the whole

number fifty died from the direct effects and from the sequels of the measure, making a death-rate of about thirty per cent. This is about fourteen and a half per cent greater than when the operation was performed for the removal of foreign bodies alone. When due to malignant disease it only acts as a palliative measure, while more than sixty per cent have recovered when performed for non-malignant cicatricial obstructions. This operation, and also *gastrotomy*, is sometimes employed for making an opening into the stomach to remove a foreign body which has entered it through the oesophagus. The line of incision, and all the steps and precautions, are similar to those for *gastrostomy* proper. After the foreign body is removed, the opening in the stomach is closed by catgut sutures, after the manner of intestinal sewing, and returned to the abdominal cavity, and the opening in the abdominal walls closed. The patient must be nourished by the rectum, and all gastric disturbances quieted by anodynes.

Gastro-enterostomy.—This is essentially a palliative operation, and was performed first by Woelfler in 1881, since which time it has been done upward of twenty times for advanced pyloric cancer and non-malignant pyloric stenosis. When performed for the former reason, about sixty-four per cent of the cases have died, while for the latter but twenty-five per cent have died.

All the antiseptic precautions that surround abdominal surgery (*gastrostomy*, *enterectomy*, etc.) should be observed.

Operation.—An abdominal incision is made in the median line from just below the tip of the ensiform cartilage downward nearly to the umbilicus, and the abdominal cavity is entered in the usual manner.

The viscera to be united (stomach and jejunum) are caused to present at the external opening, where they are carefully isolated from the abdominal cavity and protected by warm, moist antiseptic sponges. The loop of intestine to be attached to the stomach is emptied by gentle pressure, and the intestinal contents cut off from it by the intestinal pincers, by the fingers of an assistant, or by strips of loosely tied iodoformized gauze. The stomach

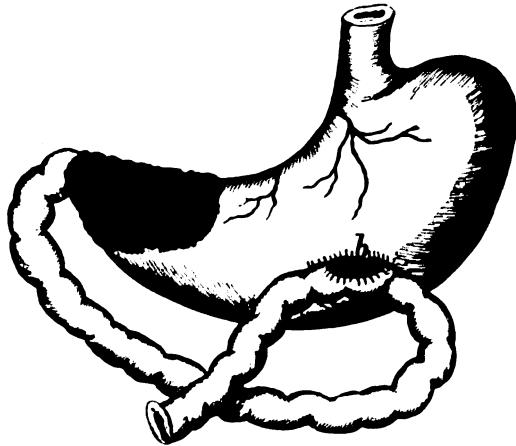


FIG. 565.—Gastro-enterostomy.

should have been emptied and thoroughly washed out with a salicylate-of-soda solution before the operation. An incision about an inch and a half in length is made through the anterior inferior wall of the cardiac half of the stomach, down to the mucous membrane (Fig. 565). An incision of a similar size is then made on the intestinal loop down to its mucous membrane, *b*. The lower borders of the cut surfaces are placed in contact and united with a continuous suture of silk or catgut, carried from without inward between the mucous and muscular coats of the respective viscera, thereby causing the borders of similar structures to be brought in contact with each other. The mucous coats are then opened by scissors, taking care to prevent the least extravasation into the abdominal cavity. The remaining portions of the borders are now united in a similar manner to the first, and the whole circumference of the wound is fortified by a second row of either the continuous or interrupted suture, carried through the serous coats only.

Duodenostomy, or the formation of a permanent artificial opening into the duodenum through the abdominal wall, has been suggested as an alternative to pylorotomy. It has been performed three times, with a fatal result in each case. It is not, at the present time, thought to be a justifiable operation.

Jejunostomy has been recommended as a substitute for pylorotomy. It is, no doubt, much more easily performed than duodenostomy; but the advantages in favor of gastro-enterostomy are too numerous and important to admit of its being superseded by either of the other operations.

Resection of the Pylorus.—This operation has been quite frequently employed since 1879 to relieve obstruction occurring at the pylorus, due to malignant disease, and stenosis from other causes. While its inception and performance are in keeping with the rapid strides made in abdominal surgery in the past few years, the nature of the operation and the causes for which it is done must of necessity insure a large number of deaths. The pylorus is in the epigastric region, between the median line and a line falling from the tip of the cartilage of the eighth rib on the right side to the middle of Poupart's ligament, and is in contact with the under surface of the right lobe of the liver.

The duodenum, which is the next most important factor, is located in the right hypochondriac region, being, of course, a direct continuation of the pyloric extremity of the stomach. The normal relations, however, will avail but little in connection with the abnormal size, and the displacement attendant upon an already over-distended stomach. All primary incisions must therefore be located so as to meet the indications of the case in question. The difference in the outlines of the stomach is noted, both in its distended and empty condition,

to better enable the surgeon to properly locate the abdominal incision. In some cases the greater curvature may reach the symphysis pubis.

The patient is prepared by washing out the stomach daily with salicylated water or any suitable antiseptic for four or five days prior to the operation, the stomach-pump, or siphon, being employed for the purpose. The intestinal canal is evacuated the day before the operation. An anæsthetic is given, chloroform being preferable as less likely to produce vomiting, and the patient is placed on the back in a good light. The stomach should be thoroughly washed out before beginning the operation.

Operation.—An incision is made about four inches in length in the median line, or parallel to the right costal margin (Fig. 563, 2), as nearly as possible over the displaced pylorus. The tissues are divided carefully down to the peritoneum, and all bleeding stopped before this membrane is divided; an exploration with the finger is also made, to determine, if possible, the exact location of the indurated portion, after which the final opening is made to correspond to it.

If it be impossible to satisfactorily outline the organ, it may be distended with fluid—which must be withdrawn when the location of the diseased portion is determined—or with carbonic-acid gas; even the fumes of ether can be introduced as in rectal anæsthesia. The peritoneum is cut, and the pylorus and such other portions as are necessary are then drawn through the wound and isolated and surrounded by napkins or large flat sponges wrung out in a warm antiseptic solution. A large, flat, soft sponge, moistened with an antiseptic solution, is then passed beneath the part to be removed, to prevent the entrance of blood and other fluids into the abdominal cavity. Strong ligatures may now be passed through the walls of the viscus at three or four points outside of the proposed incision, so as to raise the walls of that extremity as soon as it is divided, that its contents may not escape.

The omenta are separated the necessary distance along the curvatures of the stomach by tying them in small portions and dividing them between the ligatures. The pyloric extremity of the stomach is then incised with strong, long-bladed scissors from above downward, and from left to right, for about two thirds of its depth, through both walls, at a point at least two thirds of an inch from the diseased growth in its structure. The stomachal borders of this incision are then joined by the Czerny-Lembert suture, the threads being located about one-eighth inch apart. The pyloric extremity of the stomach is now cut entirely across, and the resulting opening in the stomach should correspond in its extent to the width of the duodenum, which should now be cut completely across in the same manner as the stomach. The divided extremity of the duodenum is carefully sewed to the opening

in the stomach by the Czerny-Lembert suture, or such other form of suture as may suit the surgeon.

The diseased growth should be removed with great care, and with due regard to the preservation of the vascular supply of the viscera. Sloughing of the gastric or duodenal margin of the wound or the walls of the colon caused by disturbance of nutrition is one of the greatest dangers. The pyloric, gastro-duodenal, and gastro-epiploica dextra arteries and their branches should be preserved for this reason, when this can be done, and the removal of the diseased tissues be still accomplished.

If any oozing occur from the cut surfaces, it may be controlled by the protected blades of the T-shaped pincers (Fig. 566), etc. The extent of the incisions, as well as their shape, will be governed by




FIG. 566.—Cross-bar forceps.

the diseased tissue to be removed. If adhesions exist between the growth and the contiguous parts, they can be separated if expedient; if not, no further attempt to complete the operation need be made, and the abdomen should be closed. The respective extremities of the

the diseased tissue to be removed. If adhesions exist between the growth and the contiguous parts, they can be separated if expedient; if not,

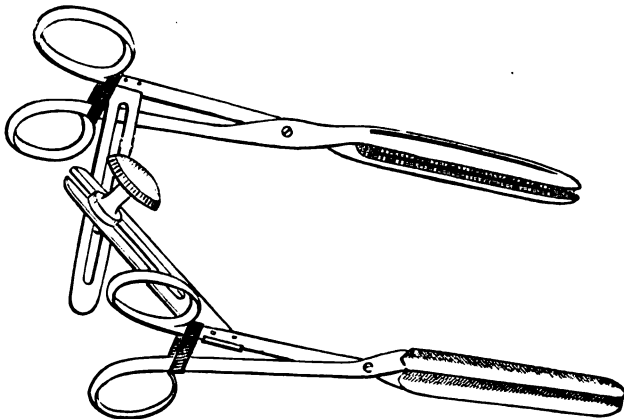


FIG. 567.—Abbe's intestinal pincers.

divided viscera can be well controlled by the fingers of an assistant with or without the use of the intestinal pincers (Fig. 567). The outline of the pyloric cut may be greater than the caliber of the remaining duodenum (Fig. 568). The caliber of the larger portion must be reduced to a suitable size to be joined to its fellow, *c*, *a* to *d*,

e; or *c*, *b* may be sewed until it shall conform in width to *d*, *e*, to which it is sewed, thus transferring the pyloric opening to the greater curvature of the stomach; the Czerny-Lembert suture answers admirably for the purpose; or the borders of the openings may be joined by means of a double row of the Lembert form of suture. The first row should be carried down to the mucous membrane, and be interrupted; the second row should be deposited outside of the first one, and include the serous membranes only.

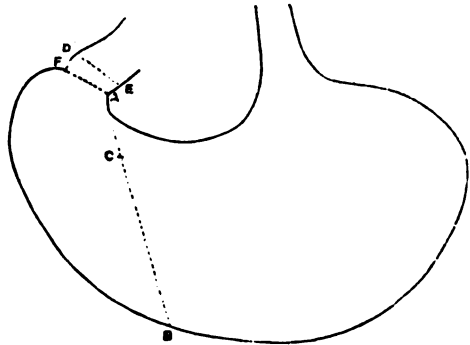


FIG. 568.—Outlines of incisions.

This row may be continuous. After all bleeding is checked, and the peritoneal cavity is thoroughly cleaned, the parts are returned and the abdominal wound is closed in the usual manner. The patient is then quieted by anodynes and nourished by the rectum during the first three or four days, until fluid food can be given by the mouth. *The contraindications* to the operation are: Old or weak patients; evidences of malignant secondary deposits; existence of extensive adhesions; chronic incurable dilatation of the stomach, etc.

Results.—Of the twenty-three cases reported by Rydigier in 1883, five had recovered. Still, one of these died four months after the operation from a return of the disease. At the present time pylorotomy has been performed at least eighty-two times, with twenty-one recoveries from the operation. Of thirty-six cases for carcinoma, seven had recovered and two were doubtful. The prognosis is much better in the colloid than other forms of carcinoma. In only about five per cent of the cases were adhesions and enlarged glands absent. Adhesions to the pancreas and enlarged glands of the great omentum were most frequent. Twenty-nine cases are reported where it was not deemed advisable to continue the operation, owing to extensive adhesions, shock, etc. The time occupied in the operation is modified by the complications, being from an hour and a quarter to five hours. The rate of mortality from the operation is about seventy-five per cent as the cases occur. If uncomplicated, it is fifty per cent, heart failure, from shock, being the fatal element. The percentage of ultimately successful cases is but little above eight and a quarter.

Loreto's Operation is divulsion of the pylorus by the fingers, or other similarly effective agents. In this the abdominal incision is made to correspond to the location of the disease as in the preceding operation;

or, if the condition will permit, it is commenced an inch and a half below the ensiform cartilage and carried obliquely downward and outward for four or five inches to within an inch and a half of the ninth costal cartilage (Fig. 563, 2). The opening is sometimes made through the linea alba. The abdominal incision is made with the same precautions as in the preceding operation. The pyloric extremity of the stomach is drawn out and an opening made into it between and at equal distances from its two curvatures, about two and a half inches in length, beginning an inch and a half from the situation of the pyloric valve. The hemorrhage is then controlled; the index-finger is introduced through the pyloric valve and carefully rotated, with pressure and counter-pressure. The second finger is introduced beside the former in the same cautious manner, and so on until the constricted portion is well distended. The wound in the stomach is then closed by the Gély or Lembert suture, the parts are returned, and the abdominal wound is closed as before.

The results of this operation are much more favorable than those for excision of the pylorus, and it is entirely proper that dilatation should be considered in connection with it; the incision through the abdominal walls being made with a view to excision, if it be malignant, and divulsion if the stenosis be due to non-malignant causes. Divulsion has been performed eight or ten times, with a rate of mortality varying from fifty to seventy-five per cent.

OPERATIONS ON THE GALL-BLADDER.

It occasionally happens that obstructions of the cystic duct and distention of the gall-bladder from gall-stones or other causes give rise to an abdominal tumor of considerable size, which is dangerous on account of the liability to rupture, and is distressing from the pain and tenderness.

Cholecystotomy.—This operation consists in cutting down through the abdominal wall upon a tumor, caused by a distended gall-bladder, and evacuating its contents. The incision is made, as a rule, over the center of the tumor, parallel to the free border of the ribs. At first it should be about three inches in length, large enough for exploration, after which, if need be, it can be enlarged. The various layers composing the abdominal wall are divided on a director down to the peritoneum, which should not be opened until all hemorrhage is arrested. Two methods of procedure are now recommended: 1. Ascertain if the serous covering of the tumor be adherent to the parietal layer of the peritoneum; if such be the case, open into the tumor and evacuate its contents. If it be not adherent, and the conditions of the patient will permit, fill the wound with strips of antiseptic gauze or marine lint. After five or six days sufficiently firm adhesions will have been caused to permit the opening of the gall-bladder, which should

be done in the same manner and be treated in all respects as the similar step in the second method of procedure. 2. After hemorrhage is arrested, divide the peritoneum cautiously, catching its free borders by forceps, which are then allowed to rest on the surface of the abdomen. If the wall of the tumor be not adherent, introduce two fingers through the opening into the abdominal cavity, and even the entire hand if necessary, and examine the condition of the contiguous abdominal organs, size of the tumor, nature of its contents, etc., care being taken not to rupture it by the manipulation. If gall-stones be found in the cystic or the common ducts, they should be dislodged if practicable. If the tumor be distended with fluid, it should now be aspirated, and then held firmly in contact with the external opening, while an incision about an inch in length is made into it. Its fluid contents must be carefully excluded from contact with the peritoneal lining, and also from the raw surfaces of the incision. This can be quite satisfactorily accomplished by means of a narrow, trough-like arrangement made of tin, gutta-percha, or other suitable material to conduct the fluid beyond the wound. If the cut surfaces around the point to be opened be smeared with carbolic acid and oil, and covered with small pieces of antiseptic gauze, and the borders of the incision in the tumor be quickly grasped with forceps and held upward, any danger of unwholesome contact of the fluid will be obviated. The distended gall-bladder and its associated ducts are carefully examined, and all gall-stones are removed with forceps. The edges of the opening in the gall-bladder are now stitched to the abdominal incision, a drainage-tube is introduced, and the whole is covered by an antiseptic dressing. The resulting fistula will soon close if the common duct be not obstructed, and the parts will resume their normal functions. If the wall of the tumor be not adherent to the abdominal wall, it is recommended by some—after the evacuation of its contents—that the opening be carefully stitched and the sac returned; also that the sac be ligated at its neck and removed. It can not be said, however, that these procedures are as rational in all respects as the one more fully described.

Results.—Forty cases have been reported, of which ten were fatal. The second method anticipates the dangers of rupture and the structural changes induced by over-distention, which are offset by those of opening into the abdominal cavity; the latter, however, when done under antiseptic precautions, is rarely followed by an unfortunate result. These facts emphasize the wisdom of an early operative interference.

Cholecystectomy, or extirpation of the gall-bladder, is employed instead of cholecystotomy when, by reason of the presence of a troublesome biliary abdominal fistula, malignant disease, or tumors of the gall-bladder, the latter is rendered useless. If the opening through the

abdominal walls be the same as in cholecystotomy, and the case is found to be better adapted to cholecystectomy, the incision will then require to be extended upward sufficiently to command the neck of the sac. If, however, the latter operation be contemplated in the beginning, the abdominal incision can be made in the right hypochondrium, parallel to the lower border of the liver, and joined by a second incision running along the outer border of the right rectus muscle (Fig. 563, 3). The abdominal cavity is then to be opened, the transverse colon and small intestines pushed down by a large sponge, and the liver elevated, so as to bring the hepatic duodenal ligament into prominence. The gall-bladder is easily separated from the liver, the cystic duct exposed and ligatured in two places with carbolized silk, and severed between them, the tumor removed, and the abdominal wound closed.

This operation, like the ones preceding it, should be done with full antiseptic precautions.

Results.—Cholecystectomy has been done six times, with a death-rate of fifty per cent.

The base of the gall-bladder has sometimes been connected to an opening made in the duodenum to admit the discharge of bile into the intestine, when this had been prevented from taking place by a permanent stoppage of the common duct. Nothing definite can be said, as yet, of its adoption as a practical measure in such cases.

Laparotomy, or Abdominal Section.—This operation is employed to overcome intestinal obstructions due to various causes, such as invagination, adhesions, etc., to ligature arteries, and for the operative treatment of penetrating wounds of the abdomen. Laparotomy should be divided into two varieties: 1, the explorative operation; 2, the operation in entirety—i. e., the addition of enterotomy or enterectomy, etc., for the relief of the trouble calling for the abdominal section.

Explorative Laparotomy consists in opening the abdominal cavity, usually in the median line, sufficiently to permit the inspection and examination of its contents for the morbid condition, and to determine whether the *culs-de-sac* of the cavity contain blood or other extravasations. If nothing be found, or further operative procedure is not required, the abdominal opening is then closed.

Results.—The large number of abdominal sections performed, both in this country and abroad, with favorable results, serves to establish the belief that an explorative laparotomy, under favorable precautions, does not expose the patient to any unusual dangers.

If it be performed for intestinal obstruction, the opening can be made over the seat of obstruction; but it is better to make it in the median line below the umbilicus (Fig. 563, 4). It should be a free incision, and of sufficient size to permit the easy introduction of the hand, and should be made under strict antiseptic precautions. If any

difficulty be experienced in locating the seat of the trouble, or overcoming it, the opening should be still further enlarged. Care must be taken not to tear or injure the intestine. It is better, if the obstruction does not yield readily, to raise the obstructed portion out of the opening, and surround it, along with such of the intestines as may escape, with the Lister gauze, wet in a warm antiseptic solution, or with large flat sponges treated in the same manner. As soon as the obstruction is relieved and the intestines are restored to their normal position, the abdominal cavity is cleaned by warm antiseptic sponges, and the external wound closed.

Results.—The rate of mortality in all cases of this character is about sixty-five per cent. The prognosis would be much better were it not that the diagnosis is uncertain, or the operation objected to, until the condition of the patient almost precludes a successful issue.

Enterotomy consists in opening the intestine above or at the point of an obstruction, and, when the opening is low down, it may be attached by its borders to the abdominal walls, thereby establishing a fecal fistula.

This operation can also be done when the gut is gangrenous or otherwise unfit to be returned. At the present time, in both of these conditions, it is thought to be proper by some authorities to relieve the obstruction by means of abdominal section, followed by enterectomy or enteroraphy, and return the intestine into the abdominal cavity. The final percentage of recoveries, however, is much greater if a fecal fistula is established at first, which can afterward be closed by the usual method or by enterectomy.

This particular form of enterotomy is commonly performed in the right iliac fossa, since the intestines above the obstruction lie principally in this situation. The intestines above the obstruction are filled; those below are empty; consequently the selection of the proper one to open becomes easy on inspection.

In "*Right Inguinal Enterotomy*" (Nélaton), as this operation is sometimes called, an incision is made an inch above Poupart's ligament and parallel with it, beginning at the anterior superior spine of the ilium and ending opposite the internal abdominal ring (Fig. 563, 5). The layers of the abdominal walls are divided consecutively on a director, down to the peritoneum, which is opened, after all hemorrhage has ceased, for one inch and a half. The first intestinal loop presenting is drawn through, provided it be not an empty one; a long thread is passed through the muscular walls and looped, and the intestine again returned and kept from the opening by a small-sized carbolized sponge, to which a string is attached; this is forced through the opening and allowed to remain, while the peritoneum is drawn outward and stitched to the integument. The sponge is then removed, and the intestine pulled out by the looped ligature which has

remained upon the abdominal wall. The coats of the intestine are carefully united to the walls of the opening by a deep row of interrupted carbolized silk or catgut sutures passed in the transverse axis of the gut, through its serous and muscular coats, being entered two or three lines from the border of the integumentary wound, and, after including the gut, returned through the same border of the wound from below upward, and tied. After the serous surfaces are accurately apposed by a row of stitches, the intestine is raised to a level with the surface of the abdomen, and the space between it and the border of the abdominal wound is packed with absorbent cotton or lint saturated with carbolic acid and oil for the purpose of protecting their surfaces from contact with any of the intestinal contents. The gut is opened longitudinally for one inch, its edges being caught with pinccrs as fast as cut. After the intestinal contents near the opening are evacuated, a small sponge with a string attached should be pressed into the opening in the gut to prevent any further escape while its borders are being carefully sewed to the integumentary margin by the continuous or interrupted suture.

The immediate results of this operation are better than those of laparotomy in entirety, but the patient is subjected thereafter to the annoyance of a fecal fistula. If the obstruction be due to a foreign body in the gut, and its position be located, the intestine can be incised, obstruction removed, wound of the intestine closed by the Lembert or other suture, the gut returned, and the abdominal incision closed.

Enterectomy consists in removing a segment of intestine and uniting the divided extremities, which, when combined with abdominal section, constitutes a laparotomy in entirety. Enterectomy is performed for penetrating shot and stab wounds of the intestine, and for the removal of malignant growths and gangrenous portions of the same. The antiseptic precautions relating to the operator, to the patient, and to the surgical surroundings should be of the most complete kind, and, in addition thereto, the patient and the abdominal viscera should be kept warm and the latter moist. Warmth and moisture can be secured by operating in a thoroughly purified room, charged with antiseptic vapor, and having a temperature of 98° to 100° Fahr. The warmth of the abdominal viscera can be quite well maintained if they be surrounded by large, flat sponges or antiseptic gauze moistened in warm solutions of mercuric bichloride (1-10,000), carbolic acid (1-100), or Theirsch's fluid. If blood or intestinal contents escape into the abdominal cavity, the site of the injury causing it must be sought for and closed. All bleeding points should be tied with fine catgut, no matter how insignificant the bleeding may seem at the time; for after the parts are returned into the abdominal cavity, and their normal relations and tempera-

ture have been restored, a trivial oozing may become a serious hemorrhage. All wounds of the intestine, at other than its mesenteric attachment, may be closed by the continuous suture of Lembert, or by the Gély suture. Catgut or antiseptic silk may be used for this purpose. A double row of sutures may be deposited, provided, however, the closure does not reduce the caliber of the intestine more than one third. If the wounds be too large or too closely associated to admit of closure, or if they be at the mesenteric border of the gut, enterectomy or removal of the injured portion should be done. The contents of the portion to be removed should be pressed out into the uninjured portion of intestine, and its return prevented by the intestinal pincers (Fig. 567), by the fingers of an assistant, or by strips of iodoformized gauze tied loosely around the gut. The incisions for the removal of the injured portions should be made as closely as possible to the incoming mesenteric arteries, so that the extremities of intestine will be well nourished. The mesentery may be treated by one of the following methods: 1. A triangular portion of it may be removed, its base corresponding to the length of the portion of intestine excised, after which the gap is closed by bringing the divided borders of the mesentery together and uniting them. 2. It may be tied in small segments, about a quarter of an inch from the intestine, with catgut, divided and allowed to remain free, or may be sewed to the mesenteric border of the gut after it has been repaired. 3. The serous coat for a quarter of an inch each side of the mesenteric attachment may be divided and stripped from the subjacent tissue, intestine excised, ends approximated, and the loop formed by the serous slip closed by sutures. During the sewing the ends of the intestine may be held by the fingers of an assistant or by introducing a small, distended rubber bag. Pieces of stale bread may be made of a size to support the ends during the sewing. The rubber bag should be removed before the intestine is entirely closed, and care must be taken or it will be sewed in position. The bread or large macaroni tubes will escape from the natural opening. It is difficult to manage these extremities and at the same time properly coapt the borders and deposit the sutures so that effective and permanent union will be secured, since the point above the obstruction will be distended by air and fecal accumulation, while the portion below will be collapsed and appear smaller than normal. The mobility of the extremities, the danger of the escape of fecal matter, together with hemorrhage, and the length of time necessary to triumph over the obstacles already enumerated, bring about a degree of exposure which adds more to the gravity of the operation than the division and removal of the diseased tissue. Anything, therefore, which will expedite matters in this respect must constitute a real advance in surgery. The instrument devised by Mr. Treves, of London (Fig. 569), is certainly in-

genious, but does not seem to be sufficiently simple to become of practical utility. It can not be better described than in Mr. Treves' own language: "The apparatus consists in the first place of two

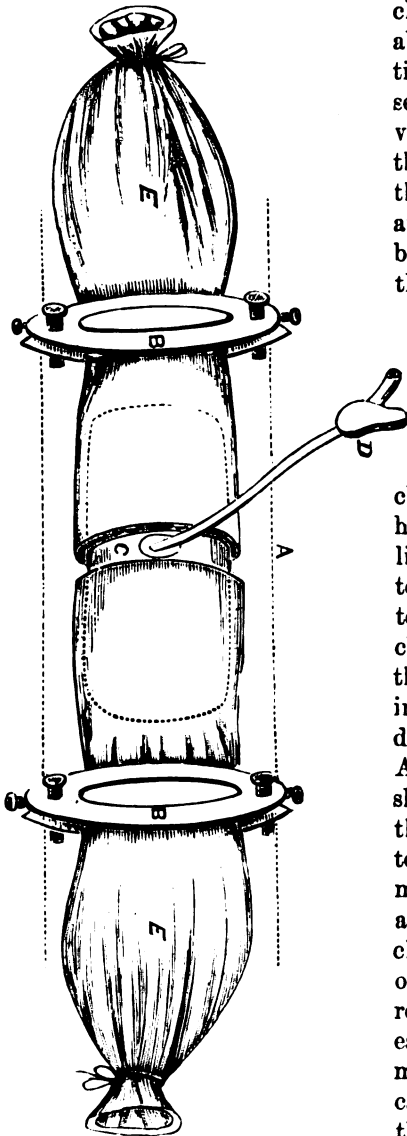


FIG. 569.—Treves' apparatus for enterectomy.

clamps, B B, to secure the gut, E E, above and below the point of resection. Each clamp is made of two separate and light metal bars, provided with an India-rubber pad on the surfaces that are in contact with the gut. The clamp is two inches and a half in length, and, one part being placed beneath the gut and the other upon it, the two are then approximated by screws placed at each end. By these means the gut can be evenly and accurately compressed with as much or as little force as may be thought fit. I first apply a

clamp to the gut one inch and a half below the proposed resection-line, and, having emptied the part to be excised by squeezing its contents upward, I apply the second clamp at a similar distance beyond the second resection-line, which will, in most cases, insure an empty condition of the part to be removed. A triangular piece of mesentery should then be excised, the base of the triangle exactly corresponding to the amount of gut to be removed; secure the divided vessels and excise the diseased gut. The clamps are now united with each other by means of the long, narrow reel-rods, A A, which are secured to each clamp by a small screw. By means of these bars the two clamps can be evenly approximated, and the divided ends of the gut brought into accurate contact. If the screws be now tightened, the bowel extremities are held in a rigid frame, and can be turned or moved in any

direction without disturbing the contact of the divided ends. The

ends to be united will be easily commanded if a very thin India-rubber bag, G, about three inches in length, of sausage-shape, that can be distended by air to a large size, be inserted about the middle of its long axis. Having blown out this bag till it was about the size of the divided bowel, I inserted one end into the lower piece of the intestine and the other end into the upper piece. The supply-tube, D, will thus occupy the suture-line. After the bag is suitably distended the sutures are applied all round the gut, and almost up to the interruption in the suture-line occupied by the tube that fills the bag. The last sutures are then applied, but not tied, the bag exhausted of air and withdrawn from the bowel through the interruption in the suture-line." Two rows of sutures should be used—the first an interrupted Lembert of iron-dyed silk, extending to the mucous membrane; second, the continuous Lembert, including the serous surfaces only. The Czerny-Lembert is entirely suitable for this purpose. Great care is requisite to properly close the mesenteric border of the intestine. A small artery is found here that often bleeds persistently. The entire intestinal tract should be carefully examined for other injuries, even though it be necessary to remove the intestines from the cavity to do it. Severe intestinal contusions should be treated like penetrating wounds of the intestine. The "toilet" of the abdominal cavity must be patiently and thoroughly performed by soft, moist, antiseptic sponges. It is not enough to wipe off the intestines only, but all the *culs-de-sac* must be examined, and all blood and other extravasations, together with antiseptic fluids found therein, should be sponged out and drainage provided if deleterious discharges appear likely to be produced. The abdominal wound is dressed antiseptically.

Results.—The general result shows a death-rate of about fifty per cent. This is very satisfactory, when it is considered that over ninety per cent of penetrating shot-wounds of the abdomen die when treated expectantly. When this operation is done for causes that do not involve extravasation into the abdominal cavity, the death-rate is much diminished. It is not advisable to excise the intestine for malignant disease if the mesenteric glands be much involved, since an artificial anus can then be made with better prospects of prolonging life.

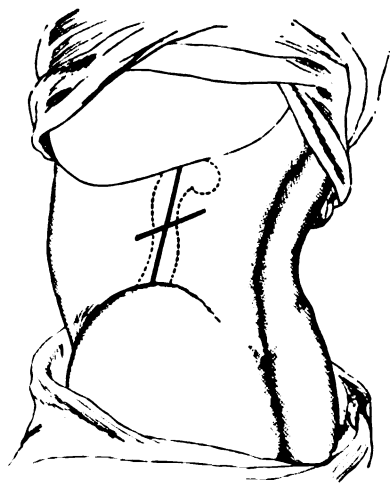

FIG. 570.—Guide to colon.

Left Lumbar Colotomy (Amussat).—In this operation the descending colon is opened between the crest of the ilium and the last rib.

Linear Guide to the Operation (Fig. 570).—Draw a line which shall connect the anterior and posterior superior spinous processes of the ilium; draw a second line perpendicular to this, one inch posterior to its center. This line marks the course of the colon. Draw a third line four inches in length obliquely downward and outward, midway between the lower border of the last rib and the crest of the ilium, its center corresponding to the perpendicular one, parallel with the lower border of the last rib. The third line marks the course of the incision, half of which is behind the perpendicular line.

Muscular Guides.—The outer border of the erector spinæ, also the outer border and anterior surface of the quadratus lumborum.

Contiguous Anatomy.—The colon at this situation is covered by peritoneum at its anterior surface and sides; its posterior internal surface is not covered by this membrane. If the gut be collapsed, it retreats toward the median line, behind the quadratus lumborum, and is followed by its peritoneal covering. The collapsed condition of the gut, therefore, exposes the peritoneum to greater danger of being injured. When distended, it presses its peritoneum outward, and can be readily seen projecting beyond the outer border of the quadratus lumborum. The surfaces not covered by peritoneum are surrounded by areolar tissue, which separates the intestine from the left crus of the diaphragm, the left kidney, and anterior surface of the quadratus lumborum; and externally it is in contact with the small intestines. The left kidney is situated posteriorly to it, and its lower extremity can be easily felt at the upper border of the wound. The vessels lying in the course of the incision are the abdominal branches of the lumbar vessels. The ilio-hypogastric and ilio-inguinal nerves likewise cross in front of the quadratus lumborum at this situation.

The colon is recognized by its greenish color and its longitudinal bands, which are three in number—one anteriorly, which is covered by peritoneum, a second corresponding to its attachment, the third or lateral at its inner side. It is not quiet during respiration, although it does not move upward and downward as the small intestines are sure to do. It can not be raised, while the small intestines can. Finally, if it be filled with air after the fascia lumborum is divided, and the fat be pushed aside, it will become distended quickly and assume a proportionately greater size than the small intestines.

Fallacies.—The colon may be mistaken for a loop of small intestine, also for the kidney, especially in the young subject. From the former it is readily distinguished by the differences already given; from the latter, by the density of the structure of the kidney, its rounded extremities, reniform shape, lobulated appearance, and the upward and downward movements of the kidney with the respiratory

acts. If the preceding be not satisfactory, the introduction of a hypodermic needle will demonstrate not only the density of the kidney, but the absence of fecal matter and offensive gases.

If the conditions will permit, the bowel should be thoroughly washed out before the operation is begun; after which the patient is etherized and placed on the right side, with a hard pillow under the loin, so that the left side may be made more prominent.

Operation.—An incision is made in the course of the line already marked out, and carried through the integument, fascia, and thick layer of fat usually found at this situation, down to and through the latissimus dorsi muscle and the posterior fibers of the external oblique, the internal oblique, and transversalis, which are divided upon a director, bringing into view (Fig. 571) the outer portion of the quad-

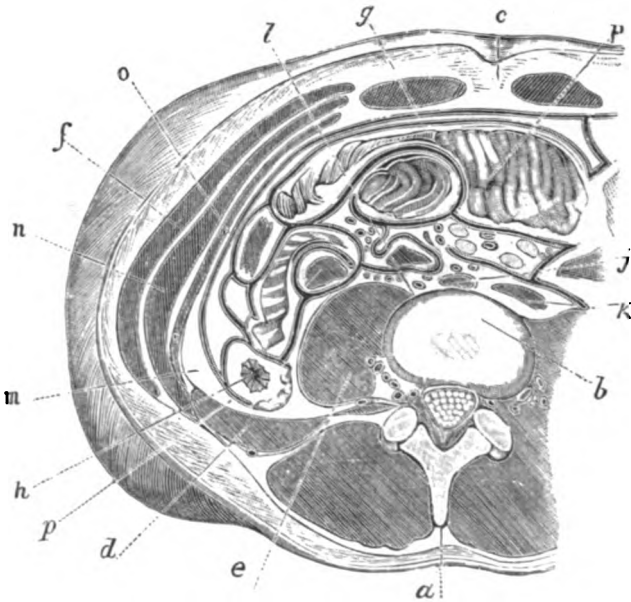


FIG. 571.—Surgical relations of descending colon. *a.* spine of fourth lumbar vertebra. *b.* Cartilage between third and fourth vertebrae. *c.* Umbilicus. *d.* Quadratus lumborum m. *e.* Psoas magnus m. *f.* External oblique m. *g.* Rectus muscle. *h.* Descending colon, covered anteriorly and externally by peritoneum. *i.* Transverse colon. *j.* Aorta. *k.* Inf. vena cava. *l.* Ureter. *m.* Adipose tissue covered by the transversalis fascia. *n.* Internal oblique muscle. *o.* Transversalis m. *p.* Reflection of peritoneum.

ratus lumborum inclosed within its compartment of the lumbar aponeurosis, which extends outward to become continuous with the transversalis muscle. The aponeurosis is carefully divided upon a director, and the fascia transversalis that lies beneath it is divided in a similar manner, thus bringing into view the fatty areolar tissue that separates the gut from the quadratus lumborum and the left crus of the dia-

phragm. The fat is pushed aside by the finger and handle of the scalpel, and the bowel distended with air, when its situation will become positive. By the means already given, confirm its identity before proceeding further. As soon as the gut is distended it will appear at the opening, and perhaps even rise above its level; roll it outward with the finger from beneath the quadratus, cutting the outer border of the muscle, if necessary, so as to reveal its inner aspect, which is known by the longitudinal band; seize it with a tenaculum or forceps, and hold it upward while a stout, curved needle, armed with a well-carbolized silk ligature, is passed deeply through the skin and deeper tissues at one side of the perpendicular incision, about four lines from the border, into and transversely through the intestine, to emerge on the other side of the opening at a similar distance from

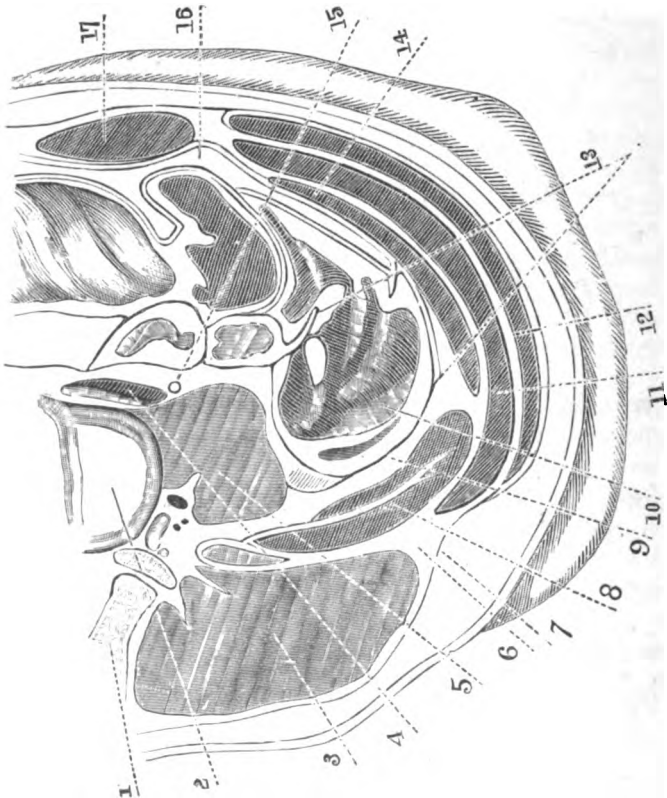


FIG. 572.—Surgical relations of ascending colon. 1. Spinous process of fourth lumbar vertebra. 2. Cartilage between third and fourth vertebræ. 3. Erector spinæ m. 4. Inferior vena cava. 5. Psoas magnus m. 6. Fascia lumborum. 7. Subcutaneous fat and latissimus dorsi m. 8. Quadratus lumborum m. 9. Adipose tissue covered by the transversalis fascia. 10. Cavity and wall of the ascending colon. 11. Internal oblique m. 12. External oblique m. 13. Limits of peritoneal reflection. 14. Transversalis m. 15. Ureter. 16. Great omentum. 17. Rectus muscle.

the border of the wound ; this suture is drawn through, and each end given to an assistant. The needle is then passed in a similar manner at the opposite extremity of the incision, and its ends are also given to an assistant (Fig. 573). All the space between the walls of the gut and borders of the wound is then packed with lint saturated with carbolic acid and oil. The gut is opened by a longitudinal or oblique incision, about an inch and a half long (Fig. 574). The liability to a



FIG. 573.—Sutures passed through colon.

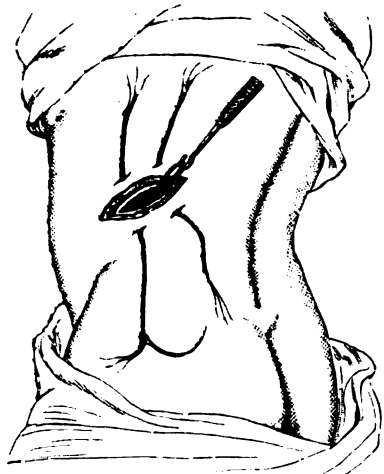

FIG. 574.—Hooking up sutures.

subsequent protrusion of the mucous membrane and of injury to the peritoneum at the time is less with a longitudinal than with a transverse incision. After the contents of the bowel are evacuated, a sponge, with a string attached, should be pressed into the opening to retain any remaining discharge until the edges of the gut have been stitched to the borders of the wound. The finger or hook should now be inserted into the bowel, and the loops of the ligature just passed be caught, drawn out (Fig. 574), and divided at the middle, when each one will become two distinct sutures which, after the oiled lint has been removed and the wound cleansed, can be tied (Fig. 575). The re-

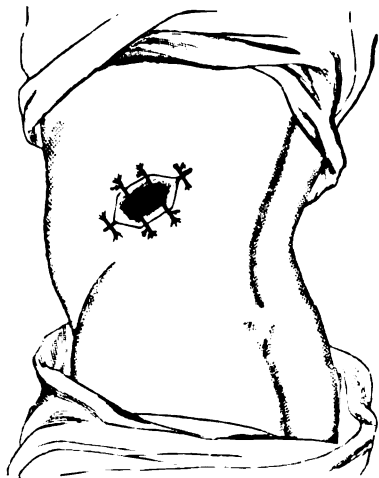

FIG. 575.—Sutures tied.

maining portion of the gut-wound is then stitched, sprinkled with iodoform (Fig. 576), and a carbolized pad is bound over the opening. This pad, together with the sponge, must soon be removed to allow the escape of fecal matter. If malignant disease of the rectum be the cause for the operation, it is recommended to bring the intestine through the opening as far as possible, divide it, turn in the borders of the upper extremity of the lower portion, sew them together, and drop it into the abdominal cavity. This plan will prevent any fecal matter from passing down the rectum and irritating the malignant growth. The upper opening is then carefully sewed to the borders of the abdominal wound. Great caution

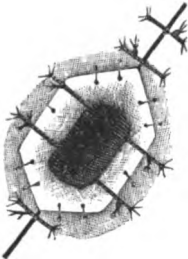


FIG. 576.—Wound stitched.

is necessary in taking these steps, or the peritoneal covering of the colon will be torn through. If this accident should happen, close the peritoneal opening with catgut sutures. Inflammatory products, and even fecal matter, may collect below if great care be not observed.

Results.—The rate of mortality from this operation is variously estimated, being from twenty to thirty-eight per cent. Recently Dr. Bott reported two hundred and forty-four cases, with a death-rate of a little more than thirty-one and one half per cent.

Right Lumbar Colotomy.—In this operation the incision is made at the right side. Its formation, however, is in all respects governed by the same rules as the preceding. The caput coli is the portion to be opened, and, owing to its size, can be more readily distinguished than the colon on the left side of the body (Fig. 572).

The results are much less favorable, owing partly to the loss of the function of the colon, and also to the more objectionable location of the disease compelling the operation in this situation.

Left Inguinal Colotomy (Littre).—This operation consists in opening into the sigmoid flexure of the colon by an incision into the left iliac fossa through the abdominal walls, including the peritoneum.

Linear Guide to the Operation.—Draw a line two inches in length over the left iliac fossa, commencing about an inch internally to the anterior superior spine of the ilium, and extending downward parallel with Poupart's ligament (Fig. 563, 6).

Operation.—The patient is placed upon his back, and an incision made to correspond to the line given above. All hemorrhage is stopped before the peritoneum is opened. As soon as the peritoneum is cut, insert a small antiseptic sponge connected with a string, which will prevent the escape of the intestines; stitch the peritoneum to the integumentary border; withdraw the sponge, and draw out the intestine which is located directly under the opening, and which can be recognized by the peculiarly shaped fatty fringe attached to it. This

is then stitched to the external wound in the same manner as in the lumbar region. In all respects the treatment is the same as for colotomy in other situations.

Results.—Left inguinal colotomy is not as safe an operation as that in the left lumbar region, since the peritoneum is directly involved.

The rate of mortality is from ten to twenty per cent greater.

Abscess in the Right Iliac Fossa.—This abscess may be superficially or deeply seated. If it be of the former character, it can be opened readily.

Operation.—If the development of a deep-seated abscess be suspected, aspiration should be frequently performed to detect the earliest existence of pus. If pus be found, make an incision four or six inches in length, commencing an inch internal to and above the anterior superior spinous process of the ilium, and extending downward parallel with Poupart's ligament; divide cautiously the various layers of the abdominal wall on a director, and, when the abscess wall is reached, insert an aspirating-needle again as a precautionary measure; open the cavity freely in the course taken by the needle; wash it thoroughly, insert a drainage-tube, and allow it to heal from the bottom.

If pus be not present, the incision may be made, if expedient, and the wound allowed to remain open, when, if pus form, its discharge can be readily effected.

Results.—This operation is to be earnestly commended to the attention of all practitioners of medicine and surgery. The association of typhlitis with abscess located in this situation, and the great danger to the patient from a rupture into the abdominal cavity, emphasize the necessity of an early diagnosis and a thorough treatment. The prognosis is flattering when active measures are early and promptly taken.

Artificial Anus, or Fecal Fistula.—When the distal extremity of the bowel is pervious and the fistula has served its purpose, it should be closed. If the septum between the openings be shallow and yielding, it can be forced back by means of a sponge pressed against it and confined in position; wooden plugs and lint are employed in a similar manner; failing in this, the septum should be grasped by a clamp or enterotome (Fig. 577), passed into the opening on either side of it, and the blades firmly screwed together. In a few days the constricted portion sloughs, and the instrument is released. The external opening usually closes spontaneously; if not, a plastic operation may become necessary. If these methods fail, the affection

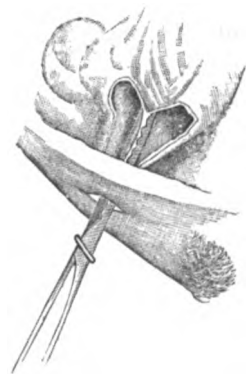

FIG. 577.—Enterotome applied.

may be cured by enterectomy, as was practiced by Kinloch, of South Carolina, in 1863.

OPERATIONS ON THE KIDNEYS.

The surgery of the kidney has made rapid strides within the last few years. The accepted operations on this organ are nephrotomy, nephrectomy, nephro-lithotomy, and nephroraphy or fixation of a movable kidney.

Nephrotomy.—Nephrotomy consists in opening into the kidney through an incision in the lumbar region. The operation should be preceded by the introduction of an aspirating needle, both to locate and define the nature of the tumor.

Operation.—The patient is placed in the same position as in lumbar colotomy. The incision is made in the same direction; and in other respects its location is similar, although it is often made nearer to the last rib than in colotomy. A vertical incision, just outside the quadratus lumborum, extending from a point immediately below the last rib four or five inches downward, is preferred by some. The same precautions preparatory to and attending the operation are required that characterize colotomy, and the tissues resting upon the tumor are divided in the same manner. When the sac is reached it should be aspirated to confirm the diagnosis. An opening is then made into it, the contents evacuated, and the cavity washed out with a solution of the bichloride of mercury, 1 part to 2,000 of water. Carbolic solutions should be avoided, since carbolic-acid poisoning seems more likely to occur from its use in this situation than elsewhere.

Remove all calculi that may be present, and unite the edges of the kidney to the wound, and allow it to heal by granulation; or a drainage-tube is inserted and the external opening is closed by deep sutures, and dressed antiseptically.

If the kidney structure be destroyed, or be the seat of malignant disease, it is then wise to remove the entire organ.

Results.—Nephrotomy has been practiced, for various causes, nearly one hundred and twenty-five times, with an average mortality of about twenty per cent. The death-rate after operations for calculous pyelitis was about forty-three per cent, but for other causes in no case did it reach eighteen per cent.

Nephrectomy.—Nephrectomy consists in removing the kidney in part, or entirely, from the body. The removal is indicated in cases of a wounded or painful floating kidney, cystic kidney, hydro-nephrosis, pyelitis, with or without calculi, neoplasm, and urinary fistula from a communication with the ureter. Before the operation is performed, it should be ascertained, if possible, whether the other kidney is present, and in a healthy condition.

The primary incision may be made in the loin or through the abdominal walls; which is the better one is a matter as yet unsettled. The character of the case will have much to do in determining this point. If the tumor be movable, malignant, of large size and adherent, or if it be suspected that the disease be bilateral, the abdominal incision is preferred, since it admits of the examination of the other kidney.

The rate of mortality, however, favors the lumbar incision.

Lumbar Nephrectomy is to be done with every possible antiseptic precaution. The primary incision is made usually in the same situation and direction as in nephrotomy, although the vertical one, in large tumors, is highly commended. If the space will permit, the tumor is isolated, and its pedicle tied *en masse*, or, what is better, the vessels are secured separately. The ureter must always be tied, and the lower extremity brought through the external opening. It often happens that the size of the tumor and its adhesions to surrounding tissues require the opening to be enlarged. This can be done by extending it toward the spine as well as in the opposite direction. If the opening, when taken in conjunction with the additional space to be gained by pushing upward the last rib, be inadequate, the rib can be resected subperiosteally for three or four inches, and this will be found to afford quite sufficient room.

After the removal of the tumor, the wound should be thoroughly disinfected with a solution of carbolic acid or other suitable substance; ureter secured externally, and the opening closed by deep sutures, and dressed antiseptically.

Abdominal Nephrectomy.—In abdominal nephrectomy the opening into the abdominal cavity can be made in three situations: 1, the most frequent situation is through the linea alba; 2, at the outer side of the rectus (linea semilunaris); 3, in the inguinal region. The first two require that the peritoneum be divided; the last admits of a subperitoneal removal, but can scarcely be employed except in well-marked cases of movable kidney. In either case the abdominal opening is made in the usual cautious manner, about six or eight inches in length, and larger if the size of the tumor demand it. The hand is introduced, tumor located and outlined, and the condition of the other kidney noted. The diseased organ is then enucleated and raised through the opening, its vessels and the ureter are tied separately with strong carbonized ligatures, and are cut short, and returned. The opening remaining in the peritoneum after the removal of the kidney can be closed after all hemorrhage has ceased by uniting its divided borders with fine catgut. The abdominal cavity is then cleansed of all foreign matter, and its walls united and dressed antiseptically. If the ureter is to be returned into the cavity of the abdomen, its extremity should be thoroughly asepticated with the carbolic acid, or the bichloride of

mercury solution. It is considered better, however, to attach it to the abdominal opening. It is recommended to tie the vessels of the pedicle before commencing the enucleation, thus lessening the danger of hemorrhage. The advantages of an opening outside of the rectus are said to be, less hemorrhage from the abdominal walls than when the opening is made through the linea alba; also, it brings the surgeon more directly on the tumor, its pedicle, and the ureter. If the space from which the tumor has been removed be a large one and show a strong tendency to bloody oozing from the surface, the perforated glass drainage-tube should be introduced, carried directly to the bottom, and allowed to protrude through the abdominal incision. The fluid which accumulates in the tube can be removed by carbolized sponges under the antiseptic spray. Drainage may also be provided by passing a small drainage-tube through the abdominal wall in the lumbar region, communicating with the former site of the diseased organ; then the posterior peritoneal incision should be closed.

It is impossible to lay down more than the general means of procedure in this operation, since the conditions surrounding individual cases often call for the employment of other than stereotyped rules.

Results.—Of two hundred and thirty-three nephrectomies collated by Prof. S. W. Gross, about forty-five per cent died. The mortality from the lumbar incision was forty per cent, that from the abdominal incision about fourteen per cent greater. Shock was the cause of death in forty per cent of the entire number operated upon.

Nephro-lithotomy, or renal lithotomy, is the exploration of the pelvis of the kidney with a long needle, to ascertain the presence of calculi within it. If calculi be present, they are removed with forceps, through an incision made into the kidney.

Operation.—The external opening is made similar to that for lumbar nephrotomy; the kidney is exposed, calculus detected, and an incision is made through the cortex into the pelvis in the long axis of the kidney of sufficient size to remove it with suitable forceps. The hemorrhage resulting from the division of the kidney structure is quite severe at first, but is quickly controlled by pressure. The wound in the kidney usually heals readily; nevertheless, urine will sometimes escape through it for ten or twelve days. With a view to cause union of its structure, the lips of the kidney-wound have been united by fine catgut sutures with favorable results. The external wound is suitably drained, closed, dressed antiseptically, and the patient given demulcent drinks.

Results.—All of the reported cases (six) of this operation have terminated favorably.

Nephrorraphy (*Fixation of a Floating Kidney*).—To accomplish this purpose in cases where all ordinary means have failed, an incision is made from a little below the lower rib to the crest of the ilium,

along the outer border of the erector spinæ, and down to the quadratus lumborum. The same tissues are encountered in this as in the vertical incision of nephrotomy. There is a greater danger of hemorrhage, however, than from the oblique incision, as the vertical incision is made at nearly right angles to the lumbar vessels. As soon as the fascia lumborum is divided, the kidney should be pushed into the wound, the fascia transversalis slit up, the fatty capsule surrounding the kidney opened longitudinally, and its borders stitched to the deep structures of the wound with eight or ten catgut or carbolized silk sutures. The wound is then stuffed with carbolized gauze and allowed to heal from the bottom; the patient remaining in the dorsal position until the healing is well completed; after which, any of the various forms of pads or other retentive apparatus may be applied to retain it until the adhesions are thoroughly established.

Results.—Nephrorraphy has been performed eighteen times, with one death. In about forty-four per cent of the cases but little or no relief was gained. Forty-one per cent die from nephrectomy for this condition.

The subsequent giving way of the fixation point under the influence of movement, suggests the practicability of continuously wearing some form of retentive apparatus.

Splenectomy, which consists in the removal of the spleen, has been performed between thirty-five and forty times. It has not proved successful, however, in any instance when practiced for leucocythemia. When employed for displacement or simple hypertrophy, the results are flattering, being in excess of fifty per cent.

Operation.—An incision about eight inches in length is made at the outside of the rectus or in the median line, its center corresponding to the umbilicus; the peritoneal cavity is opened in the usual manner, the omentum and intestines displaced, and the tumor carefully raised through the opening; after which the vessels at the hilum, and those of the gastro-splenic omentum, are clamped and tied. This omentum should be divided into several sections by transfixion, and each section should be tied by two ligatures and divided between them. All hemorrhage is stopped, and the abdominal wound closed either with or without a drainage-tube, depending on the amount of prospective oozing.

The spleen must be handled very carefully during the removal, or it may be ruptured.

Paracentesis Abdominis.—This procedure is an operation employed to remove fluids from the abdominal cavity. The instruments necessary are the scalpel and the trocar, Fig. 578 being an admirable example of the latter. Fig. 579 represents the ordinary form, which will meet all common indications.

The aspirator (Fig. 580) is cheap, durable, and efficient. The

handy aspirator of Fitch (581) is not expensive, and can be used in conjunction with the canula figured above. In either case the caliber




FIG. 578.—Wood-Harris trocar.

FIG. 579.—Trocar and canula.

FIG. 580.—Potain's aspirator.

of the canula should be small enough to admit of the gradual discharge of the fluid, for if it be discharged too rapidly the danger of syncope will be imminent. If the canula be sharp-pointed, it can be introduced without the aid of the scalpel, after the presence of the fluid has been determined by the aid of the hypodermic syringe.

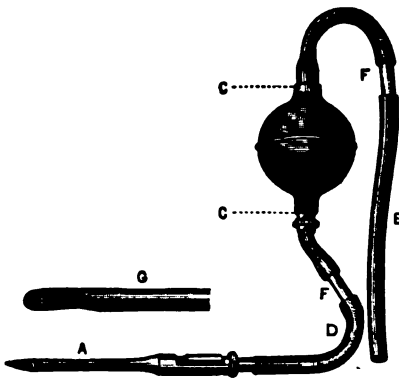


FIG. 581.—Fitch's aspirator.

An anæsthetic is not necessary. A local injection of a solution of cocaine will suffice to relieve all pain caused by the introduction of the needle. The

bladder and rectum should be emptied, and the abdomen carefully percussed to determine the limits of dullness. The belly is then surrounded by a broad, many-tailed bandage, having a small opening in the center corresponding to the point of proposed puncture. If unable to sit up, the patient is placed upon his side near to the edge of the bed, but if his strength will permit, he can be placed in an ordinary chair, with the body bent forward, and the head and arms resting upon the back of another chair in front.

Operation.—The instrument is seized firmly with the index-finger resting on its upper surface (Fig. 582) to limit the extent of its introduction, and is plunged quickly through the wall of the abdomen in the median line, midway between the umbilicus and pubes, and the trocar is withdrawn. As the fluid escapes, the bandage



FIG. 582.—Introducing trocar.

is tightened to facilitate the flow, as well as to support the patient. The flow is permitted to continue until the fluid is removed, unless the patient is threatened with syncope, when the trocar is withdrawn at once. The puncture should be closed by a strip of adhesive plaster, or, better, by a hare-lip pin, confined in the usual manner; the tails of the compressing bandages are then tied firmly to maintain the pressure. Care is taken that no air be permitted to enter the cavity of the abdomen.

Fallacies.—A distended uterus or bladder, or a displaced or enlarged liver, may be punctured.

If the canula be sharp-pointed, the intestines may be injured during the withdrawal of the liquid. A blood-vessel of the abdominal walls may be injured by its introduction. If the uterus be distended from any cause, the puncture can be made through the right or left semilunaris or above the limit of the distention.

OPERATIONS APPLICABLE TO THE VARIOUS CONDITIONS OF ABDOMINAL HERNIA.

The operations on the various forms of herniæ that are amenable to operative procedures are: for the reducible hernia, an operation for a radical cure; for the strangulated, taxis, and division of the

constriction ; for the simple irreducible and obstructive forms, the liberation of their contents, and their return to the proper situation.

A **hernia** may be defined to be the protrusion of a portion of the contents of the abdomen through any opening in its walls. Each protrusion is composed of a sac and its contents, surrounded by more or less of the tissues composing the abdominal walls. With but few exceptions all herniæ possess a sac, and this sac, in every case, is composed of the parietal peritoneum (Fig. 583). Only those viscera, such

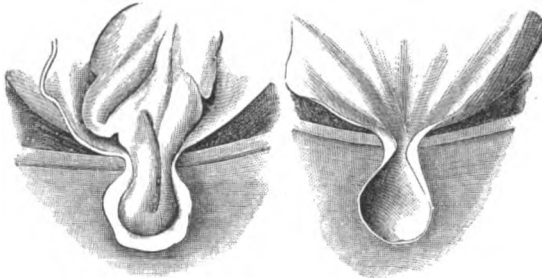


FIG. 583.—Sac of a hernia. FIG. 584.—Sac and contents.

as the caput coil, colon, bladder, pancreas, etc., which are not normally surrounded by this membrane, can form a hernia without a sac. The contents of a hernial sac, in the ordinary sense of the term, then consist of the small

intestine and omentum, either singly or conjointly (Fig. 584). If the larger viscera escape, it will be exceptional, and probably depend upon an abdominal wound. Such a condition is then called a protrusion of this or that organ rather than a hernia of the same. The normal appearance of the omentum and small intestines should be given a careful study, that the operator may be able to determine the various degrees of change in their appearance when subjected to the different influences associated with hernial protrusions. The granular appearance of the omental fat, together with its pale color and extra fibrous structure, will distinguish it from the subserous tissue fat. The omentum and gut, while in the sac, usually bear the same comparative relation to each other as in the abdominal cavity, the former being in front. The sac has a neck and a body ; the shape and size of the latter depend upon the amount and density of the surrounding tissues and the nature and compactness of its contents. The neck is its constricted portion, and corresponds to the opening through which it escaped ; its size is governed by the density of the tissues by which it is surrounded, the age of the protrusion, degree of traction, and compressibility of its contents. A knowledge of the normal characteristics of the peritoneum is as essential to the surgeon as is a knowledge of the peculiarities of the contents of the sac. Its rough outer and smooth inner surfaces, the arrangement of its vessels, and its transparency should be understood. It must not be forgotten, however, that the physical appearance of the sac and its

contents become changed when long subjected to the vicissitudes attending hernial protrusions.

The tissues composing the walls of the protrusion, or the "coverings of hernia," vary according to its situation, rapidity of development, and size. While they may readily be distinguished in their proper places as component parts of the abdominal wall, yet, when stretched around the body of a hernia and more or less changed from the effects of pressure and extraneous influences, their identity often becomes difficult of recognition.

In a recent hernia the cellular tissues and fat will vary but little from their normal conditions; in an old one, these tissues will be much thinner than usual. In a recent protrusion the muscular fibers of the cremaster will be exceedingly sparse and illy developed, while in the older ones the influence of the coincident traction will lead to their becoming well developed and of great diagnostic importance, not only as to the depth of the incision, but the variety of the protrusion. The transparent sac often becomes more or less opaque, and so connected with the cellular tissue upon it as to be scarcely distinguishable from it.

It can be safely said that the changes in the appearance and the anatomical relations of the component parts of a hernia, and the influences and processes to which it is subjected, may be so manifold that it will present as varied and perplexing problems, requiring a speedy solution, as any morbid condition of the body.

Prior to attempting any form of operation upon a hernia, it is necessary that the surgeon be acquainted with the important blood-vessels and their relation to the body, and more especially the neck of the sac. He must know the bony landmarks, the ligamentous associations, and the direction of the exit, else he will be unable to distinguish the variety of hernia or to manipulate its return.

OPERATIONS FOR RADICAL CURE.

Heaton's Operation.—This consists in injecting into the inguinal canal with a syringe, constructed for the purpose, ten or fifteen drops of a mixture, composed of one half an ounce of Thayer's fluid extract of quercus alba, prepared *in vacuo*, and fourteen grains of the solid extract of quercus alba. Triturate with gentle heat until the solution is as perfect as possible. A grain of morphia to the ounce can be added to alleviate the pain caused by the injected fluid.

The patient is placed on the back, contents of the sac returned, and if necessary retained by the finger of an assistant. Locate the external abdominal ring with the right forefinger passed upward and outward, invaginating the scrotum; press the left forefinger perpendicularly upon the integument over the ring, using sufficient force to press the integument together with the finger directly into the ring,

thus leaving nothing between it and the external pillar but the integument and subjacent fascia. The syringe, already charged, is taken in the right hand, and quickly introduced through the integument and fascia into the inguinal canal, closely hugging the external pillar. The forefinger is then removed, and the needle carried carefully along the posterior surface of the aponeurosis of the external oblique, for an inch or so, when the fluid is deposited, drop by drop, in various portions of the canal, by moving the point around during its withdrawal. A small portion should be deposited at the extreme end of the canal; the intercolumnar fascia and the pillars of the external ring should be well medicated. The needle is then withdrawn, the opening sealed, compress and bandage applied, and the patient kept in the dorsal position. If undue inflammation occurs, it is to be treated in the usual manner. As a rule, the pain and tenderness will disappear in two or three days, after which the patient is to be kept quiet for ten days before attempting to walk, and then the part should have proper support, which should be continued in use for six or eight weeks, and even longer in the interest of discretion.

The results claimed for this method by its originator have not been substantiated by the trials to which it has been subjected by many careful and unprejudiced surgeons. It is, however, devoid of danger, provided the fluid be not thrown into the peritoneal cavity, and is rarely followed by suppuration. In a recent oblique hernia with a small neck it is a harmless expedient, which often affords relief. It must not be forgotten, however, that unless constant caution is observed, the protrusion may recur.

The percentage of cures and failures are about the same—thirty per cent. In the remainder the result is indifferent.

Wützer's Method.—The protruded parts are returned, and a fold of integument is pushed as far as possible into the canal with the

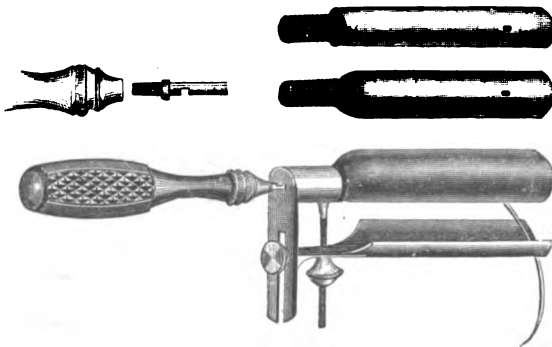


FIG. 585.—Wützer's apparatus.

index-finger of the left hand; the cylindrical portion of the instrument (Fig. 585) is well oiled and carried into the *cul-de-sac*, guided by the finger, which is slowly withdrawn as the instrument is inserted. The distal extremity of the instrument is

passed up to the internal ring, the needle projected, passing through

the neck of the sac and tissues of the abdominal wall; the concave cover is then screwed down and a cork fixed on the end of the needle. The instrument is allowed to remain in position eight or ten days. After the removal, the patient is kept in bed as much longer, and is then permitted to get up, keeping the parts supported by a truss for five or six months.

Agnew's Modification.—Evacuate the patient's bowels thoroughly the day before the operation. Place him in a horizontal position, shave and cleanse the parts, make an incision through the integument, commencing at the external abdominal ring and terminating two inches below it; separate the integument from its fascial connections at either side of the incision, then invaginate the fascia and dartos, pushing it to the outer extremity of the canal by the index-finger, along which the instrument is now passed. The instrument (Fig. 586) is introduced with its grooved blade resting internally to carry the invaginated integument to the outer extremity of the canal. The blades are then widely separated, and the long needle, armed with a silver wire, is inserted into one of the grooves of the inner blade, and, guided by it, is passed through the superimposed tissues, the end of the wire grasped, needle withdrawn and directed by the other groove through the tissues in the same manner, causing the points of puncture to be about half an inch apart. The wire is then cut of sufficient length to be twisted around a piece of cork, or bent, thus securely fastening the apex of the invagination within the canal. The sides of the inguinal canal are now drawn together by three transverse sutures half an inch apart, introduced by a needle armed with stout silk thread, which is passed between the blades of the instrument. This should then be withdrawn, the wound closed and dressed antiseptically, the patient confined to the bed, and the bowels kept closed by opium to avoid straining.

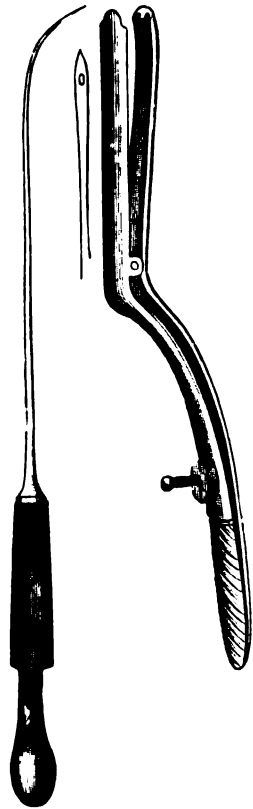


FIG. 586.—Agnew's apparatus.

The transverse sutures are allowed to remain in position for eight or ten days, the silver one somewhat longer, the object being to cause a firm agglutination of the invaginated plug to the surrounding tissues.

The results of this operation are flattering. If the cases be correctly reported, over eighty per cent are cured.

Wood's Method.—This consists in drawing together and retaining the tendinous structures of the inguinal canal and pillars of the ring by the means of a ligature, until the parts become united by effused lymph.

The instruments required are a tenotome, semicircular needle attached to a strong handle, and a silver-plated copper wire (Fig. 587).

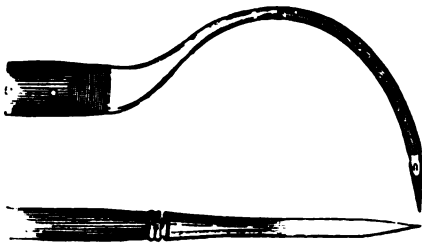


FIG. 587.—Wood's apparatus.



FIG. 588.—Tissues invaginated.

The method of procedure is succinctly portrayed by Mr. Druit: "The patient being tied on his back, with the shoulders well raised, with the knees bent, the pubes cleanly shaved, the rup-

ture completely reduced, and chloroform administered, an oblique incision about an inch long is made in the skin of the scrotum over the fundus of the hernial sac. The knife is then carried flatwise under the margins of the incision so as to separate the skin from the deep coverings of the sac, to the extent of about an inch, or rather more, all around. The forefinger is then pressed into the wound, and the detached fascia and fundus of the sac invaginated into the canal as

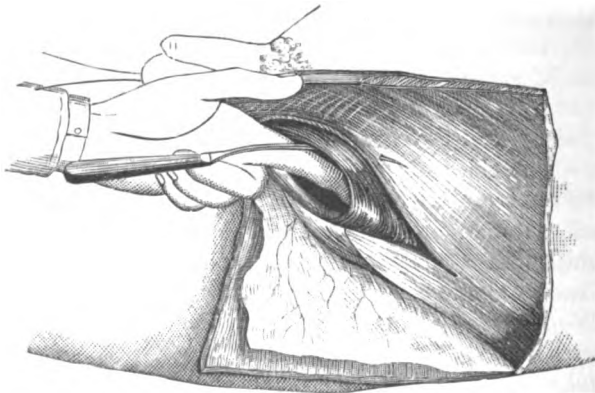


FIG. 589.—Transfixing conjoined tendon.

represented in Fig. 588. The finger then feels the border of the internal oblique muscle, lifting it forward to the surface. By this means the inner edge of the conjoined tendon is felt at the inner side of the finger. The needle is then carried carefully up to the point of

the finger along its inner side and made to transfix the conjoined tendon, and also the inner pillar of the ring (Fig. 589). When the point is seen to raise the skin, the latter is drawn over toward the median line, and the needle made to pierce it as far outward as possible.

A small hook is bent on the point of the wire, inserted into the eye of the needle, and drawn back into the scrotum and detached. The finger is next placed behind the outer pillar of the ring and made to raise that and Poupart's ligament as much as possible from the deeper structures. The needle is now passed along the outer side of the finger through Poupart's ligament a little below the deep hernial opening (Fig. 590), and the point is then directed to the skin

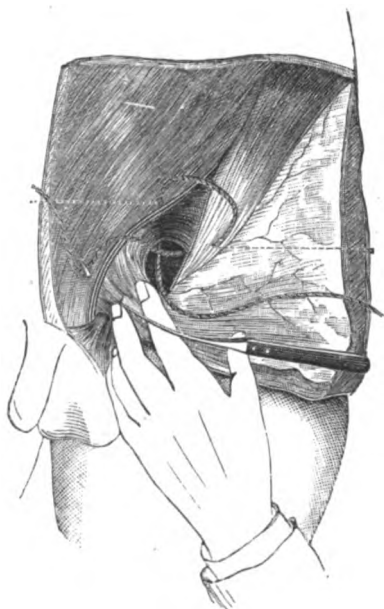


FIG. 590.—Transfixing Poupart's ligament.

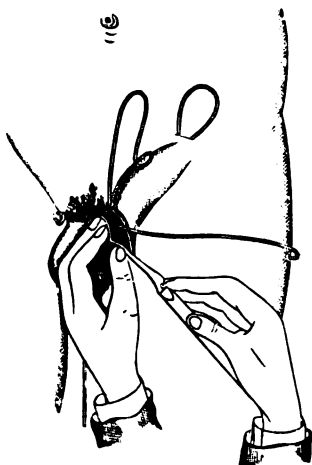
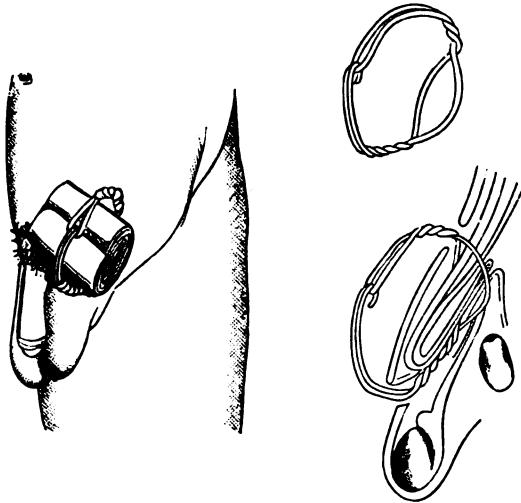


FIG. 591.—Passing through or behind the sac.

puncture before made. The outer end of the wire is hooked on to the needle, and the wire is then drawn back into the scrotal puncture as before, and detached.

Next the sac at the scrotal incision is pushed up between the thumb and forefinger, and the cord slipped back from it, as is done in taking up varicose veins. The needle is then passed across behind or through the sac, between it and the cord, entering and emerging at the opposite ends of the scrotal incision, as shown in Fig. 591. The end of the inner wire is again hooked on and drawn back behind the sac. The needle may be made to pass through one or both of the pillars at the same time close to their insertion. Both ends of the wire

are then drawn down until the loop is near the surface of the groin above, and they are twisted together down into the incision and cut off at a convenient length. Traction is then made on the loop so as to invaginate the sac and scrotal fascia well up into the inguinal canal. The loop of wire is firmly twisted close down into the upper puncture and bent downward to be joined to the two ends below in a bow or arch, beneath which is placed a fine pad of lint (Figs. 592 and 593), and the whole confined in position by a spica bandage.



FIGS. 592, 593.—Invagination completed.




FIG. 594.—Wood's rectangular pins.

Modification with Pins.—For small herniæ and herniæ in children Dr. Wood employs a pair of rectangular pins (Fig. 594). With the finger in the inguinal canal, as in the preceding operation, one pin is




FIG. 595.—Passing the pins.

made to pass through the conjoined tendon and the internal pillar from above downward, and the other to pass through Poupart's ligament from below upward (Fig. 595).

They should both be caused to enter and emerge at the same point of cutaneous puncture. The pins

are bent at a right angle at the blunt extremity, the angle being looped. After the transfixion they are locked to each other and twisted around to more closely entwine the included structures. The ends of the pins are then cut off and the blunt extremities are pressed against the abdominal wall, confined in position, and allowed to remain eight or ten days (Fig. 596).

The results obtained by this method, as recorded by Dr. Wood, are most excellent, seventy per cent being satisfactory; between one and two per cent died.

These results have not, as yet, been duplicated by other operators.

Czerny's Method.—Expose the sac by a free incision in its long axis and separate it from the surrounding tissues, isolate its neck and tie it with a strong catgut ligature. Amputate the sac below the ligatured point, push the stump into the abdominal cavity, refresh the borders of the opening, and unite them by a continuous catgut ligature.

Results.—Of the cases reported all but one resulted in a satisfactory manner. It is suggested by Prof. S. D. Gross that the method can be modified by simply tying the sac as before and returning it to the abdominal cavity, which will expose the patient to no unnecessary danger.

It is recommended that the sac be twisted after tying its neck, to excite adhesive inflammation. The lower end of the sac may be drawn to the outer end of the inguinal canal by a ligature extending from it through the abdominal walls, and the sac is then fastened in place by tying the ligature around an antiseptic compress.

The author has employed a method of treating the sac of ordinary-sized herniæ, which he has not, as yet, seen described. After the neck of the sac is tied, a looped ligature armed with a large needle is carried through the lower extremity and tied. Two parallel incisions are then made half an inch apart, the lower one being made half an inch above the border of the internal pillar. They should correspond in length to the width of the sac. The external pillar is treated as nearly as possible in the same manner; the first incision being located a little below its upper border. The sac is first carried upward behind the internal pillar, drawn through the upper slit, and returned through the lower slit of the same pillar; then it is carried behind the external pillar, out through its upper slit, and returned again by being pushed

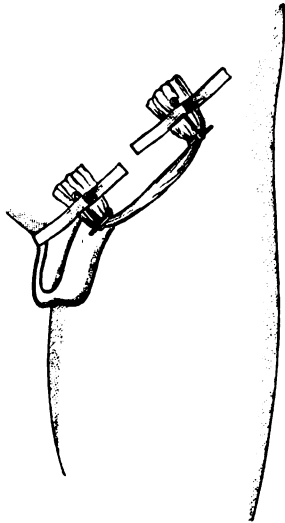


FIG. 596.—Pins in position.

inward through the lower slit of the pillar. The sac is drawn tightly, the borders of the external ring are approximated and sewed with catgut or silver wire, the stitches being carried through the walls of the sac lying beneath. This "weaving" process not only thoroughly closes the external abdominal ring, but also introduces additional layers of peritoneum in front of the weakened point of the abdominal wall.

Results.—Sufficient time has not yet elapsed since the first operation performed by this plan to admit of a positive expression of opinion regarding the result.

Dowell's Method.—Prepare the patient as in the preceding methods. He is then placed in a recumbent posture with the shoulders elevated and the limbs flexed.

Operation.—Be sure the hernia is reduced. Invaginate the scrotal tissues with the index-finger. Take the semicircular needle, especially designed for the purpose, and arm it with a strong silken ligature. The needle is entered one inch and a half above the external ring and passed beneath and close to the tip of the finger and brought out through the skin on the opposite side, near to Poupart's ligament. This stitch passes through the integument, the aponeurosis of the external oblique, and the hernial sac near the posterior wall of the canal. The needle is withdrawn till its point is disengaged from the tendon, and is then carried *over* the point of the finger in close contact with it, and pushed through the first puncture, situated near to Poupart's ligament. By this procedure the loop is made to surround the inguinal canal, and both its extremities lie together in the primary puncture. To one end of the silken ligature just passed attach a silver wire which is then drawn into the position of the former. Two or more silver wires are introduced in a similar manner at different situations along the canal. Each of these is then twisted over a cylinder of antiseptic gauze placed upon the abdomen and the whole is dressed antiseptically. The patient should be kept quiet in bed for eight or ten days, upon a restricted diet, after which the stitches can be removed; and the patient allowed to walk, three or four days later.

Results.—Dr. Dowell some time since reported ninety-six cases treated in this manner, with eighty cures and sixteen failures.

In many cases of the so-called radical cures obtained by any method, the fondest anticipations of the patient and surgeon are too often dispelled by the return of the protrusion. To avoid this, if possible, an easy-fitting truss should be worn for a long time afterward. The direct methods can be employed in the treatment of all forms where the neck of the sac can be reached and the borders of the opening approximated.

Radical Cure of Femoral Hernia (Wood).—The same instruments are required for operation upon femoral hernia as upon inguinal. The

patient is placed on the back with shoulders well elevated, and an incision an inch in length is made in the long axis of the protrusion through the integument. The subjacent fascia is separated from the integument and is pushed into the femoral opening with the index-finger, which is placed at the inner side of the femoral vein to protect it. The needle is passed upward through the sac, and is directed so as to include with it the pubic portion of the fascia lata over the pectineus muscle (Fig. 597, *b*). The point of the needle appearing at the wound is then pushed upward and through Poupart's ligament toward the nail of the invaginating finger. The skin of the groin is drawn outward and pierced by the needle. A wire is passed through the eye of the needle and is carried downward by its withdrawal. The wire is removed and left in the wound, and the needle again carried through the pubic portion of the fascia lata about an inch outside of its preceding course, and upward through the falciform process of the fascia lata and Poupart's ligament through the integumentary puncture previously made (Fig. 597, *a*). The other end of the wire is then inserted into the needle and pulled down as before. The lower ends are then twisted together in the incision, the twisted end cut off five or six inches long, and the upper external loop twisted firmly down upon the integument (Fig. 598) and looped as before (Fig. 599).




FIG. 597.—Passing needle through fascia lata. FIG. 598.—Wire in position for twisting.

Umbilical Hernia.—The instruments required are a stout needle, a spoon-shaped concave director, and two pieces of stout silvered copper wire, eight or ten inches in length (Fig. 600). The patient is placed

on the back, the shoulders are raised, the thigh flexed on the abdomen, and the contents of tumor reduced. The spoon-shaped director,



FIG. 599. — Wire looped in position.

b, with its concave surface uppermost, is pushed into the highest portion of the opening, upon either the right or left side, carrying the integument beneath the free border of the tendinous outline of the opening. The needle, *d*, is carried along the concave surface and thrust through the invaginated integument, fibrous border, and also the superimposed integument, after this has been drawn upward. The end of the wire *a*, is then introduced into the needle and drawn through the puncture. The lower portion of the opening is pierced in the same manner, the skin being drawn downward to cause the needle to emerge at or near the puncture previously made. The second wire is then drawn through in a similar manner. The operation is repeated on the opposite side, the end of the needle being

introduced, first, at the puncture first made and carried along beneath the integument situated between the fibrous boundaries of the open-

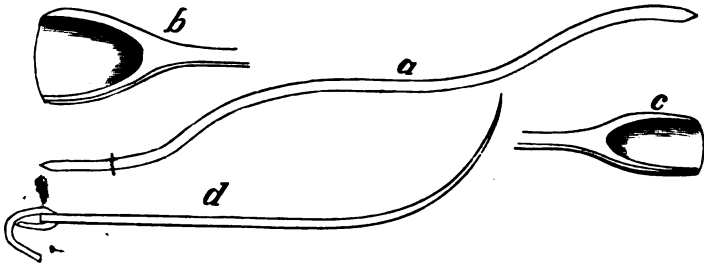


FIG. 600.—Instruments for umbilical hernia.

ing, thence out through the tendinous border of the rupture as before described. The extremities of the wire are then twisted until the opening is closed, when they are cut of a sufficient length to be hooked over a compress of lint and retained by adhesive plaster and a bandage.

STRANGULATED HERNIA.

Strangulation is a condition induced in the sac by a constriction located at the neck or within the sac itself, which obstructs the circulation entirely or in part, thereby exposing the contents of the constricted portion to the danger of gangrene. The operations for its relief are *taxis* and *herniotomy*, the latter sometimes being called *kelotomy*, and in common parlance “an operation upon strangulated hernia.”


Taxis.—This consists in returning the constricted viscus to the abdominal cavity through the channel of its escape by manipulation aided by force of gravity and the relaxation of the constricting agencies. As a rule it will be found that strangulation occurs to a protrusion of long standing, where the patient has become self-educated in the practice of returning it. It therefore follows, when the case is brought to the attention of the surgeon, that the patient has made persistent but ineffectual efforts to reduce it; under these circumstances the outlook for the surgeon's success is not brilliant. He should first diagnosticate the variety of hernia, that his efforts may be intelligently directed; also its condition, that his efforts may do no further injury to the parts or cause harmful procrastination. If moderate effort be not sufficient to return it, a hypodermic injection of morphia may be given near the seat of the constriction, and the patient kept in a warm bath, with the pelvis elevated, until the combined influences are felt on the general system. It can thus often be returned without difficulty, either by the patient or surgeon, the former being less liable to employ harmful force because of the pain produced. If these measures fail, and if the strangulation be of recent date and the symptoms not urgent, the patient is then thoroughly dried, surrounded by warm wraps, placed in a bed with its foot well elevated, and hot applications applied to the parts. These measures are of themselves often sufficient to cause its return. If they fail, then *taxis* is repeated with or without an anæsthetic. If an anæsthetic is used, it should be with the understanding that a failure at reduction will be followed by an immediate operation.

Taxis is practiced by elevating the hips, relaxing the tissues, and endeavoring to return the part first which escaped last, in the direction of the channel through which it came. Empty the bowels and bladder, flex the thigh upon the body, abduct and rotate it inward to relax the muscular and fibrous tissues about the groin, grasp the tumor with the right hand, and draw it downward carefully to disengage its neck and at the same time to give to it the proper direction for reduction. Gentle, uniform, and continuous pressure is then made upon it by the right hand, while the thumb and fingers of the left steady the upper extremity. If successful, in a few moments the surgeon will be conscious of a slight gurgling noise, followed by a diminution in its size and tension. This is caused by the escape of gas or fecal matter, and will soon be followed by the return of the entire protrusion. Properly directed *taxis* should not be continued longer than fifteen or twenty minutes, when the herniotomy should be proceeded with. If it be improperly directed, the sooner stopped the better.

If *taxis* be applied to a femoral protrusion, if it be a complete one, it must not be forgotten that it is necessary to *first press downward, and then backward and upward*. It not infrequently happens that a

large femoral hernia is mistaken for an inguinal one, and efforts are directed to returning it through the inguinal canal.

Kelotomy.—The instruments required for this operation are the ordinary scalpel, thumb-forceps, and artery-forceps, scissors, hernial knife (Figs. 601 and 602) and hernial director (Fig. 603), hypodermic



FIGS. 601, 602.—Hernial knives.

syringe, ordinary grooved director, needles, and the materials for complete antiseptic treatment. The steps of the operation may be logically divided into six : 1, division of the tissues ; 2, recognition of the




FIG. 603.—Levis' director.

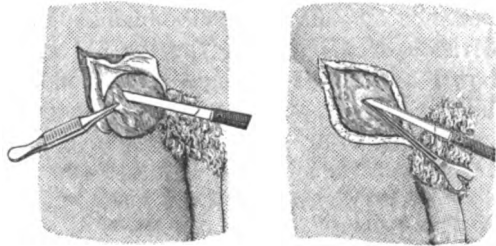
sac ; 3, opening of the sac ; 4, examination of the contents ; 5, division of the

stricture and return of the protrusion ; 6, closure of the wound.

Division of the Tissues.—After the patient is etherized, and the parts are shaved and cleansed by scrubbing, and suitably placed in a good light, an incision two or three inches in length is made through the integument, by transfixion or otherwise, in the long axis of the tumor. The remaining structures, forming the wall of the sac, are picked up one after another with the thumb-forceps at the lower angle of the wound and nicked, the grooved director is pushed beneath each one, and it is then divided with the knife or scissors. The possibility of recognizing the different layers will depend very largely on the length of time the hernia has existed, as well as upon the amount of external irritation to which it has been subjected. It is exceptional, however, when many of the layers can not be easily recognized, especially those of a muscular character and the dense fascia. As the sac is approached, the question which will most annoy the surgeon is, which is the sac ? am I without or within it ? The sac is recognized by the various layers and their anatomical characteristics ; the fascia transversalis, which surrounds it and is separated from it by the fatty subserous tissue, is quite liable to be mistaken for the peritoneum. The

fascia is dense, opaque, non-translucent, and always present. If a similar tissue has not been divided before, this, then, can not be the sac. A minute opening should be made through it at the lower portion of the wound, a grooved director passed beneath it, and its division carefully made. The next layer is the subserous fat, which is often quite well marked. If the surgeon with hesitation divides the fascia transversalis under the impression that it is the sac, he will become somewhat reassured by mistaking the subserous fat for the omentum in the protrusion. This feeling of security will be quickly dispelled, however, when he attempts to find the intestine, or to return the supposititious omentum.

Recognition of the Sac.—It is globular in form, of a bluish color, and often transparent. A sense of fluctuation is often discernible at its lower portion. It can be pinched up between the thumb and finger, and its smooth serous surfaces can be rubbed together, if they be not adherent to its contents. This is diagnostic. The intestine may be pinched up in the same manner before



FIGS. 604, 605.—Opening the sac.

the sac is opened, when it will quickly and easily escape the grasp on account of the smooth opposed serous surfaces. If a needle be introduced, a drop of fluid will escape; this is characteristic of a hernial sac. Finally, if the membrane be examined, it will be found to surround and limit the protrusion, being movable only as a whole, denser than the intestine, and devoid of its external serous surface. The sac is now to be picked up with the thumb-forceps at the fluctuating point, or the point where the drop of fluid escaped, and a small slit made in it with the knife-point held at right angles to the forceps (Fig. 604). If fluid be present it will then escape. A grooved director is inserted (Fig. 605) and an opening made of sufficient size to admit the index-finger, which is introduced to determine with certainty the tissue just cut, as well as the location of the constriction (Fig. 606). If the finger be in the sac, it will come in contact with smooth surfaces, and, after division of the constriction, can be passed through the neck of the sac into the abdomen. If the fin-

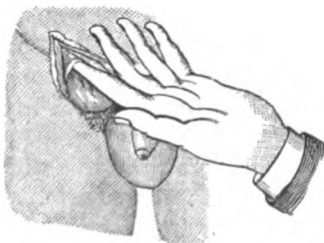


FIG. 603.—Introducing the finger.

gertine be in the sac, it will come in contact with smooth surfaces, and, after division of the constriction, can be passed through the neck of the sac into the abdomen. If the fin-

ger be without the sac, it can not be passed upward without being arrested. The existence of cysts in the line of incision may confuse the surgeon. If, however, the finger be introduced into them, their non-serous lining and limited extent will expose the fallacy. The sac is now opened sufficiently to expose its contents to a careful scrutiny, that the propriety of returning them may be carefully considered.

Examination of the Contents.—Under all circumstances there will be more or less injection of the vessels. If the constriction be recent or slight, the changes in the imprisoned tissues will not be great; but when severe or long continued, the intestine will be of a more or less purple or blackish color, with isolated ecchymoses. The bowel may present this appearance, and yet may possess sufficient vitality to recover. The color is not of as much importance in determining the presence of gangrene as the inability to restore the circulation after division of the stricture by the aid of warm fomentations. If the bowel be pricked or slightly scarified and no blood flows; if sensibility be absent and the part becomes cool; if its luster be destroyed and its structure be softened and crackling, it should not be returned. If to all these be added the odor of gangrene, it should be opened to afford exit to its contents and be treated with warm fluid carbolized dressings. It is considered good practice at the present day to excise a circular portion of the intestine corresponding to the gangrenous part and unite the extremities as described under the head of enterectomy. If the omentum be gangrenous or bulky, ligature it near the mouth of the sac and cut it off; if not, it can be returned. If the contents be adherent to each other or to the sac, the adhesions may be ruptured if of recent date. It is often necessary, however, to sever them with the knife or scissors, and in doing so, the vessels should be ligatured with fine catgut as soon as seen. When the adhesions are very firm and limited, the corresponding portion of the sac may be dissected off and returned with the bowel.

Division of the Stricture.—The constricting agency may be without or within the sac, the former being the more frequent site. If without, it may be divided before or after the sac is opened, the latter being the almost universal custom. If the hernia be a small one, and strangulation have lasted but a few hours without stercoraceous vomiting or other severe symptoms, and be composed of intestine alone, the constriction may be divided external to the sac. This can be readily done by passing beneath the constricted tissues of the neck of the sac the hernial director of Levis (Fig. 603), which is cautiously carried upward until the constricting band falls into the notches at either side of the groove; a probe-pointed bistoury or the ordinary hernial knife is then carried along the groove, and the structure divided (Fig.

607); *not freely*, but just sufficiently *nicked* to permit the return of the intestine. When the gravity of the case requires the constriction to be divided within the sac, so that its contents may be examined, the finger is carried up to the point of the obstruction, followed quickly by the director, which is employed as in the preceding instance. The edge of the knife should be directed away from important vessels and the extent of the cut be only sufficient to relieve the constriction. If the gut be gangrenous, great caution must be observed in cutting the band, or the adhesions may give way and allow the bowel to re-enter the abdominal cavity. If gangrene of the gut be assured, it is better not to divide the constriction, since to do so not only exposes the patient to the danger of the return of the gangrenous gut into the abdominal cavity, but also to the entrance of discharges from the wound. As soon as the bowel is returned, stop all hemorrhage, unite the wound with catgut carried through the sac, introduce a drainage-tube, apply a compress, dress antiseptically, raise the foot of the bed, and quiet the patient with an opiate.

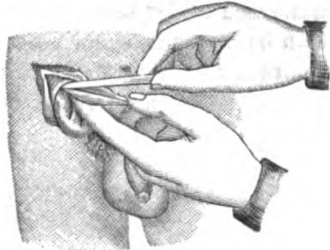
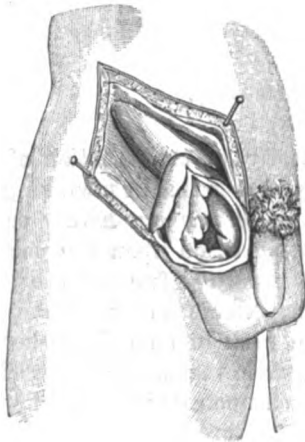


FIG. 607.—Dividing the constriction.



FIGS. 608, 609.—Oblique inguinal hernia.

Strangulated Inguinal Hernia.—A hernia in this situation may be direct or indirect, either of which may be complete or incomplete. In the indirect or oblique form (Figs. 608 and 609), if it be a complete hernia, it enters at the internal abdominal ring, passes downward

forward to, and through, the external ring. The constricting agent external to the sac may be located at either the internal or external abdominal rings, and rarely in the inguinal canal. The manner of cutting down upon the sac, and of detecting and dividing the constriction, is described under the general considerations. If the seat of the constriction be at the internal ring, it should be divided upward and outward to avoid the epigastric artery which runs along its inner border (Figs. 609, 4 and 610). In fact, in the oblique variety the incision upward

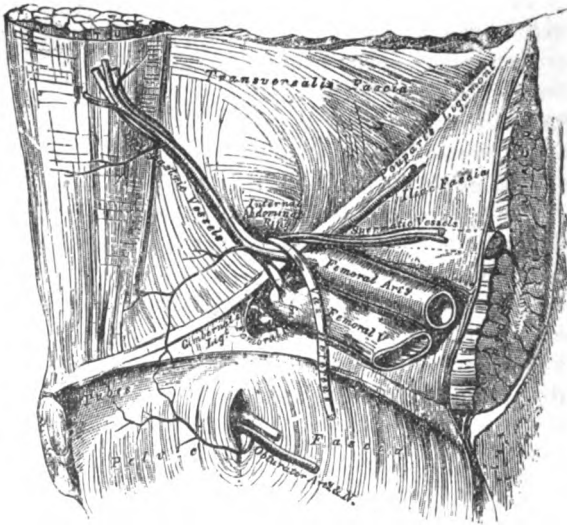


FIG. 610.—Course of epigastric artery.

and outward is always to be made irrespective of the situation of the constriction. *The only fallacy* that may arise is that of mistaking the direct for the indirect form. In recent cases this can hardly occur, but in those of long standing, where the traction upon the neck of the sac of the oblique form has drawn it inward in front of the point of the exit of the direct variety, it is quite difficult and often impossible to distinguish between them. If the neck of an oblique hernial sac be dragged inward, it causes the epigastric vessels to be pressed directly against its inner and also to encroach upon its upper and lower borders. Under these conditions, if the stricture be divided agreeably to directions often given—parallel with the course of the epigastric vessels—or even upward and slightly outward, these vessels will be in imminent danger of injury.

If, upon the other hand, the protrusion be of the direct variety, and the incision be made upward and outward, under the impression that it is a displaced indirect form of hernia, the epigastric vessels will

then be exposed to peril (Fig. 611, 6). It is readily seen, therefore, that great caution should be employed in distinguishing between the two, prior to cutting the constriction. It is practically impossible to discriminate between them until the coverings of the sac are examined. The oblique variety has for a covering the cremaster muscle, which can readily be distinguished in an old hernia. This muscle never forms the covering of a direct hernia *except* when it passes to the outer side of the conjoined tendon; then its coverings are similar to those of the oblique form. It therefore follows, from the anatomical relations, that when the cremaster does not form a covering the constriction should be divided upward and inward—that is, away from the epigastric vessels. If it

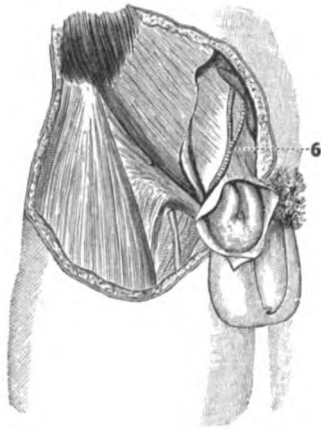

FIG. 611.—Direct inguinal hernia.

forms one of the coverings, then the constriction must be cut upward and outward, provided there be no evidence that it is a direct hernia which has escaped to the outer side of the conjoined tendon. This latter condition of affairs is fortunately rare, and this fact, when taken in connection with the location of the tumor at its incipiency, should settle the question between the two. If, however, it be impracticable to settle the doubt, dull the edge of the knife by drawing it across a nail or stone, and then proceed carefully to nick the neck of the constriction in an upward direction. If the constriction be at the external abdominal ring, it matters little in which direction the cut is made; however, to simplify matters, the direction upward and outward should still be adhered to. The methods of examination of the contents of the sac and their reduction, together with the subsequent treatment, are sufficiently considered in the preceding pages. If the protrusion be incomplete, the treatment is similar, and the matter simplified by the inability to confound the direct with the indirect varieties of this form.

Strangulated Femoral Hernia.—The protrusion in this instance escapes at the femoral or crural ring at the inner side of the femoral vein (Fig. 612), then passes along between the vein and Gimbernat's ligament, and the inner boundary of the femoral canal for about half an inch, to the upper portion of the saphenous opening through which it escapes, and in many instances passes upward and rests upon the falciform process of that opening (Fig. 613). The *two common points of constriction* are: Gimbernat's ligament, and the sharp border of the falciform process of the saphenous opening. The im-

portant boundaries of the upper extremity of the crural canal are : within, Gimbernat's ligament, and without, the femoral vein, sur-

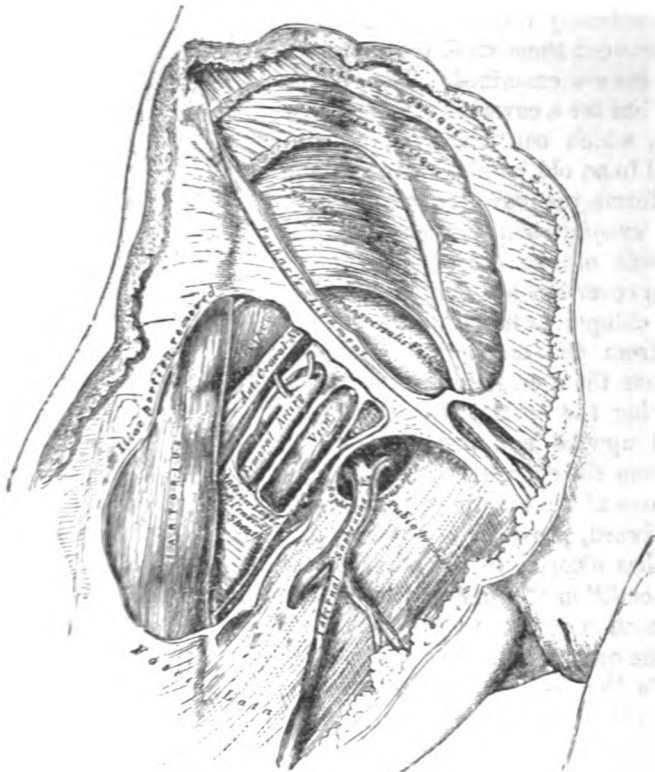


FIG. 612.—Location of the femoral canal.

rounded by its sheath. Throughout the course of this canal the femoral vein lies at the outer side. The distinctive coverings of this protrusion are : the cribriform fascia, crural sheath, and septum crurale, together with the subserous tissues. The important vascular relations are those of the femoral vein and the obturator artery. Taxis should not be employed in femoral hernia as long as in inguinal, since the constricting influences are greater, and the neck of the sac much smaller. I must again refer to the fact that a femoral hernia, which extends upward toward Poupart's ligament, sometimes reaching above it, may be mistaken for one of the inguinal variety, and that the efforts at reduction are directed to returning it through the external abdominal ring, instead of pushing it downward, backward, and upward, as is necessary to effect a reduction.

Operation.—The part should be washed, shaved, and disinfected ; patient placed on the back, thigh flexed and rotated outward, bladder

emptied, patient anæsthetized, and an incision made in the long axis of the tumor. The integument and superficial fascia should be care-

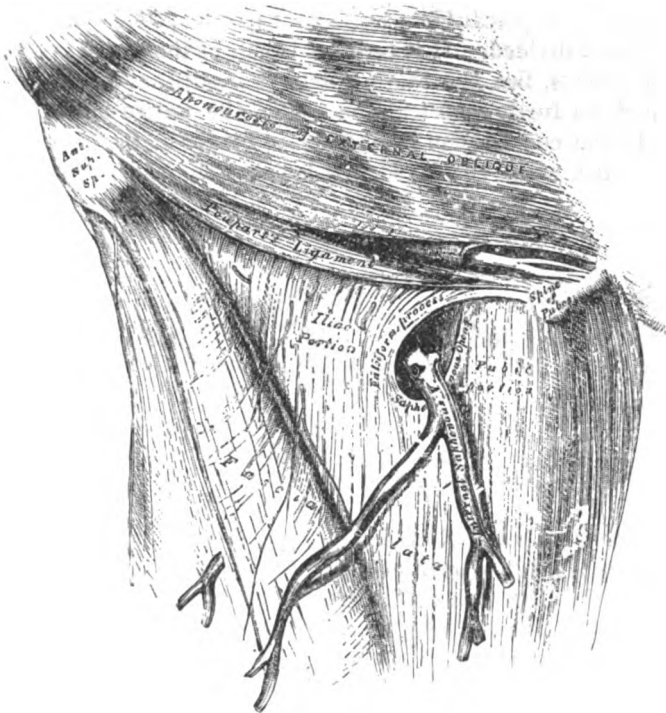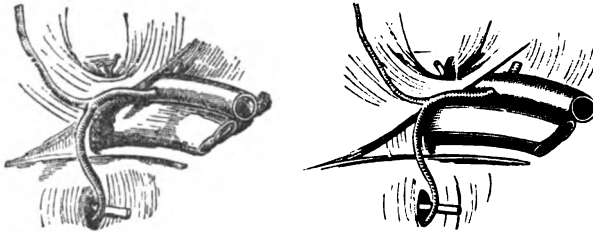


FIG. 613.—Saphenous opening.

fully divided, thus exposing the *cribriform fascia*, which in fleshy subjects is loaded with fat. This, with the glands connected with it, especially if the latter be enlarged, forms a mass often difficult to understand. The glands should be pushed aside, and the remainder of the structure carefully divided. It can hardly be mistaken for anything but the omentum, or the deeper layer of fatty tissues. The absence of the sac will readily expose the fallacy of the former, and the nature of the latter will be soon recognized.

The *femoral or crural sheath* comes next in order. It is dense, like the fascia transversalis, of which it is a prolongation, and might be mistaken for the sac did it not present those appearances of a different character, which have already been described. The *septum crurale*, if the protrusion be large, will hardly form one of its coverings; if it does, its texture will be much diminished in thickness, and somewhat blended with the subserous tissue. It sometimes happens that the small lymphatic gland, which normally exists between the subserous tissue and the septum crurale, can be distinguished, which, of course,

settles all doubts as to the identity of the tissues under inspection. The careful use of the knife and director soon exposes the sac with its characteristic appearance. It should be opened at the lower extremity with the precautions previously enjoined, and the stricture sought for and divided. If it be, as is usual, at the free border of the falciform process, flex the thigh, rotate it inward, and then, if it is proper, and no further obstruction exists, the protrusion can be reduced. If the constriction be at the free border of Gimbernat's ligament, this, too, must be nicked. It is necessary to remember, before



Figs. 614, 615.—Course of obturator artery.

attempting this, that the obturator artery, once in three and one half cases, arises from the epigastric, and although it usually lies in contact with the vein in its descent (Fig.

614), and is, therefore, out of danger, yet it not infrequently curves inward along the free margin of Gimbernat's ligament (Fig. 615), thus nearly encircling the neck of the sac, and is therefore in great danger of being cut. The knife should be made quite dull, and the ligament nicked superficially in several places. The tip of the little finger may then be inserted and the artery felt for; if not discovered, the nicking may be repeated, or firm traction with the finger against the ligament may be made, so as to tear or stretch it. This vessel has been severed ten or twelve times during the operation, but in each instance the bleeding was controlled without a fatal result. Ligation and compression were the principal expedients resorted to. After the return of the protrusion, the wound is closed and dressed antiseptically.

Femoral herniæ do not always follow the course just described; they take, though rarely, anomalous courses, sometimes appearing at the outer side, or behind the femoral vessels. They have been known to pass through Gimbernat's ligament. It is important to know that in all the anomalous cases the neck of the sac lies closely associated with the epigastric artery alone, or, together with the obturator, and troublesome and often fatal hæmorrhages may be caused unless care is taken in dividing the constriction.

Strangulated Umbilical Hernia.—If the symptoms be not urgent, it is recommended that taxis be continued longer in umbilical hernia than is considered admissible in other forms of hernial strangulation, owing to the greater death-rate attending herniotomy in this situation. In the employment of taxis the patient lies upon the back, with the

shoulders raised and the thighs flexed. The location and size of the opening can often be defined by the finger before the viscus is returned. The seat of the strangulation is usually at the upper border of the opening. The taxis pressure should be directed upward and backward to correspond to the line of its escape. The incision for the operation is made to suit the shape and size of the tumor. All the tissues are divided on a director, and the upper border of the opening sought for, since it is at this situation that the constriction is most frequently seated. If it be possible, the stricture should be divided without opening the sac, and the contents returned, if they be not gangrenous. If the stricture be without the sac and the contents in an uncertain condition, a small opening, just large enough to admit of inspection, can be made through the sac. If the stricture be within, the only recourse is to relieve it through as small an opening in the sac as possible. If the intestine be gangrenous, the constriction must not be divided, for to do so will allow the wound discharges to run into the abdominal cavity, even though the intestine remain outside.

Strangulated Obturator Hernia.—The viscus follows the course of the obturator vessels in its escape from the pelvis, and lies beneath the pectineus and obturator muscles. It is usually small and not detected during life.

The incision for its relief is made over the tumor at the inner side of and parallel to the femoral vessels. The constriction has been found in the fibers of the pectineus muscle; and it is usually necessary to divide some fibers of this muscle in order to expose the opening through which it has escaped. The relation of the obturator vessels to the neck of the sac varies, being equally frequent at the outer and inner sides; never in front, and occasionally behind it. If the constriction be found at the foramen, it will require much caution to divide it without implicating these vessels.

CHAPTER XV.

OPERATIONS UPON THE ANUS AND RECTUM.

Examination of the Anus.—Place the patient in either one of four positions: 1, in the knee and elbow position; 2, upon the back; 3, upon the right side, with the knees drawn upon the abdomen; 4, or cause the patient to kneel upon a chair and lean over its back.

The position most commonly employed is upon the back in the lithotomy attitude. The one, however, which is most comfortable and

at the same time most delicate, is upon the side. It is hardly necessary to add that the surgeon should be familiar with the normal characteristics of the parts, not those alone relating to the appearances, but to their sensibility and density as well. On inspection, not only will the presence of the anal opening be noticed, but the wrinkled appearance of the contiguous integument, the condition of the blood-vessels bordering upon it, but also the white line at the muco-cutaneous junction will be seen, which indicates the interval between the internal and external sphincters. The instruments necessary to properly examine the anus and rectum consist of variously formed specula constructed for that especial purpose, which may often be wisely supplemented by those intended for vaginal examinations (Figs. 616, 617,

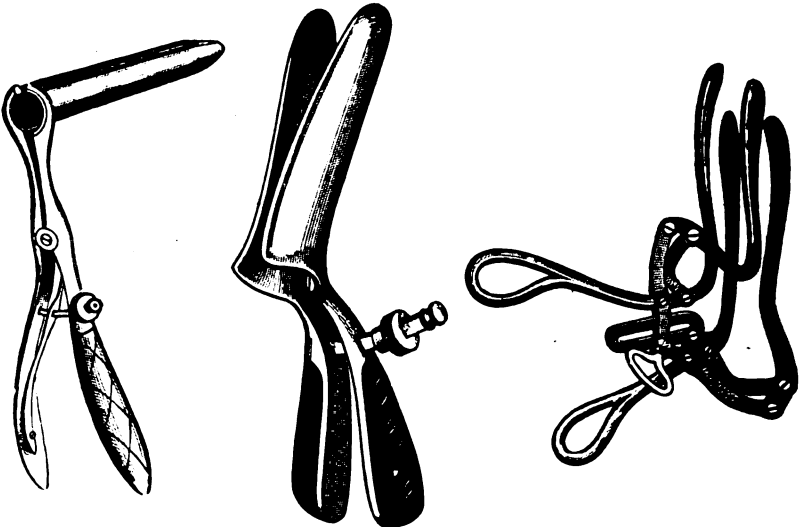


FIG. 616.—Bivalve speculum.

FIG. 617.—Williams' rectal speculum.

FIG. 618.—Allingham's rectal speculum.

and 618). Sims' speculum, or a simulated pattern of it, made by bending the handle of an ordinary tablespoon at a suitable angle, will be found to be of much use. Any form of speculum which possesses ample power of adjustment will serve the purpose well.

Imperforate Anus.—This condition depends upon a layer of tissue of variable thickness which exists between the normal site of the external opening and the lower extremity of the rectum. It may be simply a thin layer of fibro-cellular tissue, which by its projection indicates the nearness of the loaded bowel. In these cases, the emotions of the child may be noted by the movements of the interposed membrane, and a positive diagnosis can be made by a hypodermic puncture. If the septum be thin, a longitudinal or crucial incision, or even a

simple puncture, followed by the careful introduction of a well-oiled finger, will be a sufficient operative interference, especially if afterward the extremity of a suitable sized rectal bougie be occasionally introduced. If the membrane be of sufficient density to interpose an obstacle after its division, it should be trimmed away, care being taken to not include the proper structure of the opening.

Absence of the Anus (Fig. 619).

—In this deformity all trace of the opening is absent; and the median raphé may extend continuously from the scrotum to the tip of the coccyx. The fibro-cellular interval may be thin or of extreme thickness. If thin, the previously detailed signs of imperforate anus may be evident.

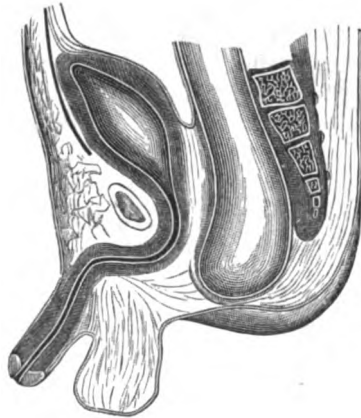


FIG. 619.—Absence of anus.

If they be not present, the occlusion is then of considerable thickness, and may even involve the entire length of the rectum itself.

The operation for its relief consists in first placing the patient, properly anæsthetized, in the dorsal position. Then introduce a sound into the bladder, if the patient be a male, into the vagina if a female, and make a vertical incision in the median line from just behind the scrotum or vagina to the tip of the coccyx, continue it cautiously upward and backward, shortening each succeeding cut, and carefully feel for the fluctuating extremity of the gut. It is sometimes located posterior to the central line and must be sought for near the hollow of the sacrum. During the entire progress of the dissection the situation of the vagina or urethra must be marked by the location of the sound previously introduced. When the dark-brown, fluctuating extremity of the gut is detected, the introduction of a hypodermic needle will settle all doubt. The gut-end should then be seized by a pair of strong toothed forceps (Fig. 620), and drawn firmly downward, while its connections with the surrounding tissues are separated by the scissors and fingers. As soon as the *cul-de-sac* is drawn down to a level with the external opening, pass two short ligatures transversely through the sides of the wound, one through its anterior and one through its posterior portion, transfixing the anterior and posterior portions of the bowel in their passage. Protect the raw surfaces with lint saturated with carbolized oil, then open the sac between the ligatures and allow its contents to escape; after having thoroughly cleansed it, remove the lint, draw the ligatures through the opening in the bowel by means of a hook, cut and tie them, as in the operation for lumbar colotomy.

The mucous membrane should be closely adjusted to the integument, in order to secure perfect union and prevent the contact of the raw




FIG. 620.—Byrne's rectal forceps.

surfaces with the discharges. If it be impossible to draw the end of the gut down to the external opening, it can be incised at its lower extremity, and the discharges allowed to escape over the lower surfaces, which are kept opened by the use of the bougies; or, the coccyx can be removed, as recommended by Verneuil, and the extremity of the bowel drawn through the gap and united to the integument as before.

Fistula in Ano.—A fistula here, as elsewhere, is a sinus, which in

this case leads into the cavity of an abscess located near to the rectum. It may be either complete or incomplete; if of the latter variety, it may be an incomplete internal or external fistula (Fig. 621). The complete form is the most frequent. In the case of a suspected fistula, before making an examination evacuate the bowel by a cathartic and an enema; place the patient on the back or side, and introduce the well-oiled index-finger of the hand corresponding to the side of the patient representing the external opening. The end of the finger will often detect a nipple-like projection in the bowel, indicating the internal opening. If a flexible probe

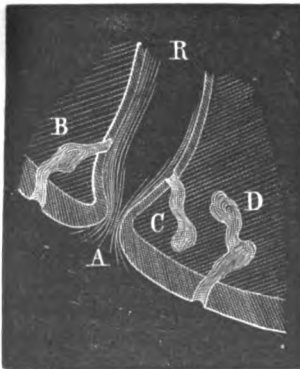


FIG. 621.—A, R. Anus and rectum. B. Complete fistula. C. Incomplete internal fistula. D. Incomplete external fistula.

be then introduced through the external opening, it can with a little care be carried into the lumen of the rectum (Fig. 622). Sometimes,

however, the end of the probe will be felt separated from the finger by only the thin mucous lining of the gut; this may be due to the inability to find the internal opening, or to its non-existence. In either case the thin wall should be perforated by the instrument, thus producing a complete fistula. It not infrequently happens that more than one opening, E, F, communicates with the original abscess (Fig. 623, D), and also that the mucous membrane is undermined to a considerable extent above a previously existing abscess (Fig. 624, A). It is of importance to remember that the introduction of the finger and the probe often produces such a degree of contraction of the sphincter as to prevent the passage of the probe without great difficulty along

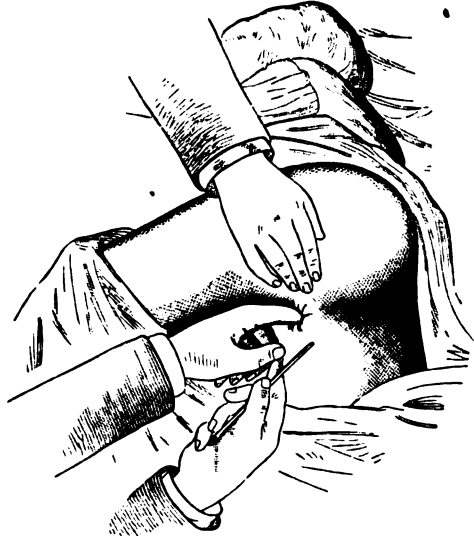
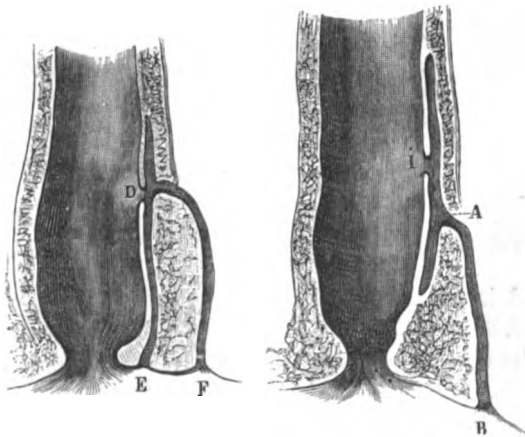


FIG. 622.—Probing a fistula.

the sinus into the gut; therefore the attempt to pass it should not be made until the muscular contraction ceases. It may be advisable to paralyze the sphincter by overdistention before dividing the sinus; this causes the parts to remain at rest, adding to the comfort of the patient and hastening recovery. It can be accomplished by inserting the thumbs through the anus back to back, flexing the first joints and withdrawing them, or by the use of a speculum designed for that additional purpose (Fig. 625).



FIGS. 623, 624.—Variations of fistula in ano.

The accepted method of treatment, namely, that of laying open

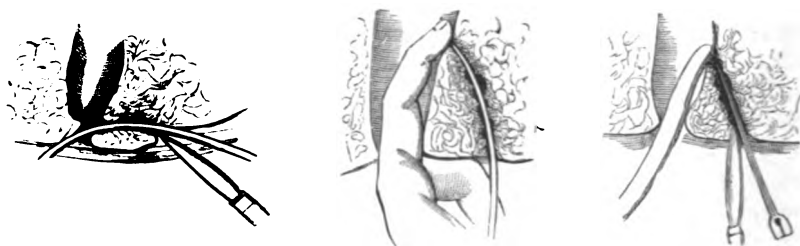the sinus into the gut; therefore the attempt to pass it should not be made until the muscular contraction ceases. It may be advisable to paralyze the sphincter by overdistention before dividing the sinus; this causes the parts to remain at rest, adding to the comfort of the patient and hastening recovery. It can be accomplished by inserting the thumbs through the anus back to back, flexing the first joints and withdrawing them, or by the use of a speculum designed for that additional purpose (Fig. 625).




FIG. 625.—Thebaud's dilating speculum.

the sinus, can be practiced by *direct incision*, by *ligature*, or by the *galvano-cautery*. The first method is the one most commonly employed. For this purpose the bowel should be thoroughly evacuated by a brisk cathartic on the day preceding the operation, and be followed by light diet. On the day of the operation it should be thoroughly cleansed by one or two copious enemata.

Operation by Direct Incision.—Place the patient on the back, give an anæsthetic, pass the finger into the bowel as before described, introduce a grooved director through the sinus into the bowel; if the end can be turned out (Fig. 626), then divide the sinus upon it; if not, press it against the finger, and pass a probe-pointed bistoury along the groove into the bowel; after which, the director may be withdrawn, the point of the bistoury pressed against the finger (Fig. 627), and the sinus cut outward with the point thus protected. The finger may be replaced by a wooden director introduced into the bowel, and the division made upon it (Fig. 628). The



FIGS. 626, 627, 628.—Dividing fistulas.

scissors may be employed instead of the knife, either with or without the grooved director (Fig. 629). Whenever the depth of the sinus demands the division of the entire thickness of the internal sphincter, it should be done at right angles with the course of the fibers, to avoid, as far as possible, the danger of incontinence of flatus and fæces.

While each sinus should be opened, still, when possible to avoid it, the sphincter should be divided in but one situation, in order that its integrity can be the better restored; and, when practicable, a small portion of the circular fibers should be preserved with the same object




FIG. 629.—Allingham's scissors and director.

in view. It is not necessary to divide the walls of the abscess above the opening into the gut, since the drainage and loss of power due to the division of the tissues below permits a rapid healing of this portion. As soon as the sinuses are opened, their pseudo-membranous linings can be scraped or touched with a thermo-cautery, all hemorrhage stopped, the cut packed with oakum, marine lint, or iodoformized gauze, a T-bandage applied, patient placed in bed with limbs extended, and morphia or opium freely given to relieve all irritation and to produce constipation of the bowels. The food should be light, and not of a nature likely to leave a residue. In ten days or two weeks make use of a mild cathartic in conjunction with a copious enema.

Incision with Closure.—If the extent of the sinus will permit it, the entire track may be removed and the resulting wound closed by catgut sutures, carried deep enough to bring the walls of the wound in contact. Two sets of sutures may be employed; one, a superficial set, which shall bring the borders of the mucous membrane together, while the second should unite the deeper structures. In this manner union by first intention may be secured, thus shortening the period of recovery and obviating all danger of fecal incontinence dependent upon the incomplete closure, which sometimes occurs when the cut is deep and is permitted to heal from the bottom. If, however, there be a cavity at the upper end of the sinus, or if any portion of the track be not dissected out, the recovery by rapid healing will be retarded if not entirely prevented.

Treatment by Ligaturing.—The elastic liga-




FIG. 630.—Allingham's ligature-carrier.

ture is the only one worthy of consideration. It consists of a rubber cord about one tenth of an inch in diameter. This is carried through the sinus into the gut by an appropriate instrument (Fig. 630), the inner extremity drawn out through the anus and tied, after any integument which might be included in its grasp has been divided, to prevent the pain and delay incident to the division of its peculiar structure. A strong silk thread can be substituted for the more elaborate apparatus shown in Fig. 630. This, after being passed through the sinus and attached to the rubber cord, can be employed to carry it into position. It is sometimes difficult to tie a knot in the rubber cord securely. Still, this can be accomplished easily by tying the first half of the knot over a silk ligature placed at right angles to the course of the elastic one, and then tying the silk ligature firmly around the half-knot. This holds the elastic cord securely while the knot is completed. The elastic ligature will cut its way through in six or eight days.

This method possesses some advantages over that by incision, among which may be noted that, in simple cases, little or no pain is inflicted, and the patient can walk out-doors without any especial danger.

Nervous persons will often submit to it when they will not to the knife. There is no bleeding, which is of advantage when the larger vessels may be implicated, or when an undue tendency to hemorrhage exists. It is the best method in phthisical patients, for manifest reasons. It can be employed in all cases where but a single sinus exists; if, however, a second be present, the result must of necessity be unsatisfactory, as this involves a repetition of the operation or the use of the knife.

The galvano-cautery does not secure better results than incision, and is much more cumbersome in its application; still, it is useful when dangerous hemorrhage is apprehended.

Surgical Anatomy of the Rectum.—The length of the rectum is from six to eight inches, the latter being the length of advanced life. It has various curves. The first, an inch and a half in length, extends from the anus to near the prostate, and is directed upward and forward, a fact which should be remembered in the introduction of instruments. The second portion follows the curve of the sacrum, and is about three inches in length; the greater portion of this is covered by peritoneum, it being reflected upon it at a point about two and one half inches above the anus in front, and about five inches behind, when the bladder and rectum are empty; if filled, the distance is increased about an inch. The anterior surface of the lower part of this portion is intimately associated with the base of the bladder, vesiculæ seminales, and prostate body in the male. In the female the posterior wall of the vagina is in front. The third curve extends

from the middle of the third piece of the sacrum to the left sacroiliac synchondrosis. This portion is almost entirely surrounded by serous membrane. The vessels having surgical associations with the rectum are the superior, middle, and inferior hemorrhoidal arteries. The first is the most important; it runs between the rectum and the sacrum, a little to the left of the median line, to within about four or four and a half inches of the anus. Its branches run parallel with the long axis of the bowel down to the anus, and can be best avoided by longitudinal incisions.

For a rectal examination the patient is placed in one of the many positions previously cited. The bowel should be thoroughly emptied and cleansed prior to the attempt. One or two fingers, or even the whole hand, may be introduced, or the tube may be inspected through the various forms of specula.

If the examination is made with the index-finger, it should be well oiled and inserted with a semi-rotary motion, allowing the remaining fingers to lie in the median line between the buttocks. In this manner, by the use of moderate force, the lower four or five inches of the organ may be examined. The introduction of the middle finger along with the index-finger will somewhat increase the range of examination, especially if the patient be requested to bear down.

The introduction of the whole hand must be done with great caution in order not to lacerate the bowel or the peritoneum enveloping it. For this purpose the patient is placed upon the back, anæsthetized, bladder emptied, and the services of a person with a small hand, not exceeding eight inches in circumference, are enlisted. The hand should be well oiled, and a conical form given to it by applying the thumb to the palmar surface of the approximated fingers. The tips of the fingers are then inserted by a semi-rotary motion, which is slowly continued until the whole hand enters the bowel. After the entrance of the hand, the fingers are to be moved in various directions to ascertain the caliber of the gut, and, at the same time, favor the circulation of the imprisoned hand.

If the hand meets a narrowing of the bowel at a distance of three or four inches above the anus, but little force should be used, as the peritoneum, which is connected with the gut in this situation and is the cause of the narrowing, may be ruptured. If the hand be small, it not unfrequently happens that the sigmoid flexure may be passed, the descending colon entered, and the kidneys, uterus, and great vessels may be examined through it. It is, however, extremely fatiguing to the examiner; still, the discomfort experienced should not lead the surgeon to relax in the least the degree of caution necessary to the safety of the patient.

Prolapsus Ani.—Prolapsus ani occurs in two distinct varieties: *first*, as a partial or complete prolapse of the mucous membrane alone

(Fig. 631); *second*, as a prolapsus implicating the deeper tissues, often attended by invagination (Fig. 632). The aims in the operative treat-

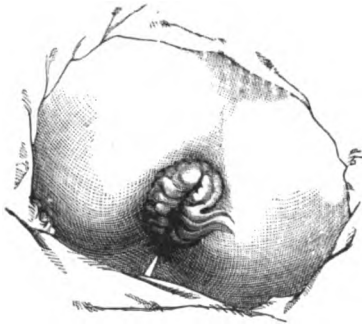


FIG. 631.—Prolapsus ani.

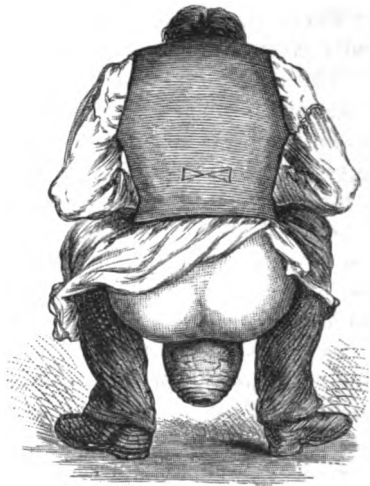

FIG. 632.—Prolapse with invagination.

ment of the former consist in producing adhesions of the mucous membrane to the tissues beneath it, and a narrowing of the orifice of the anus by stimulating the function of the sphincter. The adhesions may be established by clamping and destroying isolated portions of the mucous membrane, or by removing similar portions of it by the ligature or the galvano-cautery. If piles be present, they should be ligatured, as this will alone often effect a cure. The application of Paquelin's cautery, longitudinally or at isolated points, to the prolapsed part, after its return, is an excellent method of procedure, and this, when combined with rest in the horizontal position and the production of fluid evacuations, as adjuvants to the treatment, will usually effect a speedy and satisfactory cure.

Operation.—The patient must be anæsthetized, placed in the knee-elbow position, the prolapse reduced, and the parts exposed by the Sims' speculum. Then four or five longitudinal stripes about three inches in length are made with the point of a cautery at a dull-red heat, at equal intervals apart, and terminating externally at the border of the true skin. The number, size, and depth of the eschars made will depend on the age of the patient and the severity of the case. In the infant, two or three a line or two in width may be sufficient. The older the patient and the severer the case, the deeper should be the eschars. The possibility of reanimating the sphincter is somewhat uncertain, yet the medical expedients directed to the restoration of paralyzed muscles may be employed with some success. The anus

may be narrowed by removing elliptical-shaped pieces from the mucous membrane and uniting their raw surfaces; and also, by linear eschars made in a manner similar to that for prolapsus ani.

Expedients of this kind, while they frequently fail of curing, generally give marked relief to the patient.

The second or complete variety of prolapse exists in three forms: 1. In which the external surface is devoid of a sulcus; in this, the prolapse follows as the result of the continuous traction exerted by long-standing prolapse of the mucous membrane. Peritoneum exists in the tumor, and sometimes also a loop of intestine (Fig. 633). 2. In which a sulcus exists at the base of the tumor, at the bottom of which the lining membrane of the gut can be felt as it is reflected from the invaginated protrusion. 3. In which the finger, when introduced into the anus beside the tumor, fails to detect any evidence of the reflection of the mucous membrane of the rectum upon the tumor, because the invagination is extensive, involving the colon, caput coli, and sometimes the ileum itself.

All three varieties must first be reduced; sometimes this is accomplished with great difficulty, especially when an acute case is complicated with evidences of strangulation of the protruding portion.

Place the patient in the knee-elbow position, and endeavor carefully to return the part first which escaped last, and, if necessary, the external sphincter can be divided. If this fail, renew the effort by reducing the part first that escaped first. If the case be a severe one, the mucous membrane of the protrusion can be painted with a solution of cocaine, and even an anæsthetic may be given. To the treatment of the third variety of prolapse must be added the copious injection into the bowel of fluids or gases, the introduction of the hand, etc.

The after-treatment of the first two forms of the second variety is substantially the same as that for the first variety, except it should be more vigorously and persistently applied, and the patient be con-

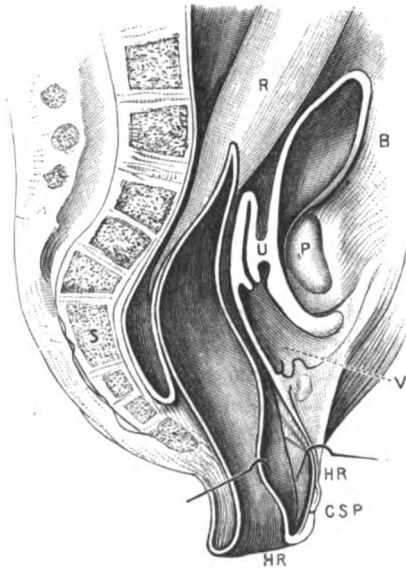


FIG. 633.—Complete prolapse, with peritoneum.
R. Rectum. B. Bladder. S. Sacrum. P. Pubes. U. Uterus. V. Vagina. CSP. Cavity of the peritoneal sac.

fined to the recumbent position and be required to use a bed-pan. It is not advisable in any of the forms of prolapse to resort to the direct removal of the protruding portion by means of the knife or ligature until all other methods have been faithfully tried and have failed.

In the third form of the second variety the question of laparotomy must be considered ; and the answer to the question as to whether it should be performed or not, will depend largely on the symptoms and conditions of the case. Its early performance, however, improves the prognosis for recovery.

Cancer of the Rectum.—Excision of the rectum and colotomy are the only operative measures of radical importance employed in this disease.

Rectotomy, or External Proctotomy.—Place the patient in the lithotomy position, empty the bladder, expose the posterior wall of the rectum by a Sims' speculum, and, with the Paquelin cautery, or with a knife, make an incision through the diseased mass at the posterior aspect of the gut, about four inches in length, carrying it downward through the sphincters. The *écraseur* may be employed, introducing the chain by means of a trocar passed from the tip of the coccyx upward behind the mass, thence into the gut, and dividing the included structures slowly. Rectotomy is only a palliative measure, enabling the bowel to discharge its contents more readily and with less pain. Iodoformized dressings, combined with frequent cleansing, comprise the local after-treatment.

Excision of the Rectum.—Excision of the rectum, either as a curative or a palliative measure, is, at the present time, a generally accepted surgical procedure. It can be stated as a conservative precept, however, that if the upper limit of the growth can not be easily reached with the index-finger, its removal should not be contemplated, owing to the contiguity of the peritoneum. Still, even under these circumstances, if the mucous membrane be involved alone, the diseased structure can be stripped off without entering the peritoneal cavity. If contiguous viscera be involved, or the pelvic lymphatic glands be enlarged, the expediency of the operation is decidedly questionable. Prior to the operation the entire length of the intestinal tract should be thoroughly evacuated, and the rectum cleansed by antiseptic enmata. A large antiseptic sponge, with a string attached, is then pushed up the bowel beyond the disease, to prevent soiling the operation field. The bladder is emptied, and a sound carried into it to guide the operator in making the anterior dissections. An anæsthetic is administered with the patient in the dorsal position, after which the position may be changed to conform to the convenience of the operator. The entire operation should be conducted with strict antiseptic precautions.

Volkman's Method.—This surgeon has described three different operations, intended to meet as many different phases of the disease :

1. *For Removal of a Circumscribed Growth.*—Dilate the anus, pull down the diseased portion, and remove it by an incision so directed that when closed the caliber of the bowel will be diminished as little as possible. If the sphincter have been involved, its fibers should be united after the removal of the growth, and deep drainage provided. If the growth be above the sphincter, after uniting the borders of the wound, deep drainage must be made by allowing the tube to pass through or beneath the sphincter.

2. *For Removal of a Growth involving the Circumference of the Bowel, but not the Anus.*—Divide the anus forward into the perineum and backward to the tip of the coccyx, the latter incision extending to the lower limit of the disease. The morbid growth is dissected out by means of the knife, scissors, fingers, etc. ; the healthy mucous membrane above is carefully stitched to that below, and deep drainage is provided behind and in front, and the antero-posterior preliminary incisions are carefully closed.

3. *For Removal when the Disease involves the Circumference of the Bowel, and Part of or the Entire Anus.*—Make the preliminary incisions as in the second class, and carry a circular incision around the anus, outside of the sphincter, from which the dissection is carried upward parallel with the gut to the upper limits of the morbid growth, which is drawn down, the healthy mucous membrane above it stitched to the cutaneous border, and the disease removed. Deep drainage is then provided, the parts are carefully united, and the wound tamponed with iodoform gauze. If, in case the structure of the bowel is to be cut transversely, as when the morbid growth is being completely separated, the healthy portion be transfixed and tied by several catgut ligatures before the final separation, all danger of hemorrhage from this source is avoided.

Lately, Volkmann has recommended the entire removal of the external sphincter, whether it be diseased or not, as he believes the growth is less liable to return than when it is left. If it be found difficult to draw down the mucous membrane of the bowel sufficiently to readily unite it to the external cutaneous opening, it should be permitted to remain above, and the exposed surfaces below it sprinkled with iodoform or naphthaline, and packed around with antiseptic gauze. A tube of suitable size to discharge flatus and even fecal matter may be then passed up and confined in position. By these simple expedients the raw surfaces may be kept quite clean.

The prostate, and even the base of the bladder, have been removed in conjunction with the diseased rectal tissue, but there is little, if anything, to be said in favor of this measure.

Cripp's Method.—A posterior incision by passing a curved

bistoury into the rectum and bringing its point out at the tip of the coccyx, cutting all the intervening tissue. Separate the parts sufficiently to put the tissue on the stretch, and make lateral incisions from the posterior cut around to the median line in front, on each side, either without or within the anus, according to the location of the disease. These cuts should reach into the ischio-rectal fossæ, and each one be completed in its turn. The dissection is carried above the point of the disease in the usual manner, the bowel drawn downward, and the morbid growth removed with an *écraseur*.

Maisonneuve's Method.—A circular incision is made around the anus, through the integument and subcutaneous tissue, and a long, strong needle, bearing at its point a ligature one foot in length, is passed upward through the external incision outside the bowel into the gut above the growth. The loop of the ligature is seized at the eye of the needle and drawn out of the anus, while the needle retraces its course, thus depositing a double uncut ligature, one end hanging by the anus, the other lying in the primary incision. A sufficient number of ligatures are thus deposited, at equal distances from each other, to include the entire circumference of the gut. A strong whipcord, about six feet in length, is now passed through the loops hanging from the anus, leaving an interval of about ten inches between each loop. The ligatures are then drawn outward by seizing the extremities in the external cut, thereby drawing the whipcord through the openings made in the bowel by the receding ligatures. Each loop of the whipcord is allotted in turn to an *écraseur*, and the portion of the rectum included by it is cut through.

Results.—The rate of mortality following this operation is from twenty to twenty-five per cent. The operation is a proper one, under favorable conditions, and will prolong the life of eighty per cent of the patients, and effect a cure in a small proportion of them.

Stricture of the Rectum.—Ordinarily a stricture of the rectum is treated upon substantially the same principles as a stricture of the urethra: the repeated use of rectal bougies passed in the direction of its curvatures; nicking its edges with a probe-pointed knife; division, elastic distention, rectotomy, and, finally, if the stricture be high up, colotomy.

Imperforate Rectum (Fig. 634).

—This form of occlusion varies in

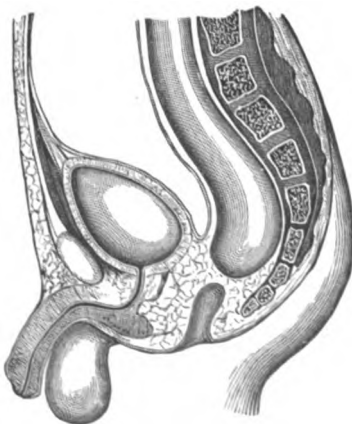


FIG. 634.—Imperforate rectum.

thickness, and is usually situated within half an inch of the anus, which is normal. If the structure be thin, it will be influenced by the emotions of the child and depressed by the superimposed fecal accumulations.

Operation.—A radiating incision, with its center corresponding to that of the obstruction, can be made through the tissues, the contents of the gut evacuated, the flaps trimmed off, and the opening maintained by the occasional introduction of a well-oiled bougie. Sometimes the occlusion is so thick as to raise the question as to the presence or absence of the gut above. The sigmoid flexure may terminate in a blind point, while the rectum below

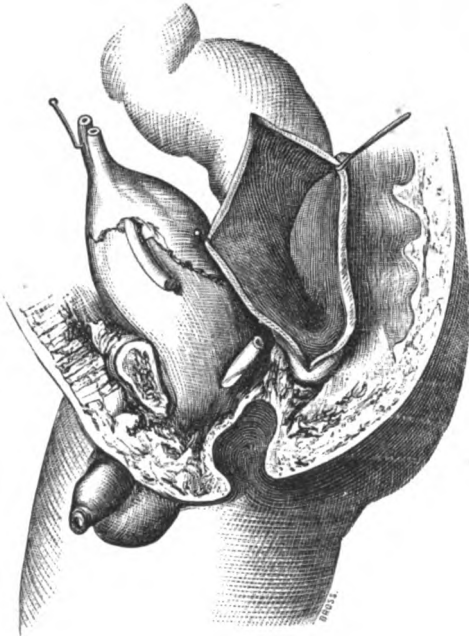


FIG. 635.—Rectum ending in blind pouch.

is marked by an impervious cord (Fig. 635). An attempt should always be made to find the blind extremity, which is done by introducing a sound into the bladder and carefully seeking, by aid of the scissors and finger, for the *cul-de-sac* above. In doing this, the established relation which the rectum bears to the curve of the sacrum must be carefully regarded, and the fibrous trace of the rectum sought after. If the abdomen of the patient be pressed upon, any existing tumor above will be made more distinct and tense. If the *cul-de-sac* be found, the diagnosis should be still further strengthened by exploring it by means of a hypodermic syringe or a small aspirating needle carried into its posterior aspect. If fecal matter or offensive gases be detected, the blind extremity of the gut is drawn carefully downward toward the external opening, and held in this position by forceps or by a loop of thread passed through its apex while it is opened carefully, the incision into it being guided by the exploring needle, which is allowed to remain for that purpose. After the contents are evacuated and the parts are thoroughly cleansed, a sponge with a string attached to it is pushed up the bowel to prevent any further escape of fecal matter while the extremity of

the bowel is being sewed to the surface below—if practicable, to the cutaneous border. When this step is impracticable, the after-treatment should be the same as that following excision of the rectum. If the extremity of the bowel be not found, colotomy must be performed. Not infrequently the rectum communicates with the bladder, and even the glans penis, conditions which are determined by the fecal character of the urine. In these cases the bowel should be sought for, and, when found, drawn down and stitched as before, and the fecal canal kept open by the frequent introduction of a well-greased finger or a suitable bongie. The fistulous openings are closed with catgut, suitable drainage provided, and the contents of the bladder evacuated at short intervals, to prevent its distention during the healing process.

CHAPTER XVI.

OPERATIONS ON THE URINARY BLADDER.

THE cavity of the bladder may be explored by catheters, sounds, and searchers; its outer surface by rectal and abdominal palpation. Catheters can be practically divided into the soft rubber, silk, gum-

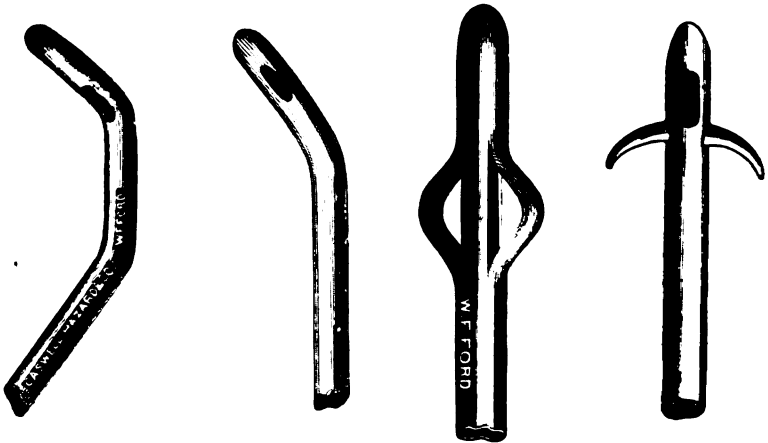


FIG. 636.—Mercier's double elbow catheter.

FIG. 637.—Mercier's elbow catheter.

FIG. 638.—Self-retaining catheter.

FIG. 639.—Bak's self-retaining catheter.

elastic, and metal varieties. The first two varieties are simple, and are most innocent instruments in the clump

636, 637, 638, 639, 642, and 643). It is sometimes necessary that a soft rubber catheter be provided with a guide in order to properly direct it as well as to overcome any slight impediment in its course (Figs. 640 and 641). The gum-elastic and metal instruments are too familiar to all to require a description, except such of them as have been especially modified for distinct purposes.

Introduction of a Catheter or Sound into the Bladder.—Select an instrument of a suitable curve and size; place the patient on the back, with the shoulders somewhat raised, and the thighs slightly flexed on the abdomen, and rotated outward to relax the abdominal muscles; warm and smear the instrument

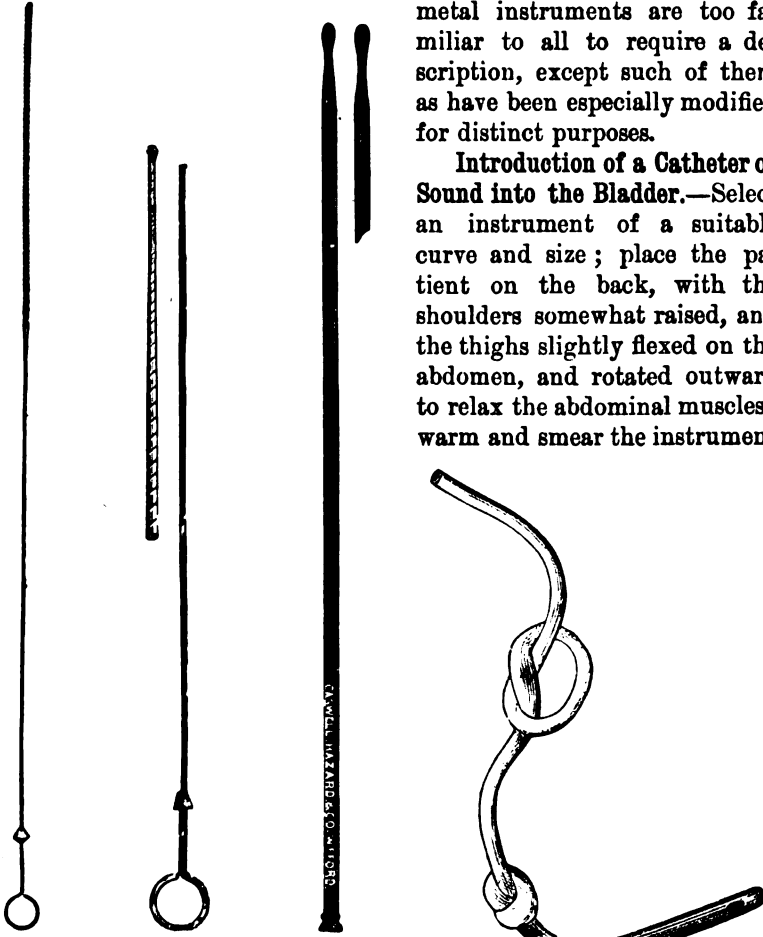


FIG. 640.—Keys' catheter-guide.

FIG. 641.—Otis' catheter-guide.

FIG. 642.—Ollivary gum catheter.

FIG. 643.—Velvet-eye catheter.

with oil or vaseline; stand on the left side of the patient; grasp the penis with the middle and ring fingers of the left hand and raise it vertically. The catheter or sound is then taken lightly between the thumb, index, and middle fingers of the right hand and introduced into the meatus, held open by the left index-finger and thumb. The instrument and penis should now be carried close to the body in the

line of the groin. The penis is then gently drawn over the instrument, which at the same time is carefully pushed, or allowed to enter by its own weight, into the canal. After about five inches of the instrument have disappeared, the outer extremity should be carried toward the median line of the body of the patient and elevated slowly to a vertical position, when its weight will usually cause the advancing end to pass beneath the pubes (Fig. 644), after which the upper extremity is depressed between the thighs, causing the point to enter the bladder (Fig. 645). Not infrequently the end

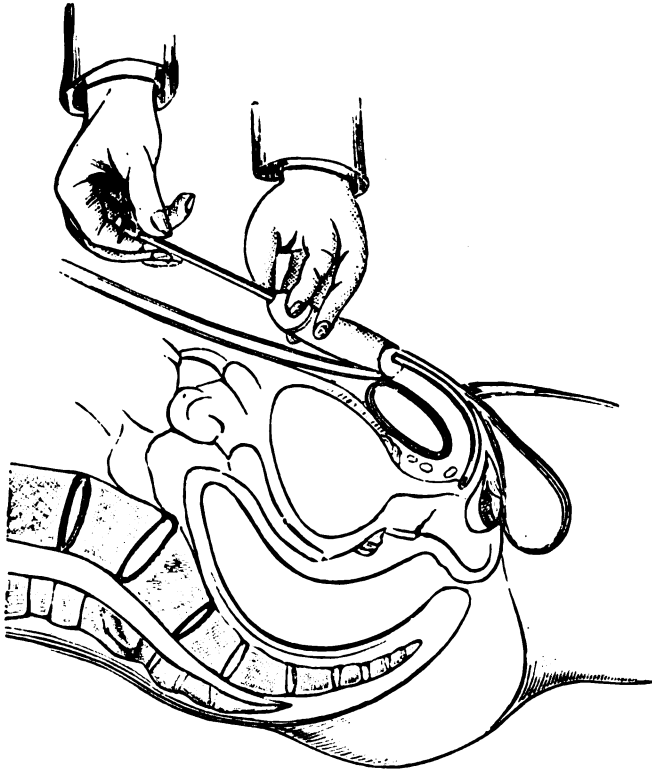


FIG. 644.—Passing catheter.

will hitch upon the triangular ligament as it passes beneath the arch of the pubes. This can be obviated by raising the point of the instrument at this situation by the finger pressed firmly against the median line of the perineum, accompanied by upward traction as the point is being advanced; in a word, causing the instrument to hug the roof instead of the floor of the canal. The beginner is apt to carry the handle of the instrument between the thighs too soon, causing the beak to be reversed in front of the pubes. Un-

der no consideration must violence be employed in introducing a catheter, *ars non vis* being an almost traditional axiom in this connection. The surgeon should always follow the advancing end of the instrument with the mind's eye, aiming to keep it in the axis of the urethral curve. The first approach of the instrument to the perineal

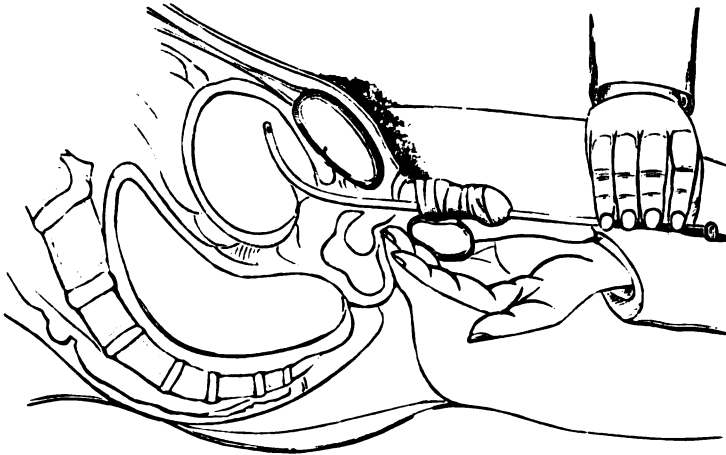


FIG. 645.—Catheter entering bladder.

portion of the urethra not infrequently causes a contraction of the muscles of this region, which interposes an effectual temporary obstacle to its advancement. If, however, the patient's attention be engaged in conversation or otherwise diverted from the procedure, while at the same time the end of the instrument is pressed continuously and carefully against the obstacle, it will soon give way and enter the bladder without further trouble. If it be a catheter, the flow of urine usually announces its entrance into the bladder. However, if the eye of the catheter be obstructed, or a sound be introduced, the exact situation of the instrument may be determined by rotating it on its long axis; when, if the beak be in the viscus, its extremity will describe the arc of a circle around its shaft as a center; if not, then the shaft will describe a circle around its beak. If the bladder be empty or contracted, the impinging of the beak upon its walls may deceive the beginner and also cause the patient much pain. The introduction of the index-finger into the rectum will aid in guiding the instrument into the bladder, and determine the fact of its entrance as well. Hot fomentations to the abdomen, together with an anodyne and a ten-grain dose of quinine, should be employed if a urethral chill be feared. The injection into the urethra of a weak solution of carbolic acid and oil after the passage of the sound is thought to sometimes prevent urethral chills.

Retention of Urine.—Retention of urine depends upon some obstruction to its egress, located at the neck of the bladder, or in the course of the urethra; also upon paralysis of the muscular coats of the bladder, or upon both combined.

The indications are met by overcoming the obstruction or restoring tone to the bladder. If the obstruction be due to stricture, and it be permeable, catheterization will effect ready relief. It is important to know, however, that the bladder should not be entirely emptied of its contents, but that only a sufficient amount of urine should be drawn to afford complete relief from all pain and tension. If it be completely emptied, its walls will collapse from want of support, causing congestion of its lining, and, in all probability, the catheter will be required at the next attempt at urination. If but a third or a half of the contents be withdrawn, the bladder will probably expel its contents properly at the next act of micturition. If it be impossible to introduce an ordinary catheter, even of a small size, recourse must then be had to the filiform bougies (Fig. 646) or whalebone guides (Fig. 647).




FIG. 646.—Filiform bougies.

The latter are more commonly employed. The patient is placed in the dorsal position, an anæsthetic given, unless the bladder be much distended—as then there is danger of its rupturing during the struggles of the patient. If anæsthesia be necessary under such a circumstance, it is advisable to relieve the bladder of some portion of the fluid by supra-pubic aspiration. If one be not entirely familiar with the use of the whalebone guides and the retention catheter, local or general anæsthesia is not advisable, as then the patient's sensations can not be consulted, and great harm might arise from their use.

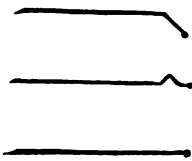


FIG. 647.—Gouley's whalebone guides.

Introduction of Whalebone Guides.—The urethra is forcibly filled with sweet-oil by means of a syringe, and the end of the penis grasped to retain it as long as possible, leaving sufficient room at the meatus for the introduction of a whalebone guide. The guide is carefully introduced, and if its point becomes engaged in a lacuna, it is withdrawn a little and again carried onward with a rotary motion. If it enters a false passage, it is allowed to remain there, while another guide is passed by its side. If a second enters the false passage, it is treated in a similar manner, and so on until four or six, or even more, are contained in the canal, some of which have the spiral and others

the straight end foremost. Each one is then taken separately and pressed onward with or without the spiral twist, always remembering to use no force, else the small points may pierce the mucous membrane of the urethra, or enter and perforate Cowper's ducts. As soon as all the side openings are closed by the extremities of the guides, one guide will be found to have entered the stricture, and with a little coaxing will pass into the bladder, which is known by the painless ease with which it can be moved in and out. The others are then withdrawn, and the end of the one remaining is passed through the eye of a tunneled sound (Fig. 648), or, what is better, the tunneled catheter (Fig. 649). This guide serves to direct the passage of the instrument into the bladder, which should be done cautiously, as the guide may be cut by the eye of the instrument, causing it to double and lead the end of the catheter astray. The instrument is known to have entered the bladder if urine flows from it, or if its innermost extremity can be turned from side to side. After the requisite amount of urine is withdrawn, a tunneled sound of larger size may be passed in a similar manner as the catheter, after which the guide can be taken out and an ordinary steel sound of small size carefully introduced to insure a channel of sufficient capacity to admit the ready entrance of an instrument thereafter.

Aspiration of the Bladder.—The contents of the bladder can be removed by aspiration by introducing the aspirating needle into it above the pubes, at the point indicated for the passage of a trocar (Fig. 657). This, however, is a temporary measure only. The same can be said of tapping per rectum. These are important expedients to enable the surgeon to gain time for the performance of external perineal urethrotomy.

Rupture of the Bladder.—
Rupture occurs

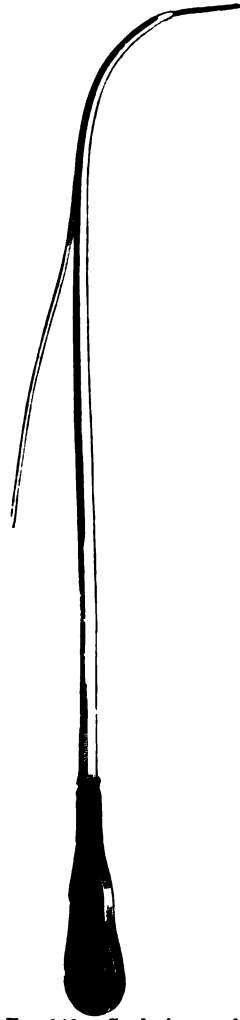


FIG. 648.—Gouley's tunneled sound.

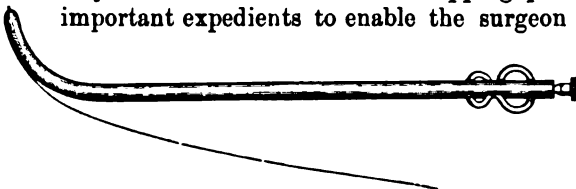


FIG. 649.—Gouley's tunneled catheter and guide.

most frequently on the posterior surface, involving the peritoneum, and allowing the urine to escape into the abdominal cavity. When the rupture occurs anteriorly, the extravasated urine infiltrates the perineum and the anterior walls of the abdomen.

Free incisions to relieve the extravasation and the performance of cystotomy, together with the opening of the abdomen in the median line—laparotomy—to remove the urine contained in its cavity, are the practical operative procedures.

Cystotomy.—This operation consists in opening into the bladder through the median line of the perineum, as in the median operation for stone. Place the patient on the back, evacuate the rectum, introduce a grooved staff into the bladder, and with a sharp knife make an incision in the median line about two inches in length, terminating about half an inch in front of the anus; by repeated applications of the knife the staff is reached and the membranous urethra opened backward to the apex of the prostate. Introduce a small probe into the bladder by way of the groove in the staff, withdraw the staff cautiously, introduce the index-finger into the bladder along the probe as a guide, and distend the neck of the bladder sufficiently to cause the urine to escape as fast as it flows into the bladder. The prostatic structure must be well dilated, else it will soon return to its normal condition and require a repetition of the dilating process. The prostate may be incised on either one or both sides, as in lateral and bilateral lithotomy; it is necessary to do so to maintain the patency of the opening for any length of time. Cystotomy is now quite frequently performed as an ultimate expedient in obstinate cystitis in both sexes. In the female the incision is made into the bladder through the vagina.

Prognosis.—The operation implies about the same danger to life as the median operation for stone in the bladder.

Digital Exploration of the Bladder.—This procedure is resorted to for the purpose of detecting encysted calculi, polypoid and other morbid growths, and to settle many vexatious questions relative to the bladder cavity. It must of necessity be preceded by a preliminary cystotomy.

In order to properly accomplish the purposes of an exploration, anæsthesia to complete muscular relaxation is essential; the finger-tip must enter the bladder, which should be empty and be depressed by supra-pubic pressure.

Instruments such as forceps, scoops, curettes, etc., of various sizes and patterns, can then be introduced into the organ to remove the offending agent.

After the operation the bladder is washed out, and a large-sized catheter is introduced through its neck to drain it of its contents for four or five days, and the occurrence of hemorrhage carefully watched for.

Prognosis.—The digital exploration of the bladder of itself implies no especial danger to the patient if the kidneys be sound, but cystotomy and removal of morbid growths, especially of a villous character, by crushing or curetting, may, in the latter, give rise to severe if not fatal hemorrhage, or cause death from blood-poisoning. This operation is reported to have been performed frequently, but the results are not sufficiently definite to enable one to estimate a percentage, although they are such as to establish the entire justice of the measure in severe cases.

Extroversion of the Bladder.—In extroversion of the bladder the anterior wall of the bladder and abdominal parietes are absent, while the posterior and inferior portion of the bladder protrudes through the opening in the abdominal wall on account of the pressure of the viscera behind it. Various measures have been attempted to establish a more feasible channel for the escape of urine, none of which, however, have afforded any practical benefit. Mr. Simon made an attempt to connect the ureters with the rectum, but with indifferent success. Floyd and Johnson attempted to establish a fistulous communication between the bladder and rectum by means of setons, but the patient died shortly after from peritonitis. The methods by auto-plasty are the most rational, and have in many instances afforded substantial relief.

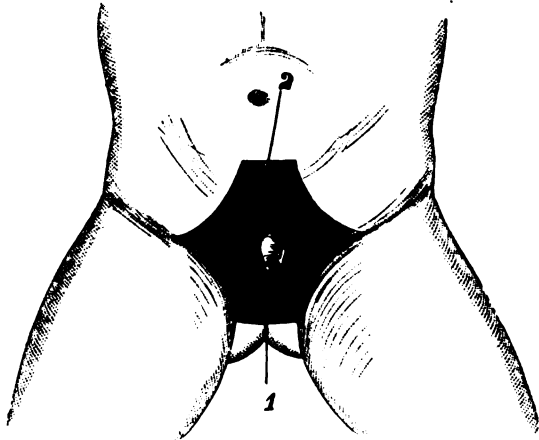


FIG. 650.—Maury's operation.

Dr. F. F. Mau-ry's Operation.—

Make a curvilinear incision, with the convexity upward, on each side, extending from the outer third of Poupart's ligament downward and inward below the scrotum to the middle of the perineum, at which point they become joined (Fig. 650). This flap, 1, is dissected upward over the scrotum to the root of the penis, which is slipped through a valve-like incision made at its base, thus permitting the urine to escape without coming in contact with the raw surfaces. A second or abdominal flap is now raised transversely across the abdomen, extending upward from below the umbilicus. The lower flap, 1, is then turned upward to bring its cutaneous surface in contact with the mu-

cous surface of the bladder (Fig. 651, 2), and the cuticle is removed from all portions of it that are to be placed in contact with freshened

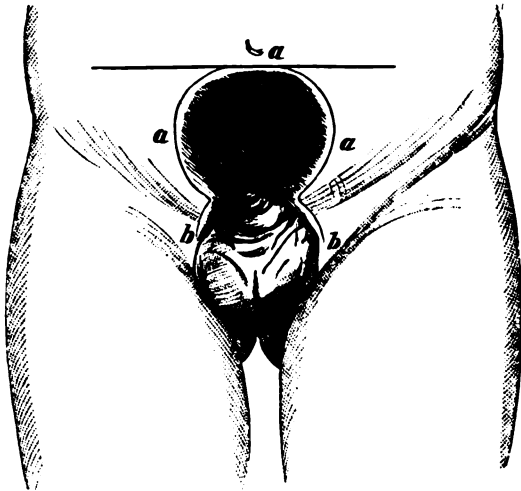


FIG. 651.—Bigelow's method.

surfaces. The edges of the lower flap are then beveled and carried under the upper flap, to which they are united by catgut sutures. This method offers the best results in operations upon males. Bigelow dissected off the mucous membrane of the exposed bladder down to a line with the ureters, constructed lateral flaps from each inguinal region (Fig. 651, *a*, *b*), united them in the median line and

above (Fig. 652), and thereby secured a perfect result.

Wood's Method (Fig. 653).—This is best adapted to female subjects,

and consists in making a central or umbilical flap, *a*, and turning it downward over the bladder, after which a flap is made from each groin, *b*, *c*, and carried inward over the everted central one and united in the median line to the other (Fig. 654). This arrangement brings the integumentary surface of

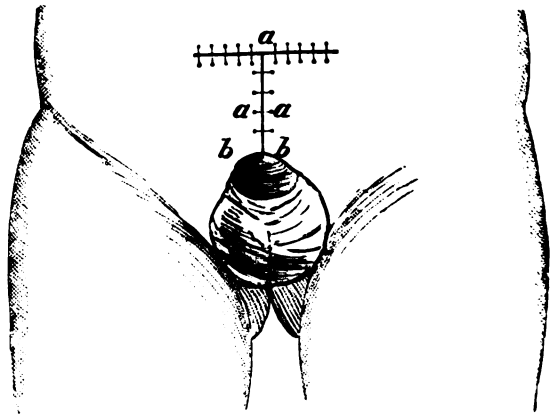


FIG. 652.—Bigelow's flaps united.

the central flap in contact with the mucous surface of the bladder, and the raw surfaces of the central and lateral flaps are apposed; the uncovered raw surface above being allowed to heal by granulation.

Dr. Pancoast raised two flaps, one from each inguinal region, joined them together in the median line, and allowed the raw external surface to cicatrize.




FIG. 653.—Wood's method.

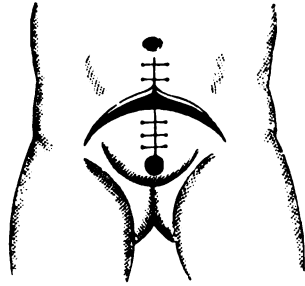


FIG. 654.—Wood's method. Flaps in position.

Ayres covered the opening by turning down an umbilical flap with its raw surface uppermost; this surface, together with that from which it was taken, was covered by two broad flaps dissected from the abdomen at both sides, of sufficient width to fill the gap when joined together in the median line.

Results.—Some fifty-five cases have been operated upon by one method or another, with the satisfactory results of forty-three successful cases. Four were failures, and eight fatal.

Puncturing the Bladder (Fig. 657).—Puncturing the bladder is done to relieve the organ from over-distention. It can be done above or below the pubes, and through the rectum.

It may be performed with the ordinary curved trocar (Fig. 655), or with the aspirator, the latter being the safer and more satisfactory.

Above the Pubes (Fig. 657).—Place the patient




FIG. 655.—Rectum trocar.

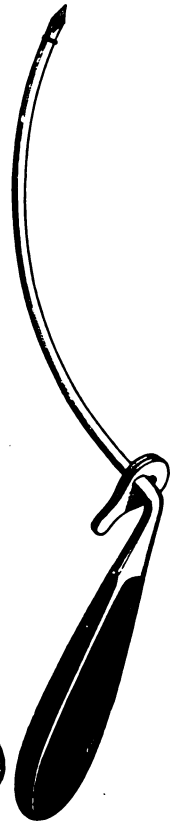

FIG. 656.—Buck's rectum trocar.

on the back; outline the distended bladder by percussion; explore the tumor with a hypodermic needle if a doubt exists as to its nature.

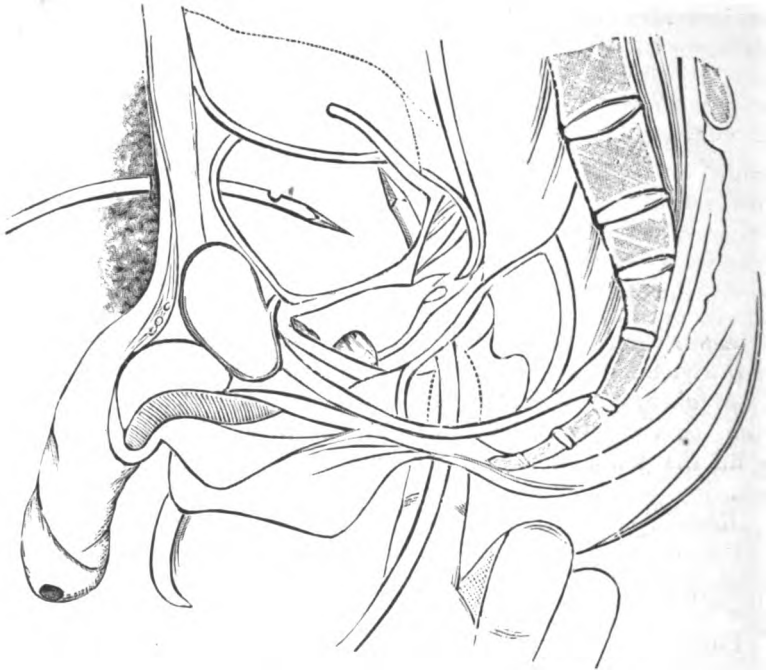


FIG. 657.—Puncturing the bladder.

Select a small straight or curved trocar, the latter being the better; make the skin tense about an inch above the pubis, and push the trocar through the median line with its convexity upward. An initiatory incision through the skin is often made with a sharp knife which permits the easier entrance of the trocar. An injection of cocaine may relieve the patient of the pain caused by the introduction of the trocar.

Under the Pubes.—If the bladder be small and shrunken behind the pubes, or the prostate be too large to admit of the rectal puncture, the penis can be pulled downward, and a small curved trocar, with the concavity upward, passed just beneath the arch of the pubis into the viscus.

Through the Rectum (Fig. 657).—Place the patient in the lithotomy position; introduce the left index-finger into the rectum; locate the vesiculæ seminales and base of the prostate; place the end of the finger between the former, allowing it to rest upon the base of the prostate; along the palmar surface of the finger, a curved trocar (Figs. 655 and 656) is then carried just above the base of the prostate, and

pushed into the bladder; the canula may be tied in position, or a soft catheter substituted therefor, by passing it through the canula.

The almost universal practice of using some form of aspirator, and the superiority of this instrument over the trocar, are fast consigning the latter to an honorable remembrance only.

STONE IN THE BLADDER.

This morbid condition is quite common, and usually is accompanied by well-marked and characteristic symptoms. Sometimes, however, calculi of inordinate size, and with unusual asperities, are attended by only trifling manifestations. When it is suspected that a stone may be in the bladder, the proof of its presence is sought by aid of a searcher. There are various patterns of this instrument (Figs. 658, 659, and 660). The one devised by Thompson is most commonly employed. It can be used for the double purpose of regulating the amount of water in the bladder, by injection or by out-flow, thereby better accommodating the bladder-walls to the remaining function of this instrument—sounding for stone.

Sounding.—The time selected should be when the patient is suffering the least from the bladder difficulty. If the patient be a child, an anæsthetic should be given; if an adult, only when he is extremely restless from the pain. Two or three ounces of a two-per-cent solution of cocaine have been employed successfully in the bladder to relieve the pain and irritation of sounding and even of crushing. The urine of one or two hours' secretion should be collected in the bladder, or its equivalent, four or five ounces of water, should be injected before attempting the sounding.




FIG. 658.— Thompson's searcher.
 FIG. 659.— Lit- searcher.
 FIG. 660.— searcher.

Place the patient on the back with the hips raised, the operator standing upon the right side. Introduce the searcher in substantially the same manner as that employed to introduce a lithotrite (page 429); then push it carefully to the posterior wall of the bladder, with the beak upward; withdraw it slightly to give easy play to the end, and then carefully turn the beak from side to side, until the lateral walls of the bladder are touched by it. This is done by rotating the instrument on its long axis between the thumb and finger. In this manner the whole inner surface of the bladder is examined, the instrument being withdrawn each time a sufficient distance to accomplish this object thoroughly. As soon as the beak comes in contact with the neck of the bladder it can be withdrawn. If the prostate be enlarged, the handle should be depressed, and the beak turned toward the floor of the bladder and rotated from side to side while it is being gradually withdrawn. This manœuvre will be quite sure to detect the stone if it be lodged behind that body.

If a stone be not detected, it is better to make a second and even a third examination before positively asserting that none is present. Five or ten minutes is quite sufficient time to employ at one sitting. If the presence of stone be detected, the number, size, and the probable consistency should be determined. After the searching is completed, apply warmth to the hypogastrium, give an anodyne along with ten grains of quinine, and keep the patient quiet.

The ability to detect the "click" from small fragments by aid of the searcher is greatly enhanced by the attachment of the so-called "lithophone." This attachment can be extemporized by taking a piece of rubber tubing, twenty-five or thirty inches in length with an eighth-inch caliber; double one end upon itself and place it against the handle of the searcher, allowing also the tubing continuous with it to lie along the handle, or push it into the open end of the handle of the searcher. The other extremity is then placed in the ear directly, or connected to it by the medium of an otoscope. The ability to detect fragments of an almost infinitesimal size is said to be thus attained. The washing process of litholapaxy may also cause the "click."

Lithotrixy, litholapaxy, and lithotomy are the only practical methods of relief in the male.

Lithotrixy is the reducing of stone to fragments so minute as to allow of their easy escape with the urine through the urethra.

The instruments used to effect the reduction are called lithotrites, of which there are several varieties (Figs. 661, 664, and 667). The ones devised by the ingenuity of Thompson, Bigelow, and Keyes are most frequently used. For this operation the patient should be in a good condition, and the urethra of suitable size to admit the lithotrites; he is required to hold the urine for an hour or two, and is then placed upon the back with the pelvis elevated; the older the

patient, the greater the elevation should be. An anæsthetic may be given, and should be administered if it be the intention to triturate the entire mass at one sitting; or, if the patient be irritable, or the bladder over-sensitive.

Introduction of the Lithotrite.—The operator having chosen and well oiled a suitable instrument, stands upon the right side of the patient, taking the penis in the left hand, inserts the beak and draws the member upward upon the instrument, which is tightly grasped by the right. The handle is then slowly raised until the shaft becomes vertical, when it is transferred to the left hand, and the fingers of the right are placed on the perineum to follow the angle of the beak as it advances. The weight of the instrument will cause it to sink low enough to permit the beak to engage the opening of the triangular ligament, through which the urethra passes. A little careful manipulation, aided by




Fig. 661.—Thompson's lithotrite.




Fig. 662.—Fenestrated jaws.

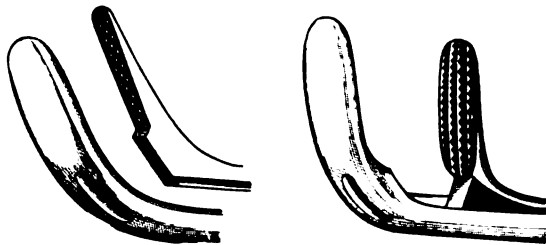


Fig. 663.—Non-fenestrated jaws.

the right hand on the perineum, will cause it to enter this portion of the canal, when the handle of the instrument should be taken by the right hand, and allowed to fall slowly of its own weight between the thighs. If the instrument be now slightly pressed upward, its upper extremity will be found to be disengaged, and can be easily ro-

tated upon its long axis. If the prostate be enlarged, it increases the length of the deepest portion of the urethra, and interposes an obstacle to its progress. The handle should not, therefore, be depressed so rapidly during the latter stage, and the instrument must be pushed farther upward. Under no consideration should any undue force be used. The weight of the handle is of itself sufficient, unless under proper control, to cause laceration of the soft urethral tissues.

The instrument is pressed upward in the line of its entrance until it reaches the posterior wall of the bladder, unless its course be sooner interrupted by the stone, when the beak is turned from the stone and the male blade withdrawn; then the separated blades are turned toward the stone, which is seized and fixed. The beak is now turned upward—care being taken to observe that the mucous lining of the bladder is not caught—and the fragment crushed. The blades are again separated and turned sidewise to catch the resulting fragments, which manœuvre is continued until the sitting is completed.

During the crushing, the female blade must be held firmly and remain entirely passive, and the blades should only be separated sufficiently to admit the stone between them. If the beak be not turned away from the stone before it is opened, the stone may be displaced by the separation of the blades. While it is true that, in a large majority of cases, the plan of action just described will suffice, still, in those where the prostate is enlarged, or an excavation exists at the base of the bladder from another cause, it may become necessary to reverse the beak of the instrument, causing it to look toward the rectum. To do this properly, the handle of the instrument is depressed until the beak is elevated sufficiently to allow of its revolution without impinging upon the walls of the bladder. If the simple reversing of the instrument does not bring it in contact with the stone, the beak should then be turned in various directions with care. Another manœuvre, which in the case of small stones located behind the prostate will often prove successful, consists in drawing the reversed beak outward until it nearly touches the prostate, and then separating the blades by pressing the female blade backward until it strikes against the posterior wall of the bladder, the male blade being held firmly in position; raise the handle until the female blade rests lightly upon the floor of the bladder, then draw it forward to join the male blade, lightly touching the floor in its course. If a stone lies in the line, it will be touched, and, moreover, the mucous membrane will not be pinched. It is better that the blades be smooth in these reversed movements.

During this antero-posterior manipulation the neck of the bladder should be carefully preserved from any unnecessary contact with the instrument. When the sitting is completed the blades must be screwed firmly together, that the instrument may be withdrawn with-

out injury to the urethra. Each sitting, if without anæsthesia, should not exceed five or ten minutes; with it, a sitting can be prolonged until an ordinary calculus is reduced to fragments. The intervals of the crushing will depend upon the size of the stone, its hardness, and more frequently the effect of the crushing upon the patient. Inasmuch as the conditions differ greatly, it is impossible to lay down

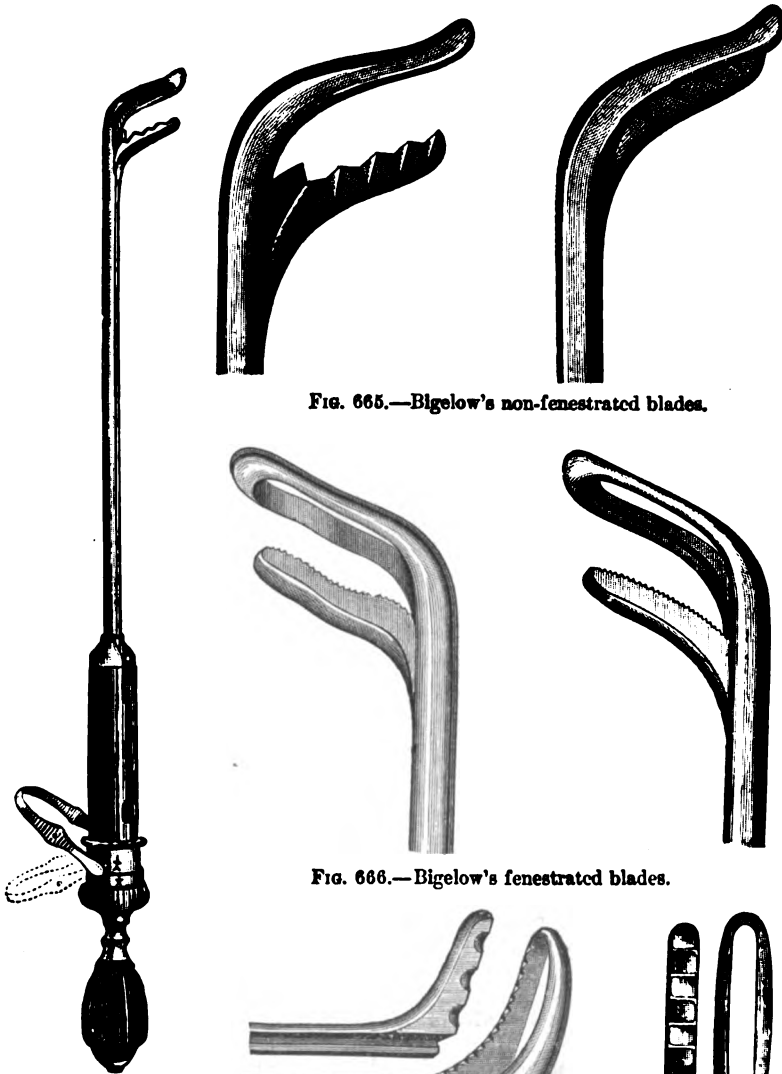


FIG. 665.—Bigelow's non-fenestrated blades.

FIG. 666.—Bigelow's fenestrated blades.

FIG. 664.—Bigelow's lithotrite.

FIGS. 667, 668.—Keyes' modified blades.

any stereotyped rules. The surgeon should not repeat the operation until the subsidence of the irritation produced by the previous attempts. Villous growths of the bladder, and deformities which interpose a mechanical obstruction, are the principal contraindications to lithotripsy. After the completion of the sitting the patient is given an anodyne, and hot fomentations are applied to the abdomen, and he is caused to remain in the recumbent posture for twenty-four hours subsequent to the operation, even to the extent of lying on his side during micturition.

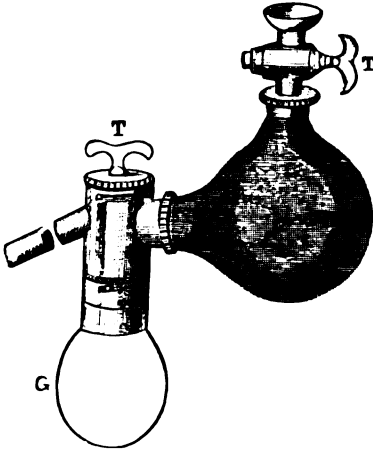


FIG. 669.—Thompson's washer.

Results.—The rate of mortality is about eleven per cent.

Rapid Lithotripsy, or Litholapaxy.—The crushing and washing out of a stone at a single sitting has supplanted the ordinary lithotripsy.

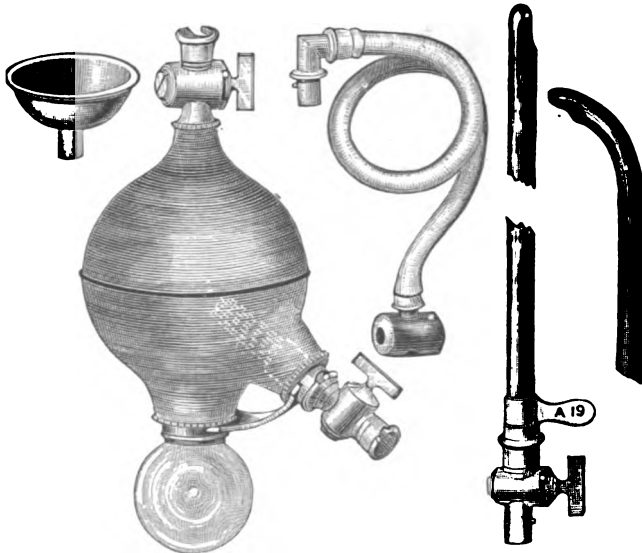



FIG. 670.—Bigelow's washer.

The instruments usually employed in this procedure are the lithotrites of Thompson or Bigelow, as shown in Figs. 661 and 664, the latter being in common use. The blades of lithotrites differ in their grinding surfaces from a simple roughening to a well-marked denticu-



lation. The blades of Bigelow's instruments present appearances peculiar to themselves (Figs. 665 and 666). The instrument used by

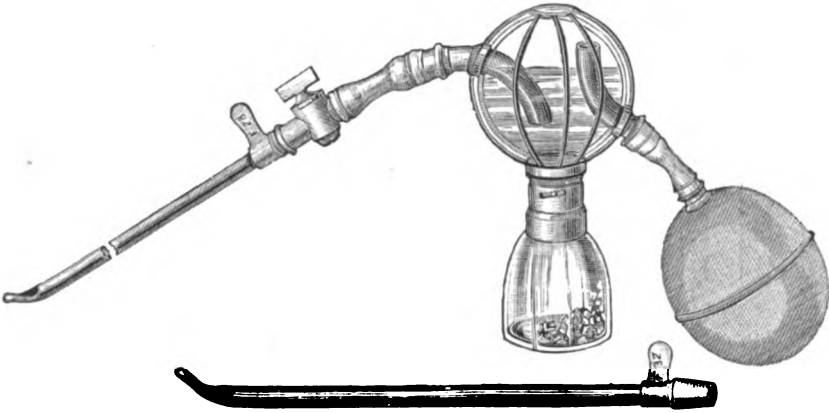


FIG. 671.—Otis' washer, ready for use.

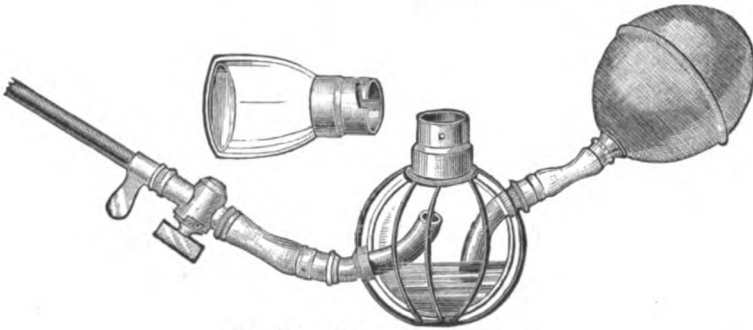


FIG. 672.—Otis' washer, inverted.

Dr. Keyes is of a stronger pattern than is usually employed, and is provided with a large wheel at the end, that a greater force may be quickly applied. The blades are fenestrated (Figs. 667, 668), and are so constructed that they can not clog. The operator should possess lithotrites of two or three sizes and of different patterns, to enable him to comply with the demands of individual cases, as modified by the hardness and size of the stone, size of the urethra, etc. For crushing large and hard stones, a fenestrated blade should be employed. If the stone be small and friable, the blades may be roughened only, with the




FIG. 673.—Bigelow's evacuating catheter.

male blade much the smaller. A non-fenestrated or "scoop" lithotrite can be used to crush the smaller fragments. The larger and

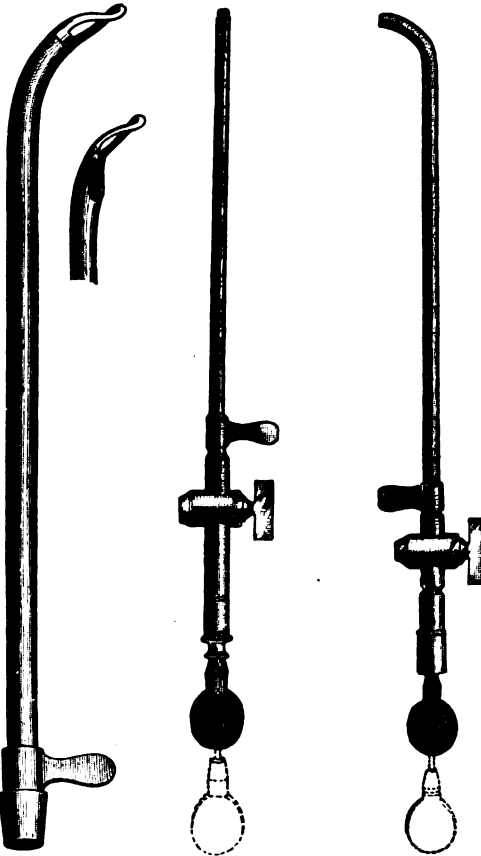


FIG. 674.—Warren's spiral-tipped evacuating catheter.

FIG. 675.—Keyes' straight tube and guide.

FIG. 676.—Keyes' curved tube and guide.

harder the concretion, the stronger should be the instrument employed. In addition to the instruments for crushing, the operator must be provided with an evacuator or washer. The Thompson washer is admirable (Fig. 669), and the latest pattern by Bigelow leaves but little to be desired in this respect (Fig. 670). Otis' washer is simple, cheap, and efficient (Figs. 671, 672).

The evacuating-tubes of Bigelow (Fig. 673), or their modifications, complete the outfit. The spiral-tipped tube of Warren (Fig. 674) and the straight, open-ended one of Keyes (Fig. 675), are thought to fa-

facilitate the discharge of the *detritus*, while in the latter instance especially the lining membrane of the urethra is not exposed to injury from a fragment lodged in the eye of the instrument during its withdrawal from the bladder. The size of the tube commonly employed varies from 16 to 18, English scale.

The *contraindications* to the operation are of a limited number.

It is not admissible, if the bladder be sacculated and affected by cystitis, or if it be ulcerated, or intolerant of the presence of instruments. Repeated and severe chills following the introduction of instruments into the urethra and bladder contraindicate the operation. If the organ contain morbid growths, or, if the patient be feeble, es-

pecially if the stone be large and hard, crushing should not be attempted.

The preparatory treatment consists in alleviating all symptoms dependent upon the existence of the stone, and in preparing the urethra for receiving the instruments by increasing its size if necessary, and subduing any undue sensibility of it.

Operation.—An assistant, besides the one to administer the ether, must be present to empty the washer and adjust it. The bladder should contain four or five ounces of fluid, which condition is best obtained by causing the patient to retain the urine for two or three hours prior to the operation; or, if it be empty, a similar amount of tepid carbolized water must be injected. If the contents of the bladder be offensive, empty it and wash it out with a tepid solution of borax, a drachm to the pint, before beginning the operation.

The patient is placed on the back, complete anæsthesia secured to insure perfect quiet, pelvis elevated, thighs slightly flexed and rotated outward.

The method of introduction of the lithotrite, and the process of catching and crushing the stone, are similar in this operation to the ordinary method, except that the crushing process is interrupted by the introduction of the evacuating catheter as soon as the stone is well broken. This may be within five or ten minutes after the introduction of the lithotrite, depending, of course, upon the success attending the efforts of the operator. A well-oiled evacuating catheter is then passed down to the prostatic urethra, and the washer is attached while it is in this situation to avoid the entrance of air into the bladder. The air in the catheter while it is thus located will, if water be forced gently into it, pass upward through the water in the washer and remain in the air-trap above, after which the evacuating-tube is carried on into the bladder. If, now, the elastic, half-filled bulb be alternately compressed and expanded, the changing current thus produced will wash the fragments from the bladder, and their weight will precipitate them into the glass receiver beneath. If all the fragments be not removed—which can be ascertained by the introduction of a searcher—the process of crushing is again resorted to, and the resulting comminutions treated as before until the entire stone is removed. The last fragments not infrequently elude the grasp of the instrument, and, were it not that they can be heard to strike the evacuating catheter when the water is drawn upward, their existence might not be known. If the curved tube be used, the beak should be turned from side to side to present its eye to different aspects of the bladder, while the square-ended tube of Keyes is passed just beyond the neck of the bladder, and its external extremity is well lowered between the thighs. It is better some-

times to allow these fragments to remain until the patient has recovered from the operation, and then seek for them again, than to continue indefinitely the attempt to secure the last one at the first sitting. Very small fragments which escape detection are not infrequently passed with the urine within four or five days after the operation.

The limit of time to which the first crushing may be prolonged is not an arbitrary one; an hour or two is not unusual, and even a longer time may be employed. However, an hour is a safe rule to adopt.

After the operation the patient is kept quiet in bed and well wrapped; if retention occurs, it is relieved by a catheter.

Sequels.—Litholapaxy has various sequels—rigors, retention of urine, cystitis, impaction of stone in the urethra, pyæmia, atony of the bladder, suppression of urine, etc.—all of which should be treated on general principles. Under ordinary circumstances the patient will be up and around at the end of a week or ten days.

Results.—The rate of mortality is about three and one half per cent.

Combined Crushing and Evacuating Instrument.—The idea of the possible utility of such an instrument suggested itself to me some time since, after a somewhat annoying effort on my part to seize the “last fragment,” the existence of which could be easily and quickly demonstrated by the characteristic click against the eye of the evacuating catheter during the washing-out process. I also recalled the fact that, on other occasions, the suction-force of the washer had been temporarily arrested by the closure of the eye of the evacuating catheter by a fragment of calculus. The male blade of an ordinary lithotrite is modified to fit the anterior or concave wall of the ordinary evacuating catheter, which is lined with a brass tube. The washer can be easily connected with the catchers of the instrument, as shown by the cut (Fig. 677). It is not expected that this instrument can supplant the lithotrite. The idea is to crush the stone at the first introduction of the lith-

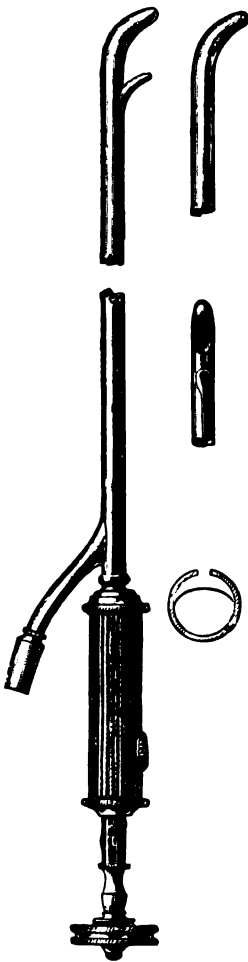


FIG. 677.—The author's combined instrument.

otrite as effectually as practicable, and to introduce the combined instrument instead of the ordinary evacuating catheter. By means of this the detritus is removed from the bladder, and such of the remaining fragments as are caught in the throat of the instrument are crushed and likewise removed. It thus becomes possible to avoid the interchange of instruments incident to repeated crushings. With an assistant to manipulate the washer, the operator can devote his entire attention to crushing the fragments caught in the throat of the instrument.

When applied to an extemporized bladder it worked admirably, and seemed to require only the perfecting influences of repeated and practical applications to create for it a place among the recognized appliances for the performance of litholapaxy.

Perineal Lithotrity.—A stone may be crushed by gradual or rapid lithotrity through an opening in the perineum. Perineal lithotrity has, as yet, been rarely adopted as a primary method of treatment,



FIG. 678.—Dolbeau's method, first step.

but rather as an expedient to facilitate the removal of a stone too large to be removed through the incision made for the purpose of a simple lithotomy. It has been advocated as a substitute for lithotomy, because the crushing and the use of the washing apparatus can be



FIG. 679.—Dolbeau's method, second step.

substituted for the incision through the deeper parts. Still, the withdrawal of an ordinary sized stone can hardly compare, in point of

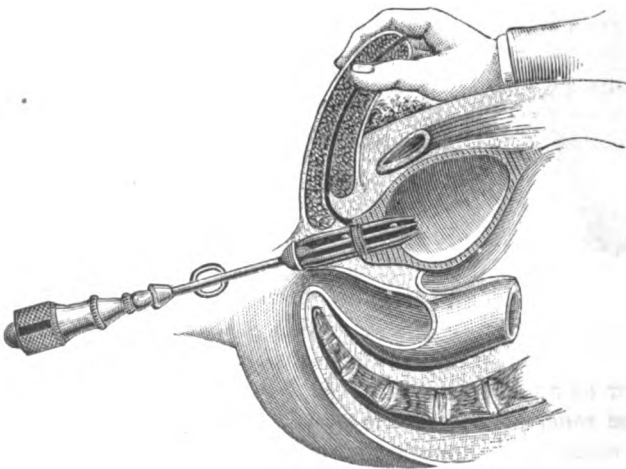


FIG. 680.—Dolbeau's method, third step.

danger, to the repeated introduction of instruments and the necessary prolongation of the operation of crushing through an open wound. However, it is, without doubt, an expedient which should be more frequently adopted, especially for the removal of large stones through an opening too small to admit of their safe withdrawal.

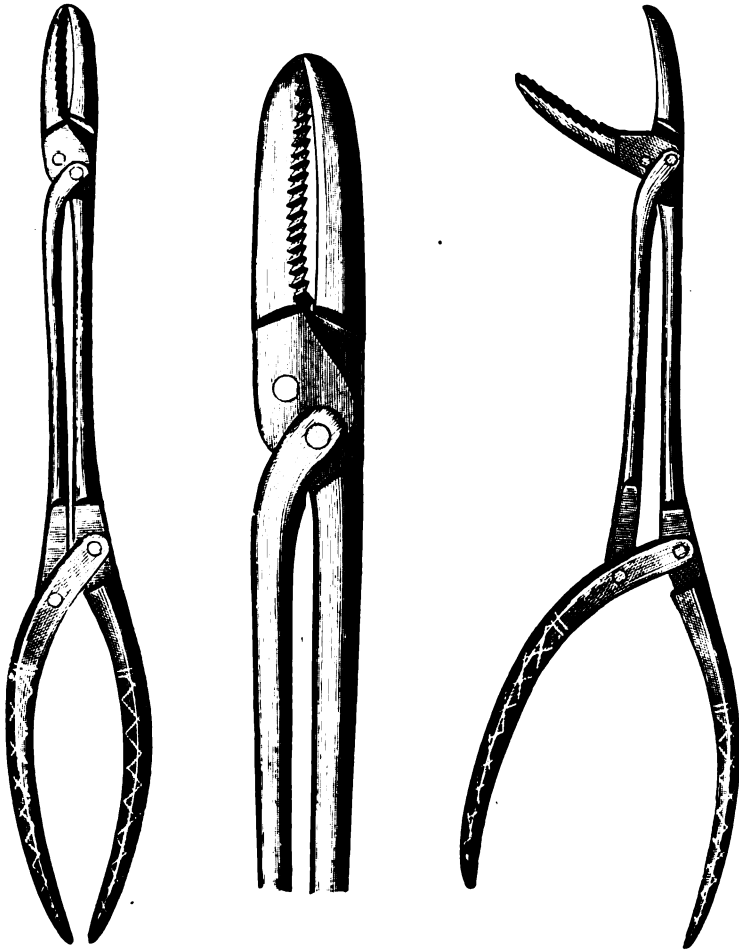


FIG. 681.—Gouley's lithoclasts.

Professor Dolbeau systematized this method. The incision is made through the perineum, as in median lithotomy, after which the dilatation is divided into three steps, the dilator of Mr. Dolbeau being employed. *The first step* consists in the dilatation of the tissues down to the groove in the staff (Fig. 678); *the second*, the dilatation of the tissues nearly through the neck of the bladder (Fig. 679);

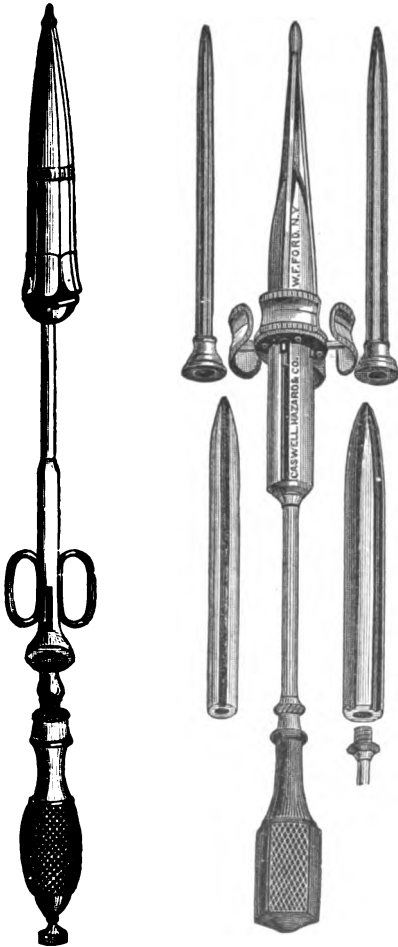
third, the withdrawal of the staff and carrying the dilator in sufficiently to thoroughly dilate the neck of the bladder (Fig. 680).

The dilatation in all the steps must be done carefully, and in accordance with the resistance encountered. After it is completed a lithoclast (Fig. 681) of suitable size is introduced, and the stone fragmented, after which it comes away with the urine. A small reverse current of carbolized water thrown into the bladder will wash the fragments out.

The results, while very satisfactory, are not equal to those of litholapaxy.

Lithotripsy in the Female.

—The absence of the prostate body, and the shorter and larger urethra of the female, combine to secure a more complete emptying of the bladder, and also lessen the liability in the female to the formation of vesical calculi. A stone in the female bladder can not be grasped with the same facility as that in the male, owing to the difference in the normal shape and surroundings of the bladder, and to the pathological modifications to which its cavity is subjected, due to its connections with the uterus and vagina, and their physiological and pathological variations caused by child-bearing and its sequels. The greater liability to a sacculated base requires that the instrument be reversed more frequently



FIGS. 682, 683.—Dolbeau's dilator.

than in the sterner sex. The operation can, however, be readily performed, and, aside from the slight variations in the manœuvres necessary to catch the stone, differs but little from that in the male.

Lithotomy.—Lithotomy is the operation for the removal of stone from the bladder by cutting. The varieties of incision in common use

are classed as the lateral, median, and bilateral, together with the occasional employment of the supra-pubic method.

Lateral Lithotomy.—Lateral lithotomy is employed in preference to the median, when the stone is too large to be easily removed through




FIG. 684.—Staff.

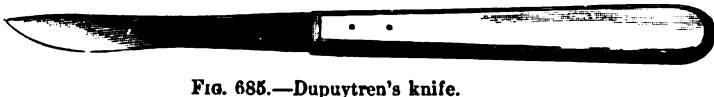

FIG. 685.—Dupuytren's knife.

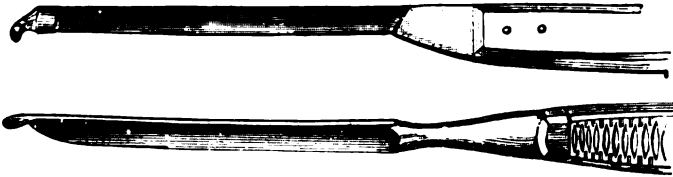


FIG. 686.—Blizard's knife.



FIG. 687.—Blunt gorget.




FIG. 688.—Scoop and conductor.

the dilated prostate. The instruments necessary for the operation are a staff of suitable size, with the proper curve and a deep groove upon its convexity which approaches its right lateral aspect as it nears the extremity of the beak (Fig. 684); a bistoury with a stout blade and handle, a solid shank, a sharp point, and a cutting edge of about two inches in length; a probe-pointed knife—the one devised by Blizard being the best—and, if the perineum be deep, due to obesity, the gorget may be selected; forceps of various sizes and shapes to seize the stone, one of which should be arranged with crossed handles to avoid stretching the parts about the neck of the bladder when the stone is grasped. It is likewise well to be provided with a small lithoclast, for the purpose of breaking those stones too large to be extracted with

safety ; a scoop to dislodge the remaining fragments of stone (Fig. 692), and a syringe to wash from the bladder any small fragments that



FIG. 689.—Straight forceps.



FIG. 690.—Curved lithotomy forceps.




FIG. 691.—Dolbeau's lithoclast.



FIG. 692.—Luer's scoop.

may remain (Fig. 693). Davidson's syringe can be used, but is less satisfactory than one designed for the purpose. The chemise or shirted canula (Fig. 694) is useful to control hemorrhage. At least five assistants should be present. To one of these the staff should be intrusted ; the lower limbs may be held by two others, either with or without the limbs being confined by the anklets (Fig. 695). The hands and feet may be bandaged together satisfactorily for the purpose. Of the remaining assistants, one should attend the instruments, and the other the sponges, etc. The more modern device for separating the lower limbs and exposing the perineum will be of great service (Fig. 696).

Operation.—Shave and disinfect the parts, empty the rectum with

an enema, administer an anæsthetic, draw the patient down to the edge of the table, and confine the extremities. The staff is then introduced and the stone found; a diagnosis which should be verified by others present. If the stone be not detected, the staff should be withdrawn, and its presence and location determined by the searcher. These points must likewise be confirmed by others.

If the stone be not found at all, the operation must be deferred.

The principal assistant, who holds the staff, should satisfy himself that the sound touches the stone, although it is not necessary that it be pressed against it during the operation. The holder of the staff should stand at the patient's left and press it firmly beneath the pubes with the right hand, while the integu-

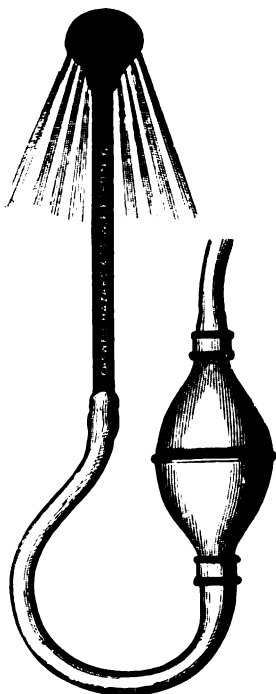


FIG. 693.—Van Buren's debris syringe.




FIG. 694.—Chemise catheter.

ment of the perineum is made tense by drawing up the scrotum with the left. The convexity of the staff is easily felt in the perineum. If the perineum be thin the groove may be distinctly defined. Some surgeons have advised that the staff be pressed against the perineum instead of the pubes, to better define its outline. However, it is a matter of little importance which course is taken, so long as the pubes

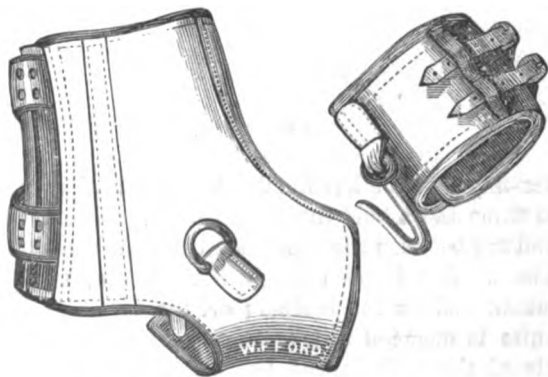


FIG. 695.—Pritchard's anklets and wristlets.

is hugged by the instrument while the incision is being made into the bladder. The surgeon should sit upon a low stool, and, before beginning the incision, carefully map out the location of the bulb, and the point where the incision is to begin, also determine the outlines of the rami and tuber ischii. He then introduces the index-finger of the left hand into the rectum, locates the apex of the prostate, and determines its relations to the sound. The finger is withdrawn, disinfected, and the groove in the staff again located. The incision is commenced a little to the left of the median raphé, from an inch and a quarter to an inch and a half in front of the anus. The point of the knife is made to enter the groove at the second or third cut, being guided by the nail of the in-

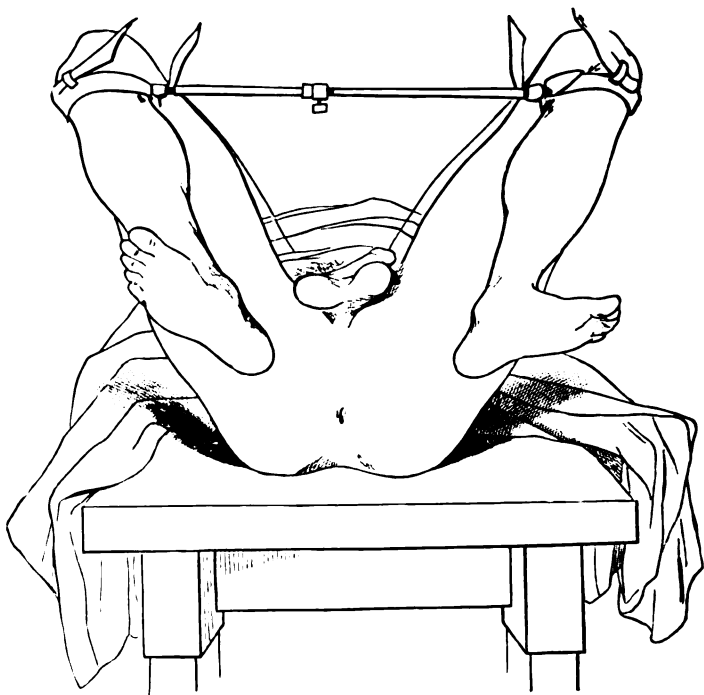


FIG. 696.—Clover's crutch applied.

dex-finger of the left hand. The perineal incision is made from three to three and a half inches in length, and carried obliquely downward, midway between the tuber ischii and the verge of the anus (Fig. 708, *b*). The urethra is then freely opened, and the probe-pointed bistoury substituted for the scalpel; or, the blunt extremity of the Blizard's knife is engaged in the groove—when, the surgeon, taking the handle of the staff in the left hand, lowers it somewhat, and holding it firmly carries the knife toward the bladder, depressing its handle

slightly to correspond to the curve of the staff. If he were to push the knife downward and backward without depressing its handle, the point would leave the staff and pass behind the bladder, a fact which would not be discovered until the withdrawal of the knife and the attempt to pass the finger into the bladder. As soon as the end of the knife is stopped by the termination of the end of the groove in the staff, its handle is depressed, the edge turned still more, and the deep tissues severed from within outward by its withdrawal, care being taken to make the incision through the prostate more horizontal than that of the perineum (Fig. 697). The flow of urine which follows assures the operator of successful entrance to the bladder.

It is recommended to press the point of the scalpel firmly against the groove in the staff with the right hand, seize the staff with the left, depress the handle of the staff and the knife at the same time, to the same extent, and thus convert them for the moment into one instrument which is pushed into the bladder. This course is often followed, and will prevent the escape of the point of the knife from the groove. It is more difficult, however, to properly lateralize the knife

in its passage through the prostate in this than by the former method; besides, it is much less elegant. The purified index-finger of the left hand is now passed carefully into the bladder along the staff, which is then withdrawn. The neck of the bladder is dilated by the finger, the stone reached, and its diameter estimated, if it has not been done before. If it exceeds an inch in diameter, the right side of the prostate should be nicked by introducing a knife along the finger. The forceps are now passed in as the finger is withdrawn, and the stone carefully grasped in the short diameter. If one blade of the forceps be pressed

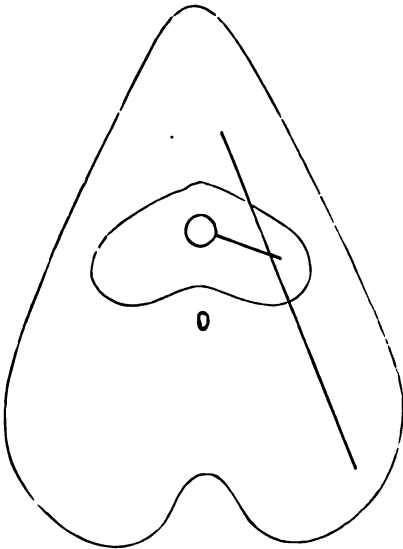


FIG. 697.—Lateral incision of prostate.

upon the floor of the bladder, and the instrument opened, the stone will often roll properly within its grasp. However this may be, unusual caution must be employed not to bruise the contracted walls of the empty viscus. If the stone be grasped in its long axis, it should be dropped and the direction corrected by the finger carried into the bladder. A change in direction may sometimes be accomplished by

carrying two fingers into the rectum, separating and pressing them upward against the bladder, thereby compressing its sides and creating a furrow running antero-posteriorly, into which the corresponding long axis of the stone will drop. When properly grasped it is withdrawn by steady traction made in the line of the incision through the perineum. Lateral movements can be made with direct traction. If inordinate traction be deemed necessary for its removal, it should be crushed, after which it can be easily extracted. Too great traction may tear off the neck of the bladder, or lacerate the tissues beyond the limits of the prostate; still, tearing is safer than extensive cutting, since the plexus of veins is less liable to be injured by it. As soon as the calculus is removed, its surface is examined for facets, which indicate the presence of still one or more calculi in the bladder. Having removed all the calculi, irrigate the bladder with tepid carbolyzed water to remove all blood-clots and whatever detritus may be present. If earthy matter exist in the bladder, it may be necessary to remove it with a scoop. If the stone be encysted, it is very difficult and often impossible to remove it. It may be grasped with the forceps with or without nicking the confining structure; in either instance great care and judgment must be exercised. If arterial hemorrhage occur, it may be checked by ice-pressure, by the devices previously illustrated, or by the ligature; if these fail, the serrefine forceps (Fig. 54) may be clasped to the bleeding point and allowed to remain. The tying in of a tenaculum, or acupressure, will check it; venous hemorrhage may be controlled by the chemise catheter or some other similar expedient. After the operation place the patient in bed with a rubber cloth beneath the hips, separated from the body by cloths, to collect the urine and indicate the occurrence of hemorrhage. The temporary introduction of a catheter or drainage-tube into the bladder through the wound in the perineum is not commonly practiced.




FIG. 698.—Smith's lithotome.

Give light and stimulating diet, alkaline drinks, and treat all sequelæ on general principles.

Results.—The rate of mortality ranges from six to ten per cent.

The operation just described is the one usually employed. There are, however, instrumental modifications which, in the opinion of some, may deprive it of the little danger that may arise even with a careful adherence to the details. The instrument devised some years ago by Dr. Smith, of Baltimore, and successfully employed by him and others (Fig. 698), is worthy of mention. It consists of a rectangular staff with a well-rounded angle, and is deeply grooved on its horizontal portion, and provided with an indicator attached to the shaft by means of a hinge. The indicator is likewise rectangular and terminates in a lance-shaped blade. The indicator can be adjusted by sliding it up and down the staff; or various sizes of the instrument may be employed to meet individual differences. The staff is introduced and held by an assistant in the usual manner, and the cutting extremity of the indicator is applied to the median line and pushed through the tissues, until it lodges in the groove of the staff. The probe-pointed gorget is then passed into the groove and lodged in the channel on the staff, along which a cut is made into the bladder. A probe-pointed bistoury may be substituted for the gorget. The single and double lithotomes (Figs. 699 and 700) have their advocates. They are, however, in a small minority when compared with the number of adherents of the scalpel and grooved staff.

Median Lithotomy.—Median lithotomy is applicable to cases having one or more small stones half an inch or so in diameter, and in advancing puberty. In this method there is less danger from hemorrhage, much better control of the urine from the first, and the wound heals rapidly. If the stone be larger than was anticipated,

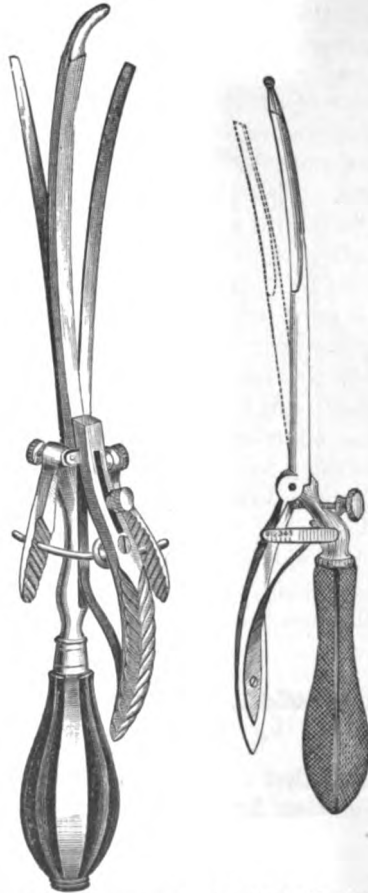


FIG. 699.—Dupuytren's double lithotome. FIG. 700.—Hutchinson's lithotome.

the temptation to use violence during the extraction is great. It is claimed that this method may be followed by stricture of the urethra,

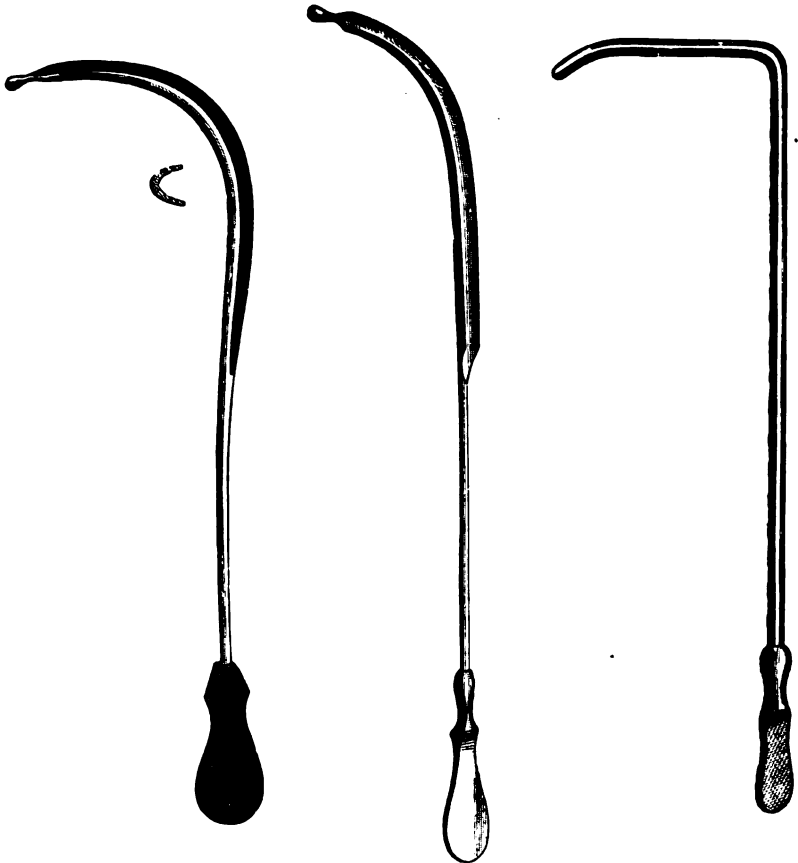


FIG. 701.—Little's lithotomy staff.

FIG. 702.—Markoe's staff.

FIG. 703.—Rectangular staff.

and also that the mouths of the seminal ducts are more likely to be injured than by the other methods. The general precautions to be employed in all forms of lithotomy are mentioned more fully in connection with the lateral operation.




FIG. 704.—Little's director.

The instruments required are the staff, director, and knife. The staffs vary somewhat in the shape and depth of the grooves. The

ones devised by Drs. J. L. Little (Fig. 701) and T. M. Markoe (Fig. 702) leave nothing to be desired. The rectangular variety (Fig. 703) can be used in lieu of the curved one, although it is rarely employed in this country. The director devised by Dr. Little is an admirable instrument (Fig. 704), but is by no means essential to a successful operation.



FIG. 705.—Little's lithotomy bistoury.

A stout, straight, sharp bistoury, double-edged at the point (Fig. 705), for making the perineal incision, makes the especial outfit complete.

Operation.—Confine the patient in the lithotomy position (Fig. 696); introduce the staff, placing the end of the beak in contact with the stone; pass the left index-finger into the rectum, and locate the apex of the prostate just where the staff enters it; introduce the point of the knife into the median line of the perineum half an inch in front of the anus (Fig. 708, *a*), with the long cutting edge uppermost, and push it carefully upward to the apex of the prostate, guided by the finger in the rectum, into the groove of the staff. The knife is advanced sufficiently toward the bladder to nick the apex of the prostate, after which it is carried forward to divide the membranous portion of the urethra. The external incision should be from one and a quarter to one and a half inch in length, care being taken to avoid the bulb of the urethra. The director is then passed into the bladder along the staff, and the neck of the bladder moderately dilated by separating the two. The staff is then withdrawn, and the index-finger of the left hand carried through the neck along the director with a semi-rotary motion to complete the dilatation. The forceps are then introduced, the stone caught at its short diameter, and removed by steady, gradual traction, which may be accompanied by rocking movements, but never by a rotation of the instrument on its long axis while grasping the stone.

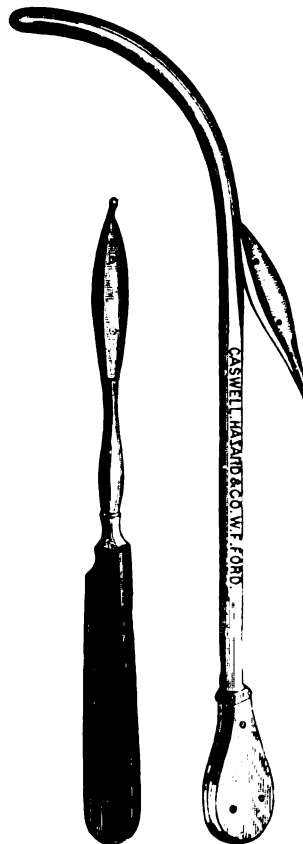

FIG. 706.—Wood's staff and bisector.

Various instruments have been devised to dilate the prostate in this and other methods calling for the procedure (Figs. 682 and 683),



FIG. 707.—Wood's bisector.

all of which answer the purpose well, but are by no means essential to the safe performance of the

operation. After the removal of the stone, stop all hemorrhage, seek for any remaining calculi, wash out the bladder, place the patient in bed with the limbs extended, administer an anodyne, and maintain quietude.

Bilateral Method.—The preliminary preparations, the precautions, and general arrangements in this are similar to those necessary in the other methods. The special instruments are the grooved staff, and the bisector, so intimately associated with the name of the late Prof. James R. Wood (Figs. 706 and 707).

Operation.—Make a semilunar incision across the perineum, three fourths of an inch in front of the anus, beginning midway between the anus and the tuberosity on the right side, and terminating at a similar point on the opposite side (Fig. 708, *c*). The convexity

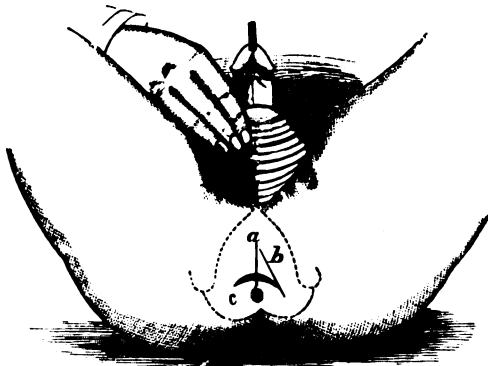


FIG. 708.—External incisions in perineal lithotomy.

of the cut is directed forward. The several tissues are divided down to the membranous urethra, which is opened and the beak of the instrument inserted in such a manner as to cause the beveled edges of the bisector to be uppermost. After moving the beak backward and forward, to be certain it is well lodged in the groove, it is then firmly

pressed against the groove of the staff, and, with the staff held firmly, it is carried into the bladder. They may be, practically, converted into a single instrument by pressing them firmly together and carrying them both in at the same time, being careful to depress the handle of each to the same degree.

Fallacies.—The bisector may be carried behind the bladder if any tissues exist between the groove and its probe-pointed extremity, or if the handle be not depressed to conform with the long axis of the staff. The anterior wall of the rectum may be cut. Avoid this accident by

inserting the index-finger of the left hand into the bowel when the primary incision is being made, and drawing the anterior wall backward while the cut is being completed.

The results obtained by this method in the hands of Dr. Wood were equal to, if not better than, those previously given in connection with the other methods of cutting for stone.

Nélaton's Modification.—Nélaton modified the first step of the bilateral method, with the view of lessening the danger of cutting the bulb and the wall of the rectum. He introduced the left index-finger into the rectum, placed the end of it against the apex of the prostate, and steadied the anterior border of the anus with the thumb of the same hand. He then made a semilunar incision in front of the anus, the extremities of which were four fifths of an inch from the opening, and the greatest convexity three fifths of an inch from it. The dissection was continued, layer by layer, the wall of the rectum and the bulb being carefully avoided, until the membranous urethra was reached and opened, and the cutting instrument introduced. The same object was accomplished through a transverse incision an inch and a quarter in length, with its center located three fifths of an inch in front of the anus.

Medio-Lateral Operation.—This method was devised by Buchanan, of Glasgow.

The instruments necessary are a rectangular staff with a broad groove in its left side, and a narrow, straight knife with a long edge. The staff is introduced, and the prominent staff-angle adjusted to correspond to the muco-cutaneous junction on the anterior verge of the anus in the median line.

The instrument is then firmly held with the handle inclined toward the abdomen, and the tissues are penetrated by the knife, held horizontally and with the edge turned to the left, until the groove in the staff is reached (Fig. 709); then the knife is pushed forward into the bladder upon the staff. As it is withdrawn, an incision three fourths of an inch long is made downward and outward toward the fore part of the tuber ischii. This incision is completed by being continued directly downward about half an inch. If necessary, it can be extended.

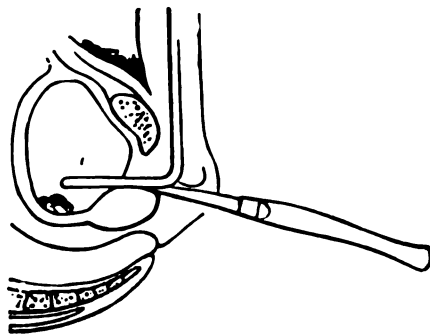


FIG. 709.—Medio-lateral method.

Results.—A little over ten per cent are reported to have died after operations by this method.

Medio-Bilateral Operation.—This method was brought to the notice of the profession by Civiale, and has since been championed in this country by Dr. W. F. Briggs, of Nashville. The staff for the median method is introduced with the patient placed in the usual position; the rectum is drawn backward by the finger, and an incision made through the median line into the staff an inch and a half in length, beginning about half an inch in front of the anus.

The lithotome (Fig. 710, *a*) is then introduced into the groove, carried into the bladder, the blade expanded half an inch, and the instrument withdrawn, enlarging the wound on either side a quarter of an inch throughout. The wound is then dilated and the stone removed in the usual manner. If too large, it may be crushed. The author has modified Briggs' instrument somewhat by introducing an independent guiding stem, which leaves the cutting blades uninterfered with during the withdrawal of the instrument from the bladder (Fig. 710, *b*).

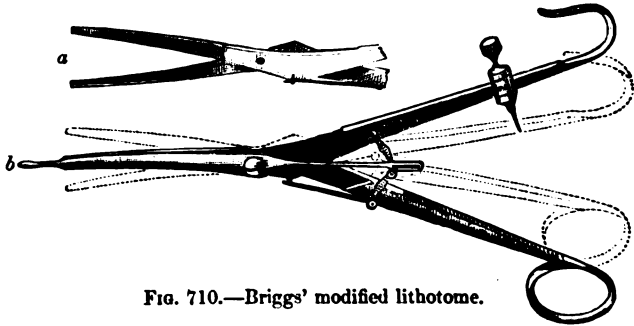


FIG. 710.—Briggs' modified lithotome.

Results.—Prof. Briggs reports his mortality as at the rate of one in thirty-seven cases operated upon. These are certainly astonishing results.

Supra-Pubic Lithotomy.—The supra-pubic or high operation was done first by Frère Côme, about 1560. Since this time it has found favor at several epochs, and is now again being strongly advocated by prominent surgeons. The various relapses of the method depended, without doubt, more upon the determination of its exponents to make it an exclusive operation, than upon its own intrinsic defects.

The following are a few of the many conditions said to call for this method: Great prostatic hypertrophy; inability to extract the stone through the perineum on account of its size; encysted stone, large stone with a contracted bladder surrounding it firmly; impermeability of the urethra. The practical objections to it may be limited to these two—operation on an obese patient, and one with a contracted bladder containing a small stone. The possibilities of urinary extravasation—which is rare—and of cutting the vesico-abdominal reflection of peritoneum, are the dangers

Operation.—Place the patient on the back, and anæsthetize to complete insensibility to overcome the contractility of the bladder. This is first washed out, and then moderately distended with a warm four-per-cent solution of boric acid. The amount injected will depend on the capacity as well as the irritability of the organ; usually six or seven ounces will suffice. The rectal balloon is next introduced—the ordinary colpeurynter will do—and distended with warm water sufficiently to raise the bladder well above the pubes. An incision three or four inches in length is then made in the median line, commencing just above the pubes. The various tissues are divided down to the linea alba, which is cut through and the interspace between the pyramidal muscles is sought for. If it be not found, the muscular fibers should be separated, when the fatty layer on the transversalis fascia and the fold of peritoneum will make their appearance. Divide the fat, draw up the peritoneum with the finger, and, after passing a strong ligature through each side of the bladder and looping it, to provide a means to control the opening to be made into it, open the bladder with a bistoury, in the median line. The hemorrhage, which may at first be severe, subsides as the bladder contracts and empties itself. Introduce the finger into the bladder and locate the stone. The forceps are now introduced into the bladder along the finger, the stone seized and removed. If it is necessary, enlarge the opening; it should be extended downward. Examine the bladder for remaining calculi, and cleanse the wound. Some surgeons sew the wound in the bladder with catgut, carried down to but not through its mucous membrane. The abdominal wound is then closed with deep and superficial sutures, and dressed antiseptically. The bladder should be evacuated once in two or three hours during the first three days; after this it may be done less frequently and at the end of a week discontinued. It is strongly recommended—and justly, too, it seems to me—to leave enough of the visceral and abdominal wounds open to admit the introduction into the bladder of a long drainage-tube, and, by keeping the patient on the side, thus avoid the use of the catheter. The use of the drainage-tube is open to the objection, however, that a small amount of urine will escape beside it, in spite of the greatest care. It is also advised to sew the lips of the visceral wound to the borders of the abdominal wound, thus to surely prevent urinary extravasation. Opposed to this last plan is the possible effect—as yet uncertain—on the functions of the bladder of the union of its walls with those of the abdomen. The wound should always be dressed with antiseptic care, irrespective of the method employed. The opening through the linea




FIG. 711.—Aponeurotome.

alba may be made with the aponeurotome (Fig. 711), or by the ordinary scalpel. The *sonde à dart* (Fig. 712) may be introduced into the bladder and its trocar pushed through the anterior wall, thus serving as a good guide. The hooked gorget (Fig. 713) is useful to hold up the bladder, and keep the wound open while the stone is being removed.

Results.—The rate of mortality as reported by some is about one in four. These estimates are, however, deceptive, since they relate principally to the results gained by this method when employed under unfavorable circumstances. A rate of one in eight or nine is now attained.

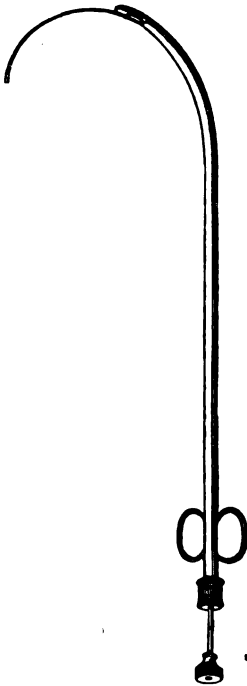


FIG. 712.—Sonde à dart.




FIG. 713.—Hooked gorget.



FIG. 714.—Gross' dilator.

LITHOTOMY IN THE FEMALE.

Aside from the method of crushing, a stone may be removed from the bladder of the female by *rapid dilatation of the urethra*, or by *urethral* and *vesico-vaginal lithotomy*. The method by dilatation is performed with the aid of the finger or an instrument (Fig. 714) especially designed for the purpose. A calculus an inch or more in diameter can be removed in this manner without unfavorable results. The operation of lithotomy is not difficult of execution in the female.

Operation.—Introduce a broad-grooved director into the bladder, pass upon it a straight probe-pointed bistoury, and cut directly upward toward the symphysis pubis. Follow the incision by dilatation, and then remove the calculus with forceps. If greater space be required, the cut may be extended downward and outward toward the tuber ischii.

This method is modified by combining the two preceding methods as follows: first dilate the urethra, then divide either its anterior or posterior wall as best suits the indications of the case, and remove the stone.

The *vesico-vaginal method* consists in simply connecting the vagina with the cavity of the bladder by a longitudinal incision made in the median line of the vagina, the length varying according to the size of the stone. A grooved staff is introduced into the bladder, the position of the groove ascertained by the finger, and the tissues between the finger and the groove are divided by a scalpel or scissors. The *sequel* which contraindicates the vesico-vaginal method is the formation of a chronic fistula. It is claimed that the wound can be made to heal completely if the parts be frequently irrigated, so as to prevent phosphatic deposits. Tepid water acidulated with nitric or hydrochloric acid will aid materially in the prevention of the deposit. A solution of the acetate of lead—one grain to the ounce of warm water—is also highly extolled for this purpose.

CHAPTER XVII.

OPERATIONS ON THE PENIS AND SCROTUM.

Hydrocele.—This morbid condition may be treated by *tapping* (which is palliative), and by *incision, excision, and injection*.

Tapping is a simple process, requiring for its performance a small trocar and canula, or an aspirating needle, or an instrument of a similar nature. The patient is caused to sit upright on the edge of a chair with the limbs separated, the enlargement is seized by the left hand, and the tissues made tense on its anterior surface. The testicle is carefully located, and the course of the scrotal vessels as carefully avoided. The instrument, guarded by the end of the finger (Fig. 715), is quickly plunged into the scrotum at about the junction of its middle and lower thirds. As the fluid escapes, the end of the canula is turned away from the testicle, and the tumor is compressed carefully to expel the entire fluid collection. After the fluid is removed the scrotum is suspended, and the patient kept quiet, otherwise inflammation of the sac may occur, which, while it may lead to a radical cure, will not be

welcome, as it causes much pain and confines the patient to bed. It will be necessary to repeat the operation in five or six months.

Fallacy.—The testicle may be punctured by the trocar, unless the exact location of the fluid has been determined by transmitted light.

Incision.—In this operation the sac is laid freely open on the anterior surface, and the wound dressed from the bottom. It heals in

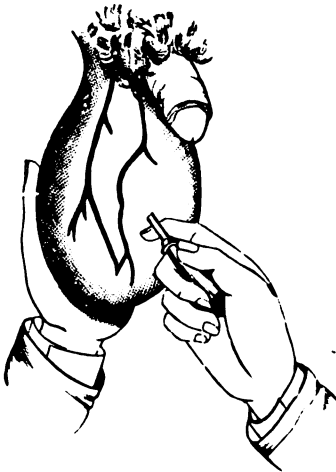

FIG. 715.—Tapping hydrocele.

from four to six weeks, and is seldom followed by a return of the disease. It is of especial efficacy when it is desired to examine the pathological condition of the testicles, with the view of determining the relation of a suspected morbid process to the fluid collection. Volkmann incised the tissues under antiseptic precautions, and stitched the sac to the scrotal incision. This operation, like the preceding one, has been followed, though rarely, by a return of the disease.

Excision.—In this method a portion of the sac is cut away on either side of the primary incision. As a modification it allows a freer escape of the discharges, and prevents the protrusion of the rigid tunic, but

otherwise makes no practical difference. The external incisions in the preceding methods may be made either long or short; the former is the better, as it affords more suitable drainage.

The wounds, after all of these operations, may be treated antiseptically with most satisfactory results.

Incision with Excision.—This method differs but little from the one last mentioned, and is, in my opinion, the best operative procedure for the radical cure of hydrocele. A long incision is made into the tunica vaginalis, under the bichloride douche, and the condition of the testis ascertained. The rigid protruding borders of the divided tunic are then excised in the direction of the long axis of the external incision, and the remaining portions stitched by catgut to the subcutaneous scrotal tissues at the borders of the long incision. A drainage-tube is introduced, the scrotal wound closed, and the scrotal flaps quilted together by catgut sutures to prevent the contractions of the dartos from disturbing the union, the whole is then dusted with iodoform, and surrounded by antiseptic gauze.

Prognosis.—The wound usually heals completely, in a week or ten days, under the primary dressing, without any suppuration; and the probability of a return of the disease is very remote.

Injection.—The fluids recommended are numerous, among which iodine, sulphate of zinc, and carbolic acid are preferred at the present time. The instrument required in the performance of the operation is the rubber injection-bag, in addition to the ordinary trocar (Fig. 716). The trocar is introduced and the fluid drawn off. The sac is then seized, together with the scrotal tissues, to prevent the escape of the extremity of the trocar from the cavity of the sac, and the medicated fluid is thrown in by means of the gum bag. If the tincture of iodine be used, it may be diluted with three or four parts of water. Three or four ounces of the mixture is quite sufficient to come in contact with the entire surface. It should be retained for five or ten minutes, until the patient complains of pain, and then allowed to escape through the canula. If the pure tincture be used, a drachm or two injected in the same manner, and allowed to remain and become absorbed, is quite sufficient. If the sac be small, fifteen or twenty drops may be thrown into it by a hypodermic syringe, without the previous removal of the fluid.

If the sulphate of zinc be used, a solution composed of a drachm of the salt to the pint of water is of sufficient strength.

A drachm or two of a ten- to fifty-per-cent solution of carbolic-acid crystals in glycerine may be injected and allowed to remain. This plan is strongly advocated at the present time by competent observers.

The after-treatment in these cases consists in putting the patient in bed, suspending the scrotum, and keeping lead and opium applied to it, with anodynes to allay pain. For obvious reasons, *the congenital hydrocele should not* be treated radically until its communication with the abdominal cavity is closed.

Accidents.—If care be not taken, the fluid may be thrown into the connective tissue of the scrotum instead of the sac. If the canula slip out after the fluid is withdrawn, a fresh puncture must be made, since the previous opening will be closed by the contraction of the

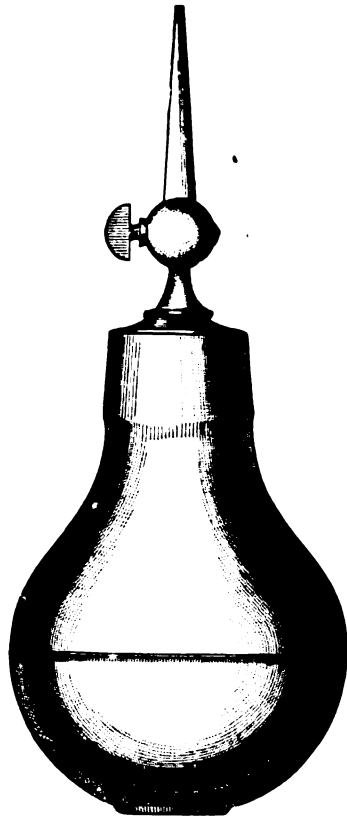


FIG. 716.—Rubber bag for injecting.

dartos. Suppuration, sloughing, etc., which rarely follow, should be treated upon general principles. The results following all of the enumerated methods of operation are flattering; yet failures are not unknown in the best.

Castration.—Castration is an operation simple of performance and free from danger. Shave and disinfect the parts; place the patient upon the back and administer an anæsthetic. Make an incision in the long axis of the tumor, beginning just below the external abdominal ring and extend it to the lower extremity of the scrotum. The tissues are carefully divided on a director down to the cord, which should always be cut off short, if the operation be done for malignant disease. The three arteries accompanying it should be tied separately with catgut ligatures. If any doubt exists as to their having been properly secured, the cord should be isolated and transfixed by a needle armed with a strong catgut ligature, each half tied separately, and the cord divided. If it be divided low down, each vessel can then be tied separately. In cases where it is divided high up, it must be secured before its division, otherwise it may retract and seriously complicate the final treatment.

After the division of the cord, the testicle can be easily removed from the enveloping tissue by means of traction and an occasional use of the scissors. All bleeding is then stopped, a small drainage-tube is inserted into the lower edge of the wound, which is united by fine catgut or carbolized silk, and the wound is dressed antiseptically. If hemorrhage of the cord occurs afterward, the dressing must be removed and the wound opened, and enlarged if it be necessary in order to secure the bleeding vessels.

Circumcision.—When phymosis or a simple redundancy of the foreskin exists, circumcision, or some modification of this operation,

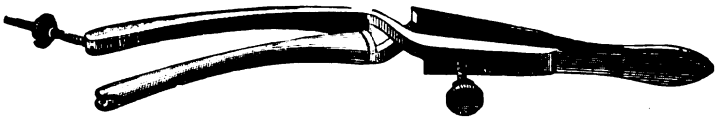


FIG. 717.—Henry's phymosis forceps.

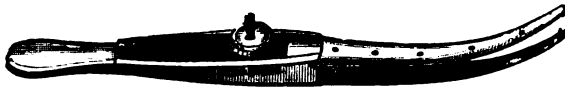

FIG. 718.—Fisher's phymosis forceps.

should be performed. The instruments especially designed for the purpose consist of the variously formed clamps (Figs. 717, 718), a grooved director, and probe-pointed scissors (Fig. 719). The patient is placed on the back and an anæsthetic administered, or a cocaine

solution injected into the prepuce, unless a determination is expressed to endure the pain without it. The object of the operation is not to remove the foreskin so as to leave the entire glans penis exposed after




FIG. 719.—Taylor's phymosis scissors.

recovery, but to allow sufficient integument to remain so as to afford the protection characteristic of the normal prepuce. The situation of the base and apex of the glans should be determined, and with a pen or pencil an oblique line drawn corresponding to the direction of the base of the glans, about midway between it and the apex, upon the integument. The foreskin is then drawn downward, placed between the blades of the clamp, with the line just made corresponding to the lower border of the blades, care being taken to not include the glans in its grasp (Fig. 720). The clamp is tightened and the distal portion severed by a sweep of the scalpel. The clamp is now removed, and the integument retracts to or a little behind its previous location. The mucous membrane which still covers the glans (Fig. 721, *a*) is slit up on a grooved director, along the dorsum, *b*, and trimmed symmetrically on either side, not even with the integument, *c*, but near enough to it

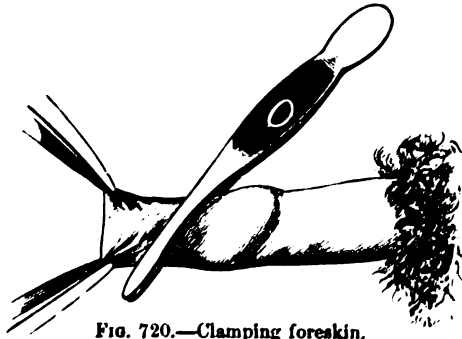


FIG. 720.—Clamping foreskin.

so that when it is turned over and its free borders are stitched to the skin, a vermilion border, *d*, at least a third of an inch wide, will be formed. Before the sewing is done, the mucous membrane should be stripped off the glans to a point behind the corona, after which it can be returned and its border joined to the integument.

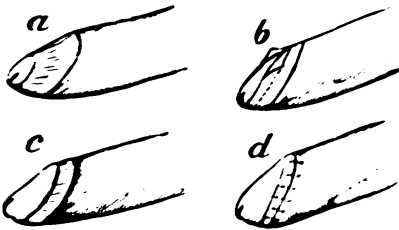


FIG. 721.—Steps of circumcision.

ument by a continuous horse-hair suture. If the mucous membrane grasps the glans too tightly, endangering the occurrence of paraphimosis, it must be slit on the dorsal surface up to its point of reflection, after which the borders are joined as before described. The complete division along the dorsal surface will permit the prepuce to accommodate itself to the varying dimensions of the penis that not infrequently occur during the process of healing.

Another admirable method (Keyes), which is intended to meet the same indications, is represented by Fig. 722. In this the mucous membrane is not slit up, but both it and the integument are shaped to correspond to the outlines 1, 2, 3, and 4, 5, 6, after which the former is reflected backward and joined to the integument, so that 1 shall correspond to 4, 2 to 5, and 3 to 6. This plan does not, however, insure the same freedom as the long dorsal slit just described. If the phimosis be not attended by an elongation of the foreskin, a cure may be effected by slitting it upward on the dorsal surface to the base of the glans. The ear-like projections on either side are then trimmed off, and the mucous and cutaneous borders stitched to each other (Fig. 723). *Cullerrier* well accomplished the purpose in this condition by subcutaneously dividing the mucous membrane in three or four places by means of blunt-pointed scissors, the blunt point resting upon the glans, while



FIG. 722.—
Keyes' modification.

the sharp one was passed between the membrane and the integument. If the prepuce be short, and the case not an aggravated one, the *mucous lining can be stretched*, and even torn asunder, by introducing the blades of dressing-forceps between the glans and foreskin and expanding them, after which the foreskin can be drawn backward and retained until healing is completed. In all the methods of operating, the after-treatment is directed to modifying the inflammation and preventing the occurrence of an erection of the penis.

For this purpose, cold applications, large doses of bromide of potassium, and anodynes are recommended. It is now a favorite method to sew the borders of the wound with a continuous suture of fine catgut, dust it with iodoform, and surround the organ with iodoform gauze. The catgut sutures are allowed to remain until absorbed.

In one case I now recall, local and general medication combined were not sufficient to control or hardly mitigate the tendency to erection; yet this tendency was effectually controlled by employing

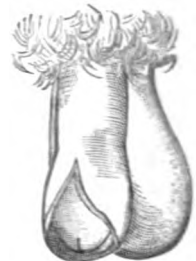

FIG. 723.—Dorsal slit.

nurse to watch the penis while the patient slept, with instructions to awaken him at the first indication of an erection.

Paraphymosis (Fig. 724).—In this condition the foreskin is immovably lodged behind the corona glandis, so as to cause great congestion and œdema of the parts if not relieved (Fig. 725), and the condition may even terminate in gangrene and sloughing. *The reduction* may be accomplished as follows :



FIG. 724.—Paraphymosis.

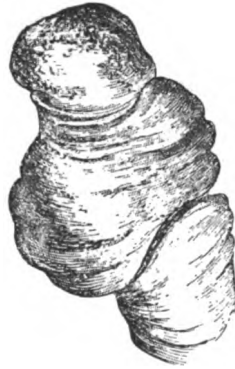

FIG. 725.—Results of the constriction.

Oil the parts well, and administer an anæsthetic, if necessary ; grasp the penis behind the constriction with the thumb and fingers of the left hand, and the glans with the tips

of the thumb and fingers of the right ; press the glans with the latter gradually to reduce the swelling, then draw the constriction forward with the left, while the glans is gradually forced through it with the thumb and fingers of the right (Fig. 726). If the constriction be not

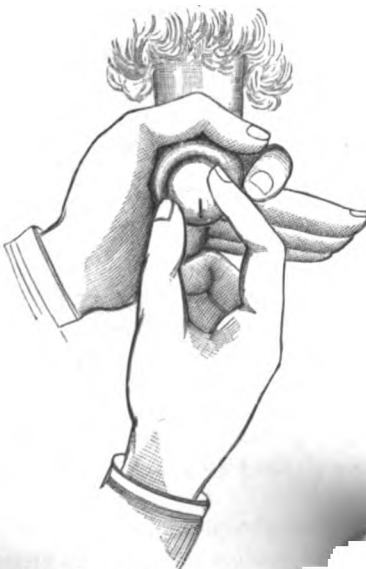

FIG. 726.—First method of reduction.

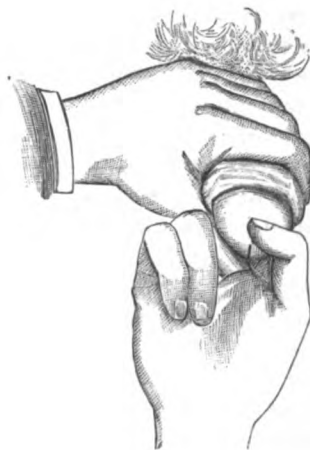

FIG. 727.—Second method.

great, and the œdema and congestion be slight, this manipulation will soon effect the reduction. When the part is corrugated and much swollen by long-standing severe constriction, followed by inflammation and plastic œdema, it will be found necessary to sever the constriction



FIG. 728.—Third method.

on the dorsal surface by a sharp-pointed, curved bistoury. In all cases where much œdema exists, acupuncture should be performed, and the fluids squeezed through the openings before reduction is attempted. Other methods of grasping the penis are recommended to effect the reduction of the foreskin (Figs. 727, 728).

After reduction, thoroughly cleanse and disinfect

the parts; place the patient in bed, with the penis resting upon the abdomen, and dress with cooling antiseptic lotions.

Amputation of the Penis—Old Plan.—Place the patient on his back and give an anæsthetic, cause an assistant to retract the integument somewhat, transfix the corpora cavernosa transversely by an acupressure-pin to prevent retraction of the stump, embrace the penis behind the seat of the disease by a clamp (Fig. 729) inclined slightly forward, and remove the projecting portion with a large scalpel, by cutting obliquely downward and forward; secure all the bleeding points, draw out the mucous membrane of the urethra, divide it transversely, and stitch it




FIG. 729.—Bodenhamer's clamp.

to the integument at four different points, to prevent its contraction into the canal. If the cavernous bodies bleed too freely, the hemorrhage can be checked by acupressure. If the amputation be made too near the pubes to permit the application of the clamp, a tape or cord, carried behind the pin, may be substituted.

Hilton's Modification consists in dividing the spongy body about a fourth of an inch in front of the cavernous portion, splitting it longitudinally, and uniting the lateral flaps to the integument as before.

Humphrey's Modification consists in dissecting up the skin of the penis, and turning back a circular flap about half an inch in length, dividing the corpora cavernosa on a level with the attachment of the flap, and cutting the spongy body at least half an inch longer than the preceding, and attaching the integument to its extremity.

If the amputation is to be made close to the symphysis, two accidents must be guarded against, viz., retraction of the stump and infiltration of the scrotum with urine. If a stout ligature be passed through the fibrous sheath of the penis, a little above the point of proposed section, the first accident will be obviated. The infiltration can be prevented by dividing the scrotum entirely through, in the line of the urinary canal, and uniting the borders of the integument to those of the urethra, thus forming two scrotums, with the urinary opening between them.

Extirpation of the Penis (Gouley).—Anæsthetize the patient, make a curvilinear incision on either side of the root of the penis, beginning in the median line, about one inch and a half above the level of the pubes, and ending a little below the peno-scrotal junction. The cavernous bodies are exposed and transfixed with a large knitting-needle, or with a suitable substitute; the urethra is transfixed by a smaller one on the same plane, and the penis is amputated an eighth of an inch in front of them. After all the bleeding points are secured, the urethra is found and a grooved staff introduced through it into the bladder. A sharp-pointed scalpel is then carried through the perineum and lodged in the grooved staff, and all the tissues, including the scrotum, divided from behind forward. The urethral cut is about an inch and a half in length, and the cutaneous one three inches. The urethra is now detached from the cavernous bodies, and these bodies, together with their crura, are dissected away, after which the borders of the urethra are united to those of the perineal wound.

CONGENITAL MALFORMATION OF THE URETHRA.

The urethra may be absent or occluded; it may be extremely small or bifid; the external opening may be higher or lower than normal, and even double; its walls may be deficient above or below, constituting epispadias and hypospadias. Epispadias is sometimes complicated by separation of the symphysis pubis and exstrophy of the bladder.

Hypospadias results from a deficiency in the floor of the urethra. The opening may exist in the glans or in the penile or scrotal portions. The first form is the most frequent and the least important. The scrotal is the next in point of frequency, and the most important of all. When the deficiency is in the anterior or balanic portion, the following operation will give satisfaction:

Gouley's Method (Fig. 730).—Make two longitudinal cuts, 2-3 and 2-3, far enough apart to leave ample material for the new urethra;

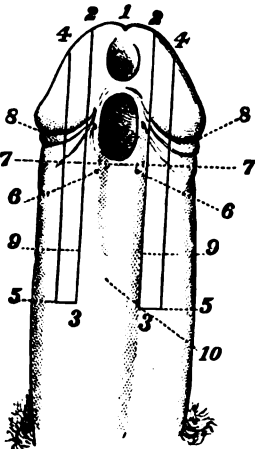


FIG. 730.—Gouley's method.

make 4-5 and 4-5 a fourth of an inch outside; remove the integument of the spaces bounded by these incisions; leave undisturbed the skin and mucous membrane included between the incisions 2, 3 at 1, 10; slide the loose skin at the root of the penis and of the scrotum forward, making it double upon itself until 3, 3 is brought to 2, 2, and the denuded surfaces are brought in accurate apposition, making the angle of the fold at 7, 7. The first suture is taken at 6, 6, passing through the upper flap from within (beneath) outward, and the lower flap or border, 2, 3, from without inward; before tying, pass the suture of the opposite side in the same manner; tie both, cut the ends short, leaving the knots inside the new urethra; introduce sutures along the external

borders, uniting 3, 5, 9 to 2, 4, 8. The newly formed meatus is transverse, its under lip being the fold of the skin from 10, formed by the apposition of the points 3, 3 to 2, 2. If the opening be in the penile portion, and the organ bent downward, the curve must first be relieved by subcutaneous section of the tissues while the penis is forcibly extended.

If transverse incisions of the skin be needed to aid in overcoming the deformity, they will be found to assume a longitudinal aspect when the organ is straightened, and can then be united by sutures.

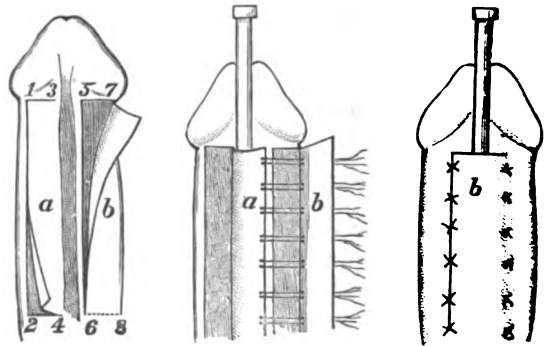


FIG. 731.—Anger's method.

When the defect

is in the penile portion, the following method is worthy of trial:

Anger's Method (Fig. 731).—Make an incision on the left side of the penis, from the glans to the scrotum, 1, 2, half an inch from the median line, also incisions at 1, 3 and 2, 4; the flap thus formed, *a*, is dissected up, its base being attached near to the median line, 3, 4. A second longitudinal incision, 5, 6, is made at the right side of the

median line, near to it, and of the same length as 1, 2, with lateral incisions an inch and a half long at each extremity, 5, 7 and 6, 8. The flaps are raised, a sound introduced into the urethral groove, and the first flap, *a*, turned over it, bringing the integumentary portion in contact with the urethral sound. Independent sutures, each armed with a needle, are passed through the free margin of the first flap, *a*, and outward through the base of the second flap, *b*, and fastened by shot pressed around them. The remaining flap, *b*, is then placed upon the raw surface of the first, *a*, and fastened to the margin of the first incision, 1, 2. The sound or catheter is then removed, and only introduced thereafter to evacuate the bladder.

Duplay's Method (Fig. 732).—This operation can be divided into three steps: 1, if the penis be incurved, it is straightened and a new

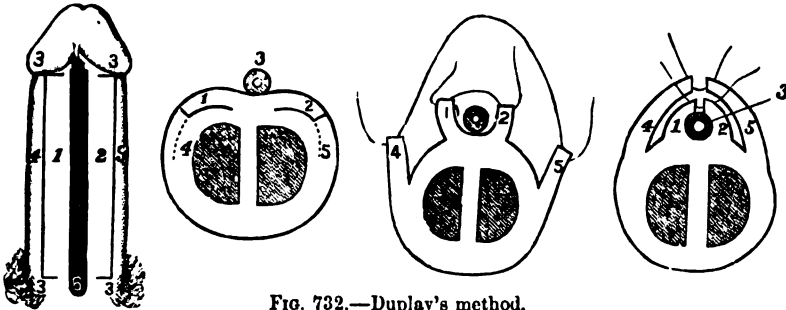


FIG. 732.—Duplay's method.

meatus made; 2, the missing wall of the urethra is restored; 3, the old and new portions are joined together.

The penis is straightened by making transverse subcutaneous incisions through the restraining bands while the organ is being extended; if the integument be too taut to admit of the proper rectification of the organ, it, too, must be severed, the resulting cuts united in the long axis of the penis, and the penis confined in the corrected position a sufficient time to permit the healing of the wound before the second step of the operation is attempted.

The first step is completed by freshening, and, if necessary, deepening the urethral groove at the situation of the proposed meatus, and uniting its raw surfaces by silver wire or carbolized silk around a sound or gum catheter as in Thiersch's method (Fig. 736).

Second Step.—Two longitudinal incisions are made, 3, 3, extending from the glans to near the abnormal opening, one on each side of the urethral groove, at a distance from each other equal to half the circumference of the proposed urethra, a dimension which can be ascertained by measuring the gum catheter over which the flaps are to be reflected. From the ends of these a transverse incision is made toward, but not quite to, the median line. The flaps, 1 and 2, are

dissected up and turned inward over a gum catheter, 3 (transverse sections), and their margins fastened together in the median line by fine sutures. The outer flaps, 4 and 5, of the longitudinal incision are dissected up sufficiently to permit them to be easily drawn over the reflected ones, 1 and 2, when they, too, are united in the median line by interrupted or continuous sutures. Unite the anterior extremities of all the flaps to the raw borders of the glans, thus completing the anterior portion of the tube.

Third Step.—Freshen the edges of the abnormal opening, 6, and unite it to the posterior extremities of the flap by a double row of sutures.

Szymanowski's Method (Fig. 733).—Make an incision, 1, 1, near the edge of the fistula, extending half an inch beyond it; dissect

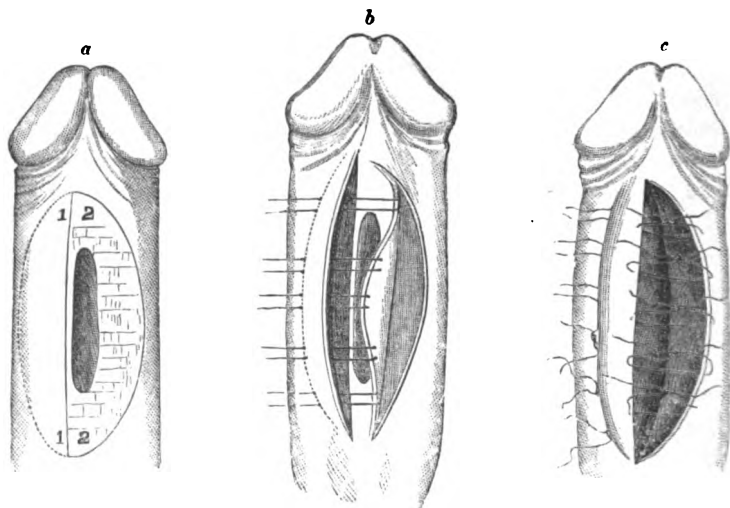


FIG. 733.—Szymanowski's method.

up a flap bounded by the dotted line; make a curved incision, 2, 2, on the opposite side, its length being a trifle less than that marked on the dotted line upon the other side, but otherwise of sufficient width to cover the fistula and reach the dotted line when turned upon itself; scrape the cuticle from the flap 2, 2, and dissect it up to the edge of the fistula; arm each end of a fine carbolized silk suture with a small curved needle; pass these two needles from the epidermic surface, about a quarter to a sixth of an inch apart, through the edge of the curled flap (Fig. 733, b), introducing them from within outward—corresponding to the dotted line—through the base of the flap formed by the straight incision; after passing a sufficient number of these sutures—one every quarter inch—draw the curved flap beneath the straight one into the space formed by the separation of the latter

so that its edge will correspond to the dotted curved line (Fig. 733, *c*), and secure them over a piece of quill or cork. The inner edge of the straight flap is now united to the outer edge of the curved one, and the operation is completed.

Epispadias.—Epispadias results from a deficiency in the roof of the urethra. The ability to secure as satisfactory results in this as in the preceding deformity has not yet been attained.

Nélaton's Method.—A ligature is passed through the prepuce, which is drawn over the end of the penis and held during the operation. An incision, 1 and 2, is then made along each side of the urethral gutter at the junction of the skin and mucous membrane, beginning at the prepuce and ending at the abdominal wall (Fig. 734). The external lip of each incision is dissected outward

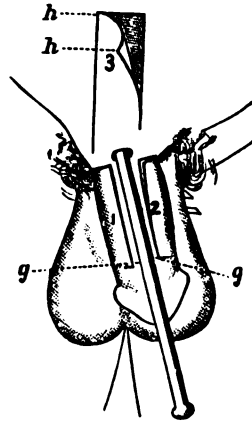


FIG. 734.—Nélaton's method.

about a sixth of an inch and allowed to remain continuous with the skin; the inner lip of each is likewise slightly detached. A third flap, 3, is marked out upon the abdominal wall, its base being located

immediately above the abnormal urethral orifice, between two vertical incisions, which are connected above by a transverse one; this flap should be as broad as and a little longer than the penis, and be dissected from above downward. It is then turned downward upon the dorsum of the penis, the raw surface being uppermost (Fig. 735, 3), and the cuticle forms the roof of the new urethra. The borders of the flap, *h h*, are now united by sutures to the inner lips of the incisions on the dorsum of the penis (Fig. 734, *g g*), the contact being made as broad as possible. The abdominal flap is now

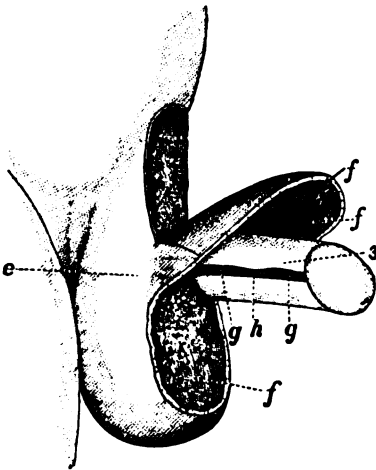


FIG. 735.—Nélaton's method.

re-enforced by a scrotal one (Fig. 735, *f f*), which is limited above by a curved incision circumscribing the under half of the penis at the peno-scrotal junction, and below by a curved incision located the length of the penis below the upper one, each extremity remaining continuous with the integument on the outer surface (Fig. 735, *e*).

This flap is dissected up, the penis slipped under it, and its raw surface apposed to the abdominal one already in position.

The outer borders of the scrotal flap are now united to the borders of the external flaps, 1, 2, found by the primary incisions made along the urethral gutter.

Thiersch's Method.—This method comprises four distinct steps, and requires several months for its completion.

A fistulous opening should be established in the perineum to permit the escape of the urine before any of the steps are taken.

First Step.—Formation of a meatus and that portion of the canal occupying the glans.

A deep incision (Fig. 736, 1) is made along each side of the urethral groove, in the glans, and the surface of the outer lips of each

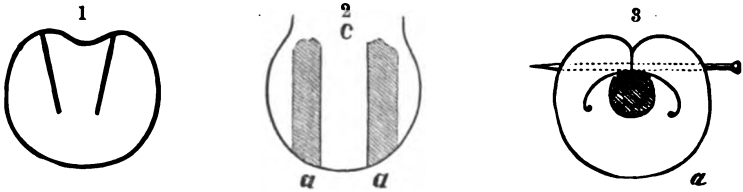


FIG. 736.—Thiersch's method: forming the meatus.

incision is pared, *a a*, 2, and they are drawn around a sound or catheter, brought in contact with each other, and united by sutures or hare-lip pins, *a* (Fig. 736, 3).

Second Step.—Formation of the urethra.

Make an incision through the skin and subcutaneous tissue at the edge of the urethral gutter at the right side, 3, 3 (Fig. 737); also a

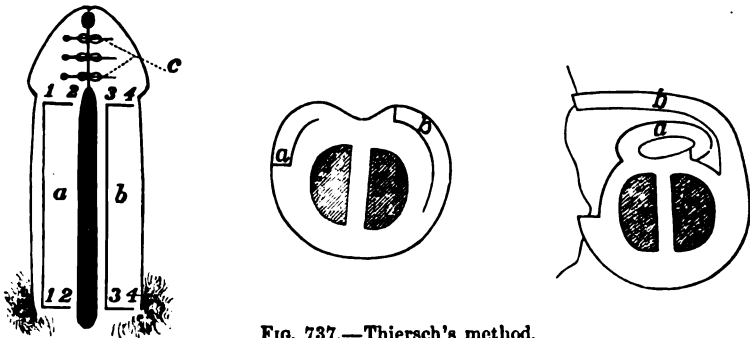


FIG. 737.—Thiersch's method.

short transverse cut outward from each end, 3, 4. Make a second incision on the left side parallel with the preceding one half an inch external to the edge of the gutter, 1, 1, and a transverse one at each extremity, 1, 2, extending inward to the border of the groove. The flap, *a*, is dissected up, making it as thick as possible. The flap on the right

side, *b*, is also raised. The flap, *a*, is now turned over to form the roof of the new channel, its raw surface being uppermost. Several sutures should be passed through it near to its free margin, in the manner previously shown (Fig. 731), thence through the base of the flap *b*, and fastened by a quill or shot attachment. The flap *b* is then drawn across the former so that their raw surfaces are in contact throughout, and its free margin, 3, 3, joined to the outer side of the incision, 1, 1, by sutures.

Fourth Step.—To close the posterior portion of the canal.

This opening is closed by two flaps, one taken from each groin. The left flap is shaped like an isosceles triangle. Its base is located at the left half of the opening, and when turned downward forms the roof of the new urethra. The right flap is quadrilateral, its base being located at the right external abdominal ring; its raw surface is placed in contact with the raw surface of the fellow, and its borders are united by sutures to all contiguous borders. After the healing is completed, the perfection of the canal can be tested by temporarily closing the perineal fistula by the finger during micturition. If satisfactory, the perineal fistula should be permanently closed.

· ACQUIRED URETHRAL DEFECTS.

The walls of the urethra may suffer loss of substance, producing a fistula. The caliber of the canal may be diminished, causing stricture, either of which usually depends upon acquired causes.

Before attempting an operation for the closure of a urethral fistula, the caliber of the canal should be made as near to its normal size as possible by appropriate treatment of the strictures and such other obstructions as may exist.

Urethroraphy.—This operation is employed to close a small urethral fistula, not exceeding a fifth of an inch in diameter if it be circular, and one fourth if longitudinal. If reasonable success is to be attained, it is necessary that careful attention be paid to every detail.

Before beginning the operation empty the bladder, and if necessary administer an anæsthetic.

Operation.—A sound is introduced into the urethra and the handle given in charge of an assistant. The edges of the opening are carefully pared obliquely, and when completed should present a funnel-shape appearance, the apex corresponding to the mucous opening of the canal. The wound is then closed longitudinally by means of a fine wire, horse-hair, or antiseptic silk, carried down to, but not through, the mucous lining; the intervals between them being short.

The patient should be kept quiet and given alkaline and demulcent drinks, and the urethra drawn with a catheter. It is a wise pre-

caution to inject oil into the urethra before the introduction of the catheter, to protect the cut as much as possible from any urine that might come in contact with it.

Urethroplasty.—Urethroplasty is employed to close larger openings than those within the domain of urethroraphy.

If flaps be dissected upon either side of the opening, and drawn together and joined in the median line, imperfect union is very apt to result on account of their thinness and median contact. To overcome this, it has been proposed to pass a sheet of thin rubber above the flaps to protect them from the urine during the healing process (Fig. 738). If, for this sheet-rubber, thin rubber-skin, separated from

the cut surfaces by a strip of Lister gauze, be substituted, the irritation will be lessened and the prospect of success correspondingly increased.

Nélaton's Method (Fig. 739).—The edges of the opening are first pared, and then the integument is detached subcutaneously for about an inch around it by entering a long, thin knife-blade through a transverse cut just below the opening (Fig. 739). The liberated integument is then joined in a longitudinal fold along the median line by means of quilted sutures.

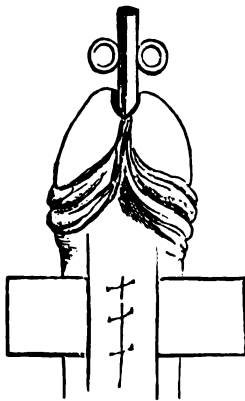


FIG. 738.—Urethroplasty.

Dieffenbach, instead of dissecting subcutaneously, raised two parallel longitudinal flaps and fastened the middle of their raw under surfaces together by sutures passed through leather supports at each side. Two or three rows of sutures can be used instead of this.

Delpech dissected up a single flap, drew it across the fistula, and fastened it to a raw surface prepared on the opposite side. *Arlaud* made two transverse flaps, one in front and the other behind the fistula, about an inch and a half in width. The anterior one was dissected up toward the glans about three fourths of an inch, and the posterior one back over the scrotum, until it could be easily drawn forward, so as to cover the fistula. The cutaneous surface of the anterior portion of the scrotal flap was freshened and the flap drawn forward so as to cover the fistula, and the anterior flap drawn backward over it and united by sutures.

Rigaud (Fig. 740) closed a large fistula at the peno-scrotal junc-

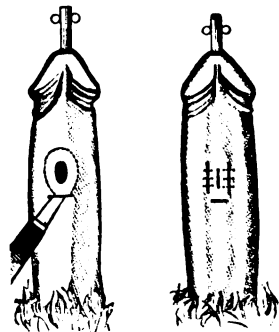


FIG. 739.—Nélaton's method.

tion by the method employed by Nélaton in the treatment of epispadias. A quadrilateral median flap, with its base adjoining the opening, was taken from the scrotum, turned forward over the fistula, and its raw surface covered by two flaps taken from the sides and drawn together so as to meet in the median line.

Szymanowski suggested that the cutaneous surface of the reversed flap be blistered instead of scraped. This method is not as reliable, however, as the former.

External Perineal Urethrotomy, sometimes called *perineal section*, is employed in the treatment of intractable strictures, especially when accompanied by a urethral fistula located in the perineum. It may be performed

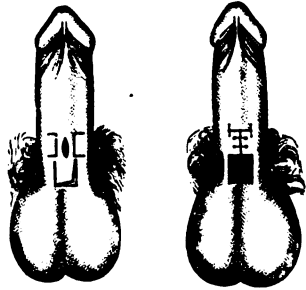


FIG. 740.—Rigaud's method.




FIG. 741.—Gouley's beaked bistoury.

either with or without a guide. The former is not a difficult operation, while the latter is frequently an extremely perplexing one. *The instruments essential* for the operation are an ordinary scalpel, also

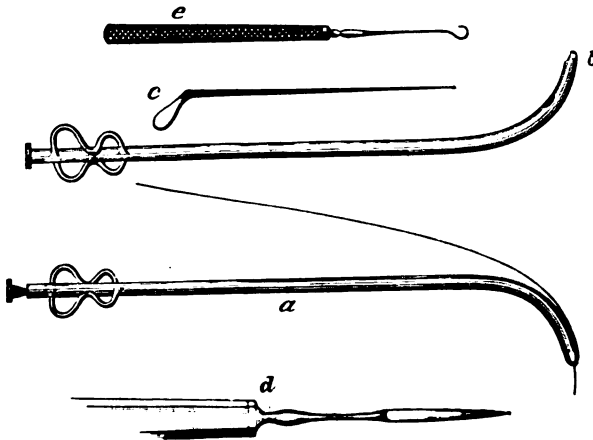


FIG. 742.—Gouley's grooved and tunneled catheter staffs.

one with a sharp point and a long, thin blade, the beaked bistoury of Gouley (Fig. 741), whalebone guides, a grooved and tunneled catheter staff (Fig. 742, *a*, *b*), ordinary sounds, a gum catheter, small probe, grooved director, *c*, spatula, tenacula, two strong ligatures, each armed

with a curved needle, and the usual instruments for controlling hemorrhage. Syme's grooved staff (Fig. 743) is objectionable, in that its point may get into a false passage and the stricture be missed. Moreover, its introduction through the stricture is more difficult than that of the whalebone guide, and attended by greater danger to the soft parts. If the ordinary small-sized grooved staff employed in lithotomy can be introduced, nothing better need be asked for.



FIG. 743.—Syme's grooved staff.

Operation with a Guide.—Evacuate the bowel, shave and cleanse the perineum, administer an æsthetic, fill the urethra with olive-oil, and introduce a whalebone guide into the bladder in the manner before described (page 420); over this pass the grooved and tunneled catheter staff down to and through the stricture, if it can be done readily; if not, allow its beak to rest against the obstruction, carefully supported by an assistant, who at the same time raises and holds the scrotum. The patient is now placed in a lithotomy position, and the limbs supported by an assistant upon either side. The surgeon, sitting upon a low stool facing the perineum of the patient, introduces the left index-finger into the rectum to ascertain the condition of the membranous and prostatic portions of the canal. A free incision, from an inch to an inch and a half long, is then made in the median line of the perineum, extending from the base of the scrotum to within half an inch of the anus, through the integument and fascia. The grooved instrument is carefully located by the finger, and the urethra brought into view by repeated cuts in the same line. The nail of the index-finger assures the surgeon of the location of the groove, and the urethra is divided upon it. Two silk ligatures are now passed, one through each border of the divided

urethra, and are then looped and given in charge of the assistants, who are instructed to carefully draw the lips of the wound apart (Fig. 744). This important step exposes the mucous wall of the urethra completely, enabling the operator to follow its course by carefully observing the continuity of its structures. The staff is now withdrawn sufficiently to show the black guide, then the beaked bistoury is introduced in its course, and the stricture is divided with about half an inch of the canal immediately behind the divided in the median line.

The admission of a grooved director or a small gum catheter through the opening into the bladder, followed by the flow of urine, assures the surgeon that he has located the proper channel; or, after

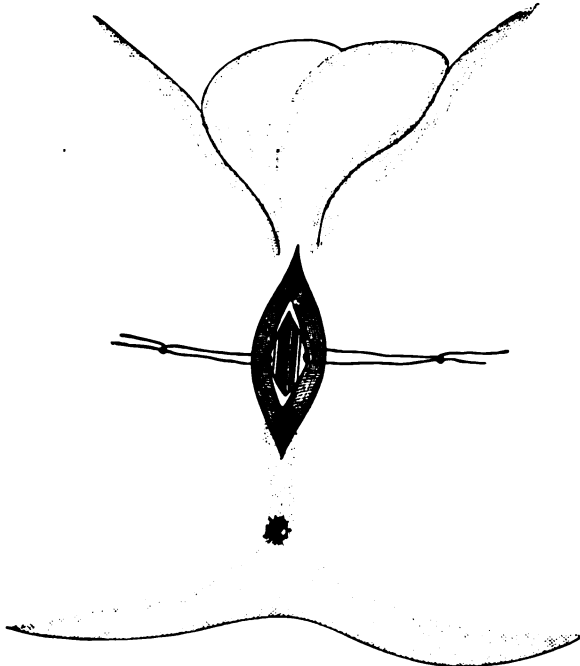


FIG. 744.—Borders of incision drawn apart.

the division of the stricture, the tunneled catheter staff may be passed along the whalebone guide into the bladder and the stylet withdrawn, when the diagnostic urinary stream will appear. The instruments are now withdrawn from the urethra, and the ordinary sound of suitable size is introduced into the neck of the bladder, through the urethra, to determine the complete freedom of the passage.

Operation without a Guide.—After all efforts to introduce a whalebone guide into the bladder have failed, pass the tunneled catheter staff over a whalebone guide along the urethra as far as it will go without using violence; then place the staff and guide in charge of an assistant, as before. Make an incision of the usual length directly in the median line down to and through the urethra into the groove at the end of the staff; pass the silken loops through the borders of the incised urethra as before; check all hemorrhage, withdraw the staff, and examine to see if the catheter is located in the urethral tube. The urethral incision and the staff are now drawn well apart, and the

operator, whose patience, care, and knowledge must now be well tested, endeavors to introduce a whalebone guide or a fine probe or grooved director through the stricture into the bladder by way of the perineal incision. If the effort be successful, the remainder of the operation is simple, and consists only in dividing the stricture with the probe-pointed bistoury from above downward as before ; usually, however, no anterior opening can be found, or one may be detected which leads away from the median line, showing the existence of a false passage.

In either case the plan of the operator must be the same. Keep in the median line. If, after a patient search, no direct orifice be found, it is often possible to detect it, by making moderate pressure above the pubes on the bladder, which will frequently cause a few drops of urine to escape from the obscure opening in the perineal cut, into which a whalebone guide or a fine director can be inserted, and usually passed into the bladder. If the pressure accomplishes nothing, then the surgeon feels for the opening in the triangular ligament, through which the urethra normally passes, and cuts toward and even through it if the urethra can not be found before. As he cuts he repeatedly seeks for the orifice, and closely examines for a continuation of the fibrous mass in the line of his incision with the tissues composing the walls of the urethra. In the obscure division of the amalgamated perineal tissues, the surgeon is also guided by the established relations of the normal urethra to the arch and rami of the pubes, to the tuberosities and rami of the ischium, and, still more important, the relations to the rectum. The careful cutting and searching are continued until an opening is found which leads into the bladder. The tissue barring the passage is cut, and a small gum catheter is passed along the probe or director into the organ. This is followed by the welcome flow of urine. The catheter is then withdrawn, the canal dilated with the little finger, and all constricting bands at the roof and floor of the urethra are severed. A steel sound the size of the canal is then introduced into the bladder through the urethra several times until its uninterrupted entrance is assured. Increase the size of the meatus and divide by internal urethrotomy all obstinate strictures in front of the perineal opening. Examine the bladder for stone, and, if found, remove it ; stop all bleeding ; place the patient in bed with hot fomentations to the abdomen ; elevate the scrotum to prevent infiltration ; administer anodynes and demulcents, and keep the patient quiet. The major portion of the perineal wound may be closed by antiseptic sutures carried deeply, leaving, however, sufficient room for the introduction of a large flexible catheter, through the neck of the bladder. The wound should be dressed antiseptically. The catheter should be allowed to remain in position for four or five days unless its presence causes some degree of vesical irritation. Suit-

able-sized sounds should be passed every two or three days for a considerable time at a later period.

Results.—In eight thousand cases of external urethrotomy a little over five per cent died.

Internal Urethrotomy.—The division of strictures by cutting instruments introduced into the urethra is called “internal urethrotomy.”

It is usually limited to strictures of the penile portion, although sub-pubic and even those of the membranous portions may be divided. The number, size, location, and extent of the obstructions should be determined before their division is attempted.

For this purpose, bulbous bougies and urethrometers have been devised. The metallic bougie of Otis (Fig. 745), and also the non-metallic forms (Fig. 746), meet the indications admirably. If it be the intention of the operator to distend the canal to its fullest capacity, and if the meatus be undersized, it should be slit up before the stricture is divided.



FIG. 745.—Otis' bougies à boule.



FIG. 746.—Non-metallic bougies.

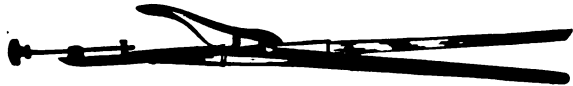

FIG. 747.—Civiale's bistouri caché.

The slitting can be easily done by means of the bistouri caché of Civiale (Fig. 747). After properly distending the meatus, it is introduced with the cutting surface downward, and quickly withdrawn. The ordinary probe-pointed bistoury, or a straight-edged one, with the end guarded, will accomplish the purpose perfectly. The lips of the cut will unite unless they be kept separated by lint or cotton, or by the occasional introduction of a large-sized sound. The *location*, *number*, and *size* of strictures can be determined by the introduction of bulbous bougies. One of large size that will slip through the meatus is selected, oiled, and passed down the canal until arrested. The distance in the canal is noted on the handle. It is then withdrawn, and the size of the bulb measured by the familiar scale.

The surgeon next ascertains the size of the one that will pass the obstruction, and so on, recording the location and size of each obstruction in its turn until the bladder is entered. The urethrometer of Otis (Fig. 748) is constructed on a principle calculated to give practically accurate measurements. The unexpanded blades of the extremity of the instrument, B, are covered by a small rubber cap or closed tube, C; the instrument is oiled and carried, closed, through the last obstruction, if possible, when the extremity is expanded by a screw at the outer end until it fills the urethra, the capacity of which is noted upon the dial; it is slowly withdrawn while the expanded extremity is regulated to accommodate the varied dimensions of the canal, the caliber and location of which should always be noted. By this simple though ingenious method the surgeon is enabled to locate quite correctly the seat of the obstacle he is to treat. The remaining instruments required are the urethrotome, and a double-barreled catheter, to apply an iced-water current to the canal.

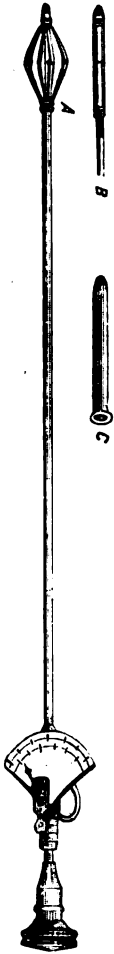


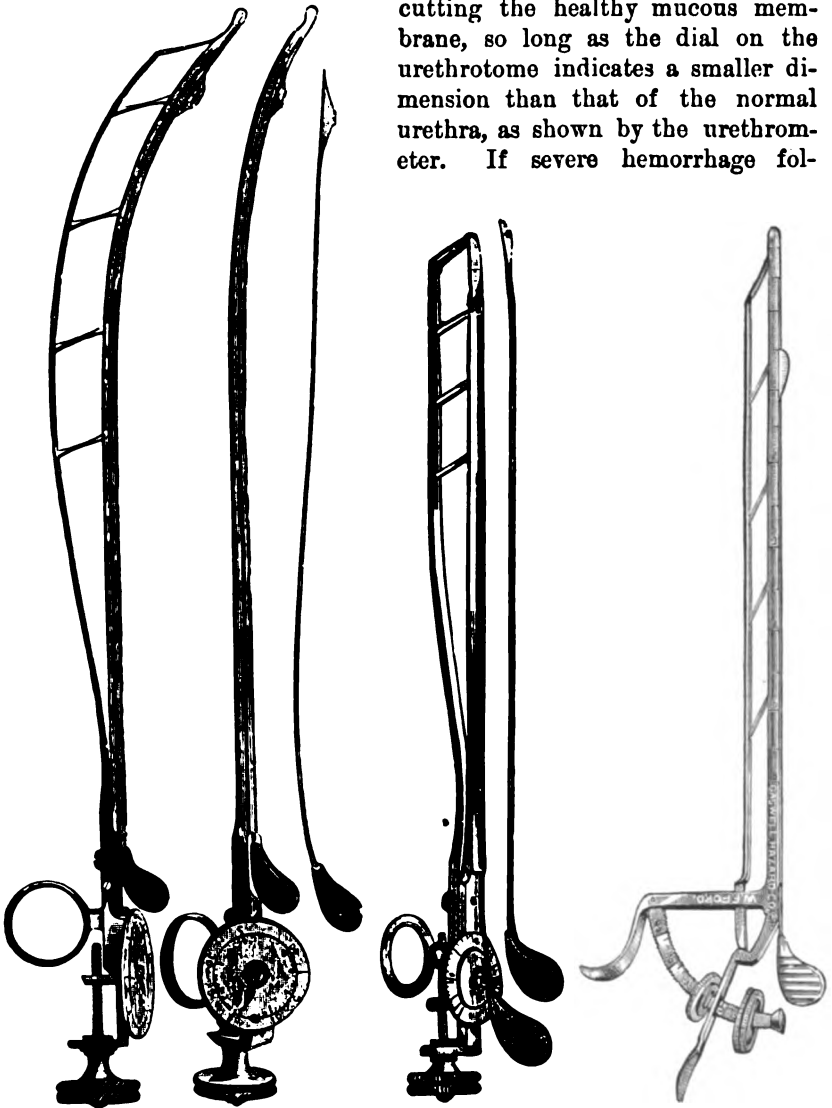
FIG. 748.—
Otis' urethrometer.

Urethrotomes, like other instruments designed for special purposes, vary in many important particulars. Those, however, of greatest practical utility were devised by Otis and Peet (Figs. 749, 750, and 751). Each bears upon its handle a scale which enables the operator to ascertain not only the size but the distensibility of an obstruction. Either of these instruments, when taken in connection with the urethrometer, enables the surgeon to divide the strictured portions until the scale on the dial or handle of the cutting instrument indicates that the strictured portions of the urethra correspond in size to the dimensions of the normal portions, as indicated by the dial of the urethrometer.

Operation.—An anæsthetic or cocaine solution is employed, and the patient is placed upon the back. Then a well-oiled instrument is introduced, and the extremity concealing the blade is carried beyond the obstruction, which is dilated by turning or depressing the screw at the end until the strictured tissues are made tense, when

the knife is withdrawn sufficiently to divide the stricture freely. The action of the instrument is then reversed and the knife pushed back into its hiding-place, and the instrument again dilated to note the effect of the incision upon the caliber of the stricture. If it still be below the standard, as indicated by the urethrometer, the blade is again applied to it. In this manner each constriction can be divided and the tube made of a uniform diameter throughout. If two or

more strictures have a common, or an almost common, diameter, they can be cut simultaneously by drawing the knife along the course of the shaft. There is little danger of cutting the healthy mucous membrane, so long as the dial on the urethrotome indicates a smaller dimension than that of the normal urethra, as shown by the urethrometer. If severe hemorrhage fol-



FIGS. 749, 750.—Otis' urethrotomes.

FIG. 751.—Peet's urethrotome

low, a large-sized sound can be introduced, and the penis bandaged to it. Cold may be applied by means of a stream of iced-water conducted through a double-barreled catheter. It is sometimes necessary

to make pressure on the perineum, in conjunction with other expedients. The necessity for this is extremely rare. Following urethrotomy the patient must be kept quiet in bed for three or four days, with a light diet and open bowels; demulcent and alkaline drinks are often advisable. A sound may be passed every third day until the wound is healed. Very few patients perish as the direct result of internal urethrotomy,

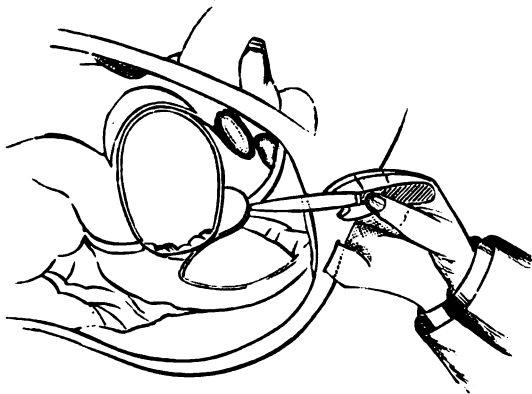


FIG. 752.—Tapping the urethra.

and when carefully done upon proper cases, an unfavorable result need not be anticipated.

Tapping the Urethra (Cock).—In a distended bladder from impassable stricture this is a feasible operation. The patient is placed in the lithotomy position, and the left index-finger introduced into the rectum, and its tip pressed against the apex of the prostate (Fig. 752). A double-edged knife is then plunged into the perineum, in the median line, the point being directed to the tip of the finger, and caused to open the urethra in front of the prostate, behind the stricture, by a slight lateral motion. As the knife is withdrawn, the dimension of the wound may be increased anteriorly. A grooved director is then carried into the bladder through the opening, and a catheter passed upon it to relieve the distended viscus. The opening may be made through the anterior wall of the rectum when objections exist to the perineal puncture.

CHAPTER XVIII.

MISCELLANEOUS OPERATIONS.

Tapping the Pericardium.—If the pericardium be hyper-distended by fluid, or contain pus, and the attending symptoms denote dangerous heart failure from pressure, the accumulated fluid may be removed by tapping or by aspiration through the trocar of Fitch.

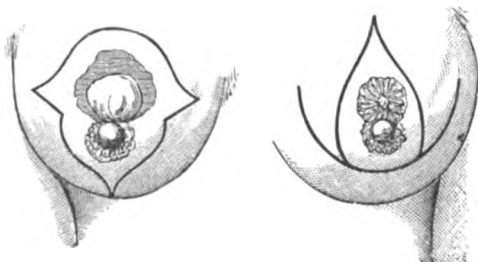
The instrument devised by Dr. Roberts, of Philadelphia, who has

given much attention to the subject, is well adapted to the purpose mentioned. The principal operation should be preceded by an exploratory puncture with a hypodermic syringe. The arteries to be avoided are the mammary and intercostal; the former rests upon the costal cartilages, about a half inch from the outer border of the sternum, the latter run along the lower border of the ribs. The point of the instrument should be directed away from the apex of the heart, since the latter moves from left to right and from behind forward at each pulsation.

Operation.—Place the patient diagonally upon the left side, with the shoulder and chest raised. Insert the instrument through the fifth intercostal space, an inch or an inch and a half from the left border of the sternum, close to the upper border of the sixth rib, using great care to prevent the entrance of air.

Results.—Nearly forty per cent of the patients have recovered after the operation.

Extirpation of the Breast.—The breast is removed to eradicate growths of a malignant and non-malignant character. If malignant, the entire gland must be extirpated. If non-malignant, only such tissues as are involved in the growth need be removed. If the growth be malignant or of a doubtful character, all of the enlarged lymphatics in its vicinity should be taken away. Indeed, it is wise



FIGS. 753, 754.—Incisions for removal of the breast.

under these conditions to remove the entire axillary system of lymphatic glands, even though but one or two have become slightly enlarged. The shape and extent of the growth will modify the outlines of the incisions. If it be irregular, some other form rather than the established elliptical cut may be employed (Figs. 753 and 754).

Operation.—Wash and asepticize the part and its immediate surroundings; shave the axilla if the examination of the contents be contemplated; place the patient on the back and administer an anæsthetic. Raise the arm to make tense the fibers of the pectoralis major; assume a position relative to the patient which will be most convenient for making the inferior incision first (Fig. 755). A scalpel of large size is now selected; the breast pressed upward and supported by the left hand, and the inferior incision made in the direction, if possible, of the fibers of the pectoralis major. It should extend down to the pectoral fibers, and the breast should be reflected upward from them by traction with the hand, aided by the scalpel when necessary. As

of the jaw ; behind, by the external auditory meatus and mastoid process. The gland is separated from the submaxillary region by the stylo-maxillary ligament, and from the deeper tissues by the styloid process, and the ligaments and muscles connected with it. Prolongations of considerable size extend from its deep surface inward, one in front and the other behind the styloid process, the former passing behind the mastoid process and sterno-mastoid muscle, the latter to the back part of the glenoid fossa. The external carotid artery passes through the gland from below upward, dividing into its terminal branches before its escape. Superficial to this artery there is a venous trunk formed by the union of the temporal and internal maxillary veins ; to this trunk the internal jugular is connected by a small branch that passes through the gland structure. The facial nerve and its branches traverse the gland from behind forward and receive a communicating branch from the great auricular in its substance. Immediately beneath the floor of the space lie the internal carotid artery and internal jugular vein, along with the spinal accessory, glosso-pharyngeal, and pneumogastric nerves. Lymphatic glands lie over the parotid, and their enlargement may be mistaken for that of the gland itself.

Contraindications to Extirpation : immobility of the tumor, and a malignant growth implicating the structure of the gland.

Operation.—Place the patient upon a suitable table, in a good light, with the shoulders elevated and the head turned to the opposite side. Make an incision from the zygoma along the central line of the tumor to its lower border. If necessary, this one can be supplemented by one or more extending from it at right angles. The integumentary flaps are freely reflected to expose the growth. The tumor should be raised from below upward, and held by a volsella. This will raise the external carotid from its bed, when it must be isolated and tied between two ligatures. The vessels that enter or escape from the tumor at this point should be treated in the same manner. The tumor can now be raised upward, and its separation from the deeper tissues continued by means of the fingers or handle of the scalpel ; the former are the better.

The separation of the growth from the floor of the space must be done gently and with great caution, on account of the contiguity of the internal jugular vein and the other important vessels, and the nerves located there, which, if the growth be a large one, will be pressed upon by it, and may become adherent to it. It is scarcely possible to avoid division of the facial nerves if the growth be compact. If it be soft and spongy, the integrity of the nerve may be preserved by a careful use of the fingers or director. The upper extremity of the gland is last removed. This step of the operation is necessarily attended with considerable hemorrhage, which is, however, easily

controlled. After the removal, unite the flaps, establish drainage, and dress antiseptically.

Results.—This operation has been done upward of one hundred and ten times. When done for malignant growths, the disease has almost invariably returned within six months. The dangers to life from the operation itself, when carefully performed, are not imminent.

Paracentesis Thoracis.—This operation is done to remove a fluid accumulation from the chest cavity.

The instruments employed for the purpose should be one of the many forms of aspirators (Figs. 580, 581). If one of these be not available, the ordinary trocar and canula can be used, due heed being given to the danger of the admission of air into the pleural cavity. The intercostal space through which the trocar should be introduced will depend upon the amount of fluid in the cavity. As a rule it may be stated that the intercostal space selected should be three or four inches above the lowest limit of abnormal dullness. The instrument is introduced nearest to the upper border of the rib, midway between its sternal and vertebral extremities, or on a line with the inferior angle of the scapula. It is often very difficult, on account of obesity, to determine the numerical relations of the ribs. The elevation between the first and second bones of the sternum corresponds exactly to the articulation of the second costal cartilages. The nipple in the male is located usually between the fourth and fifth ribs. If the nipple be normally located, a line carried horizontally from it around the chest will pass over the sixth intercostal space in the line of the axilla; if the arm be raised, the first visible digitation of the serratus magnus is attached to the sixth rib. The inferior angle of the scapula covers the seventh rib, therefore the first intercostal space below it is the seventh. The eleventh and twelfth ribs can be felt in corpulent persons outside the erector spinæ, sloping downward. If any one of the intercostal spaces below the seventh be selected, the diaphragm may be punctured if the trocar be inserted incautiously.

Operation.—Prop up the patient in bed, or, if able, allow him to sit astride a chair with his arms resting on its back, and his head supported by them. The thickness of the walls of the chest and the presence of fluid must first be determined by the introduction of the needle of a hypodermic syringe. All the instruments and the surface at the point of proposed puncture should be well carbolized. The integument over the intercostal space through which the puncture is to be made must be drawn upward, since, as the fluid escapes from the chest, the space will descend; if this be not done, the puncture through the skin will soon be above the intercostal space. A knowledge of this fact is of immense importance if a permanent opening is to be established, as in empyema. If the puncture be made in the vicinity of the diaphragm, the point of the instrument must be di-

rected upward and inward. Locate the seat of the proposed puncture and make a small incision through the skin with a lance, with or without the use of cocaine, insert the end of the instrument, and as soon as the point is fully engaged in the tissues, extract the air if it be connected with an aspirator, and push it quickly in, guarded by the index-finger laid along its side. If the instrument become closed by false membrane or floating fibrin, the obstruction must be removed by a small wire passed through its lumen. The pulse and the sensations of the patient must be consulted during the evacuation to avoid, if possible, sudden syncope. Death is rarely directly due to this operation.

Perforation of the Antrum.—When fluid accumulations occur in this cavity, they can be removed by the trephine, or by the ordinary bone-drill passed into it through its anterior wall, or into its floor through the socket of the first permanent molar tooth, being careful that the drill does not perforate the floor of the orbit. The cavity is then washed out and the opening maintained by the introduction of a gold tube, if practicable, until the function of the mucous membrane is restored.

OPERATIONS UPON THE NOSE.

Plugging the Posterior Nares (Fig. 756).—This is done to arrest obstinate epistaxis. The tampon or plug can be made of sponge, lint,

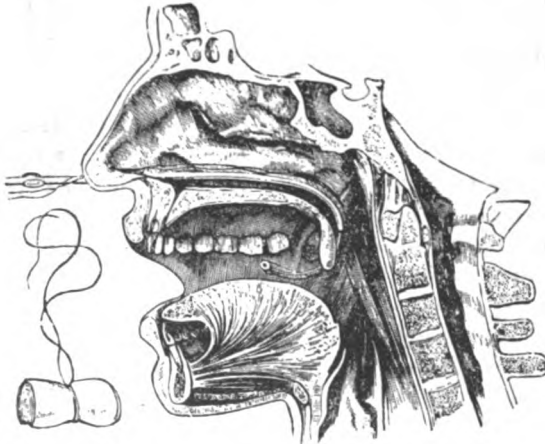


FIG. 756.—Plugging posterior nares.

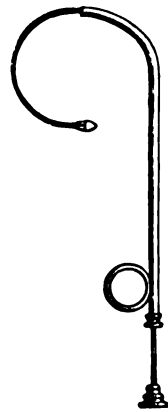


FIG. 757.—Belloccq's canula.

or of suitable cloth, and should be of a proper size to closely fit the posterior naris, which in the adult is about three fourths of an inch long and half an inch wide. The plug is made by tying a strong ligature around the middle of the material selected for the purpose and suitably arranged, cutting the ends of the ligature short, and passing beneath it on opposite sides of the plug two equally strong liga-

tures, which are looped around and firmly tied to the first one. The canula of Bellocq (Fig. 757), with the spring withdrawn, is then carried along the floor of the nostril to the posterior wall of the pharynx, when the movable rod is projected and curves forward into the mouth. The extremities of the loop at one side of the tampon are passed through the instrument and down through the meatus by returning the central rod and withdrawing the instrument. The tampon is now carried into position by pulling upon the strings aided by the finger carried behind the soft palate. Sufficient traction is made upon it to forcibly close the naris, and the strings in front are tied around a plug of a similar material, which closes the anterior opening. The plug should be well carbolized before its introduction, and, if need be, can be wet with astringent solutions. It should be removed at the end of forty-eight hours, which can be easily done by pulling on the strings remaining in the mouth while it is forced backward by an instrument introduced through the floor of the nostril. If the canula of Bellocq be not available, a long, flexible probe, an ordinary gum catheter, and even common wire, may be utilized. Sometimes a string is carried through the nostril by means of the canula and attached to the plug, instead of being tied to it before the canula is introduced.

Removal of Nasal Polypi.— If the growths or pedicles be small, they can be quite readily removed by forceps (Figs. 758 and 759) or the snare. If the forceps are to be employed, the patient should sit in a chair, exposed to a strong light, with the head supported by an assistant, and, after spraying the nares with a strong solution of cocaine, the attachment of the growth is seized, and it is twisted off by turning the instrument several times on its long axis. If the growth be attached to a turbinated bone, it may be necessary to pull away some of the bone structure before the tumor can be removed. If the growth be situated far back or hang down into the




FIG. 758.—Curved nasal polypus forceps.

FIG. 759.—Straight nasal polypus forceps.



FIG. 760.—Nasal polypus canula.

fauces, it may be detached by the finger passed behind the soft palate. If this fail, it may be snared (Figs. 761, 762, 763). The wire, either

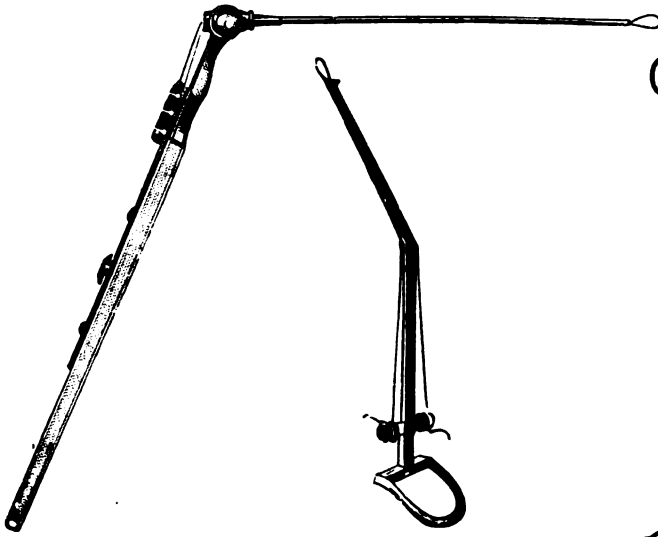


FIG. 761.—Sexton's snare.

FIG. 762.—Codman & Shurtleff's snare.

FIG. 763.—Jarvis' polypus snare.

with or without the canula, is passed along the floor of the nose, and the loop passed over the tumor (Fig. 764), by aid of the finger

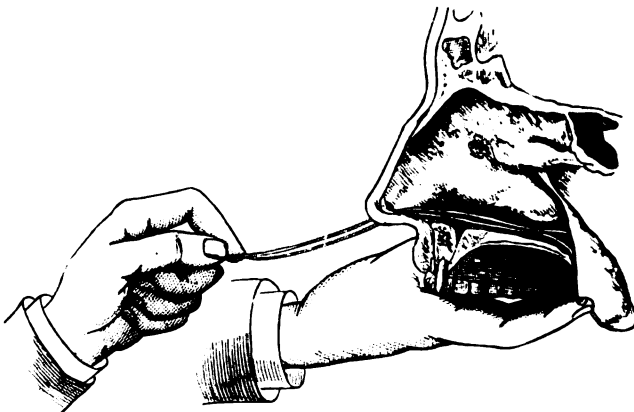


FIG. 764.—Removing polypus.

if necessary ; the loop is tightened and the growth severed (Fig. 765). If the growth be fibrous and not accessible by the previously mentioned methods, it can then be exposed by opening the nasal cavity.

The cavity of the nose may be exposed if the nose be turned *upward* after detaching it on both sides through the alæ and at the junction of the nasal bones with the nasal processes of the superior maxillæ, and in the median line to the septum. After the removal of the growth the parts are restored to their normal position, and the edges of the wound united. *If this method be not deemed advisable*, the nose can be turned downward by making a U-shaped incision

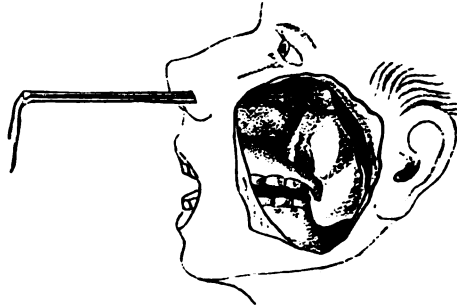


FIG. 765.—Double canula in position.

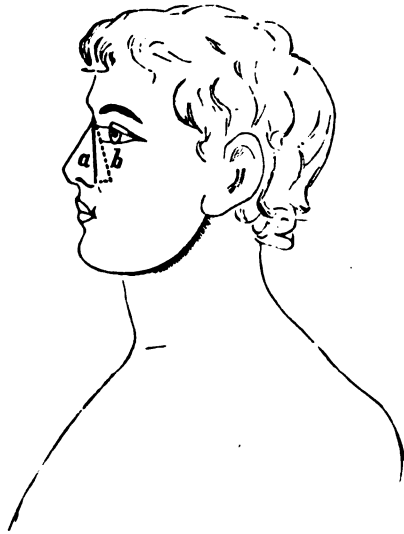


FIG. 766.—Lines of incision.

down to the bone, the convex portion of which shall cross the root of the nose between the eyes and extend downward at each side of the nose to the outer borders of the alæ (Fig. 766, *a*). The bones are then sawn through in the line of the incision, the septum liberated at their under surface, and the nose turned downward, so as to expose the interior surfaces to observation and manipulation. If the growth be a large one and greater space be necessary, the incision can be modified, as shown by the dotted line *b*, and the bones lying in their course sawn through as before described, care being taken to avoid the roots of the teeth. After the removal of the growth the parts are replaced and confined in position by sutures, dressings, etc. Naso-pharyngeal polypi can sometimes be removed by this method (Ollier).

Langenbeck's Method.—Make an incision from the junction of the nasal with the frontal bone vertically downward in the median line of the nose to the upper border of the cartilages of the alæ, thence outward upon the cheek (Fig. 767, *a*). Dissect off the triangular flap, leaving the periosteum; sever the alar cartilage from the nasal bone, and with bone nippers sever the nasal bone from its fellow. Also in the same manner separate the nasal process of the superior

maxilla from its body, then the entire upper part of the nasal cavity can be exposed by raising upward the quadrilateral plate of bone.

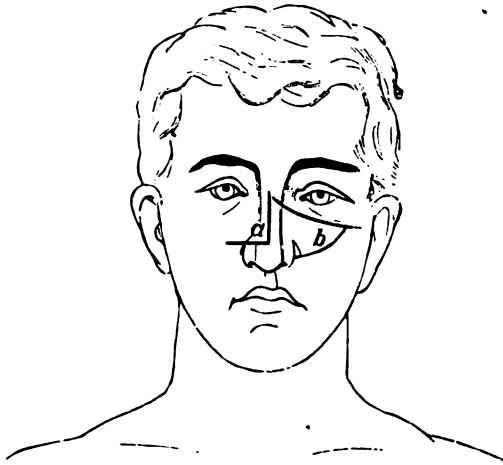


FIG. 767.—Langenbeck's lines of incision.

After the tumor is removed, the bone can be returned and fastened in its proper position. If the tumor be still larger, it may be attacked by an opening through the hard palate (Nélaton, Fig. 768).
Nélaton's Method (Fig. 768).—Make an incision in the median line, through the soft palate down to the bone; continue it forward, along the posterior half of the hard palate; two others are now carried obliquely outward on either side from the anterior extremity of the incision along the hard palate, to the alveolar process; these flaps, including the periosteum, are reflected outward, the hard palate perforated and cut away, the periosteum and mucous membrane of the floor of the nose turned aside, the septum removed if necessary, and the tumor will be exposed to view and can be removed. The periosteal flap of the hard palate should be returned to the normal position, and stitched after the growth is removed. The cut through the soft palate can be joined subsequently. If the growth be a small one, but one side of the hard palate need be attacked. Nasopharyngeal polypi may be advantageously reached by this method.

Removal of Naso-Pharyngeal Polypi.—
Langenbeck's Method.— Make a slightly curved incision with the convexity downward, extending from the ala of the nose to the malar bone and as far backward as the middle of the zygoma. A second incision is made, beginning near to the center of the root of the nose, and, passing along the inferior margin of the orbit, it joins the former near the middle of the malar bone (Fig. 767, *b*). These incisions should extend




FIG. 768.—Nélaton's method.

through the periosteum down to the bone ; the soft parts, however, are not to be raised. Separate the masseter muscle from the malar bone, divide the buccal fascia, depress the inferior maxilla, and pass the finger, if possible, into the posterior nares by carrying it through the pterygo-maxillary fissure into the spheno-maxillary fossa, thence through the spheno-palatine foramen, all of which passages may have been distended by the morbid growth. A small key-hole saw is passed by the same route, and the superior maxilla divided from behind forward ; the extremity of the saw is covered by the end of the index-finger, carried into the pharynx through the mouth, to protect the tissues from being injured by it. The zygomatic process of the temporal, frontal process of the malar, and orbital process of the superior maxilla are sawn through to the lachrymal bone. The superior maxilla can be divided in the line of the superior incision of the soft parts, thus leaving the orbital process intact. The osteo-cutaneous flap is now raised by an elevator carried beneath the malar bone and slowly lifted upward and inward toward the nose, the bones and soft parts of which form a hinge to the flap at that side. If the saw can not be passed into the posterior nasal cavity even by the aid of a grooved director, the lips of the incision of the soft parts may be drawn asunder and the bone sawn from without inward and before backward. Either incision exposes polypoid growths of the pharynx admirably for manipulation. The operation is usually attended by quite severe hemorrhage, which, however, can be controlled readily by pressure and an occasional ligature. After the removal of the growth, the parts are adjusted and confined in position by sutures, etc. If the growth to be removed be a large and vascular one, a preliminary tracheotomy should be done. If it be malignant and very vascular, and have a large attachment, I deem it a wise precaution to tie both external carotids prior to removal. The dangers from hemorrhage will be lessened by this measure, and, moreover, the diminished vascularity of the parts will hinder the redevelopment of the growth.

Results.—The rate of mortality from this method is less than twenty-five per cent, and depends more on the removal of the growth than upon the steps necessary to reach it. The mortality is greater when the operation is done through the hard palate than when performed by means of the displacement of the upper jaw.

Cheever's Method.—In this both superior maxillæ were removed, owing to the large size and central situation of the growth. He made an incision from near the inner canthus on each side of the nose downward along the natural furrow, around the alæ to the median line of the lip, which he divided. These flaps were reflected upward and outward as far as the malar prominence, and the body of each superior maxilla was sawn from behind forward to the middle meatus of the nose ; the septum and vomer were cut by scissors ; the jaws were

then depressed and the tumor removed; after which the bones were replaced and wired in position. The loss of blood was not great, but the patient died on the fifth day from exhaustion.

The excision of the entire upper jaw may be practiced for the removal of these growths, or only the portion below the line of the orbital floor may be removed. The superior maxilla can be raised and turned outward on a hinge formed by the zygomatic process of the malar bone and the contiguous soft parts, by dividing the bone in the line of Ferguson's incision (Fig. 243, *b*), the upper portion of which, for this purpose, should be extended to the malar bone. The maxillæ are separated by sawing through the hard palate and alveolar process, and the nasal bone is disconnected from the superior maxilla by severing its connections with bone-forceps. The osteo-cutaneous flap can then be raised and swung outward. If necessary, the soft palate may be divided. After the removal of the growths the parts, including the soft palate, are adjusted and joined by sutures.

With the view of avoiding as far as possible the division of the terminal filaments of the superior dental nerve, and obviating the loss of function incident thereto, Langenbeck recommended that a curved incision be made, crossing the cheek about midway between the angle of the mouth and the lower border of the orbit, beginning near the lower end of the nasal bone and extending downward, outward, and upward so as to avoid the Stenon duct. The flaps are dissected from the superior maxilla and it is removed through the opening made in the soft parts. If the whole bone is to be removed, the integrity of the superior maxillary nerve can be still further preserved by removing it from the infra-orbital groove by the aid of a fine, sharp chisel.

The removal of a growth of any great size from the posterior nares or pharynx, especially the latter, will be attended, if its attachment be extensive, by the entrance of a large amount of blood into the pharynx and trachea; it is, therefore, wise to do a preliminary tracheotomy so that the lower extremity of the pharynx may be closed by sponges, or otherwise tamponed. If the shoulders be elevated and the head allowed to fall far backward, the blood can be removed from the dependent portion of the pharynx as fast as it collects; this position, however, impedes respiration by over-extending the muscles that act on the os hyoides. If a preliminary tracheotomy be done, the anæsthetic must be administered through the tube. The apparatus devised for this purpose by Trendelenburg (Fig. 769) may be used entire, or only the inhaling portion attached to the ordinary tracheotomy-tube can be employed; the latter plan is generally to be preferred, since the rubber tampon attached to this tube often causes bronchial irritation when inflated; moreover, if it become ruptured

during the course of an operation, or be imperfectly distended, blood may enter the trachea unawares.




FIG. 769.—Trendelenburg's trachea tampon.

Deviation of the Septum Nasi.—It not unfrequently occurs that both the bony and cartilaginous portions of the septum are deflected to such an extent as to seriously interfere with breathing through the nose during attacks of coryza, and likewise impart a distinct nasal twang to the voice. This deformity may or may not be associated with external modifications of the nasal symmetry. In either case the indication remains the same—to overcome the deformity and to maintain the corrected relations of the parts until recovery takes place.

Operation.—The deformity can be overcome by grasping the abnormal septum between the blades of forceps especially designed for the purpose (Fig. 770), which are thrust into the anterior nares and closed upon the deformed septum, and held for a few moments with sufficient firmness to press its irregularities into a normal position. The resistance is still fur-

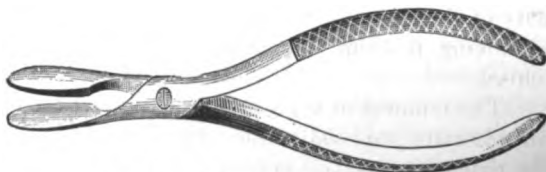

FIG. 770.—Adams' rhinoplastos forceps.

ther overcome by cautiously turning the forceps from side to side on their long axis. The pressure exerts a crushing and compressing influence on the septum, causing it to assume or admit of its being pressed into a normal position. The retentive apparatus is a specially constructed clamp (Fig. 771), which is screwed into position with the blades grasping the septum. The instrument retains the parts thus reduced until the reparative processes necessary to their permanency have taken place. The clamp can be permitted to remain in position for two or three days, not tightly screwed—for this would cause undue pressure—but closely enough to exert a gradual controlling influence. This indication can likewise be well met by introducing ru

tubes of proper size and length, surrounded by oiled lint, into each nostril; these tubes by their elastic pressure answer the purposes of the clamp, and at the same time permit air to pass unobstructed through the nostrils.

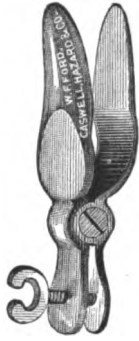


Fig. 771.—Adams' clamps.




Fig. 772.—Ivory plugs.

After three or four days either of the preceding appliances should be replaced by ivory plugs (Fig. 772), which are pushed into each nostril and worn at night only. It is true that this treatment is annoying and even attended by positive discomfort, yet the almost assured good result will amply repay the patient for the affliction incurred. In addition to this, other operations are recommended, such as the removal of the inferior turbinated bone on

the side of the deflection; punching the septum, to establish a communication between the closed and the unclosed nostril. Neither of these rectify the deformity, and both are open to objections, the former of a physiological, the latter of a pathological nature. The removal of the projecting cartilage and its mucous membrane is likewise commended. The removal of the deformed septum together with a portion of the superior maxilla (Post), accomplished by separating the side of the nose from the cheek, turning the nose over, and thus gaining access to the obstruction, constitutes an operation having a severity out of proportion to that of the primary difficulty; and, moreover, it may be followed by an unsightly scar. It is recommended that the meatus be burred out (Wagner) by means of the dental engine. The results which he reports certainly give strong testimony in favor of the suggestion. The deformed portion of the septum may be sawn off on a plane conforming to that of the remaining portion by first applying a strong solution of cocaine to it, then removing the deformity with a narrow fine saw constructed especially for the purpose. This plan is followed by Professor Bosworth, and it appears to me preferable to burring or punching the septum.

BRONCHOTOMY.

This expression includes three distinct operations—*laryngotomy*, *tracheotomy*, and *laryngo-tracheotomy*, the first two of which are further classified. These operations are comparatively easy in the adult, especially if the neck be long and the landmarks well developed. In the infant and the child, and before puberty—the peri-

of life when they are most demanded—the performance is most difficult, owing to the shortness of the neck, obesity of the patient, and the rudimentary condition of the landmarks. The thyroid cartilage, which is well marked in the adult, constituting a prominent point of reckoning, is scarcely discernible in the child, and in the infant it is impracticable to determine its location by physical examination. The cricoid cartilage is a far better guide by which to determine the comparative relations of the parts. It is the distinctive cartilage of the laryngeal group, and, irrespective of age, it can be felt as a firm, round ring, much more prominent than the cartilaginous rings of the trachea, which lie immediately below it. The crico-thyroid space, through which in laryngotomy the deep incision is made, is located immediately above the cricoid cartilage, between it and the thyroid (Fig. 773). It is situated at the bottom of the first groove-like depression above the cricoid cartilage. The crico-thyroid membrane is composed of yellow

elastic tissue, and is, therefore, of a yellowish appearance, and is often dotted by openings for small vessels. When incised it will retract, owing to its resilient nature; hence all hemorrhage should be stopped before it is opened—if the urgency of the case will permit. It is not difficult to locate the guides in the dead subject under ordinary circumstances; but, in the living, when they are being jerked upward and downward by the efforts at respiration, it is a matter of great difficulty, and may be impossible. The only artery normally in the line of the operation of laryngotomy that need be respected is the crico-thyroid, which runs along the upper border of the space, resting on the membrane of the same name. It is troublesome, not from the amount of blood it contains, but from its relation to the opening in the membrane, through which a small amount of blood may pass into the tube. The vessels causing the greater annoyance—especially if the patient be much cyanosed—are the small venous trunks which run across the tracheal and laryngeal region, without any definitely established relationship, and which return their blood chiefly into the superior thyroid veins (Fig. 774). The anterior jugular veins will be troublesome, unless the median line be adhered to closely. It

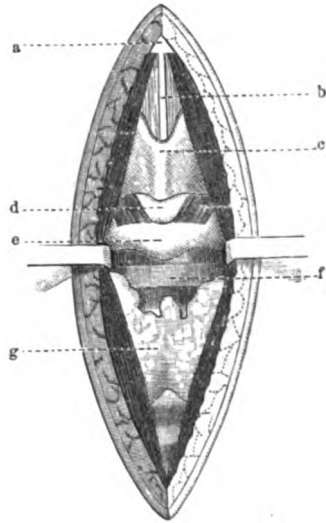


FIG. 773.—External cartilages of the larynx. *a.* Body of hyoid bone. *b.* Thyroid-hyoid membrane. *c.* Thyroid cartilage. *d.* Crico-thyroid membrane. *e.* Cricoid cartilage. *f.* First tracheal ring. *g.* Isthmus of thyroid body.

is unnecessary, I trust, to allude to the well-known relation between the larynx and the large vessels of the neck. The thymus gland in

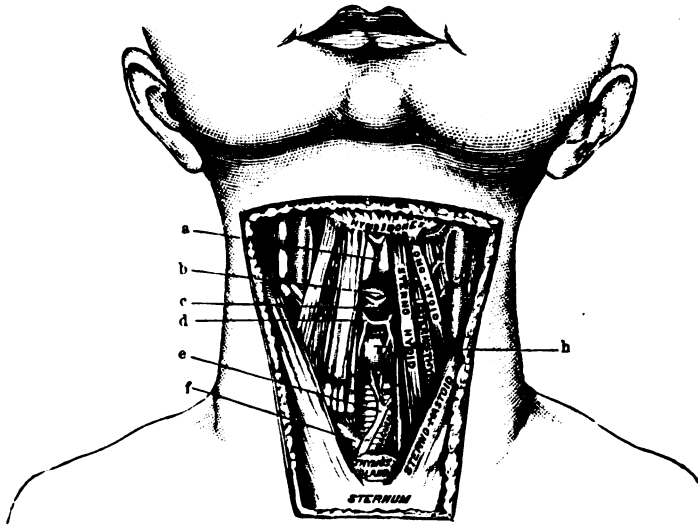


FIG. 774.—Surgical anatomy of larynx and trachea. *a.* Thyroid cartilage. *b.* Crico-thyroid membrane and artery. *c.* Cricoid cartilage. *d.* Superior thyroid vein. *e.* Inferior thyroid vein. *f.* Arteria innominata. *h.* Thyroid body.

the very young deserves respectful consideration, as will hereafter appear. The choice of anæsthetics to be given in operations where the respiratory function of the larynx is involved is a matter entitled to some consideration. For instance, if ether be given to one who has no laryngeal irritation or obstruction, the frequent spasm of those parts is familiar to all. If to this be now added the deficient aëration of the blood, due to a laryngeal obstruction, together with the increased tendency to spasm, dependent on laryngeal disease, then is the danger of asphyxia greatly augmented. Chloroform may be given with but little danger of causing spasm; if ether be administered, it must be commenced very gradually, to avoid as much as possible the occurrence of laryngeal spasms. In many instances the pressing nature of the case will not permit the expenditure of the time necessary to produce anæsthesia. In those cases presenting marked cyanosis the sense of pain is much blunted, and the operation should be done without anæsthesia. The instruments suitable for these operations are quite numerous, yet the absence of any one or more of them is not to be considered a reason for its non-performance when demanded. When necessary, a pocket-knife, a hair-pin, or a toothpick, can be extemporized to advantage, thus preventing the death of the patient unaided because a tracheotomy-tube is not obtainable.

Tracheotomy Instruments.—Two scalpels should be at hand, one sharp and the other probe-pointed (Fig. 775); also an ordinary grooved director, retractors (Figs. 776 and 777), and small spatulæ, to draw aside the tissues, and tracheotomy-hooks, to fix the trachea during its

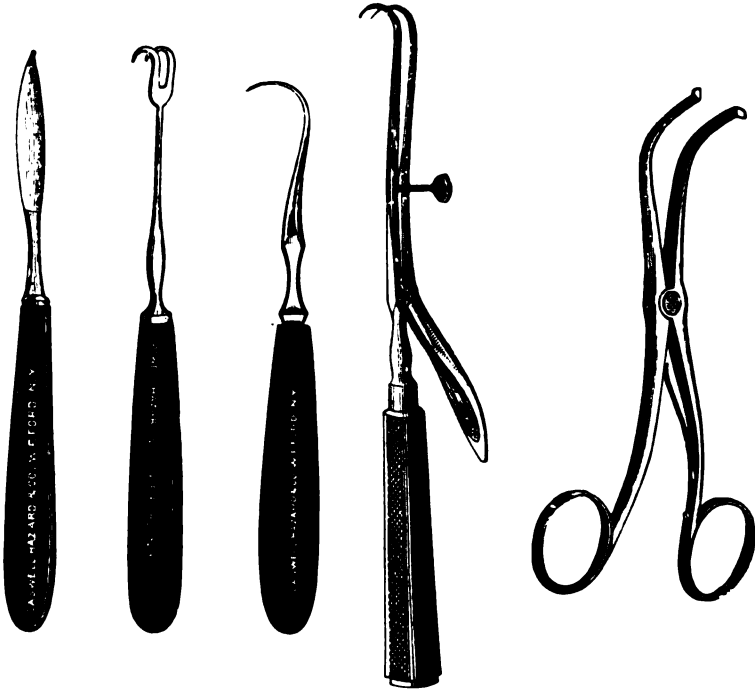


FIG. 775.— Probe-pointed scalpel. FIG. 776.— Retractor. FIG. 777.— Tenaculum-retractor. FIG. 778.—Lan-genbeck's double hook. FIG. 779.—Trousseau's trachea dilator.

incision (Fig. 778). The hook illustrated is the best in use, because the line of the cut can be made between its blades, and the center line of




FIG. 780.—Chassaignac's trachea dilator.

the trachea is therefore better assured. There are various forms of tracheotomes, which should not, in my opinion, be substituted for the sharp-pointed bistoury, because they are much less surgical in their

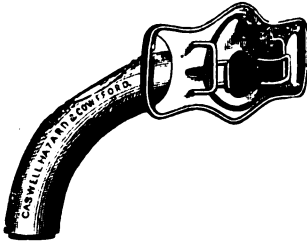


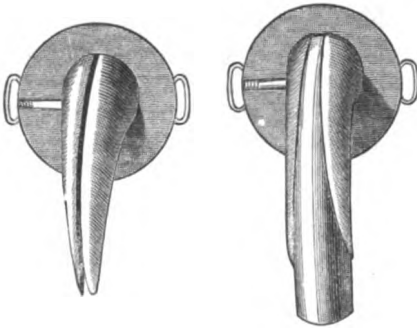
FIG. 781.—Silver trachea tube.



FIG. 782.—Hard rubber trachea tube.

inception and far more dangerous in their use. Dilators, too, are quite numerous and varied in pattern. Trousseau's (Fig. 779) and Chassaingnac's (Fig. 780) are fair representatives of them, and will answer the purpose admirably. The borders of the tracheal opening can always be easily drawn apart by the common tenacula or by two of the ordinary grooved directors with aneurism-needle attachments. Tracheotomy-tubes of various forms are employed. Figs. 781 and 782 represent

those in every-day use, the latter being of hard rubber. The bivalve trachea tube (Fig. 783) is an admirable instrument, since it can be introduced through the opening in the trachea much more readily than the ordinary blunt-ended pattern, and can be afterward quickly opened by the introduction into it of the companion tube (Fig. 784). Fig. 785 represents forceps for the removal of foreign bodies. A long feather,



FIGS. 783, 784.—Bivalve trachea tubes.

with the tip of the brush remaining, should be at hand to insert into the trachea through the tube, to create the irritation sometimes necessary to cause the expulsion of the tracheal mucus. A so-called trachea aspirator has been devised to remove mucus and blood from the trachea (Fig. 786). It is used as follows: After the insertion of the trachea tube, place the thumb on the air-hole of the barrel; apply the soft rubber cup over the tube, and withdraw the piston, when the mucus and blood will enter the barrel. It has not infrequently happened that a patient is unable to expel the blood and mucus on account of stupor or weakness, and the lips of the operator were used to clear the trachea.

This is obviously a hazardous procedure, if the patient have syphilis or diphtheria. The possession of the tracheal aspirator will be welcomed as preferable under all circumstances.

A serviceable instrument for the purpose of removing blood, etc., from the trachea-tube, and even from the trachea itself, can be quickly extemporized by attaching to the nozzle of an ordinary two-ounce rubber syringe a soft piece of rubber tubing



FIG. 785.—Trachea forceps.



FIG. 786.—Trachea aspirator.

five or six inches in length. The unattached end of the rubber tubing is inserted into the trachea-tube or into the trachea itself; the piston of the syringe is withdrawn somewhat quickly, and the fluid sucked up. If the suction be made too quickly, the tube will be collapsed and inoperative. Large portions of membrane have been drawn from the bronchial tubes in this manner.

Laryngotomy.—Place the patient on a table with the shoulders elevated, head thrown back, and neck exposed to a strong light. At least three assistants are required, especially if an anæsthetic be given. Locate the cricoid cartilage, support the larynx firmly between the thumb and finger of the left hand, then make an incision through the integument an inch and a half in length in the adult, terminating at the lower border of the cricoid cartilage, and divide the fascia on a director; divide the connections between, and separate the borders of the sterno-hyoid muscles with retractors, push aside the veins and connective tissue, and the crico-thyroid membrane will be seen. If the case be not urgent, check all hæmorrhage before opening the larynx. If otherwise, open it at once, when the entrance of air and the resumption of the respiratory functions will dispel the cyanosis and check the bleeding. The larynx is seized and held firmly by a tenaculum while the opening is made through the crico-thyroid membrane transversely along the upper border of the cricoid cartilage to avoid the crico-thyroid artery, that runs along the upper border of the membrane, near the thy-

roid cartilage, and also to remove the tube as far as possible from the vocal cords. The whistling of the ingoing air, succeeded by an expulsive cough—which ejects the mucus, blood, and other matters—follow

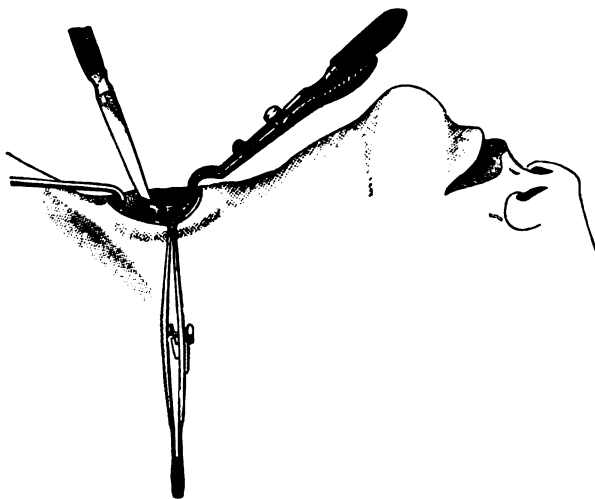


FIG. 787.—Opening the trachea.

quickly after the incision. If the operation be performed for the removal of a foreign body, it may at this time be expelled, or become lodged near the opening, when it can be removed by forceps. If the

operation be performed for laryngeal diphtheria, the tube should not be inserted until all loose membrane has been expelled, and such as may be within reach of the forceps has been pulled away. If blood escape into the opening from the oozing vessels, the pressure of the tube upon the lips of the wound will serve to check it, and for this reason it may be introduced early. The tube is carried carefully in while the borders of the opening are held apart with the orthodox retractor, or by means of two blunt artery-needles or tenacula, after

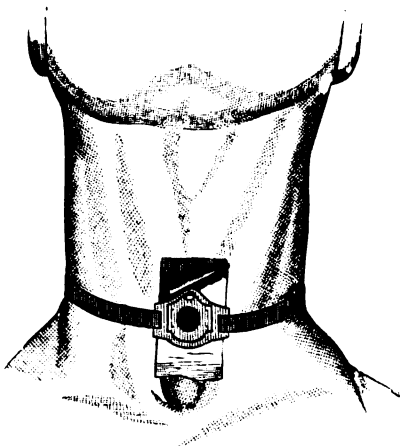


FIG. 788.—Tube in position.

which it is fastened in position by means of tapes carried around the neck and tied behind (Fig. 788). If the opening be too small, it may

be increased by division of the cricoid cartilage (crico-laryngotomy). *The size of the tube* is a matter of great importance, since if it be too large it will be difficult to introduce and be followed by ulceration. For patients four years and under, a tube with a caliber of a fourth of an inch is sufficient, in those four to eight years of age, one third of an inch, and about one half an inch for an adult. The soft parts above and below the tube are closed by antiseptic sutures, the patient is then placed in bed and caused to breathe air saturated with warm vapor from which all floating particles of dirt should be excluded. The tube is carefully watched to prevent it from becoming closed, and occasionally removed and cleansed. Too great emphasis can not be laid upon the necessity of instantly relieving the sudden occlusion of the tube due to false membrane. For this reason, a momentary inattention, as leaving the room, etc., may prove fatal to the patient. After three or four days the tube may be removed and the patient allowed to breathe through the opening for a few hours, when the tube must be again inserted; later in the case it may be inserted only during the night. As soon as the patient can breathe well, the tube should be entirely removed, the opening closed and cleansed, and the soft parts joined by a suture. If antiseptic gauze (not bichloride) or adhesive plaster be placed between the surface of the neck and the flanges of the tube, the danger of irritation of the soft parts by these portions of the tube will be obviated (Fig. 788).

Tracheotomy is the operation usually performed upon children, owing to the small size of the crico-thyroid space. It is the preferable operation in all instances when the incision should be made as far as possible from a contagious local disease. *It may be done in three situations—above, below, and behind the isthmus of the thyroid gland; the one below the isthmus is to be preferred.* The upper portion of the trachea is quite superficial, while the lower is from half an inch to an inch in depth, depending upon the shortness of the neck and the obesity of the patient. The lower portion recedes, following the curve of the spinal column. The vascular structures in this portion are far more important and numerous than in other parts of its course; the inferior thyroid veins (Fig. 789), and their communications, pass in the course of the incision; the arteria thyroidea ima when present runs along the center of the trachea; the arteria innominata, especially in the child, runs obliquely across it, at the root of the neck from left to right. The isth-

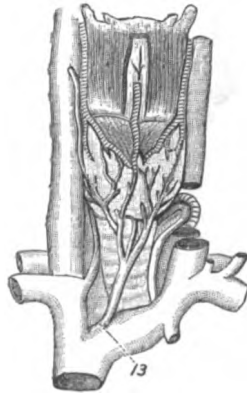


FIG. 789.—Vascular relations of throat.

mus of the thyroid covers the second, third, and often the fourth rings of the trachea; above it is seen the communicating branch between the superior thyroid veins (Fig. 774, *d*); the thymus gland, which attains its full size at two years, encroaches upon the space from below upward with each labored respiratory act, and may be incised. *It is sometimes difficult* for the beginner, when surrounded by the turmoil incident to the operation, to be certain of the location of the trachea. If the index-finger be inserted into the wound, the trachea will roll under it, and be felt ascending and descending beneath its extremity, and, when sufficiently isolated, the rings can be seen and felt. The inexperienced operator is also likely to make the opening at one side of the median cut, which makes it difficult to introduce the tube, causes it to bind after introduction, and not infrequently, if the tissues overlap the cut before its introduction, causes air to be forced between their planes, creating local emphysema. If the knife be inserted too far, the posterior wall of the trachea will be divided.

Operation below the Isthmus.—Place the patient as for laryngotomy, and, if practicable, administer an anæsthetic. Finally, support the trachea in the median line of the neck and make an incision in the median line, extending from the cricoid cartilage to within half an inch of the top of the sternum; divide the fascia on a director; cautiously separate and pull aside the sterno-thyroid and sterno-hyoid muscles, thus exposing the deeper cervical fascia, beneath which are located the inferior thyroid veins (Fig. 789, 13) supported by connective tissue. This fascia should be torn asunder by a blunt instrument, and pushed aside along with the veins and connective tissue beneath, which will expose the trachea. The blunt ends of two ordinary directors can be utilized for separating the fascia, or instruments especially devised for dry dissections can be employed. Throughout the entire operation the tissues must be drawn asunder as fast as separated, by means of blunt hooks or other form of retractors, to afford ample exposure of each succeeding part. As soon as the trachea is reached and all hemorrhage checked, it is seized by a hook—the double one of Langenbeck being the best—drawn forward to near the surface of the wound, firmly held, and three or four rings of the trachea divided exactly in the median line from *below upward*, by a sharp-pointed knife (Fig. 787). Then the dilator is introduced, and the tube inserted and confined in position after the tracheal mucus and blood have been expelled. All incisions, except the primary one, must be directed upward to avoid the great vessels at the root of the neck. The opening in the trachea should be long enough to admit the easy expulsion of all false membranes and foreign bodies (even an inch in length is not too much for this purpose), and must likewise readily admit the trachea tube.

Operation above the Isthmus.—Make an incision of the usual

length, its center corresponding to the lower border of the cricoid cartilage; divide and carefully separate the tissues as before; the loop of communication between the superior thyroid veins must be carefully drawn upward; the fascial attachment between the isthmus and the cricoid cartilage divided, the isthmus pulled downward and drawn forward by a blunt hook, when the trachea can be opened beneath it from below upward, and the tube inserted with the same precautions as before.

Operation through the Isthmus.—This is hardly of enough practical importance to be entitled to a detailed consideration, since the opportunities afforded above and below it will be sufficient. If, however, this position be selected, the isthmus should be divided between two ligatures to avoid the probability of troublesome hemorrhage. It sometimes happens that the isthmus is small or too illy developed to be troublesome after its division.

Laryngo-tracheotomy.—In this operation the larynx and trachea are both opened by a continuous incision, which is usually made to increase the space, that foreign bodies and false membrane may be removed. The incision through the cricoid cartilage and upper rings of the trachea is then secondary to the opening of the larynx. Before the primary incision is extended, the communicating branches of the superior thyroid veins should be pulled downward, the lower border of the cricoid exposed, its fascial connection to the isthmus severed, and the isthmus drawn downward and forward as before.

Rapid Laryngo-tracheotomy (Saint-Germain).—It is sometimes necessary to open the larynx very quickly; therefore it is quite proper to mention some of the points connected therewith, that the surgeon may be prepared to act with dispatch combined with great caution.

Operation.—With the patient placed in the usual position for tracheal operations, the surgeon locates the thyroid and cricoid cartilages and the space between them. Then, standing on the right side of the patient, he seizes and pushes forward the larynx by pressing the thumb and index-finger between it and the vertebral column, thereby making the integument tense. At the same time the index-finger locates the lower border of the thyroid cartilage. A straight, sharp-pointed bistoury is then seized between the thumb, index, and middle fingers, its back upward, with the middle finger so placed that the knife can not penetrate to exceed half an inch in depth. While thus held, its point is quickly entered at the nail of the index-finger and the blade is carried downward with a sawing motion, dividing the crico-thyroid membrane, cricoid cartilage, and one or two rings of the trachea. The opening through the integument should equal in length the one made in the larynx and trachea. The dilator is introduced, all bleeding checked, and the tracheal tube placed in position. Saint-

Germain up to 1877 had operated by this method ninety-seven times, with but three cases of hemorrhage, and one in which the posterior wall of the trachea was cut.

If the tube be too large, too loose, or too angular, it is liable to cause erosions and ulcerations of the trachea, which may extend through it and implicate the vessels at the root of the neck, causing fatal hemorrhage. The method of opening into the trachea by a single incision is fraught with danger, and should not be attempted except the neck of the patient be long and thin, and not even then unless the exigencies of the case call for it. The division of the tissues down to the trachea by means of thermo- or galvano-cautery has many advocates; it is not, however, the adopted practice of this country. The searing of the tissues is said to prevent or lessen hemorrhage, and likewise to obviate the inoculation of the incision by contagious germs. This is not altogether true, since the large veins which might be otherwise avoided are burned asunder and too often cause severe hemorrhage, which is not easily controlled because of the difficulty of properly securing the charred extremities of the vessels. The resulting cicatrix is more disfiguring than that following other methods. It is advised in bronchotomy for diphtheria and acute affections of the air-passages that the tube be dispensed with, since it can only prove a source of local irritation, and obstructs the exit of false membranes and the secretions. As a substitute, the borders of the tracheal opening can be kept drawn asunder by passing looped ligatures through them (Martin), which are united to each other behind the neck. The patient must be carefully watched with this appliance, since if the head be turned the opening may become closed. If this prove troublesome, an elliptical piece can be removed from the anterior surface of the tube. If the piece removed exceed a third of the diameter of the tube, fatal stenosis may follow its closure.

Results.—But few perish from the direct results of the preceding operations. Bronchitis, pneumonia, hemorrhage from ulceration through the trachea caused by the tube, and primary hemorrhage from wounds of the vessels at the root of the neck, or from any abnormally large crico-thyroid artery, constitute the leading causes of death directly due to the operation. A deeply cyanosed patient, in the tonic stage of anæsthesia, may die, especially if blood be allowed to enter the tracheal opening. In this contingency the blood must be removed at once, and artificial respiration be resorted to. Tracheotomy in diphtheria is undoubtedly a most feasible operation, and should be performed early, before cyanosis is well established. Dr. Monti, of Vienna, in his recent work on "Croup and Diphtheria," records 12,736 tracheotomies for diphtheria alone, with 3,409 recoveries, or nearly twenty-eight per cent. It is estimated that twenty-five per cent of these cases have been saved which otherwise would have died.

About twenty-seven and a half per cent perish after bronchotomy for the removal of foreign bodies.

Intubation of the Larynx.—It appears to be proper in this place to consider a plan of treatment of laryngeal obstruction which has of late attracted more than usual attention, especially in connection with the apparatus devised for the purpose by Dr. O'Dwyer, of this city (Fig. 790). "The numbers on the scale (Fig. 790, *d*) indicate the

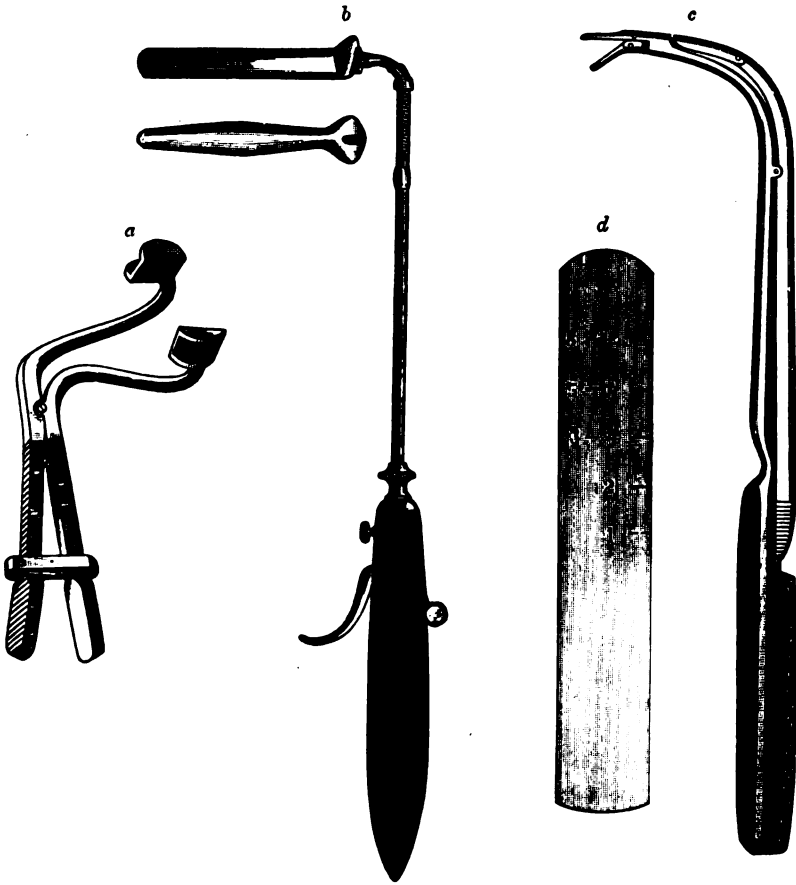


FIG. 790.—O'Dwyer's instruments for intubation of the larynx. *a*. Mouth-gag. *b*. Introducer, with larynx tubes. *c*. Extractor. *d*. Scale.

years for which the corresponding tubes are suitable. For instance, the smallest tube when applied to the scale will reach to the first line, marked 1, and is intended to be used up to the age of twelve or fifteen months; the size marked 2 is suitable for the next year, 3 and 4 for these years, and so on. When the proper tube is selected for the case

to be operated on, a fine thread is passed through the small hole near its anterior angle, and left long enough to hang out of the mouth after the introduction of the tube, its object being to withdraw the tube should it be found to have passed into the œsophagus instead of the larynx.

“The obturator is then fastened tightly to the introducer, to prevent the possibility of its rotating while being inserted and passed into the tube.

“The following is the *method of introducing the tube*, which is done without the use of an anæsthetic: The child is held upright in the arms of a nurse, and the gag (Fig. 790, *a*) inserted in the left angle of the mouth, well back between the teeth, and opened widely; an assistant holds the head, thrown somewhat backward, while the operator inserts the index-finger of the left hand into the mouth to elevate the epiglottis and draw the base of the tongue forward, and at the same time direct the tube into the larynx.

“The handle of the introducer (Fig. 790, *b*) is held close to the patient's chest in the beginning of the operation, and rapidly elevated as the canula approaches the glottis. The tube is then pushed downward, without using much force. The tube is then detached. The joint in the shank of the obturator is for the purpose of facilitating this part of the operation. As soon as the obturator is removed, and it is ascertained that the tube is in the larynx, the thread is withdrawn, but at the same time the finger is kept in contact with the tube to prevent its being also withdrawn.

“It is important that the attempt at introduction be made quickly, as respiration is practically suspended from the time that the finger enters the larynx until the obturator is removed. It is, therefore, under the circumstances, much safer to make several abortive attempts than one prolonged effort, even if successful.

“For the purpose of removal, the patient is held in a similar position, except that the head is not inclined backward, or very slightly so, and the extractor (Fig. 790, *c*) passed into the tube guided by the index-finger of the left hand, which also fixes the epiglottis, and is brought in contact with the head of the canula. Firm pressure with the thumb is then made on the lever above the handle while the tube is being withdrawn. If secondary dyspnoea supervenes at any time, the tube should be removed and a larger one substituted. These tubes will also prove valuable as dilators in chronic stenosis of the larynx or trachea.”

It is recommended by Dr. O'Dwyer that preliminary practice in the introduction and removal of the tube be had upon the cadaver when this means of gaining experience is feasible. The removal of the tube is more difficult than the introduction, on account of the trouble of inserting the blades of the extractor into the open upper

end of the tube while more or less completely hidden from view by the natural position of the surrounding soft parts. This part of the operation becomes especially troublesome when the patient offers any opposition to the attempt, and it may become necessary under these circumstances to administer an anæsthetic before the tube can be safely removed.

Prognosis.—The rate of mortality in laryngeal obstruction when treated by this method is not as yet well established, although it appears thus far to compare favorably with that following either of the varieties of bronchotomy. This plan certainly offers especial advantages for the treatment of stenosis of the larynx from other causes, and for the relief of those cases of acute stenosis for which the friends of the patient refuse tracheotomy as a means of relief.

Foreign Bodies in the Bronchi.—It is advisable to endeavor to extract a foreign body located in either bronchus rather than to trust to nature to expel it. Its site should be carefully determined by auscultation—it is more frequently located on the left side—before the opening is made in the trachea. After this, if a flexible probe be passed through the opening in the lumen of the suspected bronchus, it may be easily detected. The foreign body may be grasped by forceps of a proper shape and size, or a wire with a hooked extremity may be passed beyond it, and withdrawn, thus displacing or removing the obstruction. A loop of surgical silver wire, as suggested by Dr. J. L. Little, can be pushed past it, turned somewhat and withdrawn with the best of results. In any instance no harm can be done by this simple agent. Half an hour is quite sufficient time to continue the manipulation.

Thyrotomy.—This operation consists in dividing the thyroid cartilage exactly in the median line, together with the crico-thyroid and thyro-hyoid membranes when additional room is desired. Morbid growths and foreign bodies in the larynx, below the false vocal cords, which threaten death from asphyxia and can not be removed through the mouth, demand its performance. It is wise to anticipate the danger that may arise from the passage of blood into the trachea, by preliminary tracheotomy, especially if the tumor be a large or a very vascular one.

Operation.—Place the patient as for tracheotomy; administer an anæsthetic; make an incision an inch and a half in length in the median line, extending from the hyoid bone downward; divide the fascia on a director; separate the sterno-hyoid muscles, and with a grooved director press aside the tissues beneath, and expose the angle of the thyroid cartilage. If the patient be a child, this will be somewhat difficult to discern, even after the exposure; still, the center of the notch at the upper and lower borders of the cartilage marks the extremities of the line of the incision to be made. The cartilage is

held firmly by a *tônaculum*, and the division made exactly in the median line, with a sharp-pointed knife, down to the mucous lining within. If it be divided at either side of the median line, the origin of the corresponding vocal cord will be cut. After all hemorrhage is checked, the mucous lining is divided and the lips of the cartilage wound separated by hooked retractors, and, if need be, the incision extended through the membranes above and below. The obstruction is then removed and the cartilage accurately apposed and united by fine catgut. The soft parts are then united and treated antiseptically. If the cartilage be not accurately joined, the functions of the vocal cords will be impaired, owing to their abnormal relations to each other. If the cartilaginous ridge be nicked transversely before its division, it can be accurately apposed thereafter by joining the cartilaginous borders on the line of the nicks.

Results.—Nearly eight and one half per cent die from the operation.

Sub-hyoid Laryngotomy, or Pharyngotomy.—This operation is admissible for the removal of foreign bodies and morbid growths situated high up in the air-passage, and for the relief of abscesses at the base of the epiglottis.

Operation.—Place the patient as for laryngotomy; administer an anæsthetic, and make an incision an inch and a half or two inches in length transversely along the lower border of the hyoid bone, with its center in the median line. The integument, fascia, platysma, and the inner portions of each sterno-hyoid muscle, and finally the thyro-hyoid, are divided on a director. The only vessel contiguous to the incision is the superior thyroid artery, which runs along the upper border of the thyroid cartilage, parallel with the incision. As soon as the thyro-hyoid membrane is cut, the epiglottis will project through the opening, and must be drawn aside, when the tumor will be exposed to view. After the removal of the growth, the wound is closed and dressed antiseptically. The majority of the conditions calling for this operation can be satisfactorily treated through the mouth.

Prognosis.—The operation itself implies no unusual danger to the patient.

Laryngectomy.—The removal of the entire larynx is not a difficult operation if the surrounding tissues be not involved by the disease.

Operation.—Make a vertical incision in the median line from the hyoid bone to the second ring of the trachea; free the sides of the larynx from its muscular attachments without opening into it; draw the trachea forward with a hook and separate it transversely from the larynx; a siphon-tube of vulcanite is then introduced, or the Trendelenburg tampon, to prevent the entrance of blood, and at the same time afford a proper channel for the use of the anæsthetic. If there be much oozing of blood, the head may be lowered to cause it to flow

from the trachea, when the posterior and upper connections of the larynx are severed. The œsophagus must be carefully located, or it may be cut. The tissues should be separated by the fingers when possible, aided by blunt-pointed scissors. The amount of hemorrhage is trifling and easily controlled; the branches of the superior and inferior thyroid vessels furnish the principal bleeding points, and these should be tied and divided between two ligatures before the growth is separated from its connections. The after-treatment consists in keeping the parts thoroughly cleansed, and regulating the temperature of the room, together with careful attention to the tracheal tube. It often happens that in addition to the larynx the hyoid bone, base of the tongue, pharynx, and œsophagus, are involved in a malignant growth. The first step under these circumstances is to introduce the tampon canula of Trendelenburg, or a substitute, through which the anæsthetic is administered. Make a transverse incision through the skin from the inner edge of one sterno-mastoid muscle to the other, passing half an inch above the hyoid bone; from this carry a second one vertically downward along the median line of the trachea to the incision made to open the trachea; turn the flaps outward; remove all large glands in the vicinity; divide the muscular attachments to the hyoid bone; tie the lingual and superior thyroid arteries; excise the tongue below the disease, along with the palato-pharyngeal arches if necessary, carefully avoiding the external carotid arteries, when it is possible; if not, draw them forward along with the pharynx and divide them between two ligatures; cut the lingual and hypoglossal nerves. The larynx is now separated from the trachea by cutting the latter just below the cricoid cartilage; a canula is introduced into it; the parts are thoroughly washed with a carbolized solution; the flaps placed in contact with the raw surfaces without sutures, and the wound sprinkled with iodoform. If the œsophagus be divided, its lower extremity must be kept open and so placed that it can be protected from the entrance of discharges, and become an available channel through which to nourish the patient.

Results.—The prognosis of complete extirpation is better than the partial. In speaking of the results, Prof. S. D. Gross says: "Of thirty-seven complete excisions, nineteen recovered and eighteen died, at periods varying from ten to sixteen days, the cause of death in twelve having been pneumonia. Of the entire number thirty were for carcinoma, of which sixteen perished from the effects of the operation; seven died of the recurrence of the disease in from four to nine months; one died from an accident, and six were still living." After the extirpation of the larynx, its place may be supplied by an artificial appliance which, although ingenious, serves as a poor substitute for the normal parts.

Cohen, of Philadelphia, in a paper on "Does Excision of the Lar-

ynx tend to the Prolongation of Life?" gives the results of sixty-five complete operations, over forty of which were done for carcinoma. Without entering into the details of the cases, it is sufficient to add that Dr. Cohen is of the opinion that tracheotomy and simpler means give a much better chance of prolonging life.

Removal of a Goitre (Watson).—When the patient is in danger of suffocation, it is admissible to attempt the removal of the growth, which is done in the following manner :

Operation.—The patient is placed in the dorsal position with the head situated so as to afford the best opportunity for breathing ; carefully administer an anæsthetic ; make a free incision in the median line from the upper part of the growth to the sternal notch ; divide all the tissues on a director in the line of the incision down to the capsule ; draw aside the muscles covering the growth if its size will permit ; if not, cut them transversely on a director ; secure all bleeding points as fast as seen ; separate the cervical fascia from the capsule of the tumor with the fingers, down to the thyroid arteries, which must be ligatured. All fibrous connections between the capsule and the fascia should be tied before they are cut. The capsule can now be opened and its attachments to the growth severed by the scissors. If the capsule be opened before the arteries are ligatured, the hemorrhage will be profuse and the ability to control it limited. After all hemorrhage has ceased, the wound is closed with catgut sutures, drained, and dressed antiseptically.

Results.—The chance for the life of the patient is flattering. Since the plan of operation just described has been practiced, less than seven per cent have perished from it. The operation has been performed about three hundred and forty-five times since 1877. Recently, when done with antiseptic precautions, a large proportion have proved successful. Total extirpation is no more fatal than incomplete. Kocher has pointed out the fact that, if the thyroid body be removed before adolescence, cachexia followed by idiocy of the patient are common sequels.

Arthroctomy.—The performance of this operation is limited substantially to the knee-joint, and consists in forming a flap by a semilunar incision, similar in its outline to the one employed in excision of the knee. The flap is reflected upward, and the capsule opened at each side of the patella and its ligament, or the patella may be sawn across and the fragments turned upward and downward. The remainder of the operation consists in the careful removal of all the diseased portions of bone, cartilage, synovial membrane, and ligament, with scissors, scoops, etc.

The most difficult part of the operation is the removal of the posterior portions of the semilunar cartilages and the synovial membrane at the posterior part of the joint. Much time and patience are neces-

sary to faithfully meet the indications of this operation. After all hemorrhage has ceased, the entire cavity, including the upper synovial pouch, must be thoroughly cleansed and drained, and an anti-septic dressing applied to the limb.

Prognosis.—The results thus far do not warrant the belief that this operation can be employed as a suitable substitute for excision, except, perhaps, in those cases where suppuration is slight, disease of the bone superficial and circumscribed, and when no constitutional vice is present.

Wiring the Patella.—The generally accepted opinion that this operation is a justifiable measure in selected cases, and under suitable conditions, requires that its *modus operandi* be given some attention.

Operation.—An incision is made transversely across the joint from one condyle to the other, passing between the fragments of the bone and freely exposing the joint-cavity. All blood-clots and bony asperities are removed from the broken borders of the fragments. The lacerated tissues about the joint are trimmed away and the blood-clots turned out. The fibrous tissues at the broken borders of the bone are trimmed off closely. Every form of blood and foreign substance must be removed from the joint-cavity, especial care being taken to cleanse the upper synovial pouch and the posterior aspect of the joint. Drainage should be made through the posterior wall at each condyloid depression, carefully avoiding the nerves and vessels in the popliteal space. The fragments are then drilled (Fig. 791), and one or more wire sutures introduced (Fig. 792). The joint-cavity is again thoroughly cleansed, all hemorrhage checked, and the fragments placed in contact with each other, the sutures tightened, their ends twisted together, cut short and turned inward from the surface (Fig. 793). The cut borders of the capsule of the joint are united independently by a continuous suture of fine catgut, after

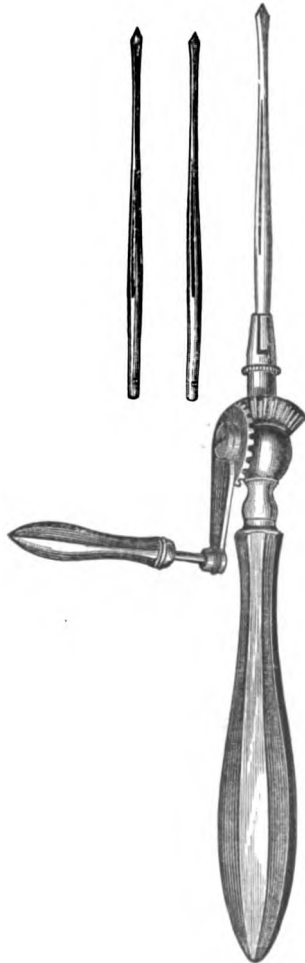


FIG. 791.—French bone-drill.

which the superficial tissues are joined by catgut of a larger size. Horse-hair drainage may be made at the sides between the tissues

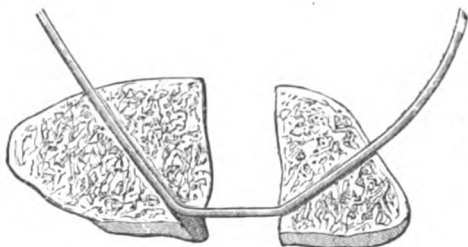


FIG. 792.—Wire introduced.

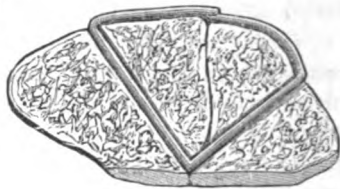


FIG. 793.—Fragments united.

joined by the two rows of sutures. The antiseptic douching should be continuous during the entire operation. The external dressings are applied, and the limb is immovably fixed in an extended position. After a week or ten days fresh dressings are applied, and the drainage agents removed; if suppuration has not occurred, one redressing may suffice. Yet it is better to again redress the limb after a week or so, when, if the wounds be healed, the limb can be confined in a plaster-of-Paris splint and the patient permitted to move around. The operation may be performed at any time during the first week or ten days after the injury. If the fracture be compound, it should be wired at once. In an old case, when the quadriceps extensor tissues have become contracted and atrophied, a V-shaped incision through its structure may be necessary in order to bring the freshened edges of the fragments in contact. The olecranon process, when fractured, may likewise be wired. The wire sutures need not be removed at all unless they cause trouble. Silk-worm gut is sometimes employed for this purpose, instead of the silver wire.

Results.—Prior to 1883 the patella had been wired forty-nine times, of which two of the patients died, one of pyæmia and one of exhaustion. Besides these, six cases resulted in suppuration and ankylosis. During the last two years upward of a hundred and forty cases have been reported, in a few of which suppuration has occurred, and in two or three death has followed. In my opinion, this measure should not be employed except for other reasons than that of the existence of a simple fracture of the bone, because I do not believe that it is good surgery to expose a patient to the contingencies of suppuration, amputation, ankylosis, and even death, for the better rectification of an injury, which at its worst has no tendency to terminate fatally, and almost invariably results in a serviceable limb when treated by the ordinary methods.

Movable Bodies in Joints.—Movable bodies in joints not infrequently become a source of so much annoyance that the comfort of

the patient, as well as the usefulness of the limb, demand their removal. Ordinarily these bodies appear at intervals at some point corresponding to the external line of the articulation, where they can be easily felt, and where they will remain until displaced into the articulation again by movements of the joint or by manual manipulation.


Operation.—An attempt to remove these bodies should not be made except under strict antiseptic precautions. The patient is given an anæsthetic, or, if the object be a small one, an injection of cocaine may be employed instead. After the movable body is fixed firmly in position by passing into it through the superficial tissues a sharp-pointed awl-like instrument, an incision is made directly down upon it, all bleeding checked, and the synovial lining of the joint is carefully opened sufficiently to permit the introduction of a strong pair of sharp-toothed forceps, by which the movable body is grasped and carefully drawn through the incision in the soft parts. If it be adherent to the deeper joint-structure, it may be either pulled or cut away. The wound is closed by two rows of sutures, one of fine catgut, that unites the borders of the synovial membrane and its subjacent tissue, the second completely unites the remaining tissues. A few strands of horse-hair or catgut introduced between the tissues united by the two rows of sutures are sufficient for suitable drainage. The limb is now dressed antiseptically and immovably fixed in the extended position. At the end of four or five days the dressing is removed, drainage agents withdrawn, and the limb redressed as in the first instance. If the drainage agents are composed of a material that can be absorbed, one dressing may suffice for the entire treatment of the case. If the foreign bodies be not accessible during their wanderings, it may become necessary to open the joint in front by a free incision to relieve the suffering of the patient. Flexion and extension of a joint often aid in the removal of these bodies.

Prognosis.—The danger to life or limb is trivial when the operation is performed antiseptically. Relief from the suffering is certain if all the offending agents be removed.

Ganglion is a name applied to a limited though abnormal collection of fluid found in connection with the sheaths of tendons, and situated most commonly at the back of the wrist, although found not infrequently at the anterior surface and in the palm. It is also dependent on the protrusion of the synovial lining of the carpal articular surfaces, through a rupture of the fibrous sheath by which they are connected with each other.

Two methods of treatment are commonly employed: 1. The simple or palliative method. 2. The radical or curative method.

The palliative method comprises simple measures, such as rest to the part, pressure, counter-irritation, tapping, etc. These measures are sometimes followed by permanent recovery.



INDEX.

- ABDOMINAL** aorta, ligature of, 60.
linear guide to, 60.
- Abdominal section**, 362.
explorative, 362.
- Abdominal tourniquet**, Brandis', 287.
Esmarch's, 287.
Lister's, 287.
Lloyd's, 289.
Pancoast's, 287.
- Abscess in the right iliac fossa**, 373.
perityphlitic, 373.
- Actual cautery**, 35.
- Acupressure**, 31.
pins, 32.
- Adams' operation for subcutaneous division of the neck of the femur**, 216.
- Adductor magnus, tenotomy of**, 158.
- Agents for controlling hemorrhage**, 23.
- Agnew's operation for radical cure of inguinal hernia**, 333.
- Air in the veins**, 55.
symptoms, 55.
treatment of, 55.
preventive treatment of, 55.
- Allis' ether-inhaler**, 8.
- Amputating knife, manner of grasping the**, 230.
knives, 230.
knives, the catlin, 231.
saw, proper method of using an, 233.
saws, 232.
- Amputation, agents required for**, 230.
circular method, 224.
circular method, modified, 226.
classification of flaps, 224.
comparative merits of different forms of flaps, 230.
double-flap method, 227.
equilateral flaps, 229.
hood flap, 229.
how to operate, 235.
Langenbeck's method, 228.
mixed double-flap method, 228.
oval method, 227.
periosteal flap, 229.
rectangular-flap method, 228.
single-flap method, 227.
Teale's method, 228.
the retractor in, 236.
- Amputation at the ankle-joint**, Pirogoff, 270.
Bruns' modification of Pirogoff's, 272.
Esmarch's modification of Le Fort's, 273.
Fergusson's modification of Pirogoff's, 271.
Le Fort's modification of Pirogoff's, 272.
Roux's, 269.
Syme's, 267.
modification of Syme's, 268.
- Amputation of the arm**, 248.
circular-flap method, 248.
large anterior and small posterior flaps, 250.
musculo-cutaneous flaps, Langenbeck, 249.
unequal double-flap method, 249.
- Amputation at the elbow-joint**, 247.
circular method, 247.
single-flap method, 248.
- Amputation of the forearm**, 246.
circular method, 246.
equilateral skin-flaps, 246.
musculo-cutaneous flaps, 247.
- Amputation at the hip-joint**, 287.
anterior oval method, Verneuil, 296.
circular method, Dieffenbach, 292.
lateral-flap method, 296.
long anterior and short posterior flap, Maenec, 290.
single-flap method, Maligne, 293.
- Amputation at the knee-joint**, 278.
bilateral method, 279.
circular method, 280.
long anterior, with a short posterior flap, 281.
through the condyles, 281.
through the condyles, Carden, 282.
through the condyles, Gritti, 283.
Stokes' modification of Gritti's, 283.
- Amputation of the leg, lower third**, 274.
lower third, bilateral method, 276.
lower third, circular, with periosteal reflection, 274.
lower third, hood or oval flap, 277.
middle third, 277.
middle third, unilateral-flap method, 278.
supra-malleolar, 274.
upper third, 278.
- Amputation, lower extremity**, 255.
through medio-tarsal joint, Chopart, 262.

- Amputation through medio-tarsal joint, Forbes' modification of Chopart's, 264.
of the last four metacarpal bones, 243.
through the metacarpal bones, 242.
- Amputation at the metacarpo-phalangeal articulation, 239.
through all the metatarsal bones, 258.
- Amputation, osteoplastic, of heel and ankle, Mikulicz, 273.
- Amputation of the penis, old plan, 462.
Hilton's modification, 462.
Humphrey's modification, 463.
- Amputation at phalangeal articulations of the hand, 237.
- Amputation above the shoulder-joint, 255.
- Amputation at the shoulder-joint, 250.
by circular incision, 252.
by internal and external flaps, Dupuytren, 250.
by oval method, Larrey, 252.
Spence's method, 253.
- Amputation, subastragaloid, De Lignerolles, 264.
subastragaloid, Hancock, 266.
subastragaloid, Tripier's method, 266.
- Amputation, tarsal, irregular, Molière, 266.
- Amputation at the tarso-metatarsal joint, Lisfranc, 260.
Bauden's modification of Lisfranc's, 262.
Hey's modification of Lisfranc's, 262.
Skey's modification of Lisfranc's, 262.
- Amputation of the thigh, 283.
antero-posterior musculo-integumentary flaps, 285.
bilateral method, 284.
circular integumentary flap, 285.
long anterior-flap method, Sédillot, 256.
single circular incision method, Celsus, 285.
- Amputation of the thumb, at the carpo-metacarpal articulation, lateral-flap method, 241.
at the carpo-metacarpal articulation, oval method, 240.
- Amputation of the toe, fifth, with its metatarsal bone, lateral-flap method, 259.
fifth, with its metatarsal bone, 259.
great, by large square internal flap, 257.
great, with its metatarsal bone, 259.
- Amputation of the toes, all, at the metatarso-phalangeal joint, 258.
of toes, in their continuity, 255.
of toes, two adjoining, 257.
of single toes, 256.
of single toes, by lateral flap, 256.
- Amputation of upper extremities, 236.
- Amputation at the wrist-joint, 244.
circular method, 244.
double-flap method, Ruysch, 244.
radial flap, Dubrueil, 245.
single palmar-flap method, 245.
- Amputations, 223.
- Amussat's operation of left lumbar colotomy, 368.
- Anæsthesia, how to prepare a patient for, 12.
- Anæsthesia, local, 16.
- Anæsthetic, purity of, 11.
- Anæsthetics, 5.
inhalers for, 7.
- Anchylolysis, 297.
bony, of knee-joint, supra-condyloid, osteotomy for, 217.
of inferior maxilla, 178.
of inferior maxilla, removal of a wedge-shaped piece, Esmarch, 179.
- Aneurism-needle, 59.
Fletcher's, 60.
Mott's, 59.
students', 60.
Syme's, 59.
- Anger's operation for hypospadias, 464.
- Ankle and heel, osteoplastic amputation at, Mikulicz, 273.
- Ankle-joint, amputation at, Bruns, 272.
Fergusson's modification of Pirogoff's, 271.
Le Fort's modification of Pirogoff's, 272.
Le Fort's modification of Esmarch's, 273.
Pirogoff's, 270.
Roux's, 269.
Syme's, 267.
Syme's, modification of, 268.
- Ankle-joint, excision of, 199.
excision of, subperiosteal, Langenbeck, 199.
disarticulation at the, 267.
- Annandale's operation for webbed fingers, 301.
- Antiseptic fluid, Thiersch's, 51.
protective, 48.
receptacle for instruments, 21.
solutions, 22.
spray apparatus, 48.
- Antrum, perforation of the, 484.
- Anus, absence of, 408.
artificial, 373.
examination of, 401.
imperforate, 402.
- Aorta, abdominal, ligature of, 60.
- Aorta, abdominal, linear guide to, 60.
- Apparatus, antiseptic spray, 48.
douching, 49.
for enterectomy, Treves', 365.
- Arch, palmar, superficial, ligature of, 106.
- Arch, palmar, superficial, linear guide to, 106.
- Arm, amputation of the, 248.
by large anterior and small posterior flaps, 250.
by musculo-cutaneous flaps, Langenbeck, 249.
circular-flap method, 248.
unequal double-flap method, 249.
- Arteries, ligature of, 56.
general considerations, 56.
guides to, 56.
iliac, 62.
instruments required for, 59.
operations on special, 60.
- Artery, abdominal aorta, ligature of, 60.

- Artery, abdominal aorta, linear guide to, 60.**
axillary, first portion, ligature of, 95.
axillary, first portion, linear guide to, 95.
axillary, ligature of, 95.
axillary, third portion, ligature of, 97.
axillary, third portion, linear guide to, 97.
brachial, ligature of, 98.
brachial, linear guide to, 99.
Artery, carotid, common, ligature of, 106.
common, linear guide to, 107.
common, ligature of both, 110.
external, ligature of, 110.
external, linear guide to, 110.
internal, ligature of, 111.
Artery, dorsalis pedis, ligature of, 82.
dorsalis pedis, linear guide to, 82.
dorsalis penis, ligature of, 69.
epigastric, ligature of, 71.
epigastric, linear guide to, 71.
facial, ligature of, 115.
femoral, deep, ligature of, 77.
femoral, ligature of, 72.
femoral, linear guide to, 72.
gluteal, ligature of, 66.
gluteal, linear guide to, 66.
Artery, iliac, circumflex, deep, ligature of, 71.
iliac, common, ligature of, 62.
iliac, external, ligature of, 69.
iliac, internal, ligature of, 65.
Artery, innominate, ligature of, 86.
lingual, ligature of, 113.
lingual, linear guide to, 113.
mammary, internal, ligature of, 94.
mammary, internal, linear guide to, 95.
occipital, ligature of, 116.
peroneal, ligature of, 85.
peroneal, linear guide to, 85.
popliteal, ligature of, 77.
popliteal, linear guide to, 77.
profunda femoris, ligature of, 77.
pudic, internal, ligature of, 68.
pudic, internal, linear guide to, 68.
radial, ligature of, 101.
radial, linear guide to, 101.
sciatic, ligature of, 67.
sciatic, linear guide to, 67.
subclavian, ligature of first portion, left side, 87.
subclavian, ligature of first portion, right side, 89.
subclavian, ligature of second portion, 92.
subclavian, ligature of third portion, 90.
subclavian, second portion, linear guide to, 89.
subclavian, third portion, linear guide to, 89.
temporal, ligature of, 116.
thyroid, inferior, ligature of, 95.
thyroid, inferior, linear guide to, 95.
thyroid, superior, ligature of, 113.
tibial, anterior, ligature of, 79.
tibial, anterior, linear guide to, 79.
tibial, posterior, ligature of, 82.
tibial, posterior, linear guide to, 83.
tibial, posterior, linear guide to, 104.
Artery, ulnar, linear guide to, 104.
vertebral, ligature of, 92.
vertebral, linear guide to, 93.
Arthrectomy, 508.
Artificial anus, 373.
Artificial hemostatics, 24.
Artificial respiration, 14, 54.
Aspiration of the bladder, 421.
Assistants at operations, 40.
Astragaloid osteotomy, Stokes', 303.
Astragalus, excision of, 199.
Auricularis magnus nerve, operations on, 146.
Axillary artery, first portion, ligature of, 95.
Axillary artery, first portion, linear guide to, 95.
Axillary artery, ligature of, 95.
Axillary artery, third portion, ligature of, 97.
Axillary artery, third portion, linear guide to, 97.
Axillary glands, extirpation of the, 481.
Bandages, 24.
clastic, 24, 54.
Battery, electric, 53.
Bauden's amputation at tarso-metatarsal joint, 262.
Bichloride-of-mercury dressing, 51.
Bilateral lithotomy, 450.
Nélaton's modification of, 451.
Billroth's operation for excision of the tongue, 342.
Birth-mark, 132.
Bladder, aspiration of the, 421.
digital exploration of the, 422.
extroversion of the, 423.
extroversion of the, F. F. Maury's operation, 423.
extroversion of the, Pancoast's operation, 424.
extroversion of the, Wood's operation, 424.
stone in the, 427.
operations on the, 416.
puncturing the, 425.
puncturing the, through the rectum, 426.
puncturing the, under the pubes, 426.
rupture of the, 421.
Bloodless stretching of sciatic nerve, great, 148.
Bone-forceps, 136, 163.
Bones, operations on, 162.
excision, 165.
gouging, 162.
osteotomy, 212.
sequestrotomy, 163.
sequestrotomy, direct method, 164.
sequestrotomy, indirect method, 165.
wiring of, in compound fractures, 512.
Bourgary's excision of bones of forearm, lower extremities of, 192.
Bow-legs, 221.
Brachial artery, ligature of, 98.

- Brachial artery, linear guide to, 99.
 Brachial plexus, operations on, 146.
 Brandis' tourniquet, abdominal, 287.
 Breast, extirpation of the, 480.
 Brisement forcé, 297.
 Bronchi, foreign bodies in the, 505.
 Bronchotomy, 492.
 Bruns' amputation at ankle-joint, 272.
 Buchanan's medio-lateral operation of lithotomy, 451.
 Buck's operation of cheiloplasty, for lower lip, 322.
 interno-lateral flap method of cheiloplasty of upper lip, 325.
 semicircular flap method of cheiloplasty of upper lip, 325.
 Bull's (W. T.) transfusion of saline solutions, 130.
 Bunion, 302.
- Calcaneum, excision of, 198.
 Canalization, Neuber, 47.
 Cancer of the rectum, 412.
 Capillaries, operations on, 131.
 division and ligaturing, 134.
 subcutaneous ligaturing, 132.
 Carden's amputation at the knee-joint, 282.
 Carotid artery, common, ligature of, 106.
 common, linear guide to, 107.
 external, ligature of, 110.
 external, linear guide to, 110.
 internal, ligature of, 111.
 Carotid arteries, common, ligature of both, 110.
 Carpo-metacarpal articulation, amputation of the thumb at, by lateral-flap method, 241.
 by oval method, 240.
 Castration, 458.
 Catgut ligatures, 39.
 how prepared, 40.
 Catheter, introduction of a, into the bladder, 417.
 Catheterization, 417.
 Cautery, actual, 35.
 galvano-, 37.
 thermo-, 36.
 Celsus' circular amputation of thigh, 285.
 method of cheiloplasty for lower lip, 321.
 Cheever's operation for removal of nasopharyngeal polypi, 459.
 Chiene's osteo-arthrotomy, 220.
 Cheiloplasty, 320.
 Buck's method of, for lower lip, 322.
 Buck's interno-lateral flap method of, for upper lip, 325.
 Buck's semicircular flap method of, for upper lip, 325.
 Celsus' method of, for lower lip, 321.
 deformity of lower lip, V-shaped incision, 320.
 Dieffenbach's operation of, for upper lip, 326.
 horizontal incision for lower lip, 321.
 Cheiloplasty, Malgaigne's operation of, for lower lip, 324.
 Sedillot's operation of, for lower lip, 324.
 Sedillot's vertical-flap method of, for upper lip, 326.
 Syme's operation of, for lower lip, 322.
 Chloroform, 6.
 inhaler, Esrarch's, 6.
 poisoning by, or overdose of, treatment for, 14.
 Cholecystectomy, 361.
 Cholecystotomy, 360.
 Chopart's amputation through medio-tarsal joint, 262.
 Circumclusion, 32.
 Circumcision, 458.
 Cirroid growths, 134.
 Clavicle, excision of, 180.
 Clean towels and old linen, 22.
 Clover's ether inhaler, 9.
 Cocaine, 17.
 Cock's operation of tapping the urethra, 478.
 Colotomy, left inguinal, linear guide to, 372.
 left inguinal, Littré, 372.
 left lumbar, Amussat, 368.
 left lumbar, linear guide to, 368.
 right lumbar, 372.
 Compresses, 26.
 Compress, graduated, 26.
 Cone, ether, simplest form of, 7.
 Continuous suture, 44, 349.
 Contraction of palmar fascia, 160.
 Cotton-batting dressing, 49.
 Cripp's operation of excision of the rectum, 413.
 Crural nerve, anterior, operations on, 149.
 Curvature of the spine, 298.
 Czerny's operation for radical cure of inguinal hernia, 387.
 Czerny-Lambert intestinal suture, 351.
- Davy's lever, 29, 288.
 Decalcified drainage-tubes of Neuber, 47.
 Deep circumflex iliac artery, ligature of, 71.
 Deformities, 297.
 of upper lip, 325.
 Deformity of lower lip, V-shaped incision, 320.
 De Lignerolle's amputation, subastragaloid, 264.
 Delpesch's operation of urethroplasty, 470.
 De Morgan's incision for spinal accessory nerve, 146.
 Dental nerve, inferior, operations on, 144.
 Deviation of the septum nasi, 491.
 Dieffenbach's amputation at the hip-joint, 292.
 operation of cheiloplasty for the upper lip, 326.
 operation of rhinoplasty, 310.
 operation of urethroplasty, 470.
 Digital pressure, 27.
 Disarticulation at the ankle-joint, 267.

- Disarticulation, at the elbow-joint, 247.
 at the hip-joint, 287.
 at the knee-joint, 278.
 at medio-tarsal joint, 264.
 at the metacarpo-phalangeal articulation, 239.
 at the metatarso-phalangeal joint, 258.
 at the phalangeal articulations of the foot, 256.
 at the phalangeal articulations of the hand, 237.
 at the shoulder-joint, 250.
 at the tarso-metatarsal joints, 260.
 at the wrist-joint, 244.
 of the fingers, 237.
 of the last four metacarpal bones, 243.
 of the toes, 256.
 sub-astragaloid, 264.
- Dorsalis-pedis artery, ligature of, 69.
 linear guide to, 82.
- Dorsalis-penis artery, ligature of, 82.
- Douching apparatus, 49.
- Dowell's operation for radical cure of inguinal hernia, 388.
- Dubrueil's amputation at the wrist-joint, 245.
- Duodenostomy, 356.
- Duplay's operation for hypospadias, 465.
- Dupuytren's amputation at shoulder-joint, 250.
 contraction, 160.
 contraction, operation for, 160.
- Drainage of wounds, 46.
- Drainage, spiral, Ellis', 46.
- Drainage-tube, decalcified, of Neuber, 47.
 rubber, 46.
- Dressing, open, 53.
- Dressings, bichloride of mercury, 51.
 combined, 49.
 cotton batting, 49.
 iodoform, 49.
 peat, 50.
 protective, 48.
- Elastic bandages, 24, 54.
- Elbow-joint, amputation at, 247.
 amputation at, circular method, 247.
 amputation at, single-flap method, 243.
 disarticulation at the, 247.
 excision of, Hüter, 189.
- Electric battery, 53.
- Ellis' drainage spiral, 46.
- Elongated uvula, 335.
- Emergencies, special, 54.
- Empty vessels, 21.
- Engine, surgical, 169.
- Enterectomy, 364.
 Treves' apparatus for, 365.
- Enterotomy, 363.
 right inguinal, Nélaton's operation of, 363.
- Epigastric artery, ligature of, 71.
 linear guide to, 71.
- Epispadias, 467.
 Nélaton's operation for, 467.
 Thiersch's operation for, 468.
- Erector spinæ, tenotomy of, 159.
- Esmarch's chloroform inhaler, 6.
- Esmarch's modification of Le Fort's amputation at ankle-joint, 273.
- Esmarch's operation for anchylosis of inferior maxilla, 179.
- Esmarch's tourniquet, abdominal, 287.
- Ether, 5.
 amount required to produce anæsthesia, 10.
 cone or inhaler, simplest form, 7.
 dangers from use of, 11.
 method of administering, 13.
 treatment for poisoning by, or overdose of, 14.
- Ether inhaler, Allis', 8.
 Clover's, 9.
 Lente's modified, 9.
 Noyes', 10.
 simplest form of conc, 7.
 Squibbs', 10.
- Etherization, intestinal, 15.
- Excision of the ankle-joint, 199.
 of ankle-joint, subperiosteal, Langenbeck, 199.
- Excision of the astragalus, 199.
- Excision of bones of forearm, lower extremities of, Bourgary, 192.
- Excision of the bones of the leg, 202.
- Excision of the calcaneum, 198.
- Excision of clavicle, 180.
- Excision of elbow-joint, Hüter, 189.
 of the elbow-joint, Liston, 190.
 of elbow-joint, subperiosteal, Langenbeck, 190.
- Excision of the fibula, 202.
- Excision of great trochanter of femur, 207.
- Excision of hip-joint, 208.
 subperiosteal, Langenbeck, 209.
 Sayre, 211.
 White, 208.
- Excision of humerus, 185.
 head of, subperiosteal, Langenbeck, 186.
 lower extremity of, 188.
 shaft of, 187.
 upper end of, Langenbeck, 185.
- Excision of the knee-joint, 202.
 by transverse incision, 207.
 non-subperiosteal, Mackenzie, 204.
 subperiosteal, Langenbeck, 205.
 subperiosteal, Ollier, 206.
- Excision of joints of lower extremities, 197.
- Excision of maxillæ, both, 174.
- Excision of maxilla, inferior, 175.
 alveolar process, 178.
 central portion, 176.
 half of, 177.
 lateral portion of body, 176.
 whole of, 178.
- Excision of maxilla, superior, 170.
 below floor of orbit, 173.
 by median incision, with removal of the whole bone, 172.
 subperiosteal, 173.
- Excision of metacarpo-phalangeal joints, 197.
- Excision of nerves, 141.

- Excision of the patella, 207.
 Excision of phalangeal joints of hand, 197.
 Excision of the radius, 192.
 Excision of the rectum, 412.
 Cripp's operation, 413.
 Maisonneuve's operation, 414.
 Volkmann's operations, 413.
 Excision of rib, portion of, 180.
 Excision of scapula, 182.
 body of, 183.
 for malignant growths, 184.
 glenoid angle of, 187.
 subperiosteal, Ollier, 184.
 Excision of scrotum, 122.
 Excision of the sternum, 179.
 Excision of the tibia, 202.
 Excision of the tongue, 339.
 Billroth's operation, 342.
 Heart's operation, 342.
 Knox's operation, 342.
 Kocher's operation, 343.
 Regnoli's operation, 342.
 Sédillot's operation, 342.
 Excision of the tonsils, 337.
 Excision of the ulna, 192.
 Excision of wrist-joint, 193.
 of the wrist-joint, complete, Langenbeck, 194.
 Exploration, digital, of the bladder, 422.
 Extensor communis digitorum, tenotomy of, 153.
 longus digitorum, tenotomy of, 156.
 ossis metacarpi pollicis, tenotomy of, 153.
 primi internodii pollicis, tenotomy of, 153.
 proprius pollicis, tenotomy of, 156.
 secundi internodii pollicis, tenotomy of, 153.
 quadriceps cruris, tenotomy of, 157.
 Extirpation of the axillary glands, 480.
 of the breast, 480.
 of the parotid gland, 481.
 of the penis, Gouley, 463.
 Extroversion of the bladder, F. F. Maury's operation, 423.
 Pancoast's operation, 424.
 Wood's operation, 424.
 Extremities, lower, excision of joints of, 197.
 Facial artery, ligature of, 116.
 Facial nerve, operations on, 145.
 Fasciotomy, 151.
 Fascia, palmar, 159.
 Dupuytren's contraction of, 160.
 Dupuytren's operation for contraction of, 160.
 Fascia, plantar, 159.
 Fecal fistula, 373.
 Femoral artery, ligature of, 72.
 linear guide to, 72.
 deep, ligature of, 77.
 Femur, great trochanter of, excision of, 207.
 neck of, subcutaneous division of, Adams, 216.
 Ferguson's amputation at the ankle-joint, 271.
 Ferguson's operation of uranoplasty, 334.
 Fibula, excision of the, 202.
 Fingers, disarticulation of the, 237.
 Fingers, webbed, 300.
 Annandale's operation, 301.
 Nélaton's operation, 301.
 Fistula in ano, 404.
 incision with closure, 407.
 operation by direct incision, 406.
 treatment by ligaturing, 407.
 Fistula, fecal, 373.
 Fistula, salivary, 335.
 Horner's operation, 336.
 operation by a seton, 336.
 Flat foot, Ogsten's operation, 302.
 Fletcher's aneurism needle, 60.
 Flexor, biceps cruris, tenotomy of, 157.
 biceps cubiti, tenotomy of, 154.
 carpi radialis, tenotomy of, 153.
 carpi ulnaris, tenotomy of, 154.
 longus digitorum, tenotomy of, 154.
 longus pollicis, tenotomy of, 155.
 profundus digitorum, tenotomy of, 153.
 sublimis digitorum, tenotomy of, 153.
 Fluid, antiseptic, Thiersch's, 51.
 Foot, flat, Ogsten's operation, 302.
 Forceps, artery, 33.
 bone, 136, 163.
 bone-holding, 167, 235.
 needle, 42, 332.
 throat, 348.
 thumb, 18.
 wire-twisting, 329.
 Fore-arm, amputation of, 246.
 circular method, 246.
 equilateral skin-flaps, 246.
 musculo-cutaneous flaps, 247.
 Foreign bodies in the bronchi, 505.
 Forbes' amputation through the medio-tarsal joint, 264.
 Fractures, compound, wiring of bones in, 512.
 French operation of rhinoplasty, 307.
 Gall-bladder, operations on the, 360.
 Galvano-cautery, 37.
 Ganglion, 511.
 Gastro-enterostomy, 355.
 Gastrostomy, 353.
 Gauze, iodoform, 50.
 Gely's intestinal suture, 350.
 General considerations of operative surgery, 1.
 nursing, 3.
 place for operation, 3.
 season of year, 2.
 temperature of room, 3.
 time of day, 3.
 Genu valgum, 218.
 ostectomy for, 218.
 Genu varum, osteotomy for, 220.
 Giralde's operation for hare-lip, 318.
 Gland, parotid, extirpation of the, 482.
 Glands, axillary, extirpation of the, 480.
 Glover's suture, 44.

- Gluteal artery, ligature of, 66.**
Goitre, removal of a, Watson, 508.
Gouley's operation for extirpation of the penis, 463.
Gouley's operation for hypospadias, 464.
Gracilis, tenotomy of, 157.
Graduated compress, 26.
Grafting, skin, 307.
Gritti's amputation at the knee-joint, 283.
Grooved director, 18.
Guide, linear, to abdominal aorta, 60.
 to axillary artery, first portion, 95.
 to axillary artery, third portion, 97.
 to brachial artery, 99.
 to carotid artery, common, 107.
 to carotid artery, external, 110.
 to dorsalis pedis artery, 82.
 to epigastric artery, 71.
 to femoral artery, 72.
 to gluteal artery, 66.
 to iliac arteries, common, 62.
 to iliac artery, external, 69.
 to left inguinal colotomy, 372.
 to left lumbar colotomy, 368.
 to lingual artery, 113.
 to mammary artery, internal, 95.
 to palmar arch, superficial, 106.
 to peroneal artery, 85.
 to popliteal artery, 77.
 to pudic, internal, artery, 68.
 to radial artery, 101.
 to sciatic artery, 67.
 to subclavian artery, second portion, 89.
 to subclavian artery, third portion, 89.
 to thyroid artery, inferior, 95.
 to tibial artery, anterior, 79.
 to tibial artery, posterior, 83.
 to ulnar artery, 104.
 to vertebral artery, 93.
Guides, whalebone, introduction of, 420.
Gussenbauer's intestinal suture, 351.

Hallux valgus, 222.
Hancock's subastragaloid disarticulation, 266.
Hare-lip, 315.
 complicated, 319.
 double (simple), 319.
 simple, 317.
 simple double-flap operation, 318.
 Giraldes' operation, 318.
 simple single-flap operation, 317.
 sutures, 45.
Heart's operation for excision of the tongue, 342.
Heaton's operation for radical cure of inguinal hernia, 381.
Hemorrhage, agents for controlling, 23.
Hemorrhoids, 119.
Hemorrhoids, internal, operations for, 119.
 crushing, 120.
 excision, 119.
 injection, 121.
 ligaturing, 120.
 ligaturing with incision, 120.

Hemostatics, artificial, 24.
Hernia, 380.
 femoral, radical cure for, Wood's operation, 388.
 femoral, strangulated, 397.
Hernia, inguinal, radical cure for, Agnew's operation, 383.
 Czerny's operation, 387.
 Dowell's operation, 388.
 Heaton's operation, 381.
 Wood's operation, 384.
 Wood's operation with pins, 386.
 Wutzer's operation, 382.
 Hernia, inguinal, strangulated, 395.
 Hernia, obturator, strangulated, 401.
 Hernia, strangulated, 390.
 Hernia, umbilical, 389.
 Hernia, umbilical, strangulated, 400.
Hey's amputation at tarso-metatarsal joint, 262.
Hilton's amputation of the penis, 462.
Hip-joint, amputation at, 287.
 anterior oval method, Verneuil, 296.
 circular method, Dieffenbach, 292.
 lateral-flap method, 296.
 long anterior and short posterior flap, Maenec, 290.
 single-flap method, Malgaigne, 293.
Hip-joint, excision of, 208.
 Sayre, 211.
 subperiosteal, Langenbeck, 209.
 White, 208.
Hip-joint, disarticulation at the, 287.
Holder, needle, 42.
Horner's operation for salivary fistula, 386.
Horse-hair sutures, 43.
Humerus, excision of, 185.
 of lower extremity of, 188.
 of shaft of, 187.
 subperiosteal of head of, Langenbeck, 185.
 of upper end of, Langenbeck, 186.
Humphrey's amputation of the penis, 463.
Hüter's excision of elbow-joint, 189.
Hydrocele, 455.
 incision of sac of, 456.
 incision with excision of part of sac, 456.
 injection of sac, 457.
 injection of sac, accidents after, 457.
 tapping of sac of, 455.
Hydrocephalus, 134.
Hydro-rachis, 135.
Hypertrophy of the tongue, 340.
Hypospadias, 463.
 Anger's operation, 464.
 Duplay's operation, 465.
 Gouley's operation, 464.
 Szymanowski's operation, 466.

Iliac artery, circumflex, deep, ligature of, 71.
Iliac arteries, common, ligature of, 62.
 linear guide to, 62.
Iliac artery, external, ligature of, 69.
 linear guide to, 69.
Iliac artery, internal, ligature of, 65.
 linear guide to, 66.

- Imperforate anus, 402.
 Imperforate rectum, 414.
 Incisions, 20.
 Indian method of rhinoplasty, 311.
 Infra-orbital nerve, operations on, 142.
 Ingrowing toe-nail, 302.
 Inhaler, chloroform, Esmarch's, 6.
 Inhaler, ether, Allis', 8.
 Clover's, 9.
 Lente's modified, 9.
 Noyes', 10.
 simplest form of cone, 7.
 Squibb's, 10.
 Inhalers for anæsthetics, 7.
 Innominate artery, ligature of, 86.
 Inorganic or metallic sutures, 43.
 Instrumental pressure for controlling hemorrhage, 28.
 Instruments necessary for the performance of an operation, 18.
 Instruments, receptacle for, 21.
 Instruments should be plain, 21.
 Internal œsophagotomy for stricture, 346.
 Interrupted suture, 44.
 Intestinal etherization, 15.
 Intestinal suture, Czerny-Lambert, 351.
 Gely's, 350.
 Gussenbauer's, 351.
 Jobert's, 350.
 Lembert's, 350.
 Intubation of the larynx, O'Dwyer, 508.
 Iodoform dressing, 49.
 Iodoform gauze, 50.
 Italian method of rhinoplasty, 312.
- Jaw, lower, ankylosis of, 178.**
 Esmarch's operation for, 179.
Jaw, lower, excision of, 175.
 of alveolar process of, 178.
 of central portion of, 176.
 of half of, 177.
 of lateral portion of body of, 176.
 of whole of, 178.
Jaws, upper, excision of both, 174.
Jaw, upper, excision of, 170.
 below floor of orbit, 173.
 by median incision, with removal of whole bone, 172.
 subperiosteal, 173.
Jejunostomy, 356.
 Jobert's intestinal suture, 350.
Joint, ankle, amputation at, Esmarch's modification of Le Fort's, 273.
 Pirogoff, 270.
 Pirogoff's, Bruns' modification of, 272.
 Pirogoff's, Fergusson's modification of, 271.
 Pirogoff's, Le Fort's modification of, 272.
Joint, ankle, amputation at, removal of entire foot, Syme, 267.
 removal of entire foot, modification of Syme's, 268.
 removal of entire foot, Roux's modification of Syme's, 269.
Joint, ankle, disarticulation at the, 267.
Joint, ankle, excision of, 199.
Joint, ankle, subperiosteal, Langenbeck, 199.
Joint, carpo-metacarpal, amputation at, 240.
Joint, elbow, amputation at, 247.
 circular, 247.
 single flap, 248.
Joint, elbow, disarticulation at the, 247.
Joint, elbow, excision of, Hüter, 189.
 Liston, 190.
 subperiosteal, Langenbeck, 190.
Joint, hip, amputation at, 287.
 anterior oval method, Verneuil, 296.
 circular method, Dieffenbach, 292.
 lateral-flap method, 296.
 long anterior and short posterior flap, Maenec, 290.
 single-flap method, Malgaigne, 293.
Joint, hip, disarticulation at the, 287.
Joint hip, excision of, 208.,
 Sayre, 211.
 subperiosteal, Langenbeck, 209.
 White, 208.
Joint, knee, amputation at, 278.
 bilateral method, 279.
 circular method, 280.
 long anterior, with a short posterior flap, 281.
 through the condyles, Carden, 282.
 through the condyles, Gritti, 283.
 through the condyles, Stokes' modification of Gritti's, 283.
Joint, knee, disarticulation at the, 278.
Joint, knee, excision of, 202.
 by transverse incision, 207.
 non-subperiosteal, Mackenzie, 204.
 subperiosteal, Langenbeck, 205.
 subperiosteal, Ollier, 206.
Joint, knee, osteotomy for bony ankylosis of, 217.
Joint, medio-tarsal, amputation through, Chopart, 262.
 Forbes' modification of Chopart's, 264.
Joint, metacarpo-phalangeal, amputation at, 239.
 disarticulation at, 239.
 excision of, 197.
Joint, metatarsö-phalangen, amputation of all the toes at, 258.
 disarticulation at the, 258.
Joint, shoulder, amputation above the, 255.
Joint, shoulder, amputation at the, 250.
 by circular incision, 252.
 by internal and external flaps, Dupuytren, 250.
 oval method, Larrey, 252.
 Spence's method, 253.
Joint, shoulder, disarticulation at the, 250.
Joint, subastragaloid, amputation at, De Lignerolle's, 264.
 subastragaloid, Hancock's, 266.
 subastragaloid, Tripiet's, 266.
Joint, tarso-metatarsal, amputation, Lisfranc, 260.
 Bauden's modification of, 262.
 Hey's modification of, 262.
 Skey's modification of, 262.

- Maxilla, superior, excision of, subperiosteal, 173.
 Maxillary nerve, superior, operations on, 142.
 Maury's (F. F.) operation for extroversion of the bladder, 423.
 Mechanical apparatus for loss of nasal septum, 310.
 Mechanical means employed in uranoplasty, 334.
 Median lithotomy, 447.
 Median nerve, operations on, 147.
 Medio-bilateral lithotomy, 452.
 Medio-lateral lithotomy, Buchanan, 451.
 Medio-tarsal joint, amputation at, Chopart, 262.
 Forbes' modification of Chopart's, 264.
 Meningocele, 135.
 Metacarpal bones, amputation of last four, 243.
 amputation through the, 242.
 disarticulation of the last four, 243.
 Metacarpo-phalangeal articulation, amputations at, 239.
 disarticulation at, 239.
 joints, excision of, 197.
 Metatarsal bones, amputation through all the, 258.
 Metatarso-phalangeal joint, disarticulation at the, 238.
 Metallic sutures, 43.
 Mikulicz's osteoplastic amputation at the ankle-joint, 273.
 Molière's amputation at ankle, 266.
 Mother's mark, 132.
 Mott's aneurism needle, 59.
 Movable bodies in joints, 510.
 Multifidus spinæ, tenotomy of, 158.
 Musculo-cutaneous nerve, operations on, 147.
 Musculo-spiral nerve, operations on, 147.
 Nævus, 132.
 operations for, 132.
 Nail, toe, ingrowing, 302.
 Nares, posterior, plugging the, 484.
 Nasal polypi, removal of, 485.
 Langenbeck's operation, 487.
 Nélaton's operation, 488.
 Nasal septum, mechanical apparatus for loss of, 310.
 Naso-pharyngeal polypi, removal of, Cheever's operation, 489.
 Langenbeck's operation, 488.
 Needle, aneurism, 59.
 Fletcher's, 60.
 Mott's, 59.
 "students'," 60.
 Syme's, 59.
 Needle forceps or holders, 42.
 Nélaton's modification of the bilateral operation of lithotomy, 452.
 Nélaton's operation of excision of the right inguinal, 353.
 for epispadias, 467.
 Nélaton's operation for removal of nasal polypi, 488.
 of urethroplasty, 470.
 for webbed fingers, 301.
 Nephrectomy, 374.
 abdominal, 375.
 lumbar, 375.
 Nephro-lithotomy, 376.
 Nephrorrhaphy, 376.
 Nerve, auricularis magnus, operations on, 146.
 crural, anterior, operations on, 149.
 dental, inferior, operations on, 144.
 facial, operations on, 146.
 infra-orbital, operations on, 142.
 lingual, operations on, 145.
 maxillary, superior, operations on, 142.
 median, operations on, 146.
 musculo-cutaneous, operations on, 147.
 musculo-spiral, operations on, 146.
 occipital, great, operations on, 145.
 perineal, operations on, 149.
 plantar, operations on, 149.
 popliteal, external, operations on, 148.
 popliteal, internal, operations on, 148.
 radial, operations on, 147.
 saphenous, external or short, operations on, 150.
 saphenous, internal or long, operations on, 150.
 sciatic, great, operations on, 147.
 sciatic, small, operations on, 148.
 spinal accessory, operations on, 146.
 supra-orbital, operations on, 141.
 tibial, anterior, operations on, 148.
 tibial, posterior, operations on, 148.
 ulnar, operations on, 147.
 Nerves, branches of brachial plexus of, operations on, 146.
 Nerves, excision of, 141.
 Nerves of the cranium, operations on, 141.
 Nerves, spinal, operations on, 145.
 Nerves, stretching of, 141.
 Nerves, suturing of, 150.
 Nerves, transplantation of, 151.
 Neuber's canalization, 47.
 Neuber's decalcified drainage-tubes, 47.
 Nitrous oxide, 7.
 Non-subperiosteal excision of knee-joint, Mackenzie, 204.
 Noyes' ether inhaler, 10.
 Occipital artery, ligature of, 116.
 Occipital nerve, great, operations on, 145.
 O'Dwyer's intubation of the larynx, 508.
 Oesophagectomy, 346.
 Oesophagostomy, 347.
 Oesophagotomy, 344.
 internal, for stricture, 346.
 Oesophagus, removal of foreign bodies from, 347.
 stricture of the, 345.
 stricture of the, retrograde division for, Loretta, 346.
 Ogsten's osteo-arthrotomy, 220.

- Ogsten's operation for flat-foot, 302.
 Ollier's operation for osteoplastic rhinoplasty, 313.
 Ollier's subperiosteal excision of knee-joint, 206.
 Ollier's subperiosteal excision of scapula, 184.
 Open dressing for wounds, 53.
 Operating table, 21.
 Operation, antiseptic, preparation for, 52.
 Operations, assistants at, 40.
 nursing after, 3.
 place for, 3.
 preparatory treatment for, 4.
 requirements, essential, 4.
 requirements, necessary, 4.
 requirements, precautionary, 53.
 season of year for, 2.
 surroundings of patient after, 3.
 temperature of room after, 3.
 time of day for, 3.
 Operations on bones, 162.
 excision, 165.
 gouging, 162.
 osteotomy, 212.
 sequestrotomy, 163.
 sequestrotomy, direct method, 164.
 sequestrotomy, indirect method, 165.
 Operations on the gall-bladder, 360.
 Operations on hollow viscera in contact with serous surfaces, 348.
 Operations on special arteries, 60.
 Operations on the palate, 329.
 Operations on the stomach, 352.
 Operation wounds, treatment of, 41.
 Operative surgery, general considerations, 1.
 Osteo-arthrotomy, Chihène, 220.
 Ogsten, 220.
 Reeves, 220.
 Osteoplastic amputation of heel and ankle, Mikulicz, 273.
 Osteoplastic rhinoplasty, 313.
 Ollier's method, 313.
 Pancoast's method, 314.
 Sabine, T. T., 314.
 Osteotomy, 212.
 for genu varum, 220.
 inter-trochanteric, Sayre, 217.
 inter-trochanteric, Volkmann, 217.
 supra-condyloid, for bony ankylosis of knee-joint, 217.
 supra-condyloid, for genu valgum, Macewen, 218.
 astragaloid, Stokes, 303.
 Palate, operations upon the, 329.
 Palmar arch, superficial, ligature of, 106.
 linear guide to, 106.
 Palmar fascia, 159.
 Dupuytren's contraction of, 160.
 Dupuytren's operation for contraction of, 160.
 Pancoast's operation for extroversion of the bladder, 424.
 operation for rhinoplastic osteoplasty, 314.
 Pancoast's tourniquet, abdominal, 287.
 Paracentesis abdominis, 377.
 Paracentesis thoracis, 483.
 Paraphymosis, 461.
 Parotid gland, extirpation of the, 482.
 Patella, excision of, 207.
 wiring the, 509.
 Peat dressing, 50.
 Pectineus, tenotomy of, 158.
 Penis, amputation of the, old plan, 462.
 Hilton's modification, 462.
 Humphrey's modification, 463.
 Penis, extirpation of the, Gouley's operation, 463.
 Perforation of the antrum, 484.
 Pericardium, tapping the, 479.
 Perineal lithotrixy, 437.
 Perineal nerve, operations on, 149.
 Perineal section, 471.
 Perineal urethrotomy, external, 471.
 with a guide, 472.
 without a guide, 473.
 Perityphlitic abscess, 373.
 Peroneal artery, ligature of, 85.
 linear guide to, 85.
 Peroneus brevis, tenotomy of, 155.
 Peroneus longus, tenotomy of, 156.
 Peroneus tertius, tenotomy of, 156.
 Phalangeal articulations of the hand, amputations at the, 237.
 of the hand, disarticulation at, 237.
 of the foot, disarticulation at, 256.
 Phalangeal joints, excision of, 197.
 Pharyngotomy, 506.
 Phlebotomy, 125.
 Pins, acupressure, 32.
 Pirogoff's amputation at the ankle-joint, 270.
 Plantar fascia, operations on, 159.
 Plantar nerve, operations on, 149.
 Plaster-of-Paris jacket, Sayre's, for curvature of the spine, 298.
 Plastic surgery, 304.
 preparation of patient, 304.
 size of flap, 304.
 Plastic surgery, methods of transfer, 305.
 grafting, 307.
 inversion or eversion, 306.
 jumping, 306.
 skin-grafting, 307.
 sliding, 305.
 Taliacotian operation, 306.
 Plexus of nerves, brachial, operations on branches of, 146.
 lumbar, operations on branches of, 149.
 Plugging the posterior nares, 484.
 Polypi, nasal, removal of, 485.
 Langenbeck's operation, 487.
 Nélaton's operation, 488.
 Polypi, naso-pharyngeal, removal of, Chcever's operation, 489.
 Langenbeck's operation, 488.
 Popliteal artery, ligature of, 77.
 linear guide to, 77.

- Popliteal nerve, external, operations on, 148.
 internal, operations on, 148.
 Precautionary requirements for operations, 53.
 Preparations for an antiseptic operation, 52.
 assistants, 52.
 douching, 52.
 instruments, 52.
 operating-table, 52.
 operator, 52.
 patient, 52.
 the wound, 52.
 Pressure, digital, for controlling hemorrhage, 27.
 instrumental, for controlling hemorrhage, 28.
 Proctotomy, external, 412.
 Prolapsus ani, 409.
 Protective, antiseptic, 48.
 dressings, 48.
 Pudic artery, internal, linear guide to, 68.
 ligature of, 68.
 Puncturing the bladder, 425.
 through the rectum, 426.
 under the pubes, 426.
 Pylorus, division of, Loreto's operation, 359.
 Pylorus, resection of the, 356.
 Quadriceps extensor cruris, tenotomy of, 157.
 Quilled suture, 45.
 Radial artery, ligature of, 101.
 linear guide to, 101.
 Radial nerve, operations on, 147.
 Radius, excision of, 192.
 Ranula, 338.
 Rapid laryngo-tracheotomy, St. Germain, 501.
 Rapid lithotrity, 432.
 Receptacle, antiseptic, for instruments, 21.
 Rectal examination, introduction of whole hand, 409.
 Rectotomy, 412.
 Rectum, cancer of the, 412.
 Rectum, excision of the, 412.
 Cripp's operation, 413.
 Maisonneuve's operation, 414.
 Volkmann's operations, 413.
 Rectum, imperforate, 414.
 stricture of the, 414.
 surgical anatomy of, 408.
 Reef or square knot, 38.
 Reeves' osteo-arthrotomy, 220.
 Regnoli's excision of the tongue, 342.
 Removal of a goitre, Watson, 508.
 Removal of nasal polypi, 485.
 Langenbeck's operation, 487.
 Nélaton's operation, 488.
 Removal of naso-pharyngeal polypi, Cheever's operation, 489.
 Langenbeck's operation, 488.
 Requirements, precautionary, for operations, 53.
 Resection of the pylorus, 356.
 Respiration, artificial, 14, 54.
 Retractors, 59.
 Retroclusion, 32.
 Rhinoplasty, 307.
 Dieffenbach's operation, 310.
 French operation, 307.
 Indian operation, 311.
 Italian operation, 312.
 Langenbeck's operation, 308.
 loss of the bony or cartilaginous septum, with or without loss of nasal bones, 309.
 Rhinoplasty, osteoplastic, 313.
 Ollier's operation, 313.
 Pancoast's operation, 314.
 Sabine, T. T., 314.
 Rib, excision of a portion of a, 180.
 Ricord's operation for varicocele, 125.
 Rigaud's operation of urethroplasty, 470.
 Rod, Trendelenburg's, 31, 288.
 Roux's amputation at ankle-joint, 269.
 Rubber drainage-tube, 46.
 Rupture of the bladder, 421.
 Ruysch's amputation at the wrist-joint, 244.
 Sabine, T. T., osteoplastic rhinoplasty, 314.
 Saline solutions for transfusion, 129, 130.
 Salivary fistula, 335.
 Horner's operation, 336.
 operation by a seton, 336.
 Saphenous nerve, external or short, operations on, 150.
 internal or long, operations on, 150.
 Sartorius, tenotomy of, 157, 158.
 Sayre's excision of hip-joint, 211.
 intertrochanteric osteotomy, 217.
 plaster-of-Paris jacket for curvature of the spine, 298.
 Saw, amputating, proper method of using an, 233.
 Saws, amputating, 232.
 Scalpel, method of holding, 18.
 Scapula, excision of, 182.
 body of, 183.
 for malignant growths, 184.
 glenoid angle of, 187.
 subperiosteal, Ollier, 184.
 Schwartz's saline solution for transfusion, 130.
 Sciatic artery, ligature of, 67.
 linear guide to, 67.
 Sciatic nerve, great, operations on, 146.
 small, operations on, 147.
 Scissors, 20.
 Scrotum, excision of, 122.
 Section, abdominal, 362.
 explorative, 362.
 Sedillot's amputation of thigh, 286.
 operation for removal of the tongue, 342.
 operation of cheiloplasty, for lower lip, 324.
 vertical-flap method of cheiloplasty of upper lip, 326.
 Semi-membranosus, tenotomy of, 157.



- Semi-tendinosus, tenotomy of, 157.
 Septum nasi, deviation of the, 491.
 Sequestrotomy, 163.
 direct method, 164.
 indirect method, 165.
 Serrefines, 33.
 Shock, 55.
 treatment of, 55.
 Shoulder-joint, amputation above, 255.
 Shoulder-joint, amputation at, 250.
 by circular incision, 252.
 by internal and external flaps, Dupuytren,
 250.
 oval method, Larrey, 252.
 Spence's method, 253.
 Shoulder-joint disarticulation at the, 250.
 Silk ligatures, how prepared antiseptically,
 39.
 Skey's amputation at tarso-metatarsal joint,
 262.
 Skin-grafting, 307.
 Solutions, antiseptic, 22.
 saline, for transfusion, 129, 130.
 Sound, introduction of a, into the bladder,
 417.
 Special emergencies, 54.
 Spence's amputation at the shoulder-joint,
 253.
 Spinal accessory nerve, operations on,
 146.
 Spine, curvature of, 298.
 Sayre's plaster-of-Paris jacket for, 298.
 Spiral drainage, Ellis', 46.
 Splenectomy, 377.
 Spray apparatus, antiseptic, 48.
 Square or reef knot, 38.
 Squibb's ether inhaler, 10.
 Staphyloplasty, 335.
 Staphylorrhaphy, operation of, 330.
 Sterno-cleido-mastoid, tenotomy of, 159.
 Sternum, excision of, 179.
 St. Germain's operation of rapid laryngo-
 tracheotomy, 501.
 Stimulants, 53.
 Stokes' amputation at knee-joint, 283.
 astragaloid osteotomy, 303.
 Stomach, operations on the, 352.
 Stomatoplasty, 327.
 Stone in the bladder, 427.
 Strangulated hernia, 390.
 femoral, 397.
 inguinal, 395.
 obturator, 401.
 umbilical, 400.
 Stretching of nerves, 141.
 bloodless, of the sciatic nerve, 148.
 Stricture of the œsophagus, 345.
 of the urethra, operations for, 471.
 of the rectum, 414.
 "Students'" aneurism needle, 60.
 Styptics, 24.
 Subastragaloid disarticulation, De Ligne-
 rolles, 264.
 Hancock, 266.
 Tripier, 266.
 Subclavian artery, ligature of first portion,
 left side, 87.
 of first portion, right side, 89.
 of second portion, 92.
 of third portion, 90.
 Subclavian artery, second portion, linear
 guide to, 89.
 third portion, linear guide to, 89.
 Sub-hyoid laryngotomy, 506.
 Subperiosteal excision of ankle-joint, Lan-
 genbeck, 199.
 of elbow-joint, Langenbeck, 190.
 of hip-joint, Langenbeck, 209.
 of hip-joint, Sayre, 211.
 of humerus, head of, Langenbeck, 186.
 of jaw, upper, 173.
 of knee-joint, Langenbeck, 205.
 of knee-joint, Ollier, 203.
 of maxilla, superior, 173.
 of scapula, Ollier, 184.
 Supra-malleolar amputation of the leg,
 274.
 Supra-orbital nerve, operations on, 141.
 Supra-pubic lithotomy, 452.
 Surgical engine, 169.
 Suture, continuous, 44, 349.
 different forms of, 44.
 glover's, 44.
 hare-lip, 45.
 horse-hair, 43.
 inorganic, 43.
 interrupted, 44.
 intestinal, Czerny-Lembert, 351.
 Gely's, 350.
 Gussenbauer's, 351.
 Jobert's, 350.
 Lembert's, 350.
 metallic, 43.
 quilled, 45.
 twisted, 45.
 Sutures, 42.
 Suturing of nerves, 150.
 of tendons, 161.
 Syme's amputation at ankle-joint, 267.
 Syme's aneurism needle, 60.
 Syme's operation of cheiloplasty for lower
 lip, 322.
 Szumann's saline solution for transfusion,
 130.
 Szymanowski's operation for hypospadias,
 466.
 Szymanowski's operation of urethroplasty,
 471.
 Table, operating, 21.
 Tapping hydrocele, 455.
 the pericardium, 479.
 the urethra, Cock, 478.
 Tarsal amputations, irregular, Molière, 266.
 Tarsectomy, 303.
 Tarso-metatarsal joint, amputation at, Lis-
 franc, 260.
 Bauden's modification of, 262.
 Hey's modification of, 262.
 Skey's modification of, 262.

- Tarso-metatarsal joints, disarticulation at the, 260.
- Taxis, 391.
- Teale's method of amputation, 228.
- Temporal artery, ligature of, 116.
- Tenacula, 33, 34, 53.
- Tendo Achillis, tenotomy of, 155.
- Tendon suturing, 161.
- Tenotomy, 151.
 in lower extremities, 154.
 in upper extremities, 153.
 of adductor longus, 158.
 of biceps flexor cruris, 157.
 of biceps flexor cubiti, 154.
 of erector spinæ, 159.
 of extensor communis digitorum, 153.
 of extensor longus digitorum, 156.
 of extensor ossis metacarpi pollicis, 153.
 of extensor primi internodii pollicis, 153.
 of extensor proprius pollicis, 156.
 of extensor secundi internodii pollicis, 153.
 of flexor carpi radialis, 153.
 of flexor carpi ulnaris, 154.
 of flexor longus digitorum, 154.
 of flexor longus pollicis, 155.
 of flexor profundus digitorum, 153.
 of flexor sublimis digitorum, 153.
 of gracilis, 157.
 of latissimus dorsi, 158.
 of multifidus spinæ, 158.
 of pectineus, 158.
 of peroneus brevis, 155.
 of peroneus longus, 155.
 of peroneus tertius, 156.
 of quadriceps extensor cruris, 158.
 of sartorius, 157, 158.
 of semi-membranosus, 157.
 of semi-tendinosus, 157.
 of sterno-cleido-mastoid, 159.
 of tendo Achillis, 155.
 of tensor vaginæ femoris, 158.
 of tibialis anticus, 156.
 of tibialis posticus, 154.
 of trapezius, 159.
- Tensor vaginæ femoris, tenotomy of, 158.
- Thermo-cautery, 36.
- Thiersch's fluid, antiseptic, 51.
 operation for epispadias, 468.
- Thigh, amputation of, 283
 antero-posterior musculo-integumentary flaps, 285.
 bilateral method, 284.
 circular integumentary flap, 285.
 long anterior flap method, Sedillot, 286.
 single circular incision method, Celsus, 285.
- Thumb, amputation of, at the carpo-metacarpal articulation, lateral-flap method, 241.
 oval method, 240.
- Thumb forceps, 18.
- Thyroid artery, inferior, ligature of, 95.
 linear guide to, 95.
- Thyroid artery, superior, ligature of, 113.
- Thyrotomy, 505.
- Tibia, excision of, 202.
- Tibial artery, anterior, ligature of, 79.
 linear guide to, 79.
- Tibial artery, posterior, ligature of, 82.
 linear guide to, 83.
- Tibialis anticus, tenotomy of, 155.
- Tibialis posticus, tenotomy of, 154.
- Tibial nerve, anterior, operations on, 148.
 posterior, operations on, 148.
- Toe, amputation of the fifth, with its metatarsal bones, 259.
 lateral-flap method, 259.
 of great, by large square internal flap, 257.
 of great, with its metatarsal bone, 259.
- Toe-nail, ingrowing, 302.
- Toes, amputation of all, at the metatarso-phalangeal joint, 258.
 in their continuity, 255.
 of single, 256.
 of single, lateral flap, 256.
 of two adjoining, 257.
- Toes, disarticulation of the, 256.
- Tongue, excision of the, 339.
 below or through the jaw, Regnoli's operation, 342.
 Billroth's operation, 342.
 entire, 341.
 Heart's operation, 342.
 Knox's operation, 342.
 Kocher's operation, 343.
 Regnoli's operation, 342.
 Sédillot's operation, 342.
- Tongue, hypertrophy of the, 340.
- Tongue-tic, 338.
- Torsion, 32.
- Torsocclusion, 32.
- Tourniquet, abdominal, Brandis', 287.
 Esmarch's, 287.
 Lister's, 287.
 Lloyd's, 289.
 Pancoast's, 287.
- Towels, clean, 22.
- Trachea, surgical anatomy of, 493.
- Tracheotomy, 499.
 above the isthmus, 500.
 below the isthmus, 500.
 instruments, 495.
 through the isthmus, 501.
- Transfusion, 54, 126.
 arterial, 131.
 direct from arm to arm, 127.
 injection of milk, 131.
 injection of saline solution, Bull, W. T., 130.
 injection of saline solution, Schwartz, 130.
 injection of saline solution, Szumann, 130.
- Trapezius, tenotomy of, 159.
- Trendelenburg's rod, 31, 228.
- Trephining the cranium, 136.
- Treves' apparatus for enterectomy, 365.
- Tripier's subastragaloid disarticulation, 266.

- Tube, drainage, rubber, 46.
tracheotomy, 53.
Twisted suture, 45.
- Ulna, excision of, 192.
Ulnar artery, ligature of, 104.
linear guide to, 104.
Ulnar nerve, operations on, 147.
Uranoplasty, Ferguson's operation of, 334.
Lannelongue's operation of, 334.
mechanical means employed in, 334.
Urethra, tapping the, Cock, 478.
Urethroplasty, Delpech's operation of, 470.
Dieffenbach's operation of, 470.
Nélaton's operation of, 470.
Rigaud's operation of, 470.
Szymanowski's operation of, 471.
Urethrotomy, internal, 475.
Urethrotomy, external perineal, 471.
with a guide, 472.
without a guide, 473.
Uvula, elongated, 335.
- Varicocele, 121.
compression, 123.
compression by double loop of Ricord, 125.
compression by wires, 123.
Keyes' operation for, 124.
radical treatment for, 123.
subcutaneous ligaturing, 124.
Videl's operation for, 123.
- Varicose veins, 118.
- Veins, air in the, 55.
symptoms, 55.
treatment of, 55.
treatment of, preventive, 55.
- Veins, ligature of, 117.
- Veins, varicose, operations for, 118.
acupressure, 118.
injection, 118.
subcutaneous ligaturing, 118.
- Venesection, 125.
- Vertebral artery, ligature of, 92.
linear guide to, 93.
- Verneuil's amputation at hip-joint, 296.
operation of rhinoplasty, 311.
- Vesico-vaginal lithotomy in the female, 455.
- Vessels, empty, 21.
- Videl's operation for varicocele, 123.
- Volkmann's intert.ochantheric osteotomy, 217.
- Volkmann's operations of excision of the rectum, 413.
- Watson's operation for removal of a goitre, 508.
- Webbed fingers, 300.
Annandale's operation, 301.
Nélaton's operation, 301.
- Whalebone guides, introduction of, 420.
- White's excision of hip-joint, 208.
- Wiring of bones in compound fractures, 512.
the patella, 509.
- Wood's operation for extroversion of the bladder, 424.
for radical cure of femoral hernia, 388.
for radical cure of inguinal hernia, 384.
for radical cure of inguinal hernia with pins, 386.
- Wounds, operation, treatment of, 41.
- Wrist-joint, amputation at, 244.
circular method, 244.
double-flap method, Ruysch, 244.
radial flap, Dubrueil, 245.
single palmar flap, 245.
- Wrist-joint, disarticulation at the, 244.
excision of, 193.
excision of, complete, Langenbeck, 194.
Wutzer's operation for radical cure of inguinal hernia, 382.

THE END.

TEXT-BOOK OF OPHTHALMOSCOPY.

By EDWARD G. LORING, M. D.

PART I.

The Normal Eye, Determination of Refraction, Diseases of the Media, Physiological Optics, and Theory of the Ophthalmoscope.

8vo, 267 PAGES, WITH 131 ILLUSTRATIONS, AND FOUR CHROMO-LITHOGRAPH PLATES, CONTAINING FOURTEEN FIGURES. PRICE, CLOTH, \$5.00.

CONTENTS:

I. Remarks on the Ophthalmoscope.—Examination by Daylight.—Examination of the Eye by Artificial Light. II. Examination with the Ophthalmoscope.—Method of Examination.—Examination by the Inverted Image.—Examination by the Upright Image. III. The Anatomy of the Fundus of the Normal Eye. IV. The Fundus of the Normal Eye as seen with the Ophthalmoscope.—Anomalies. V. Determination of the Optical Condition of the Eye with the Ophthalmoscope.—Refraction.—Astigmatism.—Refraction, according to the Standard of the Inch.—Directions in case the Observer is Ametropic.—Determination of the Refraction of the Eye by the Mirror alone, and by means of the Inverted Image.—Astigmatism with the Mirror alone.—Astigmatism with the Inverted Image.—Amount of Enlargement produced by Upright Image. VI. Examination of the Media of the Eye.—Oblique Illumination.—The Aqueous Humor.—The Iris.—The Lens.—Opacities of the Lens.—Examination of the Media by the Ophthalmoscope.—The Iris.—The Lens.—Vitreous Humor, and Fundus of the Eye.—Differential Diagnosis of Troubles in the Media.—Entozoa.

APPENDIX.—General Principles of the Ophthalmoscope.—Physiological Optics.—Theory of the Ophthalmoscope.—The Metric System.—Ophthalmoscopes.—Adjuncts to the Ophthalmoscope.

“This is a beautiful book, the handsomest of its kind on this subject ever issued from an American press. The paper, press-work, and illustrations are gratifying to every person of correct tastes. The subject-matter is of such excellence as to be worthy of this beautiful dress. . . . His style is pleasant and easy. Avoiding the Scylla of too much technicality, he has not plunged into the Charybdis of too little. He will be doing a proper thing who adds this book to his working library.”—*American Lancet*.

New York: D. APPLETON & CO., Publishers, 1, 8, & 5 Bond Street.

THE USE OF THE MICROSCOPE IN CLINICAL AND PATHOLOGICAL EXAMINATIONS. By DR. CARL FRIEDLAENDER, Privat-Docent in Pathological Anatomy in Berlin. Translated from the enlarged and improved second edition, by HENRY C. COE, M. D., etc.

With a Chromo-Lithograph. 12mo, 195 pp., with copious Index. Cloth, \$1.00.

"Much good has been done in placing this little work in the hands of the profession. The technique of preparing, cutting, and staining specimens is given at some length; also rules for the examination of the various bodily fluids in both health and disease. The use of the microscope with high powers, immersion lenses, and other accessories, is explained very clearly. It is a very readable volume, even for those not engaged in actual laboratory work. A chromo-lithograph shows the various forms of disease-germs which have been definitely isolated."—*Medical Record*.

AN ATLAS OF CLINICAL MICROSCOPY. By ALEXANDER PEYER, M. D., translated and edited by ALFRED C. GIRARD, M. D., Assistant Surgeon United States Army. First American, from the manuscript of the second German edition, with Additions.

90 Plates, with 103 Illustrations, Chromo-Lithographs. Square 8vo. Cloth, \$6.00.

"All who are interested in clinical microscopy will be pleased with the design and execution of this work, and will feel under obligation to the author, translator, and publishers for placing so valuable a work in their hands."—*Philadelphia Medical Times*.

"Accompanying the plates is a text of explanatory notes showing the various methods of working with the microscopes and the significance of what is observed. The plates have been most handsomely printed. We have seen nothing in this special line of study that will compare in point of accuracy of detail and artistic effect with the work under consideration."—*Maryland Medical Journal*.

ELEMENTS OF MODERN MEDICINE, including

Principles of Pathology and Therapeutics, with many Useful Memoranda and Valuable Tables of Reference. Accompanied by Pocket Fever Charts. Designed for the Use of Students and Practitioners of Medicine. By R. FRENCH STONE, M. D., Professor of Materia Medica and Therapeutics and Clinical Medicine in the Central College of Physicians and Surgeons, Indianapolis; Physician to the Indiana Institute for the Blind; Consulting Physician to the Indianapolis City Hospital, etc., etc.

In wallet-book form, with pockets on each cover for Memoranda, Temperature Charts, etc., \$2.50.

"This is an abridged work in pocket-book form, presenting the more advanced views of leading authorities, with reference to general pathology and therapeutics. . . . The work contains a fund of useful information culled from the best authorities in the Old and New World."—*Canada Lancet*.

PYURIA; OR, PUS IN THE URINE, AND ITS

TREATMENT: Comprising the Diagnosis and Treatment of Acute and Chronic Urethritis, Prostatitis, Cystitis, and Pyelitis, with especial reference to their Local Treatment. By Dr. ROBERT ULTZMANN, Professor of Genito-Urinary Diseases in the Vienna Poliklinik. Translated, by permission, by Dr. WALTER B. PLATT, F. R. C. S. (Eng.), Baltimore.

12mo. Cloth, \$1.00.

"It can not be too highly recommended to the attention of the profession, not only on account of its scientific value, but also for the many practical suggestions regarding treatment to be found in the chapter on Therapeutics. The book is neatly and tastefully got up by the publishers."—*Maryland Medical Journal*.

New York: D. APPLETON & CO., Publishers, 1, 3, & 5 Bond Street.

December, 1886.

MEDICAL AND HYGIENIC WORKS

PUBLISHED BY

D. APPLETON & CO., 1, 3, & 5 Bond Street, New York.

- BARKER (FORDYCE). On Sea-Sickness. A Popular Treatise for Travelers and the General Reader. Small 12mo. Cloth, 75 cents.
- BARKER (FORDYCE). On Puerperal Disease. Clinical Lectures delivered at Bellevue Hospital. A Course of Lectures valuable alike to the Student and the Practitioner. Third edition. 8vo. Cloth, \$5.00; sheep, \$6.00.
- BARTHOLOW (ROBERTS). A Treatise on Materia Medica and Therapeutics. **Fifth edition.** Revised, enlarged, and adapted to "The New Pharmacopœia." 8vo. Cloth, \$5.00; sheep, \$6.00.
- BARTHOLOW (ROBERTS). A Treatise on the Practice of Medicine, for the Use of Students and Practitioners. **Sixth edition,** revised and enlarged. 8vo. Cloth, \$5.00; sheep, \$6.00.
- BARTHOLOW (ROBERTS). On the Antagonism between Medicines and between Remedies and Diseases. Being the Cartwright Lectures for the Year 1880. 8vo. Cloth, \$1.25.
- BASTIAN (H. CHARLTON). On Paralysis from Brain-Disease in its Common Forms. 12mo. Cloth, \$1.75.
- BASTIAN (H. CHARLTON). The Brain as an Organ of the Mind. 12mo. Cloth, \$2.50.
- BELLEVUE AND CHARITY HOSPITAL REPORTS. Edited by W. A. Hammond, M. D. 8vo. Cloth, \$4.00.
- BENNET (J. H.). Winter and Spring on the Shores of the Mediterranean; or, The Riviera, Mentone, Italy, Corsica, Sicily, Algeria, Spain, and Biarritz, as Winter Climates. With numerous Illustrations. New revised edition. 12mo. Cloth, \$3.50.
- BENNET (J. H.). On the Treatment of Pulmonary Consumption, by Hygiene, Climate, and Medicine. Thin 8vo. Cloth, \$1.50.
- BILLINGS (F. S.). The Relation of Animal Diseases to the Public Health, and their Prevention. 8vo. Cloth, \$4.00.
- BILLROTH (THEODOR). General Surgical Pathology and Therapeutics. A Text-Book for Students and Physicians. Translated from the tenth German edition, by special permission of the author, by Charles E. Hackley, D. M. **Fifth American edition, revised and enlarged.** 8vo. Cloth, \$5.00; sheep, \$6.00.

- BRAMWELL (BYROM).** Diseases of the Heart and Thoracic Aorta. Illustrated with Lithographs, Chromo-Lithographs, and numerous Wood-Engravings. 8vo. Cloth, \$8.00; sheep, \$9.00.
- BUCK (GURDON).** Contributions to Reparative Surgery, showing its Application to the Treatment of Deformities produced by Destructive Disease or Injury; Congenital Defects from Arrest or Excess of Development; and Cicatricial Contractions following Burns. Illustrated by Thirty Cases and fine Engravings. 8vo. Cloth, \$3.00.
- CARPENTER (W. B.).** Principles of Mental Physiology, with their Application to the Training and Discipline of the Mind, and the Study of its Morbid Conditions. 12mo. Cloth, \$3.00.
- CARTER (ALFRED H.).** Elements of Practical Medicine. **Third edition**, revised and enlarged. 12mo. Cloth, \$3.00.
- CHAUVEAU (A.).** The Comparative Anatomy of the Domesticated Animals. Translated and edited by George Fleming. Illustrated. 8vo. Cloth, \$6.00.
- COMBE (ANDREW).** The Management of Infancy, Physiological and Moral. Revised and edited by Sir James Clark. 12mo. Cloth, \$1.50.
- COOLEY.** Cyclopædia of Practical Receipts, and Collateral Information in the Arts, Manufactures, Professions, and Trades, including Medicine, Pharmacy, and Domestic Economy. Designed as a Comprehensive Supplement to the Pharmacopœia, and General Book of Reference for the Manufacturer, Tradesman, Amateur, and Heads of Families. **Sixth edition**, revised and partly rewritten by Richard V. Tuson. With Illustrations. 2 vols., 8vo. Cloth, \$9.00.
- CORNING (J. L.).** Brain Exhaustion, with some Preliminary Considerations on Cerebral Dynamics. Crown 8vo. Cloth, \$2.00.
- CORNING (J. L.).** Local Anæsthesia in General Medicine and Surgery. Being the Practical Application of the Author's Recent Discoveries in Local Anæsthesia. With Illustrations. Small 8vo. Cloth, \$1.25.
- DAVIS (HENRY G.).** Conservative Surgery. With Illustrations. 8vo. Cloth, \$3.00.
- ELLIOT (GEORGE T.).** Obstetric Clinic: A Practical Contribution to the Study of Obstetrics and the Diseases of Women and Children. 8vo. Cloth, \$4.50.
- EVETZKY (ETIENNE).** The Physiological and Therapeutical Action of Ergot. Being the Joseph Mather Smith Prize Essay for 1881. 8vo. Limp cloth, \$1.00.
- FLINT (AUSTIN).** Medical Ethics and Etiquette. Commentaries on the National Code of Ethics. 12mo. Cloth, 60 cents.
- FLINT (AUSTIN).** Medicine of the Future. An Address prepared for the Annual Meeting of the British Medical Association in 1886. With Portrait of Dr. Flint. 12mo. Cloth, \$1.00.
- FLINT (AUSTIN, JR.).** Text-Book of Human Physiology; designed for the Use of Practitioners and Students of Medicine. Illustrated by three Lithographic Plates, and three hundred and thirteen Woodcuts. **Third edition, revised.** Imperial 8vo. Cloth, \$6.00; sheep, \$7.00.
- FLINT (AUSTIN JR.).** The Physiological Effects of Severe and Protracted Muscular Exercise; with Special Reference to its Influence upon the Excretion of Nitrogen. 12mo. Cloth, \$1.00.

- FLINT (AUSTIN, JR.).** *Physiology of Man.* Designed to represent the Existing State of Physiological Science as applied to the Functions of the Human Body. Complete in 5 vols.
- Vol. I. Introduction; The Blood; Circulation; Respiration. 8vo.
- Vol. II. Alimentation; Digestion; Absorption; Lymph; and Chyle. 8vo.
- Vol. III. Secretion; Excretion; Ductless Glands; Nutrition; Animal Heat; Movements; Voice and Speech. 8vo.
- Vol. IV. The Nervous System. 8vo.
- Vol. V. (With a General Index to the five volumes.) Special Senses; Generation. Per vol., cloth, \$4.50; sheep, \$5.50.
- * * Vols. I and II can be had in cloth and sheep binding; Vol. III in sheep only. Vol. IV is at present out of print.
- FLINT (AUSTIN, JR.).** *The Source of Muscular Power.* Arguments and Conclusions drawn from Observation upon the Human Subject under Conditions of Rest and of Muscular Exercise. 12mo. Cloth, \$1.00.
- FLINT (AUSTIN, JR.).** *Manual of Chemical Examinations of the Urine in Disease; with Brief Directions for the Examination of the most Common Varieties of Urinary Calculi.* Revised edition. 12mo. Cloth, \$1.00.
- FOTHERGILL (J. MILNER).** *Diseases of Sedentary Life and Old Age.* 8vo. Cloth, \$2.00.
- FOURNIER (ALFRED).** *Syphilis and Marriage.* Translated by P. Albert Morrow, M. D. 8vo. Cloth, \$2.00; sheep, \$3.00.
- FREY (HEINRICH).** *The Histology and Histochemistry of Man. A Treatise on the Elements of Composition and Structure of the Human Body.* Translated from the fourth German edition by Arthur E. J. Barker, M. D., and revised by the author. With 608 Engravings on Wood. 8vo. Cloth, \$5.00; sheep, \$6.00.
- FRIEDLANDER (CARL).** *The Use of the Microscope in Clinical and Pathological Examinations.* Second edition, enlarged and improved, with a Chromo-lithograph Plate. Translated, with the permission of the author, by Henry C. Coe, M. D. 8vo. Cloth, \$1.00.
- GAMGEE (JOHN).** *Yellow Fever a Nautical Disease. Its Origin and Prevention.* 8vo. Cloth, \$1.50.
- GROSS (SAMUEL W.).** *A Practical Treatise on Tumors of the Mammary Gland.* Illustrated. 8vo. Cloth, \$2.50.
- GUTMANN (EDWARD).** *The Watering-Places and Mineral Springs of Germany, Austria, and Switzerland.* Illustrated. 12mo. Cloth, \$2.50.
- GYNÆOLOGICAL TRANSACTIONS, VOL. VIII.** Being the Proceedings of the Eighth Annual Meeting of the American Gynæcological Society, held in Philadelphia, September 18, 19, and 20, 1883. 8vo. Cloth, \$5.00.
- GYNÆOLOGICAL TRANSACTIONS, VOL. IX.** Being the Proceedings of the Ninth Annual Meeting of the American Gynæcological Society, held in Chicago, September 30, and October 1 and 2, 1884. 8vo. Cloth, \$5.00.
- GYNÆOLOGICAL TRANSACTIONS, VOL. X.** Being the Proceedings of the Tenth Annual Meeting of the American Gynæcological Society, held in Washington, D. C., September 22, 23, and 24, 1885. 8vo. Cloth, \$5.00.
- HAMILTON (ALLAN McL.).** *Clinical Electro-Therapeutics, Medical and Surgical. A Hand-Book for Physicians in the Treatment of Nervous and other Diseases.* 8vo. Cloth, \$2.00.

- HAMMOND (W. A.).** A Treatise on Diseases of the Nervous System. **Eighth edition**, rewritten, enlarged, and improved. 8vo. Cloth, \$5.00; sheep, \$6.00.
- HAMMOND (W. A.).** A Treatise on Insanity, in its Medical Relations. 8vo. Cloth, \$5.00; sheep, \$6.00.
- HAMMOND (W. A.).** Clinical Lectures on Diseases of the Nervous System. Delivered at Bellevue Hospital Medical College. Edited by T. M. B. Cross, M. D. 8vo. Cloth, \$3.50.
- HART (D. BERRY).** Atlas of Female Pelvic Anatomy. With Preface by Alexander J. C. Skene, M. D. 37 Plates with 150 Figures, and 89 pages descriptive text. Large 4to. Cloth, \$15.00. (*Sold only by subscription.*)
- HARVEY (A.).** First Lines of Therapeutics. 12mo. Cloth, \$1.50.
- HEALTH PRIMERS.** Edited by J. Langdon Down, Henry Power, J. Mortimer-Granville, and John Tweedy. In square 16mo volumes. Cloth, 40 cents each.
- | | |
|--|---|
| I. Exercise and Training. | V. Personal Appearance in Health and Disease. |
| II. Alcohol: Its Use and Abuse. | VI. Baths and Bathing. |
| III. Premature Death: Its Promotion or Prevention. | VII. The Skin and its Troubles. |
| IV. The House and its Surroundings. | VIII. The Heart and its Functions. |
| | IX. The Nervous System. |
- HOFFMANN-ULTZMANN.** Introduction to an Investigation of Urine, with Special Reference to Diseases of the Urinary Apparatus. By M. B. Hoffmann, Professor in the University of Gratz; and R. Ultzmann, Tutor in the University of Vienna. Second enlarged and improved edition. 8vo. Cloth, \$2.00.
- HOWE (JOSEPH W.).** Emergencies, and how to treat them. Fourth edition, revised. 8vo. Cloth, \$2.50.
- HOWE (JOSEPH W.).** The Breath, and the Diseases which give it a Fetid Odor. With Directions for Treatment. **Second edition**, revised and corrected. 12mo. Cloth, \$1.00.
- HUEPPE (FERDINAND).** The Methods of Bacteriological Investigation. Written at the request of Dr. Robert Koch. Translated by Hermann M. Biggs, M. D. Illustrated. 8vo. Cloth, \$2.50.
- HUXLEY (T. H.).** The Anatomy of Vertebrated Animals. Illustrated. 12mo. Cloth, \$2.50.
- HUXLEY (THOMAS HENRY).** The Anatomy of Invertebrated Animals Illustrated. 12mo. Cloth, \$2.50.
- JACCOUD (S.).** The Curability and Treatment of Pulmonary Phthisis. Translated and edited by Montagu Lubbock, M. D. 8vo. Cloth, \$1.00.
- JOHNSON (JAMES F. W.).** The Chemistry of Common Life. A new edition, revised and brought down to the Present Time. By Arthur Herbert Church. Illustrated with Maps and numerous Engravings on Wood. 12mo. Cloth, \$2.00.
- JONES (H. MACNAUGHTON).** Practical Manual of Diseases of Women and Uterine Therapeutics. For Students and Practitioners. 188 Illustrations. 12mo. Cloth, \$3.00.

- KEYES (E. L.).** The Tonic Treatment of Syphilis, including Local Treatment of Lesions. 8vo. Cloth, \$1.00.
- KINGSLEY (N. W.).** A Treatise on Oral Deformities as a Branch of Mechanical Surgery. With over 350 Illustrations. 8vo. Cloth, \$5.00; sheep, \$6.00.
- LEGG (J. WICKHAM).** On the Bile, Jaundice, and Bilious Diseases. With Illustrations in Chromo-Lithography. 8vo. Cloth, \$6.00; sheep, \$7.00.
- LETTERMANN (JONATHAN).** Medical Recollections of the Army of the Potomac. 8vo. Cloth, \$1.00.
- LITTLE (W. J.).** Medical and Surgical Aspects of In-Knee (Genu-Valgum): its Relation to Rickets, its Prevention, and its Treatment, with and without Surgical Operation. Illustrated by upward of Fifty Figures and Diagrams. 8vo. Cloth, \$2.00.
- LORING (EDWARD G.).** A Text-Book of Ophthalmoscopy. Part I. The Normal Eye, Determination of Refraction, and Diseases of the Media. With 181 Illustrations, and 4 Chromo-Lithographs. 8vo. Cloth, \$5.00.
- LUSK (WILLIAM T.).** The Science and Art of Midwifery. With 246 Illustrations. **Second edition, revised and enlarged.** 8vo. Cloth, \$5.00; sheep, \$6.00.
- LUYS (J.).** The Brain and its Functions. With Illustrations. 12mo. Cloth, \$1.50.
- McSHERRY (RICHARD).** Health, and how to promote it. 12mo. Cloth, \$1.25.
- MARKOE (T. M.).** A Treatise on Diseases of the Bones. With Illustrations. 8vo. Cloth, \$4.50.
- MAUDSLEY (HENRY).** Body and Mind: an Inquiry into their Connection and Mutual Influence, specially in reference to Mental Disorders. An enlarged and revised edition, to which are added Psychological Essays. 12mo. Cloth, \$1.50.
- MAUDSLEY (HENRY).** Physiology of the Mind. Being the first part of a third edition, revised, enlarged, and in great part rewritten, of "The Physiology and Pathology of the Mind." 12mo. Cloth, \$2.00.
- MAUDSLEY (HENRY).** Pathology of the Mind. Third edition. 12mo. Cloth, \$2.00.
- MAUDSLEY (HENRY).** Responsibility in Mental Disease. 12mo. Cloth, \$1.50.
- NEFTEL (WM. B.).** Galvano-Therapeutics. The Physiological and Therapeutical Action of the Galvanic Current upon the Acoustic, Optic, Sympathetic, and Pneunogastric Nerves. 12mo. Cloth, \$1.50.
- NEUMANN (ISIDOR).** Hand-Book of Skin Diseases. Translated by Lucius D. Bulkley, M. D. Illustrated by 66 Wood-Engravings. 8vo. Cloth, \$4.00; sheep, \$5.00.
- THE NEW YORK MEDICAL JOURNAL (weekly).** Edited by Frank P. Foster, M. D. Terms per annum, \$5.00.
- GENERAL INDEX, from April, 1865, to June, 1876 (28 vols.)** 8vo. Cloth, 75 cents.

- NIEMEYER (FELIX VON). A Text-Book of Practical Medicine, with particular reference to Physiology and Pathological Anatomy. Containing all the author's Additions and Revisions in the eighth and last German edition. Translated from the German edition, by George H. Humphreys, M. D., and Charles E. Hackley, M. D. 2 vols., 8vo. Cloth, \$9.00; sheep, \$11.00.
- NIGHTINGALE'S (FLORENCE). Notes on Nursing. 12mo. Cloth, 75 cents.
- OSWALD (F. L.). Physical Education; or, The Health Laws of Nature. 12mo. Cloth, \$1.00.
- PEASLEE (E. R.). A Treatise on Ovarian Tumors: their Pathology, Diagnosis, and Treatment, with reference especially to Ovariectomy. With Illustrations. 8vo. Cloth, \$5.00; sheep, \$6.00.
- PEREIRA'S (Dr.) Elements of Materia Medica and Therapeutics. Abridged and adapted for the Use of Medical and Pharmaceutical Practitioners and Students, and comprising all the Medicines of the British Pharmacopœia, with such others as are frequently ordered in Prescriptions, or required by the Physician. Edited by Robert Bentley and Theophilus Redwood. Royal 8vo. Cloth, \$7.00; sheep, \$8.00.
- PEYER (ALEXANDER). An Atlas of Clinical Microscopy. Translated and edited by Alfred C. Girard, M. D. First American, from the manuscript of the second German edition, with Additions. Ninety Plates, with 105 Illustrations, Chromo-Lithographs. Square 8vo. Cloth, \$6.00.
- POMEROY (OREN D.). The Diagnosis and Treatment of Diseases of the Ear. With One Hundred Illustrations. New edition, revised and enlarged. 8vo. Cloth, \$3.00.
- POORE (C. T.). Osteotomy and Osteoclasis, for the Correction of Deformities of the Lower Limbs. 50 Illustrations. 8vo. Cloth, \$2.50.
- QUAIN (RICHARD). A Dictionary of Medicine, including General Pathology, General Therapeutics, Hygiene, and the Diseases peculiar to Women and Children. By Various Writers. Edited by Richard Quain, M. D., In one large 8vo volume, with complete Index, and 138 Illustrations. (*Sold only by subscription.*) Half morocco, \$8.00.
- RANNEY (AMBROSE L.). Applied Anatomy of the Nervous System, being a Study of this Portion of the Human Body from a Standpoint of its General Interest and Practical Utility, designed for Use as a Text-Book and as a Work of Reference. Profusely illustrated. 8vo. Cloth, \$4.00; sheep, \$5.00.
- RANNEY (AMBROSE L.). Lectures on Electricity in Medicine, delivered at the Medical Department of the University of Vermont, Burlington. Numerous Illustrations. 12mo. Cloth, \$1.00.
- RIBOT (TH.). Diseases of Memory: an Essay in the Positive Psychology. Translated from the French by William Huntington. 12mo. Cloth, \$1.50.
- RICHARDSON (B. W.). Diseases of Modern Life. 12mo. Cloth, \$2.00.
- RICHARDSON (B. W.). A Ministry of Health and other Addresses. 12mo. Cloth, \$1.50.
- ROBINSON (A. R.). A Manual of Dermatology. Revised and corrected. Cloth, \$5.00

- ROSCOE-SCHORLEMMER.** Treatise on Chemistry.
 Vol. 1. Non-Metallic Elements. 8vo. Cloth, \$5.00.
 Vol. 2. Part I. Metals. 8vo. Cloth, \$3.00.
 Vol. 2. Part II. Metals. 8vo. Cloth, \$3.00.
 Vol. 3. Part I. The Chemistry of the Hydrocarbons and their Derivatives.
 8vo. Cloth, \$5.00.
 Vol. 3. Part II. The Chemistry of the Hydrocarbons and their Derivatives.
 8vo. Cloth, \$5.00.
- ROSENTHAL (I.).** General Physiology of Muscles and Nerves. With 75 Woodcuts. 12mo. Cloth, \$1.50.
- SAYRE (LEWIS A.).** Practical Manual of the Treatment of Club-Foot. **Fourth edition, enlarged and corrected.** 12mo. Cloth, \$1.25.
- SAYRE (LEWIS A.).** Lectures on Orthopedic Surgery and Diseases of the Joints, delivered at Bellevue Hospital Medical College. **New edition,** illustrated with 324 Engravings on Wood. 8vo. Cloth, \$5.00; sheep, \$6.00.
- SCHROEDER (KARL).** A Manual of Midwifery, including the Pathology of Pregnancy and the Puerperal State. Translated into English from the third German edition, by Charles H. Carter, M. D. With 26 Engravings on Wood. 8vo. Cloth, \$3.50; Sheep, \$4.50.
- SIMPSON (JAMES Y.).** Selected Works: Anæsthesia, Diseases of Women. 3 vols., 8vo. Per volume. Cloth, \$3.00; sheep, \$4.00.
- SMITH (EDWARD).** Foods. 12mo. Cloth, \$1.75.
- SMITH (EDWARD).** Health: A Hand-Book for Households and Schools. Illustrated. 12mo. Cloth, \$1.00.
- STEINER (JOHANNES).** Compendium of Children's Diseases: a Hand-Book for Practitioners and Students. Translated from the second German edition, by Lawson Tait. 8vo. Cloth, \$3.50; sheep, \$4.50.
- STONE (R. FRENCH).** Elements of Modern Medicine, including Principles of Pathology and of Therapeutics, with many Useful Memoranda and Valuable Tables of Reference. Accompanied by Pocket Fever Charts. Designed for the Use of Students and Practitioners of Medicine. In wallet-book form, with pockets on each cover for Memoranda, Temperature Charts, etc. Roan, tuck, \$2.50.
- STRECKER (ADOLPH).** Short Text-Book of Organic Chemistry. By Dr. Johannes Wislicenus. Translated and edited, with Extensive Additions, by W. H. Hodgkinson and A. J. Greenaway. 8vo. Cloth, \$5.00.
- SWANZY (HENRY R.).** A Hand-Book of the Diseases of the Eye, and their Treatment. With 122 Illustrations, and Holmgren's Tests for Color-Blindness. Crown 8vo. Cloth, \$3.00.
- TRACY (ROGER S.).** The Essentials of Anatomy, Physiology, and Hygiene. 12mo. Cloth, \$1.25.
- TRACY (ROGER S.).** Hand-Book of Sanitary Information for Householders. Containing Facts and Suggestions about Ventilation, Drainage, Care of Contagious Diseases, Disinfection, Food, and Water. With Appendices on Disinfectants and Plumbers' Materials. 16mo. Cloth, 50 cents.

- TRANSACTIONS OF THE AMERICAN LARYNGOLOGICAL ASSOCIATION, VOL. VI. Being the Proceedings of the Sixth Annual Meeting, held in Detroit, June 24, 25, and 26, 1885. 8vo. Cloth, \$2.50.
- TRANSACTIONS OF THE NEW YORK STATE MEDICAL ASSOCIATION, VOL. I. Being the Proceedings of the First Annual Meeting of the New York State Medical Association, held in New York, November 18, 19, and 20, 1884. Small 8vo. Cloth, \$5.00.
- TYNDALL (JOHN). Essays on the Floating Matter of the Air, in Relation to Putrefaction and Infection. 12mo. Cloth, \$1.50.
- ULTZMANN (ROBERT). Pyuria, or Pus in the Urine, and its Treatment. Translated by permission, by Dr. Walter B. Platt. 12mo. Cloth, \$1.00.
- VAN BUREN (W. H.). Lectures upon Diseases of the Rectum, and the Surgery of the Lower Bowel, delivered at Bellevue Hospital Medical College. **Second edition, revised and enlarged.** 8vo. Cloth, \$3.00; sheep, \$4.00.
- VAN BUREN (W. H.). Lectures on the Principles and Practice of Surgery. Delivered at Bellevue Hospital Medical College. Edited by Lewis A. Stimson, M. D. 8vo. Cloth, \$4.00; sheep, \$5.00.
- VAN BUREN AND KEYES. A Practical Treatise on the Surgical Diseases of the Genito-Urinary Organs, including Syphilis. Designed as a Manual for Students and Practitioners. With Engravings and Cases. By W. H. Van Buren, M. D., and Edward L. Keyes, M. D. 8vo. Cloth, \$5.00; sheep, \$6.00.
- VOGEL (A.). A Practical Treatise on the Diseases of Children. Translated and edited by H. Raphael, M. D. **Third American from the eighth German edition, revised and enlarged.** Illustrated by six Lithographic Plates. 8vo. Cloth, \$4.50; sheep, \$5.50.
- WAGNER (RUDOLF). Hand-Book of Chemical Technology. Translated and edited from the eighth German edition, with extensive Additions, by William Crookes. With 336 Illustrations. 8vo. Cloth, \$5.00.
- WALTON (GEORGE E.). Mineral Springs of the United States and Canadas. Containing the latest Analyses, with full Description of Localities, Routes, etc. **Second edition, revised and enlarged.** 12mo. Cloth, \$2.00.
- WEBBER (S. G.). A Treatise on Nervous Diseases: Their Symptoms and Treatment. A Text-Book for Students and Practitioners. 8vo. Cloth, \$3.00.
- WEEKS (CLARA S.). A Text-Book of Nursing. For the Use of Training-Schools, Families, and Private Students. 12mo. With 13 Illustrations, Questions for Review and Examination, and Vocabulary of Medical Terms. 12mo. Cloth, \$1.75.
- WELLS (T. SPENCER). Diseases of the Ovaries. 8vo. Cloth, \$4.50.
- WYLIE (WILLIAM G.). Hospitals: Their History, Organization, and Construction. 8vo. Cloth, \$2.50.

