





EMERGENCY SURGERY

SLUSS

THE LEATHER BOUND SERIES

OF

MEDICAL MANUALS

HUGHES. *Compend of the Practice of Medicine.* Ninth Edition. By Daniel E. Hughes, M. D., late Chief Resident Physician, Philadelphia Hospital. Revised by Samuel Horton Brown, M. D., Assistant Dermatologist, Philadelphia Hospital. With Illustrations. 785 pages. Flexible Leather, Gilt Edges, Round Corners. \$2.50

KYLE. *Manual of Diseases of the Ear, Nose and Throat.* Second Edition. By John Johnson Kyle, B. S., M. D., Professor of Otology, Rhinology and Laryngology in the University of Southern California; Member of the American Laryngological, Rhinological and Otological Society. With 169 Illustrations. Flexible Leather, Gilt Edges, Round Corners. \$3.00

SLUSS. *Emergency Surgery.* Third Edition. By John W. Sluss, A. M., M. D., Associate Professor of Surgery, Indiana University School of Medicine; Ex-Superintendent Indianapolis City Hospital; Surgeon to the Indianapolis City Hospital. With 685 Illustrations, xvii+828 pages. 12mo. Flexible Leather, Gilt Edges, Round Corners. \$4.00

THAYER. *Manual of Pathology.* 131 Illustrations. General and Special. By A. E. Thayer, M. D., Professor of Pathology, University of Texas; formerly Assistant Instructor in Pathology, Cornell Medical School. With 131 Illustrations. 711 pages. 12mo. Flexible Leather, Gilt Edges, Round Corners. \$2.50

* * *Other Volumes in Preparation.*

P. BLAKISTON'S SON & CO.
PUBLISHERS : : PHILADELPHIA

EMERGENCY SURGERY

BY

JOHN W. SLUSS, A.M., M.D.

ASSOCIATE PROFESSOR OF SURGERY, INDIANA UNIVERSITY SCHOOL
OF MEDICINE; EX-SUPERINTENDENT INDIANAPOLIS CITY HOS-
PITAL; SURGEON TO THE CITY HOSPITAL

THIRD EDITION, REVISED AND ENLARGED

WITH 685 ILLUSTRATIONS

SOME OF WHICH ARE PRINTED IN COLORS

PHILADELPHIA
P. BLAKISTON'S SON & CO.,
1012 WALNUT STREET

RI 32
S63
1915

COPYRIGHT, 1915, BY P. BLAKISTON'S SON & CO.

\$ 4⁰⁰—

©CL.A410539

THE MAPLE PRESS YORK PA

SEP 20 1915

No 1

DEDICATION

TO MY PRECEPTOR, DR. E. B. EVANS, TYPE AND EXEMPLAR OF
GENERAL PRACTITIONERS, IN MEMORY OF DAYS SPENT
TOGETHER, THIS LITTLE WORK IS INSCRIBED

PREFACE TO THE THIRD EDITION

THE present revision of this volume has adhered to the aim of former editions to present general principles concisely, and practical details amply—in short to make a book useful to the general practitioner in the surgical phase of his daily routine.

Each subject has been carefully revised. The text on Fractures has been greatly increased, consonant with the new interest to the profession generally which this subject has acquired in recent years.

The chapter on Military Surgery has been entirely rewritten in conformity with the surgical experiences of this latest and greatest war. A number of illustrations borrowed from the British Journal of Surgery and other sources are included.

The Technique of the emergency interventions will be found to coincide with the best practice of the present time. Finally the hope is expressed that the volume will continue, as in the past, to find favor with the medical public.

J. W. S.

PREFACE TO SECOND EDITION

THE fact that the first edition of this book was sold out within one year is particularly gratifying to the author because it indicates that the results of his effort to make a useful and practical book have met with the approval of the profession.

In preparing this second edition of the "Emergency Surgery" the effort has been to profit by the suggestions and criticisms of the various reviewers of the first. It is hoped, in consequence, that its usefulness has been increased and that it will continue to find favor with its readers.

A new chapter on the general technic of Laparotomy has been added; each subject has been carefully reviewed; and in many instances new matter incorporated. Thus, for example, Spinal Anesthesia is described in detail and Subphrenic Abscess and Pericardiectomy more fully considered.

Dr. Helen Knabe has contributed some new illustrations, and the skiagrams are the work of Dr. Albert M. Cole, of Indianapolis, to whom thanks are due.

J. W. S.

PREFACE TO THE FIRST EDITION

THIS is a Surgery for the general practitioner; written not to instruct his leisure hour, but in the hope some time to serve as a guide out of uncertainty in a time of stress. Its merits and demerits should be reckoned from that point of view alone. If, occasionally, the form of expression seems dogmatic, it merely comports with the constant aim to be practical; certainly that aim has denied any place to theoretical discussions and has curtailed reference to the various views of recognized authority. An absence of bibliography, it is hoped, therefore, will not be regarded as discourtesy to the many writers, teachers, and practitioners whose ideas have been so freely appropriated.

Among the text-books more constantly consulted are Senn's Practical Surgery, The American Text-book of Surgery, Walsham's Surgery, Treves' Operative Surgery, Lejars' *Chirurgie d'Urgence*, Veau's *Chirurgie d'Urgence et Pratique Courante*, Von Bergmann's *Chirurgie*, and Binnie's Operative Surgery.

The Annals of Surgery, the American Journal of Surgery, the International Journal of Surgery, and the Journal of the American Medical Association have been prolific sources of information.

For advice and aid in many ways in the preparation of this book, special thanks are due Drs. John J. Kyle, James H. Ford, A. W. Brayton, and Gustav Bergener. The original illustrations are the work of Dr. Helen Knabe.

To the publishers, through whose counsel and patient criticism the book has grown into its present form, a grateful appreciation is to be expressed.

J. W. S.

CONTENTS

PART I

CHAPTER I

	PAGE
THE GENERAL PRACTITIONER AS AN EMERGENCY SURGEON: HIS DUTIES AND RESPONSIBILITY: EQUIPMENT	I

CHAPTER II

EMERGENCY ANTISEPSIS. OPERATION IN A PRIVATE HOUSE	6
--	---

CHAPTER III

ANESTHESIA.	12
---------------------	----

CHAPTER IV

SUTURES; METHODS AND MATERIALS	25
--	----

CHAPTER V

DRAINAGE.	32
-------------------	----

CHAPTER VI

DRESSINGS, BANDAGES, SPLINTS.	35
---------------------------------------	----

CHAPTER VII

SHOCK	52
-----------------	----

CHAPTER VIII

HEMORRHAGE	57
----------------------	----

CHAPTER IX

WOUNDS: GENERAL PRINCIPLES.	71
-------------------------------------	----

CHAPTER X

	PAGE
WOUNDS OF SPECIAL REGIONS.	81

CHAPTER XI

INJURIES TO THE TRUNK.	110
--------------------------------	-----

CHAPTER XII

GUNSHOT AND OTHER WOUNDS IN MILITARY PRACTICE	133
---	-----

CHAPTER XIII

GUNSHOT WOUNDS IN CIVIL PRACTICE.	186
---	-----

CHAPTER XIV

FRACTURES OF THE EXTREMITIES	200
--	-----

CHAPTER XV

COMPOUND FRACTURES	283
------------------------------	-----

CHAPTER XVI

FRACTURES OF THE CLAVICLE, SCAPULA, RIBS, SPINE, PELVIS.	290
--	-----

CHAPTER XVII

FRACTURES OF THE SKULL AND OF THE BONES OF THE FACE.	299
--	-----

CHAPTER XVIII

INJURIES TO JOINTS	312
------------------------------	-----

CHAPTER XIX

INJURY AND REPAIR OF TENDONS.	347
---------------------------------------	-----

CHAPTER XX

INJURY AND REPAIR OF NERVES.	357
--------------------------------------	-----

CHAPTER XXI

ABSCCESS	375
--------------------	-----

CHAPTER XXII

PHILEGMON: ACUTE SPREADING INFECTIONS	421
---	-----

CHAPTER XXIII

PAGE

ACUTE OSTEOMYELITIS	432
-------------------------------	-----

CHAPTER XXIV

SEPTIC ARTHRITIS	440
----------------------------	-----

CHAPTER XXV

FOREIGN BODIES.	451
-------------------------	-----

CHAPTER XXVI

BURNS, SCALDS, AND FROST-BITE	468
---	-----

PART II

CHAPTER I

TRACHEOTOMY, LARYNGOTOMY, ESOPHAGOTOMY	477
--	-----

CHAPTER II

URGENT THORACOTOMY. REPAIR OF INJURY TO THE LUNGS. REPAIR OF INJURY TO THE PERICARDIUM. REPAIR OF INJURY TO THE HEART. PUNCTURE OF THE PERICARDIUM. PERICARDIOTOMY.	488
---	-----

CHAPTER III

EMPHYEMA—PURULENT PLEURISY.	502
-------------------------------------	-----

CHAPTER IV

URGENT CRANIECTOMY; TREPHINING	510
--	-----

CHAPTER V

MASTOID ABSCESS	522
---------------------------	-----

CHAPTER VI

GENERAL TECHNIC OF LAPAROTOMY.	530
--	-----

CHAPTER VII

LAPAROTOMY FOR TRAUMATISM	537
-------------------------------------	-----

CHAPTER VIII

APPENDICITIS; APPENDICIAL ABSCESS; PURULENT PERITONITIS . . .	557
---	-----

CHAPTER IX

	PAGE
ACUTE INTESTINAL OBSTRUCTION	577

CHAPTER X

ARTIFICIAL ANUS; TEMPORARY, PERMANENT	589
---	-----

CHAPTER XI

STRANGULATED HERNIA	598
-------------------------------	-----

CHAPTER XII

RADICAL CURE OF INGUINAL HERNIA	632
---	-----

CHAPTER XIII

RADICAL CURE OF FEMORAL HERNIA	643
--	-----

CHAPTER XIV

ENTERECTOMY. INTESTINAL ANASTOMOSIS	650
---	-----

CHAPTER XV

IMPERFORATE ANUS	662
----------------------------	-----

CHAPTER XVI

TORSION OF THE PEDICLE OF OVARIAN OR UTERINE TUMORS; OF THE SPERMATIC CORD; OF THE PEDICLE OF THE SPLEEN; OF THE OMENTUM.	667
--	-----

CHAPTER XVII

RUPTURE AND HEMORRHAGE OF TUBAL PREGNANCY.	675
--	-----

CHAPTER XVIII

CESAREAN SECTION	682
----------------------------	-----

CHAPTER XIX

RUPTURE OF THE URETHRA.	686
---------------------------------	-----

CHAPTER XX

ACUTE RETENTION; CATHETERIZATION; SUPRAPUBIC PUNCTURE; CYSTOTOMY; URINARY INFILTRATION	698
---	-----

CHAPTER XXI

SUTURE AND LIGATION OF ARTERIES	717
---	-----

CHAPTER XXII

PAGE

PRACTICAL AMPUTATIONS	728
---------------------------------	-----

CHAPTER XXIII

DILATION OF THE SPHINCTER ANI; OPERATION FOR PILES; OPERATION FOR ANAL FISTULA	783
---	-----

CHAPTER XXIV

PHIMOSIS; PARAPHIMOSIS; CIRCUMCISION; HYDROCELE; CASTRATION. .	790
--	-----

CHAPTER XXV

INGROWING TOE-NAIL	801
------------------------------	-----


CHAPTER XXVI

REMOVAL OF SMALL TUMORS	804
-----------------------------------	-----

CHAPTER XXVII

SKIN GRAFTING	807
-------------------------	-----

INDEX	813-828
-----------------	---------



EMERGENCY SURGERY

CHAPTER I

THE GENERAL PRACTITIONER AS AN EMERGENCY SURGEON: HIS DUTIES AND RESPONSIBILITY. EQUIPMENT

Surgery is no longer reserved to the elect few. That its beneficence shall be denied a place in every practitioner's art is repugnant to the spirit of the times. Modern life is complex: every profession and every calling has its specific duty to perform. Whether the medical profession shall continue to play nobly its large part in the social drama depends upon the general practitioner. The hope of the profession rests in him. But there is a price to pay the age for high respect. That price to the medical profession is nothing less than the fulfillment of its therapeutic promise and realization of its surgical opportunity. The opportunity is golden; for, with the wonderful improvements in surgical technic, the field of emergency surgery, that is to say, the indication for immediate intervention, has been remarkably broadened and the time finds the public singularly favorable to that form of relief.

The "horror of the knife," of all that pertains to surgery, has become a tradition, like the practice which gave it birth. Indeed, the public is trained to expect that, in the face of grave emergencies, the practitioner will do something effective; however serious the required intervention may be, if it but offers hope, the doctor is expected to act. Our predecessors—even those able and willing—often found their hands tied under such circumstances by the ruling policy of "let alone and let die." It is a part of their glory that they conceived, planned, and attempted in the face of tremendous obstacles, most of the interventions of urgency which are current to-day.

The surgical opportunity, then, of the general practitioner is clear, and his duty as well. The professional spirit, the humanities, his conscience, make it incumbent upon him to know and act. This he must do or drop to the rear in the march of progress, which does not halt for the timid or unwilling.

But the task imposed is heavy, the responsibility large; for the general practitioner often finds himself isolated, remote from special counsel, perhaps compelled to act alone. That he does not always rise to the surgical emergency and do all that he might do even under unfavorable circumstances, may often be laid in large part at the door of his training. He knows often what he ought to do, yet knows not how to do it. Happily the courses of instruction are now generally planned to do away with this strange antithesis between theory and practice: a theory, modern, scientific, positive; a practice, as Lejars says, still often full of error and based on empiricism age-old.

But this must not be; for, now that the indications for operation are exactly defined and one's duty obvious, vague conception of an operation as something far away and desperate, must give way to clear notions of the resources of surgery, of surgical therapeutics. Every doctor must familiarize himself with the technic of interventions which he must undertake at times, if he is not to be inexcusably remiss in an almost sacred duty.

Surgery in one respect is a handicraft, and as such requires its certain tools of first necessity. If, as has been said, emergency surgery always comes in the nature of a surprise, then the surprise will at least be less complete if one has an *equipment* and has it *prepared*.

Every doctor should have an emergency bag supplied with materials: hand brushes, soap, a fountain syringe, hypodermic syringe, catheters, flasks of alcohol, ether, chloroform and carbolic acid, bichloride tablets, a package of sterile compresses, sutures, bandages, a box of plaster of Paris, and certain instruments.

Hand Brushes.—These are almost indispensable for emergency surgery. They should be kept well wrapped and should be cleansed with soap and hot water and sterilized by boiling for one minute before using. New brushes should be boiled in soda solution for five to ten minutes. If brushes are lacking, one may scrub the hands and the field of operation with sterile gauze. In the hospital where the

cleansing at the time of operation has been preceded by another disinfection, gauze may be used to the exclusion of the hand brush.

Fountain Syringe or Irrigator.—One may use the full rubber outfit or, what is better, a porcelain container and a long rubber tube with glass nozzles. It is absolutely essential that the whole be sterilized by boiling. It is nonsense to sterilize, as is often done, the cannulæ and container, and neglect the tube. The glass nozzles are likely to be broken if plunged directly into boiling water or if cooled too rapidly. If the porcelain container is used, it may be boiled and then singed with burning alcohol. It takes up but little room in the bag, and the tube and nozzles may be wrapped up and packed in it and the whole wrapped and kept clean and dry. This outfit is almost indispensable, for in many emergencies the only adequate treatment is by hypodermoclysis or intravenous infusion.

The Antiseptics.—The alcohol must be kept in a well stopped flask and the carbolic acid or lysol, also. The bichloride may be in the form of tablets, so that the strength of a solution may be readily calculated. The most commonly employed is the formula containing mercury bichloride 7.3 gr., citric acid 3.8 gr. This tablet in 1 quart of water makes a 1 to 2000 solution, which is as strong as need be used. One to 3 pints makes a 1 to 3000 solution, and so on. Instead of the tablets, one may keep a concentrated solution of bichloride in alcohol.

Bichloride of mercury,	3j.
Alcohol,	3j.

One teaspoonful to a quart of water makes a 1 to 2000 solution;
One teaspoonful to 3 pints, 1 to 3000, etc.

Instead of the bichloride, the biniodide of mercury, 1 to 4000 may be used.

Iodine grows constantly in favor in spite of certain drawbacks. A four ounce vial of the tincture supplies for many sterilizations. Its stain on the hands and linens may be removed by moistening with ammonia or solution of hyposulphite of sodium.

Anesthetics.—One should keep on hand at least one pint of ether and four to six ounces of chloroform. Cocaine for local anesthesia is best kept in tablet form and the solutions made extemporaneously.

For example, $2\frac{1}{2}$ -grain tablets of cocaine to 1 teaspoonful of sterile water makes a 2 per cent. solution; $4\frac{1}{2}$ -grain tablets of a teaspoonful of water makes a 4 per cent. solution; $10\frac{1}{2}$ -grain tablets, a 10 per cent. solution. This is not exact, of course, but furnishes a good working rule for the emergency. Novocaine is less dangerous than cocaine and in $\frac{1}{2}$ or 1 per cent. solutions may be used in large quantity and with excellent effect. Ethyl chloride for local freezing is put up in small containers convenient for the emergency bag.

Sterile Gauze.—Too frequently the practitioner commits the error of depending upon absorbent cotton for his sponges and compresses. Absorbent cotton, as found on the market, is scarcely ever aseptic. Even so, it is almost certain to be contaminated in getting it out of the package. A supply of sterile gauze is one of the best means of promoting an aseptic operation. It should be kept in a hermetically sealed package of metal or glass.

In lieu of the gauze compresses ready sterilized, one may carry a supply of ordinary gauze which can be cut into appropriate sizes, and sterilized at the time of operation. It is a good idea to cut two sizes; a small for compresses and wipers, a larger to cover the field of operation. All these pieces should be folded once and the borders hemmed. A ball of cotton may be hemmed in between the layers, which makes a still better sponge. The compressed package of gauze as supplied by Borroughs and Welcome is especially appropriate to the small emergency bag. Once accustomed to its use it seems almost indispensable.

Sutures and Ligatures.—If these materials are not already sterilized and in a special package or container, such as a sealed tube of alcohol, catgut must be ruled out, for its preparation takes too much time. One should take care to have several sizes of silk, especially the 0 and 00; for these are the sizes required in intestinal work. Silk and silkworm-gut may be sterilized as needed.

Catheters and bougies should be kept in a metallic box. Rubber and metal catheters are always readily sterilized by boiling. Rubber catheters deteriorate rapidly unless properly cared for. They may break unexpectedly, the result of an unnoticed change in quality, and a piece be left in the bladder.

Drainage Tubes.—These should be preserved in a box or bottle which may be boiled thoroughly before opening.

Plaster should be kept in a tin box with tight cover and may be loose or already rolled. A supply of roller bandages is, of course, always kept on hand, from which the plaster bandages may be made.

Instruments.—Any list which might be enumerated must, of course, be subject to the widest variation. But the feeling of greatest confidence goes with the consciousness of having the necessary things with which to act. On the whole, the doctor should pride himself upon the completeness of his outfit, rather than upon his ability to improvise. One should have as the minimum: scalpels, two sizes of amputating knives, scissors, grooved director, dissecting forceps, artery forceps—the more the better—two retractors, a saw, a bone chisel, needle holder and needles, tracheotomy tubes, and an Esmarch tube. The instruments most frequently used may be put together in a small metal case, while the others may be kept in larger cases, or wrapped, or rolled up in a bundle.

Cleaning instruments and preserving them from rust is a matter of no small importance. After each operation they should be taken apart, scrubbed with soap and warm water, wiped with gauze saturated with alcohol, and dried thoroughly. If the cleansing has been delayed, it may be necessary to immerse them for a short time in a solution of potash, and finally cleanse in the manner described. If any stains still persist they should be polished with chamois skin.

Formaldehyde, certain acids, and iodine in too close proximity, tarnish and spoil instruments in spite of care.

A dish or two of calcium chloride in the instrument case will absorb moisture and tend to prevent rusting. Too often the practitioner neglects his instruments because, perhaps, not often used; and, in the emergency, he finds himself with knives rusty and without an edge, scissors that will not cut, and forceps that have no grip. He will certainly gain time by spending a little time in carrying out these small details in the care of his tools.

CHAPTER II

EMERGENCY ANTISEPSIS. OPERATION IN A PRIVATE HOUSE

The preparation for an urgent intervention outside of an operating room resolves itself into a question of asepsis or antiseptic, and around this point gathers a multitude of details. But it is necessary only to proceed systematically and intelligently to achieve excellent results.

The time was when the idea prevailed that an aseptic operation was scarcely possible outside a hospital. This was a harmful notion which restrained many a practitioner from an effort that might have saved his patient's life. Every day it is demonstrated that aseptic work is not peculiar to formal operating rooms.

Bonney, of Philadelphia, writes that he has done many major operations in the homes of the poor in the midst of the most unsurgical surroundings; nevertheless, the results have been excellent. Most of these operations were for urgent abdominal, pelvic, or genito-urinary disease, and though such work is often time-consuming and laborious, yet it shows what can be done in the case of necessity.

Garrison of Birmingham (Ala.) concludes a useful paper touching this subject with the statement that of a thousand cases operated in the last ten years in the patients' homes the mortality rate was zero, except that in a series of abdominal gunshot cases three died. (Amer. Jour. Surg., Aug., 1914.)

Van der Walker (Month Cyclopedia of Pract. Med., Aug., 1906) says that for thirty years he has operated in farm houses throughout central New York with as good results as those obtained in the hospital with which he was connected for many years. He goes further and concludes that, for many reasons, it is desirable that there should be a return to more home operating, and that the hospital ought to go back to its original purpose, the care of the

homeless and sick poor, and not invade the home with the arrogant assurance that only within its walls can the surgical case be cared for.

But this is aside from the main point: *the practitioner may feel assured that with decision, knowledge, and system, even under apparently unfavorable circumstances, he can nearly always realize an effective asepsis.*

As Lejars says, everywhere one finds water, fire, and linen; add salt and usually carbonate of soda: with these one may accomplish a sufficient sterilization of the instruments, the hands, the field of operation and the dressing. But it requires a will to do all the work, to proceed with method and, above all, quickly, through the minutiae of preparation. One should have a plan in mind and Lejars offers a model which, of course, can be modified to suit the circumstances and the operation. Suppose a major emergency, with every detail of the preparation to be supervised:

First Step.—Have a fire started. Have the available receptacles assembled. Review the stock of linens if you do not have gauze or muslin. Freshly laundered handkerchiefs and napkins (without fringe) furnish material for excellent compresses and coverings for the field of operation. Secure one or two large kettles—a copper wash-boiler—for boiling the water for the operation. Secure three smaller receptacles such as enameled stewing-pans: one, for boiling the instrument and sutures; another, for the brushes, irrigator, nozzles and tube, etc.; the third, for the compresses and tampons. If possible, boil also the dishes or basins selected to hold the instruments and the solutions needed during the operation. It is best to have a dish or bowl for the instruments, one for the tampons and compresses, one for the sutures, and two hand basins for sterile water and bichloride solution. The boiling must be prolonged at least a half hour to be sure of sterilization. It is a good plan to add a teaspoonful of salt to the quart of water containing the compresses which are to be tied up in a towel to facilitate their removal; and to add a teaspoonful of washing soda to the water in which the instruments are to boil, since it more readily removes grease or blood, makes the temperature slightly higher, and prevents rusting. The knives should be wrapped in soft gauze to prevent dulling; still better

edged instruments should not be boiled at all but merely immersed in alcohol for some time previous to the operation. The instruments ought not to be put in until the water is boiling, as otherwise they are likely to be tarnished. If it is necessary to boil the instruments and suture material together, the soda should not be added, since it rapidly ruins both silk and silkworm-gut. Even better than boiling water for sterilizing instruments is hot oil—olive oil, for example—since its boiling-point is a higher than that of water. The vessel containing the oil can be set in another of cold water and instruments may soon be taken from the oil ready for use. This oil may be used again many times. Five minutes of actual boiling is sufficient to sterilize instruments. When once the sterilization is under way proceed to the operating room.

Second Step. Prepare the Operating Room and Table.—If there is any choice, select the best lighted and largest room. If it is at night, arrange for the illumination. Do not displace the furniture except to make room for the operating table, two small tables, and room to “turn about.” An extensive “clearing for action” does more harm than good, for by jerking down the curtains, rolling the furniture around and sweeping, one stirs up the dust, accumulating perhaps for months.

It is preferable simply to sprinkle the floor or wipe with a wet cloth. To be sure, if one has several hours in which to prepare, then the room may be emptied, the floor covered with moist sheets and the walls sprayed, as Quenu suggests, with peroxide, the tables placed and the room closed until the time of operating.

It is never a good idea to use the patient's bed for an operating table, although the first preparation, as the shaving, may be begun there. The dining table can usually be pressed into service, covered with a blanket and that with an oilcloth. A table may be improvised from two wooden trestles with planks laid across and covered like the table. Of the two small tables required, the one on the assistant's side will hold the compresses, sutures, etc.; the other on the operator's side will hold the instruments.

Now give the patient the preliminary preparation. Shave the parts always when possible, first lathering with soap and hot water. The razor is almost indispensable as an agent of disinfection, for it

removes the hair and the superficial layer of the epidermis. It is a common fault to be too sparing with its use. In operations on the skull, the whole scalp should be shaved. The shaving may be done after the patient is anesthetized; but, as a rule, everything possible should be done to curtail the anesthesia. If the operation is likely to be prolonged, wrap the lower limbs in blankets, and speak for hot irons or water bottles.

Third Step.—Everything having boiled sufficiently, carry the vessels into the operating room and empty the contents of each into its special receptacle, which of course must first be sterilized.

If these bowls have not been boiled, as previously directed, now is the time to sterilize them by singeing with burning alcohol. Into each pour two or three spoonfuls of alcohol and set it on fire, in the meantime tilting the dish in various directions so that the flame is brought in contact with the whole inner surface. When this is done, lift the compresses and instruments out of their boilers, place them in these sterile dishes and cover them with an antiseptic solution. This protects them from possible contamination until the operation begins. Do not open the bag of compresses till needed. Remember to use only a sterile dipper, if necessary to dip out the sterile water in preparing the various solutions.

Fourth Step.—Direct the assistant to begin the anesthesia, and now *prepare your hands*. As Lejars remarks, this is a "science and art," the first duty of the surgeon. They are not to be prepared by a desultory rinsing in soapy water, or parboiling with a hot antiseptic solution, but by a patient and systematic *scrubbing*. Get your sleeves rolled up and pinned. Have before you two wash basins, one with hot and the other with cold sterile water. Pare the nails. Begin with soap and hot water. Lather the arms up to the elbow, and rub the soap in until the skin seems saturated and soft. Then begin with the brush; scrub the palms, the dorsum of the hand, between the fingers, all about the nails. One need not rub the skin off, to be sure, but the disinfection must be complete. The water should be changed several times, if possible; next rinse in cold sterile water and then rub vigorously with alcohol to remove all the oils in the skin; finally soak in bichloride solution. The cleansing will probably occupy ten minutes. The antiseptics used vary with the

operator, but, after all, it is the soap and hot water which is most important. At the Indianapolis City Hospital the routine is scrubbing with soap and water; rinsing in lysol; rinsing in sterile water; and finally scrubbing thoroughly with gauze saturated with alcohol. In an emergency one might feel safe in using the alcohol alone.

Alcohol as a disinfecting agent has the disadvantage that it fixes the blood of the operation on the skin but this may be removed by peroxide or a warm solution of sodium carbonate.

Rubber gloves are almost universally employed in hospital clinics.

Gloves are trying to the temper where the surgeon must manage them himself. One plan is to fill them with the solution used in the operation and which is squeezed out after the hand is in place.

Burmeister says that just before putting on the gloves, he rubs two tablespoonfuls of bolus alba with a little water over his hands so that they are covered with the thick paste, enabling the glove to be pulled on and off easily, protecting it against tearing and besides the paste has a soothing action on the skin. (Zent. blatt. f. Chirurg, Leipsic, Feb., 1913.) They are probably an extra guarantee against infection, but are by no means indispensable. As good plan as any, perhaps, is to use them always where infective processes are likely to be met with; thus the operator is protected; and, besides, his hands are kept free from septic agents which might be difficult to remove.

Fifth Step.—In the meantime the anesthesia has progressed. When it is well under way, *prepare the field of operation*, which we assume has been previously shaved, by scrubbing with soap and water, followed by alcohol or ether and bichloride solution. Harrington's solution is much employed and consists of

Mercuric chloride,	.8 g.
Acid hydrochloric,	60 c.c.
Water,	300 c.c.
Alcohol,	640 c.c.

Iodine is quite commonly used and for emergency work is preferable. In this case the skin is shaved dry, scrubbed with ether or alcohol and the plain Tr. of iodine applied and allowed to dry. Another application is made and when it dries the sterilization is complete.

In the case of the abdomen, particularly, the iodine should be finally removed by use of alcohol. But, whatever method may be employed, *the disinfection of the skin must be, in every respect, as thorough and vigorous as that of the hands, and must extend well beyond the proposed line of incision in all directions*, for one can never tell where the incision may finally end. A large area is almost as rapidly prepared as a small one. For example, in laparotomies the whole abdomen should be included, as well as the lower half of the thorax. In hernia operations, the abdomen as far as the umbilicus, the groin and the genitals. In amputations of the leg, the thigh should be included in the cleansing; and in amputations of the thigh, the whole region of the pelvis.

Again wash your hands. An untrained assistant changing the bowls may spoil the sterilization by getting his fingers or thumbs inside. Direct him how to lift and carry a bowl with his palms against the outside.

Having completed the final cleansing of the hands, cover the field of operation on the four sides with four sterile towels or large compresses and fasten them with sterile safety pins or artery forceps.

Time gained by relaxing in the least any of these precautions of asepsis and antisepsis, is irretrievably lost; it is the operation, now begun, which must progress rapidly.

Beware at this time of sudden blanching of the face, of dilated pupils, of weakened pulse, or disturbed breathing. If these symptoms arise, withdraw the anesthetic and prepare for artificial respiration. The patient is not ready for the operation and yet he may die in this stage.

Pallor and dilated pupils often precede vomiting, but when the pulse and respiration are good, the nausea is to be quieted by more chloroform.

When the reflexes are finally abolished, the pulse should be full, though perhaps a little slowed, the respiration quiet and regular, the pupils slightly contracted, and the face moderately pale. Any marked deviation from this standard during the operation is a matter for concern.

Weak heart action, uncertain respiration, dilated pupils, deep pallor or cyanosis, mean approaching paralysis of the automatic centers governing the circulation and respiration, and the anesthetic must be withdrawn until the symptoms improve under measures employed to stimulate.

In the case of the average adult, one and one-half to two ounces should be sufficient for the first hour and much less subsequently. Children and the debilitated require less.

Ether has the disadvantages in emergency work that it is dangerous to use near a light or fire, and that its administration is a little more complicated; but, beyond that, its anesthesia is never attended by sudden death in the early stages, as is that of chloroform. It is followed by less shock after abdominal operations or other prolonged intervention. Bronchial affections are its chief contraindications.

Ether may be administered by the drop method using the same mask as for chloroform (Fig. 2) and the same general method (Fig. 3). Or an inhaler may be fashioned out of a newspaper rolled into a cone, cotton or gauze fastened in its apex, on which the ether is poured. Begin with a drachm; let the patient get accustomed gradually to the ether, diluting it well with air by holding the inhaler an inch or so from the face and gradually approaching. In that way, the feeling of suffocation is avoided. As the patient approaches unconsciousness, hold the mask closely so as to shut out the

air, and the stage of anesthesia will be quickly reached without excitement.



FIG. 2.—Administration of ether by the drop method. Mask, with and without gauze covering. Appliance for regulating flow, unattached, to right of ether can.

If one proceeds timidly at this stage, the anesthesia will be hard to obtain and much more ether will be required. Once the reflexes

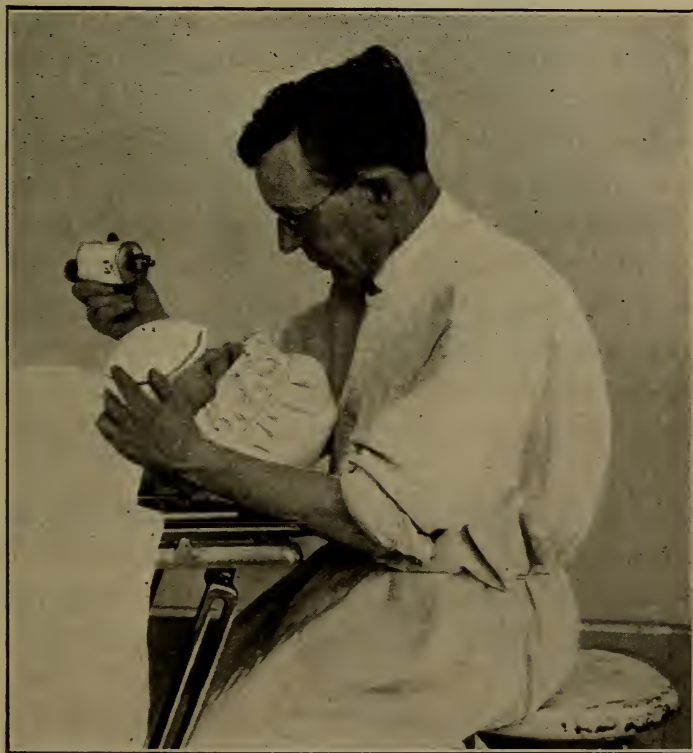


FIG. 3.—Administration of ether. Appliance regulating flow attached to can.

are abolished, use small quantities, frequently applied. The accident most to be feared is *respiratory paralysis*.

The signs indicating the favorable progress of ether anesthesia during the operation are: pulse full and regular; respiration deep and slightly snoring; face flushed; and pupils slightly dilated. Cyanosis is the signal for more oxygen. Any disturbance of the respiration demands immediate attention. Occasionally patients will be found who do not take ether well, but who will take chloroform without the least untoward effect.

TREATMENT OF THE ACCIDENTS OF ANESTHESIA

Certain measures are recommended as forestalling the dangers of anesthesia; though they are, as a rule, more appropriate to the general surgery of hospitals.

A preliminary gastric lavage will save embarrassment in certain cases. In fact, this should be an invariable rule, when compelled to operate on patients who have eaten only a short time previously. A preliminary subcutaneous injection of normal salt solution will sustain the patient in the cases of anemia and grave septic infection.

Many surgeons precede a chloroform anesthesia by hypodermic injection of morphine or strychnine, or of morphine and atropine, thirty minutes before the anesthesia. This is desirable especially in operations on regions in which the reflexes are more active, for there is scarcely a doubt that some of the circulatory disturbances under chloroform are reflected from the field of operation. This is true of the testicle, the spermatic cord, the anus, and the peritoneum. None of these methods lessens the anesthetist's responsibility and duty to watch every point.

If the circulation grows weak, the pulse small, rapid, compressible, due to the effect of the anesthetic agent and not to shock or hemorrhage, withdraw the agent and lower the head, draw out the tongue and begin artificial respiration, and the danger is usually soon passed.

Hypodermic injection of stimulants, such as strychnia or camphorated oil often do good under these circumstances; but when the circulation is paralyzed and syncope has supervened, their use is illusory. Do not waste time preparing them, though an assistant may do so; but proceed to make rhythmic traction on the tongue,

and artificial respiration, both being carried out methodically. If an assistant is at hand, carry out the two measures simultaneously; otherwise, try the tongue traction first, or at least get it pulled out well. Traction of the tongue to do good, must be rhythmic. The tongue must be caught up carefully with forceps and no force must be used. Often the tongue is seriously injured by the feverish pulls of the agitated operator, who has quite forgotten that the maneuver is effectual only when rhythmic.

The *artificial respiration* must likewise be rhythmic.

Grasp the patient's elbows and draw them gently and steadily upward until they meet above the head. The pectoral muscles are put upon the stretch and the chest expanded and inspiration produced. At the same time the tongue is drawn outward (Fig. 4).

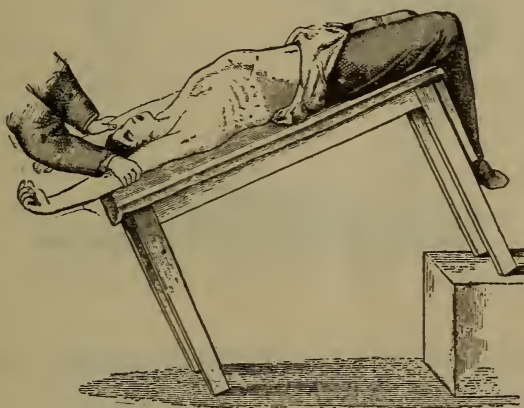


FIG. 4.—Stage of inspiration. Tongue should be drawn out with this movement. (Stewart.)

The arms are next brought with a steady movement to the chest wall and the diaphragm compressed. (Stage of expiration.) At the same time, the tongue is permitted to retract (Fig. 5).

These movements are to be repeated at the rate of about twenty per minute and should be persisted in without intermission for at least a half hour before giving up hope of resuscitation.

Direct compression of the heart is a procedure of real value and it may often be readily managed through the abdominal walls. In the case of abdominal operations, the hand may be passed up to the diaphragm and the heart seized and kneaded in that manner.

The *vomiting after anesthesia* is often troublesome and is usually

in direct ratio to the amount of the agent used. Every effort should be made to hasten its elimination from the blood by keeping the skin warm and active, and helping the kidneys with saline enemata. These enemata also diminish thirst. Warm soda water drunk freely helps to wash out the stomach and thus hastens relief of active vomiting. Five to fifteen drops of aromatic spirits of ammonia hypodermically, or, well diluted, by mouth, often does good. Both these agents probably do good by relieving acidosis which is a large factor in producing post-anesthetic troubles.

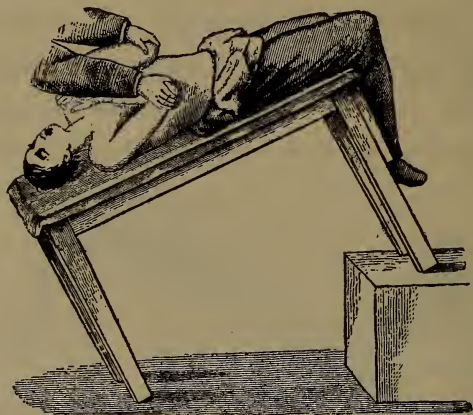


FIG. 5.—Stage of expiration. Tongue permitted to drop back in mouth. (Stewart.)

If there are evidences of beginning acute gastric dilatation, gastric lavage must be used early.

Other forms of general anesthesia will not often be of service in emergency practice for obvious reasons, however valuable they may otherwise be. It is hardly necessary, therefore, to consider nitrous oxide or ethyl chloride and their congeners; or general anesthesia by way of the rectum, which promises to be of value in operations on the face, mouth, neck, and thorax; or hedonal and ether intravenously which has been the subject of good reports.

LOCAL ANESTHESIA

The doctor, isolated and without assistants, will many times find aid and comfort in local anesthesia by hypodermic injection; but to be efficient, it must be properly induced. A definite technic must

be followed. Either cocaine or stovaine may be used, the latter safer, the former slightly more active, the two used alike. Having determined the line of incision, pinch up a fold of skin (Fig. 6), introduce the needle at one end of the line and push it into the skin, but not through the skin. The injection is intradermal (Fig. 7).

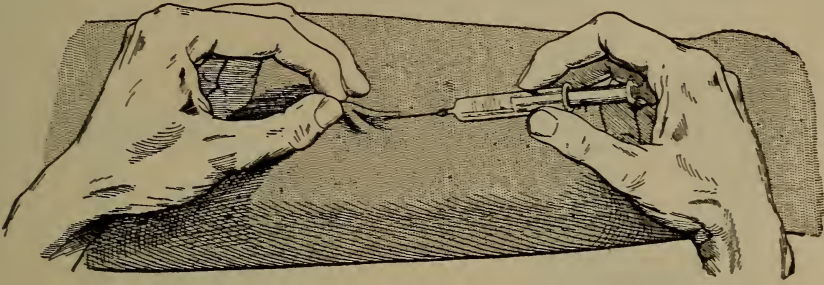


FIG. 6.—Local anesthesia; method of introducing needle. (Veau.)

As the needle is steadily advanced, the syringe is emptied slowly, and the line of injection is indicated by the formation of a wheal. When the needle has entered its length, it is reintroduced in the same line and in advance of the previous puncture, but within the area already anesthetized. In this way, only the first puncture is felt. When the line of incision has been infiltrated in this manner through-

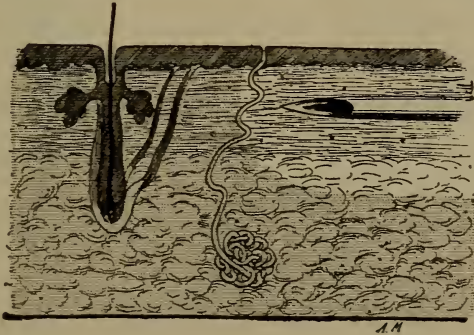


FIG. 7.—Local anesthesia; the needle does not penetrate the whole thickness of skin; "intra-dermic" injection. (Veau.)

out its entire length, it will be completely insensitive after a wait of one to two minutes. The width of the zone of anesthesia will depend upon the rate of movement of the needle through the skin (Figs. 8, 9). It need hardly be said that the needle and solution must always be sterile. It is better to pour the solution out into a sterile

dish or glass, rather than to aspirate it from the bottle. The air must be forced out before the needle is introduced; care must be taken not to throw the injection into a vein.

When an area, rather than a line, is to be infiltrated, as in case some dissection is anticipated, Schleich's method is better, in which the needle is plunged directly into the tissues and a sufficient quan-

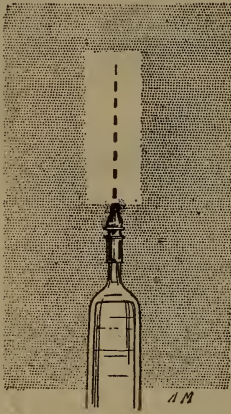


FIG. 8.—Local anesthesia; the zone of infiltration is narrow when the needle is pushed forward and emptied rapidly. (Veau.)




FIG. 9.—Local anesthesia; the zone is broad when the needle is introduced slowly. (Veau.)

tity of the solution discharged to raise a wheal. The needle is then reintroduced alongside the wheal for another injection. The anesthesia may be renewed from time to time during the operation.

Schleich's formula is as follows:

NO. 1, STRONG.

Cocain. hydrochlor.,	gr. iii.
Morphin. hydrochlor.,	gr. ⅔.
Sodii chloridi.,	gr. iii.
Aq. destillat.,	℥ iii, ℥ iiss.

NO. 2, NORMAL.

Cocain. hydrochlor.,	gr. iss.
Morphin. hydrochlor.,	gr. ⅔.
Sodii chloridi.,	gr. iii.
Aq. destillat.,	℥ iiiss.

NO. 3, WEAK.

Cocain. hydrochlor.,	gr. $\frac{1}{6}$.
Morphin. hydrochlor.,	gr. $1\frac{1}{2}$.
Sodii chloridi.,	gr. iii.
Aq. destillat.,	\mathfrak{z} iiiss.

Two or three drops of a 50 per cent. solution of carbolic acid may be added to preserve. The solution must be kept cool. Twenty-five syringefuls of Number 1, fifty syringefuls of Number 2, and 500 of Number 3, may be used without danger. *Novocaine* in $\frac{1}{2}$ per cent. solutions is, we think, even better than Schleich's solu-

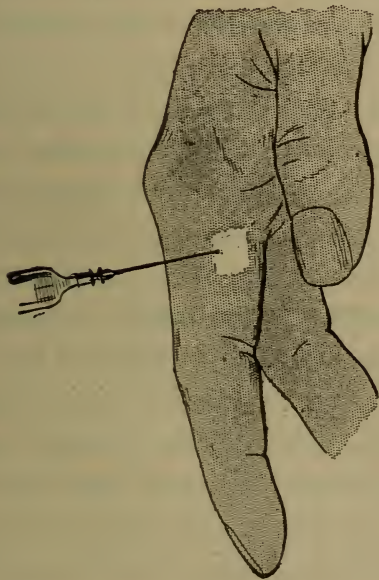


FIG. 10.—The finger may be anesthetized by a circular injection at its base. (Veau.)

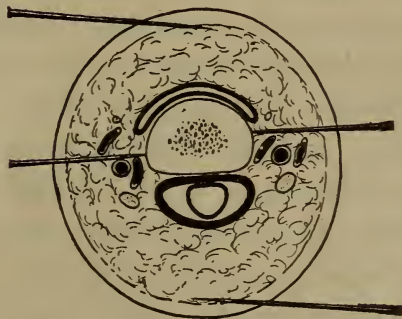


FIG. 11.—Complete anesthesia of finger induced by deep injections on each side. The upper and lower needle represent the primary circular injections. (Veau.)

tion, though in equal quantities slightly more dangerous. However, smaller quantities are required.

The patient should not be permitted to sit up during the anesthesia if cocaine is used, for it exposes him to the risk of heart failure. It is safer to keep him recumbent for a half hour or so after the operation.

If a finger or toe is to be amputated, first make an anesthetic ring involving the skin only (Fig. 10), and follow this with two deep lateral injections to obtund the main nerve trunks (Fig. 11).

SPINAL ANESTHESIA

Spinal anesthesia with stovaine can only very rarely be of use to the general practitioner in emergency work, although it is of value under certain circumstances. It is of special use in operations involving the anal and perineal regions. By this method the heart and lungs are not dangerously affected. It is a solace to those patients whose dread of a general anesthesia is greater than their dread of death, and who will refuse operations of absolute necessity rather than take ether or chloroform. The most definite contra-indication is uncertainty of asepsis, since the chief danger of the procedure is meningitis. It should not be used in the young, in advanced arterio-sclerosis, in cases of septicemia, or central nervous disease. The average duration of the analgesia thus produced is one hour. The effects are fairly uniform; the chief after-effects are headache and nausea. One of the author's patients, operated for hernia under spinal anesthesia complained for several months of loss of sensation in the penis and rectum, though not materially interfering with the functions of either. The preparation employed by the author is that of Chaput: stovaine, 10 gr.; sodii chloridi, 10 gr.; distilled water, 1 c.c. This is put up in hermetically sealed ampoules, each containing 1 c.c. of the solution, which is sufficient for an injection. Bier regards cocaine as the most dangerous and tropacocaine the safest, and this latter he employs in doses of $\frac{3}{4}$ to 1 grain. The syringe employed must be easily sterilized and with a capacity of at least 2 c.c. A long platinum needle is best. A special glass syringe with needle for this injection can be readily secured.

Technic.—The patient's back, the instruments, the solution, the operator's hands, are duly prepared. The needle is attached to the syringe and the contents of an ampoule aspirated and the needle detached. The patient sits bending forward to make the lumbar spines more prominent and to enlarge the intervertebral foramen which is to be traversed by the needle. Locate the iliac crests and mark their position with the finger nails. The line connecting the highest points of the iliac crests intersects the fourth lumbar spine the tip of which is next to be located in the middle line. The tip of

the next spine above the third is now marked and between these two points the puncture is made. Hold the left index finger on the third lumbar spine. Hold the unattached needle in the right hand, and enter its point just below the third lumbar spine a little to the right of the middle line, and push it slightly upward and inward at an angle sufficient to meet the spinal membranes in the middle line. Pushing the needle steadily upward and inward, it can be felt to reach the resisting ligamentum subflava and, finally, the puncture of the membranes is announced by the flow of spinal fluid from the needle. Hold the finger over the outlet until the syringe can be attached; then let sufficient fluid run in the syringe to make 2 c.c.; in other words, make a mixture in the syringe containing equal parts of stovaine solution and spinal fluid. The clear spinal fluid becomes milky on meeting the anesthetic solution. Now slowly inject the mixture, and when the syringe is emptied, withdraw the needle with a rapid movement and seal the puncture with collodion. It will require no further attention.

Have the patient lie down and now prepare for the operation. In ten to fifteen minutes the anesthesia begins. The patient complains of a pricking sensation in the feet and numbness in the legs. A pinch or a pin prick will be felt but will not be painful. If the pain becomes too severe in the course of the operation, a little chloroform or ether can be employed. If the anesthetic zone does not extend high enough, incline the body slightly, head downward. During the operation the patient's face is likely to be congested and his head will throb. Afterward there is likely to be a severe headache for a little while and perhaps some nausea.

The site of puncture may be numbed with cocaine, so that the spinal injection is painless. If the point of the needle engages against the vertebra, withdraw slightly and change the direction as the judgment dictates. The most common mistake is in directing the needle too much upward. Only very rarely will one fail to reach the spinal canal if the landmarks are well defined.

Jonnesco has been the great advocate of this form of anesthesia and reports its use in 2500 cases. He believes now more than ever that unlike ether and chloroform there is no contra-indication and that it is the anesthetic of the future. (*Presse Medical*, Oct., 1913).

Murphy referring to this and other of the newer forms of anesthesia wisely suggests that considering the safety and simplicity of the ether drop method the mass of the profession should await larger experiences by those who originate and are best fitted to work out the destiny of these newer forms. (Practical Medical Series, Vol. 11, 1914.)

CHAPTER IV

SUTURES; METHODS, AND MATERIALS

Sutures are applied for the purpose of maintaining the coaptation of divided structures. This is necessary to facilitate repair and restore function. Suturing serves the additional purpose of checking hemorrhage from the smaller vessels. There is no part of the surgeon's technic that deserves more attention than the selection and use of sutures. It is of special importance to the emergency surgeon who faces infection in every direction. His suturing, however, he may absolutely control and make aseptic, and this may be the only difference between success and failure.

Various *materials* are used, some quite commonly, others rarely and for a certain purpose; catgut, silk, silkworm-gut, silver wire, kangaroo tendon, and horsehair. The three first named will meet all the requirements of the emergency surgeon.

No material is available which does not have a certain strength and which cannot be made aseptic. For emergency work, these materials must be already prepared. The creation of a proper suture from the raw material is a matter of time and care.

The general practitioner will do better to buy his sutures prepared in form available for immediate use, being first assured that they come from a reliable source and are put up in a manner to keep them sterile. Much suture material on the market has neither of these qualifications.

Silk has the advantage of lending itself to emergency sterilization by boiling and immersion in an antiseptic solution, nor is it readily contaminated when once sterile; but it should not be boiled in soda solution, which makes it brittle. It has the disadvantage of not being absorbable. It may be used in buried sutures, but its usefulness in that respect grows more and more limited as the art of sterilization and preservation of catgut improves. It may be

used in interrupted skin sutures, suture of nerves, of tendon, and of the *intestine*, but muscular tissues do not tolerate it.

Catgut is the ideal material for the buried suture. The chromicized gut has ample strength and is so prepared as to resist absorption in a certain tissue for an approximate time; but it should be remembered that occasionally chromicized gut becomes practically unabsorbable and, acting as a foreign body, gives rise to persistent sinuses. With a little attention to this detail, a suture may be selected which will resist absorption until repair is complete. Plain catgut can be used in those tissues only which rapidly unite. It is ideal for suturing the peritoneum and for ligating vessels except the very large ones. It is very easily contaminated. Where there is pus it should never be used as a buried suture. The three qualities which the catgut suture must possess are: sterility, tensile strength, and absorbability. If a certain brand of catgut produces stitch-abscess persistently; if, properly used, it still breaks inopportunately; if it refuses to be absorbed, then there is something wrong with its manufacture. The occasional surgeon lacking opportunity to test all the brands, must therefore fall back upon the manufacturer's reputation and guarantee. Absorption of catgut occurs in this manner: at first the fibers untwirl and grow loose and finally become pulpy at which stage the suture has no tensile strength and is a foreign body which is gradually replaced by connective tissue, a process which is sometimes exceedingly slow. Even sterile catgut once degenerated into a gelatinous compound becomes a nidus for bacterial growth. Absorbability is therefore as important as sterility.

Watery solutions and certain chemicals as bichloride render catgut brittle and weak.

Silkworm-gut is very strong, non-elastic, non-absorbable, readily sterilized, and is much employed where the wound is large and deep and the tissues tend strongly to spread apart. Most surgeons employ it to suture the skin and fascia after laparotomy. It should be kept in various sizes.

The *pagenstecher celluloid linen* is in high favor with some surgeons; it is more flexible than silkworm-gut and absorbs moisture without softening.

The methods of suturing adapted to emergency surgery are the *interrupted suture* and the *continuous suture*. Others occasionally employed in general surgery are the quilled, the quilted (Fig. 12), the twisted, and the button sutures.

The **continuous suture** is used in aseptic wounds only. Therefore, accidental wounds will only, on rare occasions, permit its employment. It has the advantage of being very rapidly applied, but is less sure than the interrupted suture. A little practice is essential, for it is not altogether easy. Its success depends largely upon the assistant.

This is the mode of making the continuous suture: Commence by passing the suture at the upper angle of the wound.

Make three successive knots. Two are sufficient for catgut. The short thread is caught in forceps and retained till the suture is completed, at which time it is cut off close to the knot (Fig. 13).

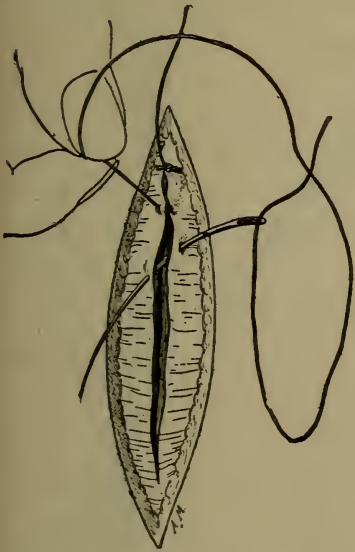


FIG. 13.—Method of making a continuous suture. Assistant holding the suture tight while the needle is passed again. (Veau.)

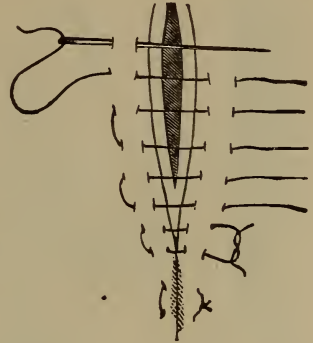


FIG. 12.—The quilted suture. (Moullin.)

The needle traverses, successively and obliquely, first the one lip of the wound and then the other; each time the assistant seizes the thread at the point of emergence, and holds it tightly until the surgeon makes a new point of emergence, when the assistant takes a new hold. In this manner, the tension of the suture is made absolutely uniform.

The *mode of arrest* of the continuous suture is important. In making the terminal knot, the suture must not be allowed to relax. To accomplish this, the surgeon slips the index finger in the last loop instead of pulling the thread all the way through, as was done with all the others. Traction with this finger holds the line of suture tight while the terminal thread on the one side is knotted three times with this loop on the other side (Figs. 14, 15).




FIG. 14.—Completing the continuous suture; holding the suture tight with finger through loop while getting ready to tie. (Veau.)




FIG. 15.—Method of tying completed continuous suture. (Veau.)




FIG. 16.—Continuous suture interrupted in its course (Hartmann.)

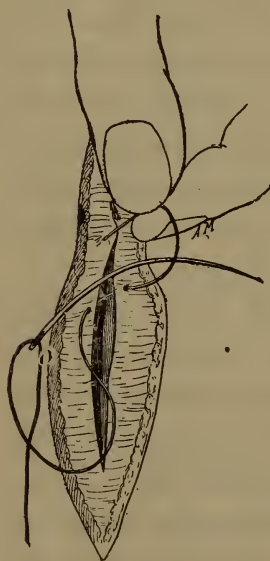


FIG. 17.—Method of interrupting the continuous suture in its course. Needle passed back under last loop. (Veau.)




FIG. 18.—The needle has been passed through the loop which is drawn back under tight and the suture proceeds as before. (Veau.)

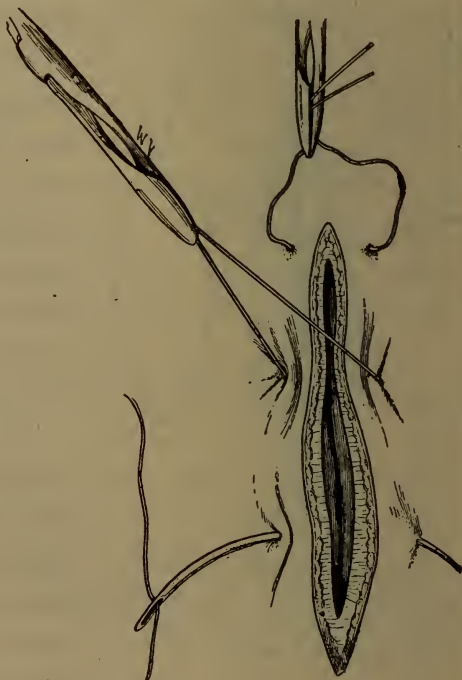


FIG. 19.—Method of passing deep interrupted sutures. (Veau.)

If the continuous suture is long, its stability is insured by crossing the threads at the middle of the line of suture (Fig. 16). The suture is thus interrupted at its middle in this manner: the needle is



FIG. 20.—Tying interrupted sutures. Forceps everting lips of wound to secure coaptation. (*Veau*).



FIG. 21.—Method of passing superficial sutures. (*Veau*.)

simply passed back under the last loop, at the time care being taken that the suture does not slip. The succeeding steps are the same as before (Figs. 17, 18). The suture completed, the loose ends are cut off close to the knot.

The **interrupted suture** is generally employed in suturing the skin, and may be of silk, silkworm-gut, silver, etc. It must not be absorbable. These sutures may be placed deeply or superficially, in the one case where there is much tension, in the other for mere approximation. The deep sutures are placed two or three centimeters apart.

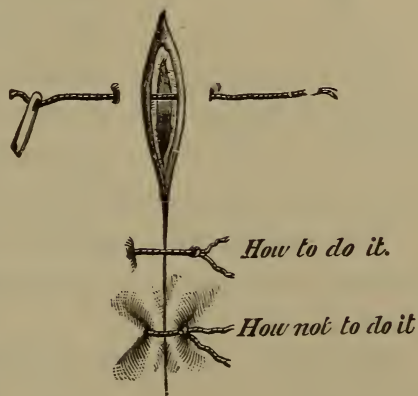


FIG. 22.—Sutures must not be tied too tight. (*Moullin*.)

The needle is entered one centimeter from the edge and emerges the same distance from the other side. The thread is concealed

through most of its extent (Fig. 19). None is tied until all are passed. The lips of the wound are brought together as the knots are tied (Fig. 20).

A few superficial catgut sutures may be necessary if the deep sutures do not completely approximate. They are passed through the thickness of the skin alone and very close to the edge of the wound (Fig. 21).

No knot should be drawn too tight. It may interrupt the circulation and defeat repair. The knot should be made to one side of, and not over the wound (Fig. 22).

If all goes well, the sutures *may be removed* toward the eighth day. Remaining too long, they favor infection.

Methods of Removing Sutures.—Seize the loop with a dissecting forceps held in the left hand. With a pointed scissors divide the thread close to the skin, being careful not to cut between the knot and the forceps, else one will be trying to pull the knot through the skin.

Suppose, in spite of care, *infection occurs*. The temperature reaches $100\frac{1}{2}^{\circ}$ on the following day. On the second day following, it is a little higher. Upon removal of the dressing, the skin around the wound is found to be reddened and swollen. Remove two or three of the middle sutures at once. Secure drainage and use a wet dressing. This will usually

check the infective process and pus formation.

The *subcuticular suture* is of great service in aseptic operative wounds, wherever it is especially desired to *prevent a scar*. It is made in this manner:

Introduce a small needle threaded with No. 1 catgut, $\frac{1}{4}$ inch above the upper angle of the wound, and let it penetrate the skin and emerge exactly at the upper angle. It next penetrates the face of the skin incision, taking a bite first on one side and then on the other exactly opposite (Fig. 23). At the end, the needle traverses the skin at the lower angle of the wound in the same

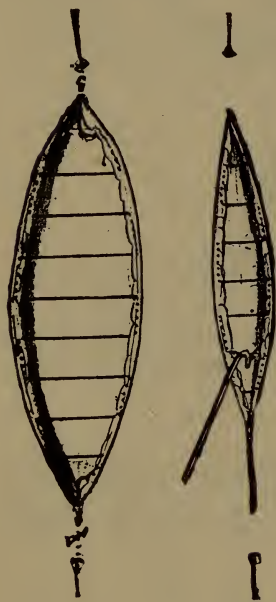


FIG. 23.

FIG. 24.

The subcuticular suture;
method of passing and
tightening. (Veau.)

manner as it entered at the upper angle; the sutures are then tightened (Fig. 24) until the edges of the wound are exactly coapted. The ends are secured from slipping either by knotting or by pasting them down with collodion or adhesive plaster. If the thread is not absorbed, it may be removed about the sixth day by clipping one end close to the skin and then gently drawing it from the other end.

Cannaday uses pagenstecher linen and after starting the suture secures the loose end by a half bow knot. The terminal thread is secured in the same way and slipping or loosening is thus prevented.

CHAPTER V

DRAINAGE

Drainage may justly be regarded as a matter of antisepsis. It prevents sepsis by creating a current which moves away from the wound, and by depriving the bacteria of their chief pabulum—the wound exudates. Drainage facilitates repair by relieving tension. In the same manner it relieves pain. But when these points are made the whole is said, for drainage is by no means an unmixed good. On the contrary, it is a necessary evil and for these reasons: in reality it is a foreign body; it necessitates frequent renewal of dressings; it may injure granulations; it keeps the wound open and delays healing; in the abdominal cavity it sometimes predisposes to fistula, hernia, and intestinal obstruction. Nor is the profession by any means of one mind regarding the indications and contra-indications. It is a matter in which one cannot be dogmatic. The rule of practice must of necessity vary with the patient, the operator, and the environment.

The emergency surgeon, the general practitioner, will more often drain than the hospital surgeon in formal operations. And this leads to the fundamental principles involved.

Aseptic wounds, as a rule, do not require drainage.

Infected wounds or those suspected should always be drained, for infection of any kind demands an outlet.

Accidental wounds are presumed to be infected, whereas operative wounds are presumed to be aseptic.

As an exception to the rule that aseptic wounds do not require drainage, note that those in which there is of necessity much post-operative oozing do better with temporary drainage. Examples: large amputation stumps, and breast amputations.

Suspected wounds are not drained after the third day, if infection has not made its appearance nor seems likely to develop.

Infections are drained as long as there are any discharges.

The means of drainage in emergency practice are three: tubes, gauze, and open wounds; or combinations of the three.

Rubber tubes, the larger the better in proportion to the infected cavity, are the best means of draining large cavities, and are the sole means of draining abscess cavities and large infections. They should be fenestrated, and may be improvised from rubber catheters. Wherever used, they must be cut off close to the surface and, in the case of cavities, must be anchored by suture or safety pins.

Gauze.—Plain sterile gauze, which drains by capillarity, is an efficient means of removing exudates, such as serum and blood. It has the additional advantage that in appropriate cases it may be at the same time employed for hemostasis. It has the disadvantage that it soon ceases to drain, acquires adhesions, and is painful to remove.

Tubal and capillary drainage are advantageously combined in the "gauze wick" and "cigarette drain." A "gauze wick" drain is made by splitting a tube of the required length and fitting it loosely with a strip of gauze. When the tube is carried to the bottom of the cavity, the projecting gauze is brought in contact with the oozing surface, is hemostatic, and finally may be removed without disturbing the tube. A cigarette drain acts on the same principle and is essentially a series of wick drains, one within the other. To make a "cigarette drain," take a 10-inch square of rubber tissue, cover it with four or five layers of sterile gauze, and roll the whole into a slender cylinder.

"Wick" and "cigarette" drains should be removed on the second or third day. If infection is present at that time, a tube should be substituted; a tube must be employed if infection develops later. Tubes employed in the drainage of pus cavities should be removed, cleaned, and reinserted at least every third day, and are to be shortened *pari passu* with granular repair.

As has been said, an open wound is a means of drainage, and for that reason accidental incised wounds are, as a rule, not completely sutured. Lacerated wounds not repairable need no other drainage than that afforded by the gauze dressings.

To note briefly some examples of drainage: Abscesses are always to be drained with tubes.

Acute spreading infections are to be drained with tubes.

Accidental incised wounds are to be drained with tubes, or simply by rubber tissue if the wound is small.

Operative wounds of the soft parts in emergency practice are often best drained superficially—all the layers are completely closed except the skin. A few strands of catgut between the lips of the wound will often be all that is necessary for drainage and has the advantage of requiring no change of dressing.

An empyema or purulent peritonitis must be drained with tubes.

Many thoracic and abdominal conditions are to be drained with the wick or cigarette drain. If there is no probability of infection, if there is not much oozing, do not drain at all.

In compound fractures and compound dislocations drain only the skin wound. If infection develops, deep drainage must be substituted.

Further details will be given in connection with the various operations requiring drainage.

CHAPTER VI

DRESSINGS, BANDAGES, SPLINTS

The emergency surgeon needs no great variety of dressing materials. If he has *sterile gauze* and *sterile absorbent cotton*, he can efficiently meet all the indications so far as dressings are concerned; for these materials furnish in the highest degree the properties which pertain to a good dressing. A good dressing is sterile, absorbent, and protective. It conducts the exudates away from the wound and prevents the approach of infective germs. For emergency work it is better to buy these materials already prepared and ready for instant use. But they must come from a reliable source. Even the most trustworthy products are not always aseptic. In major operations they should be re-sterilized if possible. Of course the surest way to sterilize is by steam. Still these materials exposed to the high heat in the closed oven of the kitchen stove might reasonably be expected to be germ free. *Medicated gauze* is often useful but not essential, nor so much employed as formerly. It may be improvised by dusting the plain sterile gauze with the preferred antiseptic powder at the time of dressing. For that matter all of the dressing may be improvised for temporary use from muslin, linen, or cheesecloth. Towels or sheets may be prepared by boiling for fifteen minutes in soda solution, rinsing in cold sterile water, wringing out the water, and completing the drying process on the stove. From these materials one may provide not only dressings, but compresses and sponges for the operation.

An *aseptic wound* requires that the dressing be dry; whatever slight serous oozing there may be is thus rapidly absorbed.

Septic wounds require a dressing moist with some antiseptic solution. For one thing, the moist gauze conforms better to the irregularities of a lacerated wound. Again, the antiseptic agent exerts some slight destructive effect, perhaps, upon the germ already in the

wound and is a more effective screen against those trying to get in. Moist boracic and bichloride gauze are the most commonly used. If acute sepsis is present, sterile gauze saturated with peroxide of hydrogen is to be recommended. As an antiseptic dressing Newman particularly recommends gauze saturated with subgallate of bismuth. (Lancet, June 28, 1913.)

The dressings must be *ample*. Too often an aseptic operative wound eventually becomes infected merely because not sufficiently protected. The dressings must not only be thick enough, but they must extend widely beyond the limits of the wound. It is a poor dressing, indeed, if one can lift its edges and inspect the wound.

The *frequency of redressing* is variable. In general, the fewer dressings the better. The aseptic operative wound should need but two dressings. The original dressing is removed when the sutures are taken out on the eighth to the tenth day.

The septic wound may need to be dressed daily. A wound probably infected but not septic, one in which a drainage tube was used, will need to be dressed on the second to the fifth day, when the drainage tube is removed. The frequency of dressing thereafter will depend upon the degree of sepsis. In changing the dressing of a sterile wound, every precaution must be taken against infection. Many a fine operative result is spoiled by carelessness in changing the dressing. The hands, the solutions, the instruments, must be prepared.

It is good practice in the case of any kind of wound to change the dressing whenever soiled, for sterile exudates may become good culture media. One may, however, follow Senn's suggestion, dusting the saturated area with boro-salicylic acid or other antiseptic powder and covering with an additional layer of cotton and bandage.

Pain or rise of temperature after the first twenty-four hours is always an indication to change the dressing and inspect the wound. A loosened dressing calls for renewal. The dressing that slips or rubs is a very poor one. When the dressings are adherent to the wound surface, they are to be saturated with warm sterile water or with peroxide of hydrogen. The latter is excellent when the dressing contains dried blood. When changing the dressings any undue movement of the parts must be avoided. The principles of support

and functional rest are not to be neglected even for the short time the dressing is off.

BANDAGES

The gauze roller is porous, absorbent, protective, and therefore a part of the dressing. The wound is covered with gauze, the gauze is amply covered with absorbent cotton, and the whole retained by a smooth bandage, uniformly compressive. Bandaging, as the older doctors knew it, is almost a lost art, for the gauze roller is accommo-

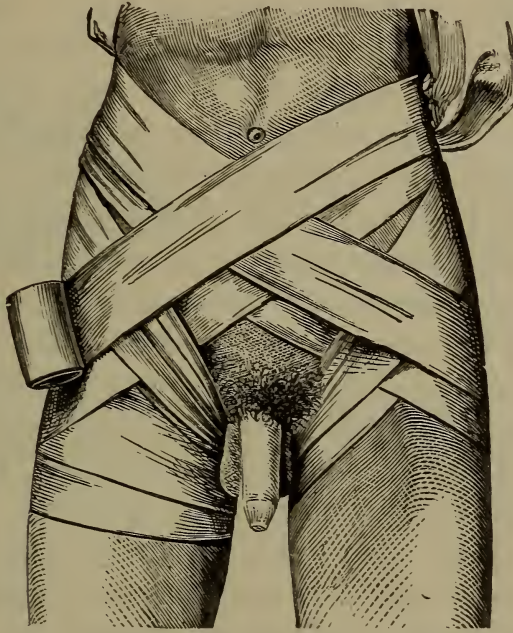


FIG. 25.—Double spicæ of groin. (Heath.)

dating and adhesive plaster convenient. One may give a dressing the appearance of stability without its being in reality efficient. The bandage must be so applied that it will not slip and will remain closed at either end. It must extend well beyond the limits of the subjacent dressing, and in the case of the limbs must reach beyond the next joint above. For example: a dressing of the foot must extend above the ankle; of the leg, above the knee; of the forearm, above the elbow. In the region of the groin a double spica should be employed, extending well up over the abdomen, and down over the thighs (Fig. 25).

A bandage of the neck, that it may not slip, must include the head and shoulder.

The dressings of the abdomen and thorax are best held in place by wide bands of flannel firmly applied and secured by safety pins, and whose edges are held down by suspenders and perineal strips.

To apply a bandage to a limb, for example: stand in front of the patient. That the bandage may unroll more freely, place the free end of the bandage in contact with the dressing by its outer surface, and hold the roller to the outside of the limb—in the right hand for the left limb, in the left hand for the right limb. Each turn should overlap about one-half the previous turn. To maintain uniform pressure in spite of the limb's change in contour as the bandage progresses certain modifications of the ordinary spiral or circular turns are necessary—the “spiral reverse” and “figure-of-eight” are to be employed. The “spiral reverse” is used where the circumference rapidly changes, as in approaching the calf of the leg; if it is not made, one edge of the bandage is tight and the other edge loose. To make the reverse, the bandage is slackened when the outer side of the limb is reached and a half rotation is made, by a twist of the wrist. The beginner is often observed to make a complete turn of the bandage instead of a half turn. This tightens the bandage, but does not give uniform compression. In making the turn, the thumb of one hand steadies the lower edge of the bandage, while the other hand makes the half turn mentioned. The reverse should always be made in the same vertical line and should, if practical, correspond to the wound, in order to give it the advantage of the extra thicknesses. The bandage is then continued on around the leg until the outside is again reached when the reverse is repeated. The “figure-of-eight,” the second means of taking up the slack, is most useful in the region of the joints, and at the calf.

Bandage for the Foot.—(Fig. 26.) Begin near the toes with spiral turns, reversed as the ankle is neared. Encircle the ankle with the “figure-of-eight” turns and continue the spiral turns up the leg. If it is desired to cover the heel, the first turn should cross the upper part of the heel and over the front of the joint; the second turn

overlaps the lower half of the first; the third turn overlaps the upper half of the first. The roller on the third turn reaches the

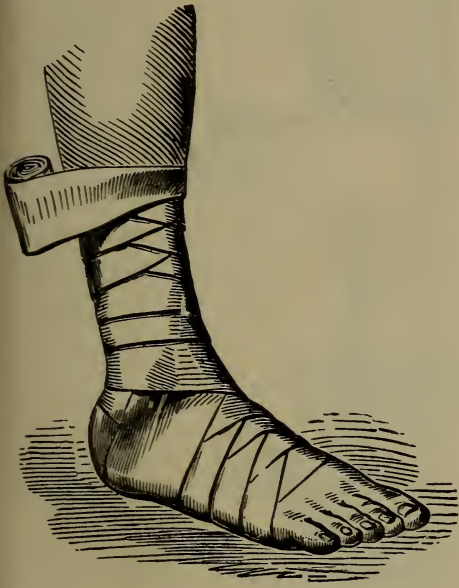


FIG. 26.—Bandage of foot. (Heath.)

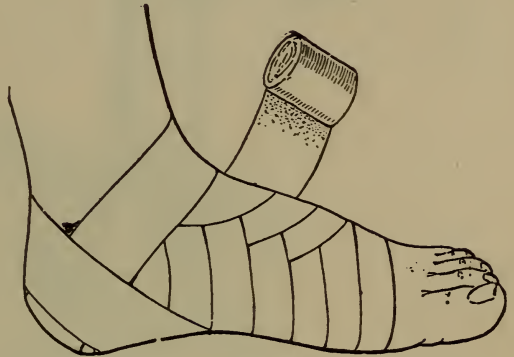

FIG. 27.—Bandage of foot. Heel covered. (Heath.)

dorsum of the foot, and is carried obliquely across toward the little toe and the foot is covered by spiral turns which progress upward, or it may be applied as indicated in Fig. 27. The spica of the foot is

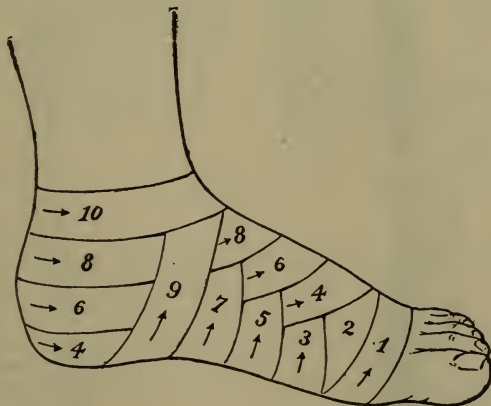


FIG. 28.—Spica of foot. (Stewart.)

indicated by Fig. 28. If it is desired to cover the toes, back and forth folds extending from in front of the ankle to a corresponding point

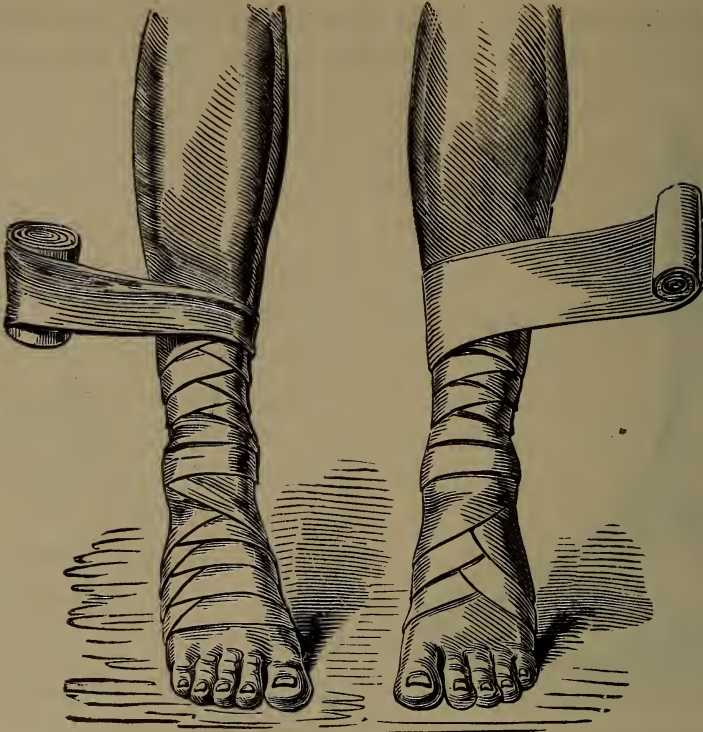
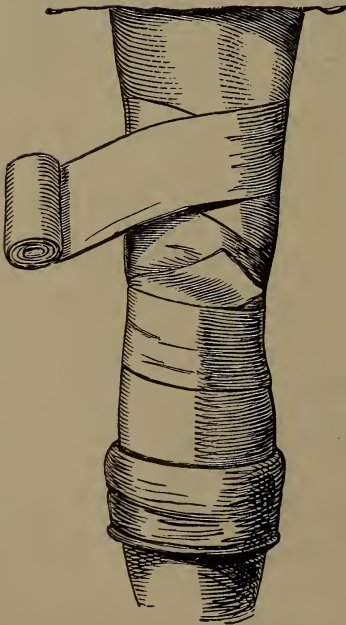
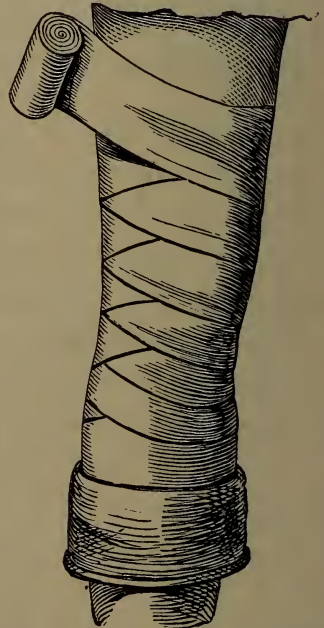

FIG. 29.

FIG. 30.

Bandage of leg. (*Heath.*)FIG. 31.—Figure of "8" of knee.
(*Heath.*)FIG. 32.—Bandage of knee.
Spiral reverse. (*Heath.*)

on the sole may be run on and held in place by additional circular turns about the foot.

Bandage for the Leg.—Begin above the ankle with spiral turns, progress upward and, as the calf is approached, use the reverse (Fig. 29); or a “figure-of-eight” may be employed throughout (Fig. 30), but the latter does not fit so well about the calf as the former.

Bandage for the Knee.—This may be a continuation of the leg bandage or may include the knee alone; in either case it is a “figure-of-eight” running from below the patella around the outer side of

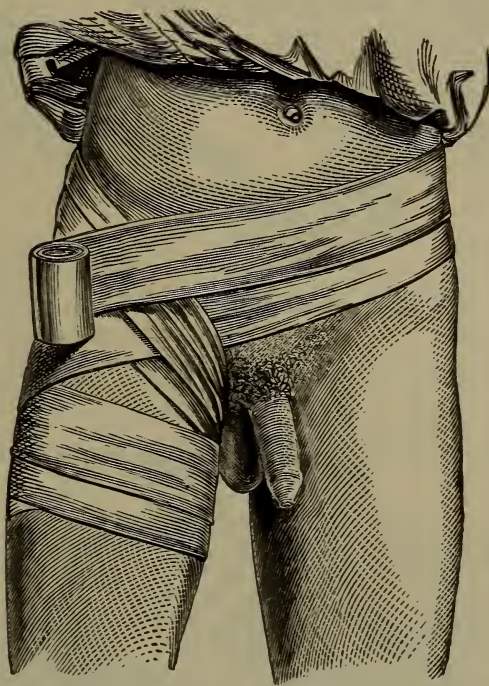


FIG. 33.—Spica of groin. (Heath.)

the knee, across and up behind the knee to the inner condyle. Now make circular turns about the thigh. From the inner condyle, cross the knee obliquely downward and outward to the head of the fibula; make a circular turn about the leg below the knee, and, when the patellar line is reached, begin over again the “figure-of-eight,” lapping the preceding one (Figs. 31, 32).

Bandage for the Groin.—Begin at the inner end of the groin and carry the roller upward and outward to the iliac crest, around to the



FIG. 34.—Bandage for breast. (*Heath.*)

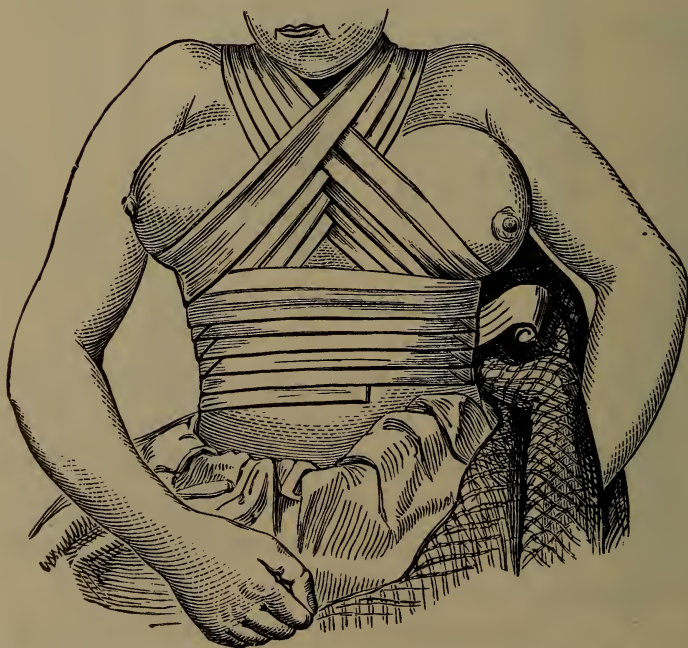


FIG. 35.—Bandage for both breasts (*Heath.*)

opposite crest, obliquely across the belly toward the pubes, around the thigh to the starting-point. Repeat these turns as often as necessary, each overlapping the preceding (Fig. 33).

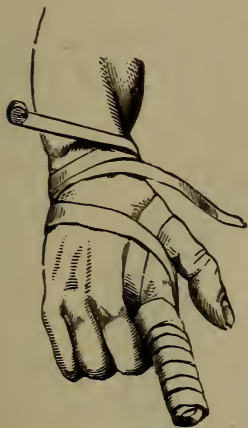

FIG. 36.—Finger bandage.
(Heath.)

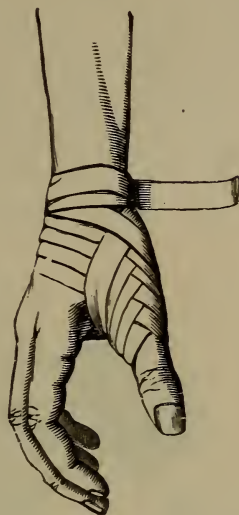


FIG. 37.—Spica of the thumb.
(Heath.)

The Double Spica.—The right groin is bandaged as described above. When the roller, carried about the body, reaches the left side of the pelvis, it leaves the original track, follows the left groin

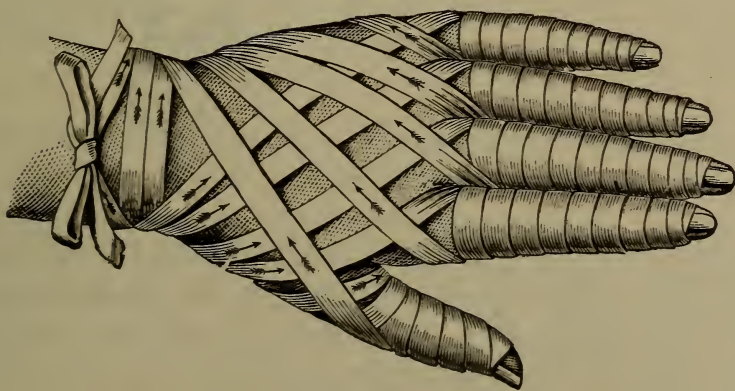


FIG. 38.—Bandage for all the fingers. (Heath.)

downward and thence around the thigh; is then carried across the belly and around the body to the right groin again. These bandages may be applied with the patient standing or with the pelvis

on the Volkman rest. For the perineum and pelvis, one may use the "St. Andrew's cross," which, after a turn about the body, crosses over the left groin, behind the left thigh just below the nates, obliquely upward across the perineum, over the right groin toward the right iliac spine. It then passes around the left iliac spine and down the left groin across the perineum.

Bandage for the Breast.—Begin with two or three turns about the chest; carry the roller across the breast to the sound side; next

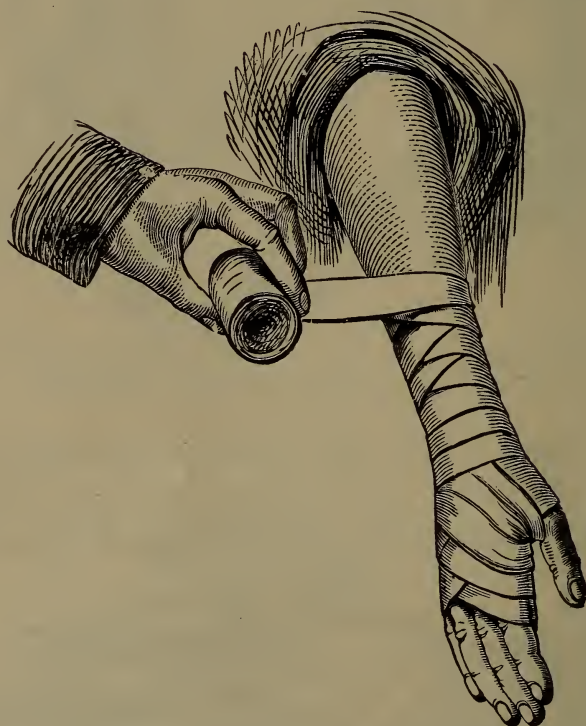


FIG. 39.—Bandage for arm. (Heath.)

carry it under the affected breast to the opposite shoulder; across the back to the breast again and up over the shoulder; and then around the body again (Fig. 34). Both breasts may be bandaged at the same time, carrying the turns about first one breast and then the other (Fig. 35).

Bandage for the Finger.—Begin with two or three turns about the wrist, and then carry the bandage across the dorsum of the hand and base of finger, and run it down to the tip by two or three oblique turns; bandage from the tip to the base by regular circular turns.

From the base, carry the bandage across the dorsum of the hand and around the wrist again (Fig. 36).

Bandage for the Thumb.—Begin at the ulnar side of the wrist and carry the bandage across the dorsum around the wrist for a turn or two. Next carry the roller obliquely across the dorsum of the hand and toward the radial side of the thumb, as near the tip as desired. Secure by a circular turn and then carry the roller back to, and around, the wrist again and so proceed, progressing toward the base of the thumb (Fig. 37). Bandage for all the fingers and thumb, see Fig. 38.

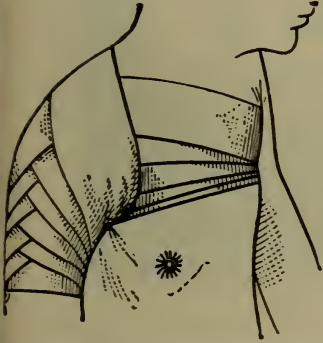

FIG. 40.—Spica for shoulder. (Heath.)



FIG. 41.—Bandage for head. (Stewart.)

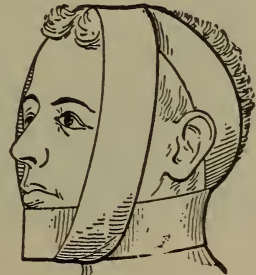

FIG. 42.—Barton's bandage. (Gould's Illust. Dict.)

Bandage for the Hand and Arm.—Begin with circular turns around the wrist and then carry a "figure-of-eight" about the wrist and hand; finish with spiral turns progressing up the arm (Fig. 39).

Spica for the Shoulder.—Begin on the arm about the insertion of the deltoid and make two or three circular turns about the arm. Next carry the roller across the shoulder, approaching the sound axilla from behind; across under the axilla and over the breast to the injured shoulder and around the arm again (Fig. 38).

Bandage for the Neck.—The shoulder and head must be included in the bandage for the neck if it is to be effective. Begin on the shoulder and carry the roller through the axilla and around the neck once or twice. Take the turn next about the neck and beneath



FIG. 43.—Capitellum. (*Heath.*)

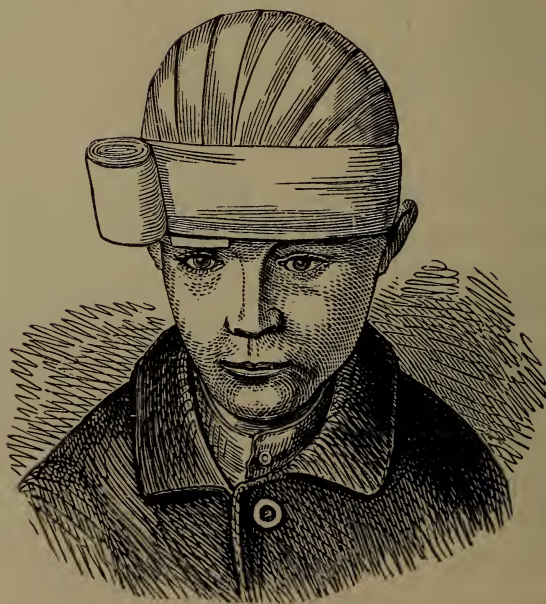

FIG. 44.—Capitellum completed. (*Heath.*)

the jaw, behind the ear on the sound side, over the top of the head, down in front of the ear on the affected side. Next carry the roller horizontally around the neck and then beneath the jaw once more; again vertically around the head; but this time it passes in front of the ear on the sound side and behind the ear on the affected side. Carry the roller now a third time beneath the jaw and, finally, from the occiput around the forehead to fix the other turns.

Bandage for the Head.—A dressing may be secured in many instances by simple turns about the forehead and occiput; but the



FIG. 45.—Showing manner in which eye is covered and the ear engaged in one slit in the bandage and the occiput in the other.

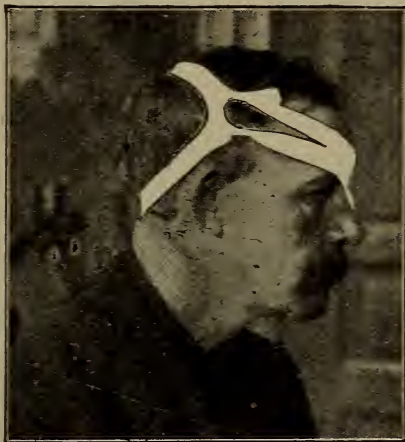

FIG. 46.—Showing sound eye free and manner of tying together the two ends of the bandage on the sound side.

bandage may be made to hold firmer if, as it approaches a certain point, it is raised in one turn and lowered in the next. It has the appearance of a spiral reverse (Fig. 41).

Barton's bandage may be used (Fig. 42). Begin at the top of the head, carry the roller beneath the chin, up to the vertex, across and to a point below the occiput. From this point, carry it forward to the chin and on to the occiput. Bring it up to the top of the head and again beneath the chin and proceed as in the beginning.

Figs. 43 and 44 represent one method of applying the recurrent or capitellum to the head.

Morley describes a useful and practical bandage for the eye (J. A. M. A., Mch. 27, 1909). Take a piece of muslin, or gauze,

long enough to go about the head and wide enough to cover the orbital region. At its center cut a round hole for the ear of the affected side and further back an oblong slit for the occiput. Trim the bandage so as to uncover the sound eye. Split the two ends and tie these tails tight enough to prevent slipping (Figs. 45, 46).

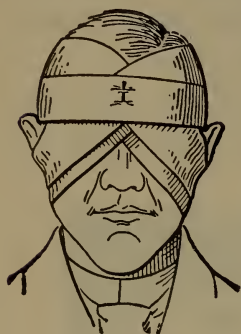

FIG. 47.—Bandage for both eyes. (Heath.)

The crossed bandage for both eyes is a figure-of-eight with circular turns about the head (Fig. 47).

Bandage for a Stump. Begin with circular spiral turns some distance up the limb. Carry the bandage back and forth over the end of the stump, and finish by more circular turns.

SPLINTS

To immobilize, to prevent muscular contraction, or to secure functional rest, splints play a large part in surgical practice. The emergency surgeon must be familiar with the principles regulating their employment and with the practical details of their use. A splint must have rigidity; it should be light. A number of materials offer these properties in varying degrees, though none are ideal perhaps, or universally applicable—wood, metal, leather, wire, cardboard, felt, plaster of Paris, silicate of potash—each has its special field of usefulness. More especially employed in emergency practice are wood, metal, and plaster.

Wooden Splints.—Wood is the material usually most available when temporary splints must be improvised. Often these splints may be used for permanent fixation, though not so much so perhaps as formerly. From soft wood—a thin pine wood—the appropriate form may be readily whittled; and, when applied, well wrapped so as to conform to the parts, furnishes a fixation at once light and rigid. The splint must be wider than the limb and long as the part to be immobilized, but not so long as to produce discomfort. The sound limb may be used as a pattern in modeling the splint. Such splints have the disadvantage that they are hard to keep in place. A number of thin wooden strips may be glued to felt, or held together by adhesive plaster, to form effective fixation in certain fractures of the humerus and thigh. On this principle the Dutch

cane splints are constructed for use in the emergencies of warfare. Gooch's splint is made from a pine board 2 feet long and 6 or 8 inches wide and $\frac{1}{4}$ inch thick, pasted on to felt and then split in strips $\frac{3}{4}$ inch wide. Before the ordinary wooden splint is applied, it should be padded with absorbent cotton 2 to 4 inches thick and wrapped with a gauze roller. The cotton should be distributed to correspond to the irregularities of the limb. The splint is molded to the limb, and held in place with adhesive strips while the roller bandage is applied.

Metal splints as ordinarily employed are scarcely available in emergency practice. These materials cannot, as a rule, be readily worked into shape; but, on the other hand, if ready-made, are likely not to fit. However, in case of necessity, a splint could be cut from tin or from wire gauze. Wire gauze, indeed, forms part of the outfit of the military emergency bag. It can be patterned, molded and bandaged to the part; the cut edges should be turned over or covered with cloth.

Plaster.—Plaster of Paris, on the whole, is the material best adapted to the exigencies of emergency practice. It is not too bulky, cheap, easily obtained, and readily prepared; once applied, it is not unduly heavy and furnishes a firm support. It has the special advantage that it can be molded to the part; the disadvantage, that it may be difficult to remove when applied as a roller bandage. Plaster is spoiled by exposure. One should buy a good quality and keep it dry. Old plaster should be baked before using. Plaster may be applied on a roller bandage or on strips to make a molded splint. The splint form is better when the parts must be frequently inspected or when much swelling is anticipated. The plaster roller may be prepared from the ordinary gauze roller or from crinoline. The latter is perhaps the best. The rollers should be about 4 yards in length; 2, 3, and $5\frac{1}{2}$ inches in width. *To prepare the plaster bandage*, pour the plaster on a table or in a wide shallow basin. Start the loose end of the roller through the plaster, rubbing it in thoroughly, and as fast as it is impregnated have the assistant re-roll it (Fig. 48). These bandages will keep indefinitely in an airtight container. Prepared in this way they are much more satis-

factory than if bought ready-made—and certainly much less expensive.

[Method of Applying.]—When the limb is ready, washed, and covered with glazed cotton or stockinet, the plaster roller is set in a pan of warm water deep enough to cover it. When the bubbles cease to rise, it is ready to apply. Seizing it at each end, wring it gently. Begin by making a few oblique turns at first to secure the dressing or cotton, and then cover the limb by systematic circular turns, progressing from below upward, each turn overlapping the preceding one. The “reverse” must not be used. A little loose plaster may be spread on and moistened to give a smooth and even finish. The limb must be supported and the extension maintained



FIG. 48.—Method of rolling plaster bandage.

until the plaster has hardened. A little salt added to the water hastens the process. If there is danger of swelling, or if the limb cannot be frequently inspected, it is better to split the case before leaving the patient. Sometimes it is quite a task to split a plaster cast after it is thoroughly hardened. The labor may be greatly lessened by the use of simple syrup, a groove being first cut with plaster knife or saw; if the groove is kept filled with syrup while the cutting is in progress, one will get through the plaster rapidly.

Plaster splints are made by cutting several thicknesses of crinoline, appropriate to the shape of the limb. It is saturated with plaster, each layer separately, dipped in warm water until well soaked, then applied and molded to the limb. Fix it with circular turns of a muslin bandage. The second splint, if needed, is then applied and fixed by a second series of circular turns. The splints

may be fixed by a plaster roller if desired. A still better way is to fold the crinoline into the desired number of layers and cut them all at once from the pattern determined. Warm water and a basin are next provided and plaster is slowly sifted into the water, until it ceases to bubble; when it is mixed, until it has the consistency of cream. The cloth is then dipped in and saturated. When well soaked, the excess of plaster is pressed out and the splint is ready to apply.

The Bavarian plaster splint is particularly useful in immobilizing the leg. Cut two pieces of flannel long enough to extend from the upper end of the thigh under the heel to the ball of the toes, a few inches wider than the greatest girth of the limb. Stitch these pieces together along the middle line for the length of the leg. Put the splint thus formed under the limb, with the seam exactly in the middle; bring the inner half around, fitting it to the leg, the dorsum and sole of the foot, like a stocking. Smear this stocking with liquid plaster and, before it sets, turn the outer half over the plaster and mold it and adjust the end pieces to the sole. The splint can be easily removed, as the seam along the back acts as a perfect hinge.

CHAPTER VII

SHOCK

Shock is a constitutional state characterized by lowered blood pressure, due to vaso-motor paralysis.

In practice, the term "shock" includes the complex of symptoms arising from the vaso-motor paralysis, hemorrhage, mechanical interferences with circulation and respiration, and beginning infection.

It may not be possible to analyze the symptoms, determining the part played by each of these various conditions in a given case, nor is it necessary to do so.

Nevertheless, the proper understanding of shock as a separate entity is essential in emergency surgery next to skill in hemostasis.

Peripheral impulses reach the automatic centers controlling blood pressure and overwhelm them. Such is the commonly accepted view of shock production.

Lucy Waite, after reviewing the subject from every standpoint, concludes that, according to our present light, we must consider it primarily a disturbance of the great sympathetic nervous system; secondarily, the vascular system, resulting in vaso-motor paresis and dilatation of the right side of the heart and the large vessels; in natural sequence derangement of the solar plexus and the automatic visceral ganglia follows; finally there is suppression of visceral activity—of rhythm, absorption, and secretion. (Medical Record, Sept. 8, 1906.)

This is practically in accord with the results of recent experiments of Janeway and Ewing. "The loss of vaso-motor control is never due to ocopnia or central nervous exhaustion in their opinion but is rather a matter of inhibition. (Annals Surgery, Feb., 1914.)

The *symptoms* of shock vary in degree with its severity and are chiefly incident to the lowered blood pressure: thirst, pallor, subnor-

mal temperature, shallow breathing, frequent sighing or yawning, rapid pulse, relaxed sphincters, faintness, nausea or vomiting, and unconsciousness.

These may appear in their slightest manifestations, or in such forms as usher in death. As Waite says, syncope causing always a cerebral anemia is practically identical with the last manifestations of overwhelming shock.

Whether shock will be mild, severe, or fatal depends upon the state of the individual, the character and continuance of trauma, the means of injury, and the tissues wounded. Age, sex, general health, and mental state are factors to be taken into consideration.

Crushing injuries with mangled nerves sending their constant signals to the disturbed vaso-motor centers furnish conditions favorable to fatal shock. Railroad accidents are typical of such as produce the severest symptoms of shock, for fright and violent emotions even without injury may be followed by vaso-motor paralysis.

Certain tissues resent insult more than others. Those which line the body cavities are most sensitive with respect to injury; the peritoneum, the pleura, the dura, and the synovial membranes of the large joints. This is true whether the trauma be accidental or operative.

The *diagnosis* of shock as distinct from hemorrhage and collapse cannot always be made with certainty. As Waite says, the diagnosis of shock is simply the recognition of the clinical phenomena, for we have no chemical or pathological findings to aid us.

In many instances it may be differentiated from collapse by the history of the case.

In collapse the heart action is slow and feeble, whereas in shock it is rapid and feeble.

In hemorrhage the symptoms may be rapidly progressive, but in uncomplicated shock the symptoms are stationary or improve. Observe, therefore, the action of the pulse and the movement of the temperature. In hemorrhage the temperature falls and the pulse rate increases. In shock the pulse becomes gradually slower; the temperature gradually rises.

The *prognosis* in the severe cases will be for a little time decidedly uncertain. The sufferer from traumatic shock may give the doctor

an erroneous notion of the gravity of the case, unless the condition of the pulse is carefully noted; for he may complain of no pain, is cheerful in the face of his calamity, discusses the need of operative measures quite coolly and directs the management of his case generally. He seems quite rational, and yet it often happens that after recovery he has no recollection of what he said or did or felt. It is probable, in the presence of grave injury that, if the pulse is thready and still failing, the patient does not know what he is talking about, however lucid his expression may appear. A little later he may be in active delirium. Any increase, not too long delayed, in the blood pressure and the attendant improvement, is a cause for hope. It may take many hours before the reaction is complete.

Any aggravation of the symptoms after reaction is once under way never indicates a return of the shock, but points to hemorrhage or infection.

It is true that, as a rule, when once improvement begins the outlook is favorable, but the prognosis must always be guarded in the case of the elderly.

An old flagman was brought to the City Hospital with both limbs crushed off, having fallen under a passing engine. He was in full shock and had lost some blood from a scalp wound. He was almost pulseless and yet his mind seemed clear. His condition precluded operation. The mangled tissues were trimmed and carefully cleansed and wrapped in moist antiseptic compress until such time as formal amputation might be undertaken. Under the treatment for shock he gradually improved. His circulation and respiration grew stronger, but not sufficiently so as to favor operation. At the end of twenty-four hours he began all at once to grow weaker, fell into a stupor, and in a few hours died. If the amputation had been undertaken, he would have died on the table, and thus another fatality would have been charged to active intervention.

The *treatment* of shock has been the subject of much discussion in recent years. The most diverse opinions exist and the most diverse methods have been proposed, but we have learned from the experience of Crile and others that it is as important to know what *not* to do as what to do.

The whole list of cardiac and spinal stimulants so commonly in-

jected hastily, indiscriminately and collectively, are shown to be not only useless, but distinctly harmful. The patient doubtless often recovers not on account of, but in spite of, such treatment.

In ordinary cases, *these directions* are sufficient to be borne in mind: disturb the patient as little as possible; lower the head; keep the body warm; attempt no operative measures until the symptoms are improved, unless it be to check hemorrhage, or to amputate in certain crushing injuries.

Adrenalin chloride is the most generally useful remedy to raise blood pressure in shock pure and simple, and given hypodermically or intravenously, it very seldom completely fails.

Crile was enabled by means of intravenous infusion of adrenalin and salt solution, combined with artificial respiration and thoracic pressure, to arouse a human heart after it had ceased to beat for nine minutes, and its action was thus sustained for one-half hour.

It must be given in small doses, frequently repeated. The effects are powerful, but fleeting.

Hypodermically, give 5 to 15 minims of the 1-1000 adrenalin solution and repeat every twenty or thirty minutes.

Intravenous infusion is even more satisfactory and certain. Give continuous infusion of adrenalin salt solution until there are signs of reaction. One teaspoonful of 1-1000 adrenalin added to one quart of normal salt solution is of sufficient strength.

Normal salt solution alone is effective within certain limits, but finds its greatest field of usefulness in shock coexistent with hemorrhage. In shock uncomplicated by extensive loss of blood, the saline solution must be used sparingly, perhaps better by enema or hypodermoclysis; used in large quantities intravenously, it may eventually defeat the end for which it is employed by acting as a mechanical obstruction to respiration. For it must be remembered that under such circumstances it finds its way into the thoracic and abdominal tissues and interferes with the movements of the diaphragm and ribs by its mere presence. According to Crile, 320 c.c. per kilo of body weight led to such accumulation of fluid in the splanchnic area as to embarrass respiration.

Do not give, then, more than a pint of normal salt solution injected slowly, in uncomplicated shock. (For technic of intravenous

infusion, see page 59). Murphy uses sodium bicarbonate 1 dram to 1½ pints of hot water as a proctoclysis, repeating the dose every three to five hours.

Crile's pneumatic suit seems to be entirely trustworthy as a means of raising blood pressure; but, of course, cannot be used in the shock occurring in emergency practice.

The prevention of shock is always something to be considered in operative work. Morphine, ¼ grain hypodermically, before the anesthesia, is a real aid. "Blocking" the nerves by cocaine injections above the site of operation is likewise advantageous and is recommended by Cushing and Crile. The nerve may be exposed in its course under local anesthesia and in turn injected.

In abdominal work the *viscera must be handled with care*; for, as Byron Robinson has shown, shock from this source is directly proportionate to the amount of manipulation or traction upon the viscera.

CHAPTER VIII

HEMORRHAGE

DEFINITIONS.—1. *Arterial hemorrhage* is due to wounds of arteries and is characterized by spurting and the bright red color.

2. *Venous hemorrhage* is due to wounds of the veins and is characterized by dark color and steady flow.

3. *Capillary hemorrhage* is characterized by persistent oozing and spontaneous arrest.

4. *Parenchymatous hemorrhage* is due to wounds of those organs and tissues in which the small arteries terminate directly in veins; no capillaries intervening, as in the erectile tissues.

5. *Primary hemorrhage* occurs immediately after the injury.

6. *Intermediate or reactionary hemorrhage* occurs within twenty-four hours and is due to the release of clots or the slipping of the ligature.

7. *Secondary hemorrhage* occurs after twenty-four hours, before the cicatrization of the wound, and is usually due to sloughing or suppuration or the too rapid absorption of the catgut ligature.

8. *Internal or concealed hemorrhage* occurs when the blood is emptied into one of the large cavities; abdomen, thorax or cranium.

CONSTITUTIONAL EFFECTS OF HEMORRHAGE

The constitutional effects of hemorrhage vary with the amount and the rapidity of the loss of blood. Thus a comparatively small amount of blood poured out rapidly will produce more marked symptoms than a much larger amount drained away slowly.

The constant accompaniments of *severe hemorrhage* are pallor, dizziness and faintness, rapid and weak pulse, subnormal temperature, rapid and irregular breathing, frequent yawning or sighing, nausea, and vomiting.

Fatal hemorrhage, or one likely to be so, is indicated by livid lips, blue finger nails, dilated nostrils, pallid mucous membranes, dyspnea, ringing in the ears, syncope, collapse and unconsciousness.

Subsequent to the arrest of a dangerous hemorrhage, occur rapid and irregular pulse, rise of temperature, asthenia, a disturbed mental condition, usually muttering delirium. This is hemorrhagic fever. As the general condition improves, the mind gradually clears up. The lowered vitality following the hemorrhage favors the development of various inflammatory processes, and one must carefully watch for the onset of these.

The diagnosis of hemorrhage is not difficult except in the case of internal hemorrhage, or when shock is present.

In the case of bleeding into the cranial cavity, various forms of paralysis and nervous disturbances, together with the general symptoms, will form the basis of the diagnosis.

In the case of bleeding into the thorax and abdomen, the symptoms, the physical signs, and the history of the case will point to the condition. (See Injuries to Thorax and Abdomen.)

When shock is also present it may be almost impossible to tell how much of the symptoms are due to the one or the other, for the symptoms of shock and hemorrhage are practically identical.

It is useful to remember that the symptoms produced by shock are usually immediate and tend to improve, except in the fatal cases. On the other hand, the symptoms of unchecked hemorrhage tend to grow worse.

TREATMENT OF HEMORRHAGE

The First Indication is the Arrest of Hemorrhage. Constitutional measures are then applied with a view to supporting the heart's action. In moderately severe cases give $\frac{1}{2}$ ounce of whiskey or a hypodermic of strychnine ($\frac{1}{10}$ to $\frac{1}{20}$ grain), or of adrenalin chloride, and repeat every hour until the symptoms have improved. Apply warm blankets, hot water bottles, or hot irons well wrapped. Do not burn the patient. Keep him quiet, with head lowered. Attend to the ventilation. As soon as possible give warm drinks and a nutritious but easily digested diet. Do not overstimulate, as the reaction in that case will be unduly severe.

In the dangerous cases of hemorrhage, in addition to these measures, do not fail to employ *normal salt solution* either by enema, subcutaneous injection, or intravenous infusion.

In the gravest cases, enemata will be of no avail, for absorption has practically ceased.

Hypodermoclysis will be a little better. For this purpose employ:

R _x —Sodii chloridi.,	℥ i.
Sodii bicarb.,	gr. xv.
Aq. destill.,	℥ xvi.

The necessary apparatus: a carefully disinfected fountain syringe or a funnel with rubber tubing, a large needle (an aspirating needle). One-half pint or more of the solution is injected by this means under the skin over the abdomen or breasts.

Intravenous Infusion.—In the gravest cases, the same solution by the same means may be injected into the venous circulation. Select a vein at the elbow, employ the strictest asepsis, and expose the vein by incision. Loosen it from adjacent tissues by careful blunt dissection and slip three catgut ligatures under it. Introduce the needle, or else the vein may be opened and a cannula used. The cannula or needle is to be held in place by tying the middle ligature. Slowly inject a pint or more of the solution, the temperature of which should be 105 to 115. Withdraw the cannula, remove the middle ligature, and tie the two remaining. Close the wound and dress aseptically. Keep the funnel full during the injection, so that no air may be carried into the vein.

Crile recommends direct transfusion from the vein of a well person into that of the patient, but of course this method is scarcely available in emergencies of general practice.

Parke-Davis & Company market a sterile salt in sterile tubes which needs only to be emptied into a liter of sterile water to form a solution for instant use. The formula used is as follows:

Calcium chloride,	0.25 gm.
Potassium chloride,	0.1 gm.
Sodium chloride,	9.0 gm.

Remember that intravenous infusion is not to be employed until the hemorrhage is arrested.

HEMOSTASIS—ARREST OF HEMORRHAGE; GENERAL PRINCIPLES

Spontaneous arrest of hemorrhage is due to several factors: contraction and retraction of the injured vessels, diminishing blood pressure due to weakening heart action, formation of a clot, these are the agents which nature employs.

Capillary hemorrhage tends to spontaneous arrest, likewise the arterial hemorrhage of lacerated wounds.

Hemostatic measures locally applied are *chemical*, *thermal*, and *mechanical*.

(A) *Chemical remedies*, chiefly styptics, are now very rarely employed. Such as are used are expected to favor the formation of a clot without doing violence to the tissues. In a persistent capillary hemorrhage, dioxide of hydrogen or acetanilid is often useful and harmless, but the most useful remedy locally applied is adrenalin chloride. The 1-1000 solution is commonly used.

(B) *Thermal hemostasis* is that induced by heat. Hot water or hot normal salt solution alone will usually arrest a moderate bleeding. Use the solution as hot as can be borne by the hand. Hot solutions are especially useful since they serve the double purpose of antisepsis and hemostasis. The actual cautery may be necessary in spongy tissue where the oozing is persistent but ill defined. The iron should not be hotter than a dull red and must be held in contact for some moments. Cold may be used but is much more likely to lower cellular vitality.

(C) *Mechanical hemostasis* includes (1) direct pressure, (2) compression, (3) acupressure, (4) forcipressure, (5) torsion, (6) ligation.

(1) *Direct pressure* is of large service especially in "first aid" treatment. The finger or thumb is pressed directly into the wound, or on each edge of the wound. If the pressure is to be prolonged, the finger will tire and a plug or tamponade of gauze must be substituted. Gauze wrung out of a sterile solution is packed into the wound.

Direct pressure is sufficient in the slight hemorrhage of *operative wounds*. The assistant presses a gauze compress on the bleeding surface, withdraws it by a gliding movement, and the bleeding practically ceases.

In general, the larger the vessels, the firmer and more prolonged must be the pressure.

In severe hemorrhage, direct pressure, is of course, a mere temporary expedient.

Parenchymatous bleeding is checked by direct pressure. The wound of the organ is lined with a layer of gauze. In this gauze cavity, complete the tamponade. This compress should be withdrawn within twenty-four to forty-eight hours. It may be painful to pull out. Release a little at a time, or soften the adhesions with peroxide.

2. *Compression* aims to occlude the vessel above or below the wound. In the emergency, a finger is applied to an artery at some convenient point along its course at some distance above the wound. Pressure is most effective if the vessel lies closely over bone. Large veins are similarly compressed below the wound.

In the case of wounds of the extremities, the main vessels, including both the vein and artery or either alone, may be compressed by the *tourniquet*. The pressure is made firmest over the vessel by laying over its course a body such as a small roller bandage, before the constricting band is applied above the wound (Figs. 53, 54).

The simplest and most convenient tourniquet is a rubber band or tube. After being tightened, the crossed ends are caught and held in place by an artery forceps. It must always be remembered that the tourniquet is likely to cut off all the blood supply to the extremity and if too long applied will produce gangrene. Paralysis may follow from pressure on the nerves. Wrap the arm with a towel and apply the tourniquet over that.

Capillary oozing is frequently troublesome after the constriction is removed. Constriction is objectionable on that account.

3. *Acupressure* is now seldom used and yet, under certain circumstances, may render great aid. The artery may be deep and retracted or imbedded in scar tissue or aponeurosis and cannot be seized by the forceps. In such a case a needle passed under the artery and secured with a figure-of-eight ligature wound around its protruding ends will press the artery between it and the tissues and stop the flow (Fig. 49).

4. *Forcipressure*, the control of hemorrhage by seizing the ends of the bleeding vessels with forceps, is the expedient most com-

monly employed in operative wounds. In the accidental wounds of large arteries, it affords immediate control of the hemorrhage. For the small vessels such pressure is sufficient, the forceps remaining attached for a certain length of time. The end of the vessel should be seized with as little other tissue as possible. If it is a large vessel it may be cleared by a moment's dissection.

5. *Torsion* is added to forcipressure, if that is not sufficient (Fig. 50). Before removing the forceps, it is given two or three turns on its long axis. The inner coats of the artery are ruptured and contracted, producing the same conditions favorable to hemostasis as are found in the artery in lacerated wounds. If the artery is a little larger, it is drawn for $\frac{1}{2}$ inch out of its sheath, a second forceps grasps

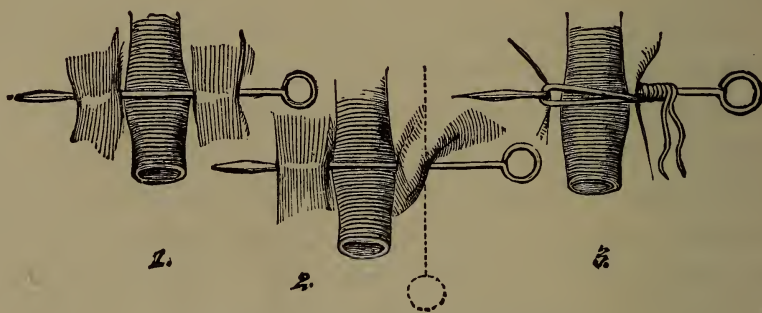


FIG. 49.—Acupressure. (Moullin.)

it higher up and is held stationary, while the lower one twists the intervening segment, the purpose being to avoid injury to the sheath and the vasovasorum.

In making torsion, do not pull at the same time, for fear of tearing the other tissues instead of twisting the artery. Torsion must not be used where the tissues are loose or cellular.

Torsion is of advantage especially in plastic surgery, for it leaves no ligature behind to interfere with repair; but it is not so certain as ligation.

6. *Ligation* is finally necessary in bleeding from the larger vessels. Employ catgut, chromicized or plain. For the largest vessels silk is occasionally used.

Lift the attached forceps so as to create a pedicle around which pass the thread and tie the first knot (Fig. 51).

In tying the second knot, two things are kept in mind; to tie

tight enough that the thread will hold when the forceps is removed, and not to include the tip of the forceps in the ligature. The forceps is usually removed as soon as the first knot is tied, so that one may be assured the suture is not badly placed before completing the knots. The first knot is secured by a second if silk is used, and by a third if catgut is used. The threads are then cut short, silk 1 mm. and catgut 2 or 3 mm. Catgut is the preferable ligature and a No. 2 is amply strong for an artery the size of the radial.

Ligation en masse may be employed in parenchymatous hemorrhage, capillary oozing, or bleeding from a deep wound. A catgut suture is carried around the bleeding area by a well curved needle,

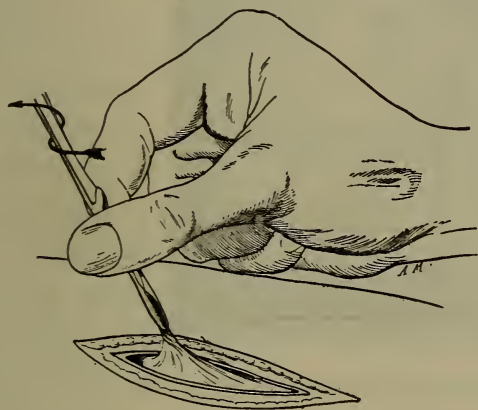


FIG. 50.—Torsion. (Veau.)

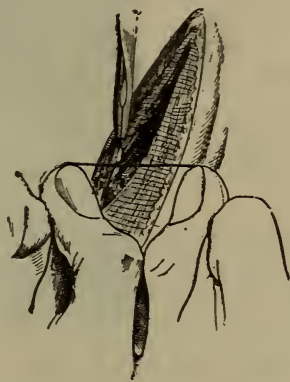

FIG. 51.—Showing method of tightening the ligature. (Veau.)

and all the tissues so included are tied; or, in the case of parenchymatous bleeding from a surface, a catgut suture may be carried around the area and subsequently tightened after the manner of the purse string.

HEMOSTASIS IN SPECIAL FORMS OF HEMORRHAGE

(a) *Capillary*—pressure, hot water, ice, adrenalin, peroxide, acetanilid, alum, ligation en masse.

(b) *Venous*—pressure, compression, forcipressure, ligation, removal of all obstruction to venous flow above the wound.

(c) *Arterial*—pressure, compression, forcipressure, torsion, ligation

(d) *Parenchymatous*—pressure (tamponade), heat, ligation en masse.

(e) *Intermediate hemorrhage*—reopen the wound, turn out the clots and treat hemorrhage as if it were a primary one.

(f) *Secondary hemorrhage*—reopen the wound, turn out clots, and apply compresses. If possible catch the ends of the bleeding vessels. If the hemorrhage is alarming and it is impossible to control it by compresses or forcipressure, apply the tourniquet, in the case of an extremity, and ligate the artery in its continuity above the wound. If this fails and the artery cannot be tied higher up, amputate.




FIG. 52.

(g) *Operative hemorrhage*—In spite of artery forceps, the bleeding remains to the inexperienced one of the bugbears of operative work. In many operations it is the chief drawback to rapid work; more time is lost in catching and tying bleeding points than in doing the actual operation. Oftentimes the field is masked by a general oozing, and the procedure must halt until the wound can be packed with hot compresses, which will usually be all that is necessary. Gentle and momentary pressure with a gauze compress is usually all that is necessary in capillary bleeding.

In operations in the various cavities, as the nose, mouth, rectum, in the mastoid operation, etc., the hemorrhage, even if not disconcerting, is often very troublesome and some special measures are required. Under the circumstances, Parke Davis' adrenalin gauze, which is cut in narrow strips, may be packed in the cavity for a moment and on its removal the operation may proceed (Fig. 52).

FIRST AID IN DANGEROUS HEMORRHAGE¹

It is rare that the regulated measures for hemotasis can be applied first hand in a dangerous hemorrhage. There are certain temporary and makeshift but extremely useful procedures which the surgeon should keep in mind, if for no other reason than that he may give precise and definite instruction to the layman who may have to play the part of surgeon for the time being.

Intelligent first aid is the chief factor in saving life in most cases of dangerous hemorrhage both in military and civil practice. Whoever has to meet these emergencies must keep cool. He must remember how to apply three principles of treatment, *position, direct pressure, compression*.

1. *Position*.—In case the upper extremity is wounded: hold the arm above the head. If it is the lower extremity: put the patient on his back and elevate the limb. If it is the face or scalp: place the patient in a sitting position.

2. *Direct Pressure*.—The wound is small, the bleeding is dangerous: plug the wound directly with the thumb or finger, or press firmly on each edge of the wound; or, in any case and better still, if supplied with a first aid packet, stuff the wound tightly with gauze and bandage firmly. It should be emphasized that a finger must never be thrust into a wound except in cases of greatest urgency and where other means less likely to cause sepsis are not at hand.

3. *Compression*.—The bleeding vessel is recognized and its course is familiar: compress it with the fingers at some convenient point or, in the case of the extremities, by constricting the limb.

In lieu of the tourniquet, knot a handkerchief, apply the knot over the artery and tie the handkerchief tightly around the limb. If it is not tight enough, a stick may be slipped under the handkerchief and given a few turns, end for end. A suspender, a rope, or a wire may, if necessary, be similarly employed. It must be remembered that, on the whole, *circular constriction is not without its dangers*, and it must not be recommended without reserve to the layman.

¹ See also "First Aid on Battlefield," page 179.

¶ *The principal arteries* near the surface have each certain points where compression is most effective.

The temporal and occipital furnish most of the dangerous bleeding in scalp wounds.

The *temporal* may be compressed just in front of the upper part of the ear.

The *occipital* may be compressed in its course from the tip of the mastoid upward toward the occipital protuberance.

The entire blood supply of the scalp may be shut off temporarily by a bandage encircling the head, passing from the forehead, above the ear, to the base of the skull and thence upward, just above the other ear, to the forehead again.

The *facial* is compressible as it crosses the body of the jaw just in front of the masseter muscle.

The *coronary* arteries, supplying the lips, are compressed by seizing the lip between the forefinger and thumb.

The *carotids* are controlled by compression of the common carotid over the transverse process of the sixth cervical vertebra.

Wounds of the vessels of the neck, however, are of such extreme danger, including, as a rule, both arteries and veins, that bleeding should be controlled by direct pressure in the wound. Nothing can be so well trusted here as the finger.

The *subclavian* is compressible against the first rib behind the middle of the clavicle. The shoulder is slightly raised to relax the cervical fascia and the finger or a padded stick pushed directly down upon the artery behind the clavicle. The circulation of the entire upper extremity is thus controlled.

The *brachial* is compressible against the middle of the humerus or the tourniquet may be applied over any part of the artery (Fig. 53).

The *radial* and *ulnar* are not compressible except just above the wrist; and, therefore, bleeding from them must be controlled by direct pressure in the wound, or by the tourniquet, or by compression of the brachial.

The *palmar arches* are not directly compressible, but hemorrhage from the palm is controlled by grasping firmly a round body as a billiard ball, an apple, a stone wrapped with gauze, and bandaging

the hand in this position. If this is not practical, the tourniquet may be applied to the forearm, or the brachial compressed.

The digital arteries are always easily controlled by constriction of the finger above the wound.

The *femoral* artery is compressible in the middle of the groin against the ramus of the pubes, but great pressure is required here to control its flow (Fig. 54). It may likewise be compressed lower

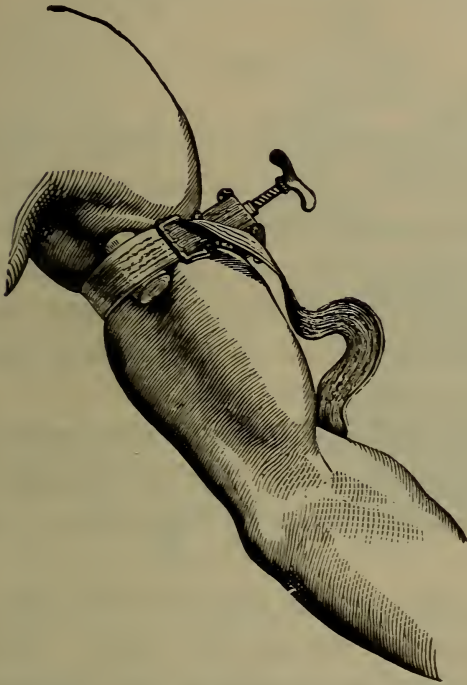


FIG. 53.—Compression of brachial.
(Moullin.)

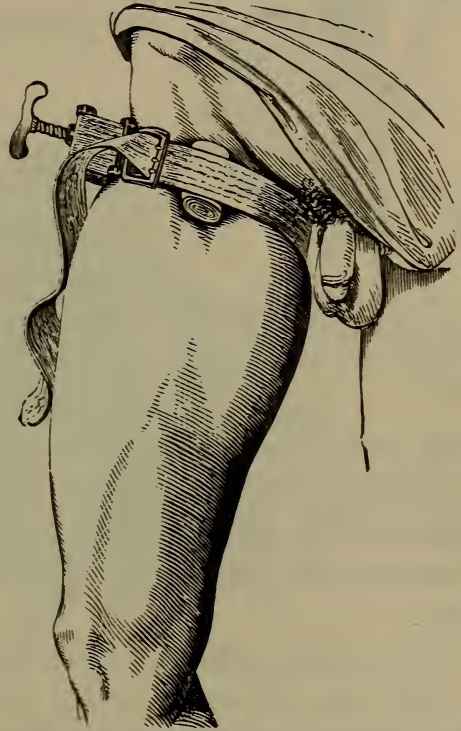


FIG. 54.—Compression of femoral.
(Moullin.)

down against the shaft of the femur. The tourniquet is, in this instance, the safer temporary hemostatic, a compress of some sort intervening between it and the artery.

The *popliteal* is not compressible. Bleeding must be controlled by direct pressure or by compression of the femoral.

The *tibials* likewise. They may also be controlled by flexing the knee forcibly upon a pad, holding the pad in place by a cross piece pressing forcibly against the popliteal space, and in turn held in place by a bandage around the flexed leg (see Fig. 133, page 183).

The *dorsal* and *plantar* arteries can best be controlled by direct pressure or by compressing the tibials and peroneal as they cross the ankle.

The arteries of the surface of the trunk most likely to produce dangerous hemorrhage are the *internal mammary*, the *intercostals*, and the *deep epigastric*. These can be controlled temporarily only by direct pressure, either with the finger or gauze packing. The method of compressing the intercostal is represented in Fig. 55.

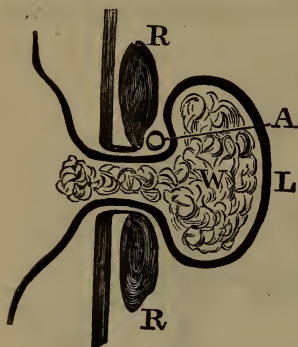


FIG. 55.—Tamponing the intercostal artery. R, ribs; A, artery; W, gauze. (Walsham.)

EPISTAXIS

Epistaxis is a form of hemorrhage often troublesome and requiring special treatment. It may occur in one or both nostrils. The simpler cases are relieved by the erect position, holding the arms above the head, by the reflex effects of cold to the back of the neck, or by pressure over the root or sides of the nose.

If these measures fail, the nostril may be syringed with certain solutions: hot water; antipyrin, 5 to 10 per cent., which is especially recommended in the *Am. Text-book of Surgery*; adrenalin, 1 to 1000.

The patient must not blow his nose, as this eliminates the clot. In the more severe cases try tamponing the anterior nares. If a nasal speculum and a good mirror light are available, the anterior nares may be systematically plugged through the speculum with adrenalin gauze; or, by such means, the bleeding point may be discovered and touched with the point of the cauter, with silver nitrate, or with chromic acid.

The *International Journal of Surgery* gives this practical suggestion: a layer of cotton is wound around a pen holder until the desired thickness is obtained and then withdrawn. The cotton cylinder is then moistened, squeezed dry, and inserted into the nasal cavity. If the projecting end is now moistened, it will swell up and thus produce sufficient compression.

If these various measures fail, then the *posterior nares* must be

plugged. For this purpose, in emergencies, an ordinary soft rubber catheter is available, in lieu of the Bellocq cannula (Fig. 56). It is threaded and passed directly backward through the inferior meatus until its point emerges below the soft palate. The thread is caught with forceps, drawn out through the mouth, and held while the catheter is withdrawn. One end of the thread projects from the nostril and the other from the mouth, and a pledget of cotton is tied to this latter end and traction made on the other, by which

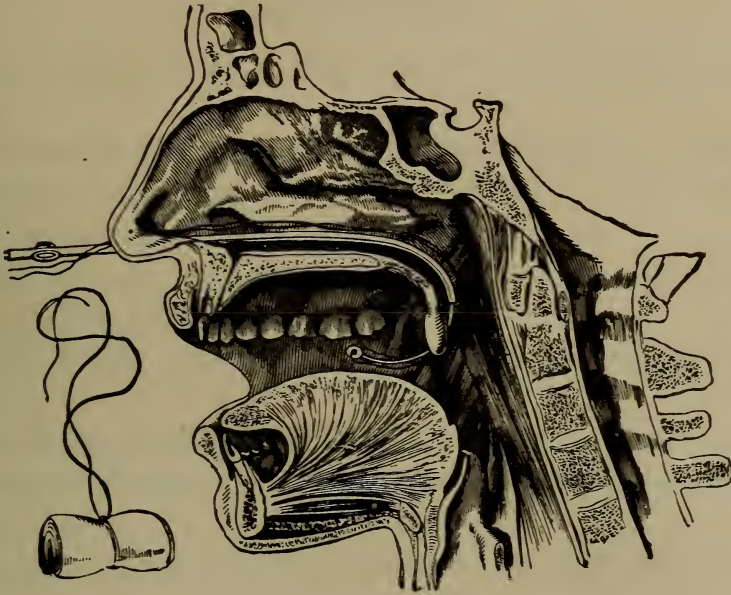


FIG. 56.—Tamponing posterior nares. (Stewart.)

means the tampon, guided by the index finger, is drawn up behind the soft palate and into the posterior nares. When the tampon is tied on it, it is a good plan to leave the thread still long enough to hang out of the mouth, which will greatly facilitate the removal of the plug; otherwise forceps are required or else the tampon will have to be pushed backward into the pharynx. Any plug put into the anterior nares must be secured by a silk thread, lest, becoming dislodged, it may drop into the larynx. The plugs must not be left in for more than two days, and should be moistened before removal with a mild antiseptic solution. Hertzfeld (J. A. M. A., March 13, 1909) describes a case of serious hemorrhage from the nasal cavity treated with perborate of soda. A strip of moist

borated gauze $\frac{1}{2}$ inch wide was covered with powdered perborate of soda and packed tightly into the anterior nares. The hemorrhage ceased immediately. The perborate may be insufflated directly into the cavity. A grayish-white foam immediately issues, nascent oxygen is liberated, and the bleeding checked.

CHAPTER IX

WOUNDS. GENERAL PRINCIPLES

DEFINITIONS

A wound is the solution of the continuity of the soft tissues, due to trauma.

(a) *Subcutaneous wounds* are traumatic lesions of the deeper tissues without any definite break in the skin. Such wounds are more commonly called "contusions."

(b) *Open wounds* are those accompanied by a solution of continuity of the integuments.

1. *Incised wounds* are open wounds produced by sharp or edged instruments.

2. *Stab wounds* are those produced by sharp-pointed instruments.

3. *Punctured wounds* are those produced by blunt-pointed instruments.

4. *Lacerated wounds* are those produced by tearing or crushing.

5. *Gunshot wounds* are those produced by projectiles; shot, bullets, cannon balls.

A *penetrating wound* is one in which the vulnerating instrument reaches a body cavity.

A *perforating wound* is one in which the vulnerating body passes through the cavity.

An *aseptic wound* is one in which there is an absence of the germs of inflammation.

A *septic or infected wound* is one in which the germs of inflammation are present.

A *poisoned wound* is one in which some agent destructive to tissue is present.

An *operative wound* is one produced by the surgeon's knife, and is presumed to be aseptic.

SYMPTOMS AND CHARACTERISTICS OF WOUNDS

All wounds produce more or less pain, hemorrhage, and loss of function; in addition, the severer wounds produce constitutional disturbances, such as shock, although shock may also occur in slight wounds. Hemorrhage depends upon the number and size of the blood vessels involved; pain, upon the character of the tissue and the extent of nerve injury; loss of function, upon the amount and kind of tissue destroyed; shock, upon the mode of injury and the tissues concerned.

Subcutaneous wounds vary widely in the amount of tissue divided. There may be any degree, from a mere strain of a few fibers, with slight intercellular exudation (bruises), to total division or widespread laceration of the various layers of subcutaneous tissue.

The pain is dull and aching. The hemorrhage is usually slight, but occasionally may be dangerous. If the hemorrhage is slight, it produces merely subcutaneous discoloration, most marked in lax tissues; if moderate, it produces an *ecchymosis*; if serious, a *hematoma*.

Contusion of the nerves may produce paralysis, usually temporary; or the nerve may be completely divided in subcutaneous wounds, and the paralysis be permanent. Shock is nearly always present in some degree.

Treatment.—Subcutaneous wounds are nearly always aseptic, and an effort should be made to keep them so.

The first principle of treatment is *functional rest*. It may be secured in bed, or by the use of splints, slings, or bandages. Mere voluntary immobilization is not often sufficient. Apply a cotton compress and bandage; a flannel bandage firmly laid on, alone, often gives great relief. Evaporating lotions, in the case of superficial contusions, often do good. Tincture of arnica and witch-hazel are common domestic remedies.

The following solution, freely and immediately applied, will often prevent a "blackened" eye.

R_x—Ammoni. chloridi.,
Alcohol,

gr. v.
℥ i.

Cold, while often giving relief, must be used with caution, since a too long application will lower the vitality of the tissues and interfere with repair, or will even precipitate death of the injured tissues.

Heat, in the form of a hot water bottle or hot flannels, is better.

If the extravasations of blood are moderate, they may be let alone; or if persistent and interfering with repair, they may be aspirated. In either event, after the inflammatory symptoms have subsided, massage is useful to hasten absorption, promote nutrition, and insure repair and restoration of function.

In those cases of severe injury, where the subcutaneous hemorrhage is marked and continuous, and where a hematoma forms, the skin must be incised without delay, the clots turned out, the wounded vessels secured, and the wound subsequently treated as an open one.

A workman fell from a scaffold striking the gluteal region. He seemed at first only severely bruised. A day or so later it became apparent that a large hematoma had formed. It was aspirated and a large quantity of blood removed but the tumor rapidly reformed. It was opened freely and in the torn fibers of the gluteus maximus a large vessel was found still bleeding. The cavity was a long time in healing but no infection occurred.

Incised wounds are characterized by sharp and severe pain, free bleeding, and a tendency to gape.

The slight actual destruction of tissue, the comparative cleanliness of a cutting instrument, the free bleeding, and the gaping present conditions most favorable for transforming an infected wound into an aseptic one, or at least practically so. At any rate, many presumably infected incised wounds heal with the same readiness and absence of inflammatory symptoms as aseptic operative wounds.

Treatment.—For the arrest of hemorrhage, ordinarily, a compress wrung out of hot water or normal salt solution is sufficient. If

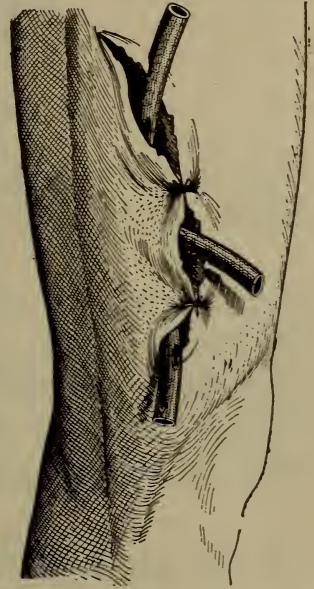


FIG. 57.—Repair of infected incised wound of thigh. (Veau.)

this does not have the desired result, the bleeding vessels are to be seized with artery forceps and ligated. The hemostasis must be complete.

The wound is next carefully cleansed of clots and foreign bodies, using normal salt solution, sterile water, or very weak antiseptic solutions. Under favorable circumstances, that is to say, if there is a reasonable certainty that the wound has been rendered practically sterile, it is closed. If sepsis is feared, a small tube or capillary drain must be employed (Fig. 57).



FIG. 58.—Method of making an incision. (Veau.)

In the first instance, the wound is as carefully closed by suture as an operative one. In the second case, sutures are employed, but are placed further apart, leaving the wound free of access for cleansing solutions and for the free escape of the exudates. If drainage is employed, it may usually be dispensed with after the third day, if no sepsis arises.

It is safer to regard all large incised wounds as infected. If the wound is closed, it must be carefully watched for signs of infection, and, on their appearance, be reopened without delay; or the sutures may be placed and left untied until the probabilities of infection have been determined. A wound sealed on the surface and infected below is a calamity.

After repair of the aseptic incised wound, a dressing of plain sterile or borated gauze is applied, and over this absorbent cotton and bandage.

In certain instances, as with incised wounds of the face, the dressing may be dispensed with, the slight serous exudate being allowed to dry and form a crust, which protection is quite adequate.

Operative wounds are incised wounds, and the aim is always to make and maintain them aseptic. Aside from preliminary sterilizations, there is a proper method of making these wounds, which is essential in keeping them aseptic and promoting repair.



FIG. 59.—A good incision. (Veau.)

The aim should be to do as little violence as possible to any tissues incised. The cutting instrument must be sharp, and the tissues evenly and smoothly divided.

To make a good incision, fix and slightly stretch the tissues on either side of the proposed line of section, with the left thumb and index finger. Never put the skin on the stretch on one side only. The first stroke of the scalpel should divide the skin for the whole length previously determined (Fig. 58). Decide beforehand, there-



FIG. 60.—A bad incision. (Veau.)

fore, the probable length of incision required. The inexperienced operator is inclined to make the wound too short and when subsequently it needs to be lengthened it is difficult to keep it straight. When the skin and subcutaneous connective tissue are divided, identify the deep fascia before incising it; it is an important landmark in nearly every part of the body. All the layers must be cut without any gashing or notching. The incision in the deeper layers should not be quite so long as in the superficial layer. The good incision gives an equally good view of all parts of the cavity (Fig. 59).

The bad incision creates irregularities which interfere with inspection, not to speak of repair (Fig. 6o).

Stab wounds differ from incised wounds only in their greater uncertainties. Their narrowness and depth make it difficult to determine what organs and tissues have been involved.

In order to make a doubtful diagnosis sure, to repair an injured structure, to control, hemorrhage, and, to insure antisepsis, it is often necessary to enlarge the wound. In other respects these wounds are treated on the same general principles as incised wounds.

Punctured wounds are peculiarly a source of worry. They are most prone to become septic for two reasons; first, infection is very likely to be carried into the wound, and, second, it is likely to be retained.

The vulnerating instrument is usually unclean; portions of it may be broken off and retained; other foreign bodies, such as shreds of clothing, sources of infection, may be pushed in and overlooked, inasmuch as the narrow tract makes exploration difficult. The tissues are not divided, but are pushed apart, and tend to close as the instrument is withdrawn. The vessels are little wounded, so that bleeding, the best agent for disinfection, for washing out the invading microorganisms, is wanting.

The bottom of these wounds may be shut off from the surface, so that the oxygen-hating bacillus of tetanus finds there a congenial lodging.

The *treatment* for, all these reasons, must be circumspect. In doubtful cases, it is better at once to lay open the wound and thoroughly disinfect and search for foreign bodies. In any event, the wound must be carefully syringed with cleansing solutions. Peroxide of hydrogen is particularly indicated if tetanus is anticipated. Antitetanic serum is indicated. If suppuration is threatened, early and free incision and drainage are imperative.

Counter openings may be required to facilitate the removal of foreign bodies or inflammatory products.

Lacerated wounds are characterized by the great destruction of tissue, comparatively speaking. "They are peculiarly the product of modern times." The machinery of rapid transit and manufactory is largely responsible. Boiler explosions contribute a

number. Gunshot wounds, especially of the face, are likely to be lacerated wounds.

The manner in which the injuries are produced, the tearing and crushing of the tissues, gives such injuries the following characteristics:

- (1) There is slight primary hemorrhage.
- (2) There is frequently reactionary or secondary hemorrhage.
- (3) Shock is usually present.
- (4) Infection seldom fails to develop.
- (5) Deformity is likely to result.

The following are the reasons:

(1) Primary hemorrhage is slight, out of all proportion to the destruction of tissue, because the coats of the torn vessels curl up and contract, the ragged, uneven surfaces favor coagulation, and the presence of shock lowers the blood pressure.

(2) Reactionary hemorrhage occurs because of the smaller vessels losing their plugs of clotted blood when the blood pressure is restored. Secondary hemorrhage occurs because of the suppuration, which is the rule rather than the exception, unless prevented by treatment.

(3) Shock is always present in some degree because of the injuries to the nerve trunks. In crushing injuries to the extremities, it is sometimes difficult to relieve shock until the mangled nerves are completely divided by amputation. Sometimes under these circumstances, the shock is immediately fatal.

(4) Infection is coincident with the injury because of the grime which is ground into the tissues. The vitality of the tissues adjoining those which were killed outright is greatly lowered, and the power to resist microbic invasion lost. An invading germ and lowered vitality are the two factors always essential to suppuration.

Treatment of Lacerated Wounds.—(1) *Hemostasis*, (2) *relief of shock*, (3) *antisepsis*, (4) *support*.

(1) Hemostasis is usually not difficult. It may be necessary to catch up a bleeding vessel with forceps and ligate, but more often pressure with gauze pads wrung out of hot normal salt solution suffices. Unless the hemorrhage is severe, sterilize the adjacent skin with soap and water, bichloride, or alcohol, before beginning exploration.

(2) Shock is treated on general principles. Maintain the body heat, lower the head, and keep the patient quiet. In severe cases, injections of adrenalin and salt solution are to be employed. (See shock.)

(3) Antiseptic measures follow the arrest of hemorrhage and shock. Begin by covering the wound with sterile gauze, and then scrub the adjacent skin with soap and sterile water, then with bichloride, 1-2000, and finally with alcohol. Next cleanse the wound. By repeatedly flushing with normal salt solution or very weak bichloride or other antiseptics, an effort is made to rid the tissues, as much as possible, of dirt and débris.

Porter, of Fort Wayne, says with regard to cleansing wounds (American Medicine, September, 1906), that it is an easy matter to overdo in our attempts to render an accidental wound aseptic. By the use of too vigorous scrubbing, too harsh mechanical means, too hot water, or too strong antiseptic solutions, more harm than good may be done. The resisting power of the tissues is perhaps the most potent single factor in preventing infection, and it may be diminished by too much antiseptic zeal. We must remember that in spite of our efforts some germs will be left for nature to take care of, and we must not make it impossible for her to do it. "Personally," says Porter, "I find myself using more care, more time, more patience, more soap, more water, and less vigorous scrubbing, less curettement, and weaker germicides."

In the author's practice such wounds are freed of grease and grime by pouring on gasoline and then painting very thoroughly with iodine; or in the case of cavities the iodine is poured into the wound.

It is not always possible to determine to what extent the tissues are fatally injured. In the case of crushed wounds of the extremities, it may be necessary to wait until a line of demarcation appears, so that no useful tissues shall be unnecessarily sacrificed.

Drainage is a matter of antisepsis. It is a *sine qua non* in the case of lacerated or crushing wounds, but there is usually little trouble in this respect for the reason that these wounds are not sutured and drainage is provided for in the dressing.

(4) Suture of the skin wound is not possible, as a rule, but certain

of the deeper structures may demand such repair. A divided nerve trunk, tendon, or muscle requires approximation. Sometimes coaptation of the wound, even though incomplete, will lessen the time required for granulation.

The dressing must fill two requirements; it must absorb the discharge and also keep out infection. The most commonly employed dressing consists of a loose but liberal covering of bichloride or borated gauze applied to the wound, and over this a covering of absorbent cotton held in place by a bandage, which is applied for the purpose also of giving equal pressure and support to the wounded tissues. The frequency with which the dressing must be changed will depend upon the degree of infection.

The author has derived much satisfaction in the treatment of this class of wounds on the hands from the use of the ointment mentioned on page 472. After the wound has been cleansed with iodine, the ointment is applied and the whole covered with gauze and bandaged. It tends to relieve tension and pain and promote repair. The gauze does not adhere to the surface of the wound and so the change of dressing is facilitated.

The aim in general is to disturb the tissues as little as possible, and no change is made except to meet the indications for some phase of sepsis.

Infected wounds may not be recognized as such from the first, but soon the processes of inflammation manifest themselves. Pain, redness and swelling, accompanied by certain constitutional states, such as fever and rapid pulse, are the cardinal symptoms.

The sepsis may produce no results more severe than temporary disturbances of the character named. On the other hand, it may result in suppuration, which prolongs repair and produces unwelcome cicatrices; or, even worse, the infection may spread so rapidly as to involve extensive areas, rendering the tissues brawny with serous exudates and overwhelming the heart and kidneys with toxins before suppuration has time to appear. It is these uncertainties which make infection so much to be feared, and make its prevention the largest element in the treatment of ordinary wounds. When once the sepsis has a definite foothold in a wound, the *treat-*

ment has two objects: to destroy the germ and remove and neutralize its toxins; and to support the tissues in their struggle.

Irrigate the wound cavity at least once daily with weak antiseptic solutions, such as bichloride, peroxide, lysol, or iodine; provide the freest exit for the exudates, employing drainage tubes, if there is a cavity. Never pack a suppurating cavity with gauze. Apply a moist gauze dressing, moistening it with alcohol, bichloride or boric acid, or other antiseptic solutions, or, what is perhaps as well, with normal salt solution. This may or may not be covered with absorbent cotton. Whatever other qualities the dressing may possess, it must be absorbent. Sometimes in the case of the extremities, prolonged immersion in warm normal salt solution does good.

After granulation once begins, it may be stimulated and the wound kept healthy by the use of dusting powders, antiseptic ointments, or balsam of Peru. The latter has been lately very highly recommended, in the treatment of wounds generally.

(For gas bacillus infection see page 285, compound fractures.)

CHAPTER X

WOUNDS OF SPECIAL REGIONS

WOUNDS OF THE SCALP

Certain anatomical features determine the special character of scalp wounds, and must be kept in mind in prognosis and treatment.

The blood vessels converge toward the vertex; they are the occipital, posterior auricular, superficial temporal, supraorbital and temporal, any one of which may give rise to troublesome bleeding, and all of which are subcutaneous instead of subaponeurotic, as elsewhere.

They are firmly connected with the dense tissue of the scalp and for that reason do not readily contract when divided; for this reason the bleeding from scalp wounds is copious and without much tendency to spontaneous arrest. The vessels are somewhat difficult to catch with artery forceps.

The aponeurosis of the occipito-frontalis is the dividing line in prognosis: wounds that do not penetrate it are less likely to become infected, nor do the conditions favor spread of infection. A wound perforating the aponeurosis is always a matter of concern; for, owing to the loose cellular tissues which connect the aponeurosis with the pericranium, an infection may spread very rapidly and in every direction.

All scalp wounds are presumably infected, yet the free bleeding minimizes the infection, and the rich blood supply of the tissues favors rapid repair.

Scalp wounds do not gape unless the aponeurosis is divided, and contused wounds often resemble incised wounds.

Contusions may result in the formation of hematoma beneath the skin, but they are of little moment. Evaporating lotions are sufficient to hasten absorption.

A severer injury may cause a hematoma under the *aponeurosis*. Glancing blows, other things being equal, are more likely to cause these tumors, rupturing the vessels of the subaponeurotic areolar tissue. Such a tumor is likely to be extensive. It may be the source of error in diagnosis, giving the examining finger the sensation of a depressed fracture, being hard around the borders, and soft in the center. If the tumor is of such size as to put the skin greatly on the stretch, it may be punctured. This is preferable to incision, for there is less chance of infecting the exudate.

Absorption always takes place so that the least interference possible is the best treatment.

A hematoma may form under the *pericranium*, usually in children in whom the bone has a rich vascular supply. Here, also, it is absorbed in time, and intervention is rarely, if ever, necessary.

Open Wounds.—The treatment of these wounds, of whatever character, may be expressed in certain general formulæ.

The first step consists in cleansing the hair of the blood, which is not always an easy task. Warm water is best to dissolve out the clots, or peroxide of hydrogen.

The next step consists in removing more or less of the hair, depending upon the gravity of the wound. In all serious cases, the whole scalp must be shaved. Begin by cutting the hair with the scissors, and then apply the razor; the "safety razor" facilitates this work.

Next cleanse the scalp with ether, to dissolve the oil which is always present, and follow this with alcohol; otherwise the ether will interfere with the soap and water cleansing which follows, and which is freely and vigorously applied.

In the meantime, a light gauze packing prevents the soap and water running into the wound. Once the scalp is cleansed, the wound itself is to be cleansed.

Strong antiseptics are distinctly to be avoided. Sterile water, normal salt solution, or peroxide are perhaps the best. An irrigator or syringe is not to be used, but the solution may be squeezed out of a compress into the wound. Be assured that every particle of foreign matter is out of the wound before considering repair.

Complete hemostasis is an essential to rapid healing, and the time and patience spent in securing it are by no means lost. If the bleeding vessels cannot be ligated in the ordinary way, the ligature may be carried on a needle through the tissues surrounding the vessel. The oozing may be entirely controlled by a few minutes' pressure with a hot antiseptic compress. The main thing is not to get discouraged or be in too great a hurry.

The cleansing and hemostasis completed, the coaptation follows. In the case of contused wounds, the ragged edges are to be trimmed. The suturing is an important step in facilitating reunion. Even wounds that do not gape heal all the more quickly for suturing, silk being probably the best material.

In many cases of incised wounds which are not deep, the suturing may be firm and no drainage required. In the great majority of cases, however, drainage is necessary, and may be secured by incomplete suture, by a tube, or, following Von Bergman, by strips of gauze or rubber tissue.

The dressing will usually consist of sterile gauze and absorbent cotton held in place by bandage. In the case of minor wounds, and where no infection is feared, it is sufficient to smear the line of suture with sterile vaseline and cover with flexible collodion.

If a large segment of the scalp has been loosened, every effort must be made to readjust and suture it accurately, though the drainage must be ample. Oftentimes with those who have been even almost completely scalped, the results have been excellent.

Flaherty reports a case of complete avulsion, occurring in a laundry worker. There were areas of denuded bone. There was no shock and but little hemorrhage. The woman who was alone at the time of the accident remained perfectly conscious and after extracting herself from the machinery, stopped the motor and wrapped a towel around her head.

Hot boric acid compresses were applied without further cleansing and after four days Thiersch grafts taken from the thigh were applied to one side of the head and a week later to the other side. The denuded bone was trephined through the outer table that granulations for grafting might form. Pursuing this line of treatment the patient was enabled to leave the hospital in two months

with head covered with good firm skin. (Annals of Surgery, Feb., 1914.)

WOUNDS OF THE PINNA

Many forms of injury befall the ear. It may be bruised, cut, or lacerated, and much or little of it lost. Even a slight loss is a disfigurement, and any very serious loss of tissue results also in some disturbance of hearing.

A laborer came into the City Dispensary with half an ear cut off and hanging by a mere thread of tissue. The sharp edge of a spade wielded by a co-worker had produced the injury. The almost discarded member was carefully sutured in place with silk. Some sloughing occurred along the edges of the wound but eventually the repair was complete and almost without a scar.

These tissues possess great vitality, and the completeness of repair after much mutilation is often surprising. Large portions of the ear may be cut off completely, and yet if immediately sutured in careful coaptation, union will occur. There may be some sloughing along the line of union, but eventually there is but little scar tissue left. In every case, then, of incised wound, an effort must be made to suture. The hemostasis must be complete, and if there is much laceration, the edges of the wound must be trimmed. Silk is the best suture material in these cases.

WOUNDS OF THE FACE

Accidental wounds of this region, more than any others, approximate aseptic wounds. These wounds do not gape much; the tissues are very vascular, so that the conditions are most favorable for repair. The chief aim is to avoid scar tissue and the consequent disfigurement. To attain that end the suturing must be delicate, the coaptation perfect. The sutures must be as small as possible and as few as possible.

The subcutaneous stitch may be employed if the wound is extensive and deep. In ordinary incised wounds extensive dressings may be dispensed with, and the line of suture may be covered with collodion or, as Von Bergman, who dislikes collodion, suggests,

the wound may be amply protected by the scab formed by the dried exudates.

WOUNDS OF THE LIPS

Wounds of the lips are likely to bleed considerably, but the hemorrhage is easily controlled by compressing the lip between the thumb and index finger, and then the *coronary artery* may be ligated on each side of the wound.

When the division is complete, begin the repair by suturing the mucous membrane (Fig. 61) with catgut. Suture the skin by continuous or interrupted suture of fine silk or catgut. The greatest care must be exercised when the border of the lip is reached; the coaptation must be exact or the result will be a disappointment.

A small drain in the skin wound is usually advisable.

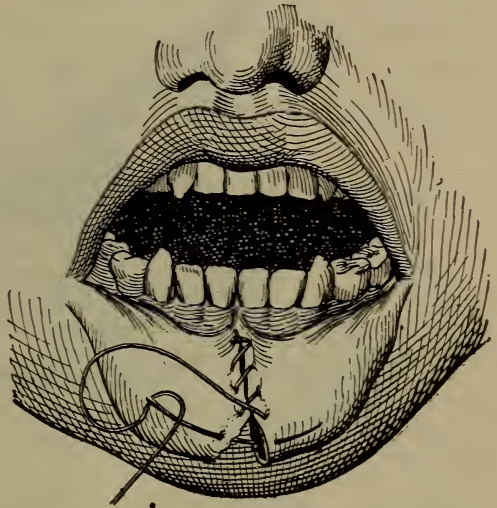

FIG. 61.—Suturing wound of lip. (Veau.)

WOUNDS OF THE TONGUE

Wounds of the tongue, which are not as infrequent as one might expect, may give rise to a disagreeable hemorrhage.

The tongue is to be drawn out of the mouth and compressed with the fingers above the wound or by a pair of forceps covered with rubber tubing or with gauze (Fig. 62).

Suture the bleeding points, employing deep sutures of catgut, No. 3. Every quarter hour the mouth should be washed with a solution of chloral, 2 grains to the ounce, until the oozing and pain have subsided.

WOUNDS OF THE EYELID

A wound of the eyelid is to be repaired like a wound of the lip, by two lines of suture. First suture the mucous membrane with

fine catgut. Then begin the suture of the skin at the free border, where the edges of the divided tarsal cartilage are to be very accurately coapted (Fig. 63). If drainage is used, it must be small and project from the middle of the wound.

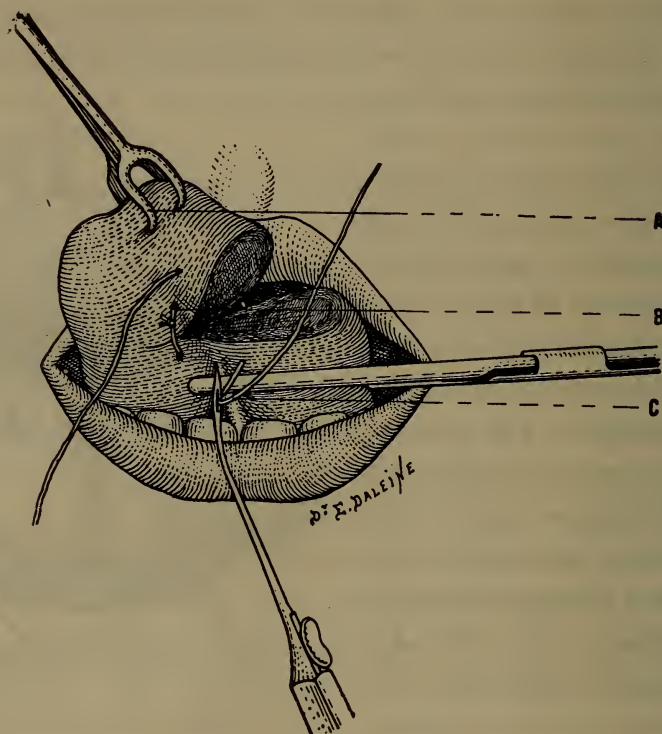


FIG. 62.—Suturing wound of tongue. A, tongue controlled by tenaculum forceps. B, first suture passed and tied. C, second suture passed, using the Reverdin needle. (*Lejars.*)

WOUNDS OF THE NECK

One has but to consider the multiplicity of the structures in the neck to realize that wounds of this region are likely to be complicated.

Whether the wound be incised or contused, a stab or a gunshot wound, there are dangers that arise from hemorrhage, asphyxia, and infection.

The most common wounds, perhaps, are those which arise from attempts at suicide. That these attempts are often abortive, and the danger done much less than one might expect, are due to the fact that the tissues are yielding and the vessels recede as the head is thrown back; the knife may be directed against the lower jaw or spend its force on the cartilages or hyoid bone; the arm may lose its

force at the moment the larynx is opened, or from failing resolution. In these attempts at suicide, the wound in right-handed people usually begins on the left side high up, and runs obliquely downward to the right, becoming less and less deep. Not infrequently the wound may appear jagged, or give the impression of two or three slashes, from the folding of the skin before the pressure of the knife (Fig. 64).

In the graver cases, *hemorrhage* is usually the first consideration. If a carotid is wounded, a geyser of blood spurts out and the patient's life is in the hands of the first comer, for there is no time to call for skilled aid. If the internal jugular is wounded, the hemorrhage is scarcely less dangerous and perhaps even more difficult definitely to control. Air may enter the venous circulation and death immediately ensue. In either case anything but intelligent first aid will fail.

The carotid may be controlled by pressure downward and backward at the base of the neck, compressing the vessel against the transverse process of the sixth cervical vertebra; or the bleeding may be temporarily controlled by direct pressure on the bleeding vessel in the wound.

When the surgeon arrives upon the scene, he finds the wound filled with a great clot, for it cannot be expected that the first aid will do anything more than partly check the bleeding. His first effort must be to cleanse out the clots and locate both ends of the bleeding vessels, clamp them, and ligate. Blind clamping of the tissues *en masse* is absolutely unsurgical. If the ends of the divided vessel cannot be located, the wound is to be enlarged over the course of the vessel, using the anterior border of the sternocleidomastoid muscle as a guide. If the character of the wound or the region preclude that, then the artery must be exposed below the wound and ligated. It may happen, especially in secondary hemorrhage, that the carotid on the opposite side also may need to be ligated either temporarily or permanently.

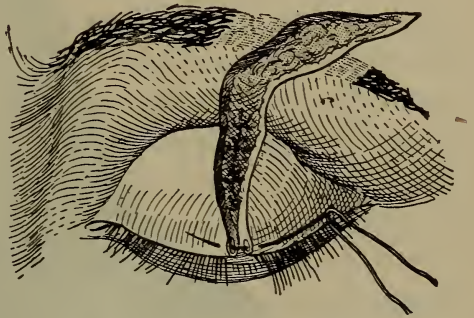


FIG. 63.—Incised wound of upper lid.
Tarsal cartilage sutured first. (Veau.)

The internal jugular may be difficult to expose and ligate because of its thin and friable walls. Even small openings in the vessel may call for circular ligation, for lateral ligation is usually unsatisfactory. Outside of the hospital, suture can scarcely be considered.

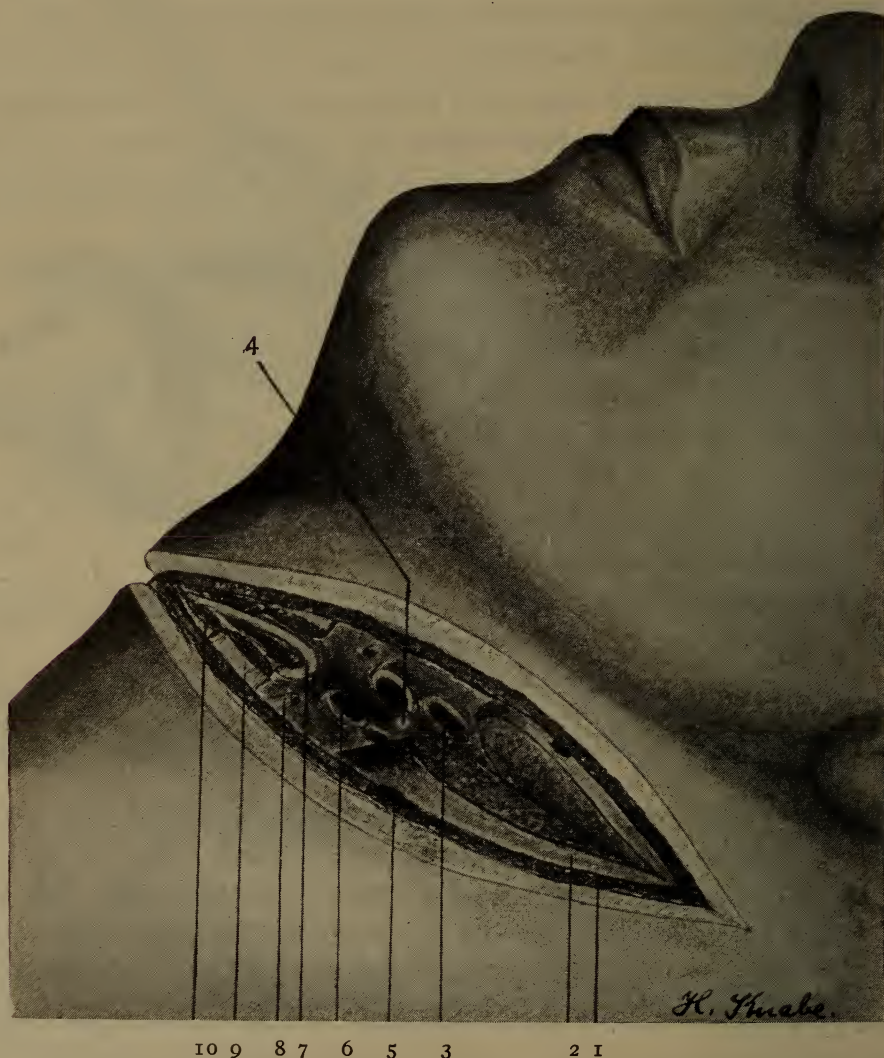

FIG. 64.—Incised wound of neck involving the larynx. 1, platysma; 2, sterno-mastoid; 3, int. jug. vein; 4, vagus nerve; 5, ext. jugular vein; 6, com. carotid art.; 7, upper part of wound in thyroid cartilage opening into larynx; 8, sup. thy. art.; 9, st. hyoid muscle; 10, sterno-thyroid musc.

If the *trachea*, in its upper part, or the *larynx* is opened, it is better to do a tracheotomy lower down and attempt repair of the wound. In many cases, however, if the wound is not extensive, it is sufficient

to close the wound by flexing the neck, omitting the sutures, and leaving nature to repair the opening in the air passage.

If the *esophagus* or *pharynx* is perforated, repair should be attempted; but drainage must be employed and the external wound left partly open, for, in the act of swallowing, particles of food may be forced into the wound to set up infection.

If infection or inflammation of the respiratory tract arises, it is to be treated on general principles.

Divided nerves should be repaired if possible, although often the difficulties are too great to surmount.

A woman, the victim of a murderous assault, was brought to the City Hospital with a gaping razor cut straight across her throat. The hemorrhage had been checked by the ambulance surgeon who had applied three or four clamps. She was anesthetized with some difficulty. It was found that the structures connecting the hyoid bone and the thyroid cartilage were severed—in other words the pharynx was opened widely and with each inspiratory effort the epiglottis protruded into the wound.

An effort was made at an anatomical repair and with some success. The mucous membrane was fairly well coapted with interrupted sutures of plain catgut.

Next all the small bleeders were tied and the muscle ends brought together with mattress sutures of chromic gut; the fascia next with chromic, and finally the skin was repaired with silkworm-gut. Rubber tissue drainage was used on either side of the middle line extending down to the muscle layer.

Following the repair, swallowing was exceedingly painful and the secretion of mucus excessive. Rectal feeding was necessary for three days.

The subsequent course of the case was remarkable. Her pulse and temperature remained normal, there was not the slightest evidence of infection and she left the hospital at the end of two weeks with a light scar as the only evidence of her terrible experience.

WOUNDS OF THE EYE

Morrison, of Indianapolis (Indiana Medical Journal, Feb., 1907), has defined the injuries of the eye, whose treatment must most often

be instituted by the general practitioner. From the diagnostic point of view, he classifies them under two heads:

(a) Those without superficial lesions of the ball.

(b) Those with more or less extensive open wounds.

(a) The first may lead the practitioner into grievous error in prognosis and injudicious lack of treatment. No blow over the eye should ever be considered lightly. While the majority of such cases lead to no serious consequences, the exceptions are of sufficient frequency to be of importance.

It is possible for the so-called "concussions" to lead to subsequent inflammation or degeneration of the deeper structures of the eye. So, then, though no treatment is to be instituted in the absence of symptoms, yet the case must be kept under observation for some time, the vision tested, irregularities of the pupil noted, and evidences of inflammation sought for.

On the other hand, there may be a hemorrhage into the anterior or posterior chambers, accompanied by pain, protrusion of the eyeball, and swelling of the lids. Under such circumstances, put the patient to bed at once and apply ice cloths to the eye, this treatment to be kept up until the symptoms begin to subside, when it is probable that the blood has clotted and the hemorrhage ceased.

In addition to, or instead of hemorrhage, there may be disarrangement of the retina, lens or iris, accompanied by disturbance or destruction of vision.

Put the patient to bed in a darkened room, and drop into the eye a solution of atropine, 4 grains to the ounce, followed by the application of cold cloths for at least twenty-four hours. Later a bandage is to be applied and the patient permitted to go about.

Any subsequent disturbance calls for an examination by an oculist.

(b) *Deep, penetrating, non-infected wounds* of the globe are serious in various degrees, depending upon the region involved, though they usually heal kindly. Injuries of the sclero-corneal junction or ciliary body often lead to sympathetic ophthalmia, and may require early or late enucleation.

The treatment is simple. Prevent infection by the free use of boric acid solution, followed by one or two drops of the atropine

solution, and the application of a sterile eye dressing. Rest in bed is indicated.

Every wound of the sclera of any moment requires suture, which is the best means of preventing infection. Infected wounds require an immediate and circumspect treatment.

If the vitreous is involved, the eye is almost certain to be lost. The prognosis is somewhat better if the cornea alone is involved.

The eye is to be irrigated with warm, sterile, saturated solution of boric acid, followed by a few drops of the atropine solution, the whole to be repeated every two or three hours, until the redness passes away. In the meantime, heat or cold is to be applied, depending upon which gives the most comfort, except in the case of the cornea, where heat is always the better application.

Morrison recommends as the best eye pad, several thicknesses of sterile gauze held in place by a single thickness of bandage or a strip of adhesive plaster so that it can be frequently changed.

To sum up, then, the chief ends of the emergency treatment are two; asepsis and conservation. Only very rarely will the question of enucleation present itself as an emergency. The *careful examination* which should be given every injured eye, should be preceded by a *regulated asepsis*. Prepare the hands; prepare the orbital and palpebral regions by patient washing with warm sterile water and soap, avoiding all pressure or rough handling which may aggravate the ocular lesions. Cleanse the conjunctiva of the grösser dirt and immediately instill a few drops of cocaine solution. In a few minutes the cleansing of the globe and palpebræ may be completed without pain, and a careful examination made and the treatment instituted.

If suture is required, use a small curved needle held with a forceps, employing catgut No. 00, and above all, a minute care and a light hand.

The suture should not pass through the entire thickness of the sclerotic coat, but only through the conjunctiva or the most superficial layers of the sclera. The reunion will usually be perfect if the sutures are carefully passed and slowly tied. (See, also, *Foreign Bodies*.)

WOUNDS OF THE EXTREMITIES

Wounds of the extremities call for varied application of all the principles of treatment of wounds, hemostasis, antisepsis, and suturing.

Only through familiarity with these principles will one acquire address in the management of the individual case, for no two injuries are exactly alike. It will be advantageous to exemplify these principles with special reference to wounds of the extremities.

INCISED WOUNDS OF THE WRIST

Such wounds are frequent and their repair is usually left to the junior surgeon; the task is, however, no light one and the functional

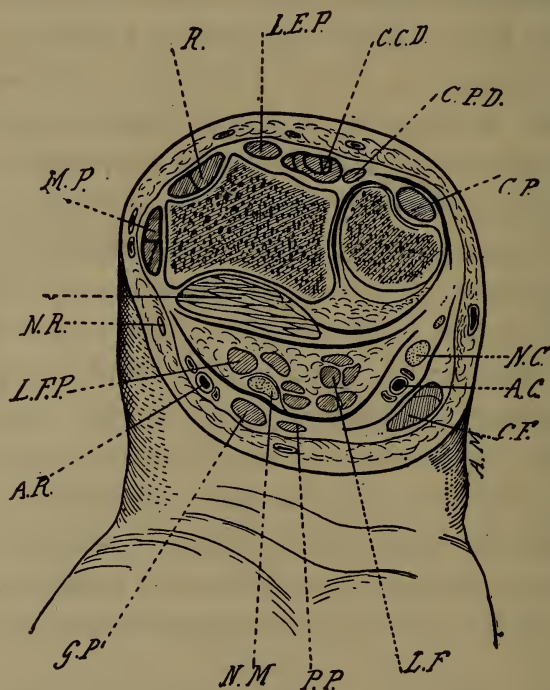


FIG. 65.—Cross section showing relations of the various tendons at the wrist-joint. *N. R.*, radial nerve; *L.F.P.*, long flexor of the thumb; *A.R.*, radial artery; *G.P.*, palmaris longus; *N.M.*, median nerve; *L.F.*, flexors of the fingers; *A.C.*, ulnar artery; *N.C.*, ulnar nerve; *C.P.*, ext. carp. ulnar; *C.P.D.*, ext. min. dig., *C.C.D.*, ext. com. digitorum; *L.E.P.*, ext. long. pollicis; *R.*, extensors carp. rad.; *M.P.*, supinator longus extensor brev. pollicis.

results are often a source of embarrassment to the operator. To locate and identify all these tendons and nerves, to get the proper ends in contact, to repair them and, above all, to avoid infection

requires no end of patience and no little skill. The management of these wounds is largely a matter of applied anatomy.

In the more superficial wounds the palmaris longus alone is divided, a quite small tendon in the middle line of the wrist.

A little deeper on the radial side of the middle line, the flexor carpi radialis may be involved; or far out on the ulnar side, the flexor carpi ulnaris, in the line of the pisiform bone.

If a still deeper plane is reached the radial artery on the radial border, the ulnar artery on the ulnar border may require a ligature. The ulnar nerve lies to the ulnar side of the ulnar artery, and little deeper. In the middle line in this deeper plane are the flexors of the fingers and the median nerve (Fig. 65).

The bleeding in such cases is usually copious.

Begin the treatment by elevating the arm and applying circular constriction for temporary hemostasis (Fig. 66).

Next sterilize the field and then the wound itself. Separate the lips of the wound, locate and clamp the superficial veins (Fig. 67). These are not of much importance yet are large enough to make troublesome bleeding. Search for the artery; both ends must be ligated, the companion vein included.

It may be necessary at this time to enlarge the wound, for the skin may be much less extensively involved than the deeper parts.

It is of great assistance to mobilize the lips of the skin in order to expose and facilitate the repair of the deeper structures. Remove

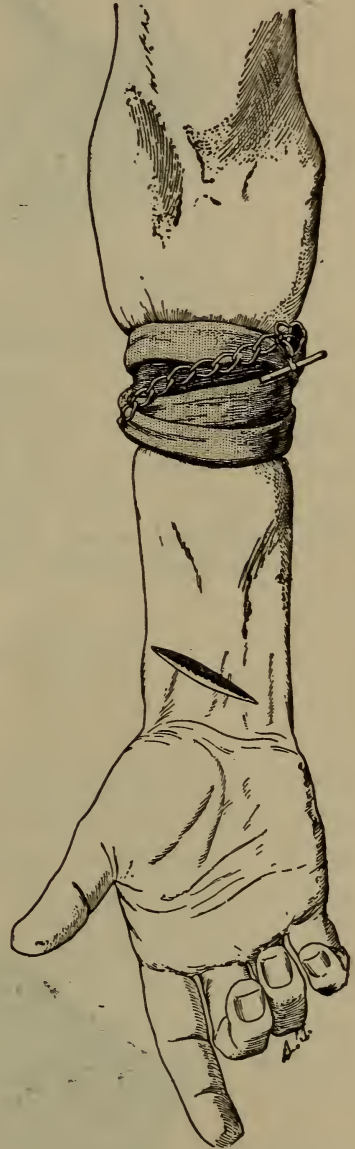

FIG. 66.—Incised wound of wrist. Tourniquet applied. (Veau.)

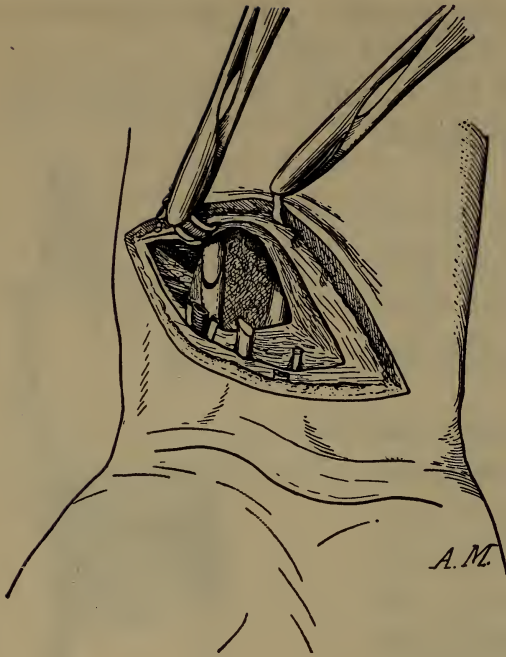


FIG. 67.—Incised wound of wrist. Bleeding vessels clamped. (Veau.)

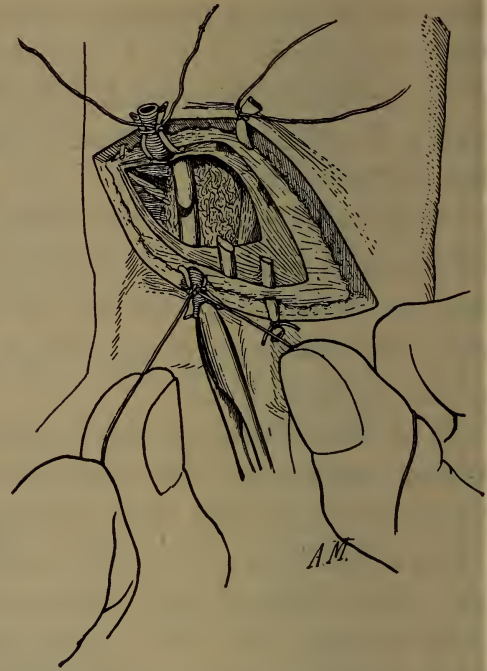


FIG. 68.—Incised wound of wrist. Vessels ligated. (Veau.)

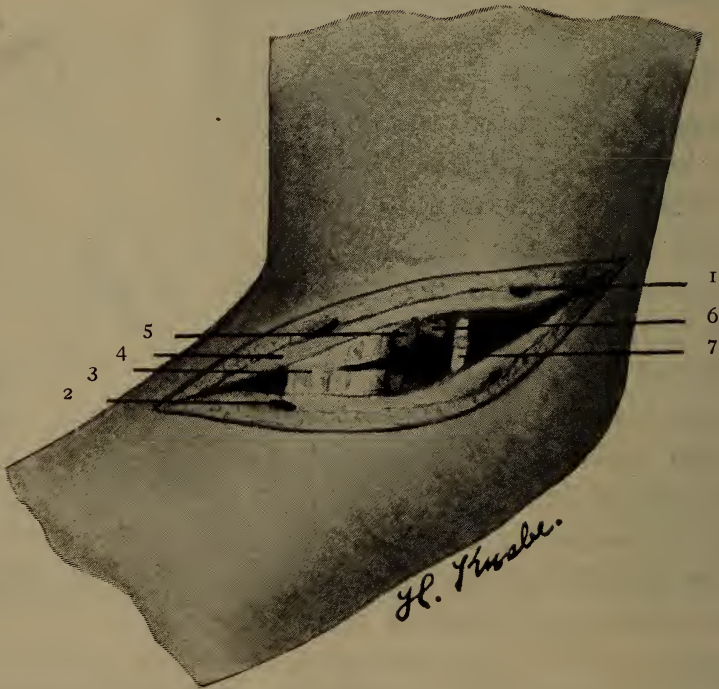


FIG. 69.—Wound at bend of elbow. 1, Basilic vein; 2, median cephalic vein; 3, biceps tendon; 4, bicipital fascia; 5, brachial artery; 6, brachial vein; 7, median nerve.

the tourniquet, complete the hemostasis, and proceed to determine the injuries to tendons and nerves. (For methods of repair see page 347.)

WOUND AT THE BEND OF THE ELBOW

The importance of the structures at the flexure of the elbow call for special reference to incised wounds in this region. They are not infrequent.

Superficially, on the inner side, is the median cephalic vein; on the outer the basilic vein; below these the bicipital fascia, an important landmark just beneath which, in the middle line lies the brachial artery with its vein to the inner side. The median nerve lies also to the inner side; and deeply placed in the middle line is the tendon of the biceps. Failure to repair any of these structures may lead to serious disability. The bicipital fascia should be repaired by a separate line of sutures (Fig. 69).

A STAB WOUND OF THE THIGH

(Fig. 70.)

The femoral has been wounded and the hemorrhage is furious. Direct an assistant to make firm digital pressure over the artery as it crosses the pubes, nor must this pressure be relaxed. If his fingers tire, a second assistant may press upon the fingers of the first (Fig. 71). Enlarge the wound freely in both directions in the course of the artery. Sponge out the clots; identify the aponeurosis and divide it in order to expose the artery; isolate the artery by careful blunt dissection and find the two ends, which is often difficult when the artery is completely divided (Fig. 72).

When both ends are found, ligate with catgut No. 3, or silk No. 2, (Fig. 73). Tie the injured vein next both above and below. It is to be tied separately from the artery (Fig. 74). The possibility of including a nerve in the ligature must always be borne in mind and no ligature is to be finally tied until certain that no nerve is to be thus compressed, to become later a source of pain. Remove the

pressure and catch any more vessels that might bleed; employ free drainage and suture incompletely.

Apply sterile gauze dressing, absorbent cotton, and a bandage, making moderate pressure, and maintain the limb in moderate elevation. Renew the dressings on the third day, and if there are no

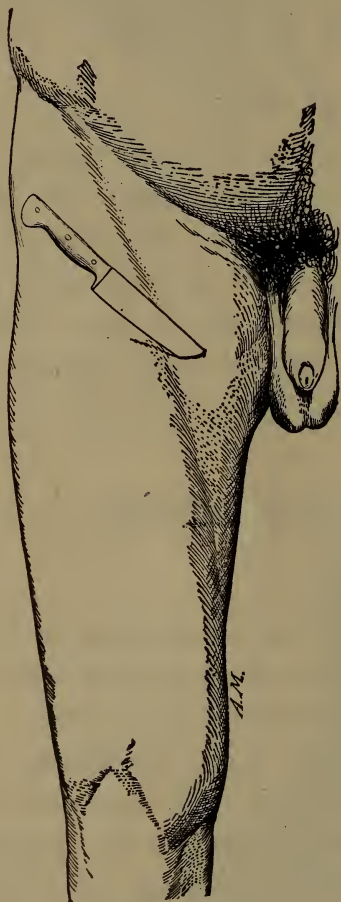

FIG. 70.—Stab wound of thigh.
(Veau.)

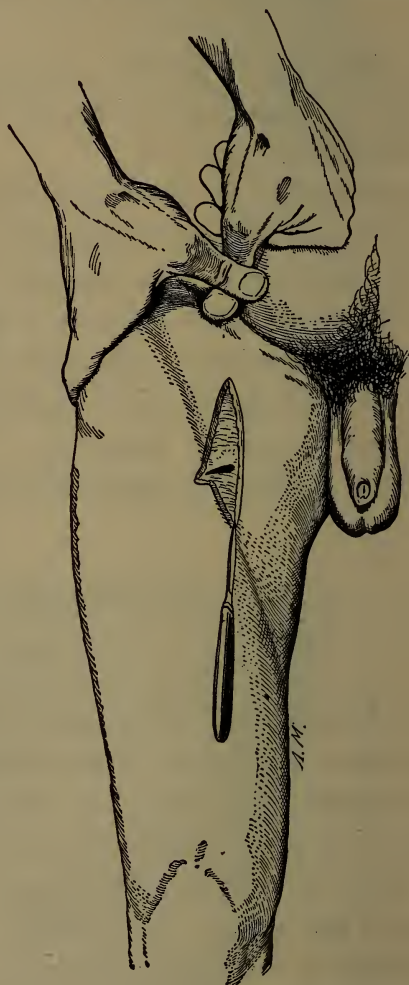

FIG. 71.—Stab wound of thigh. Compressing artery while the wound is enlarged. (Veau.)

complications, remove the drainage. Remove the sutures about the eighth day.

Certain complications may arise. If the ligatures were imperfect, hemorrhage may ensue; the operation has to be repeated and the vessels tied again. If infection occurs, if the temperature reaches

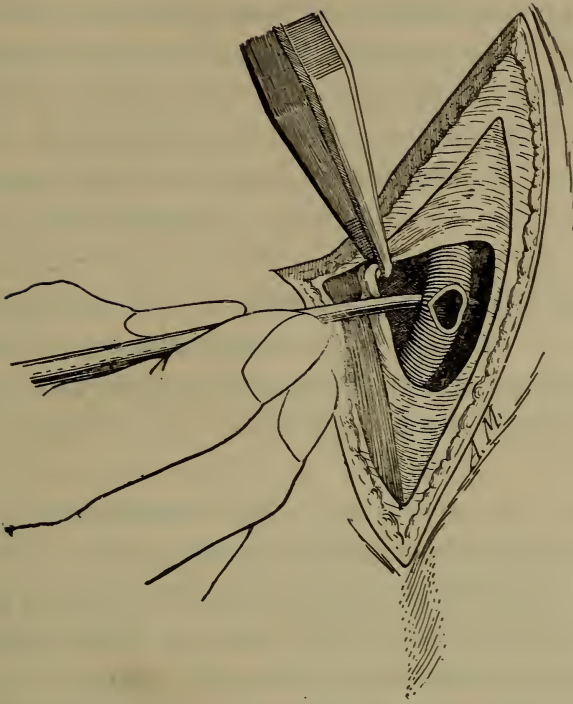


FIG. 72.—Exposing the wounded vessel. (*Veau.*)

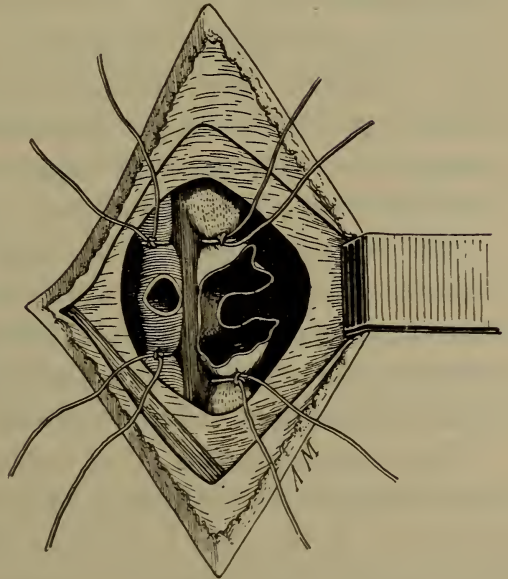
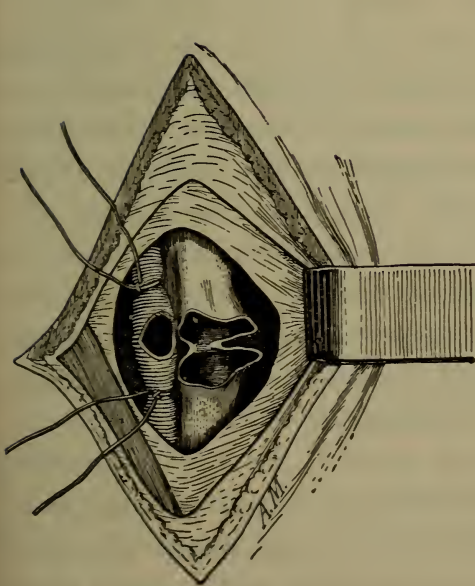


FIG. 73.—Isolating and ligating the artery. FIG. 74.—Ligating the vein. (*Veau.*)

101° F., open up the wound and establish better drainage, which is the best means of preventing secondary hemorrhage. Gangrene sometimes follows the ligation of a main artery. Watch the temperature of the extremity and look for pulsation in the arteries below the ligature. If pulsation is present, be in no haste to amputate. If gangrene does not develop before the fourth day, it is not likely to do so.

Crushing and lacerating wounds of the extremities, as Lejars says, give rise to the most perplexing problems of emergency surgery. The questions present themselves in this form: To amputate, or not to amputate? and if the latter, when, at what point, and by what method?

In order not to be vacillating in his treatment, every doctor must have his principle of action settled once for all.

Lejars states his guiding principle and rule of action in this manner: Above all, save the patient's life; save the limb wherever possible, or at least limit the mutilation to the minimum.

Clinically, he places these injuries in two groups: (a) those in which a segment of the limb is crushed or otherwise injured without peripheral involvement, and (b) injuries extending from the hand or foot upward.

(a) Suppose a case: An arm has been run over by the wheels of a heavy vehicle. The member is flail-like, although the skin is not broken, and there are no particular points of bleeding. Palpation through the skin over the injured segment shows that the deeper structures have been reduced to a pulp, both muscle and bone.

Still, below the wound, the radial and ulnar arteries are found to pulsate. This is an absolute indication against amputation. The immediate treatment must be limited to a careful disinfection of the member, the repair of any superficial wounds, a complete envelopment in absorbent cotton, and immobilization.

The immobilization is an essential feature, for by that means any bending and stretching of the vessels is prevented and repair favored. If the skin is broken and the bone crushed or shattered and exposed, the injury is a compound fracture and is to be dealt with accordingly, but the prognosis always depends upon the blood supply.

If in the case instanced, there is absolutely no pulsation in the principal arteries, it is certain that a part of the limb is lost; yet an immediate operation is not indicated. There are two reasons for this; first, that the shock may subside, and second, that too much of the limb may not be sacrificed, which latter an immediate amputation nearly always means.

Proceed to a most rigorous disinfection and await a line of demarcation. This is the rule to which there are two exceptions, one apparent, and the other actual.

If the injury is a crushing one and the member hangs by shreds of tissue, there is absolutely no use in waiting; but the completion of the ablation does not require an amputation, it is merely what Lejars terms a "regularization."

Trim up the tissues sparingly and remove enough bone that a proper stump may be formed, and then patiently cleanse the wound with hot sterile water or normal salt solution, followed by alcohol. Suture completely and then cover the wound with sterile gauze saturated with alcohol; finally cover all with a thick layer of cotton firmly bandaged.

Almost always by this means a better functional result may be obtained than by a formal amputation quite above the site of injury.

There is an actual exception to the rule of conservatism. The case is seen late and there are already *signs of approaching infection*. It is not safe to delay and risk the sepsis which menaces. It is better, under such circumstances, to proceed to immediate amputation.

(b) *Crush or laceration extending from the hand or foot upward.*

Suppose you are called to treat the foot and part of the leg, or a hand and part of the forearm, which have been crushed and lacerated. The member appears injured beyond remedy. Will you immediately proceed to amputate? By no means—or at least, not as a rule.

If the case is seen immediately, the first effort should be devoted to combating shock and infection.

It is not altogether on account of shock that one waits; there are other even more important reasons. The first is that you may not amputate high enough; the second, that you may amputate too high.

One cannot always determine from the first how high the devitalized tissues extend. There may be vascular injuries or muscular lacerations which are concealed by a sound integument, and which may later be the source of gangrene. Out of this grows the necessity of a secondary amputation, which is always a matter of chagrin to the surgeon and an element of danger to the patient.

On the other hand, tissues which appear devitalized may finally survive and thus preserve a function which might otherwise have been sacrificed.

It is true that a few inches more or less of the arm or leg, for instance, may make no great difference in the usefulness of the stump; it is quite otherwise when the question is that of amputating im-

mediately above or below the elbow or the knee, or through them. Nor do rules of conservation apply with equal force to the foot and the hand.

Injuries of similar degree affecting the upper or lower extremity demand different treatment, because of the much greater freedom of collateral circulation in the former, rendering gangrene less probable.

Where conservatism or ex-

cision would be proper in the upper extremity, amputation would be called for in the lower limb.

Extensive comminution and loss of bone of the foot may demand amputation because, if saved, the member may be useless as a means of locomotion, and should give way to a vastly more useful artificial limb.

Great laceration of the soft parts of the foot, with free comminution of bone and injury to vessels, always demands amputation; for the destruction of the skin of the heel and sole will result in a cicatrix which can never bear the weight of the body and may never be anything but a source of suffering and discomfort to its possessor.

But, aside from these exceptions and others to be noted, the rule



FIG. 75.—Ball of gauze for support of fingers.
(Marsee.)

holds in this class of injuries, to avoid amputation and devote one's skill to preventing infection. The prevention of infection is the *sine qua non*; if the efforts in this direction are going to be half-hearted, it is better to amputate at once.

Immediate amputation, again, is indicated if the wound is seen some hours after the accident, and is found soiled and dirty and manifestly infected.

Under these conditions, conservation is not the best course, for there are too many chances that the attempt at disinfection will fail; that, in spite of the best efforts, sepsis will arise.

Or, if there are already present

the symptoms of dangerous sepsis, it is no longer a question of saving a limb, but of saving a life, and it will be the part of conservatism to amputate well above the suspected level.

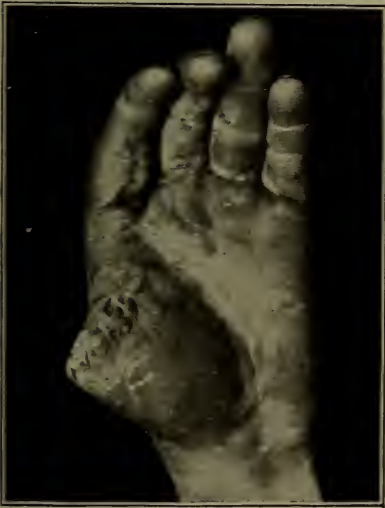

FIG. 77.—Same. Amputation completed. (Marsee.)

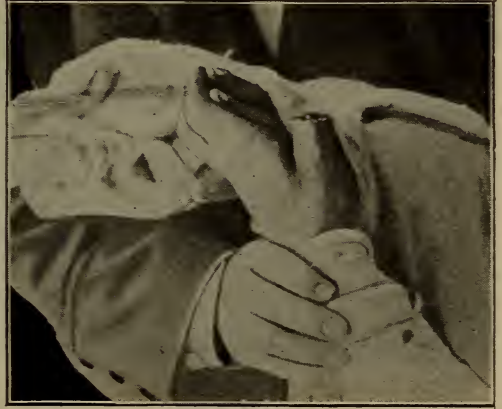

FIG. 76.—Thumb pinched off leaving square-ended stump. (Marsee.)

With regard to the conservative treatment of these severe crushing and lacerated injuries of the hands and feet which most surgeons would be prone to amputate, Reclus, of Paris, has emphasized the value of thorough and patient disinfection of the skin and then of the wound, together with a trimming away of the devitalized fragments of skin and bone. He then "embalms" the member in gauze saturated with an anti-septic pomade, crowded into all the recesses of the wound, and the whole

covered by a thick dressing of absorbent cotton and bandaged. This dressing is left undisturbed until repair is complete, unless the temperature should rise or a disagreeable odor develop.

Joseph Marsee (Ind. Med. Jour., April, 1896) has made some useful observations with respect to the *treatment of common injuries of the hand*, which are well worth repeating and which, as he points



FIG. 78.—Amputation of index finger. Head of metacarpal retained. (Marsee.)

out, appeal especially to the young man just beginning his life's work, for such will probably constitute the bulk of his surgical practice for some years. There is a natural tendency, in the popular mind, to measure an injury by the size of the member involved, and the man who would insist upon the best advice in other cases, will fly to the nearest doctor's sign when "only a

finger" is involved. But Marsee concludes, from his own experience, that the young practitioner is an accomplice in spoiling a good many hands before he learns to do them justice. On the other side, it is not too much to say that the best human skill is none too good when employed in repairing injuries of the most mechanically perfect human member.

The majority of these injuries occur in workers with machinery; the hand, therefore, is always soiled and generally greasy. This grease must first be removed. Nothing is better for this purpose than ordinary gasoline or benzine, which may be poured into the hand directly from the bottle. The fluid will find its way into the smallest recesses of the wound, washing out the grime and preparing the way for the other antiseptics. The benzine is poured on until

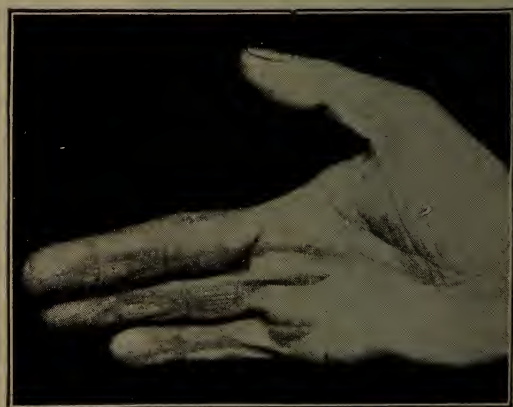

FIG. 79.—Amputation of index finger. Head of metacarpal removed making much more sightly hand. (Marsee.)

all the grease is removed, and the disinfection is completed in the ordinary way.

Even slight wounds of the fingers and palms should be treated by enforced rest by a splint or plaster-of-Paris dressing, complete enough to preclude all motion. This prophylaxis is not regarded as unnecessary by those who have seen the most marked deformities, the gravest constitutional disturbances, and even death, result from trifling wounds of the hand. Enforced rest which leaves nothing to chance, to caprice, or the patient's meddling is alone reliable. Under such treatment, the rapidity with which alarming symptoms sometimes disappear is truly remarkable. If a plaster

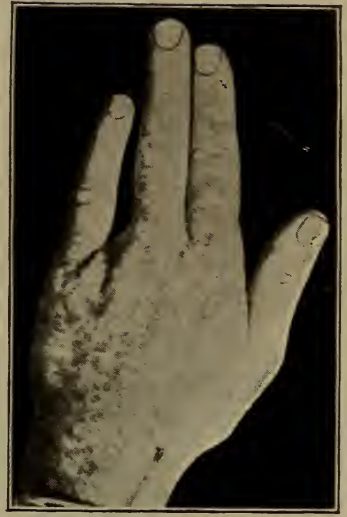

FIG. 80.—Loss of ring finger.
Dorsal view. (Marsee.)

casing is used, it should extend from several inches above the wrist to the extreme tips of the fingers, the thumb being also enclosed if necessary.

When finger wounds are extensive and parallel with the long axis, it is better not to suture them at once, for the swelling will generally be extensive and the stitches will cut out. After the inflammation has subsided, the edges may be freshened and approximated. Nor does Marsee advise immediate splinting in the case of crushing injuries of the fingers, for fear that the circulation may be interfered with. However, that the crushed member may not be wholly unsupported, a soft ball covered with cotton and wrapped with gauze is applied to the palm so that the

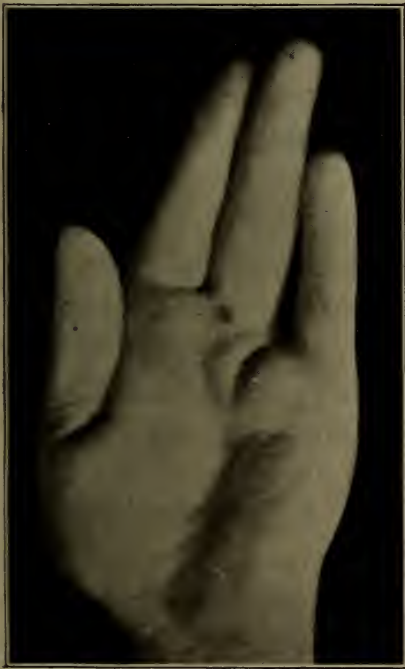

FIG. 81.—The loss of the ring finger is hardly noticed when the distal half of the metacarpal bone is excised. (Marsee.)

fingers may be spread out over it comfortably (Fig. 75), and the whole dressed with absorbent cotton and lightly bandaged. The ball, as Marsee indicates, though unsightly and bulky, has no other fault; it is light, absorbent and wonderfully comfortable, and needs only a trial to be appreciated and adopted. It should be used until the tissues are beyond danger, though it takes several days, a week or a month. No time is lost, for healing cannot begin until vitality is restored, and this will always be slow in such cases, a

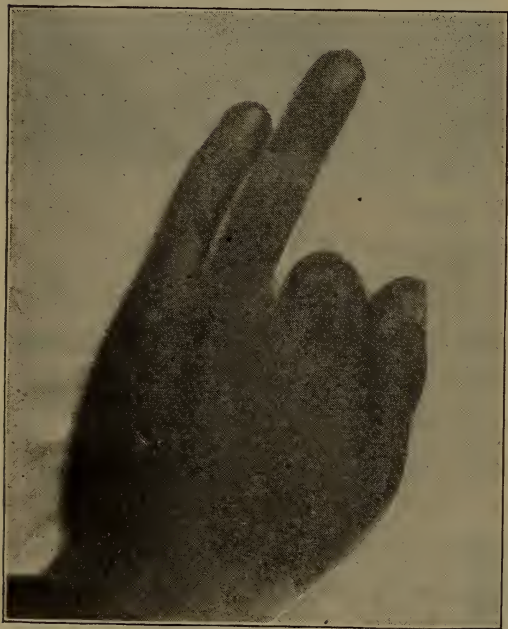


FIG. 82.—The stump of the index finger falls away from thumb when head of middle metacarpal has been removed. (*Marsee.*)

fact which should be brought thoroughly to the patient's knowledge from the beginning, that the doctor may not be blamed for the tardy convalescence.

With regard to methods of amputating fingers, opinion is divided on the question as to which is the more desirable, a palmar flap, or a slightly longer finger with a dorsal flap covering the stump.

There can be no doubt that a palmar flap is desirable, and Marsee believes in securing it, even at the expense of sacrificing more of the finger. If more than half the phalanx is gone,

it is always better, in his opinion, to amputate at the joint line and thus avoid a flexed stump.

If a portion of the distal phalanx remains, the nail should be removed and the matrix dissected before the flap is adjusted, or some deformed fragment of nail may be left to vex the patient. It is better, in removing a finger at a joint, to cut off the knobby projections of the condyles on the palmar surface and to scrape off the exposed cartilage.

If the finger is pinched off squarely, one must always insist in removing enough of the bone to give a good flap, for if the patient has

his way and the stump heals by granulation, the result will be unsatisfactory and the doctor, eventually, will have to bear the blame (Figs. 76, 77).

If the whole finger requires amputation, the head of the metacarpal bone will require special attention and the procedure will be different with the different fingers.

Remove the heads by oblique section in the case of the index and little fingers (Figs. 78, 79). Generally remove the head of the metacarpus in the case of the ring finger, cutting back far enough to let the heads of the adjacent bones fall together (Figs. 80, 81).

Do not remove the metacarpal head of the middle finger unless the appearance of the hand is the chief consideration. Marsee states as the reason for this, that it tends to let the other fingers fall away from the thumb and thus interferes with ready apposition (Fig. 82).

WOUNDS OF THE VULVA AND VAGINA

The chief danger in wounds of these parts is hemorrhage, especially when the vulva is involved and its venous plexuses torn. These wounds may be contused, lacerated or punctured, and more frequently occur from falls astride some object, and by that means the bulb of the vagina is crushed against the ramus of the pubes.

Forcipressure and ligation may be ineffectual to control the bleeding and often the only recourse is tamponade, first disinfecting the wound and the region adjacent, and afterward applying a T bandage and bringing the thighs firmly together.

Perforating wounds of the vagina call for a most careful examination, for not only may the vaginal walls be involved, but the rectum, bladder, or peritoneum as well. Careful suturing is here the best means of controlling hemorrhage. Peritonitis may result from such injuries or more remotely, fistulæ or astresia of the vagina.

Any serious hemorrhage following coitus calls for an examination. It may ensue from a tear of the hymen, or of the posterior wall of the vagina. Cases are on record in which the tear penetrated the rectum.

Deep suturing serves at the same time to control hemorrhage and to promote repair.

WOUNDS OF THE PENIS, SCROTUM AND TESTICLE

The *penis* may be fractured nearly always during coitus and in the subjects of a previous gonorrhea which has produced an area of least resistance in some of the peri-urethral structures. Usually the corpus spongiosum is torn.

Immediately the organ becomes flaccid but within a few minutes again enlarges, this time due to the edema. The extravasated blood produces at once the great discoloration and the acute flexure which is typical.

Unless the extravasation is very large and progressive, there is nothing to do but to bandage the organ and put the patient at rest.

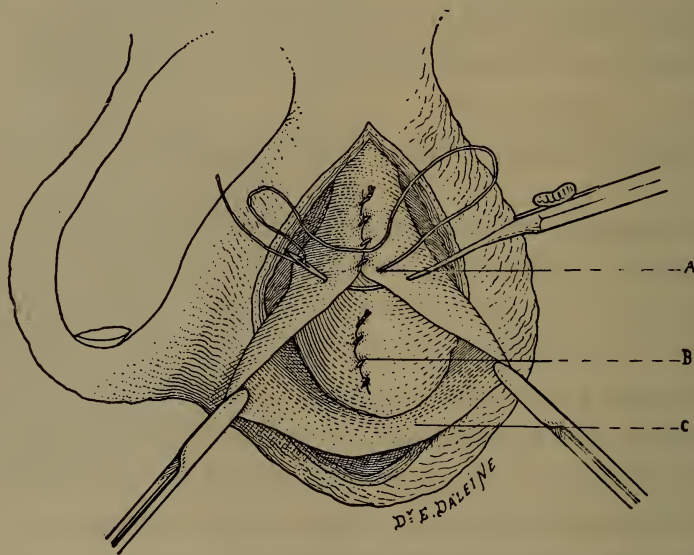


FIG. 83.—B, wound of testicle repaired. C, Tunica vaginalis. A, Beginning its repair.

Otherwise it will be necessary to expose and suture the break in the corpus cavernosum and this Legueu advises as likely to give the best functional result. But with such a procedure one may expect a severe hemorrhage. Open wounds of the erectile tissues of the corpora cavernosa or corpus spongiosum may be expected to bleed freely. It is usually advisable to pass a sound to determine the integrity of the urethra, suturing it first, if involved, and then carefully coapting the erectile tissues.

In the case of wounds of the *scrotum* merely the integuments may be penetrated, or more deeply the tunica vaginalis or the testicle as

well. It must be remembered that any considerable wounding of the tunica of the testicle may result in hernia of the parenchyma.

The scrotal tissues must not be roughly handled in cleansing, and the sutures must not be too tight, for there is a tendency to edema and sloughing. The repair of these various structures must be conducted separately.

If the tunica vaginalis is opened up and the testicle herniated, it must be carefully cleansed and returned and the tunica sutured, with or without drainage, depending upon the probabilities of infection. If the tunica be destroyed, and the testicle remains sound

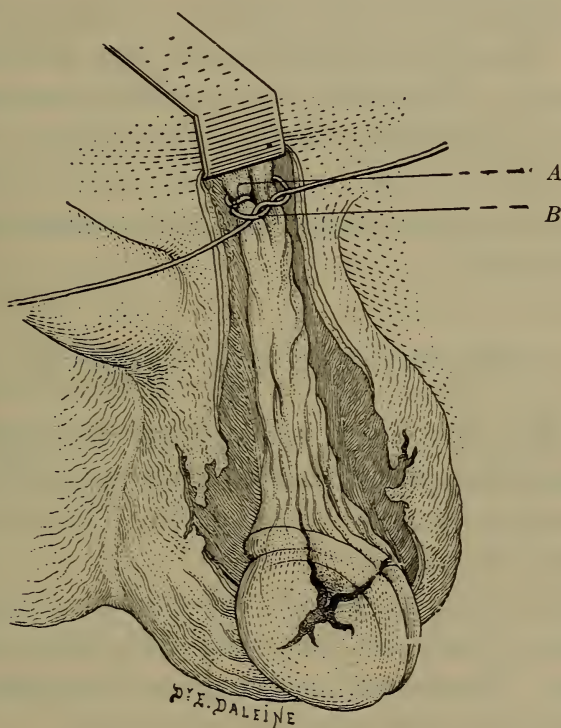


FIG. 84.—Emergency castration. A, transfixion of the cord and ligature of one-half. B, ligature carried around the entire cord. (*Lejars.*)

it must be preserved, covering it as much as possible with such serous covering as remains. Incised wounds of the testicle call for suturing of the fibrous coat with catgut.

The tunica vaginalis is next repaired with a continuous suture (Fig. 83), and finally the scrotal wound is sutured.

If the *testicle* is lacerated, or if seen late and manifestly infected, it must be removed without delay. Enlarge the wound, exposing

the spermatic cord as high up as possible, and at that level ligate the various elements separately and firmly, and resect. Trim away any infected tissues in the scrotum and repair, employing drainage (Fig. 84).

Cotton, of Boston (Amer. Jour. Urol., Nov., 1906), describes a case of injury to the testicle resulting from a blow on the scrotum by a batted base-ball. Shock and excruciating pain ensued, gradually subsiding coincident with the development of a large scrotal hematoma.

Operation. The superficial tissues were infiltrated with blood. A rent an inch long in the tunica vaginalis. Bleeding from the spermatic artery. The tunica albuginea was torn in shreds, the parenchyma destroyed. "The testis had evidently exploded under the swift impact, as a full bladder bursts under a blow." After removal of clots and irrigation, the tissues were sewed up layer by layer with catgut and without drainage, and light pressure applied. Convalescence uneventful.

WOUNDS OF THE RECTUM

Wounds of the rectum are rare. They are usually punctured wounds due to falling upon pointed objects, gunshot wounds, or tears accompanying fractures of the pelvis. The chief dangers are hemorrhage and infection.

Wounds of this region are usually self-evident, though their extent may be a matter of doubt, so that every such injury demands a careful examination. The examination calls for *inspection*. To depend upon touch alone may lead one into grave error.

In every serious injury of this character, anesthetize the patient, dilate the anus, and by the use of retractors *expose the wound*. Douche with hot normal salt solution. If the hemorrhage persists, the bleeding points are to be clamped with long forceps and an attempt made to suture en masse, for at that depth it will be hardly possible to ligate the vessels. Sometimes in lacerated wounds, the oozing can be controlled only by tamponing the rectum firmly, packing around a large tube in the center.

Suturing these wounds is not so desirable as one might at first

think, for the sutures may conduct sepsis to the deeper tissues. Do not suture, then, unless the wound is easily accessible, recent and clean. If the sutures are used, frequent irrigations of normal salt solution must be employed and the bowels kept quiescent for several days.

If the rectal wound has *penetrated the peritoneal cavity*, which fact may develop in course of the examination, or may be suspected from the tympanites and tenderness of the abdomen, the better plan is to proceed to a laparotomy. A patient seen recently had lain for two months with a low grade of sepsis following a punctured wound of the rectum. He recovered promptly after a laparotomy exposed and repaired a rectal tear, opening into the pelvic cavity.

The abdomen is to be opened in the middle line, the patient put in the Trendelenburg position, the pelvis cleansed, and the wounds repaired by two tiers of sutures.

If the small intestine should become herniated through a rectal tear, laparotomy is again indicated, reducing the hernia by traction from above. If the herniated loop protruding from the anus be gangrenous, in order to avoid infection of the peritoneum the affected segment should be resected and the two ends temporarily ligated before proceeding to the laparotomy. Once the abdomen is opened, the two ends of the bowel are to be pulled up and anastomosed.

CHAPTER XI

INJURIES TO THE TRUNK

INJURIES TO THE THORAX

Certain elementary notions must be clearly comprehended and kept in mind in order to make a definite diagnosis of these injuries. These notions relate to the anatomy, pathology, and symptomatology of the thorax. With respect to the anatomy, one must keep in mind the location of the principal vessels of the chest wall and mediastinum; the relations of the viscera to the ribs; and the normal areas of resonance and dullness. In addition, it is necessary to recall the signs and significance of the principal primary complications possible in any form of serious violence to the thorax, viz.: hemoptysis, hemothorax, pneumothorax, emphysema, and hemo-pericardium.

The various points of anatomy and physical diagnosis, elementary though they be, it were perhaps better to enumerate in more detail.

The *principal vessels* of the chest wall are the intercostals which, protected from injury, lie in the groove in the lower border the rib; and the internal mammary $1\frac{1}{2}$ inches from the sternal border, easily reached by a stab. The intercostal may be compressed in the manner indicated on page 68. If a general anesthetic is necessary for another purpose the artery should be exposed and ligated.

The wounded internal mammary requires ligation and is most easily reached through the second or third intercostal space, lying in close contact with the pleura.

The *relations of the viscera* to the chest wall acquire a special significance in connection with traumatism, particularly such perforating wounds as those produced by pointed instruments and the bullet.

Imagine the track of the bullet under a variety of circumstances: passing through the right chest antero-posterior, anywhere between its apex and the level of the nipple only the lung will be injured;

below that level, the diaphragm and liver are likely also to be perforated. Outside the nipple the range may be lower and yet escape the diaphragm since it slopes from the level of the nipple to the eighth rib in the axillary line.

In the left chest, in the area bounded by the second rib, the sternum, the sixth rib below and the nipple line externally, the heart or at least the pericardium is likely to be wounded, and, unless the track lies near the sternal line, the lung as well.

Outside the nipple line and below its level, perforation of the stomach may complicate the lung injury.

Passing transversely through the base of the chest, below the nipple line we might expect the wound to traverse successively from the right side, the lung, the liver, the stomach, the spleen and the lung again.

The principal primary complications:

Hemoptysis, following an injury to the thorax, whatever its nature, is significant of one thing—that the lung has been involved. The degree of injury may be in a manner estimated by the amount of blood expectorated. In the dangerous cases, the blood pours from the wounded lung tissue into the bronchus and gushes from the mouth. In other cases, there is only a slight spitting of blood, leading to the belief that the lung has not been seriously torn. It might be mistaken for a hematemesis, but the presence of râles in the bronchus of the affected side (or of both) and the light color of the blood and its admixture with air, point to the character of the hemorrhage.

Hemothorax, an accumulation of blood in the pleura, is nearly always the result of injury to the lung; although, of course, the internal mammary artery or the intercostals may occasionally be the source of the extravasation. Gravity determines where the blood will accumulate and therefore the patient's position will modify the physical signs.

The *symptoms* and *signs* are both modified by the quantity of blood and the rapidity with which it is poured into the pleural cavity. In the slighter forms, there is scarcely any disturbance of breathing and only slight dullness over the base of the lung.

In the graver forms, the lung is collapsed and crowded toward the hilum, so that there are symptoms of asphyxia added to those of in-

ternal hemorrhage. The face is pale, the skin moist and cold, the patient is impelled to sit up and gasps for breath, the pulse is rapid and thready, and the patient may thus go on to death. Inspection reveals a slightly bulging chest wall; percussion, a complete dullness, and auscultation, an absence of fremitus and of the vesicular murmur.

Often there is an immediate rise of temperature, due to absorption, and which is to be distinguished from the temperature of infection by its earlier appearance.

No attempt to evacuate the extravasated blood is to be made in the moderately severe cases; in others, of more urgency, an aspiration may give some temporary relief, tiding the patient over a critical point. Finally, in rare cases, the magnitude of the hemothorax will be such as to demand an immediate intervention, with the purpose in view of exposing the lung and repairing the wound in its substance. Subsequently, even if the case is mild, infection may occur and is to be treated as any other empyema.

Pneumothorax.—Air may enter the pleural cavity from without through an opening in the chest wall, or from within through a rupture in the lung tissue. In the first case it enters during inspiration, and in the second, during expiration.

The physical signs and symptoms grow out of the pressure within the pleural cavity and the consequent collapse of the lung. The chest wall on the injured side is distended, the intercostal spaces bulged out, the viscera are displaced, the ribs motionless, the vesicular murmur absent. If a coin laid on the front of the chest is tapped with another coin, the sound will be heard at the back. The symptoms are principally those of dyspnea.

If there are no complications, the air is gradually absorbed and the function of the lung restored.

In extreme cases, puncture will relieve the intrapleural pressure; and in the case of a valvular wound in the chest wall, which permits entrance of the air but not its exit, enlargement of the wound is indicated.

If air and blood accumulate simultaneously—if a *hemo-pneumothorax* exists—the physical signs will be altered, but not the symptoms.

Emphysema.—The subcutaneous cellular tissue may become charged with air and practically the whole body be involved. It is nearly always due in the marked cases to puncture of the lung by a broken rib. The air escaping from the lung is prevented, by the close contact of the pleural surfaces, from entering the pleural cavity, and is forced into the loose tissues of the ruptured chest wall.

In other rarer cases the inner aspect of the lung is wounded, and the air escapes into the tissues of the mediastinum, and follows them up into the neck.

In ordinary cases no treatment is indicated and the air is soon absorbed. However, in the severer forms, the symptoms of asphyxia and cyanosis may supervene and then free incision over the infiltrated zone may be required.

A man weighing 300 pounds was brought into the City Hospital with a crush of the chest, fracturing several ribs. Within a half hour after the accident the tissues of his whole chest were inflated and gradually the emphysema spread till his skin from his face to his feet seemed as tight as a drum. His condition was pitiable; his eyes were swollen shut, his features livid, and his efforts to breathe distressing. An effort was made to strap his chest; morphin and atropin in small doses were frequently administered, and the tissues over the chest punctured with numerous small trochars which were left in situ. In forty-eight hours his pulse and respiration began to improve and in a few days he was entirely out of danger.

A case of subcutaneous and mediastinal emphysema of extreme gravity was relieved by incising without anesthesia, the skin and fascia above the clavicle and dissecting the fascias with finger down to the wall of the trachea. A suction apparatus was attached and the air escaped in a continuous stream relieving the symptoms rapidly; subsequently a valve drainage of the pleura was established to relieve intrathoracic tension and the patient made a smooth recovery. (*Amer. Jour. Surg.*, Oct., 1913.)

Hernia of the lung is a rare complication, and may be immediate or secondary. In the first case, the pulmonary tissue is forced through the breach in the chest wall by violent expiratory effort. In some cases where the skin is not broken, the hernia may be felt as a crepitant tumor beneath the skin.

In the secondary cases, it forms more slowly, and is often due to the weakening of the thoracic wall by inflammatory processes.

Hemo-pericardium.—Blood in the pericardial sac follows injury to the pericardium. It develops more rapidly and, of course, the outlook is much more grave if the heart is also wounded.

The symptoms are those of syncope induced by the compression of the heart by the accumulated fluid; the signs are those of increased cardiac dullness. The apex beat is lost, the heart sounds muffled, the precordium bulged. It is upon the signs that one must depend for the diagnosis, for the symptoms are often complicated by those of shock and by those which originate in other injuries in the thoracic region.

To repeat, then, when you reach the patient suffering from some form of chest injury, you will observe the character of his respiration and his pulse; whether his condition is immediately serious or not is to be determined at once by that means. If the circumstances permit, you will proceed to a systematic examination. Learn from the sufferer the location of his pain and the character of his chief distress. Note the appearance of the sputum, if there is cough. Inspect the chest wall for change in outline and mobility and location of apex beat. Determine by percussion the limits of the lung resonance and heart dullness; and by auscultation, the presence or absence of the vesicular murmur or of râles.

The case may be so grave that exact diagnosis is unnecessary; or, again, it may require the most minute examination and judicious weighing of the symptoms and signs to make a correct forecast of the eventualities, and to formulate a treatment which will leave nothing to regret.

CONTUSIONS OF THE CHEST

Simple contusions of the thorax, without fracture of a rib or the sternum (which are considered elsewhere) and without symptoms pointing to internal injury, need but brief consideration. A hematoma is likely to form. The pain and soreness disappear rapidly in the young, but are extremely persistent in the aged and the rheumatic. Strapping and massage with liniment are usually sufficient.

On the other hand, following simple contusion, there may be a degree of shock out of all proportion to the trauma.

A man of thirty, apparently in good health, received a slight blow over the chest in a friendly scuffle. The blow was slight, and yet it seemed to touch a vital spot and made him gasp for breath. It was with difficulty that he reached home and for two weeks he seemed upon the verge of a pneumonia. A month later he was still unable to work and an examination at this time revealed grave organic lesions of the heart. It was greatly dilated and not a single valve seemed to be performing its function fully. In spite of rest and treatment, his condition gradually grew worse, and in six months he died with a general anasarca. We must consider that the *heart*, as well as other organs, is liable to *contusion* and that from such injuries acute endocarditis may result.

In *graver contusions*, such as crushing injuries, it is *rupture of the lung* which is always to be feared and which is usually evidenced by a large hemothorax. It must always be remembered that such an injury may occur without fracture of the ribs or sternum.

Lejars cites the case of a boy eleven years of age, whose chest was run over by a wagon. He arose immediately after the accident, but fell again unconscious, with blood pouring from mouth and nostrils. This hemorrhage did not long persist, but on the fourth day the temperature rose and he was taken to the hospital. His condition was alarming, the pulse weak with a rate of 104, his face cyanosed and the dyspnea intense; his heart was displaced to the right, and on the left side were the signs of marked hemo-pneumothorax. A puncture removing 180 G. of the exudate gave but temporary relief. The pulse continued to grow weaker and the dyspnea more intense, and an urgent intervention was indicated. The pleura was opened and the lung found retracted toward the hilum. In the upper lobe a tear was found, 7 cm. long, and running upward, and backward from the cardiac incisure. The wound gaped freely. The lung was drawn into the opening in the chest wall, and the pulmonary wound repaired with five sutures of silk which included considerable tissue to prevent their pulling out. The coaptation was perfected by a few superficial sutures. The upper lobe was sutured to the parietes and a tamponade with gauze completed the operation.

The outcome was unfortunate, for death occurred on the second day, but the autopsy found the lips of the lung wound well agglutinated. There was no costal fracture.

The *symptoms of rupture* of the lungs are the same whether a rib be broken or not: hemo-pneumothorax, abundant and increasing; a spreading emphysema; symptoms of grave anemia; to all these may be added more or less quickly, the symptoms of pleural infection.

The *treatment*, except in the cases of extreme urgency, must be conservative and expectant. Shock must be combated, the patient kept absolutely quiet, and the dyspnea relieved by the sitting posture, and, if possible, by inhalations of oxygen.

The anemia can be relieved by injections of small quantities of normal salt solution frequently repeated.

A puncture will partly empty the pleural cavity, affording great relief; and, eventually, the remaining exudate will be absorbed.

It may happen that after two or three days the symptoms will improve.

But in the worst cases, where the dyspnea is progressive and menacing, and the heart rapidly growing weaker, the responsibility cannot be shifted. It is indicated to operate at once, to open up the thorax and repair the tear in the lung, to do an urgent thoracotomy (see page 488).

OPEN WOUNDS OF THE THORAX

Non-penetrating wounds of the chest wall are of slight significance and are to be treated on general principles.

Penetrating wounds of the thorax derive their significance from the particular viscera and vessels which may happen to be involved. On the clinical basis, then, these wounds may be divided into three classes:

- A. Wounds which involve the pleura or lung.
- B. Wounds which involve the diaphragm.
- C. Wounds which involve the pericardium and heart.

A. WOUNDS OF THE PLEURA AND LUNG

In whatever manner the wound may be inflicted, there are three elements of danger: hemorrhage, asphyxia, and infection. These are

the factors which will determine the line of treatment, and without some urgent indication from one of these sources the treatment must be conservative. There are many things which stand in the way of radical procedures such as are employed in the case of abdominal wounds. In the first place, the operative technic is difficult; there is a marked disturbance of respiration following free access of air to the pleural cavity; the exact location of the lung lesion cannot often be determined; and, finally, there is always, as Lejars remarks, so much guesswork in the prognosis, that we are constrained to give the patient the benefit of the doubt and leave the case to take its natural course.

It is best to proceed in this wise: If the case is seen from the first, supervise the transportation. Too much importance cannot be attached to the dangers of rough handling. As has been said elsewhere, the nearest shelter is the best. Cut away the clothing, scrub the skin adjacent to the wound, and wash out the wound itself with alcohol or sterile salt solution. If, on opening the lips of the wound, a bleeding point is seen, catch it up and ligate.

If there is oozing from the depths, it is best to disregard it for the present. This constitutes the primary intervention except for such suturing as may be required.

Apply a dressing of sterile gauze, plain or soaked in collodion. Cover this with a layer of absorbent cotton and apply a firm bandage encircling the whole chest. Place the patient on his back with the head and shoulders slightly elevated. Absolutely prohibit conversation and movement of any kind; and, in the meantime, keep the patient under close surveillance.

In general terms, then, the treatment of any ordinary open wound of the chest involving the lung and pleura is to be summed up in two words, *immediate occlusion* and *immobilization*.

But there are conditions which demand *immediate intervention*. These are acute anemia or asphyxia, which may follow hemorrhage, external or internal; and hernia of the lung.

External hemorrhage may follow any extensive wound of the chest wall, welling up from its depths or flowing by spurts during expiration. If there is no hemoptysis, it may be inferred that the lung is not wounded; but, in any event, the first treatment must be directed to-

ward the intercostals and internal mammary. It may be that a temporary hemostasis will be necessary, and the tamponade described on page 68, will be indicated.

The definite hemostasis requires a free enlargement of the wound. If pressure made against the lower border of the rib by an aseptic finger introduced through the enlarged wound causes cessation of hemorrhage, it is certain that it is an intercostal artery that is at fault. It may be difficult to clamp; it may be necessary to resect a rib, or to detach the periosteum, which will carry the artery with it. A curved needle threaded with catgut is then carried around the artery. The ligature is tied and the hemorrhage thus controlled. The internal mammary may require ligation above and below the wound.

Internal hemorrhage is in every way more serious, for to the anemia is added the asphyxia which follows the compression of the lung.

The patient is pale, anxious, with cold extremities, weak pulse, and sighing respiration, the chest wall bulges; the normal resonance and vesicular murmur are altered; in short, there are all the signs and symptoms of an increasing hemothorax or hemo-pneumothorax.

But even in the presence of these grave symptoms, it is by no means always indicated to operate. One must be content to repair the wound, occlude and immobilize, and wait awhile.

But when the wound is followed by an immediate and complete hemothorax, or when the symptoms and signs point to a rapidly approaching fatality, one must stand by with folded hands and see the end come, or *operate*; for there is nothing else of any use. An urgent thoracotomy must be done.

Hernia of the lung is rare. The tumor is of variable size and is at first crepitant, but rapidly darkens and becomes hepatized.

The indications for treatment depend upon the time which has elapsed and upon the condition of the tumor. If the *wound is recent* and the lung intact, the hernia must be reduced. Begin by a careful disinfection of the wound. Cover the tumor with an aseptic compress and tuck its edges under the whole circumference of the wound. A steady pressure over the central portion of the tumor will expel the air little by little; and, by reducing its volume, favor the reduction of the tumor.

The compress is to be left until the skin wound is partially sutured, since by that means one may prevent the sudden pneumothorax which sometimes follows reduction.

If the lung has been wounded, it must be repaired by suture, or by ligation and resection before being reduced.

If *some time has elapsed*, it is as unsafe to reduce it as to reduce a doubtful herniated gut.

Lejars insists upon resection with the thermocautery. Around the base of the tumor pass a ligature threaded on a blunt needle. By tying the ligature, a pedicle is formed which is to be amputated with the thermocautery. The stump is carefully disinfected and reduced, the chest wall repaired, and drainage instituted.

Finally, in the case where the *tumor is already gangrenous* and sloughing, it is necessary to limit the treatment to antisepsis, leaving the slough to detach itself, and happily a cure may follow such spontaneous amputation.

Axtell reports a case of open wound of the chest which illustrates what the doctor's patience and nature's efforts may accomplish in conditions apparently most desperate. (*American Jour. Surg.*, Feb., 1909).

A shingle sawyer of twenty-eight, robust and muscular, fell against a great circular saw revolving many thousand times per minute. Sections of the second, third, fourth, fifth and sixth ribs were cut away, these segments varying in length from 1 inch at the second to 3 inches at the fourth and fifth ribs. The costal pleura was completely destroyed over the seat of the greatest injury. The lung and pericardium were exposed. There was one puncture of the lung from which the air bubbled and emphysema followed. All the intercostal arteries, veins, and nerves in the injured area were severed. The pectoralis major was completely separated from the chest, and a part of the pectoralis minor. The wounded man, thrown from the saw, fell face downward into a dust pile and the whole exposed surface of the wound was filled with sawdust and grease.

He was carried to the hospital and attempt made to repair the damage. "Over 450 spiculæ of wood fiber were picked out piece by piece from the chest cavity and the surface of the lung. Several large lumps of greasy dust were removed from the depths of the chest

cavity." All the ragged edges of the costal pleura, skin, and muscles were trimmed away. The jagged and uneven ends of the severed ribs were cut off smooth in order to bring the periosteum over them. To take the place of the costal pleura destroyed, a flap was stripped off the pectoralis major from near its attachment to the humerus; left attached near the free end of the divided muscle, it was turned forward toward the sternum and sutured to its margin, to the intercostal muscles, and the periosteum of the stumps of the ribs. The severed muscles were drawn together by cable sutures and the skin flap drawn into place and incompletely sutured. Ample drainage was installed. The intervention consumed several hours, something like 180 sutures and ligatures being required. The emphysema was enormous at first, extending from the scalp to the knees, but disappeared after forty-eight hours. At the end of six weeks the patient had practically recovered without adhesions or restriction of the lung.

B. WOUNDS AT THE BASE OF THE THORAX

Wounds at the base of the thorax require a separate consideration, for the reason that both the thoracic and abdominal cavities may be involved through wounds of the diaphragm.

It must be remembered that the diaphragm corresponds to the level of the fifth rib in the right nipple line, and to the level of the sixth rib in the left.

In stab or gunshot wounds, the lung on the one hand, and the stomach, intestine, spleen, and liver on the other, may be wounded simultaneously; so that, compared with the thoracic wounds just considered, those at the base are much more complicated with respect to prognosis, diagnosis, and treatment.

These wounds at the base of the thorax involving the diaphragm, will nearly always present an omental hernia. It is often necessary, after enlarging the thoracic wound by resecting a rib or forming a costal flap, to resect the protruding omentum; and, at the moment of reduction of the stump, one may have an unobstructed view of the wound in the diaphragm. If blood oozes from it, there is abundant evidence of a wound of an abdominal viscus. If there is no bleeding, introduce a finger through the opening in the diaphragm and examine

the stomach and adjacent structures. If no injury is found, and the examining finger is not covered with blood, proceed at once to repair the diaphragm.

A curved needle is best, and interrupted sutures. If there are wounds of the abdominal viscera, they may possibly be repaired through the phrenic wound; and, in fact, if at all possible, it is the method of election. By this route one may readily reach the convex surface of the liver on the right side, or on the left the greater curvature of stomach.

Still, if the exploration is difficult, if the bleeding is abundant, it is better to lose no time, but to do a median laparotomy at once, gaining additional room, if necessary, by a transverse incision, following the costal arch. Subsequently the wound in the diaphragm may be repaired through the thoracic opening.

Ludlow, of Cleveland (*Annals of Surgery*, June, 1905), reports a case which illustrates this subject and exemplifies the treatment in general.

The patient had received two stab wounds in the left side, inflicted with a candy maker's knife which had two blades set in a heavy handle. One wound entered at the ninth interspace in the axillary line, and through it protruded omentum. The blade had entered the chest wall obliquely and the skin acted as a valve; but, when the skin was retracted, the air rushed in and out of the pleural cavity with each respiration. The hemorrhage from the wound was slight.

The second wound was situated directly below the first in the eleventh interspace. Omentum protruded from this wound also, and the bleeding was slow, but apparently increasing.

Operation.—Ether anesthesia; a careful cleansing of the field. A digital examination revealed the fact that the upper wound, traversing the pleural cavity without injury to the lung, had perforated the diaphragm. The finger passed through these wounds, met the finger of the other hand passed through the lower wound, in the abdominal cavity.

The lower wound was enlarged, revealing an active hemorrhage from the spleen. The cut surface of the spleen was pulled into the wound and a spurting artery clamped. The splenic wound was

4 cm. in length and extended almost through the substance of the organ.

The cut surfaces were brought into apposition by mattress sutures of plain catgut No. 2, on a curved round needle. This controlled the hemorrhage. Neither by palpation or inspection could any wound of the stomach or intestines be found. The diaphragm was then repaired with chromic gut No. 3. The operation was accomplished without the resection of a rib. A small cigarette drain was left in both wounds and the external wounds sutured. The week following the operation there was some discharge of blood and débris, but no active hemorrhage. The recovery was uneventful and complete.

Wounds of the diaphragm of whatever form, perforations, or ruptures due to crushing injuries to the chest, are likely to be the site of herniæ.

Especially in the latter class of injuries, must one be on his guard for this injury. Sometimes there are certain signs which point at once to the presence of a diaphragmatic hernia; the displacement of the heart, the bulging of the lower intercostal spaces, and the presence on auscultation of sounds which in no way resemble the vesicular murmur. In these cases, it is best to open up the eighth intercostal space and resect the ninth rib, which will usually give a free access to the site of injury.

C. WOUNDS OF THE PERICARDIUM AND HEART

Not every precordial wound will reach the heart. Such a wound may be followed only by a slight emphysema and is to be treated by aseptic occlusion.

If the wound has actually penetrated to the heart, death is usually so rapid that no measure or relief can be considered. If it is a gunshot wound, death results from shock and hemorrhage; if it is a stab or punctured wound, shock plays a very minor part. It is not very likely that any small size stab wound of the heart interferes at once seriously with the heart's action, unless it involves the "coordination center," which, it is claimed, lies in the upper third of the inter-ventricular groove.

If the wound in the pericardium be small or valve-like, the blood is

retained within the cavity and the constantly increasing intra-pericardial pressure effects the softer and more yielding of the structures within the sac—viz., the pulmonary veins and the descending vena cava and the auricles; in this manner, the venous current to the auricles is cut off and the agitated heart works to no purpose. The sense of oppression, the cyanosis, and venous engorgement all bear witness to the compression of the auricles. In the meantime, the pulse grows miserably weak and rapid; the apex beat is lost, the heart sounds are muffled, the pericardial dullness is augmented, and the thoracic wall bulged. In this manner from “heart tamponade,” death soon ensues. If the wound in the pericardium is large and the pleura opened, the hemorrhage rapidly fills the pleura producing hemothorax, scarcely less distressing than the hemo-pericardium.

If the opening in the thoracic wall is free, the hemorrhage is external; the blood spurts from the wound or wells up continuously, uncontrolled by pressure or occlusion, and death ensues from hemorrhage, simply.

In spite of all this, however, a wound of the heart is not to be considered as inevitably fatal and beyond surgical skill. The number of reported cases saved by timely intervention is constantly increasing and will increase all the more rapidly as time goes by. Any wound of the heart sufficiently large to produce hemorrhage, whether external or internal, is potentially fatal.

The only measure of relief is operation. The pericardium is to be exposed and opened, the heart relieved of pressure, and the wound repaired.

The question arises as to how late an operation may be undertaken, but this cannot be answered by a general formula; as long as there is life, there is hope in skillful intervention. In the cases reported, the great majority were operated not later than six hours after the injury.

Regarding the location of the wound in the heart, the right and left sides are injured with equal frequency, but the ventricles are in much greater danger than the auricle in the proportion of seventeen to one (Vaughn). The external wound may be located over any intercostal space, but the great majority will be found in the fourth, fifth, and third in order of frequency.

Vaughn, who has carefully studied the statistics of operations for these injuries, and who reports his second successful case of suture of the heart (J. A. M. A., Feb. 6, 1909), offers the following conclusions: that there is no longer any question as to the propriety of the operation, but that its mortality is probably the same as it was twelve years ago when the operation was first introduced. Probably little more can be done to prevent death from hemorrhage, but the prevention of the great cause of death following the operation, infection of the pericardium, remains a surgical problem yet to be solved. The principles of asepsis and drainage as applied to the operation, are yet to be more carefully worked out.

This summary still holds good at this later date except that there is disposition to extend the indications for operation to those cases in which the nature of the wound presupposes heart injury but in which the classical symptoms have not yet developed. For it is certain that heart "tamponnade" with its concomitant clinical picture is often delayed.

An example is in mind.

A negro was brought to the City Hospital with a stab wound in the fourth intercostal space about halfway between the sternal border and the nipple line. His condition was good except that he had occasional slight attacks of dyspnea; pulse 100, respiration 24. In the course of two or three hours his symptoms had slightly but perceptibly grown worse. He refused operation. From that time, hour by hour the heart dullness increased, the heart sounds altered, the radial pulse weakened the dyspnea became more distressing and finally after thirty hours he died.

The autopsy revealed a small wound of the right ventricle. The only hemorrhage was within the pericardial sac.

An operation at the time of admission or a few hours thereafter would have been performed under very favorable circumstances and almost certainly would have saved the man's life.

On the other side, Wagner reports a stab case presenting all the signs of injury to the heart which an operation proved to be intact, although blood had accumulated within and around the pericardium. The man would undoubtedly have recovered without operation but

the case would have gone on record as one recovering from stab of heart under conservative treatment.

Arx reports a case in which the pain and physical signs pointed to injury to the diaphragm and liver, but a laparotomy proved them to be intact. The heart was exposed, revealing a hole in the right ventricle far under the sternum. When the pericardium was opened and the clots released the heart improved at once. In this case the heart wound was not sutured but was covered with a strip of gauze which was brought out through the closely sutured wound. The pulse kept between 80 and 88 and the temperature remained normal. Arx remarks that this case emphasizes the value of proper drainage (J. A. M. A., Aug., 1913).

A number of cases of needle punctures of the heart have been reported. About 60 per cent. die, the result of intra-pericardial hemorrhage occurring within ten days of the accident.

INJURIES TO THE ABDOMEN

I. Contusions. II. Wounds.

I. Contusions of the abdomen occur in many ways; they may be the result of severe blows, the kick of a horse, from falls, or from the crush of heavy wheels of vehicles. The gravity of such an injury is proportionate to the amount of visceral injury, but this is often not apparent from the first.

Whether the viscera are injured or not, there is always some degree of *shock*. In the first hours following the injury, in the doubtful cases, the therapeusis must be limited to the treatment of shock. If transportation is necessary, it must be done with the greatest care.

Once the patient is placed in bed, his clothing must be removed, his head lowered, the extremities kept warm, and repeated injections of normal salt solution or adrenalin made, as the character of the shock indicates.

In the meantime, the case is to be studied and it is to be decided whether or not there is a *rupture* of an *organ*, or other source of hemorrhage.

The responsibility is a heavy one, for an internal injury overlooked or discovered too late, is likely to result in death. The patient may

rapidly recover from the shock, but this by no means proves the absence of a visceral hurt.

In the typical case of grave injury, the symptoms of shock are only temporarily relieved by the injections; rather, they are shortly replaced by those of internal hemorrhage. The pulse remains small and frequent, the skin cold, the face anxious and drawn. The abdomen is distended, and tender to the least pressure, especially in the zone of direct injury. There may be dullness in the flanks. There is no escape of gas from the bowels, or passage of urine. The patient is restless and frequently sighs, and seems to realize his impending fate.

In such a case, the indications are plain. There can be no excuse for delay, for awaiting the signs that can only be those of beginning peritonitis. Prepare for an *immediate laparotomy*.

But suppose the case is not accompanied by the typical symptoms. How shall we determine in two or three hours whether or not there is a grave lesion? A conclusion must be reached from the study of two factors: (a) the pulse, and (b) abdominal tension.

(a) The pulse, disturbed at first by the shock, rapidly approaches the normal perhaps, but within a half hour or sooner, it can be determined that it is getting weaker and more rapid. Such a change is particularly indicative of hemorrhage. If there is any discrepancy between the pulse and temperature, Lejars insists that the former is the safer guide, for a subnormal temperature resulting from shock may persist long after the other symptoms have disappeared.

(b) The abdomen may or may not be swollen, but over the site of the injury the abdominal muscles soon begin to grow rigid, and resent the least touch, under which they may be felt to contract and stiffen. This rigidity, localized at first, tends to spread and include the entire abdomen.

The tension is usually augmented by *progressive meteorism*, which is also at first localized, but rapidly becomes general.

Dullness in the flanks is a valuable sign when present, but its absence settles nothing. It may be masked by the distended stomach and intestine; again the blood may not collect in the iliac fossa, but may flow directly into the pelvic cavity, especially if the hemorrhage is on the left side of the mesentery.

These modifications of pulse and temperature, of abdominal tenderness and tension, must be taken as sufficient indication for urgent intervention; for the prognosis does not, in reality, depend more upon the nature and multiplicity of the visceral lesions than upon the time of intervention, for every hour of delay adds to the chances of infection and sepsis—elements which the early operation may practically eliminate.

Another eventuality: The case is not seen until infection has fixed itself upon the peritoneum; the pulse is weak and rapid and progressively growing worse; the temperature is subnormal, the extremities cold; a marked tympanites, with persistent vomiting, perhaps comes on.

Then, indeed, it is late to operate—especially when that means a long and tedious laparotomy. Every doctor must answer for himself the question, “Is it *too late*?” As Lejars says, we must extend as far as possible the limits of intervention in such cases, for it is the last resource; and, even though the mortality is very great, the occasional unexpected recovery legitimizes the operation.

Who has not had his sad experiences with these cases? A single example illustrates the subject of *intestinal rupture*. A laborer rolling a log off a wagon was struck violently in the abdomen by the end of his lever caught by the log as it fell.

He was unconscious for a moment then arose, vomited once and after a little rest to get his breath resumed his labor.

After an hour or so, however, he decided he had better go home as he began to feel some pain in the right iliac region where the blow had fallen; six or eight hours later he called his doctor who could find no definite indication of any serious lesion, though the pain had grown very severe.

The next morning twenty-four hours later there was some rigidity, some tympanites, an increase in the pulse rate, temperature 101, complete constipation.

I saw him some sixty hours after the accident. His aspect was typical of peritonitis. He was vomiting bile with a fecal odor. He was quite conscious and expressed the opinion that he was done for unless surgery held out some hope.

He lived far out in the country and it was manifest that he would

not live through the journey to a hospital. His kitchen was hurriedly converted into an operating room and a laparotomy performed. It revealed two small circular openings in the ileum close to the cecal end, a small quantity of the intestinal content free in the cavity and a general peritonitis.

The whole operation did not last forty minutes but the poor man died four hours later.

It was apparent that he had suffered a contusion of the bowel and that subsequently the two small sloughs had occurred and this sequence accounted for the absence of hemorrhage and the small escape of intestinal fluids.

Maurice Kahn emphasizes the necessity of early diagnosis of intestinal rupture and discusses in detail the aids thereto; the part which each symptom and sign should have in this determination: Shock, pain, tenderness, rigidity, vomiting, circulation, respiration, temperature, facial expression, loss of liver dullness. He concludes that if we have the persistence for a few hours of the initial symptoms, especially of rigidity and pain we are justified even in the absence of other symptoms in urging an exploratory operation. (J. A. M. A., March 7, 1914.)

Rupture of the liver in addition to the indications already discussed may have some special features.

In the first place whatever shock there may be is early displaced by symptoms of hemorrhage.

The pulse may be abnormally slow by reason of bile absorption; and the pain is definitely localized in the right hypochondrium.

Much more frequently the tear involves the right lobe.

Rupture of the spleen produces neither the shock, the abdominal tension, nor the early peritonitis which follow rupture of the other viscera. Hemorrhage is the main feature and the severity of the symptoms are in proportion to the loss of blood and usually this depends upon the extent of the laceration. However, even a small cut at the hilum might produce early and urgent symptoms. (See also laparotomy for traumatism.)

II. *Wounds of the Abdomen.*¹—Clinically, these fall into two groups, (a) those in which there is doubtful perforation of the peritoneum,

¹For gunshot wounds, see pages 151 and 192.

and (b) those in which perforation of the peritoneum is quite obvious.

(a) The patient presents himself with a wound of the abdominal parietes, of doubtful depth. It is easy to determine, once for all, whether the peritoneum has been perforated (and upon that the prognosis depends) by passing a probe or grooved director. But one should certainly do nothing of the kind. There is a definite mode of examination to which one must rigidly adhere.

Begin by a hurried inquiry into the circumstances of the injury, and the character of the weapon. Disinfect the hands for an operation. Finally scrub and disinfect the abdominal walls. Not until this is completed, is the wound ready to be examined.

Carefully separate the lips of the wound with finger or retractors; and, as you proceed, carefully wipe each layer as it is exposed. If necessary to facilitate inspection, enlarge the wound; this will often be the case, especially where the vulnerating instrument has entered obliquely.

Dividing the various layers, the peritoneum is reached and found intact; there is no oozing from below the level of the muscular layers, and, if this finding accords with the other signs observed, you may conclude at once that the wound is *non-penetrating*. In such a case, carefully cleanse the wound and repair each layer separately by continuous suture with catgut; the skin with silk or silkworm-gut; cover with sterile gauze, a thick layer of absorbent cotton, and a firm abdominal binder; and thus have been taken the best steps to prevent infection or ventral hernia, which is often the result of these wounds.

If the wound is *penetrating*, the mode of procedure depends upon whether it is (a) a narrow, or (b) a large incised wound.

(a) A *stab wound* is the type—a thrust from a knife, dagger, or bayonet. There may be persistent oozing of blood alone, or blood mixed with bile and urine, or “food products.” Such a mixture is pathognomonic of visceral injury, but nothing can be decided from its absence.

The persistent hemorrhage is strongly suggestive of serious injury to an organ, especially where it coexists with a fading pulse, pallor, tympanites, and rigidity and tenderness of the belly wall; yet the ab-

sence of all these signs gives no assurance of the absence of a visceral injury.

In any event, then, an *exploratory laparotomy* is indicated; for only by that means can one assure himself of the conditions. Ordinarily, the wound itself is enlarged for the purpose of exploration, but in the case of more than one wound, or when the abdominal walls are very thick, it may be advantageous to resort at once to median laparotomy. In either case, the abdominal opening should be large enough for rapid work. If the laparotomy is done at the site of the injury, it will be wise to disarrange the viscera as little as possible, when sponging out the exudates. Carefully inspect whatever parts present, and often the lesion will be revealed by this first search.

If a median laparotomy is done, as soon as the cavity is opened proceed to the site of the injury; cover the adjacent coils of intestine with compresses, thus preventing their possible infection.

The lesions are only rarely multiple or difficult of repair in this class of abdominal injuries.

(b) *Extensive Incised Wounds*.—These wounds are produced by instruments with a long cutting edge, or by the ripping cut of small knives. Horned animals occasionally produce them.

The chief characteristic of these wounds is *eventration*, always present in some degree. If the case is seen immediately, the mode of procedure is very definite. But only too often the patient's efforts have augmented the hernia, or he or his friends have made untimely attempts to reduce it.

Having cleansed the hands and the abdominal walls in the usual way, begin next a *systematic cleansing* of the eventrated mass. Cleanse it with warm sterile water, or normal salt solution, rubbing gently with the fingers, every inch of the projecting bowel or omentum. Only in the thoroughness of this step is there any assurance of success. If any visceral wounds are discovered in the cleansing process, they are to be repaired at this time.

Once the cleansing and repair are complete, proceed to *reduce* the hernia. The wound may need to be enlarged; if this is necessary, slip a finger under an angle of the wound to serve as a guide, and divide the tissues with scissors. The other angle may be treated in the same way. Catch up the peritoneum with forceps along the whole

length of each side of the wound. Now lift on the forceps, and in this way create a sort of funnel with smooth sides, over which the bowel readily glides in reduction.

Do not attempt to reduce by rough pressure, which may contuse the bowel. If "taxis" fails, there is a method which will surely succeed.

Spread a large compress over the mass; tuck its edges well under the entire circumference of the wound; and, with both hands, make a gradual pressure on the mass enveloped in the compress, coaxing the refractory loops into place with the fingers, and at the same time pushing the compress further under the abdominal walls. The assistant, in the meantime, lifts up on the forceps attached to the peritoneum, raising the abdominal walls as the hernia recedes.

When the reduction is complete, leave the compress in place, secured by forceps until repair of the peritoneum is nearly complete. *Repair the abdominal wall*; begin by suture of the peritoneum with small catgut. If the tension is great, it may be necessary to include the muscular plane in the suture. Next repair the muscular layers separately by continuous chromic gut suture; in the same manner, the aponeurosis, and finally the skin, with interrupted silkworm-gut sutures.

A young man was brought to the City Hospital following a passage at arms with his prospective father-in-law who had given him the *coup de grace* with a pocket knife. A large part of his bowel he was carrying wrapped in his shirt and some towels. He was anesthetized and the examination revealed that the eventrated gut was strangulated, having crowded through a very small peritoneal wound in the lower part of the abdomen; but the external wound was extensive and the left rectus muscle was completely divided.

The strangulated loops were patiently sponged, one by one, with normal salt solution and the adjacent skin as well. Next the wound was enlarged, the strangulation relieved, the bowel reduced and the peritoneum repaired. The wound and adjacent skin were next sponged with alcohol.

The ends of the severed rectus were widely separated and were with difficulty brought together by mattress sutures.

The skin and fascia were repaired without drainage. The patient

recovered with no rise of temperature and without the least sign of infection.

Drainage is a question which always arises, but Lejars assures us that, if the cleansing is carefully carried out, drainage is in no wise necessary. *If the case is seen late*, but there exist only a few soft adhesions between the bowel and the walls of the wound, the same disinfection is carried out, the adhesions around the orifice gently broken up, and the mass reduced, as before. Drainage is quite indispensable, if there are already the signs of a beginning peritonitis.

If the mass has become the site of a *purulent peritonitis*, the coils agglutinated by false membrane, and gangrenous, there is nothing to do except to keep applied moist antiseptic compresses, which must be frequently renewed. If the patient survives, whatever intervention is needed, may be undertaken later.

CHAPTER XII

GUNSHOT AND OTHER WOUNDS IN MILITARY PRACTICE

The care of the wounded in battle has presented in all ages a constantly varying problem. Historically speaking, time and place and the instruments of war are the elements of the retrospect. The character of a particular age is dimly reflected in the character of its war wounds, and these regarded as finished products reveal, as all things else in Nature, an evolutionary aspect—a gradual change from the rudimentary to the complex.

The cave man, our earliest progenitor, sallied forth to combat armed with a shank bone or an unhewn club of oak, his valorous purpose to inflict upon his enemy some degree of contusion, the simplest form of wounds.

The very best his efforts might hope for were broken bones, or an occasional broken head, and these were the worst the primeval surgeon had to manage. At a later stage of civilization the warrior had learned how to inflict incised, stab, and punctured wounds. Finally, it has remained for our own times to produce the worst wounds of all, terrible crushes and lacerations, the product of machinery.

The European War has proven how far the powers of destruction are ahead of those that would succor and save. Former wars had taught us what the bullet in the field and the bacillus in camp might do, and the sanitary service prepared itself to cope with these problems, and prepared itself efficiently. But the unexampled loss of life and limb along the Marne, the Yser and the Vistula, and on a hundred other battlefields, left the Medical Department almost helpless with yet new problems to solve—problems for the most part unsolvable.

The artillery aided by the aeroplane have made it almost impossible to give the wounded adequate First Aid and the first aid

Martini-Henry

Guedes

Lee-Metford

Mauser

Krag-Jorgensen

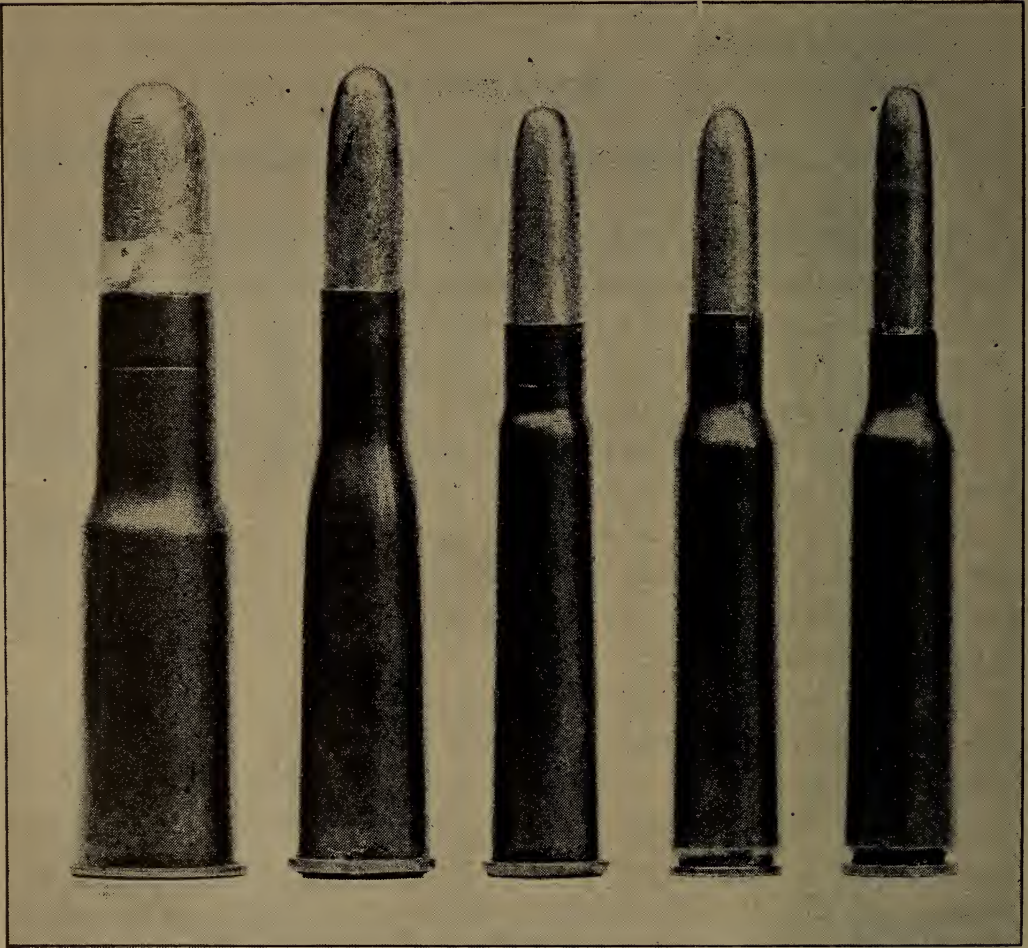


FIG. 86.—The distinguishing feature of the rifle is the spiral grooving which gives the projectile a rotary movement, maintained throughout its flight and which lessens its tendency to depart from the straight line. The various rifles differ with respect to the number of grooves, their depth and the angle they make with the bore. The Martini-Henry represents the first form of the modern Breech loading gun—0.45 caliber conical leaden bullet weighing 450 grains. The barrel rifled with 7 grooves, with one turn in 22 inches.

The later rifles have smaller bores, fewer grooves; the trajectory is less, the initial velocity and the range much greater; the steel jacketing diminishing deformation.

Lee-Metford bullet, caliber 0.303, one turn to 10 inches of rifling.

The Krag-Jorgensen, caliber 0.315, initial velocity 2034 feet per second and sighted for 2078 yards.

The Mauser, caliber 0.311, weight of bullet 154 grains, velocity 2882, range 2187 yards.

The U. S. Springfield, caliber 0.300, weight 150 grains, velocity 2600 and range 2850 yards.

dressings, which the wounded or his comrade may apply, has proven inadequate for the tremendous lacerations of bursting bombs.

Every factor, it would seem, conspired to make wound infection the great surgical feature of this war. The character of the wounds, the lack of First Aid, the delay in evacuating the wounded and the slowness of transportation combined to give the pus, the tetanus, and the gas bacillus a temporary triumph over the earnest devotion of the highest surgical skill. To meet these conditions the efforts of the sanitary service in the future must be directed.

Under what may be called the normal circumstances of war the army bullet wound still maintains the characteristics we have ascribed to it for the last twenty years. These wounds vary in severity from mere contusions through all the grades of injury to destructive lacerations, depending upon the range. If the gunshot wounds in military

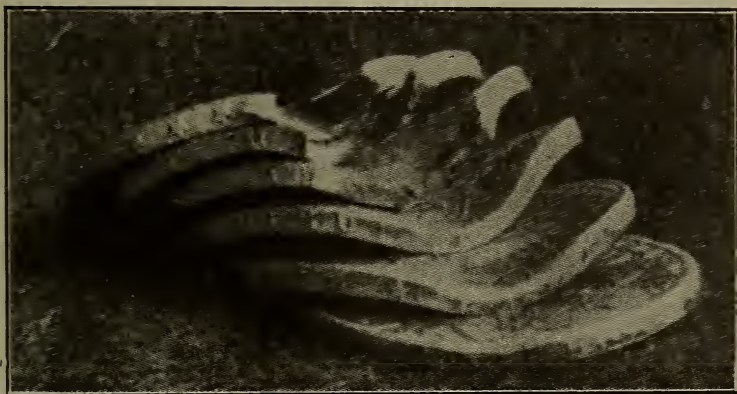

FIG. 87.—Gold coins struck by a bullet fired point blank at a Belgian who carried the coins in his belt. He was stunned by the impact and left for dead. The condition of the coins indicates the force of the bullet and its tendency to deflect. (*Peacock, Brit. Jour. Surg.*, Jan., 1915.)

practice differ from those seen in civil practice with respect to character, prognosis and treatment it is because the bullets in each case differ with respect to hardness, range and initial velocity and because the wounds are produced in different environments.

The *modern army bullet* (Fig. 86) is of small caliber, is jacketed with steel, has a very high initial velocity and, as compared with the older missile, a remarkable range.

The small, sharp-pointed bullet, used by most of the combatants in the European War, produces some effects differing from those

produced by the bullets with conical tip. These results are based on its instability of flight. Its perforating power is immense, yet unless it strikes squarely on the point it is most easily deflected (Fig. 87). At the moment of oblique impact it acquires a new movement, viz., a revolution on an axis transverse to the line of flight. In

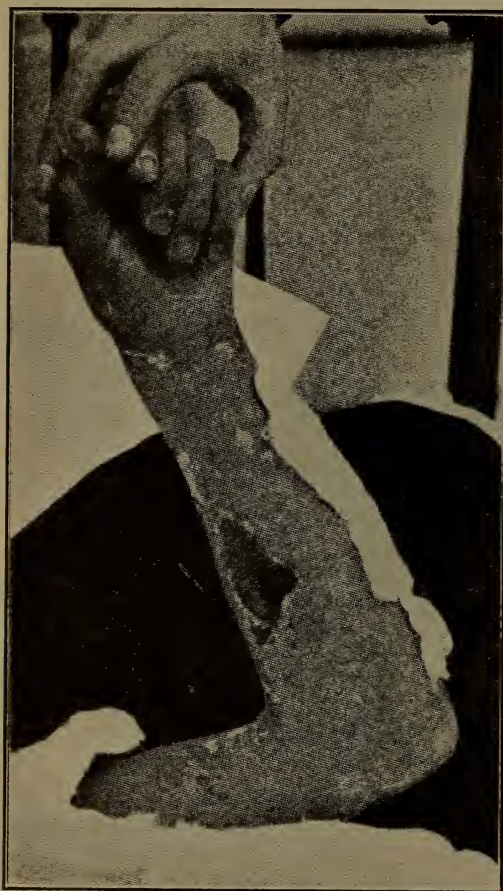


FIG. 88.—Showing wound of entrance at close range with explosive effect. (*Tuffier*, Brit. Jour. Surg., Jan., 1915.)

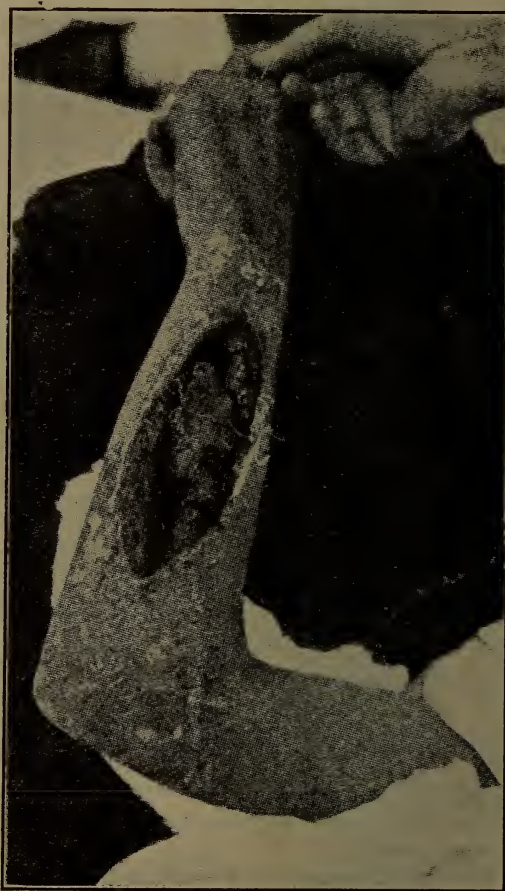


FIG. 89.—Same, showing wound of exit. Note tremendous laceration. (*Tuffier*, Brit. Jour. Surg., Jan., 1915.)

other words, the bullet moves forward like a wheel. According to Makins, if the velocity at moment of impact is not great it may make several turns in the tissues. If the velocity is still considerable it may turn end for end merely, or it may remain vertical to its path, making only a half turn. In all these cases it retains to the last the spin on its long axis, imparted by the rifling of the gun.

At *very close range* all these bullets are tremendously destructive to all the tissues alike.

At *long range* the conical bullet tends merely to perforate, whereas the pointed bullet, for the reason given above, tends to tear through the tissues in any other position than point first, unless striking

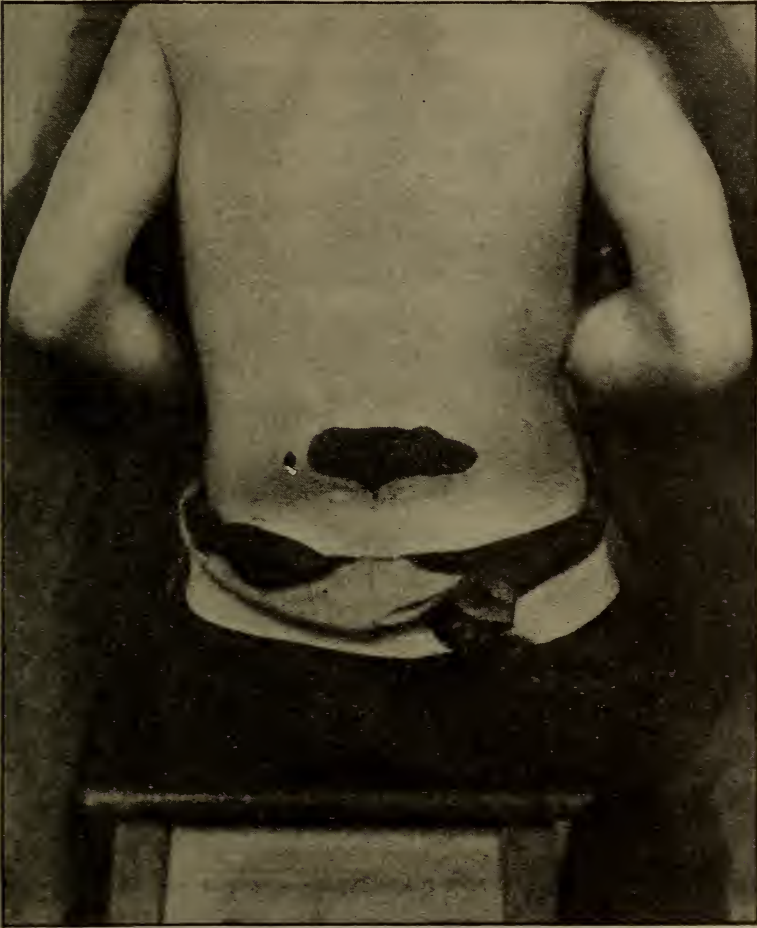

FIG. 90.—Showing small entrance wound at long range; large irregular wound of exit.
(Makins.)

squarely. In this manner, even at long range, explosive effects may be produced. However, at medium or long range the various tissues present certain general characteristics.

The *skin* presents a wound of entrance smaller than the bullet and likely to be dirty and discolored. The wound of exit, if present, is larger, more irregular and bleeds more freely (Figs. 88, 89 and

90). The pain in flesh wounds is often moderate, usually a burning sensation, and the shock is not severe.

The *fascia* presents a smaller opening than the skin and is likely to be slit rather than cut in twain and so tends to close the wound, oftentimes materially interfering with drainage.

The *muscles* are contused and lacerated, often infiltrated with blood—conditions favorable to infection.

The *tendons* are often pushed aside and thus escape serious injury. At other times they are partly or wholly divided—conditions to be considered in the course of surgical repair.

The *blood vessels* may be pushed aside but ordinarily do not escape if in the bullet's track, so that one of the frequent causes of immediate death is hemorrhage. Yet even in the case of laceration of the larger arteries, spontaneous arrest of bleeding may occur.

Contusion of the blood vessel results in aneurism, the first indication of which is the murmur (Fig. 91). The subsequent character depends on whether or not infection occurs. Heyrovsky has specially studied these injuries and points out the dangers, which are secondary hemorrhage,

FIG. 91.—Traumatic aneurism, gunshot wound. (Moullin.)

gangrene, and the late hemorrhage following prolonged suppuration. Primary gangrene is most often seen in wounds of the popliteal, and the gangrene sequent to these injuries is of the moist variety.

In the non-infected case, secondary hemorrhage may occur as late as the third week. The vessel in such cases is to be ligated at the site of injury and not at the point of election. The injured vessel is exposed and followed up to healthy tissue and no higher and then ligated, the wound to be left open and without tamponade. Following this method not a single case required amputation. Of twenty-one infected cases three died, the result of ascending thrombosis, and five more were cured only after amputation.

The mortality of all cases of secondary hemorrhage was 14.2 per cent. as compared with 81.4 per cent. statistics of Billroth in 1870. (Wiener Klin. Wochenschrift, Feb. 11, 1915.)

The *nerves*, like the tendons and blood vessels, may be pushed aside, but are more likely to be contused or divided, resulting in paralysis—immediate or remote—neuralgia or trophic disturbances, such as wasting or contractures of the muscles, or degeneration or inflammation of the skin corresponding to the distribution of the injured nerve. Even though the nerve itself is not directly injured, these conditions may later result from its inclusion in scar tissue. It is often necessary to expose the nerve in order to clear it of exudates and débris, or to attempt to suture.

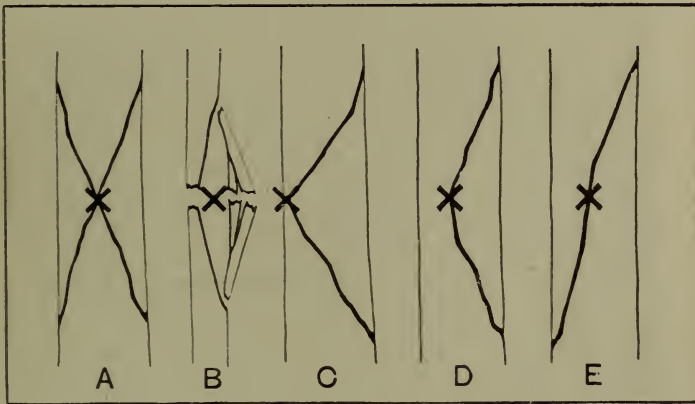


FIG. 92.—Types of fracture of long bones. (Makins.) (a) Primary lines of stellate fracture; (b) stellate on one side, transverse on the other; (c) complete wedge broken out; (d) incomplete wedge; (e) oblique fracture.

Gosset calls particular attention to the musculo-spiral in this connection and emphasizes the value of exposing it throughout its whole course down the arm. He employs for this purpose an oblique incision extending from the level of the axillary border behind to the front of the external condyle, the arm held vertically and the elbow flexed, the hand near the face. Division of the fascia and separation of the muscles readily exposes the nerve, which lies in close contact with the bone throughout its course. The results have been such as to encourage this procedure in every case of injury with symptoms of nerve involvement. (La Presse Medical, Jan. 21, 1915.)

Bone presents a wide variation in the character of the lesions produced. There may be mere puncture, there may be extensive comminution, or any grade of injury between these two extremes (Figs. 92, 93).

The character of the injury will depend upon two factors: (a) the character of the bone and (b) the range of the bullet.

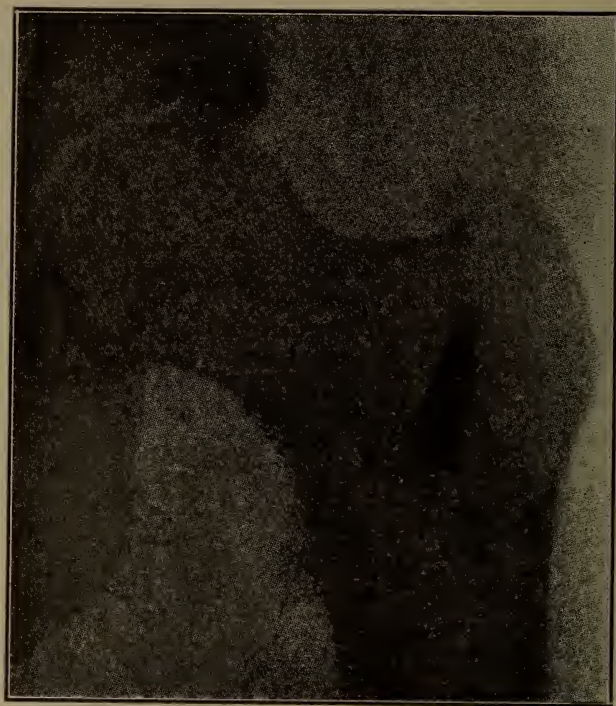


FIG. 93.—Perforation of the great trochanter, without comminution. Bullet fired at long range lodging in cancellous tissue. Note position of bullet. Bullet was not removed. (Harris, Brit. Jour. Surg., Jan., 1915.)

(a) If the bone is soft and cancellous, the tendency is toward perforation; if it is hard and compact, the tendency is toward comminution.

The articular end of the long bones, the short, and the irregular bones are likely to be merely perforated. On the other hand, the shaft of the long bones, the skull, the scapula are much more likely to be shattered.

(b) At long range, perforation is rather to be expected; at very close range, comminution is the rule.

So far as the long bones are concerned, if transverse fracture occurs, its tendency is to stop short of the articulation (Fig. 95).

With respect to the bones of the limbs, it is to be noted that the



FIG. 94.—Comminuted fracture of the femur. Bullet lodged in soft parts. (*Harris, Brit. Jour. Surg., Jan., 1915.*)

exit wound will be the more comminuted (Fig. 96). Perforating fractures without solution of continuity are often difficult of diagnosis, because of the absence of characteristic symptoms. The

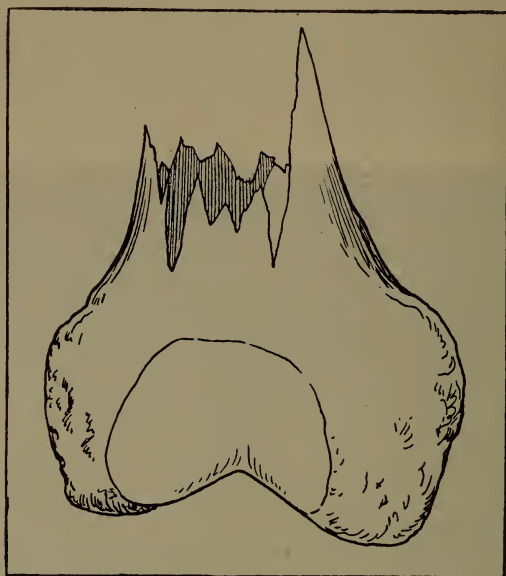

FIG. 95.—Lower end of femur, showing tendency of fissures to stop short of articular ends. (*Makins.*)

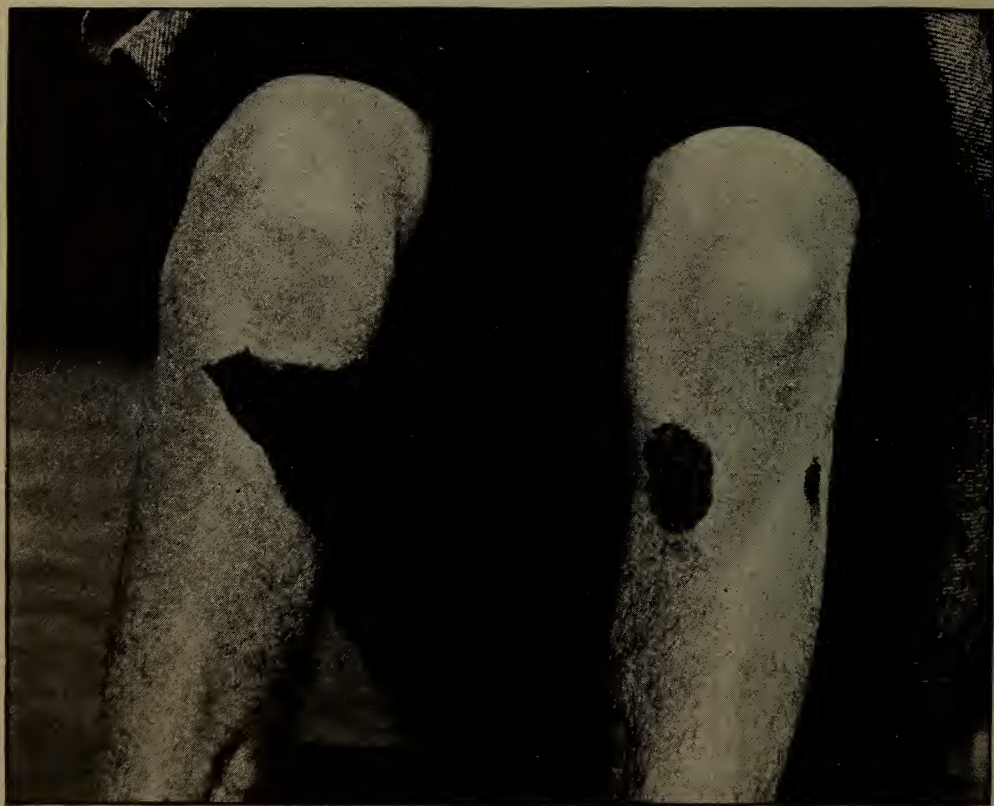


FIG. 96.—Small wound of entrance and large wound of exit on left leg. Fragments of bone carried across to right leg producing large laceration, requiring amputation. (*Makins.*)

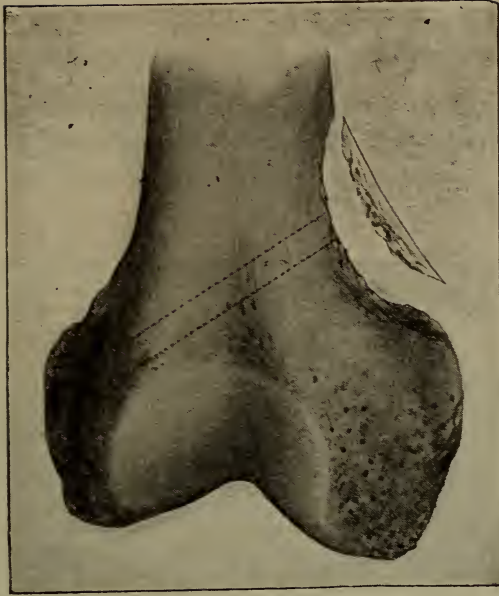


FIG. 97.—Oblique perforation, implicating both epiphysis and diaphysis, with large fragment at exit. (*Makins.*)

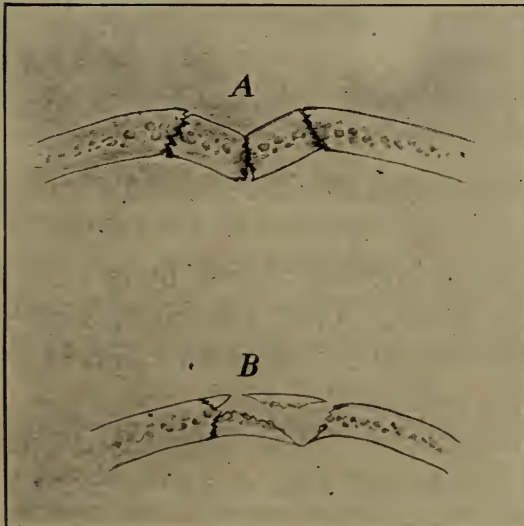


FIG. 98.—Transverse section of "gutter" fracture. (A) No loss of substance; (B) comminution. (*Makins.*)

diagnosis is to be made by reference to the track of the bullet, by palpation, and from presence of bone dust in the wound of exit, etc. (Fig. 97).

Comminuted fractures present an excessive mobility, and often crepitus is hard to elicit. Owing to "local shock," the limb may be quite powerless and yet painless.

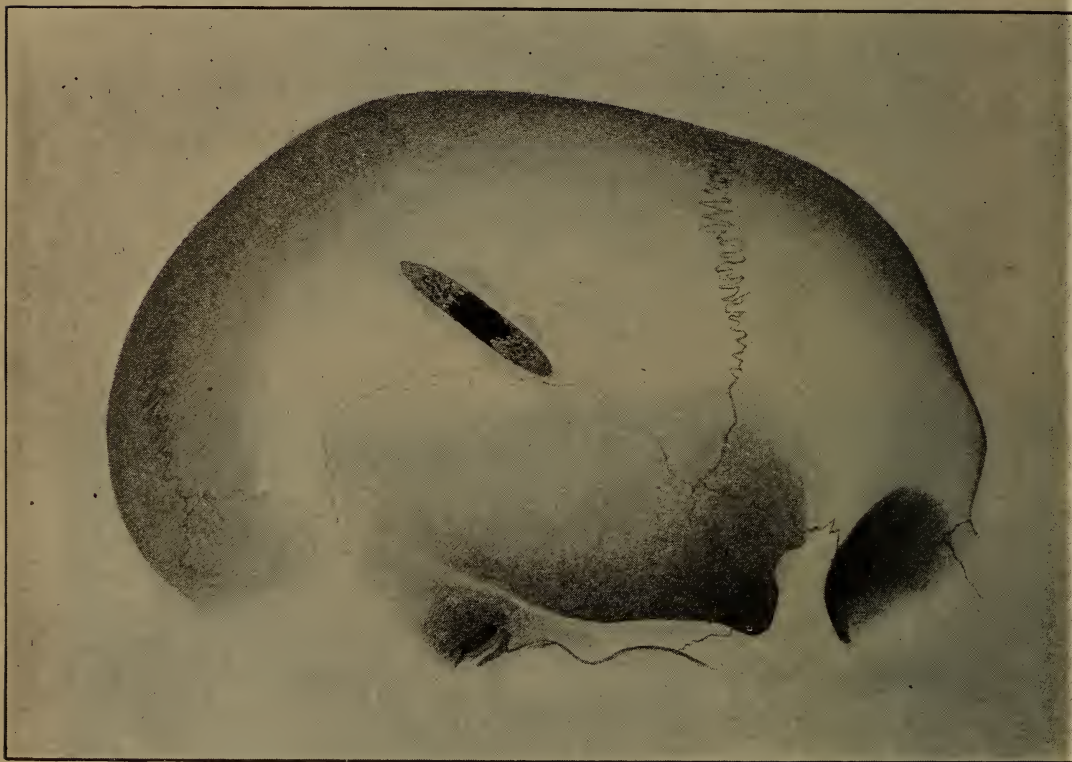


FIG. 99.—Gutter fracture perforating skull in the center of its course. (*Makins.*)

Primary shortening is often absent by reason of the muscular relaxation due to shock. Even though healing takes place uneventfully, a large amount of callus is likely to be thrown out and, for a long time, the union will not be strong.

Acute osteomyelitis may follow infection. On the other hand, necrosis may occur late and after the wound has apparently quite closed.

In the bones of the *skull* is frequently seen the so-called "gutter fracture," in which there are usually two apertures in the scalp.

connected by a trench ploughed through the outer table and diploe (Figs. 98 and 99).

The corresponding part of the inner table is comminuted extensively and perhaps depressed.

The length of the gutter depends upon the surface curvature, and the antero-posterior are more serious, as a rule, than the transverse (Fig. 100).

The *joints* present effects peculiarly variant: the capsule alone may be injured; the articular ends of the bones may be guttered or



FIG. 100.—Superficial perforating fracture; roof lifted at both openings. (Makins.)

penetrated with or without injury to the capsule; there may be much shattering, fissures radiating in all directions; or the joint may be involved by extension from the wound of the shaft. The bullet may be retained in the joint cavity. Effusion into the joint is a constant symptom following perforation—a mixture of blood and synovial fluid.

Of the *great cavities* and *viscera*, each has its own particular symptomatology.

The *cranium*, according to Von Bergman, presents the following lesions: At short range, the skull and scalp are torn to pieces; at 160 feet, the scalp is preserved but the skull is shattered; there are

two openings with lacerated edges with brain exudate, the wound exit always larger than that of entrance.

At 320 feet, there are two openings, each surrounded by a series of concentric fissures in addition to radiating fissures (Fig. 101).

At 4000 feet, the radiating fissures still appear.

At 5600 feet, entrance and exit wounds are clean-cut holes.

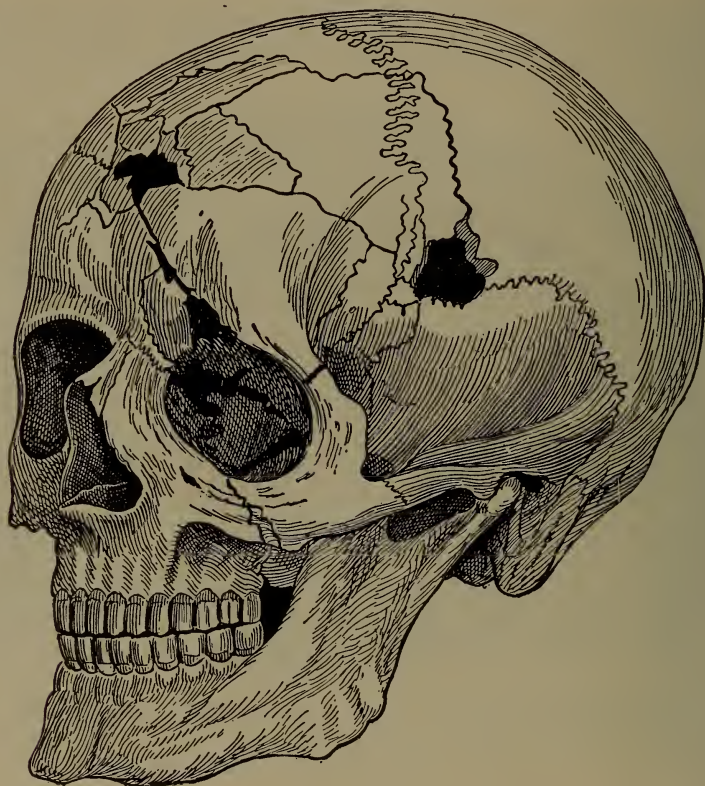

FIG. 101.—Extensively comminuted gunshot fracture, bullet fired at close range. (Senn after Von Bergman.)

At 8000 feet, there is only the wound of entrance, and the bullet lodges in the brain. The injuries to the dura mater are analogous to those of the skull.

The *brain* itself, semifluid, is torn to pieces at short range, through hydrodynamic action. At long range, the bullet merely traverses the brain, producing areas of contusion in the neighborhood of its track. There may be a diffuse hemorrhage throughout the brain, the ventricles being filled with blood.

The symptoms are such as belong to concussion, compression, contusion, or laceration in general.

Thus following these various degrees of brain injury there occur more or less marked indications of the loss of brain function, both general and focal.

Most prominent are motor and sensory paralysis; impairment of the special senses, especially sight and hearing; aphasias and amnesia—all these in various combinations.

These symptoms usually emanate from the regions adjacent to the track of the bullet, though occasionally it is evident that outlying portions of the brain have suffered as well.

The amount of damage which the brain may suffer with practical recovery is often astounding. Sometimes it would seem that it is merely a matter of controlling pressure and infection.

As illustrating this point we may instance some of the case reports of Whitehorne-Cole in service at one of the British evacuation hospitals in France.

Case 1.—Compound comminuted fracture of skull from a shrapnell bullet. Longitudinal sinus along vertex of the skull, and the brain substance much lacerated. Trephining, débridement, disinfection. Eighth day afterward, mental condition good. Partial motor paralysis. At end of month, paralysis greatly improved, sent home practically well.

Case 2.—Compound comminuted fracture of skull from rifle bullet through both parietals. Septic. Aphasia, right hemiplegia. Disinfection. Drainage.

First day after operation: Aphasia, hemiplegia, urinary incontinence.

Fourth day: General condition much improved. Hernia of the brain with some oozing of its substance. Alcohol pack applied.

Sixteenth day: Hernia practically gone.

One month: Wound healed; aphasia gone; hemiplegia much improved; can read and talk and walk; sent home.

Case 3.—Compound comminuted fracture of skull; rifle bullet through left frontal and temporal region. Left facial paralysis. Whole track of bullet laid open. Removal of fragments.

Three weeks after: Wound healed and paralysis gone.

Case 4.—Compound comminuted fracture of right parietal. Hernia of brain; left hemiplegia.

Three weeks later: Well except for slight paralysis in left arm.

Case 5.—Compound comminuted through orbital region. Left eyeball collapsed. Hernia cerebri. Both wounds septic.

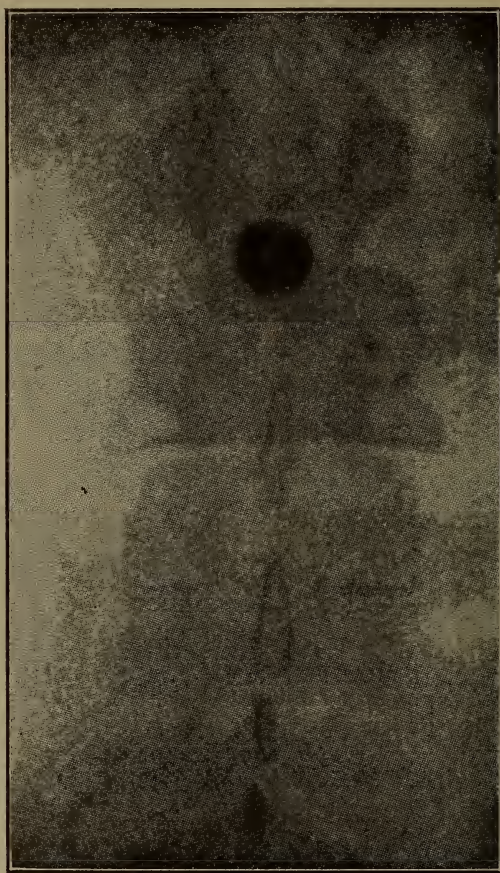


FIG. 102.—Shrapnel bullet lodged in body of the vertebra. Symptoms of concussion; complete recovery. (*Harris, Brit. Jour. Surg., Jan., 1915.*)

Did remarkably well after operation until fifth day, when pulse and temperature began to rise. Shortly afterward followed by death.

There was an enormous amount of bone and brain destruction, and that he should have done so well for five days is very remarkable. (*Lancet, March 13, 1915.*)

The *spine* is seriously injured in proportion as the cord suffers

(Fig. 102). Aside from the cases in which the cord lies in the track of the bullet and is partially or completely divided transversely, there are those cases in which there is no anatomical lesion of the cord, perhaps nothing more than perforation of a vertebra, yet the functions of the cord are markedly depressed. Absence of deep reflexes must not be taken to indicate complete rupture of the cord. This may be due to "concussion" of the cord, which Makins describes in detail.

The degree of concussion, and therefore the degree of functional depression, depends directly upon the velocity of the ball.

In slight spinal concussion, the symptoms consist in loss of cutaneous sensibility, motor paralysis, and vesical and rectal incompetence, persisting for a few hours or even two or three days.

Recovery begins with return of sensation, often modified, followed later by return of motor activity.

"Severe concussion, contusion or medullary laceration, may be considered as lesions of equal degree as to severity, bad prognosis, and unsuitability for active interference; all characterized by the same essential phenomena, viz.: symmetrical abolition of sensation and motility, absence of any sign of irritation in the paralyzed area, and loss of patellar reflex. These severe injuries are all accompanied by profound shock. The patient lies still, with eyes closed, great pallor of surface, the sensorium benumbed, the pulse small and irregular, respiration shallow" (Makins).

In addition to these lesions there are such as arise from compression, either from bone or from a lodged bullet. But, as Makins says, it may be assumed that a bullet injuring the vertebra sufficiently to displace bone, has, at the same time, produced grave lesions of the cord. If the pressure is due to the bullet, it argues that its velocity was low and that there may be no serious lesion of the cord and that the symptoms are those of compression alone. Compression due to extra-dural hemorrhage can rarely produce serious symptoms.

The *thorax* may or may not be penetrated by the impact of a bullet, though penetration, of course, is the rule, and these wounds constitute a large part of the casualties of battle. The non-penetrating wounds present no features of especial interest. The skin and

muscles may be injured in various degrees between simple perforation and serious laceration. The clavicle and scapula may be fractured; the axillary space may be involved, with serious results.

The penetrating wounds cross the thorax in every direction, transversely, longitudinally, and obliquely.

Those which traverse the thorax longitudinally, and are received while firing or advancing in the prone position, are noteworthy in that the abdominal cavity is usually also involved. The abdominal cavity is also likely to be penetrated when the base of the thorax is crossed.

If a rib is involved, the bone injury is usually limited, and these fractures are considered of importance only when the intercostal artery is wounded. In many of these fractures from the army bullet the ordinary symptoms are absent, either because of the localized character of the injury and absence of contusion of the soft parts, or because the fragmentation in the track of the bullet is so complete as to preclude crepitus.

The *lungs*, almost certain to be involved in perforating wounds of the chest, escape with remarkably slight damage, owing to their elasticity.

Those bullets which pass near the root of the lungs are very likely to involve the great vessels, followed by rapid and fatal internal hemorrhage.

Certain symptoms manifest themselves in most cases of lung injury in some degree. Shock, if it exists at all, is not usually serious and arises rather from the injury to the chest wall; nor are pain and dyspnea prominent.

Hemoptysis is fairly constant, but not persistent longer than two or three days. Cough is seldom troublesome and pneumothorax is rare.

Hemothorax is very frequent, but in the great majority of cases is due to hemorrhage from the chest walls—to the intercostals rather than to the lung injury.

Tuffier remarks of these cases as observed in the French field and base hospitals that bullet wounds of the chest—such as reach the hospital—are generally remarkably mild and cases of hemothorax requiring intervention are quite exceptional.

From one of the field hospitals comes this report which is typical: "Cases 4, 5, 6—perforating bullet wound of the chest. These cases were of comparatively benign character. Each showed the following signs and symptoms: pain, dyspnea, slight hemoptysis, immobility of one side of the chest and signs of free fluid in the base. They all did well during their stay with us.

Case 7.—Perforating chest wound of more serious character. In this case the right hemothorax showed rapid increase of the fluid with displacement of the heart and urgent dyspnea. We tapped the chest drawing off 3 pints of blood-stained fluid. Two days later there were signs of air in the pleura, but after a second tapping, which drew off air and pus, the patient made a sufficient recovery to be moved" (British Journal of Surgery, Jan., 1915).

The symptoms of a hemothorax reach their full height on the third or fourth day. The pain is severe, the pulse and temperature rise, dyspnea is prominent, respiratory movement on the affected side is annulled, and there are the physical signs of fluid on the pleura.

The course of the temperature is a matter of concern, for the fever suggests empyema. It seems always to rise *pari passu* with the increase of blood in the pleural cavity, often declining after the third or fourth day, always falling after a paracentesis and rising anew with fresh access of pleural hemorrhage. On the other hand, the fever of infection arises later, persists, or gradually mounts higher.

Perforating wounds of the *heart* in warfare Makin regards as certainly fatal, believing that the cause of death is not hemorrhage, but sudden stoppage of the heart action.

Senn believes that death usually occurs from compression of the heart, due to hemorrhage within the pericardium. In those cases where, from the anatomical features, the heart would seem to be involved and yet presents no symptoms of injury, the inference must be that it escaped, owing to change in position and size incident to contraction.

Other observers write that a bullet has been known to pass through the heart without fatal effect.

Penetrating wounds of the *abdomen* are seldom simple in character, for it only rarely happens that a single viscus is involved. The one

symptom which, if it occurs at all, is common to wounds of all abdominal organs, is peritonitis. The sources of hemorrhage are numerous. The degree of injury to every organ decreases with increased range. The *small intestine* is naturally the structure most

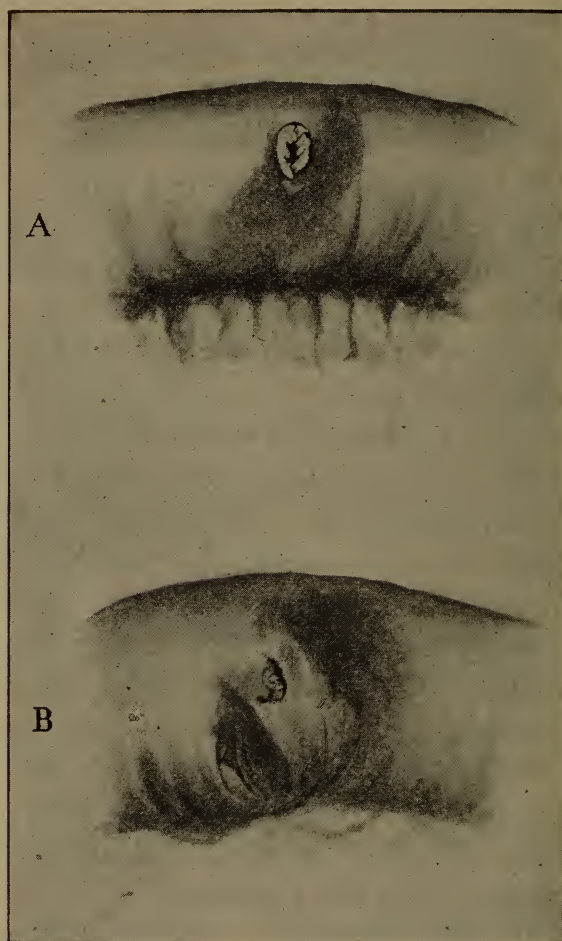


FIG. 103.—Perforating wounds of small intestine. (a) Entry; (b) exit. Note slit-like character and eversion of mucous membrane; localized ecchymosis more abundant around exit aperture. (Makins, from St. Thomas Hospital Museum.)

frequently wounded and, of course, its perforations are multiple (Fig. 103).

Pain, collapse, vomiting, and peritonitis are nearly always present, although present also in wounds of the stomach and large intestine. The peritonitis is more widespread in the case of the small intestine

than in the case of the stomach and large intestine, because of the greater activity and motility of the small intestine. Vomiting of blood may be taken to indicate perforation of the stomach. The stomach and intestines escape "explosive" effects in proportion as they are empty at the time of injury.

The *bladder* when wounded may present two openings; both may be extra-peritoneal, both may be intra-peritoneal, or one may be intra- and the other extra-peritoneal. An extra-peritoneal wound bleeds the more profusely; an intra-peritoneal wound permits the escape of urine into the peritoneal cavity. Hematuria, or suppressed urination with an empty bladder, points to the character of the injury.

The *liver* is likely to be simply perforated or notched, though at close range "explosive" effects are observed. The chief result is hemorrhage and, in some cases, an escape of bile, due to injury to the gall-bladder or the bile ducts.

The *spleen* if merely perforated gives rise to hemorrhage, usually insignificant, unless its main vessels are involved.

The *kidneys* give rise to either extra- or intra-peritoneal hemorrhage, which is not serious unless the perforation involves the hilum. Shock is nearly always present as well as hematuria and frequent urination.

The *pancreas*: there is no way by which injury to the pancreas may be diagnosed. It may be merely inferred from the course of the bullet. It is so situated that it cannot be reached by a bullet without injury to other organs more likely to give due notice of their affront.

PROGNOSIS AND TREATMENT

Flesh wounds produced by the army bullet and uncomplicated by infection tend to heal without difficulty. Whether or not infection occurs depends upon the efficiency of the first-aid dressing—that is to say whether it is ample and whether it is applied in due time.

The aim of the first dressing is to secure aseptic occlusion but if the wound is exposed to infection from sources other than the bullet

before the dressing is employed, the wound may as well be regarded as infected.

Again if the wound is large and lacerated, even if the dressing is applied at once, infection is almost certain to occur. Consequently some form of antiseptic treatment is to be carried out in these cases. This will ordinarily be done at the field hospital.

Many observers in the European War condemn the use of iodine, asserting that it does not agree with these wounds, tending to produce irritation, inflammation, or even sloughing of the parts. If these effects occur, however, it is probably not the fault of the remedy but rather the fault of the user. If the iodine solution is poured into an open vessel, the alcohol evaporates, the solution becomes more and more concentrated and of such strength as finally to be noxious to the tissues. Alcohol and iodine will probably remain for some time to come the antiseptic agents most available for such work.

In the base hospital the treatment of the wound which has become septic presents a different problem. A larger choice of antiseptics is here permissible. It is evident from the many reports on this subject that the ideal antisepsis for extensive suppurations has not yet been found.

Carbolic acid, bichloride of mercury, peroxide of hydrogen, boracic acid—each of a long list of germicides—has its special indications. A solution of 1 to 100,000 nitrate of silver has been highly recommended. Oftentimes it is indicated to enlarge the wound and search for a piece of the clothing or other foreign body, though it is unnecessary to say that no such search should be carried out unless sepsis supervenes. Under no circumstances is the bullet to be probed for. In prolonged suppurations the use of vaccines will often be found useful. In the case of the limbs, these bullet wounds of the soft parts, even as in the case of shell wounds, may call for primary amputation when the blood supply is compromised beyond the hope that a collateral circulation may be established. Skene recommends in the case of large suppurating areas that antiseptic sawdust be used. The affected area is covered with a gauze sheet, the sawdust poured on and the edges of the gauze folded over to hold the dressing, the whole to be changed every two or three hours.

Finally, tetanus or the gas bacillus infection may supervene, each requiring its special treatment. (See page 285.)

TREATMENT OF GUNSHOT FRACTURES OF THE LONG BONES

The treatment of gunshot fracture of the long bones varies in detail, depending upon the character of the injury to the bone and

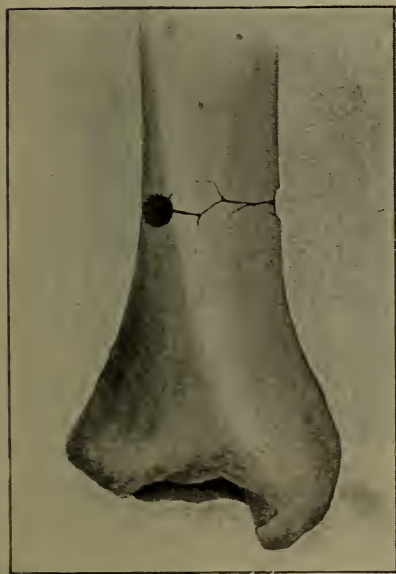


FIG. 104.—Simple perforating fracture of the lower end of the tibia. (*Makins.*)

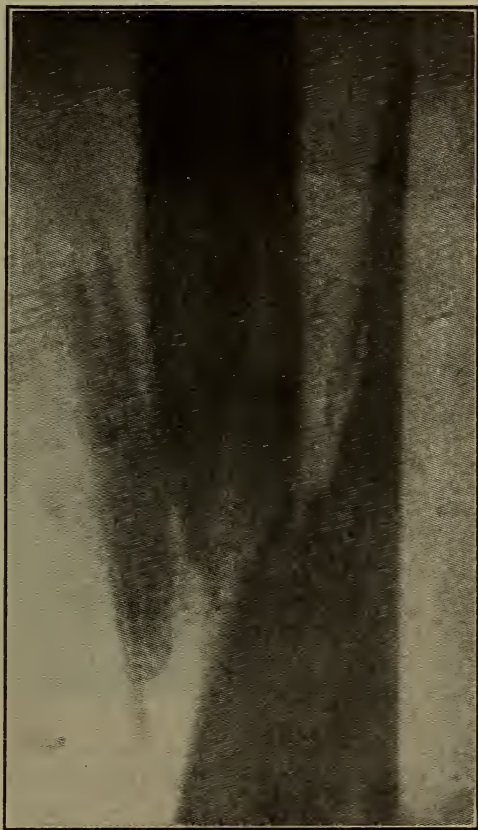

FIG. 105.—Extensive comminution with moderate injury to the soft parts. (*Harris, Brit. Jour. Surg., Jan., 1915.*)

to the soft parts. On this basis, three clinical varieties may be recognized: (a) Simple perforating fracture (Fig. 104); (b) extensive comminution with moderate injury to the soft parts (Fig. 105); (c) extensive comminution with great laceration and destruction of the soft parts (Fig. 106).

(a) The treatment of uncomplicated perforating fracture is exceedingly simple: Aseptic occlusion and immobilization and, provided only that infection is kept out of the wound, the results are uniformly excellent.

(b) In this case, conservatism is still the better course; the wound in the soft parts is cleansed and dressed, the bones adjusted and an



FIG. 106.—Extensive comminution with great laceration of the soft parts, requiring amputation. (Harris, Brit. Jour. Surg., Jan., 1915.)

emergency splint applied until such time as the more definite treatment can be instituted.

(c) In case the bones are shattered, the soft parts reduced to pulp, it is better to proceed to *immediate amputation*. It is under these circumstances that Fitz Maurice Kelley recommends the simple circular amputation of the member, dividing all the tissues at the same level, making no effort to fashion a flap. After the dangers of infection are passed, another amputation following the usual lines is to be practised.

The question of *immobilization* is complex. On the field shaped splints of zinc or molded wire splints may be employed. Tuffier, however, expresses preference for the wooden splint fashioned and padded in the ordinary way. He praises its simplicity and efficiency. At the field and base hospitals no such simple routine can be followed and each case must be treated according to its character, taking into account the degree of fragmentation, the tendency to displacement, the requirements of frequent change of dressing of the soft parts and the comfort of the patient.

In the ordinary fracture, with absence of wound infection, the plaster splint remains the dressing of choice.

In the case of the greatly comminuted fracture with serious suppurations to be treated, the problem of maintaining coaptation while handling the limb in doing the dressings is one difficult to solve.

E. W. Hey Groves, in the *British Journal of Surgery* (Jan., 1915), has pointed out the value of *continuous extension* in this class of cases and the manner in which the principle may be applied to the individual fractures. Two methods he holds in reserve: first, extension splints, modifications of those invented by Borchgevrink; second, transfixion apparatus.

The splint for the *humerus* is a Y-shaped wooden piece, the crutch padded for the axilla and the end extending beyond the elbow and fitted with a pulley wheel. A stirrup of adhesive plaster is fixed to the lower part of the arm and a perforated wooden bar fitted into the stirrup. The splint is now adjusted to the axilla and inner aspect of the arm and fixed with adhesive strips. A cord, attached to the wooden stirrup, is passed through the pulley and brought around to the inner surface of the splint where it is fastened with whatever tension may be desired.

Groves fastens the pulley cord to a solid rubber band arranged as a loop on the inner side of the splint, to perfect the continuous extension.

When the danger of infection does not contra-indicate, he applies the double transfixion apparatus pictured in connection with the femur (Fig. 113).

The upper end of the humerus is transfixed at a point in the line between the inner and outer border of the arm, and at the level just

below the middle of the deltoid, avoiding the cephalic vein and the circumflex nerve.

The lower pin is passed through the humerus from side to side,




FIG. 107.—Posterior angular splint for forearm with full supination. Note manner in which the extension cord passes through the pulley and to the rubber bands on back of splint. (*Groves, Brit. Jour. Surg., Jan., 1915.*)

$\frac{1}{2}$ inch above the epicondyles. Before the lower pin is passed, a perforated iron hoop is adjusted over the elbow and the pin passed through the proper perforations to hold the hoop in position.



FIG. 108.—Antero-internal splint for forearm, when the elbow and ulna are involved. Note the position of the rubber bands on internal surface to which the extension cord is attached. (*Groves, Brit. Jour. Surg., Jan. 1915.*)

Extension bars are now fitted to the transfixion pin above and to the hoop below. The screws of the extension bars permit of powerful extension, correction of lateral angulation and rotation, and ready

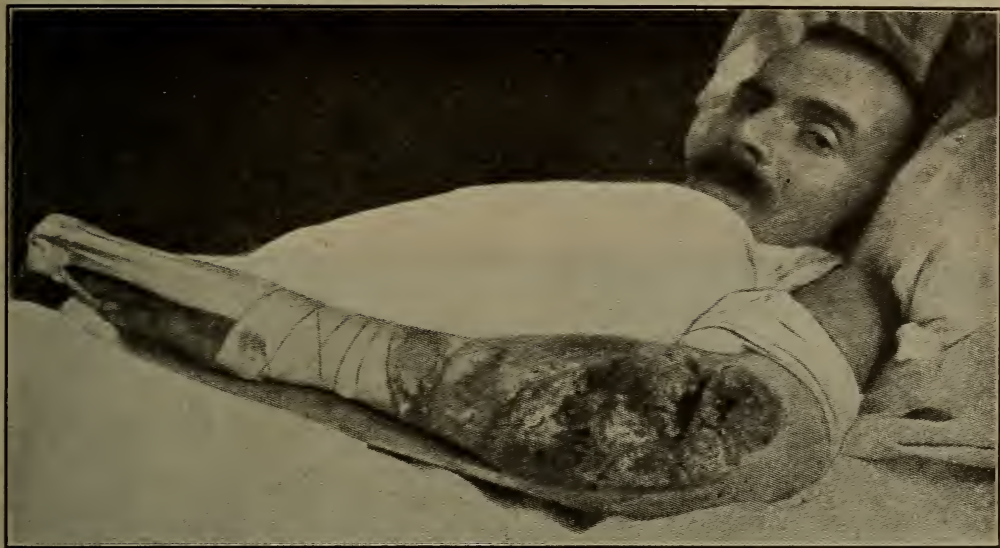

FIG. 109.—Antero-internal splint applied to patient in the 2nd Southern General Hospital, with fracture of the ulna. (*Groves, Brit. Jour. Surg., Jan., 1915.*)




FIG. 110.—Radiogram of elbow shown in Fig. 110. Note that the head of the radius is in good position as a result of the extension. (*Groves, Brit. Jour. Surg., Jan., 1915.*)

access of wounds. Of course the sepsis connected with the transfixion pins is the objection to this method to be overcome.

In the case of the *forearm* a posterior angular splint is recommended, applying the same principle of extension as in the case of the humerus. The extension, in the form of an adhesive plaster stirrup, is attached to the forearm and by means of cord and pulley

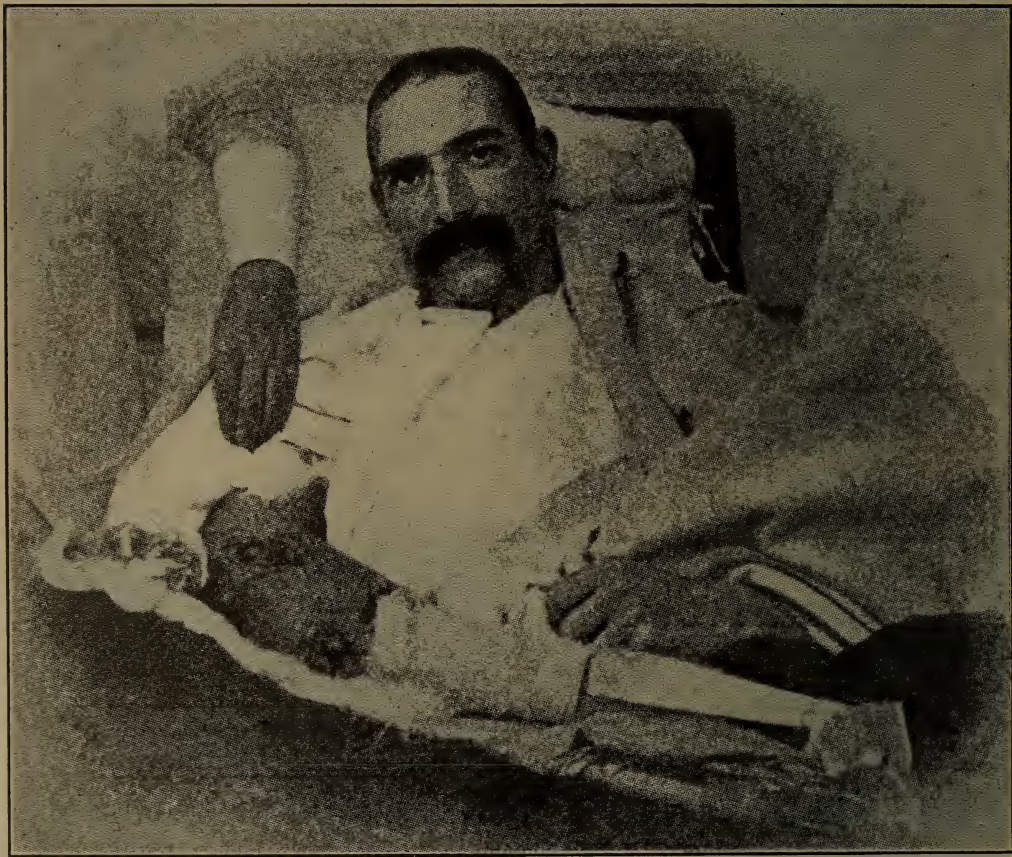


FIG. III.—Antero-internal splint applied to fractures above and below elbow. The splint with extension reduces both fractures. (Groves, Brit. Jour. Surg., Jan., 1915.)

the traction is exerted on the forearm, the arm being fixed to the upright piece of the splint. The cord is attached to an elastic rubber band on the back of the forearm piece (Fig. 107). The forearm is thus fixed in complete supination.

In case of a wound on the back of the member, it may be necessary to employ a metal frame splint with two lateral bars for the forearm, the extension being applied in the same manner.

In case the elbow is involved with comminution of the ulna and laceration of the forearm, an antero-internal splint is recommended (Fig. 108), leaving the whole outer and posterior surface accessible for dressings. The same sort of pulley extension is used. This splinting prevents dislocation of the head of the radius.

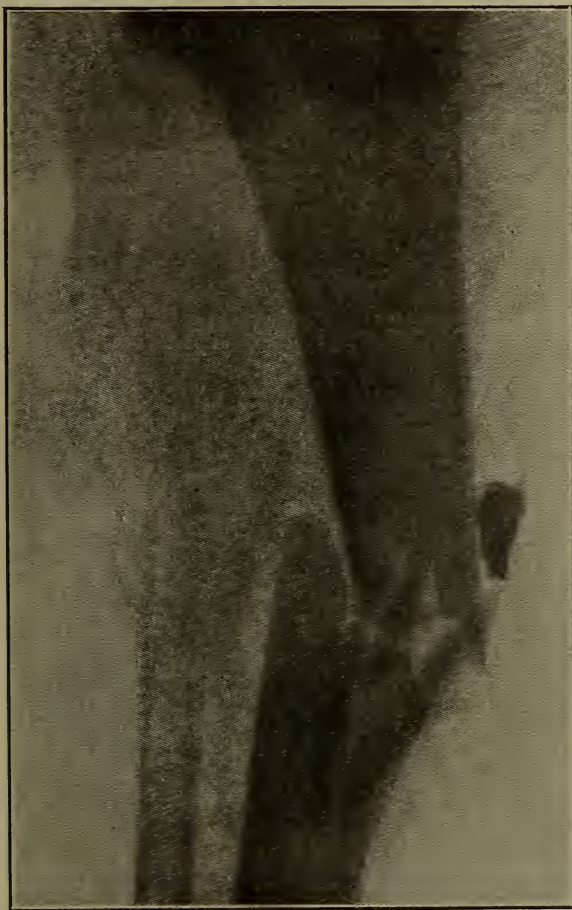


FIG. 112.—Comminuted fracture of the tibia and fibula. Part of shell *in situ*. Belgian soldier in 2nd Southern General Hospital. (Brit. Jour. Surg., Jan., 1915.)

Fig. 109 indicates the manner in which the splint is attached. Fig. 110 is a radiogram of the arm pictured above. This splint is applicable also to fractures involving the lower end of the humerus alone.

In the case pictured in Fig. 111, the patient, a Scotchman, in a Paris hospital, had a fracture of the lower end of the humerus and the ulna. Both fractures were reduced and held by this splint.

Fractures of the *tibia* and *fibula* present points of special importance because of the probability that the blood supply will be compromised and all the soft parts implicated; and in the case of the ends of the bones, the joints will be involved (Fig. 112).

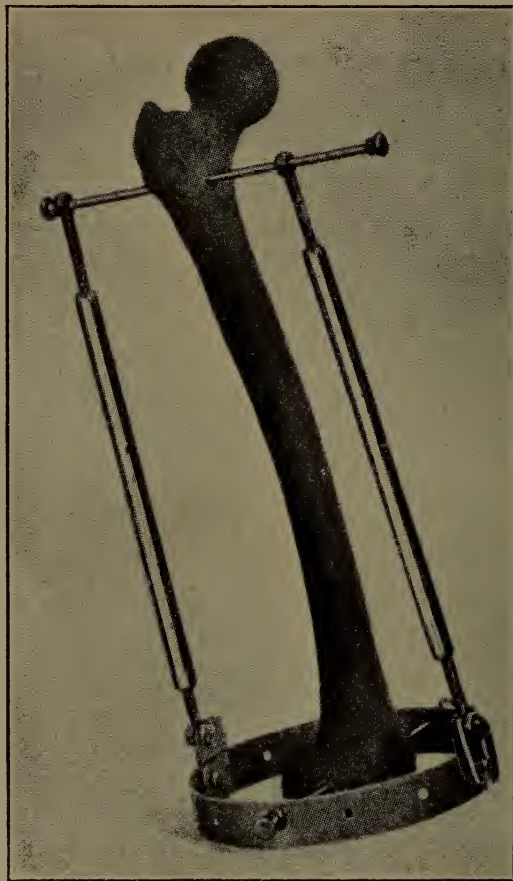

FIG. 113.—Double transfixion apparatus applied to the femur. Note the absence of parallelism of the transfixion pins, the manner in which the metal hoop is attached to the lower pin, and the manner in which the screw extension bars connect upper pin with hoop below. (Groves, Brit. Jour. Surg., Jan., 1915.)

The transfixion apparatus is specially recommended for these conditions. One pin passes transversely through the head of the tibia, the other through the malleoli or os calcis. The same mechanism as described for the humerus, consisting of a perforated hoop with lateral extension bars, is adjusted to these transfixion pins.

These compound fractures of the upper end of the *femur* present greater difficulties of management than almost any other class of

gunshot injuries. There is always great chance of infection, not to speak of the pain which the patient suffers in transportation and dressing.



FIG. 114.—Fractured femur treated by the double transfixion apparatus with little resulting deformity. (*Groves, Brit. Jour. Surg., Jan., 1915.*)

Immobilization, in many cases, it seems almost impossible to secure. The double transfixion apparatus may be applied to these cases with prospect of excellent results (Fig. 113). The inner transfixing pin is passed through the base of the great trochanter



FIG. 115.—Wooden trough splint for leg fracture. Note angles of inclination of thigh and leg. Sides are removable, permitting access to the wounds. (*Groves, Brit. Jour. Surg., Jan., 1915.*)

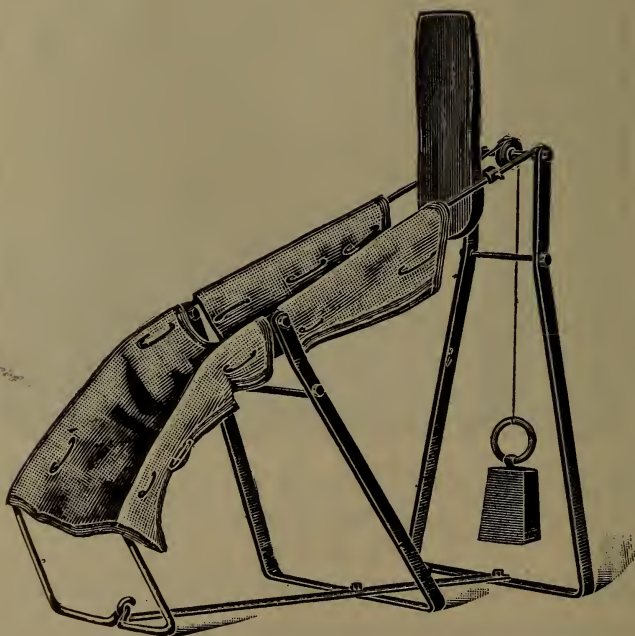

FIG. 116.—Cradle splint. Note manner in which weight is attached to the foot-piece. By lifting the foot-piece to which the foot is bandaged, the limb may be handled without disturbing the traction. (*Groves, Brit. Jour. Surg., Jan., 1915.*)

antero-posteriorly. The lower pin passes from side to side through the condyles. Even in the most severely comminuted shafts good union may be obtained (Fig. 114).

In many of the septic cases it will not be feasible to carry out this plan and, again, other forms of treatment must be available where

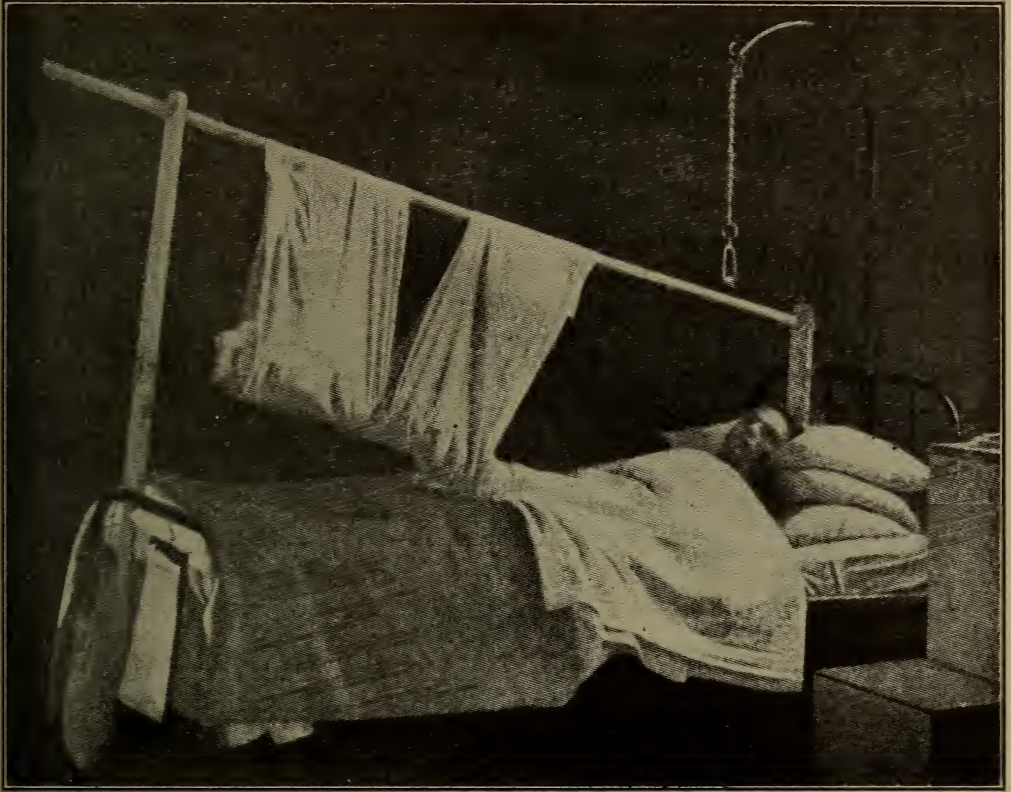

FIG. 117.—The Florschütz method of suspension and extension in the case of fractures of the upper end of the femur is more easily adjusted than the Hodgen splint. The uprights, which support the horizontal bar, can be attached to any bed and the pulley can be attached to any height. In this case, a patient from the 2nd Southern General Hospital, a 12-pound bag of sand is used for extension. (*Groves, Brit. Jour. Surg., Jan., 1915.*)

there is lack of mechanical skill in the adjustment of such an apparatus.

The wooden trough splint is simple and fairly efficient (Fig. 115). It is provided with two inclines, one for the thigh at an angle of forty-five degrees and one for the leg. The foot is bandaged to the foot-piece and the sides are removable to facilitate the dressings.

The cradle splint operates on the same principle, except that

extension is added to position. The foot is bandaged to the foot-piece and to this the weight is attached (Fig. 116). It permits the limb to be moved without relaxing the pull of the extension weight, by lifting the foot-piece off the frame.

For wounds and fractures near the hip joint the Florschütz method is simple and efficient, the thigh and leg being slung from a bar above the bed (Fig. 117).

TREATMENT OF GUNSHOT WOUNDS OF JOINTS

In the simple perforating cases the skin is sterilized, the wound dressed and the joint immobilized. As soon as the wound is healed, begin with cautious passive motion and, usually, an excellent functional result is obtained. If, on the other hand, suppuration occurs, arthrotomy is indicated. If there is much comminution to begin with, the soft parts lacerated, it will often be better to amputate.

The *shoulder-joint* usually furnishes a good prognosis while, on the other hand, the *hip-joint* presents a bad outlook on account of infection and of complications involving the rectum, bladder, etc.

The *knee-joint* is very frequently wounded and the damage is always serious. Hemorrhage into the joint is a constant feature, the hemarthrosis disappearing in about a month in the favorable cases. Under conservative and expectant treatment the results are surprisingly good.

TREATMENT OF GUNSHOT WOUNDS OF SKULL AND BRAIN

Most perforating wounds of the skull prove fatal. The fatalities increase as the range of the bullet shortens and as the impact approaches the base of the skull, death resulting from injury to the automatic centers. The most recoveries follow injury to the frontal lobes. Blindness may result from injury to the occipital lobes. Primary union of the scalp wound is an element in favorable prognosis, since by this means infection is more likely to be eliminated.

First aid on the battlefield will look to the hemorrhage. The first-aid dressing should include both the wound of entrance and exit. In the case of external hemorrhage, packing the wound is contra-

indicated; a few strips of sterile gauze loosely packed in the wound will favor hemostasis and antisepsis. At the field hospital a craniectomy should be done.

All surgeons experienced in recent wars agree on the necessity of exploring every such wound as soon as possible. Where long transportation is necessary before a trephining can be done, the mortal-

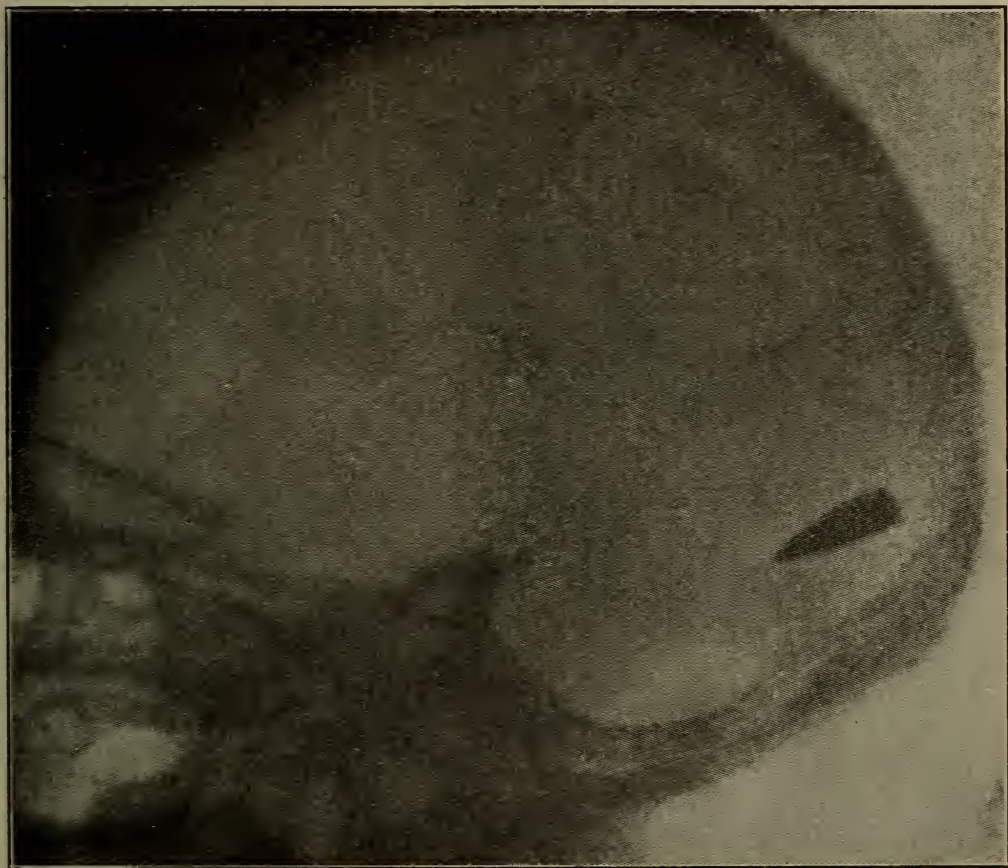

FIG. 118.—Bullet in the tentorium cerebelli. Large clear space above indicates part of skull blown away. Operation; good recovery. (*Harris, Brit. Jour. Surg., Jan., 1915.*)

ity is naturally greatly increased. Enlarging the wound in the scalp, enlarging the wound in the skull sufficiently to remove all fragments of bone and débris, controlling the hemorrhage and providing drainage—these represent the chief elements of relief. (See Urgent Craniectomy.) If infection occurs the wound is to be opened up. Disturbances of the sensorium, of motion and sensation often improve




FIG. 119.—Bullet lying in the petrous portion of the temporal bone. Treated by temporal decompression; bullet left *in situ*; good recovery. (Harris, Brit. Jour. Surg., Jan., 1915.)

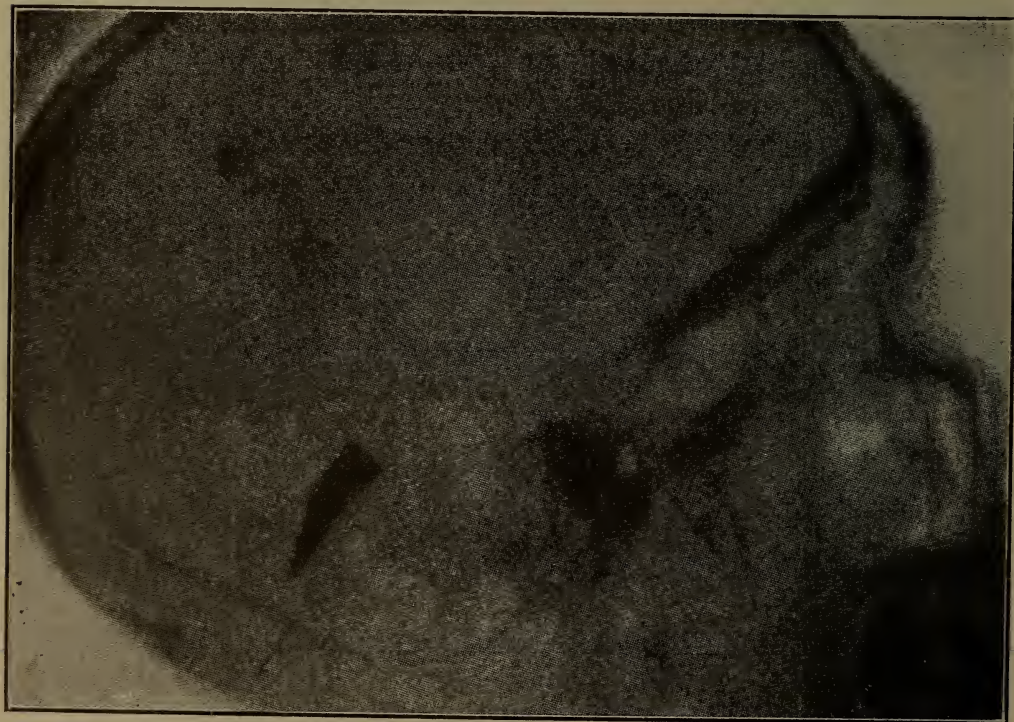


FIG. 120.—Bullet lying in tentorium cerebelli, having entered left parietal region. Marked cerebral compression. Wound of entrance trephined. Bullet removed later, trephining the right occipital region. Good recovery. (Harris, Brit. Jour. Surg., Jan., 1915.)

as by magic following these interventions. A study of the case reports from European hospitals confirms these views (Figs. 118, 119, 120).

TREATMENT OF GUNSHOT WOUNDS OF THE FACE

The chief dangers in these wounds are hemorrhage, infection and interference with respiration. The eye, the fifth and seventh nerves,



FIG. 121.—Bullet lodged in the base of the neck, having first perforated the tuberosity of the humerus and the acromion process. Note that the bullet is turned end for end and is pointing at the wound of entrance. (*Harris, Brit. Jour. Surg., Jan., 1915.*)

are most likely to be involved and these injuries are to be treated on general principles. Control of hemorrhage may call for ligation of the facial, temporal or even the external carotid arteries. Careful cleansing and packing with iodoform gauze secure excellent results.

TREATMENT OF GUNSHOT WOUNDS OF THE NECK

These wounds are always dangerous and yet in no other region does the unexpected more frequently happen in the passage of a

bullet. The fact of hairbreadth escape of important structures is explainable only by the small size of the army bullet and the mobility of the structures (Fig. 121). The transverse or oblique track is most common. Such wounds as are not immediately fatal are likely to recover. Sepsis usually has its origin in the air passages or the esophagus. Injuries to the trachea give rise to hemoptysis, emphysema or broncho-pneumonia. Gangrene of the esophagus may occur. Aneurism is not infrequent. Any of the nerves may be injured.



FIG. 122.—French boy (Hotel Majestic) shot from side to side through the neck, the bullet passing between the trachea and esophagus. Tracheotomy required on account of dyspnea. Leakage of fluids from an esophageal fistula which closed in a few days. Tracheotomy tube still in place. (*Thorburn, Brit. Jour. Surg., Jan., 1915.*)

No special treatment is called for beyond the hemostasis and antisepsis, unless occasionally a tracheotomy may be indicated (Fig. 122).

TREATMENT OF GUNSHOT WOUNDS OF THE SPINE

The treatment of wounds of the spine must be conservative; that is to say, that very rarely will immediate operation be indicated. Absence of the deep reflexes must not be taken to indicate complete rupture of the cord but if motion and sensation do not improve in

ten days a laminectomy may be performed. If the laminectomy does not seem to restore the pulsation of the cord the theca must be opened and the clots removed. Recovery does not always take place even though the cord is not lacerated.

TREATMENT OF GUNSHOT WOUNDS OF THE ABDOMEN

Rotter (Berlin. Medizin. Klinik, Jan. 13, 1915) states as the result of his studies of this class of injuries that the mortality on the field is 90 per cent.; among those living to reach the field hospital 80 per cent. die; of those reaching the clearing hospitals 40 per cent. die, and finally those who reach the base hospitals recover.

Spontaneous cure is possible only when the perforation is small and single and the bowel empty. If the patient is seen within twelve hours he advises operation and states that the conditions are so good in the German field hospitals that one need not fear sepsis by reason of the operation done there.

From the other armies the reports are not so favorable to operative treatment and most of the authorities reluctantly admit the inefficiency of operation in the field hospitals and the better, though unsatisfactory, results of conservative treatment. The prognosis varies with the part of the digestive tube involved. The ascending and descending colon and the cecum gives the best prognosis; the stomach is not quite so favorable, and the perforation of the transverse colon and small intestine are most likely to result fatally.

TREATMENT OF WOUNDS OF THE THORAX

The non-perforating wounds need only an antiseptic dressing. Broken ribs will require adhesive strapping.

The perforating wounds presenting no special indications of hemorrhage from the chest wall are to be treated by aseptic occlusion.

The internal mammary or the intercostal arteries may need to be controlled. If the hemorrhage is visceral, opium and compression of the chest wall by firm bandaging seem to be the last resort in time of war. Under no circumstances is the wound to be probed or examined with the finger. Transportation is always to be feared.

In every way the patient is to be kept as quiet as possible. He must be made to realize the seriousness of his injury. Paracentesis should not be performed in the case of hemothorax until the bleeding has ceased. Thoracotomy is to be performed if suppuration occurs. (See Injuries of Thorax.)



FIG. 123.—Fragments of Vickers-Maxim 1-pound shell. (*Makins.*)

SHELL AND SHRAPNEL WOUNDS

These wounds constitute a very large percentage of the casualties of battle. Following the usual classification they may be designated as contusions or lacerations, much more frequently the latter.

These injuries may be arranged in groups:

1. Large, destructive, mutilating wounds, often resulting in immediate death. A whole limb may be irrevocably damaged; half the skull shot away; the thoracic or abdominal cavities torn open.

2. A multiplicity of small wounds penetrating no deeper than the fascia and containing fragments of the shell or its contents. There may be thirty or forty such wounds scattered over the trunk and limbs.

3. Surface wounds; the margins irregular; the skin often bruised or burned; no fragments retained.



FIG. 124.—Shrapnel bullets normal and deformed. (*Makins.*)

4. Penetrating wounds caused by a single fragment of shell, passing right through the affected region. The wound exit is always much larger than wound of entrance. Its edges are everted, fat and muscle tissue often protruding. The edges of the entry wound are inverted and often charred. The tissues are widely destroyed, the skin presenting a brawny appearance, due to interstitial hemorrhage.

5. A single penetrating wound, the fragment retained. As in the other cases the amount of deep damage is out of proportion to the size of the wound entry. That these projectiles should pro-

duce such terrible lacerations in many cases is at once apparent from a study of their character (Figs. 123, 124, 125).

Isolated injuries to nerves and vessels are unknown. Muscles, vessels, nerves and bones all share together in the destruction caused by these irregularly shaped missiles. The great tendency to infection is not inherent in the wound but in the environment, for according to Pannett it is astonishing how mild the infection is in such




FIG. 125.—Fragments of shells (two-thirds natural size) removed from various wounds received in naval combat. The shrapnel fired by the Germans consist of irregular metallic fragments—not the round bullets found in English shrapnel pictured above. (*Pannett*, *Brit. Jour. Surg.*, Jan., 1915.)

wounds received in naval warfare, by reason of the absence of earth dust and, in many cases, by reason of a longer or shorter sea bath (*British Journal of Surgery*, Jan. 11, 1915).

In the limbs all degrees of destruction are met with, from absolute mangling to tearing of the soft parts with compound comminuted fractures of various degrees. Whether immediate amputation shall be practised depends on general principles referable to the blood

supply. If the circulation of the member is compromised beyond hope, amputation should be performed without delay (Fig. 126).

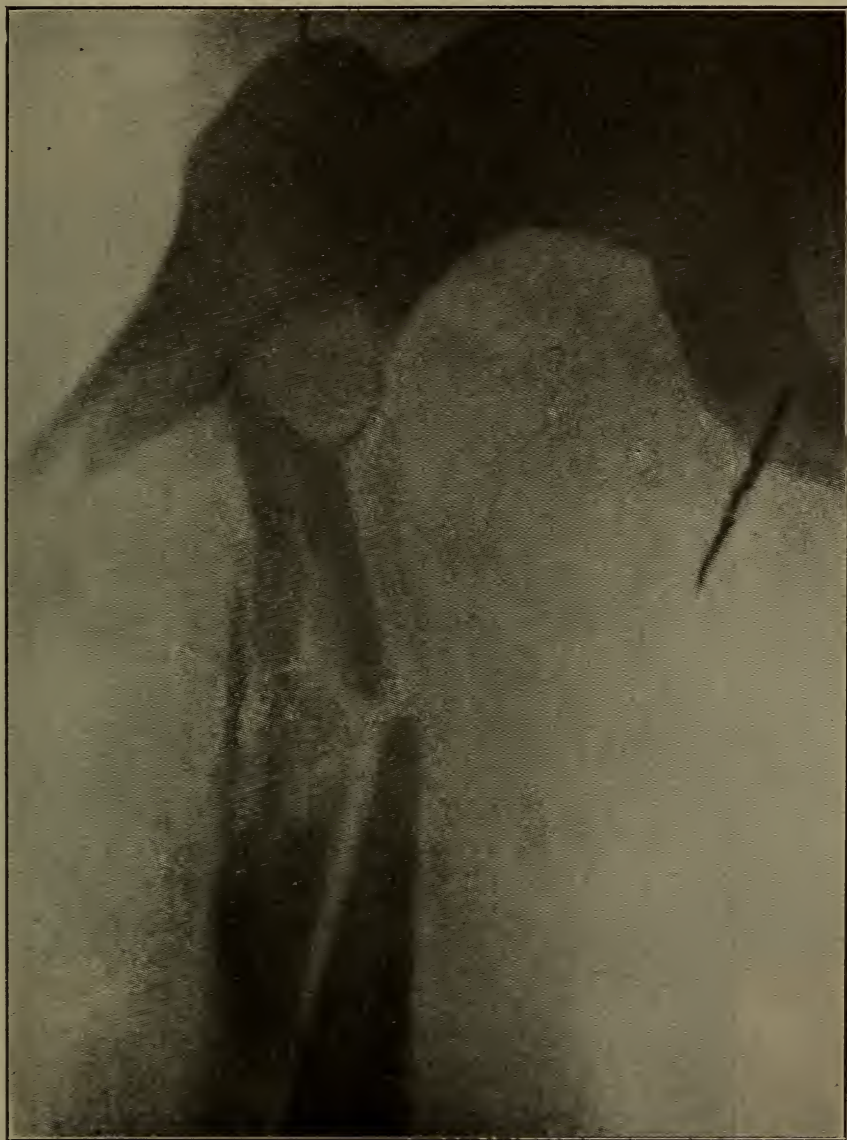

FIG. 126.—Shrapnel wound. Comminuted fracture of the femur. Frightful mangling of soft parts. Amputation. (*Harris, Brit. Jour. Surg., Jan., 1915.*)

In other cases, especially if the wound is produced by the leaden balls of shrapnel, the limb may be treated as in the ordinary case of compound fracture (Fig. 127).

Lacerated scalp wounds with compound fracture of the vertex are common.

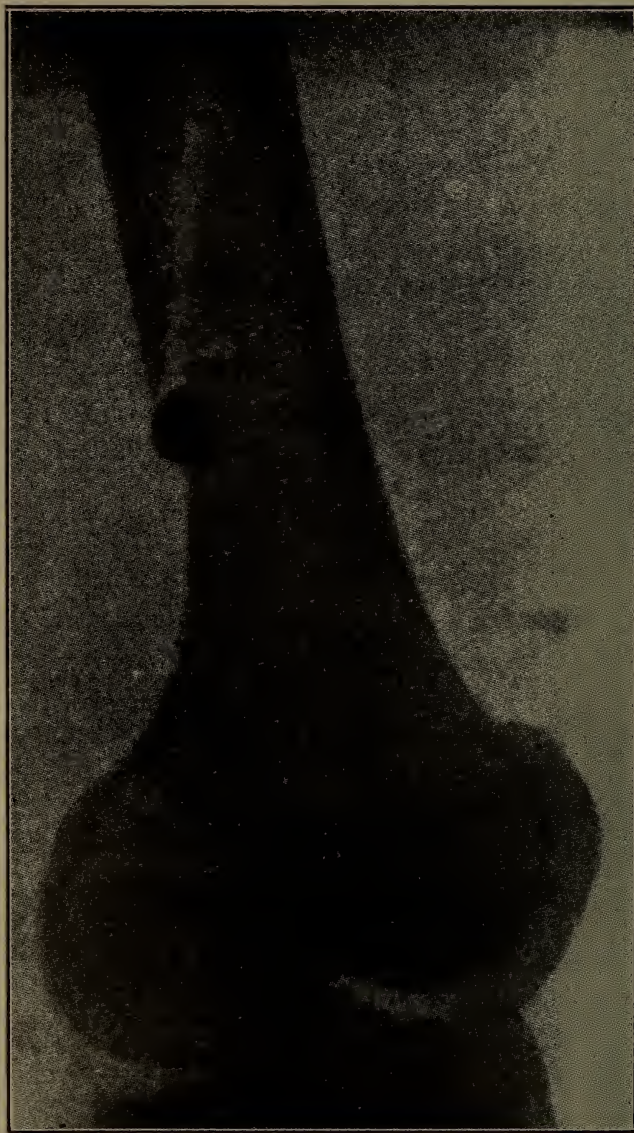


FIG. 127.—Fracture of lower third of femur. Round shrapnel ball *in situ*. (Harris, Brit. Jour. Surg., Jan., 1915.)

In the face, horrible disfigurements result; an eye may be destroyed; the mouth cavity exposed; the bones of the orbit, face or jaws splintered.

Chest injuries of this type are usually fatal, either from shock or hemorrhage.

Occasionally, however, a fragment of shell may traverse the thorax with a result no more serious than a severe hemothorax. Small fragments may be deflected by the ribs without fracture. A fragment may lodge in the thorax and empyema is likely to ensue (Fig. 128).



FIG. 128.—Shell wound of base of thorax. Empyema and subphrenic abscess, communicating through a hole in diaphragm. (*Thorburn, Brit. Jour. Surg., Jan., 1915.*)

In the abdomen such wounds are almost universally fatal. If the wound is limited to the parietes, however, recovery may follow. In some such cases the contusion of the bowel may result in a fecal fistula (Fig. 129).

All these wounds are to be treated along the lines already discussed in connection with bullet wounds. In the matter of amputation Fitz Maurice Kelly calls attention to the great advantages of a

simple circular section of all tissues at the same level. After infection is passed a second operation is done and flaps formed.

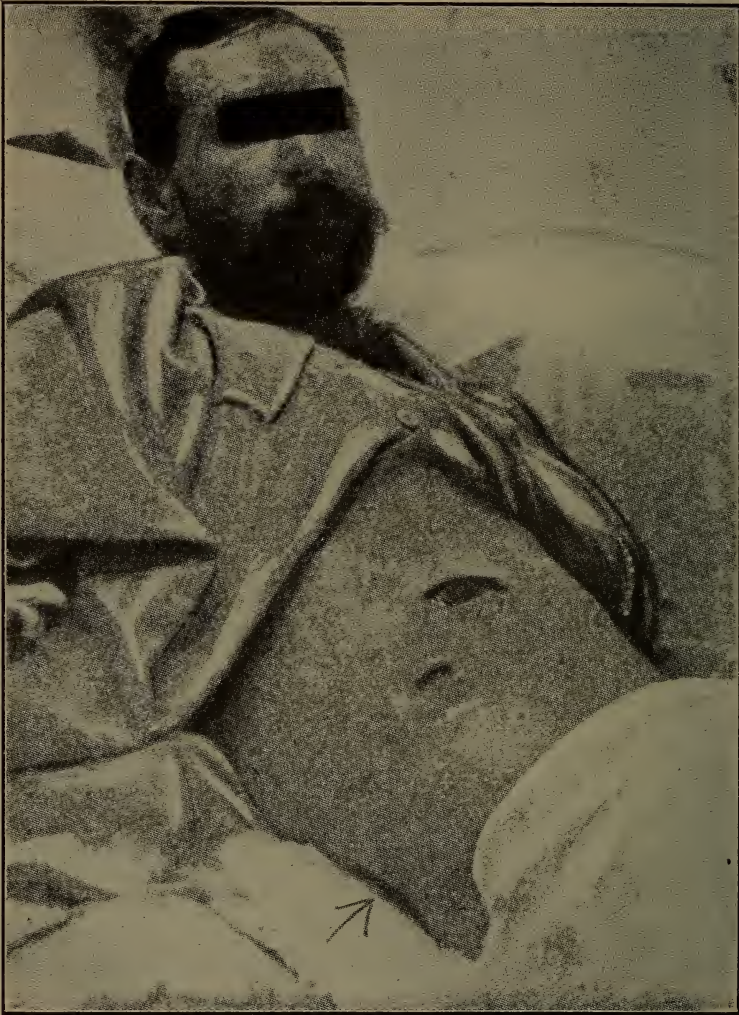


FIG. 129.—Shell wound perforating abdomen. Arrow shows aperture of entry; the topmost wound the exit; the middle wound marks site of a subsequent fecal fistula leading into the descending colon. (*Pannett, Brit. Jour. Surg., Jan., 1915.*)

BOLO WOUNDS

According to Foxworthy (*Ft. Wayne Medical Journal*, June, 1902), every insurgent in the Philippines was armed with a bolo. "This bolo was of iron with a wood or bone handle and varied in shape and size from a sword to a dagger and from a corn knife to a meat ax.

It was generally a cruder weapon than the Cuban machete, but very effective in close encounters. As it could be concealed beneath the loose jacket, it was more serviceable than a sword or saber, which was always visible. The kries is a weapon similar to the bolo, but with a wavy edge like a Christy bread-knife. It is often two-edged. The wounds produced by the bolo and kries were often of great length and usually infected.

"Another class of wounds was caused by spears and tomahawks, used by the Igorrotes and Negrites. The tomahawk, having a concave edge, was not so apt to glance off the skull as an Indian tomahawk. A blow split the skull wide open.

The spears were often of bamboo, sharpened to a fine point, and their penetrating power was almost equal to that of an iron-tipped spear. The iron-tipped spear had from one to four barbs which made an exceedingly ugly penetrating wound and usually had to be cut out. These wounds were always infected and tetanus frequently developed."

FIRST AID ON THE BATTLEFIELD

Colonel Nicholas Senn, in his address before the Lisbon International Medical Congress, 1906, formulated the principles of first aid on the battle field, and his conclusions though needing revision in the light of recent events are nevertheless herewith summarized:

(1) The fate of the wounded depends largely upon the time and thoroughness with which first aid is rendered. This first aid for many reasons cannot be rendered by the surgeon, but must be given by comrades or by the wounded man to himself. First aid administered in this manner will be effective, owing to the aseptic character of the chief wounds of battle, if previous instructions have been given. It is absolutely essential that the soldier should receive this elementary instruction when he is taught the art of war, and it should not be postponed as has been done only too often in the past until war clouds make their appearance.

(2) The first-aid dressing should combine simplicity with safety against post-injury infection. It should be on the person of every combatant and must be simple to be efficient. It must be compact and easy of application.

"The dressing consists essentially of two pads of cotton, wrapped in gauze, and fastened together by two stitches and continuous with a gauze roller, which is made use of instead of the triangular bandage for holding the dressing in place and for immobilizing the injured part. The gauze roller should take the place of the triangular bandage in every first-aid dressing as it requires much less space and is more serviceable as a means of fixation and support.

"The brown iodine spot in the center of the pad on the side to be brought in contact with the wound corresponds with the location of the anti-septic powder incorporated in the absorbent cotton and serves as an infallible guide in applying the pad in the right place."

(3) The first aid must have in view the treatment of shock and hemorrhage, dressing of the wound, and immobilization of the injured part.

The treatment of shock in the field is very unsatisfactory, but, fortunately, shock is not a characteristic of small-caliber bullet wounds. Rest in the recumbent position; hypodermic injection of $\frac{1}{4}$ grain of morphine; spirits internally—these answer the most urgent indications.

The treatment of hemorrhage at the front must be conducted with the greatest caution. Elastic constriction, if too generally practised, will do vastly more harm than good. It should be applied only in exceptional cases and then by a competent member of the hospital corps or a medical officer, who must make it his duty to send the case to the first dressing station as quickly as possible, where definitive hemostasis can take the place of the constrictor. There are less harmful means of hemostasis which will be efficient in most cases: elevation of the limb (Figs. 130, 131), acute flexion of the joint above the wound (Figs. 132, 133), digital compression over the dressing—these are measures which must be taught.

Direct treatment of internal hemorrhage of any of the large



FIG. 130.—Elevation of upper extremity in the treatment of hemorrhage. (Senn.)

cavities is entirely out of the question at or near the firing line. The cartridge belt, suspenders, or gunstrap can be used to the greatest advantage in limiting respiratory and abdominal movements and thus secure for the vascular bleeding organs a condition of rest, conducive to spontaneous arrest of hemorrhage (Fig. 134).

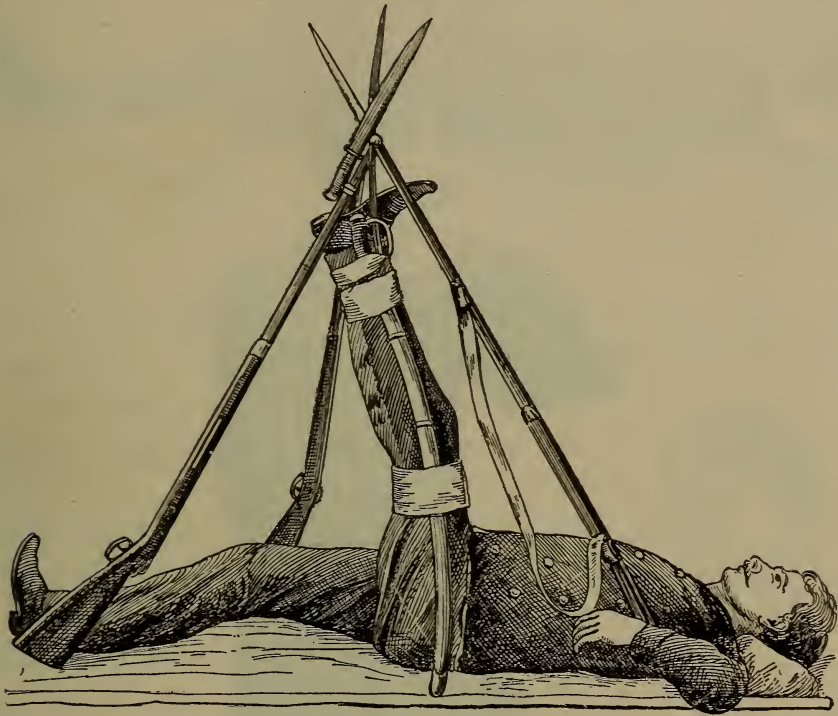

FIG. 131.—Gunstack for elevation of the lower extremity. (Senn.)

Immobilization is an essential part of first-aid treatment, conducing to primary repair, relieving pain, and preventing infection by securing the first-aid dressing.

The ideal fixation splint in such cases would be the plaster-of-Paris splint, but this method of fixation is entirely out of the question on the firing line and must be reserved for the dressing station of field hospital. This first-aid fixation must be extemporized. The sound leg may serve as a splint for the wounded one which is held in place by belt, gunstrap, handkerchief, etc. The rifle, bayonet, and saber are always available as splints (Figs. 135, 136, 137).

A fractured humerus may be splinted to the side of the body.

A well-padded bayonet will meet the indications in fracture of the forearm. The wire netting cut in the shape corresponding to the fixation of the different fractures of the limbs should be carried to the front by the sanitary corps in sufficient quantities to meet the expected requirement. Splints made of this material, well-padded, will answer an excellent purpose as first-aid fixation, as they can be



FIG. 132.—Forced flexion of the elbow-joint in arresting hemorrhage from the brachial in that region. (*Senn.*)

molded into shape and can be used subsequently to strengthen the plaster bandage at the dressing station.

(4) The first-dressing station is the most important place for skilled aid. This primary depot of the wounded should be established in a sheltered place as near as possible to the firing line, protected as much as possible against the fire of the enemy.

(5) Probing of recent gunshot wounds must be prohibited by the

most stringent rules. Under no circumstances should attempts be made to remove bullets until this can be done under strict aseptic




FIG. 133.—Forced flexion of the knee in hemorrhage from the popliteal region. (Senn.)

precautions in the hospital, and then only in those cases in which such operation is clearly indicated and the exact location of the bullet has been determined by palpation through the intact skin or by the use of the "X-ray."

(6) The surgeon's most important duties at the first-dressing station are:

(a) Inspection of first-aid dressing. If it is in its proper place, label to this effect that it may not be unnecessarily removed at the hospital. If defective, it must be renewed or more securely fastened.

(b) Application of plaster splints to the fractured limbs; the wire-netting splints are cut into strips and incorporated in the plaster-of-Paris dressing.

(c) Emergency operations. The operative treatment of gunshot wounds must be limited to the most urgent cases. The definitive arrest of hemorrhage—of dangerous external or internal hemorrhage—stands pre-eminent in the list of emergency operations. Iodized catgut is the proper ligature material for field service.




FIG. 134.—Perforating wound of chest, aseptic tamponade and immobilization by circular compression. (Senn.)

Intra-cranial and intra-thoracic hemorrhage should not be interfered with outside of a well-equipped hospital. Dangerous intra-abdominal hemorrhage calls for prompt operative interference.

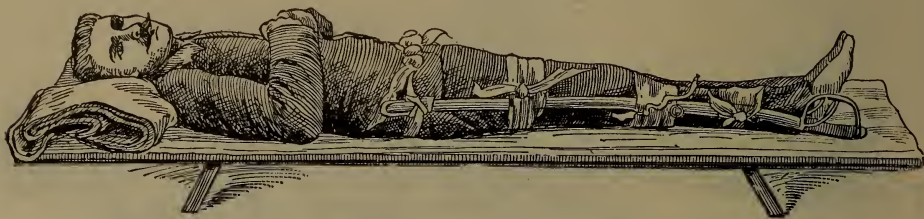

FIG. 135.—Saber splint for leg and thigh. (Senn.)

Abdominal section under such circumstances, in a tent, may contribute much in lessening the mortality from hemorrhage by a resort to ligature, suture, or aseptic tamponade.

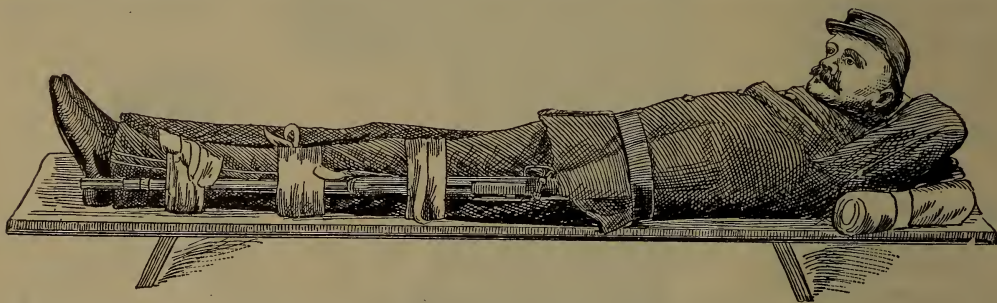


FIG. 136.—Gun splint. (Senn.)

By pursuing this aggressive course, some lives may be saved by prompt interference which would be lost by the let-alone treatment.

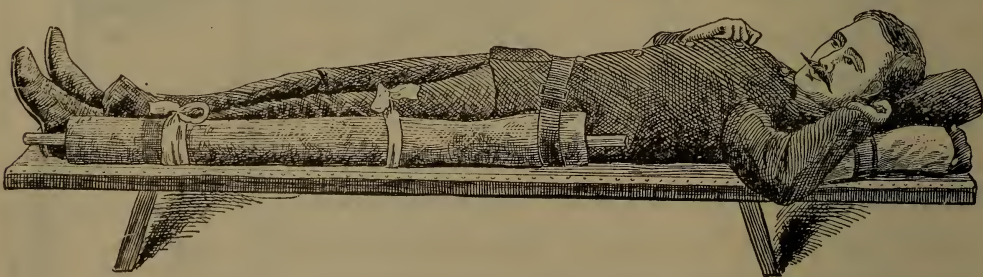


FIG. 137.—Stick and blanket splint. (Senn.)

Wounds of the larynx and trachea which have given rise to respiratory difficulties, either from emphysema or hemorrhage, call for an immediate tracheotomy.

Resection, as a primary operation for penetrating gunshot wounds of the joints, is obsolete.

Amputation must be reserved for cases in which a limb has become mangled by a cannon ball or fragment of shell or in which the fracture is complicated by division of the principal blood-vessels and nerves.

Laparotomy in the field, for gunshot wounds of the abdomen, with a view of finding and suturing perforations of the gastrointestinal canal, has not yielded in practice the anticipated results, and hence must be restricted to exceptional cases.

Clinical experience has shown that in a fair percentage of cases penetrating wounds at and above the level of the umbilicus, inflicted in the antero-posterior direction, do not implicate the gastrointestinal canal, and in such cases conservative treatment yields better results than operative. On the other hand, in wounds involving the small intestine area, more especially when the bullet takes an oblique or transverse course, we may confidently expect to find from three to fifteen perforations, and it is in this class of cases in which immediate laparotomy offers the only chance of saving life.

(7) The surgeon's field case should be light, compact, and the instruments wrapped in a canvas roll, so that instruments and envelope can be quickly sterilized in boiling soda solution.

CHAPTER XIII

GUNSHOT WOUNDS IN CIVIL PRACTICE

The projectiles of the ordinary fire-arms of civil life differ from those used in warfare, in that they are composed of soft lead, are easily deformed, are of slight initial velocity, and are usually fired at short range.

The revolver and pistol, flobert and shot-gun produce the wounds most frequently seen.

Of the shot-gun it may be said that the wounds which it produces are very likely to be either greatly destructive or comparatively harmless. At close range the charge, acting as a single body, lacerates and shreds the tissues; at long range a number of small perforations are made.

The dangerous wounds, then, have all the characteristics of lacerations and demand the treatment of lacerated wounds in general. It must always be assumed that foreign bodies have been carried into the tissues and that these wounds are therefore infected.

It is the bullet wound of the revolver, however, which it is most practical to consider. To a limited extent, its pathology is similar to that of the army bullet, and it is unnecessary to state again the effect of a bullet upon the various tissues. It is expedient to consider at once, with especial reference to treatment, the bullet wounds of certain localities.

But let it be emphasized in this connection that the course of the bullet can never be accurately determined.

Always be on the alert for the unexpected and insist, however simple the wound may appear to be, that the patient be kept under close surveillance. The wound may seem to be a flesh wound of the thigh, for example, and may be dismissed as such; later, and too late perhaps, it may be discovered that the peritoneal cavity was involved. And this happened to a boy of ten who was brought to the City

Hospital with not the slightest symptoms to indicate any serious injury. Too late, it was found that the intestine was perforated in many places.

Again, however well assured we may be that no serious damage has been done we shall nevertheless watch for signs of hemorrhage or beginning infection.

We must remember, too, that infection may develop late.

A man of thirty-five was brought in with a 38 bullet wound in the region of the knee. His limb was swelling rapidly and he was immediately prepared for operation.

The bullet had bored through the upper end of the tibia from in front backward and lodged in the popliteal space. A counter opening was made from behind, the bullet extracted. The hemorrhage indicated an arterial wound and following the track of the bullet, the anterior tibial was found divided near its point of origin. It was ligated, the posterior opening in the tibia located and a strip of gauze saturated with iodine passed through the hole in the bone. Drainage left in both anterior and posterior openings.

For a week the patient did well and was thought to be entirely out of danger. At that time however his temperature rose and very shortly there were signs of suppuration and, in spite of free drainage, gangrene developed and the limb was amputated well above the knee. But the flaps refused to heal and, grave symptoms of general, sepsis supervened. He died three weeks after his injury and the postmortem revealed a septic thrombus along the whole length of the femoral vein.

WOUNDS OF THE HEAD

The region of the brain is usually wounded in attempts at suicide, and it is the right temple or forehead which is most frequently selected. The vertex, postero-lateral, and occipital regions are seldom wounded and only then as a result of accident or assault.

As medico-legal questions are often involved in these cases, it is a wise practice to make careful and systematic examinations. Learn as much as possible about the character of the fire-arm, the nature of the projectile, the position of the patient at the time of injury.

Examine the ears and nose for blood, inspect the mouth, examine the head for a wound of exit, or see if the bullet can be located beneath the scalp.

Next examine the wound itself, but not until the field and wound have been sterilized. Begin the disinfection by shaving the scalp about the wound. Wash with soap and water and then with alcohol or bichloride.

Enlarge the wound by a cross incision, if necessary, and wipe out with sterile gauze, removing all forms of foreign bodies.

Finally examine the *skull*. If you find a mere depression without penetration, it is sufficient to pack the opening with sterile gauze, and bandage. Later the bullet may be located with the "X-ray" and removed, if it becomes troublesome. If the bullet is visible and removable without much difficulty, it is better to take it out at once.

If the ball has penetrated the entire thickness of the skull and lodged within the cavity, the size of the orifice will be some index as to its probable depth; if the orifice is large, it argues for close range and deep lodgment. If the opening is small, comparatively speaking, it is likely that the ball has not penetrated deeply. Note the direction of the fissures. If the base is involved the prognosis is always serious. Note the condition of the dura: it may be lacerated and the brain tissues may exude. If such is the case, the bullet is obviously in the brain, but its exact location must remain a matter of doubt. It is not expedient to explore it; it is not even advisable to attempt to disinfect the cerebral wound.

It is sufficient to remove all fragments of bone and débris and wipe the wound dry with sterile gauze. On these two points, however, there may be some difference of opinion. The American Text-book of Surgery insists upon the value of disinfection of the entire cerebral track of the bullet and of through-and-through drainage under certain circumstances; also upon the advisability of attempting to locate the bullet by the aluminium gravity probe, and to remove it. Still it may be said that the general practitioner has done his duty and done it well if he has cleansed the skull and dural wounds and controlled the hemorrhage. (For further details of treatments, see Urgent Craniectomy.)

GUNSHOT WOUNDS OF THE SPINE

A man was brought into the City Hospital shot in the back with a 38 revolver. Except that he was paralyzed from his hips down and without control of his bladder and bowels, his condition was good. This positive primary paralysis pointed to grave injury to the cord. At the operation it was found that the bullet had smashed into the spinal canal and there lodged, completely obliterating in

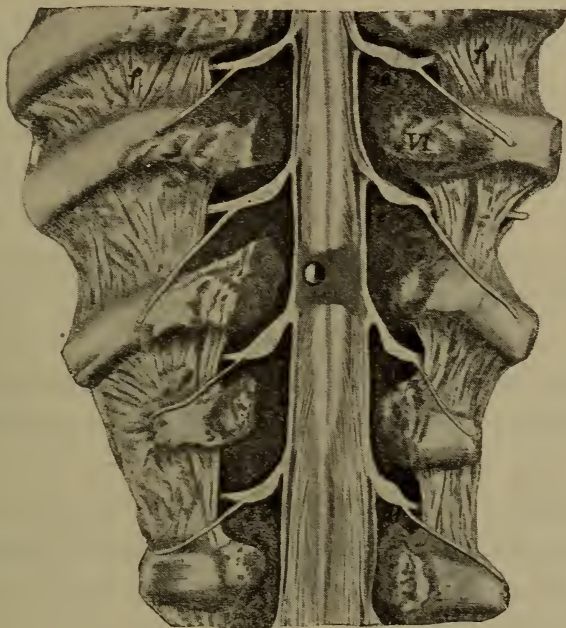


FIG. 138.—Complete division of spinal cord; bullet retained.

its course a considerable segment of the spinal cord (Fig. 138). Suture of the cord was out of the question, so the poor fellow—a man of great vitality—was condemned to linger in living death for many weeks.

Happily not all cases of gunshot wound involving the cord are beyond relief. Whenever the symptoms point to severe injury of the cord—whenever there are notable disturbances of sensation and motion—and improvement fails to take place shortly, it is bad practice to delay. It is indicated to cut down upon the spine, remove a spinous process, trephine into the canal, and cautiously cut away the arches. It may develop that the symptoms are due

merely to pressure of fragments of bone which are to be removed. If after gunshot wounds of the spine there are no cord symptoms or if they are mild and tend to improve, it is better not to operate. The smaller the projectile the less the likelihood that operation will be required. Without some positive indication in the cord, therefore, aseptic occlusion is the treatment to pursue. Probing is all the more perilous because infection may be carried directly to the spinal meninges.

GUNSHOT WOUNDS OF THE FACE

These may result from shots into the mouth with suicidal intent. Small bullets may remain imbedded in the hard palate or posterior pharyngeal wall. The instinctive tilting of the head backward gives the bullet a characteristic course through the hard palate or the root of the nose, and, owing to the involvement of the base of the brain, such wounds are deadly, except with quite small firearms.

In other cases there are grave comminuted fractures of either jaw. Sometimes there are powder burns and disintegrations suggestive of explosions.

The chief dangers in cases not immediately fatal are from interference with respiration and from hemorrhage. These wounds are also predisposed to infection, and as a result of sepsis secondary hemorrhage is not infrequent. Paralysis of the facial nerve may occur. The salivary glands or their ducts may be injured and give rise to a troublesome dribbling of saliva. Marked interference with respiration may call for immediate tracheotomy.

Arteries may need to be ligated and ligation may be difficult owing to their relation to the bones. The oozing, always marked, is to be controlled by pressure. The natural contour is to be restored as much as possible after a thorough cleansing, and the wound cavities packed with iodoform gauze. A young man was brought to the City Hospital with gunshot wound of the face, the range so close the skin was powder burned. He was bleeding profusely from the mouth. It was found that the bullet, a 38, had entered the left upper-jaw, passed through it into the nasopharynx, carrying away part of the soft palate and still ranging slightly downward had lodged in the

middle of the neck of the opposite side. It was located about the depth of the sterno mastoid. An incision under local anesthesia was made and a dissection carried down to the bullet. It was grasped with forceps but slipped away and on further attempts to seize it, was pushed back into the pharynx and coughed out.

The wound in the jaw was injected with peroxide which escaped through the mouth.

Finally a slip of sterile gauze was carried through the channel in the jaw, one end of the strip left in contact with the lacerated tissues of the soft palate, the outer end projecting from the wound. Some oozing persisted for twenty-four hours. On the second day the strip was removed and the wound injected with weak peroxide solution. No infection arose and he recovered rapidly, apparently none the worse for the injury.

GUNSHOT WOUNDS OF THE THORAX

Gunshot wounds of the thorax do not differ from other wounds in this region except in their graver prognosis. (See page 110, Wounds of Thorax, and page 149, Military Practice.) Such as involve the great vessels at the root of the lungs and most of those which involve the heart are not even of interest from a standpoint of treatment because so rapidly fatal as to preclude intervention.

Such wounds as are not obviously fatal, whether they involve the pleura and lungs or the pericardium and heart, present three sources of danger: hemorrhage, asphyxia, and infection. These are the three conditions which determine the line of treatment, and which have already been discussed under the head of Wounds of the Thorax.

Aside from these symptoms of urgency, the treatment must be conservative and expectant—quite different from gunshot wounds of the abdomen.

Begin by covering the wound with an aseptic compress and then carefully disinfect the field. Finally cleanse the wound itself and dress antiseptically. Avoid probing or other explorations.

Transportation must also be avoided, for there can be no doubt that it is often disastrous. In the country, where ambulances are out of the question, the nearest shelter is the best.

If it is evident, finally, that the hemorrhage is increasing, as indicated by the symptoms and physical signs, conservatism is no longer rational and the wounded lung should be exposed and the tear repaired. In the event a tear is found in a pulmonary vein a ligature must be placed on either side of the tear. Recovery may follow without lung complications.

Kütner, of Leipsic, proposes in the future when dealing with these wounds to evacuate the extravasated blood if it is not promptly absorbed, suturing the pleura without drainage. In the case of an already collapsed lung it does not appear that there would be increased danger operating without the aid of a Sauerbruch cabinet.

BULLET WOUNDS OF THE ABDOMEN

With reference to prognosis and treatment, these wounds fall into three clinical groups: those which are obviously penetrating and accompanied by grave visceral lesions; those which are doubtful both as to penetration and visceral injury; and those which are probably benign.

(A) One concludes that a certain wound is grave not from observing the escape of gas and fecal matter, or hemorrhage from the wound, for these are too infrequent to be relied upon, but from the general condition, which alone is of sufficient significance. The pulse is small and rapid; the face is drawn and pale; the belly wall is distended and resistant to the least pressure; dullness of the iliac fossa and flanks develops and there may be vomiting of stomach contents or of blood.

The persistence of these symptoms for the first two or three hours is sufficient to dispel any illusion of the more sanguine that the case is not dangerous.

There is but one thing to do, *operate as soon as possible*.

This is a principle so definitely established that the citation of a long list of eminent authorities is unnecessary: a rational doctrine that all may accept.

There are contingencies of time and place, of septic environment which would insure that the operation itself would likely be fatal, but those conditions are very exceptional in civil practice with the

doctor who has the "savoir-faire." An exceptional condition does not alter the principle, and he who does not act at once, must incur the reproach of having refused the wounded the best resource of safety.

There is another consideration. One may not be called to see the case until after two or three days have elapsed and may then encounter one of two eventualities: one almost certain, the other unlikely.

In the first, there are the signs of general peritonitis. Under these circumstances, again, the rule is to operate, though only as a forlorn hope.

On the other hand, it may be that despite the apparent gravity of the wounds, the pulse is good, there is no vomiting, the abdomen is not tender, there has been a passage of flatus or a movement of the bowels. Although we know these appearances are often deceitful, that it may be only the lull which precedes the storm, yet we are perfectly justified, under these circumstances, in maintaining an "armed expectancy." Under such circumstances, control peristalsis with a little morphia, impose an absolute quiet and absence of food, and in the meantime have the patient under vigilant surveillance.

Fysche reports a case of abdominal gunshot wound, which shows the value of drainage and which might be taken as an indication of the course to pursue in certain desperate cases, where, for example, the circumstances of time or place, the condition of the patient, or the isolation and lack of skill of the operator precluded a more rational and definite procedure.

A boy of fourteen was shot through the abdomen at close range with a large-caliber revolver. The bullet entered just to the inside of the right anterior-superior spine. There were all the signs of shock and internal hemorrhage. The abdomen was opened with immediate escape of blood and fecal matter. The first portion of the small intestine examined revealed a perforating wound. This and two other wounds were repaired, but the boy's condition called for haste and a hurried examination developed seven more perforations of gut and mesentery along the 6 feet exposed. The abdominal incision was closed with through-and-through sutures

with a large deeply placed drainage wick in the lower angle. He was freely stimulated and given large enemata of normal salt solution. The drainage was removed on the second day and from the opening there was a free fecal discharge. On the third day his bowels moved naturally. Thereafter the fistula closed rapidly and in a month he seemed quite well. (Montreal Med. Jour., May, 1909).

(B) The case is one of doubtful penetration and therefore doubtful visceral injury.

You are called immediately. You find nothing more than a bullet wound in some part of the anterior abdominal wall. The pulse is good, the abdomen is neither rigid nor tender, and there is no other indication worth noting.

Now, what are you to do? Wait several hours watching for some indication? But this is a dangerous formula, subject to various interpretations, for, as Lejars asks, what shall be regarded as the first "indication"—the weaker pulse, the tympanites, the altered facies? But these are the signs of beginning peritonitis.

It is better, as Brown, of St. Louis, and many others have so definitely determined, to answer the question resolutely in these terms: prepare at once to operate; determine whether the wound is a penetrating one or not, and if so, proceed with the laparotomy—provided, of course, that the situation is such that it can be done without very grave danger from the operation itself. It may develop that the operation is not necessary, but it will very much more frequently become evident that it is indispensable.

Admit that these urgent laparotomies are difficult, that they strain every resource of emergency antisepsis and surgical skill, that the perforations are often multiple, that one never knows just what he must meet. Admit that some recover from these wounds without operation, but are we authorized by that to expect in another case so fortunate a denouement? Admit that the patient has several chances of recovery without operation perhaps, but let us remember we have no means of calculating such chances even in the more favorable cases, and certainly the chance of an exceptional process cannot give more hope than an early, regulated, and aseptic intervention.

It is prudence which commands operation. As Lejars says, this seems the wisest course:

Prepare for a laparotomy. Begin by cleansing the field of operation and then the wound, which is enlarged, cutting from above downward, layer by layer. If the peritoneum is found uninjured, repair the incision carefully, first trimming the devitalized tissues away; under these circumstances, one may safely prognosticate a recovery.

If you find the peritoneum perforated, slightly enlarge that wound also, that you may get some idea as to the conditions: a flow of blood, bile, intestinal contents, or urine may indicate what one may expect. But the fact alone of perforation of the peritoneum is an indication to open the abdomen in the middle line—to do a median laparotomy.

The median incision will be above or below the umbilicus, depending upon the level of the bullet wound (see *Laparotomy for Traumatism*).

(C) There are, finally, as Lejars points out, certain bullet wounds which, even though penetrating, may be regarded as unlikely to have produced serious results. These are such as are produced by pistols in which the bullet is quite small and impelled by an insignificant charge of powder, so that its force is practically spent in traversing the abdominal wall.

And even though the digestive tube should be wounded, the opening is not large enough for the contents to escape, for the mucous membrane acts as a plug and repair quickly takes place.

In such a case, there being no doubt as to the facts, it is perhaps wiser not to operate, but to treat by aseptic occlusion. Nevertheless it is the part of prudence, however sanguine of the outcome, to keep the case under close watch for some days.

GUNSHOT WOUNDS OF THE JOINTS

The knee, which is the joint most frequently wounded, may serve as a type. Suppose it is wounded by the discharge of a *fowling-piece*, a not uncommon accident. The character of these wounds

is variable. It may be that only a few shots at long range have penetrated the joint, or it may happen that the whole load has torn its way into the joint structure. But whatever the condition, no active intervention is called for if the case is seen at once.

Cover the wound with sterile gauze, provide a temporary splint, and supervise the transportation. Once under shelter, proceed to carry out a methodical cleansing and examination. Cleanse the field first and then the wound itself.

If the wound was received at long range and probably only a few shots have penetrated the joint cavity, the careful cleansing, antiseptic dressing, and subsequent immobilization will be all that is required to bring about an uninterrupted recovery without loss of function.

If the wound was received at close range and the joint is freely penetrated by the shot, which have carried in shreds of clothing and other foreign particles, the treatment is quite different.

Suppose the joint is swollen, dark blood oozes out, and the cavity is exposed through lacerated wounds: in such a case conservatism will not cure. Prepare to operate immediately. Open the joint and with hot normal salt solution freely flush out the shot, fragments of bone and cartilage, blood clots and other débris. Do not be sparing of time and patience. Trim away the lacerated tissues. If satisfied with the cleansing, suture the deeper layers over the joint so as to close it completely, and drain only the superficial wound; otherwise, drain the joint cavity as well. Apply an antiseptic dressing and immobilize, and expect a good result.

The situation is again different if the case has been treated first by the uninstructed. The wound is seen some time after injury and found covered with dirty cloths, or a handkerchief, the worse for usage, is stuffed into the wound. No covering at all is always better than anything less clean than a sterile dressing.

The treatment is the same as before—in every way as rigorous and systematic—but there are not the same certainties by any means that it will head off sepsis. You cleanse, drain, immobilize, and watch. You watch for beginning infection, which for that matter may develop in the simpler cases if the cleansing is not complete. Fever, pain, swelling of the joint, all rapidly increasing,

are the signs of beginning infection and suppuration and call for immediate action. It is indicated to open the joint and drain. (See page 440, Arthrotomy.)

Bullet wounds produce similar lesions, although usually they are of the milder type. Hemarthrosis indicates injury to bone as well as soft parts. Sometimes these wounds occur with scarcely any injury to the joint structure, the bullet lodging in the epiphysis. In the milder cases, wherever the bullet may be, it is better merely to cleanse and immobilize, and at a later date, if necessary, the ball may be removed. If, however, the hemarthrosis is voluminous, it is better to open the joint at once and clean out the cavity and, by a happy chance, the bullet may be found and extracted. (See also *gunshot wounds of joints in military practice*, and *compound dislocations*.)

GUNSHOT WOUND OF HAND

A pawnbroker, examining a revolver brought in for a loan and which was supposed not to be loaded, was shot through the hand. The 32 bullet passed between the heads of the third and fourth metacarpals, splintering the fourth in some degree. The tissues were powder-stained along the track of the bullet and the wound bled very freely.

The wound of entrance in the palm was jagged; the wound of exit smooth. The wounds were cleansed and a slender forceps passed through the hand, a piece of gauze attached and pulled into place for through-and-through drainage by withdrawing the forceps. The bleeding stopped, but later began again, soaking the bandages. Syringing the wound with peroxide and packing with gauze served to check the bleeding for a few hours. This intermittent hemorrhage persisted for two days.

The hand was soaked twice daily for a half-hour in hot normal salt solution; the swelling and pain rapidly subsided and after three or four days the wound began to heal without the least evidence of infection. The ring finger was stiff and painful for some time, but under massage and passive motion gradually regained its use.

Injury to the tendons constitutes one of the chief complications of gunshot wounds of the hand. Free trimming away of the

shattered tissues, free drainage and free use of hot normal salt solution seem best calculated to promote repair in this class of wounds.

SUPERFICIAL WOUNDS FROM FOWLING-PIECE

A farm hand, charged with trespass, was brought to the county jail sorely wounded. Two charges of bird-shot had caught him on the fly and peppered his back, buttocks, and the posterior surfaces of thigh and calves. Evading his pursuers, aided by the darkness, he had reached his cabin exhausted and, without changing his bloody clothes, lay thus unattended for two days, when he was discovered and arrested. By this time infection had set in. His buttocks and calves, particularly, where the shot were thickest, were swollen and inflamed. Many of the shot had carried shreds of clothing into the tissue: each was a focus of suppuration; none had penetrated beyond the skin. The whole injured area was cleansed, first with soap and water, and then rubbed vigorously with peroxide of hydrogen; the more superficial of the shot were picked out, and finally the inflamed surfaces were smeared with Reclus' ointment and covered with sheets of gauze held in place by adhesive strips. The relief from pain was great. In three or four daily séances the shot were all picked out and the inflammation practically gone.

WOUNDS FROM TOY PISTOLS AND BLANK CARTRIDGES

Two things are noteworthy in connection with these wounds: first, the surprising power of penetration of cartridges supposed to be harmless; and, second, the great danger of a tetanus infection. The "wad" may be buried out of sight in the tissues, it may entirely perforate the hand, or it may produce a superficial laceration. As a rule, the hemorrhage is insignificant, which may in a measure account for the development of infection, since bleeding is nature's means of disinfection.

These wounds often present the appearance of punctured wounds, which, more than others, are likely to furnish conditions favorable to the growth of the tetanus bacillus.

It may be that the disposition of the wad is such that the wound is in a manner stopped up, so that oxygen cannot reach the recesses

where the bacillus finds its lodgment. It is true that tetanus develops in only a small percentage of cases, but one can never foretell positively what such a wound may do.

It is the duty of every doctor to warn his clientele of the danger of these "Fourth of July" injuries.

Every case is to be treated as if lock-jaw is not merely a remote possibility, but a probability. Free cleansing and douching with peroxide of hydrogen is indicated.

Luckett says (American Journal of Surgery, July, 1906): "These wounds should be freely incised, particularly if not seen on the first day of the injury, and thoroughly curetted with a small sharp spoon until all the small pieces of wad, the unburned grains of powder, and all the dirt have been removed. If the wad has entered a metacarpal space a counter-incision must be made for through-and-through drainage. Having cleaned the wound as thoroughly as can be done mechanically, we now resort to chemicals and irrigate with some mild antiseptic. After next drying the wound thoroughly, the entire cavity should be swabbed out with one of the following, named in order of choice:

"1. Pure carbolic acid followed by alcohol.

"2. Twenty per cent. tincture of iodine (made by dissolving iodine crystals, 20 parts, in ether and alcohol, each 50 parts).

"3. Plain tincture iodine.

"The wound should now be packed with moist iodoform gauze. A wet dressing is then applied, to be *changed daily*. Permission should be obtained for a prophylactic injection of antitetanic serum. Ten c.c. are intra-muscularly injected in the buttocks or thigh, under thorough antiseptic precautions."

Antitetanic powder may be applied to the wound, as advised by Calmette. Experiments conducted by Joseph McFarland, of Philadelphia, corroborate Calmette's statements as to the prophylactic value of this substance. By its use McFarland was able to protect from infection animals which he had inoculated with the tetanus bacillus.

CHAPTER XIV

FRACTURES OF THE EXTREMITIES

Definitions.—A *fracture* is a solution of the continuity of bone due to traumatism.

A *simple fracture* has a single line of solution and there is no lesion of the soft parts.

A *multiple fracture* has more than one line of solution of continuity in the same bone or several bones.

A *comminuted fracture* has so many lines of solution running into each other that the bone is in fragments or splinters.

A *complete fracture* involves the whole thickness of the bone. It may be transverse, longitudinal, oblique, dentate or comminuted.

In an *incomplete fracture*, the line of solution does not involve the whole thickness or extent of the bone. It may be a fissure, "a green stick," a depression or a separation of an apophysis.

A *subcutaneous fracture* has no communication with the surface.

An *open* or *compound fracture* has a communication with the surface, has an accompanying solution of continuity of the skin and the subjacent soft parts.

A *spontaneous fracture* is produced by an insignificant traumatism and is usually *pathological*, due to disease of the bone.

An *ununited fracture* is one in which bony union has not occurred at the usual time.

Gunshot fractures are those produced by projectiles (see Gunshot Wounds).

Fractures of the extremities are emergencies, often of the first-class; their reduction sometimes becomes equivalent to a major operation. But it cannot be said that these cases are always treated well. As Senn says, "Bad results following fractures have been the tombstones that have marked the termination of an otherwise successful professional career of many an ill-fated, unlucky, disappointed practitioner."

Malpractice suits more frequently follow this class of cases, perhaps, than any other, which is an indication that somewhere there is a fault. Doubtless it is the fear of a damage suit that often makes a basis for it and in this way: The doctor, in order that he may have testimony as to his skill, treats the case in the stereotyped, and routine way; he gets a bad result. Had he used his better judgment, given his common sense rein and risked the reproach of being an innovator, the result would have been different.

Every case must be studied and treated on its own merits, with due regard, of course, to certain general principles. To begin with, the *prognosis* should always be guarded in some degree. As King says (St. Paul Medical Journal, August, 1906): "Optimism as to the final outcome on the part of the physician is a mistake. Take the patient into your confidence, let him anticipate the certainty of some permanent defect, so that in the end an imperfect result will not reflect so much upon your skill and will tend to minimize malpractice suits. And how very rarely indeed can the result be perfect. With the very best treatment, there will nearly always remain as the best outcome some slight weakness, or limitation of motion, or ache, or pain—at least a callus as a 'lasting memorial.'"

The diagnosis of these fractures is usually easy in the large sense, as King says, but after all difficult as a whole, for no eye can see the injury wrought to the softer tissues. In many cases the position will indicate at once that there is a fracture, but one must endeavor to learn much more—the possible associated injuries to joints, muscles, blood vessels, and nerves. To be able to do this necessitates a fairly accurate knowledge of anatomy to begin with, aided by systematic examinations, and on this foundation skill grows with experience.

The *diagnosis* of fracture in the bones of the extremities is based on several factors: (a) history of the case, (b) deformity, (c) abnormal mobility, (d) pain and loss of function, (e) crepitus, (f) X-ray examination.

(a) It is essential to know how the accident occurred. Frequently in the absence of definite symptoms, the diagnosis must rest upon the history. For example, in a case of a hip-joint injury in an elderly person presenting loss of function and some pain but no other symp-

toms, a diagnosis of impacted fracture should be made if it is learned the patient fell striking the hip.

(b) Deformity includes changes in the relations or dimensions of the bones and the appearance of the limb. The two limbs must always be compared. It must be determined that there has been no previous injury to cause the deformity. When both ends of a bone are accessible to touch, it may be readily measured and compared with its opposite. In the case of the humerus, it is necessary to measure from the acromion; in the case of the femur, from the ilium. The position which the fragments assume may be due to the direction of the force or the action of the muscles.

(c) Preternatural mobility implies movement in unnatural situations or in unnatural degree or direction. As one of the cardinal signs of fracture, it has hitherto been assigned too much importance. Its presence indicates fracture, but its absence indicates nothing. We all know that in impacted fracture, there is no abnormal mobility. In fractures of the bones of the tarsus and carpus, in epiphyseal fracture, in any fracture where the fragments are small or deeply placed, it may be impossible to discover movement without a manipulation which may be distinctly injurious. In the case of fractures near joints, it may be impossible to determine whether the movement is in the joint or near it.

The fact is that in most cases where abnormal mobility is present, the fracture may be readily diagnosed without reference to this sign.

(d) Crepitus is the almost constant accompaniment of abnormal mobility and is the grating produced by the friction of the two fragments. It is pathognomonic, but must not be sought for too vigorously. It is absent in impacted fracture, and to break up an impacted fracture, testing for crepitus, may be a calamity. Crepitus may sometimes be heard with the phonendoscope and not with the ear.

(e) Pain and loss of function go together since the pain is usually the cause of the loss of function. Both are present in nearly all fractures, but often occur in as great degree with contusions.

The amount of pain varies with the location, but is nearly always aggravated by movements or pressure. Taken in connection with

the history of the case, it is a valuable diagnostic aid. The presence of pain may call for anesthesia before the diagnosis can be completed.

Stimson has recently emphasized the significance of pain in the diagnosis of fracture, and indicated the manner in which it may be interpreted. Crepitus and abnormal mobility are, to his mind, of less importance than pain as a diagnostic aid.

The search for pain in all doubtful cases should be systematic. Begin first with local pressure over the suspected area with the tip of the finger or with the rubber end of a lead-pencil. There are definite lines of tenderness to be discovered in many of the fractures about joints. For example; in Colles' fracture this line can be plainly traced across the radius just above the wrist; in fracture of the external condyle of the humerus, along the external condylar ridge just above the elbow; and in fracture of the surgical neck of the humerus along the front or outer side of the bone.

Next test the character of pain elicited by cautious movement of the limb. Increased muscular tension thus produced awakens increased pain at the site of the fracture, and the patient may be able to indicate the exact location of the lesion. The effort on the part of the patient to produce certain movements is helpful.

Finally, indirect pressure may be employed: thus, in transverse fracture of the tibia, pressure upward on the foot exaggerates the pain markedly; and in the same manner, pressure upward at the elbow, may assist in locating the fracture in the shaft of the humerus. Stimson notes the important exception, that in the case of fracture of the neck of the femur forcible pressure upward often fails to cause pain.

In the case of fracture of one of the bones of the forearm or leg, squeezing the two bones together will generally help the patient to locate his trouble.

(f) The X-ray cannot be ordinarily available in general practice, although of the greatest assistance in cases of doubt. Without its use many fractures in the region of joints will be diagnosed as something else. Bloodgood particularly emphasizes its value (*Progressive Medicine*, Dec., 1906), believing that the doctor who neglects the aid of the Röntgen picture, when he is able to obtain it, will have much to regret. There is no danger that its employment

will blunt the diagnostic sense, unless, as is often done in hospitals, it is used to the exclusion of other aids. The X-ray has at least modified our notions as to what constitutes a perfect result in the treatment of a fracture. Wherever the X-ray picture is used to back up a claim of malpractice by reason of inaccurate apposition of fractured bone, we must insist that restoration of form and function constitutes a perfect result surgically, whatever discrepancies the Röntgen picture may reveal.

THE TREATMENT implies a reposition and an immobilization that the bones may unite in their normal relations. It has that objective, but has also another which is not necessarily a concomitant of the first. The bones must unite without deformity but there also must be *restoration* of the limb's *functions*. Union in good position, then, is only one of the means to a larger end. It is better to say that the treatment includes reduction, immobilization, and mobilization.

In making reduction, violence must be avoided. Gentle but persistent effort is always better than rude haste in overcoming the resistance of muscles and ligaments, which is usually the chief obstacle to reposition. The line of traction must be adapted to the muscular action. Traction must usually be accompanied by counter-traction and local manipulation of the broken ends.

In making traction it should be made directly, if possible, on the bone involved, without the intervention of a joint. For example, in reducing the humerus the traction should be applied above the elbow joint. Often an anesthesia is necessary to relax the muscles, and if anesthesia was necessary to complete the diagnosis, everything should have been prepared previously for the treatment so that only a single anesthesia is necessary for diagnosis, reduction, and dressing.

In the cases of suspected fracture in the vicinity of a joint, it is not always best to hurry the reduction; often it is better to wait a day or so and try to reduce the swelling, for the swelling aggravates the difficulties which are always great in the differential diagnosis about the joint; and, if flexion is required, as in the case of certain fractures above the elbow, the pressure may shut off the circulation.

So far as the shaft of the long bones are concerned, however, the formula should be *immediate reduction* and *fixation*. That the reduction has been complete is attested by the appearances of the limb, by the absence of any irregularities to the touch, and by the coincidence of its measurements with those of the sound limb. These comparative measurements should be a matter of routine practice.

Warbasse says (J. A. M. A., March 13, 1909), "the sooner a fracture is reduced and held immovable, the less will be the swelling and the more satisfactory the result. There is a prevalent notion of waiting until the 'traumatic reaction has subsided.' This ancient phrase rolls off the tongue sonorously and sounds important, but is to be reverently laid aside. Traumatic reaction is going on all the time as long as the bones are out of place or so long as they are movable. If we can effect immobilization soon enough, the swelling will not come up." This is doubtless true in most cases, yet it is to be remembered that in spite of reduction of the bones, lacerated muscles and ruptured vessels may continue for some time, in some cases, to pour their exudate into the tissues to augment the swelling. This idea, however, pertains more to the mode of dressing and does not refute the doctrine of immediate reduction.

Immobilization is a phase of treatment raising many questions in dispute. In what manner shall it be applied and for how long? Or, as Championniere insists, may it not in many cases be dispensed with entirely? For he believes that absolute fixation of the fragments is not the condition most favorable to the processes of repair. A certain amount of movement is necessary to the vitality of the bone, and therefore movements and massage represent the chief elements of his treatment. That it is the best treatment for fractures about joints no one will deny, even though unwilling to dispense with fixation in other fractures of the long bones.

As to the manner in which fixation is to be attained, let it be said briefly that the simplest effective dressing is the best. Its elaborateness will depend upon the tendency for the displacement to recur, and this tendency must be measured by the degree of obliquity of the fracture and the action of the muscles. Sometimes the tendency to recurrence is an indication of imperfect coaptation. In

one case, then, only a light retaining splint is necessary and in another it must indeed be firm and strong.

At the present time there can be no question but that plaster of Paris is the dressing of choice. At any rate, it will render the best service to the general practitioner who must rely on his own resources in fashioning splints. Ready-made splints are an abomination. There are other plastic materials that are often useful, and in lieu of all these materials the splint may be cut into forms to suit the case from boards, etc., and applied well padded. (See page 48.)

Walsham formulates the principles which must regulate the use of splints in any case.

1. The splints must be well padded.
2. Pressure must not be made over the points of bones.
3. Strapping or bandages must not be put on too tightly.
4. Circular constriction of the limb must be avoided.
5. The splints, if possible, should reach beyond the joint above and below the fracture.
6. The patient should be seen within twenty-four hours after the splint is applied for the bandage may become too tight.
7. The splints should not be needlessly disturbed—that is to say, if the patient is comfortable and the limb in good condition.
8. Spasm of the muscles is to be overcome by steady extension.
9. The part below the fracture should be bandaged, or at least raised, to prevent swelling and edema.

The first immobilization will continue till there is no tendency to spontaneous recurrence of the displacement, which will vary in different cases. After this time a dressing must be used which is easily changed, and daily massage must be instituted. Complete and continuous fixation through a long period is distinctly bad practice and most especially whenever a joint is involved.

Rossi has shown (*Wiener Medical Presse*, Jan., 1902) that the amount of new cartilage formation is proportional to the amount of movement permitted and is found in the greatest amount in fractures treated by massage, and is explained by the greater formation of new blood vessels and the consequent more active circulation and absorption of effusion.

You will ordinarily, therefore, proceed in something after this manner: you will carry out a systematic *inspection* before handling the part, you will observe any deviation of the hand or foot from the normal axis of the member and compare the injured with the uninjured side. In a large number of cases this inspection will be sufficient to diagnose the case.

Measurements are of great value in many cases and must not be overlooked as a diagnostic aid. In the absence of deformity or shortening you may proceed next to *palpate* the affected region in order to determine the degree of displacement and other characters of the fracture.

Manipulation may occasionally be required to elicit crepitus and preternatural mobility but certainly should not be considered a routine procedure. In any event handle the injured limb gently, never forgetting that the least haste or carelessness may greatly aggravate the displacement and the traumatism to the soft tissues or change a simple into a compound fracture, not to speak of increased shock or suffering to the patient.

Finally, having determined as nearly as possible the conditions present, you will assemble the dressings suitable to the case. Once these are all prepared, administer the anesthetic. A full relaxation is essential for an easy reduction but as the anesthesia proceeds the injured limb must be watched by an assistant lest in the stage of excitement the patient do himself an added hurt. The anesthesia also favors a more detailed diagnosis and a better determination of the minutiae of treatment. In a few days the part should be skiagraphed and if the position of the fragments is good, the limb well immobilized you may consider that a good union is in sight.

Finally the question of *operative treatment* is to be considered. Whatever advantage plating may possess it cannot be the method of choice with the general practitioner. The open treatment, therefore, will be reserved strictly for those cases in which either reduction or fixation cannot be otherwise accomplished.

First aid to those disabled with fractured limbs is in civil practice more frequently given by others than the doctor. It is desirable, however, whenever possible, that he should direct the transportation and the preliminary treatment.

The utmost care must be practised in lifting and handling the broken limb, lest the injuries be augmented and a simple fracture converted into a compound.

If fracture is merely suspected, it must be assumed to be present. The limb must never be lifted by the foot or hand but must be lifted as a whole, resting upon the palms of the hand. Two attendants are always better than one in handling a broken leg. If the deformity is quite obvious even to the unpractised, an effort should be made toward reduction before applying temporary splints, this with a view to preventing further injury to the soft parts.

The limb is seized by an attendant at each end and gentle and steady traction made in the direction of its axis. If this does not succeed, the attendants must not persist in the effort. It must be left for the surgeon.

If the fracture is compound, with severe hemorrhage, the clothing must be removed. Otherwise this is not necessary. In removing the trousers or a coat, for example, the sound limb is uncovered first and then, very gently, the injured one. It is better to cut the clothing or rip along a seam.

A *splint* is next improvised from whatever may be first at hand, a thin board, laths, an umbrella, or the branch of a tree. The splint is padded, or the limb wrapped with whatever presents itself, a blanket or anything to prevent undue pressure, and then is fastened on the limb by a cord, or belt, or suspenders, etc., and finally the injured leg is bound to the sound leg, the injured arm to the side of the chest or carried in a sling.

The limb thus temporarily immobilized, the patient is ready to be moved.

To lift the patient with the greatest safety in the case of a broken leg, for example, one attendant standing on the sound side, places his arms under the body of the patient, who in the meantime locks his arms about the attendant's neck. A second attendant, standing on the same side, places one hand under the body, one under the sound limb, while a third attendant, facing the others, supports the broken limb. At his word of command, all lift. This carefulness must not be relaxed.

If a litter is available, or one can be improvised, it is placed parallel

with the patient, its feet at his head, so that without any inconvenience the patient may be laid upon it.

FRACTURES OF THE HUMERUS

Certain points of anatomy apply to nearly all fractures of the arm, and are useful in diagnosis and reduction. Recall the relations of the humeral head to the acromial and coracoid processes; the location of the greater tuberosity, the internal and external condyles; the attachments of several muscles, particularly the deltoid, biceps, and triceps; the relations of the musculo-spiral nerve. Remember that in the normal relations a line dropped from the tip of the acromion to the external condyle will touch the greater tuberosity.

Nor must one forget the location of the great vessels on the inner side of the arm, the proximity of the brachial plexus in the axillary space and the intimate relations of the ulnar nerve to the internal condyle.

All these matters must be present in the imagination as the injured arm is inspected.

The musculo-spiral groove is a line of least resistance and determines many of the spiral fractures of the shaft.

The age of the patient is of great importance in determining the nature of the fracture at the extremities. The difficulties of reduction and fixation determine largely by muscular action and accordingly the musculature must be kept well in mind.

The symptoms, the deformities, the complications, the treatment all vary, depending on the part of the humerus involved; therefore the shaft and the two extremities must be studied separately.

FRACTURE OF THE SHAFT OF THE HUMERUS

Direct or indirect violence, a fall on the elbow or wrist, a twist, or muscular contraction may produce fracture of the humeral shaft which for the present purpose is considered as extending from the attachments of the deltoid to the upper level of the condyles (Fig. 139).

The line of fracture may be transverse, oblique, or spiral, depending on the nature of the violence. Thus a blow will more likely

produce a transverse; a fall on the elbow, an oblique; a twist of the arm, a spiral fracture of the shaft.

On inspection the broken arm is usually found to be considerably

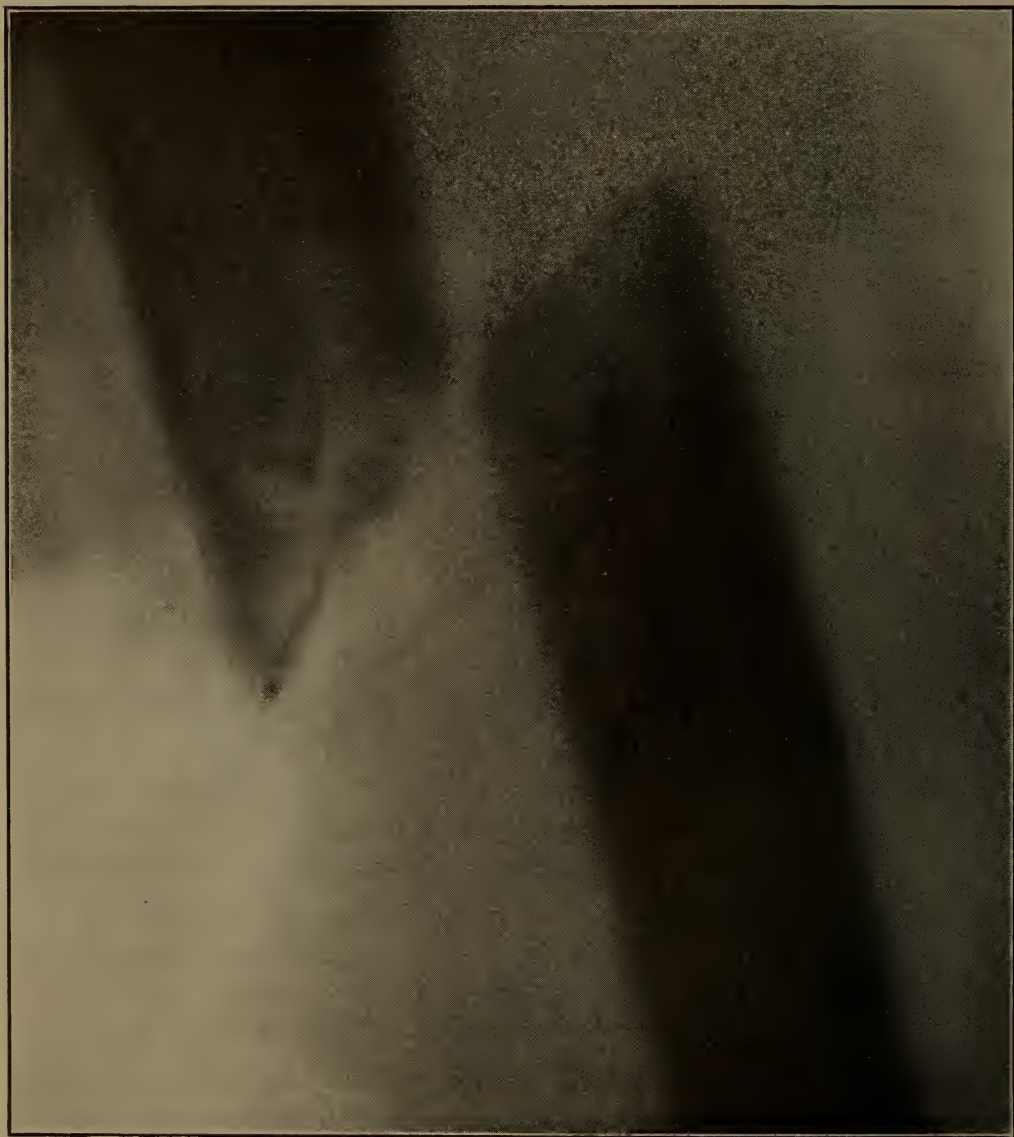

FIG. 139.—Fracture of the shaft of the humerus.

swollen; the deformity marked, only when the patient lies down; pain, preternatural mobility and crepitation are easily elicited. There is usually shortening as compared with the sound side, meas-

uring from the tip of the acromion to the external condyle and, normally, this line lies over the greater tuberosity (Fig. 140).

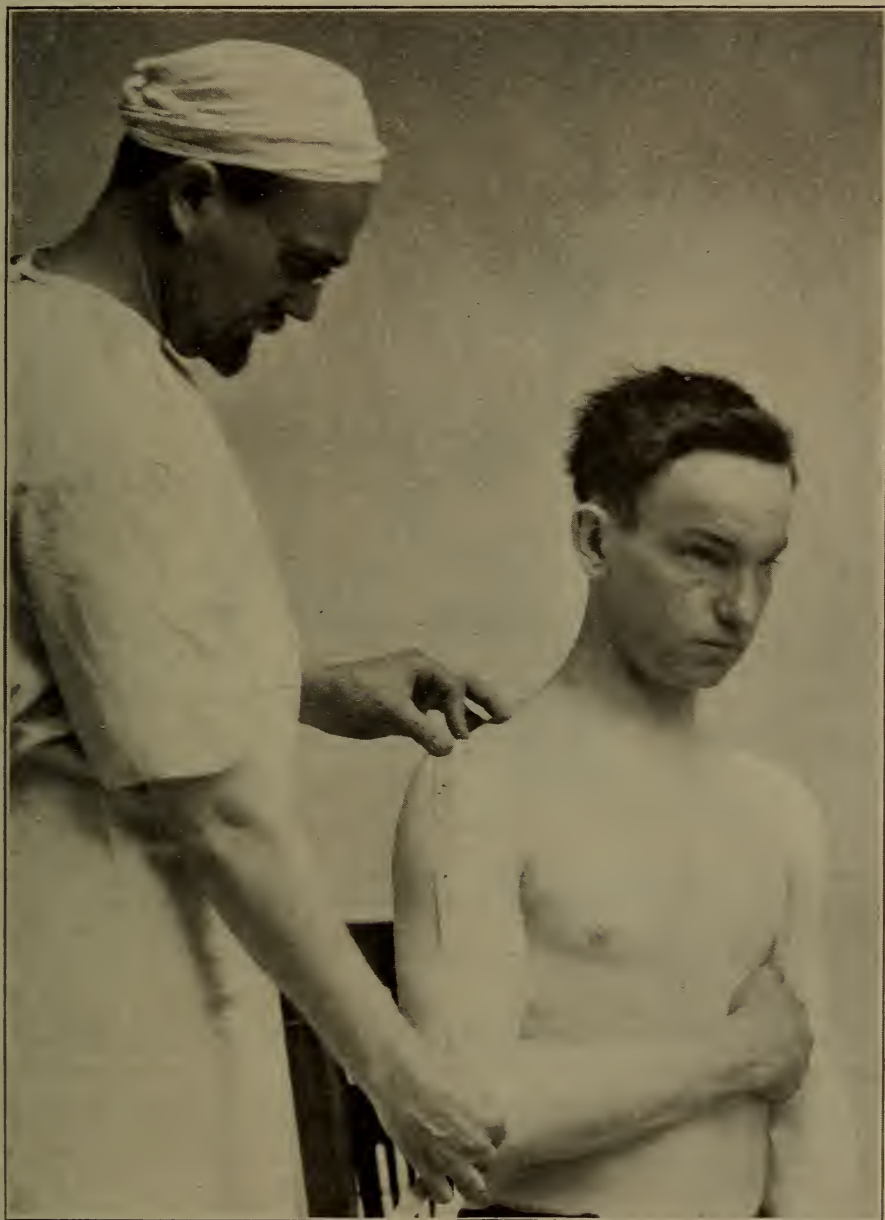

FIG. 140.—Testing the humerus for shortening. Measuring from the acromion to the external condyle.

The *treatment* will depend on the degree of displacement. If displacement is absent apply well-padded splints, one internal ex-




FIG. 141.

The patient is seated; bandage the injured member from the wrist to about 3 inches above the elbow; protect the axilla with absorbent cotton; flex the forearm at a right angle and maintain in that position in a sling. Pass a band under the axilla and fasten it to something (a hook in the wall), so that the shoulder is slightly lifted. That is the counter-extension.

Another band crosses the forearm just below the bend of the elbow and to it is attached a weight, say of 2 K. G., that is the extension. Give the apparatus a little time and it will effect a reduction as the muscles tire. Employ this interval to prepare the fixation dressing.

Cut out sixteen strips of crinoline, each about 1 yard long, and wide enough to cover the arm at its thickest part. Lay these strips one upon the other, and fasten them together; and from the sheet thus formed, cut a deep scallop out of either end—at the lower end 45 to 50 cm. and at the upper end 15 to 20 cm. deep. Of the yokes thus formed, one will fit into the axilla and the other into the bend of the elbow, while the intermediate portion forms an internal splint for the arm.

Soak the cloth in liquid plaster and apply it in the manner indicated, molding it carefully to the arm. The two upper bands overlap the shoulder and the two lower ones are wound spirally around the arm to the wrist. In this way the shoulder and wrist are immobilized. In the meantime the extension and counter-extension are not disturbed until the plaster split is fully hardened. The dressing may be further secured by a few turns about the chest.

tending from the axilla to the bend of the flexed elbow the other external from the acromion, below the elbow. These splints are held in place by adhesive strips and the whole firmly bandaged.

If, on the other hand, the displacement is conspicuous, it may be difficult to reduce, difficult to hold. A number of procedures are available; the patient may be anesthetized, the fracture reduced by strong traction, the patient's shoulder then brought well over the edge of the table, the extremity bandaged with glazed cotton and a plaster roller applied, including the wrist and shoulder. The patient must stay in bed. Instead of the plaster roller, plaster splints may be applied on the same principle as the wooden splints described above.

Hennequin's dressing is strongly recommended by Lejars. Its purpose is to reduce the fracture without anesthesia and to maintain the reduction until an internal splint is applied (Fig. 141).

Union requires from six to eight weeks; failure to unite is usually due to the interposition of the soft parts. The importance of the musculo-spiral nerve in this connection must never be forgotten. Paralysis of this nerve occurs in about 8 per cent. of such fractures; it may be immediate or remote, depending on whether the nerve is itself injured by the traumatism or whether it is caught in the scar tissue. The recognition of this injury is imperative. Inclusion of the soft parts which cannot be remedied calls for an open operation.

FRACTURE OF THE UPPER END OF THE HUMERUS

These injuries often offer the very greatest difficulties in diagnosis. Such cases for the most part present themselves with swollen, painful, and contused shoulders, perhaps deformed, and functionless. You ask yourself: is it only a severely bruised joint; is it a dislocation or a fracture of the surgical neck, or perhaps both; or is it an impacted fracture of the anatomical neck; are the soft parts implicated?

Do not waste time in vague palpations but proceed at once to a systematic examination, under anesthesia, if necessary. Begin by locating the apex of the acromion; if there is no depression beneath it; if the thumb cannot be pushed into a concavity but comes in contact as it should with the humeral head, you may conclude there is no dislocation. With the thumb still in front, close the fingers on

the posterior aspect of the head of the humerus, and with it thus held firmly, attempt rotation of the arm. The humeral head rotates with

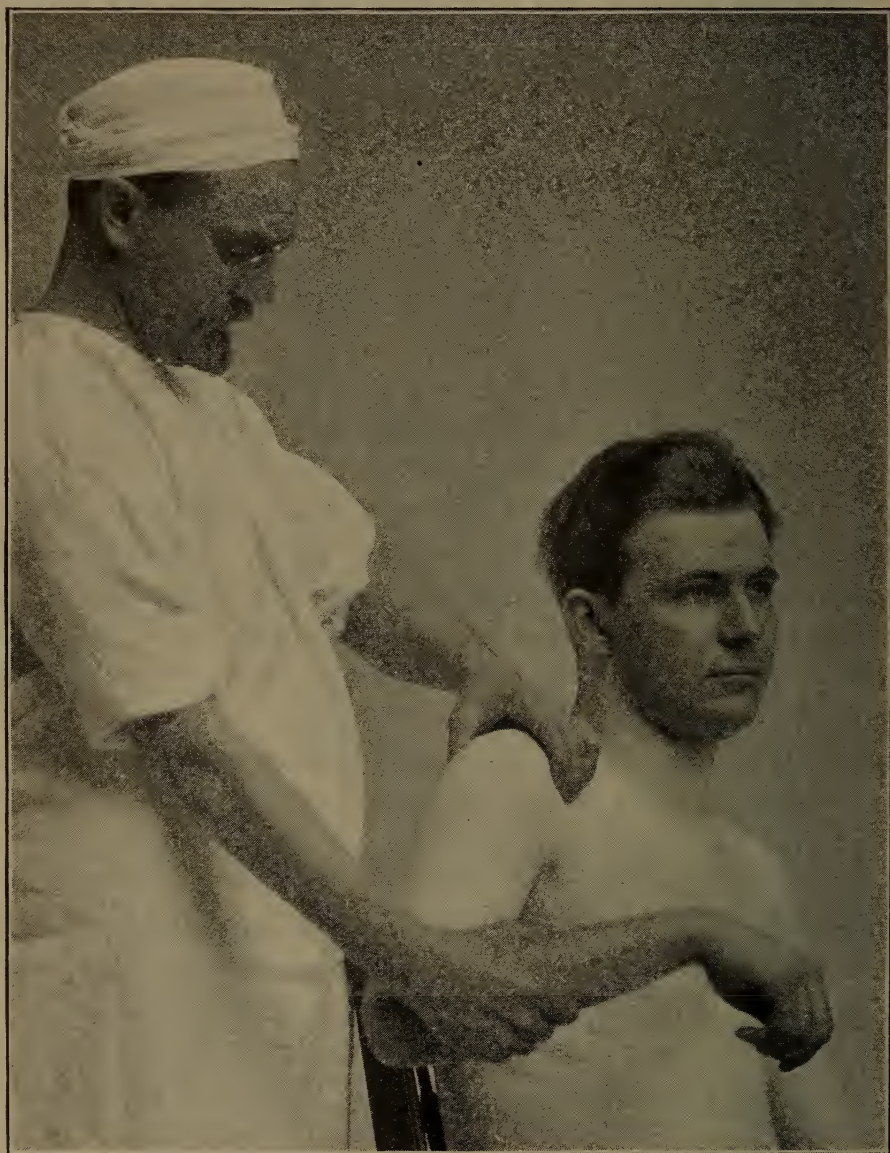


FIG. 142.—Examining the shoulder. Rotating head of humerus.

The head of the humerus is grasped between fingers and thumb of one hand; the other moves the patient's forearm through an arc.

In the case of dislocation the rotation is produced with difficulty, if at all.

In case of fracture of the anatomical neck the joint is much thickened but there may be slight rotation of the head. Fracture of the surgical neck: the arm is freely moved, but the head does not rotate.

difficulty in dislocation; it does not rotate at all if there is fracture, and besides, there is crepitation (Figs. 142, 143).

A source of error: If the lower fragment overrides much, its rotation might be felt and mistaken for the humeral head. Abduct the arm; easily done in fracture, with increase of deformity and pain. Pain is also produced by pressure upward at elbow and by local pressure over the front and outer side of humerus.

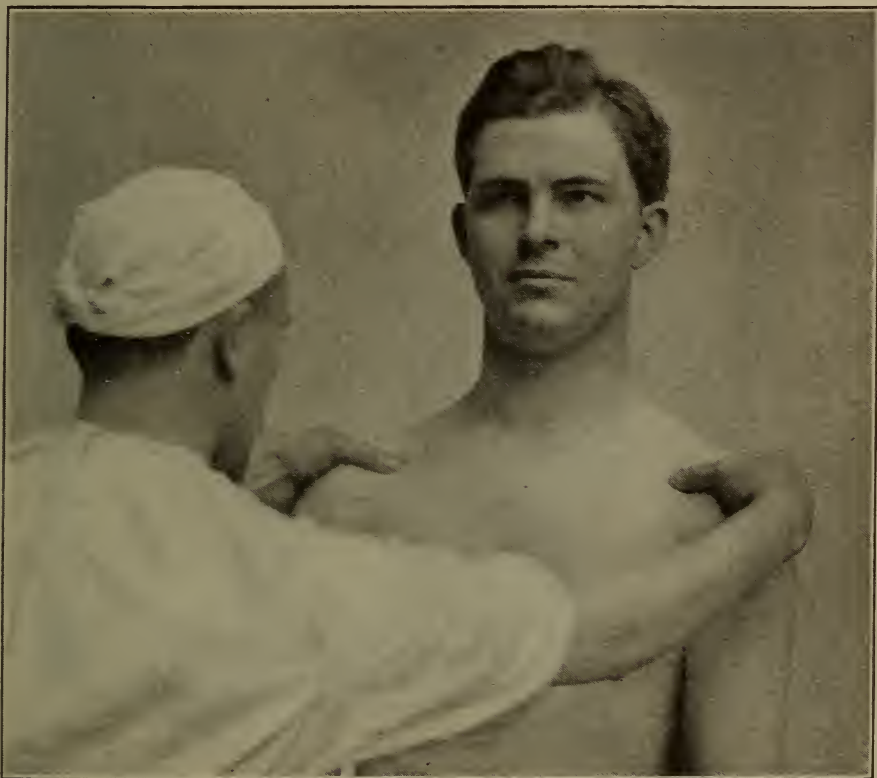

FIG. 143.—Examining the shoulder. Comparing the relations of the coracoid processes.

Examine the axillary space and all the other aspects of the shoulder, comparing the two sides; and compare the other landmarks of the arm. *Do not begin any treatment until the diagnosis is assured.* How unfortunate it is to attempt reduction of a supposed dislocation by the ordinary method when it is complicated by fracture; or to treat as a contusion, a fracture with displacement!

To consider briefly the more common findings of such examinations:

1. *Fracture of the surgical neck without overriding* (Fig. 144) needs only the simplest treatment: Brace the arm on the inside with a "V" shaped axillary pad, and with the forearm flexed at a right angle; support the whole extremity in a sling of the Mayor type. Additional protection may be afforded by a shoulder cap (Fig. 145). Begin massage early.



FIG. 144.—Fracture of surgical neck of humerus. (Moullin.)

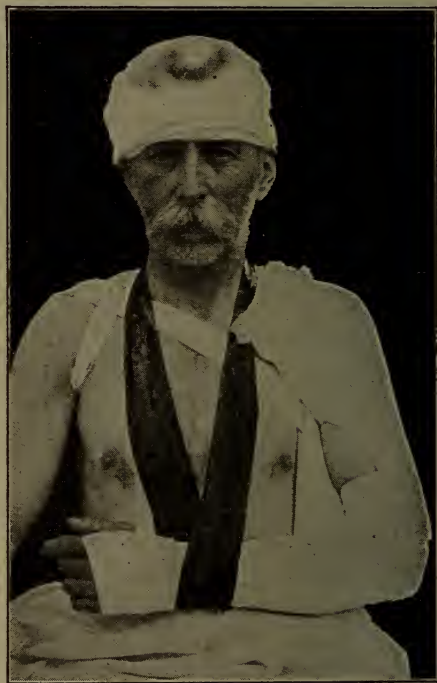


FIG. 145.—Fracture of surgical neck. Axillary pad; shoulder cap; forearm supported in sling. (Scudder.)

2. *Oblique Fracture of the Surgical Neck with Much Overriding.*—These are difficult to reduce; difficult to maintain; likely to be mistaken for dislocation (Fig. 146).

Reduction.—In making traction, draw downward and outward at first and then in the axis of the limb. Do not stop until the arm is the correct length by measurement; until the subcoracoid projection has disappeared; until the acromion, greater tuberosity and the external condyle are in the same straight line. Extension must be

maintained while the dressing is applied or the displacement will certainly recur.

The arm must be fixed in *abduction* and with the *elbow slightly forward*; only in this position will the lower fragment coapt with the upper which, of course, the fixation apparatus will not affect. Either the patient must be put to bed and *extension* with weight and pulley applied or else the rather complicated splints of the type used

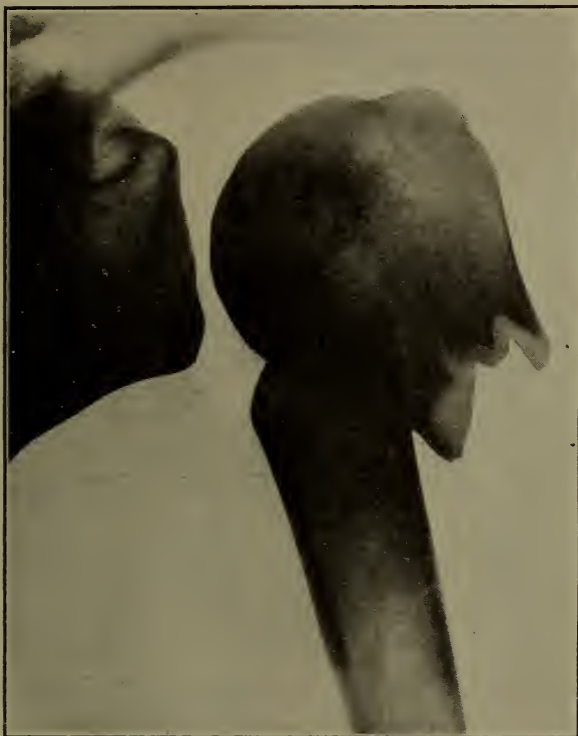

FIG. 146.—Fracture of surgical neck with overriding.

by Heitz-Boyer or Dupuy must be employed to maintain these positions. In either case the fixation must not be prolonged, and massage and passive movement begun early. If the circumstances permit, the open operation gives by far the most satisfactory result.

FRACTURE OF THE SURGICAL NECK WITH DISLOCATION

This is a very serious injury; difficult of diagnosis; of bad prognosis. Carrying out the systematic examination described, you find the head displaced, but the arm is not fixed in abduction as in the

ordinary dislocation; it drops to the side. Again, the head does not rotate with the arm; there may be crepitation; from these and other confirmatory points the diagnosis is made.

Reduction.—Anesthesia is necessary. Make a slow, gentle, but



FIG. 147.—Fracture with dislocation before reduction.

persistent traction on the arm; this combined with manipulation of the head of the humerus in the axillary space may succeed in restoring the head to the glenoid fossa, for more than likely the head is still attached to the shaft by periosteum and muscular fibers. As the assistant makes the traction apply your thumbs to the

head in axilla and, with the fingers braced by the shoulder, try to force the head into place (Figs. 147, 148).

Once the dislocated head is reduced, reduce and treat the fracture

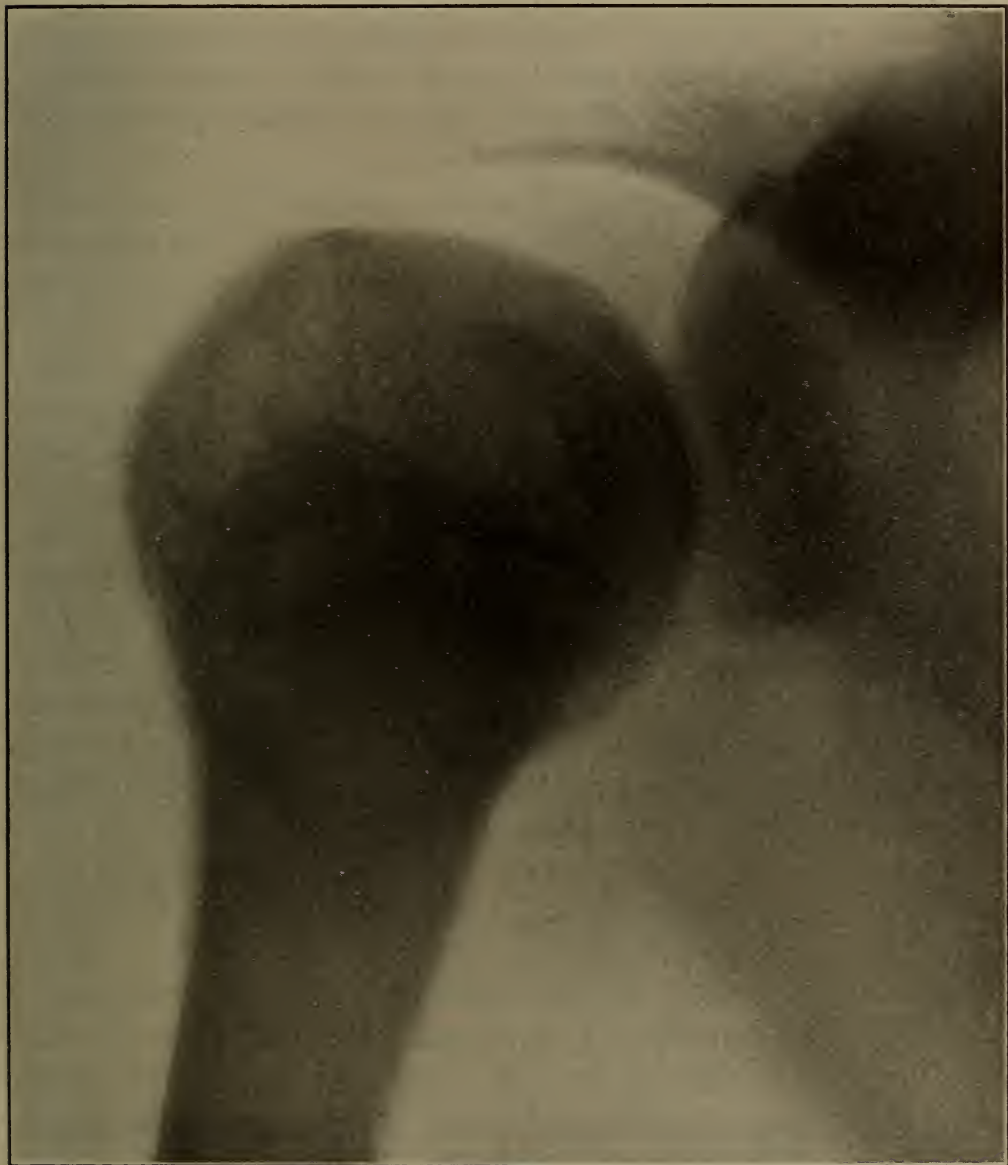

FIG. 148.—Same fracture of surgical neck with dislocation after reduction.

by the ordinary means. Massage must be begun especially early. If these efforts fail, choice lies between operation and expectant treatment.

The expectant treatment may give a surprisingly good result in case the dislocated part includes only the head. With early massage and passive motion a new joint is created, the upper end of the shaft adapting itself to the glenoid cavity.

In case the dislocated fragment includes the surgical neck a persistently stiff shoulder may be expected and not only that but a large callus may seriously interfere with the brachial plexus, or even the axillary vessels.

Royster, of Raleigh, N. C. (Journal A. M. A., Aug. 10, 1907), reviews his own experience and the literature dealing with this condition, and concludes very logically that *operative treatment* in the great majority of cases is alone effective.

The preferable incision begins at the acromion process, extends vertically downward as far as necessary, and aims to reach the bone by passing between the pectoralis major and the deltoid. The head, thus exposed, is to be reduced by manipulation, although occasionally a special hook or bone forceps may be necessary. Wiring will seldom be required except in the cases operated late. The dressing should be applied so as to maintain the arm in abduction. Royster believes in immediate operation, regarding such cases as emergencies, as much so as strangulated hernia or appendicitis. "Even in cases of doubt, it is preferable to expose the parts to view rather than to wait in the hope that nature and time will clear it up." Our own experiences seem amply to confirm this view.

FRACTURE OF THE ANATOMICAL NECK

This fracture nearly always results from falls upon the point of the shoulder and in consequence is impacted. A fall upon the elbow may produce an impacted fracture of the upper end of the surgical neck but only the X-ray could make the distinction. Great swelling and ecchymosis are prominent characters and loss of function is complete. Palpation and manipulation reveal nothing but the degree of pain.

The X-ray picture usually shows the head turned either forward or backward and an irregular dentated line of fracture. The treatment from the first is massage and passive motion.

The massage of the first two days should be chiefly friction; later kneading will hasten the absorption of the exudates. The passive motion consists of gentle flexion and extension and the treatment must not be such as to aggravate the pain. The daily treatment is followed by fixation in a sling.

After a couple of weeks the treatment may be carried on more vigorously and as soon as the patient can move the joint actively he must be directed to keep at it many times each day. The first movement to return is the antero-posterior; a little later, rotation; and last of all abduction. Often times in these cases, in spite of systematic treatment the motion is imperfect and the tenderness persistent, especially over the acromion, the coracoid, and deltoid tubercle.

Fracture of the greater tuberosity may occur as the result of either direct or indirect violence, such as fall upon the hand with arm extended. The displacement of the tuberosity may be upward, outward, and backward. Early disability and swelling are prominent symptoms; crepitus may be absent. Pain is produced by local pressure. Taylor, of New York, asserts (*Annals of Surgery*, Jan., 1908) that in uncomplicated cases with moderate displacement recovery may be practically perfect without the use of splints, massage, or special movements, but on the whole the best result will be obtained by immobilization or abduction to a right angle with external rotation.

FRACTURE OF THE UPPER END OF THE HUMERUS IN CHILDREN

With respect to diagnosis and treatment, fractures of the upper end of the humerus in children present some special features. Practically speaking, there are but two types of injury; fracture of the surgical neck and separation of the epiphysis. The head and anatomical neck are immune by reason of their spongy character.

If the surgical neck is fractured without displacement of the fragments or with impaction, the pain, loss of function and deformity are moderate. Usually there is considerable swelling. The treatment is simple; fixation in a sling for a week and thereafter frequent and gentle passive motion without massage and the functions of the joint are rapidly restored.

If on the other hand there is much displacement, the deformity is quite constant, the joint is thickened in front and externally and the end of the lower fragment bulges the subcoracoid area. This might be taken for the head of the humerus, but on palpation the head is found to be in the glenoid cavity. The shortening of the shaft of the humerus and the abnormal direction of its axis point to the nature of the injury.

These same signs and symptoms characterize separation of the epiphysis but this lesion is much the more serious for improper treatment may result in checking linear growth.

The *treatment* is the same for the two conditions. Reduction requires a general anesthesia and a definite maneuver.

Make strong traction on the abducted arm, directing the assistant to press outward with his thumbs against the broken ends which form with each other an angle pointing toward the coracoid. If the arm is now brought to the side the deformity recurs; on that account therefore the arm is to be fixed in abduction. This may be accomplished by plaster splints; still better by a plaster dressing including the thorax. A part of this dressing is applied previous to the anesthesia and reduction.

The patient is seated and a plaster jacket applied, including the shoulder but not the arm.

The patient is then anesthetized and the fracture reduced.

The arm is held in abduction and in a forward position, the forearm flexed to a right angle and semiprone. A plaster roller is now applied, including the shoulder, the arm and forearm. By this means you fix the scapula and relax the abductor group of muscles which act upon the upper fragment; in this manner the normal axis of the humerus is maintained.

After two weeks remove the plaster and for the next two weeks carry the arm in a sling, and function is soon restored.

FRACTURES OF THE LOWER END OF THE HUMERUS

Injuries about the elbow are always to be regarded seriously. They occur much more frequently in children and are usually due to falls upon the flexed elbow. Scudder insists that even in the apparently trivial cases the examination should be made under

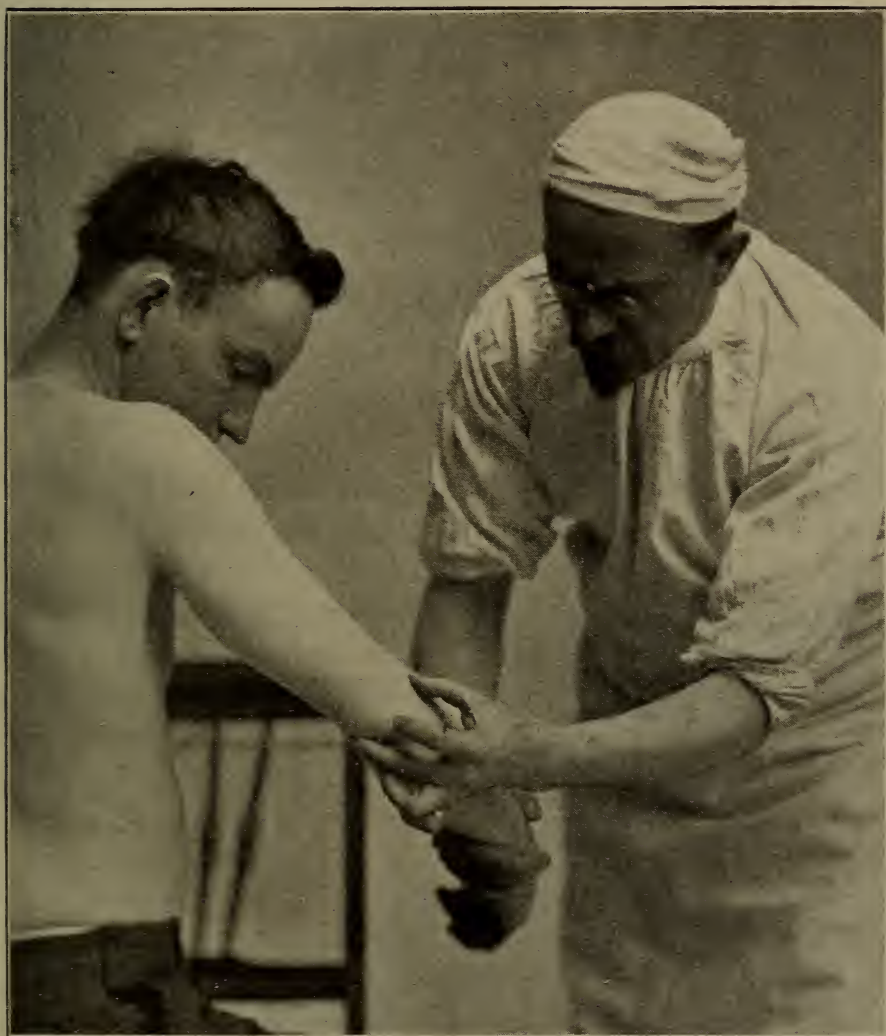

FIG. 149.—Examining the elbow; locating the three cardinal points—the internal condyle, the tip of the olecranon and the external condyle.

When the elbow is flexed at a right angle the three points stand for the corners of an equilateral triangle; when the elbow is extended the three points are in a straight line. The head of the radius is easily felt on the normal joint one-half to three-quarters of an inch below the external condyle. Gently rotating the forearm helps to locate the capitellum.

The gutter behind the external condyle is broad and shallow; on the ulnar side deeper, containing the ulnar nerve.

anesthesia, for only by that means, as a rule, can the injury be exactly diagnosed.

The diagnosis itself is chiefly a matter of applied anatomy. The landmarks and the normal relations must be clearly in mind. Observe on the sound side the relations of the internal and external condyles, the olecranon, the head of the radius. It is uncertain at first whether it is a contusion, or dislocation, or fracture. Even when sure that the case is a fracture, yet it is to be determined whether it is supracondylar, or condylar, or some combination of the two.

Scudder formulates a routine mode of procedure in making the diagnosis.

Observe the character of the swelling—whether general or localized.

Observe the carrying angle.

Palpate the external and internal condyles.

Palpate the olecranon process and head of the ulna.

Rotate the head of the radius.

Note the relation of the three bony points in extension and flexion (Fig. 149).

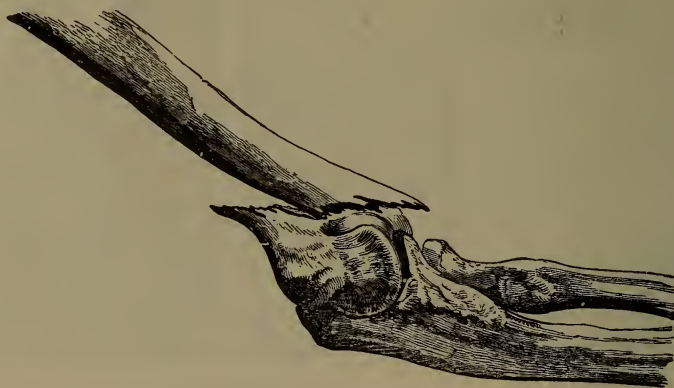

FIG. 150.—Supra-condylar fracture of humerus. Note obliquity. (*Moullin.*)

Determine the possible movements of the elbow-joint. Make measurements. Make pressure with the point of the finger to locate a painful line which marks the fracture. If the X-ray is used it should show both the lateral and antero-posterior view.

Certain forms of injury are found most frequently: (1) Supra-condylar fracture, (2) fracture of one of the condyles, (3) multiple fracture involving the joint.

(1) *Supra-condylar Fracture*.—This type occurs more frequently in children. The joint is not usually involved, the plane of fracture



FIG. 151.—Extension fracture; slight backward displacement of elbow.

extending commonly from above downward and forward. The displacement of the upper fragment, therefore, is downward and forward, and if union takes place in this position the flexion of the elbow is much abbreviated (Fig. 150).

This is the so-called “extension” fracture (Fig. 151); whereas in the “flexion”

fracture the lower fragment is displaced upward and forward (Fig. 152). It must be definitely determined which form exists.

The extension fracture, by the far the more frequent, simulates backward dislocation but you find the condyles, the olecranon and the head of the radius in their normal relations to each other. The condyles may be moved independently of the shaft and measuring from the acromion to ext. condyle you will probably find some shortening and also the normal axis is disturbed.

Compared with the other joint there is no change in width which excludes intercondylar forms.

Along with the ordinary signs of fracture the sharp end of the upper fragment may be felt in the flexure of the elbow.

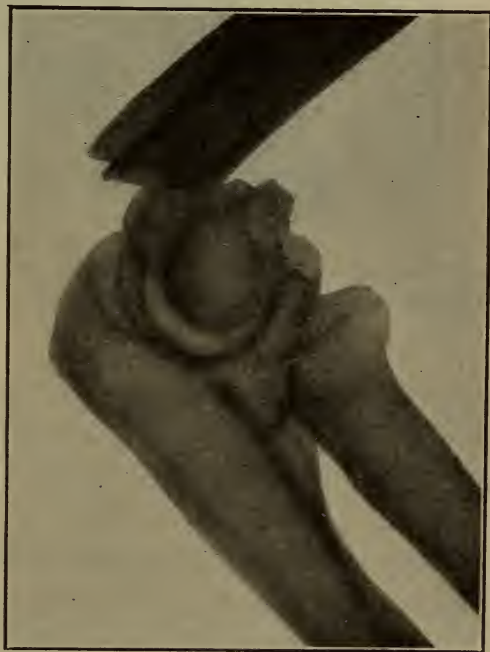

FIG. 152.—Supra-condylar fracture: forward displacement of elbow. (“Flexion fracture.”)

Imperfect reduction of these fractures leads to some loss of move-

ment and awkward deformity; and in many instances to nerve complications, the result of a large callus. A "wrist drop" for example may gradually develop in such a case the result of interference with the musculo-spiral.

Still more important, if the fracture follows the *epiphyseal* line the child's arm never attains its normal growth. How greatly necessary then that we recognize not only the type of fracture



FIG. 153.—Epiphyseal fracture of humerus; backward displacement of elbow.

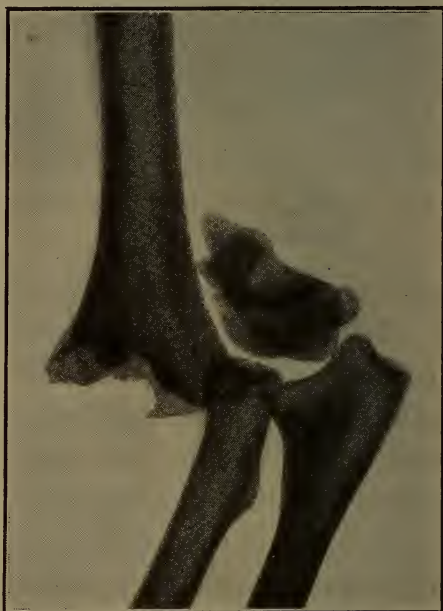

FIG. 154.—Fracture and complete dislocation of the epiphysis, lower end of humerus.

but the variations as well and that we know how to proceed so as to restore form and function to the near-normal. And this is by no means always easy even when the X-ray has exposed the details of the bone disturbance (Figs. 153, 154).

Three displacements are to be overcome: (a) An antero-posterior which uncorrected leads to interference with flexion and extension; (b) lateral, affecting the carrying angle; and (c) rotation, affecting the supinator function.

Ordinarily you will proceed in this manner: direct the assistant to make strong traction on the extended forearm, gradually changing the extension to acute flexion and while he does this, you will

make counter-traction on the humerus grasping it above the line of fracture so as to pull on the shaft and at the same time push against the olecranon with the thumbs. Grinding and tearing, the lower fragment is felt to move forward. Traction and counter-traction must be maintained on the flexed elbow while by manipulation the lateral displacement and rotation are overcome (Fig. 155). Fixa-



FIG. 155.—Supra-condyloid fracture of the humerus. Method of reduction before applying retentive splint. Counter-traction on upper arm. Traction on condyles of humerus with right hand; backward pressure with thumb of left hand. Also illustrative of method of beginning acute flexion. (*Scudder.*)

tion in forced flexion may be secured by encircling bands of adhesive or still better, we think, by a posterior plaster splint made as follows:

Twelve to sixteen pieces of crinoline long enough to reach from the deltoid insertion to near the wrist, and wide enough to cover the arm, are quilted together and two oblique notches cut corresponding to the bend of the elbow. This piece of padding is now impregnated with liquid plaster and applied to the back of the arm and forearm, and well molded (Fig. 156). The two notches permit a ready adjustment at the bend of the elbow. The support of the arm is not

relaxed until the plaster has hardened. The gutter thus formed may be strengthened by a loosely applied roller which passes from the wrist across to the arm near the axilla, around it and back to the wrist again, and so on. The arm is thus fixed in *acute flexion* (Fig. 157). Immediate reduction, immediate fixation in forced flexion is the correct formula therefore for this type of injury. But the case may be seen late and the swelling be of such degree that flexion is out of the question because of interference with the brachial vessels, something which must be watched whatever the form of treatment.

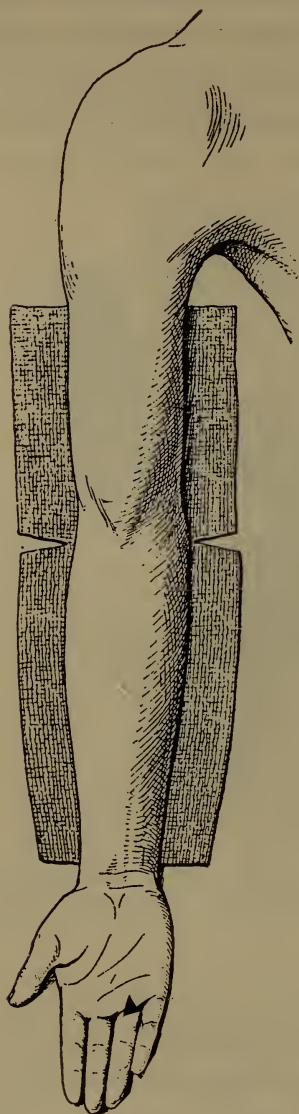


FIG. 156.—Fracture of the elbow in the child: pattern for plaster splint. Notched so that when the elbow is flexed splint may be easily molded.

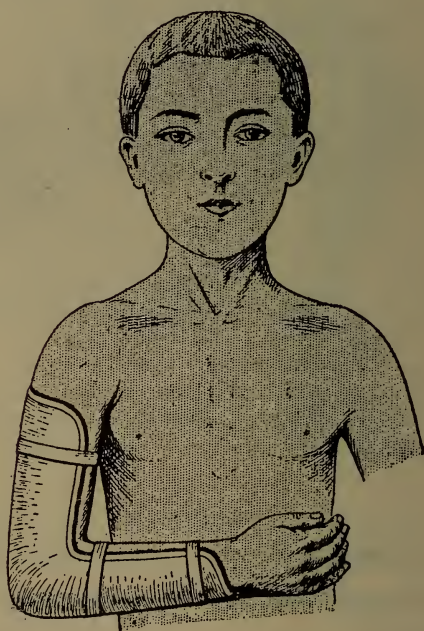


FIG. 157.—Fracture of elbow in the child: plaster splint molded to the flexed elbow.

A boy of twelve years was brought in from the country with an injury received the day before by being thrown from a horse. A diagnosis of fracture about the elbow had been made, and with it

the effort to fix the arm in forced flexion. The whole member was greatly swollen, edematous about the elbow with blebs in process of formation. The X-ray confirmed the diagnosis, showing epiphyseal separation with fracture and separation of the internal condyle. The dressing was removed, the arm fixed in extension; daily light massage was instituted to remove the tumefaction, and after four days an effort was made to reduce the fragments and put the arm in forced flexion; but this only resulted in complete obliteration of the radial pulse. The arm was left in semiflexion and pronation, and very light massage was again instituted for a few days; gradually the swelling subsided, and after the end of a week more another effort was made to reduce under general anesthesia, with better results. After a week of fixation in the corrected position the massage was begun again and continued for some weeks. Eventually the restoration of function was almost complete.

Massage in the case of these elbow injuries in children is likely to do more harm than good and should have for its only object the absorption of the exudates. Too freely used, it overstimulates the new bone formation and produces excessive callus which in this case we wish particularly to avoid lest the olecranon and coronoid fossæ be obliterated. Nor need we concern ourselves too much with passive motion. If the joint surfaces are free we may expect the child gradually and unconsciously to increase the amplitude of the movements and in one to five months a practical restoration of function is the rule. Finally there is to be mentioned the occasional case which comes in two or three weeks after the accident with the fragments unreduced and at this time irreducible. Such cases are by no means hopeless for the bone may be exposed, the periosteum turned back, the fragments pried apart, the callus chipped away and the raw bone surfaces adapted; the limb fixed in flexion and thereafter treated as a primary fracture.

FRACTURE OF THE EXTERNAL CONDYLE

This accident is not infrequent in children, due to fall upon the outstretched hand the force being transmitted through the radius to the condyle. In the adult a direct force is required.

The diagnosis is easy before much swelling occurs; after that it

can be made with certainty only by the X-ray. The ecchymosis, the pain on pressure, the limited flexion, and painful supination, point to the nature of the injury.

The fragment may be displaced upward or downward and may be rotated as well. (Fig. 158.)

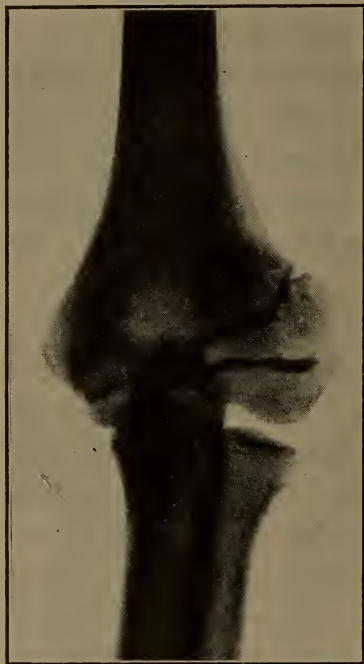


FIG. 158.—Fracture of the external condyle in the child.



FIG. 159.—Fracture of internal condyle. (*Moullin.*)

Reduction, sometimes difficult, is accomplished by manipulation and the arm is to be put in plaster in either extension or flexion depending upon which holds the fragment in place. The dressing should be removed about the end of the second week and the child encouraged to use his arm. In one or two months the junction will be nearly restored. Massage as mentioned before is not desirable in fractures about the elbow.

FRACTURE OF THE INTERNAL CONDYLE

This fracture is not nearly so frequent in children as the supracondylar form or even fracture of the external condyle because the

force of a fall on the hand is much more likely to be transmitted through the radius which abuts on the external condyle (Fig. 159).

In the adult, however, the internal condylar fracture is the more frequent and is due to direct violence.

It derives its importance from the loss of joint function, the muscular disability, or the nerve complications which may ensue.



FIG. 160.—Fracture of the internal condyle with backward dislocation of elbow.

The movements of the olecranon process are likely to be impaired, the ulnar nerve likely to be compressed by the callus; the flexor group of muscles attached thereto impaired by the shift in their point of attachment.

The symptoms and signs of fracture of the external condyle apply with equal force here. Practically the same mechanical principles operate to produce displacement, rotation and tilting of the fragments.

The *diagnosis* is to be made from these symptoms and signs, coupled with the physical examination.

It may be readily mistaken for a backward dislocation, for if the head of the radius is out of place the fragment may move backward carrying the ulna with it. In the case of children there may be actual dislocation along with the fracture (Fig. 160).

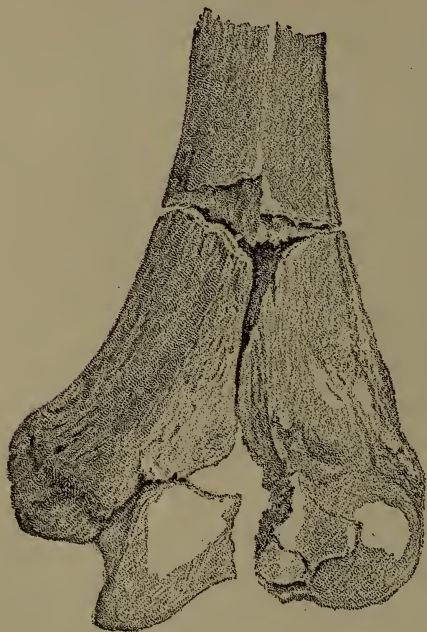


FIG. 161.—Intercondylar fracture of humerus. (Moullin.)

The X-ray will confirm these findings. The treatment, if no displacement exists, is simple; firm bandaging and the forearm fixed at a right angle in a sling.

If the displacement is marked the position of fixation will be that which best maintains the reduction. Usually this will be flexion since thereby the attached muscles are relaxed.

After a few days gentle passive motion should be practised as the best means of molding the forming callus and keeping the fossæ clear. In the course of a few months the joints functions will be normal. If the fracture is complicated by dislocation, this may be easily reduced by traction in extension and subsequently fixing the elbow in forced flexion.

If flexion is much limited it is certain that the fragment is locked in the joint and an open operation should be practised without delay.

(3) The *intercondylar* and *multiple fractures* involving the joint, as they do, require a very guarded prognosis (Fig. 161). By referring to the landmarks, the displacements are to be figured out and the fragments are to be manipulated until all the movements of the joint are restored.

The forearm is then to be acutely flexed and fixed either by the adhesive strips or plaster splints as before described. If the displacements cannot be held by this means the fracture must be treated by extension for a few days and then put up in acute flexion. Massage and passive motion must be very early begun in these cases and persisted in for a long time.

FRACTURE OF THE OLECRANON

Following fractures of the lower end of the humerus, fractures of the olecranon should be next considered for the same anatomical features are to be recalled in diagnosis. The diagnosis of this fracture has no particular feature but is to be made by inspection, palpation of the landmarks mentioned and by manipulation. This break is usually due to direct violence, sometimes to muscular action. The amount of separation of the fragments depends upon the amount of the tear in the fibrous attachments of the triceps, and is, of course, most marked in flexion, and is increased by swelling of the joint. A complete fracture opens into the joint.

As to the treatment it is obvious that no one method is equally applicable to all cases. There can be no doubt that the method of choice, where it is possible, is suturing.

If this is not advisable, or not permitted, the next best procedure is the treatment by massage begun immediately—and this whether there is much or little separation. No immobilization, only massage.

If asepsis can be assured or if the fracture is compound, suture is indicated. The operation is not difficult. The bone is exposed by a transverse incision, or if there is a wound it may be enlarged. Cleanse the wound of all exudates and trim away the ragged tissues; next expose the fracture, separate the fragments and expose and cleanse the joint.

There are several methods of suture. If the fracture is transverse, the periosteum on each side is laid back and two holes drilled in each fragment for the passage of two silver wires. When a wire is passed its ends are twisted and the coaptation perfected. The drill holes should not involve the cartilage. The wires are cut short and hammered down smooth, and the periosteum and fibrous sheath sutured, and the skin wound repaired without drainage. The arm is im-

mobilized in flexion for eight or ten days and then massage is begun. The main object of which is to prevent permanent contraction of the triceps. By this means the fragments are kept as nearly as possible in contact but even in the most favorable cases the union is merely fibrous.

If the fragments are split, they may be each perforated from without inward and a suture passed and tied on the outer side. By

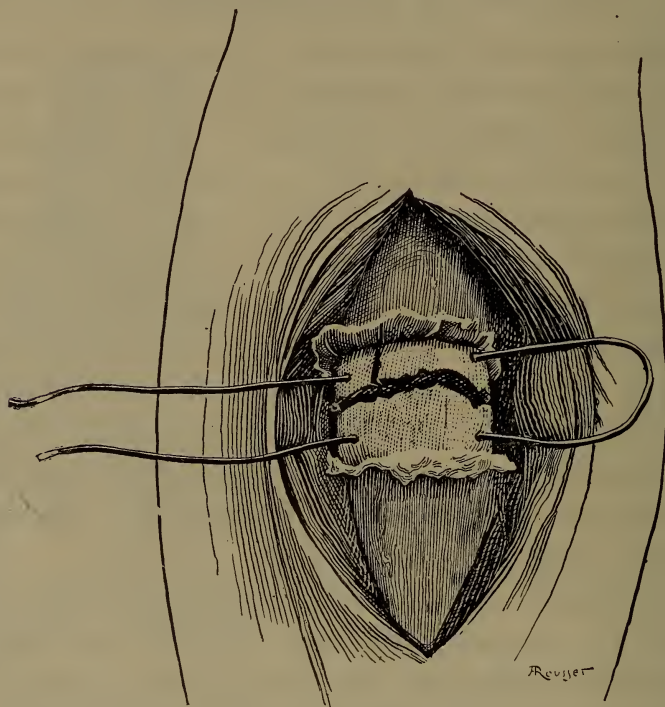


FIG. 162.—Suture of the olecranon. The suture in the form of a transverse loop perforates the lower and two upper fragments. (Schwartz.)

this means the fragments are all drawn into coaptation. If the upper fragment is small the upper transverse perforation may involve only the tendon.

A carpenter fell from his ladder, striking the point of his elbow upon the sharp edge of a timber. The joint was laid wide open, the olecranon broken across transversely and split as well. At the Deaconess Hospital the joint was cleansed thoroughly with normal salt solution, the mangled tissue trimmed away. The fragments were exposed by free use of the rugine. Two transverse holes were drilled, the upper one including both fragments (Fig. 162). Chromi-

cized catgut was used to draw the fragments together. The single suture was quite sufficient to secure coaptation. A small drainage-tube was left in the joint cavity. The periosteum was repaired (Fig. 163), and the soft parts closed with additional drainage. After the third day, the tube in the joint cavity was removed permanently. There was a little suppuration in the soft parts and

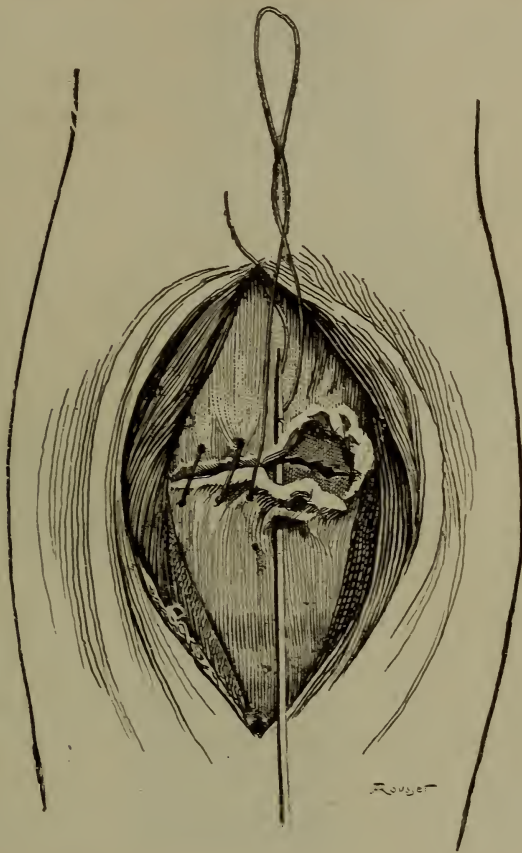


FIG. 163.—Suture of the olecranon. Repairing the periosteum by a continuous catgut suture. (Schwartz.)

the superficial drainage was retained for a week. At the end of ten days the soft parts being healed, the position of the elbow was changed from extension to flexion and daily passive motion and massage was begun. The result was perfect use of the joint.

J. B. Murphy has devised and recommends a method of subcutaneous suture (*Jour. Am. Med. Assn.*, Jan. 27, 1906). Begin by making a small incision over the external border of the olecranon

below the line of fracture. Through this small opening ($1\frac{1}{8}$ inches) drill the olecranon transversely, and over the point of emergence of the drill on the inner border of the olecranon incise the skin again. An aluminum-bronze wire is passed through the drill-hole from without inward and the inner end is pushed up under the skin along the internal border of the olecranon to the level of the apex of the bone. At this level another incision is made, the end of the wire recovered and pushed through the tendon of the triceps from within outward. A fourth small incision is made over the end of the wire to the outside, and the end of the wire again directed under the skin to the starting point and there tied tightly, in that manner approximating the fragments. Close the skin wounds.

FRACTURE OF THE HEAD OF THE RADIUS

Another fracture not infrequent should be considered in connection with injuries about the elbow and that is fracture of the head of the radius. It is the result of direct violence, or indirectly by falls upon the hand. The fracture is usually vertical, much or little of the articular surface being broken off. It derives its importance from the fact that it may interfere with all the functions of the elbow-joint—flexion, extension; rotation, supination. The diagnosis will usually require the X-ray; nevertheless the absence of change in the landmarks along with swelling and tenderness and especially the pain on supination and pronation should point to the character of the break. Sometimes crepitation may be felt by pressing the thumb over the radio-ulnar joint while rotating the forearm.

The treatment required will most frequently be excision of the fragment followed by two weeks' fixation in semipronation, and after this passive motion. The results are good.

The *neck of the radius* may be broken in much the same manner. The lower fragment is drawn upward by the biceps. Flexion of the forearm combined with traction and manipulation will effect a reduction and the forearm which is flexed for two weeks in flexion and semisupination. The point is to keep the biceps from acting on the lower fragment (Fig. 164).

FRACTURES OF THE FOREARM

Fractures of the shaft of the ulna and radius are of the greatest importance because of the possible evil consequences, immediate or remote. The chances of gangrene, of deformity, of ankylosis or paralysis are never slight. This prospect of a crippled or useless

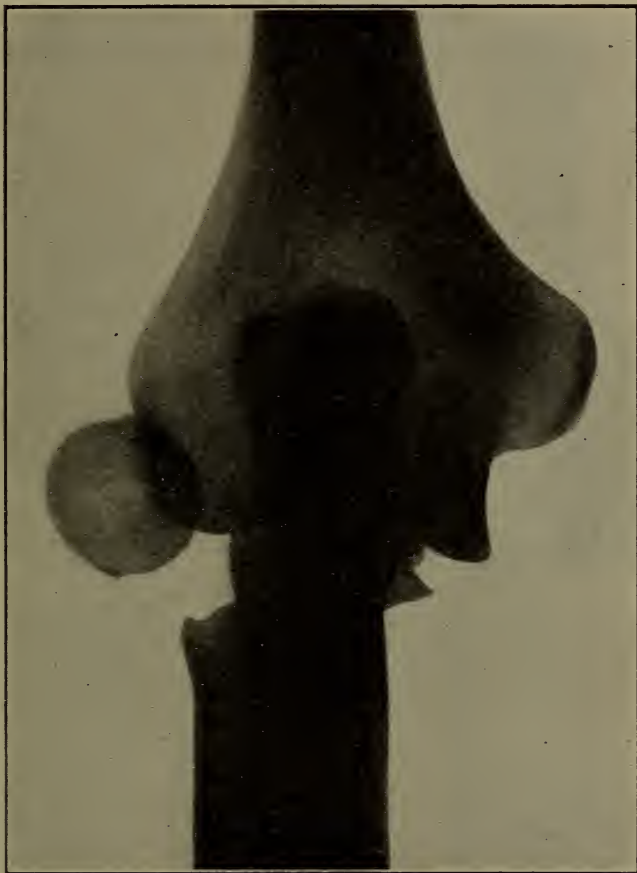

FIG. 164.—Fracture through neck of radius. Head displaced, requiring excision.

arm or hand must put us on our guard. There are several anatomical points to be kept in mind as regulating both the diagnosis and treatment. The relative position of the two bones in the stages of rotation; the attachments of the biceps, the supinator, and the pronators and their pull upon the fragments; the interosseous membrane; the variations in relative size and strength of the two bones at different levels; these are all factors to be taken into account in the study of

the mechanism of these fractures. They are produced by direct or indirect violence; in the latter case, most frequently by falls upon the hands, but it is to be noted that such accidents are more likely to produce, in the adult, a Colles's fracture; in the child, a supra-condylar fracture of the humerus. The middle third of these bones is most likely to suffer, the radius breaking at a higher level than the

ulna. The radius loses strength upward; the ulna, downward (Figs. 165, 166).

Deformity and displacement may exist in any degree. Thus one bone may be broken completely, a green-stick fracture occur in the other. There may be only a slight angulation, or some lateral displacement or extreme overriding. Naturally, fracture of both bones presents the worst prognosis. The displacements of the radius are always the more difficult to manage because of the tendency of the two fragments to rotate in different directions.

Thus the upper fragment is rotated outward by the biceps; and the lower, inward by the pull of the two pronators.

The diagnosis is not difficult. The patient presents himself supporting the injured arm which tends to turn inward below, and outward above. Pain, deformity, mobility and perhaps crepitation are present. Lateral pressure wherever applied excites pain at the site of fracture. Comparative measurements in the case only one bone is fractured will show but little shortening; or, if there is much shortening it is certain the other bone is dislocated at the elbow. For example, isolated fracture of the ulna with overriding is accompanied by forward dislocation of the head of the radius.

Treatment.—Whether one shaft is broken or both, the principles of treatment are the same. Principally, it is obliteration of the interosseous space which must be guarded against, lest pronation and supination be lost. The contrary rotation of the two fragments

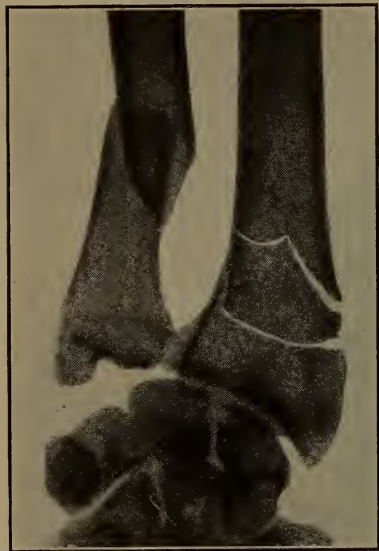

FIG. 165.—Fracture of both bones of forearm due to crushing injury; in this case the fracture of the radius is at the lower level.

of the radius determines the position in which the forearm must be fixed.

Complete supination fulfills these two main indications; it separates the shafts most widely; it permits the lower fragment of the radius

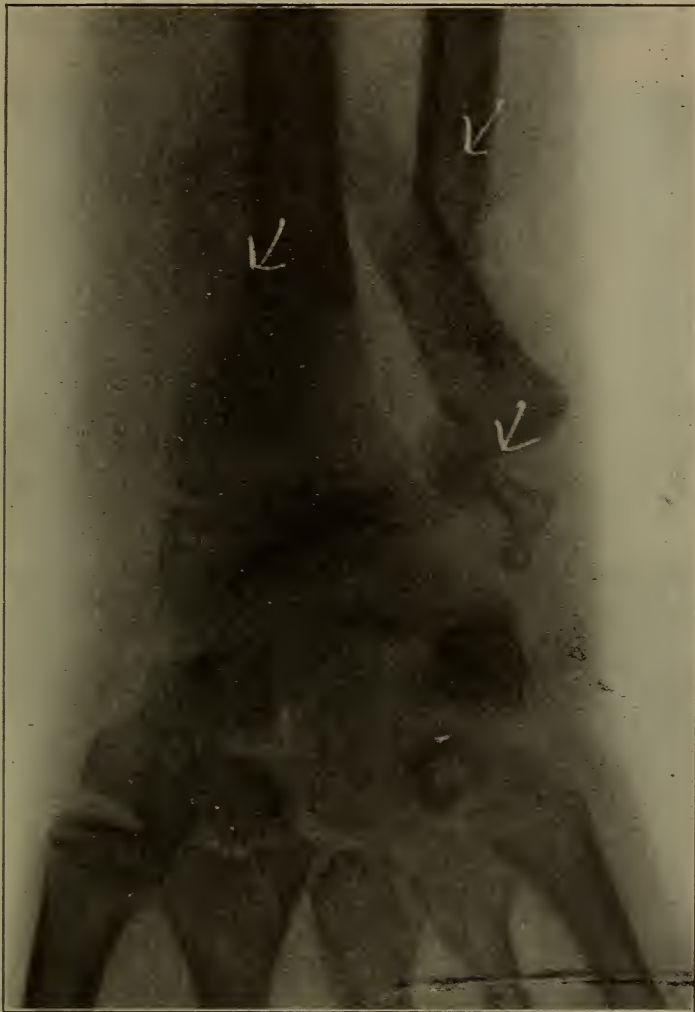

FIG. 166.—Fracture of the shaft of ulna with separation of the epiphysis; fracture of the shaft of the radius, too high for a Colles' fracture.

to fall in line with the upper which is fixed by the pull of the biceps. Reduction presents no special difficulties, theoretically, but a perfect coaptation is seldom secured. Nevertheless an excellent functional result is the rule. Under anesthesia, with the forearm supinated and flexed, strong traction and counter-traction aided by manipulation

of the fragments, will bring them into place. Maintaining the traction and supination, the dressing is applied. The simple anterior-

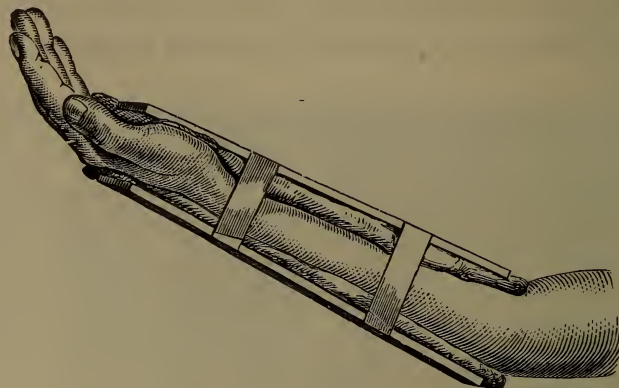


FIG. 167.—Anterior and posterior splint for forearm. (*Heath.*)

posterior splint (Fig. 167) is of little use, except in isolated fracture of the ulna, because it does not maintain supination. Whatever dressing is used, it must have one negative character; it must not compress

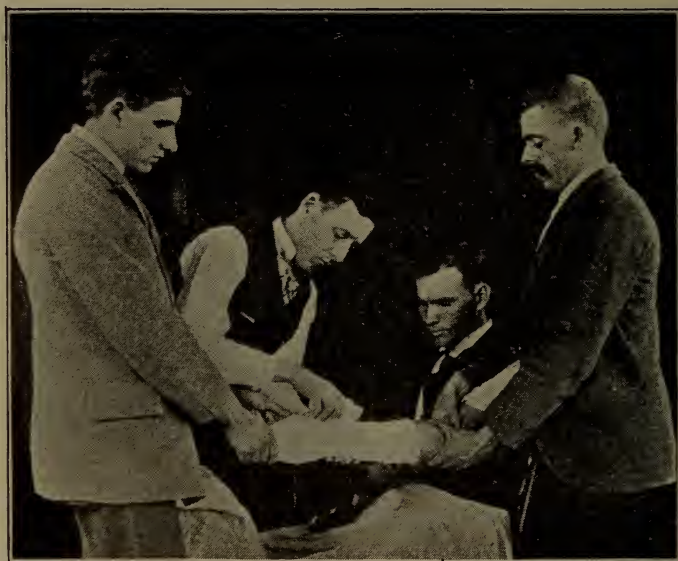

FIG. 168.—Method of supporting arm while applying plaster bandage.

the forearm laterally lest the bones be forced together and the interosseous membrane be obliterated. A plaster bandage may be used including the supinated forearm, the wrist and elbow (Figs. 168, 169).

A molded plaster splint is still better, fashioned in this manner: Twelve to fifteen layers of crinoline are cut in the form of an irregular quadrilateral long enough to reach from the axilla to the palm and wide enough to encircle the arm are loosely quilted together to form a splint. It is notched where it is to support the elbow and a hole cut near one border for the thumb. The splint is soaked in

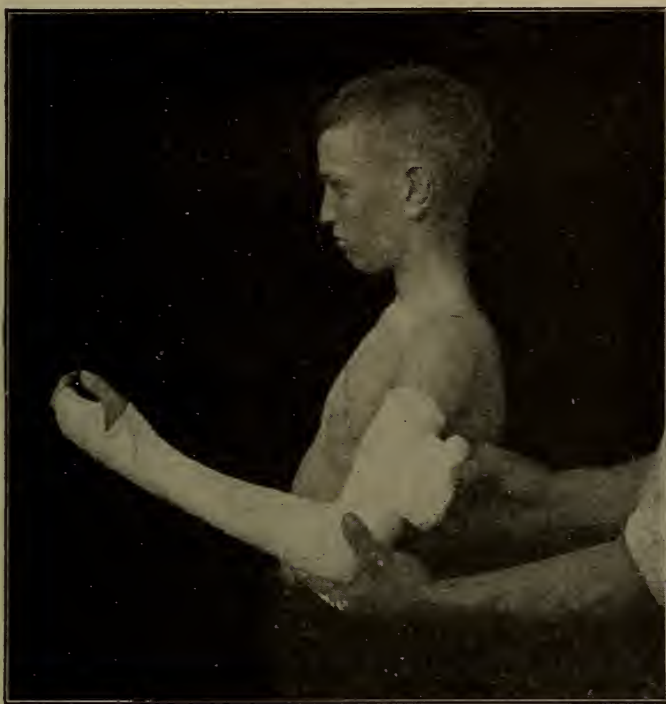

FIG. 169.—Fracture of forearm. Plaster-of-Paris splint applied. Elbow at right angle. (*Scudder.*)

liquid plaster and then molded to the posterior surface of the arm and finally fixed with a loosely applied roller. This is the best dressing for children. In the case of adults it may be necessary in some instances to apply extension to prevent overlapping.

In any event extreme care must be taken to prevent compression of nerves and arteries lest an ischemic paralysis occur.

FRACTURES OF THE LOWER END OF THE RADIUS

Certain landmarks about the wrist are useful in diagnosis of injuries in this region.

The styloid processes are easily palpated, the radial styloid lying nearer the joint line. The radio-carpal joint line is indicated on the anterior surface by the higher of three transverse creases. In supination, the styloid of the ulna lies in the plane of the posterior surface while the radial lies nearer the anterior plane. The radial styloid can be best felt in the depression at the base of the thumb, between the long and short extensor tendons. The two wrists

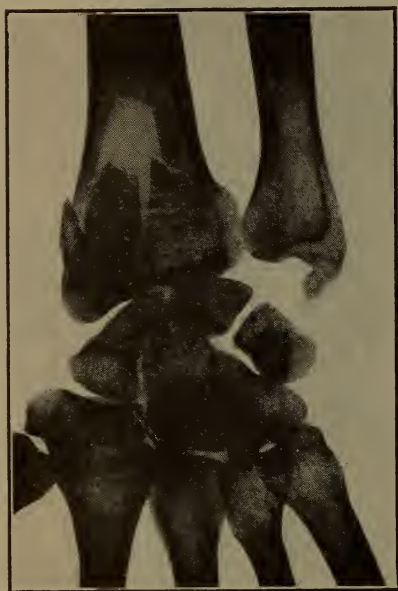

FIG. 170.—Typical Colles' fracture; impacted fracture of lower end of radius and fracture of styloid process of ulna.

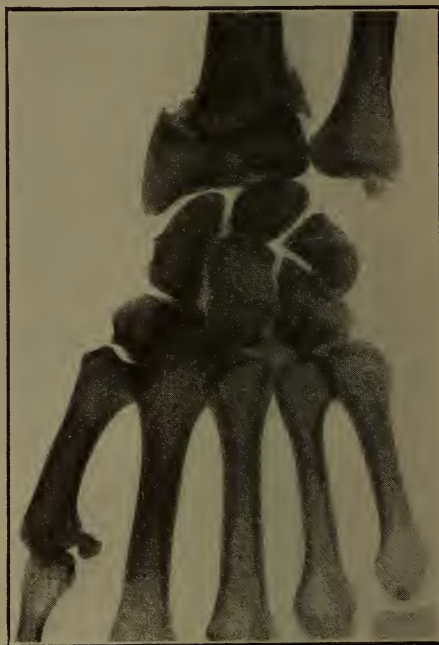


FIG. 171.—Colles fracture; marked impaction, lateral displacement producing widening of the wrist.

should be compared point for point. In the skiagraph the epiphyseal lines are distinct up to twenty years of age.

A variety of fractures may occur in the lower end of the radius but by far the most frequent and most important is that produced by falls upon the outstretched palm. The direction of the force is such that the hand is shoved against the end of the radius, carrying it backward at the same time. As a result the lower end of the radius is driven into the shaft, shoved backward and rotated toward the ulna (Figs. 170, 171).

Colles' fracture is one of the most easily recognized; producing

the characteristic hump—the silver fork deformity (Fig. 172). But it is by no means seldom that fracture occurs without deformity. In addition to the injury to the bone, the inter-articular fibrocartilage may be torn loose from both its attachments, the radio-ulnar liga-

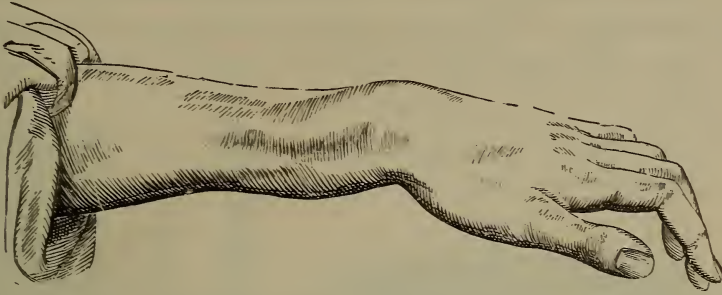

FIG. 172.—Colles' fracture. Silver fork deformity. (Moullin.)

ments are strained or ruptured, and the head of the ulna carried forward. Sometimes the tendon sheaths are lacerated and blood extravasated into the synovial sac.

Diagnosis.—Determine the position of the styloid processes of the

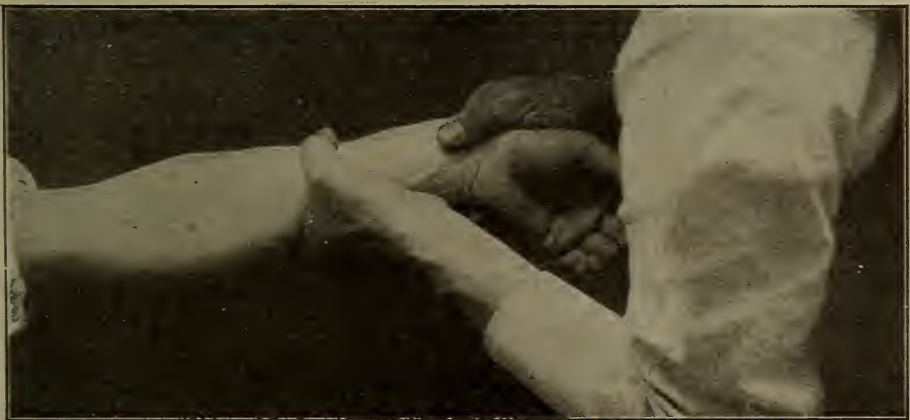

FIG. 173.—Reduction of Colles' fracture. Note grasp upon forearm and the lower fragment of the radius, traction and counter-traction being made; breaking up the impaction. (Scudder.)

radius and ulna. If there is a fracture the styloid of the radius is pushed up to a level with that of the ulna, the wrist is broadened. The transverse lines on the flexor surface of the wrist are deepened and the axis of the limb bent toward the radial side. The pain is

pronounced, mobility and crepitus are absent. Pain is elicited by point pressure across the radius, an inch above the wrist.

The X-ray is very useful in diagnosis of these fractures.

Reduction is often difficult, but it is the chief thing and must be complete, otherwise the result will be a disappointment. Anesthesia is usually necessary. Clasp the patient's hand in your own, palm to palm, and with the other hand grasp the wrist at the site of

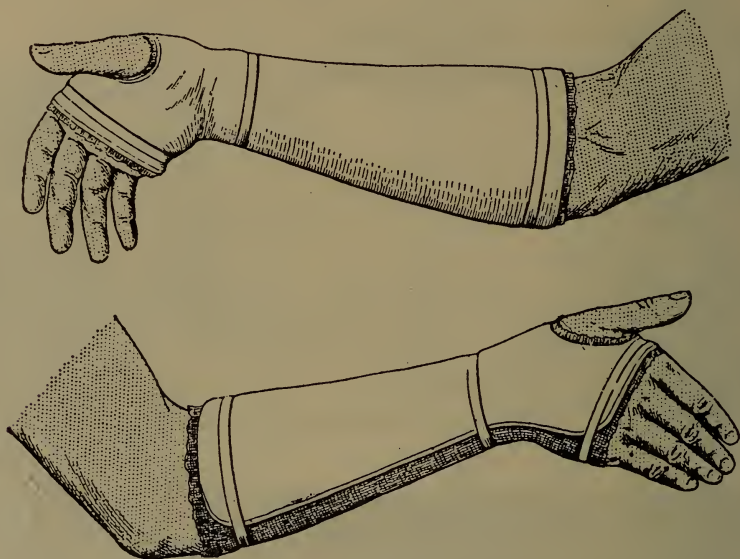


FIG. 174.—Plaster splint molded to maintain flexion and adduction, as shown in the two views.

fracture. While the assistant makes counter-traction you make forcible traction on the hand, at the same time inclining it to the ulnar side and making pressure upon the fragments. This combined traction, pressure and ulnar flexion may require force, but it will quickly reduce the fracture (Fig. 173).

Another method consists in having the assistant support the arm extended and supinated while you grasp the hand in such manner that your two thumbs may make strong pressure on the dorsum of the wrist.

The fragments grate as the deformity recedes.

Flexion and adduction are the capital points in this procedure and these positions must be maintained (Fig. 174). The best dressing is indicated in Fig. 175; or a roller plaster dressing may be applied, reviewing the position of the hand before the plaster hardens (Fig.

176). In some cases when the displacement has been slight simple anterior and posterior splints padded to suit the shape of the hand, may be employed.

There is very little tendency to recurrence of the deformity if it is properly reduced, and the fixation is a secondary matter. If there was no deformity, or a very slight one easily reduced, it may be treated altogether by massage. Otherwise a week's fixation in one of the dressings just described is advisable, to be followed by active massage.

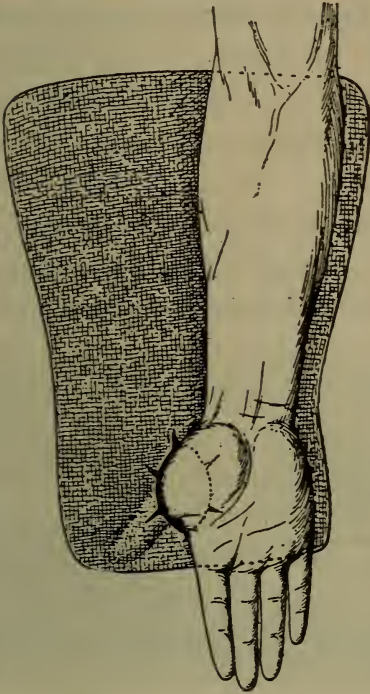


FIG. 175.—Pattern for plaster splint for Colles' fracture.

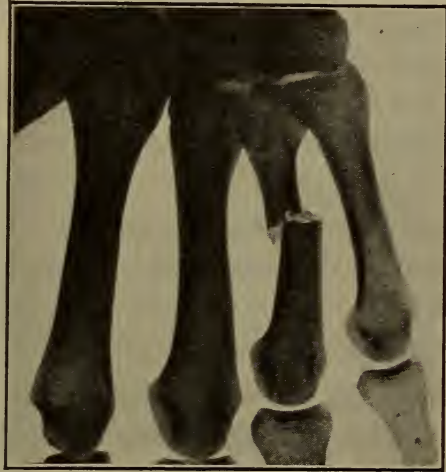

FIG. 176.—Fracture of metacarpus.

Andrews, of Mankato, Minn., emphasizes the necessity, in a reduction of this fracture, of a general anesthesia and a knowledge of the anatomy of the parts, which latter will be of more value to the tyro than any confusing description of the manner of taking hold of the parts. He remarks further that the head of the ulna must be brought back to rest in the sigmoid of the radius.

Thinking the fracture set when merely the lower fragment of the radius is in position is a mistake that has brought sorrow to many a surgeon after union has taken place.

The most frequent permanent deformity is the slumping forward of the ulna and the widening of the wrist. Andrews does not believe that early passive motion does a great deal of good and may do harm

by keeping the joint irritated by increasing the amount of callus and by causing useless suffering. Early massage, if gentle, is not only permissible, but to be recommended (Amer. Jour. Surg., July, 1909).

FRACTURES OF CARPUS AND HAND

Fractures of the bones of the carpus are not infrequent, and may occur with fractures at the lower end of the radius. The scaphoid is the most frequently involved, either alone or with one of the other bones. The injury results most frequently from a fall upon the hand when it is extended and abducted.

Fracture will be suspected from the pain and loss of function, and on examination the styloid process of the radius is found too close to the base of the first metacarpal, and the "tabatière anatomique"—the depression at the base of the thumb between the long and short extensors of the thumb—is occupied by a hard body and pressure there is exceedingly painful. This sign alone is diagnostic of fracture of the scaphoid. Point pressure in case of fracture elicits much pain. Often the thenar eminence is ecchymosed. The exact character of the lesion can only be determined by the X-ray. Reduction may be accomplished by putting the hand in the ulnar flexion and making pressure on the fragments through the palm. Excision may be necessary.

Another type of injury consists of fracture of the scaphoid with dislocation of the semilunar. This is due to a fall upon the hand and is accompanied by pain, swelling and loss of flexion of the wrist, loss of extension of the fingers. The displaced semilunar may be felt in the palmar surface and the fossa at the base of the thumb is filled up. On the back of the wrist the os magnum may be felt.

These cases untreated are likely to terminate in ankylosis of the wrist.

The *treatment* consists in hyperextension of the wrist (under anesthesia) with the purpose of facilitating the pressure into its place of the semilunar. Subsequently the hand is flexed in flexion.

In neglected cases it may be necessary to resect the semilunar in order to restore function.

Fracture of the *metacarpals* is to be diagnosed by swelling, tender-

ness, loss of function, and sometimes by crepitation and mobility (Fig. 176).

The nature and degree of the displacement is variable and is often quite indeterminable without lateral and anteroposterior X-ray views. The deformity is to be overcome by traction on the corresponding finger confined with pressure. The palm is padded with cotton and firmly bandaged.

About three weeks is required for repair.



FIG. 177.—Showing "sway-backed" appearance after fracture of the first phalanx of middle finger. (Marsee.)



FIG. 178.—Splint with attachment for correction of lateral deformity. (Marsee.)

sequently a window may be cut in the plaster over the base of the thumb and padding applied to press the fragments into place. Instead of plaster three well-padded pencil splints may be used.

Fracture of the *fingers* is sometimes compound, requiring a careful antisepsis. There is usually a tendency to displacement, so that after reduction splinting is necessary.

Fracture of the metacarpal of the thumb has some special characters and is designated as Bennett's fracture of stave of the thumb.

It is probably the most common and is the most important of the metacarpal fractures, difficult to reduce and hold.

After reduction a plaster spica may be applied with the thumb abducted and subse-

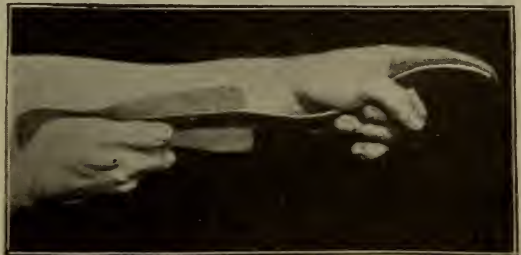

FIG. 179.—Mode of adjusting splint for simple fracture of the finger. (Marsee.)

A well-padded palmar splint is often all that is necessary, retaining it by bandages or adhesive strips.

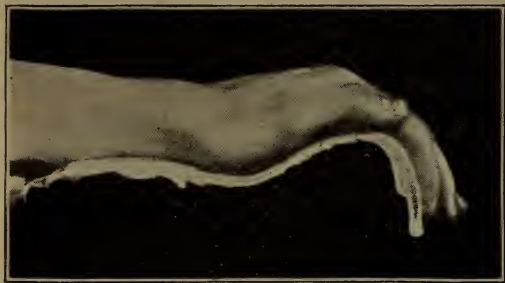

FIG. 180.—Splint wrapped with gauze adjusted for fracture of first phalanx, index finger. (*Marsee.*)

In many cases, however, the matter is not so simple and it cannot be denied that the splints ordinarily used are often very unsatisfactory, for they are not seldom so fashioned as to be inadequate to maintain extension, to immobilize perfectly, or to correct deformity.

The first or proximal phalanx most frequently suffers and the fragments are likely to bulge toward the palm, giving the finger a “sway-backed” appearance (Fig. 177). As Marsee has pointed out, this deformity will not yield to the ordinary splint, not indeed to any splint which is straight or but slightly curved.

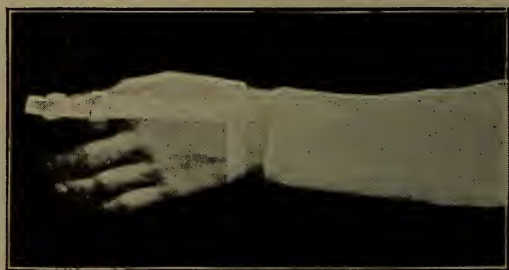

FIG. 181.—Finger splint applied. Dorsal aspect. (*Marsee.*)

The appliance recommended for this condition and which may be useful in any fracture of the digits consists of a strip of tin, zinc, copper, or galvanized iron,

14 inches long and $2\frac{1}{2}$ inches wide. This is to be folded upon itself lengthwise and hammered flat so as to make a three-ply strip three-fourths of an inch in width. Of whatever material made, it should be just flexible enough to be bent readily by the unaided fingers. Upon one end of the



FIG. 182 —Splint applied. Palmar aspect. (*Marsee.*)

strip, a piece of thin leather or canvas 4 or 5 inches long and 3

inches wide is to be riveted (Fig. 178) in order to give the strip stability when bandaged to the forearm. The strip is then shaped to suit the curved outline, in which position the fingers should be immobilized (Figs. 179, 180). The splint is to be adjusted snugly to the forearm, so that its end projects slightly beyond the tip of the finger, and fastened by strips of adhesive plaster, by a roller bandage, or by a light plaster-of-Paris casing. The finger, carefully wrapped in several thicknesses of gauze, is then adjusted with painstaking care to the splint in such a manner that the deformity, if any, is thoroughly overcome, and longitudinal and circular strips of adhesive plaster are applied (Figs. 181, 182).

In this manner, almost complete control of the finger is assured.

When, however, the lateral angular deformity is pronounced (Figs. 183, 184), some modification of the apparatus may be necessary.

Two or three strips of zinc or copper are cut out $2\frac{1}{2}$ inches long and $\frac{1}{2}$ inch in width. These are bent by one end around the splint, fitting it snugly but yet capable of being slipped backward and forward along the splint. The free end is left wide and is

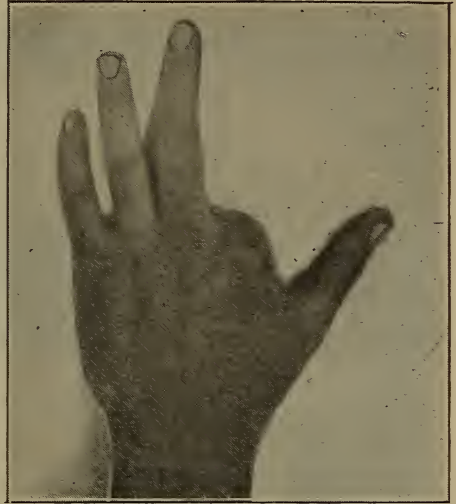

FIG. 183.—Lateral angular deformity of middle finger. Unsightly stump of index. (Marsee.)



FIG. 184.—Crushed hand. Lateral angular deformity of little finger. (Marsee.)

bent up to give the finger lateral support. This lateral support may be slipped along to the desired point and effectually corrects the deformity (Fig. 185).

Should two or more fingers be broken, several strips may be used side by side, but fastened to the same flange of leather or canvas. For two fingers, a splint of double width may be fashioned.

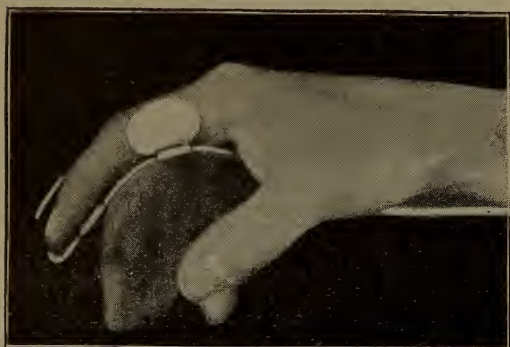

FIG. 185.—Splint applied to prevent lateral angularity. (*Marsee.*)

Should the thumb be broken, the splint may be heated and bent laterally in proper shape, or an arm may be riveted to the ordinary strip.

If the fracture or dislocation is compound, especially if attended with much displacement and difficulty in maintaining reduction, the fragment should be exposed and wired, for which one needs only a small

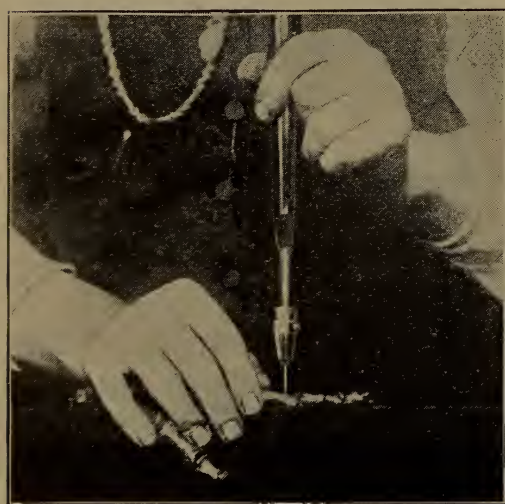

FIG. 186.—Suturing bones of finger. Drilling. (*Marsee.*)

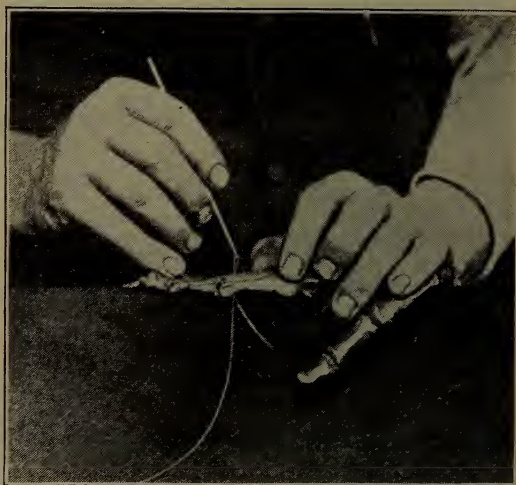


FIG. 187.—Suturing bones of finger. Drawing suture through with crochet hook. (*Marsee.*)

drill or awl, a fine steel crochet-hook and chromicized gut (Figs. 186, 187). Such is the method taught by Marsee.

The after-treatment is of importance. The splint will be required probably for two weeks or longer, but in order to prevent

stiffness, passive motion should be begun at the end of the first week and repeated every other day at first. The fragments must be held in place during the first séances. Under this treatment, the stiffness and soreness will disappear together.

FRACTURES OF THE LOWER EXTREMITY

The *first aid* in these cases is of special importance, as has already been indicated. Even more than elsewhere the principle applies that there must be absolutely as little motion as possible in order that the patient may be spared pain and augmented shock; that the deformity may not be aggravated and the periosteum and other soft parts lacerated; and that a simple fracture may not be converted into a compound one with all the additional dangers of infection. The method of lifting a patient so injured has already been described.

There are certain anatomical points useful in the diagnosis of injuries of the lower extremities, certain landmarks that must be kept clearly in mind; the anterior superior iliac spine, the spine of the pubes, the ischial tuberosity, the great trochanter, the patella and condyles of the femur, the tuberosities and crest of the tibia, the malleoli.

There are three lines useful in mensuration: Remember that the line passing from the anterior-superior spine to the ischial tuberosity overlies the apex of the great trochanter. This is Nélaton's line. Remember that the line dropped from the anterior-superior spine to the internal malleolus touches the inner border of the patella (Fig. 188).

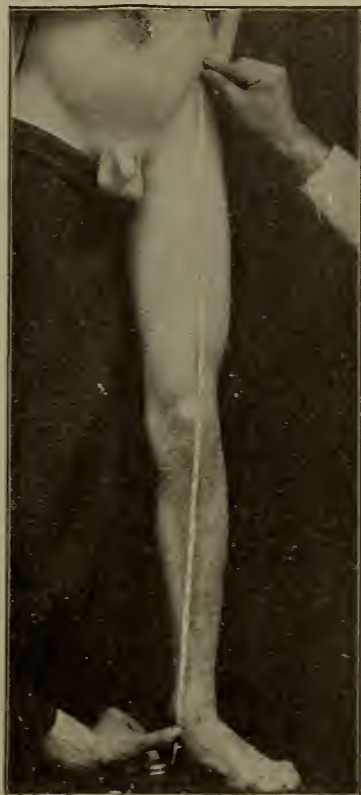

Fig. 188.—Measurement of lower extremity. Patient lying on the back looked at from above. Position of tape, hands, and limbs to be noted. (Scudder.)

Remember that the line of the tibial crest prolonged reaches the second toe.

A routine method should be practised in diagnosis. Inspection reveals changes in position, deformity swelling. Manipulation determines mobility, loss of function and pain; palpation discovers changed relations in bony landmarks and displacement of fragments; mensuration, shortening and deformity. In every case these details of examination should be carried out. Shortening is determined by two lines of measurement.

If the injured limb is shorter than the sound, measuring from the anterior-superior spine to the internal malleolus, there is a fracture. Now if the distance from the top of the trochanter to the external malleoli are compared, shortening proves fracture of the anatomical neck.

Fracture of the neck is indicated also by changes in the relation of the trochanter to Nélaton's line.

FRACTURE OF THE UPPER END OF THE FEMUR

Fractures of the upper end of the femur have been the subject of much discussion, and various forms of treatment have been recommended for imagined clinical and anatomical varieties. At the present time, nearly all surgeons are of the opinion that these lesions may be grouped under two heads, impacted and non-impacted. Even this division is not important for diagnosis, but only for prognosis, since impaction, provided it is not broken up, offers the conditions most favorable for bony union (Fig. 189).

Although the differential diagnosis is usually difficult, sometimes impossible, yet the presence of a fracture of some kind is usually determined after a little study. A severe contusion may indeed be mistaken for fracture, but this is not a serious error. On the other hand, it is a very serious error to mistake and treat a fracture about the hip as a contusion. In case of unresolvable doubt, treat the injury as a fracture. The *diagnosis* is made from several factors:

(a) *Pain* is a symptom upon which one cannot greatly rely. It is more constant in impacted than non-impacted fracture because of the accompanying bruises of the soft parts. The pain is aggravated by pressure over the hip. Tenderness and especially a full-

ness in Scarpa's triangle is frequently observed. Pain with thickening of the trochanter means impaction.

(b) *Loss of function* may also be due to contusion; moreover, the patient may be able to walk with an impacted fracture, so that this

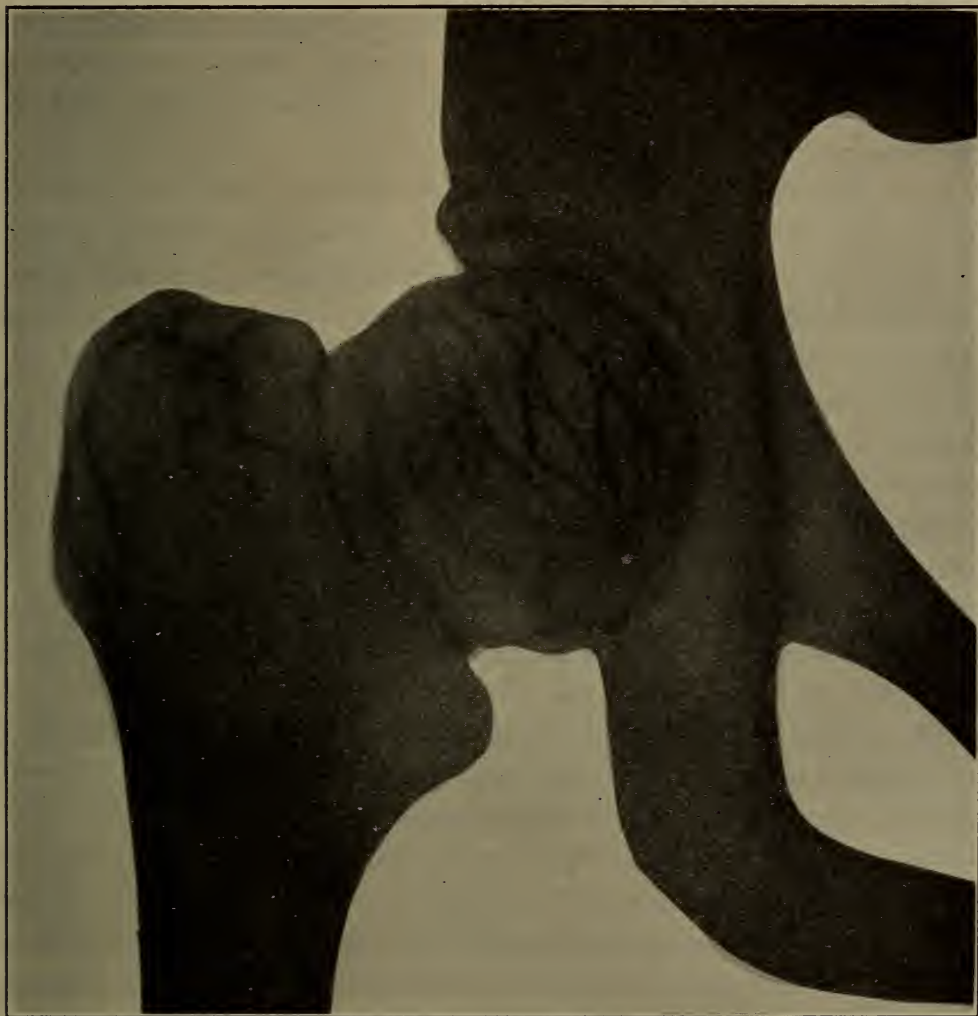

FIG. 189.—Impacted fracture at the hip. Note lines of fracture in head, neck and trochanter.

symptom is no certain criterion. However, the patient is usually unable even to draw his heel upward.

(c) *Eversion of the foot* is nearly always present in some degree, but is more frequently indicative of non-impacted than impacted fracture, and is due to the weight of the limb.

(d) *Shortening* is more frequently the accompaniment of impacted fracture. It is definitely determined by comparing with the sound side, measuring from the anterior-superior spine to the internal condyle and internal malleolus; also by determining the relation of the trochanter to Nélaton's line (Fig. 188).

(e) *Crepitation* is proof incontestable but rarely available. One should make no effort to elicit this symptom, fearing to break up impaction, which is an accident much to be deplored, according to the usually accepted view.

Senn (Practical Surgery) says upon this point that it is better to be satisfied with the probable evidence of fracture. If the surgeon in his anxiety to obtain a perfect diagnosis moves the limb freely in all directions, he overcomes impaction, rupturing the cervical ligaments, demonstrating beyond all doubt the existence of the fracture and at the same time effectually destroying all hope of reunion. As Senn suggests, a useless limb is certainly a high price to pay for a perfect diagnosis.

Age is an important feature in differential diagnosis. In the elderly the injury is more likely to be intra-capsular with or without impaction: In the middle age extra-capsular, impacted fracture is the more likely; and in the child or adolescent, separation of the epiphysis is much the more frequent.

Oftentimes the X-ray alone can determine the lines of fracture, and again it will often unexpectedly reveal a fracture in the young in whom contusion is the favored diagnosis.

The *treatment* resolves itself into two lines of procedure, depending upon whether or not the fracture is impacted. In either case the treatment should be modified by the age and constitution of the patient. Confinement on the back may be fatal in the aged, and it is imperative in such cases to give the patient more freedom. This imperfect immobilization may eventually result in an imperfect union, but one must be consoled by the reflection that a fatal attack of hypostatic pneumonia may have been prevented. In the case of the aged, therefore, the main object is to get the patient on his feet as soon as possible. For the first week the limb should be fixed with sand-bags and massaged daily. After that a plaster spica ex-

tending halfway to the knee may be applied and the patient permitted to get about with crutches.

In the case of *undisturbed impaction* in adults, the treatment is of the simplest form. The patient is placed on a smooth mattress, the limb supported by sand-bags or perhaps light extension applied, and systematic massage early instituted. Union may occur with no treatment at all. I recall the case of a man of sixty who fell in the street with what was supposed to be an apoplectic stroke. He was carried to his home to die but it was soon discovered that the conditions were not so serious but it was still supposed that he was paralyzed in one leg. After two months in bed he was able to get about with crutches but he had a very painful hip. A year later he was still on crutches and was brought to the hospital for examination and the X-ray showed that he had suffered an impacted fracture of aggravated form. He had marked eversion and shortening but a firm union. Now a year later he still walks lame but without the aid of a cane.

Union with deformity and large loss of function may be secured by doing little or nothing.

Restoration of function implies restoration of form and this accomplished by breaking up the impaction, abducting the limb and fixing it with a plaster spica.

Whitman has formulated a technic: Unless the condition of the patient forbids, he proceeds gently to break up the impaction under anesthesia. The limb is reduced by extension and gradual abduction to an angle of forty-five degrees, in the meantime supporting the upper end of the femur and rotating the leg inward.

In this position, the limb is well covered with cotton batting, all the bony points especially well protected and a flannel bandage smoothly applied. A plaster spica is now applied extending from the lower ribs to, and including, the foot. The plaster fits the pelvis snugly and is molded close to the trochanter and posterior aspect of the joint. It is also molded to the patella and condyles, and to the foot to prevent rotation. This dressing permits the patient to rise up in bed without much discomfort.

The advantage of abduction is that it makes the capsule tense and thus aligns the displaced fragments; that it directs the surface

of the outer fragment toward that of the inner; that it relaxes the muscles that produce distortion by their traction; that it apposes the trochanter to the side of the pelvis and thus checks upward displacement. Repair in these fractures is slow and can hardly be completed within a year; thus prolonged after-treatment is necessary to restoration of function (J. A. M. A., Feb. 20, 1909).



FIG. 190.—Non-impacted fracture of the anatomical neck of the femur; so called intracapsular fracture.

If the case is one of *non-impaction* (Fig. 190) with much shortening and the condition of the patient will admit Senn advises reduction followed by prolonged immobilization in plaster extending from the waist to the toes and which is fenestrated over the trochanter for the

purpose of applying lateral pressure. The lateral pressure he regards as essential to good union. But the plaster cast is difficult to apply. It is necessary that there be some sort of pelvis support and strong traction must be continued until the plaster is hard.

The limb and trunk are encased in glazed cotton or what is much better drawers of stockinet. Three layers of plaster roller are run on from the thorax to the toes. The plaster splint is then molded to the outer side of the limb, pelvis, and trunk, and fresh layers of the roller applied. The plaster is molded very carefully to the bony points as by this means the dressing secures an effective grip. The plaster splint consists of ten or twelve layers of crino-line, cut in two sections, the first extends from the thorax down to the toes along the outer side and cut to a pattern which covers half the limb, the second section is wide enough to extend from the trochanter to the level of the ensiform and long enough to reach two-thirds about the body. It is fastened to the first section in the manner of a cross.

FRACTURE OF THE SHAFT OF THE FEMUR

In this fracture the lower fragment is nearly always displaced forward and backward. If the fracture has been produced by direct force, it may be transverse, but this is the exception. The diagnosis is simple: shortening, eversion, loss of function.

Manipulation is unnecessary and decidedly to be avoided, not only that the patient may be spared the pain, but also that the trauma may not be aggravated, the periosteum torn, the muscles bruised, the vessels injured.

Reduction.—This must not be begun till all the dressings are quite ready. General anesthesia. One assistant grasps the thigh with both hands near the pelvis; the other assistant, the foot and lower third of the leg. As they make traction and counter-traction the surgeon manipulates the fragments. The traction must be prolonged as these strong muscles relax only gradually.

When the fracture is quite oblique and the pointed extremities are caught in the soft parts, a little patience will be required to free the fragments. To effect this, slight rotation and oscillation must be added to extension and abduction.

How will one know that reduction is complete?

(1) These points must exactly correspond when the two limbs are placed side by side: the upper border of the two patellæ, the lower border of the two internal malleoli, the two soles.

(2) The limbs must be the same length. by measurement from the anterior-superior iliac spine to the inner malleolus.

(3) The line dropped from the iliac spine to the malleolus must touch the inner border of the patellæ.

Dressing.—Many forms of splints are described; many of them complex; all effective in some degree. Whatever the form employed, the limb must be frequently measured and the patient's general condition kept under close watch. Scudder highly recommends a modified Buck's extension. Many are more successful with the plaster cast.

Lejar recommends, as the simplest in emergency practice, the dressing of Tillaux. From a roll of adhesive plaster are cut eight or nine strips $1\frac{1}{2}$ inches wide, and long enough to extend from the level of fracture down the side of the limb, over the sole of the foot after the manner of a stirrup, and up the opposite side of the leg to the level of the fracture.

Begin by applying one of the strips in the direction indicated. Next slip a strip transversely under the thigh, another under the calf, and a third under the ankle, and make one circular turn of each. Next apply a second longitudinal strip slightly overlapping the first; follow with another turn of each circular strip, and so on. In this manner the strips are given a firm attachment.

Every point of contact of the adhesive must be perfectly smooth. Every longitudinal strip must extend the same distance as its fellows below the sole in order that the extension weight shall make uniform traction on all the components of the stirrup.

A cord is fastened to the stirrup, passed through a pulley at the foot of the bed and a weight of 5 or 10 pounds attached. If a pulley is not obtainable, a hole can be cut in the foot of the bed if it is wooden; or the cord may work over broom handle attached to an iron bedstead. The weight must be increased in the case of the muscular or in the case of a very oblique fracture.

A case will illustrate the difficulties which may attend reduction in

these cases of fracture of middle of the shaft. A young man caught and crushed under a falling load of telegraph poles was brought to the City Hospital in full shock. It scarcely seemed possible for him to survive. It seemed certain that he must have had grave internal injuries though there was no direct evidence to that effect. The shock gradually subsided and no further evidence of visceral compli-



FIG. 191.—Supracondylar fracture of the femur.

cation arising, attention was directed to his fractured femur, which was broken about the middle. Efforts at reduction were painless but wholly ineffectual in securing a coaptation. Continuous extension was applied but after two days an X-ray examination showed the fragments still separated and overlapping.

Later an open operation found the broken ends interlocked with muscular tissue. With some effort they were freed, coapted and plated. Some suppuration delayed repair, but he finally recovered with a good limb.

SUPRACONDYLAR FRACTURES

These derive their importance from the frequency with which the fragments involve the knee-joint or the structures in the popliteal space, and from the difficulty of maintaining coaptation. Both these characteristics depend upon the obliquity of the fracture which usually extends from behind downward and forward (Fig. 191). The complications must be treated on general principles.

The fixation may be any of the means just described for fractures of the shaft. In this case as in any very oblique fracture, flexion of knee and hip seem specially indicated.

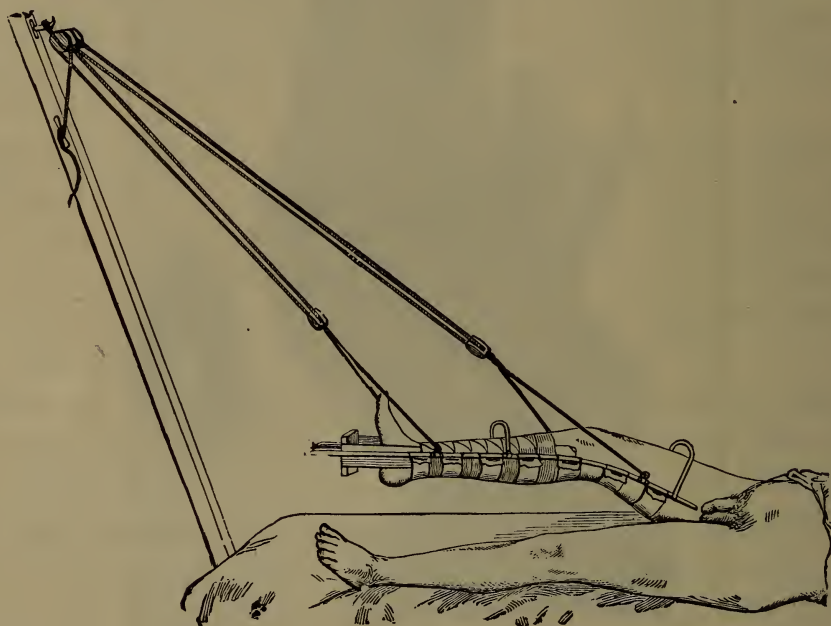


FIG. 192.—Hodgen splint for fractured thigh. (Moullin.)

Hennequin's apparatus secures an efficient extension, combined with flexion of the hip and knee and permits the patient to sit up. Downey, of Gainesville, Ga., has thought out a device which involves the same principles as the Hennequin apparatus but is simpler in application. As Downey remarks (*American Jour. Surg.*, March, 1915) the dressing aims to secure at once the *position* of the Esmarch, Smith, Hodgen (Fig. 192), or Cabot apparatus; the *extension* of the Buck apparatus; the *fixation* of plaster of Paris. This is accomplished by means of a double angular plaster-of-Paris splint.

The mode of application (briefly) is this: Secure counter-traction by a padded sheet passed between the legs and brought well up against the perineum; traction, by grasping the leg above the ankle with one hand, under the knee with the other. A plaster cast is applied from the toes to just above the knee, which is well flexed. Now secure coaptation.

Next apply the second section of the cast, beginning at the upper border of the first and carrying the roller in the ordinary manner up to the ensiform, all the while maintaining the traction with hip well flexed. Strengthen the outer side of the cast at the hip-joint by up-and-down folds of the roller or by metal splints. Split the splint if constriction is feared.

AFTER-TREATMENT OF FRACTURE OF THE FEMUR

Whatever the form of treatment, union will scarcely ever occur short of six or seven weeks. Whether union has occurred or not can be determined by manipulation of the fragments, and if they are well fixed the patient should be encouraged to use his crutches, but he should not be permitted to bear his weight on the injured leg short of three months. And even then only if he can lift his leg without pain, if the callus is rounded, and of moderate volume, and if pressure does not produce pain.

Attention should be given the selection of the crutches which should just reach to the axilla and the cross piece for the hand should not be too low lest undue pressure fall on the musculo-spiral nerve. The edema, usually moderate, disappears with increased use and likewise the muscular atrophy.

The knee, nearly always stiffened, gradually regains its movements. Shortening in some degree is inevitable but in a general way it may be said that in the course of time the functional cure is complete.

FRACTURES OF THE FEMUR IN CHILDREN

Fractures of the shaft present nothing special in the matter of diagnosis.

The treatment of choice is the plaster spica much more easily applied than in the case of adults. It must be molded carefully and

special precautions must be taken to strengthen the cast in the region of the groin.

The cast may be left off after a month. In the case of the *new-born* the best treatment is by vertical extension. In this portion the infant can be easily kept clean which is the most important part of the treatment. The fracture in the great majority of cases involves the upper third and requires much more force to effect a reduction than might be expected.

The vertical extension is accomplished by applying adhesive plaster to both limbs in such manner as to make a small stirrup for either foot to which cords are attached and passed through pulleys and fastened to the cross bar over the bed. A weight sufficient to keep the legs straight in the vertical position is applied.

A very light plaster roller incases the injured limb and which need not be changed till union is fairly firm which will usually be within two weeks (Fig. 193).

Judet particularly recommends, in these cases, treatment in the horizontal position without extension, using for fixation a gutta-percha splint. The splint is cut out of a sheet of gutta-percha at least 6 mm. thick the upper part wide enough to encircle two-thirds of the trunk from the nates to the lower ribs.

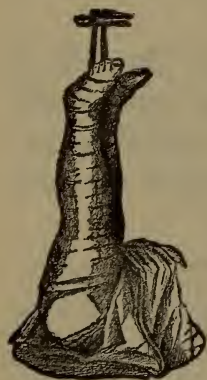

FIG. 193.—Bryant's vertical extension for fracture of femur in children.

The lower portion is as long as the limb and so tapered as to cover two-thirds of the circumference of the entire limb forming in other words a posterior splint.

This gutta-percha splint is next soaked in hot water and when soft is molded to fit the trunk and thigh and leg posteriorly, next dipped in cold water and when hardened is lined with absorbent cotton and, when the fracture is reduced, this splint is applied and held on with a roller bandage. A splint similarly molded to the anterior part of thigh may be added. This dressing may be removed every day when the infant has his bath, taking care to support the limb in the interval.

Separation of the epiphysis of the lower end of the femur is another injury which must not be forgotten (Fig. 194).

A youth of sixteen was brought to the City Hospital for an amputation of the thigh. He had a greatly swollen and painful knee, of long duration and upon which a great variety of treatment had been applied on various hypotheses. A careful manual and [X-ray ex-

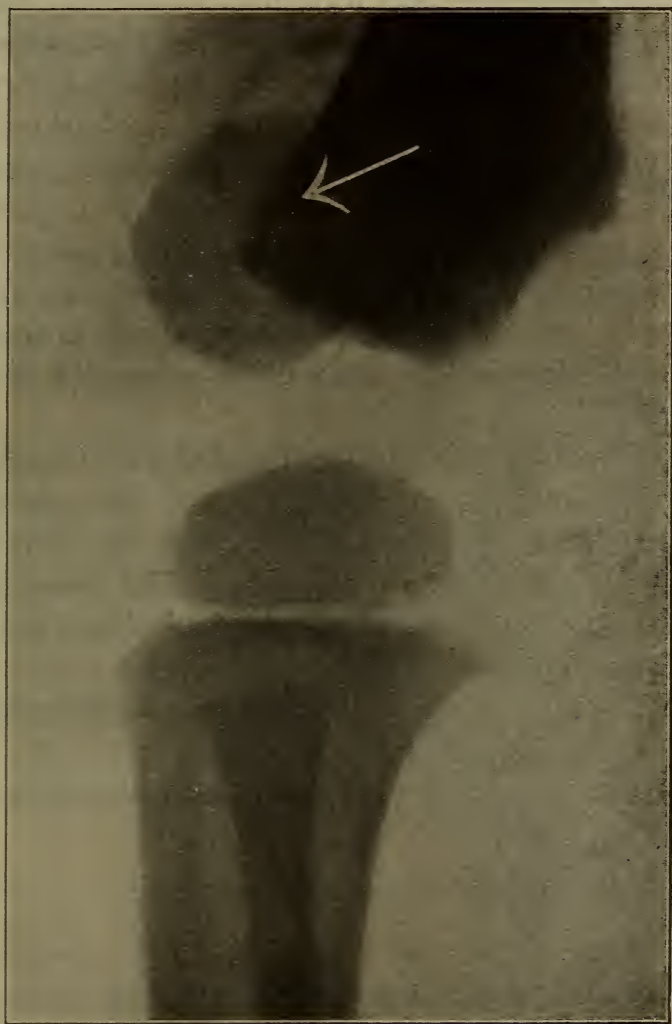

FIG. 194.—Separation of epiphysis of lower end of femur; below is shown the epiphysis of the tibia in its normal relation.

amination developed the presence of a bony mass projecting into the popliteal space from the inner side of the knee and the patella lay upon the outer aspect of the limb.

The conditions manifestly insured a permanently useless limb.

There was a history of a fall from a bicycle with injury to the knee, supposed to be a bruise. Nevertheless he had never borne his weight on the limb from that time.

A diagnosis of separation and displacement of the epiphysis was made and operation advised. A semilunar incision below the patella, followed by section of its tendon, exposed the joint and revealed the epiphysis united to the shaft in a distorted position. The spongy tissue was easily divided, the fibrous connections loosened, the raw surfaces of bone trimmed and the condylar end brought back into something like its normal position, and wired.

The patella was with some difficulty shifted into its proper groove and the tendon reunited. The limb was fixed in plaster and after three weeks passive motion was begun. Now six months after the operation the outlines of the knee are practically normal, there is slight motion and the patient walks easily with only the help of a cane.

Usually the condyles are displaced forward and laterally and the shaft projects toward the popliteal space. The change in the landmarks, the great swelling about the joint, the deviation in the axis of the limb is sufficient for a diagnosis. The treatment consists in replacement by strong traction with manipulation of the fragments under anesthesia, followed by fixation in plaster.

Sometimes forced flexion as in the case of the elbow will succeed and after two weeks extension must be begun.

Finally a few cases will resist reduction and will require immediate operation.

FRACTURE OF THE PATELLA

Fractures of the patella are comparable with those of the olecranon. They may be transverse, such are usually fractures resulting from indirect force; or they may be vertical, or oblique, or multiple (Figs. 195, 196).

There are two obstacles to osseous reunion: the action of the quadriceps extensor and the intervention of the patellar fascias, preventing exact coaptation. In spite of these unfavorable circumstances, there is generally some form of fibrous reunion unless the fragments are very widely separated (Fig. 197).

The treatment of the present time is by one of two methods—massage or suture. If the fracture is transverse, with very little separation

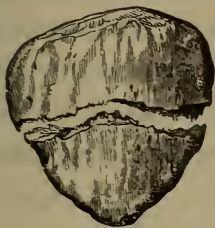

FIG. 195.—Transverse fracture of patella. (Moullin.)

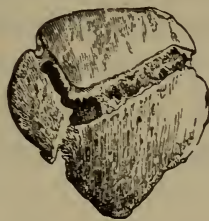

FIG. 196.—Comminuted fracture of patella. (Moullin.)

tion, and the conditions are not favorable for an aseptic operation, massage may be expected to give a good functional result. If the separation is considerable, massage will still give a better result than any splints.

In any case suturing is the ideal form, although the ideal cannot always be attained. Again, every compound fracture should be immediately sutured. J. H. Ford, whose experience with these fractures has been large, describes his method of procedure in ordinary fracture (Ind. Medical Jour., July, 1907).

In the *non-operative* cases he begins by elevating the limb for several days to relax the quadriceps. If there is effusion he bandages lightly with a flannel roller, or if the hemarthrosis is marked, a firm constriction is practised or ice-bags applied.

As soon as the acute symptoms have subsided, which is after three to five days, massage is instituted and daily applied. Begin with gentle constriction of the

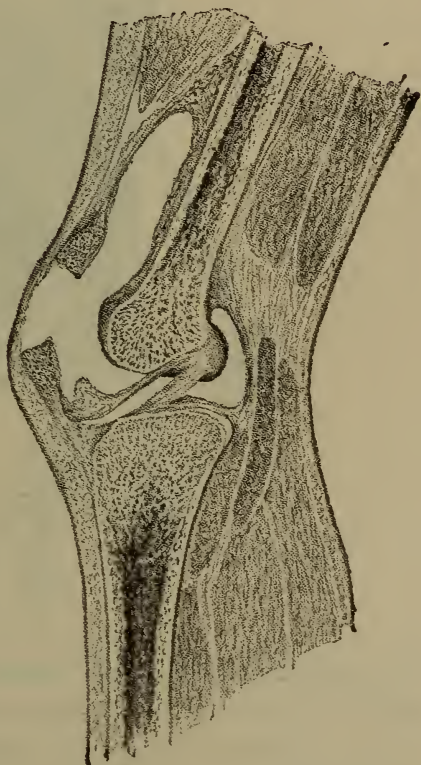

FIG. 197.—Fracture of the patella. Showing separation of fragments and distension of the synovial sac. (Moullin.)

joint with the hands by an upward movement, and ending with more vigorous pressure of the sides of the patella and the joint. In the intervals the limb should be maintained on a posterior splint. After from four to six weeks of this treatment, he immobilizes the joint in a plaster cast, preferably for two weeks more, and subsequently, he recommends a morning and evening massage and flannel bandaging until the functions are practically restored.

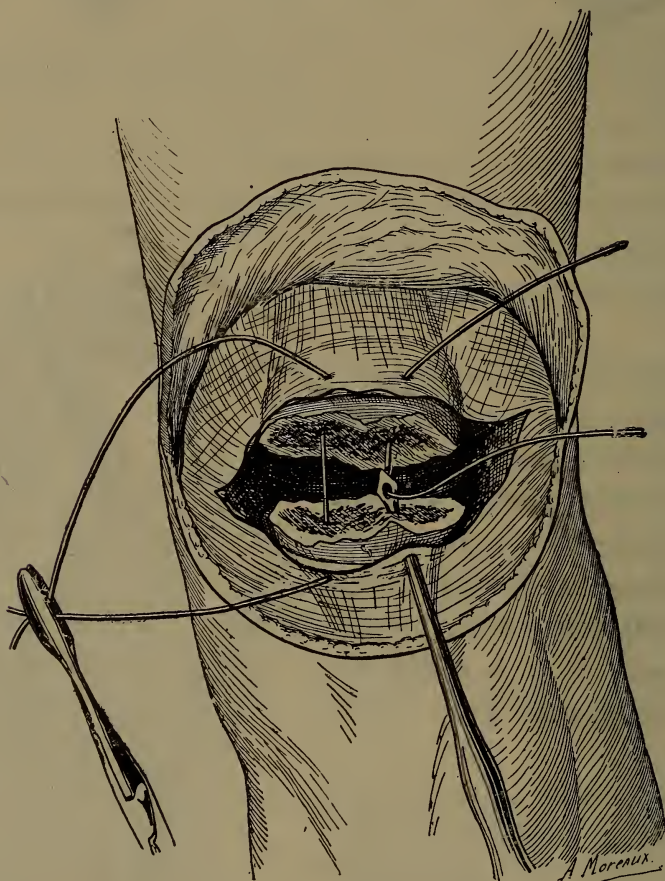


FIG. 198.—Suture of patella. Method of drilling and passing sutures. (Labey.)

The *operative* treatment is not simple, yet by no means beyond the skill of anyone who knows how to secure asepsis and to apply a bone suture. Begin with a semilunar incision, concave upward, well below the line of fracture and reaching to either border of the patella. Raise the cutaneous flap and expose the patella. The articulation is carefully wiped out and freed of all fragments and clots.

Fixing the upper fragment by appropriate forceps, two slight incisions are made in the periosteum at the points where the drill is expected to enter. Two tunnels are now drilled from above, emerging on the face of the fracture well outside the line of the cartilage. The sutures are drawn through these openings and the process is repeated in the lower fragment, but great care must be used in securing a correspondence with the first two drill holes or the coaptation will be imperfect (Fig. 198). By traction on the sutures the fragments are brought together, and great care is necessary to avoid

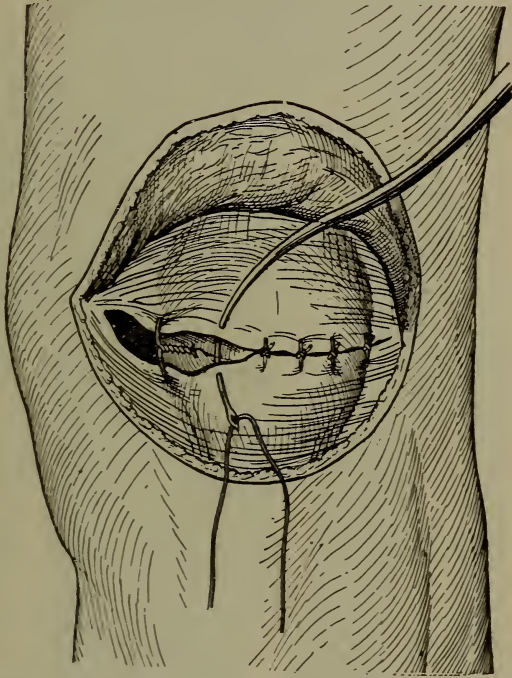


FIG. 199.—Suture of patella. Completing repair by suture of periosteum and fibrous coverings. (*Labey.*)

including shreds of fascia. The sutures are tied, twisted firmly, and pressed down upon the bone. The periosteum and fibrous coverings are next sutured with catgut (Fig. 199).

Ford prefers not to wire, but, after approximation, sutures the lateral fascia with No. 3 forty-day chromicized catgut and the aponeurosis in front with No. 1. A No. 1 forty-day suture, 18 inches long, is then threaded on a strong, half-curved needle which is entered into the aponeurosis just above and on a line with the outer

edge of the patella and follows the upper border of the patella to the inner side where it emerges; is re-entered and carried down the inner side; again around the lower fragment, passing through the ligamentum patella and emerging at its outer border. This retention suture is now tied tightly at this last point of emergence (Fig. 200). The skin wound is next repaired without drainage. The limb is subsequently immobilized for two weeks when massage is to be begun.

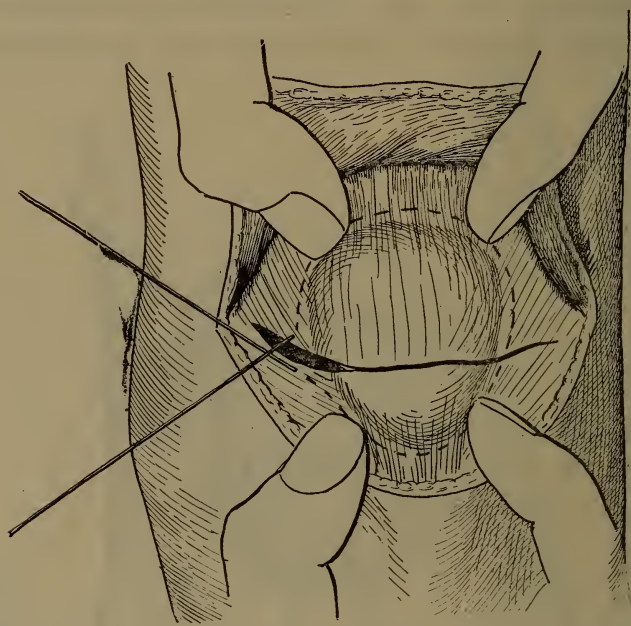


FIG. 200.—Fracture of patella. Circular suture. (Labey.)

Ford lays down these rules respecting the treatment of simple transverse fracture:

(1) Operative treatment should never be undertaken except under the best conditions for maintaining asepsis.

(2) Even under aseptic conditions not every case should be operated on, but only those in which the separation is at least $\frac{1}{2}$ inch and the "reserve extension apparatus" is compromised by lateral tears.

(3) Operative treatment fulfills all the indications in a degree which the non-operative treatment can only partially achieve.

(4) Early massage favors complete restoration of function and should be used in all cases.

- (5) In operative treatment open arthrotomy should be practised.
(6) Absorbable suture material applied only to the soft parts is sufficient in nearly every case.

FRACTURES OF THE LEG

Fractures of the leg present many variations, but the prognosis and the difficulties of treatment depend chiefly upon whether the fracture is transverse or oblique. If transverse there is usually

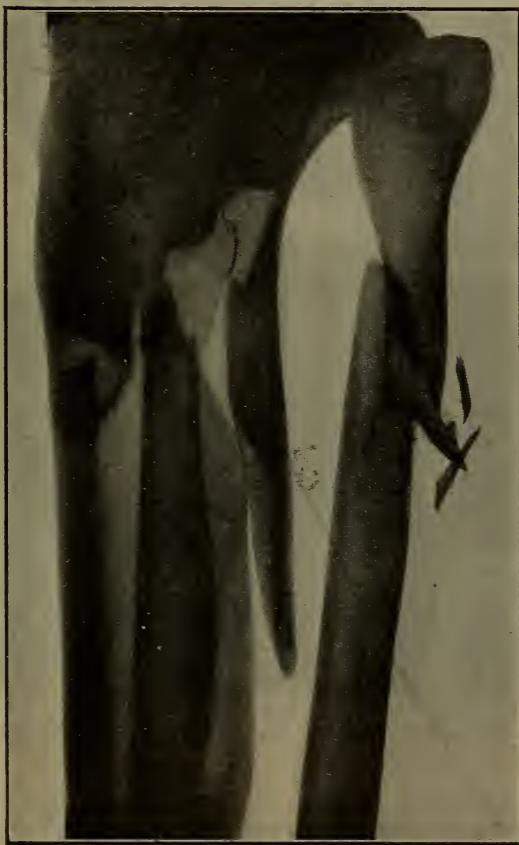


FIG. 201.—Longitudinal fracture of tibia and oblique fracture of fibula.

slight displacement, easily reduced and easily maintained; if oblique there may be much displacement which is difficult to reduce and hold, and often results in much loss of function.

Transverse fractures more commonly are due to direct force and the lesion corresponds to the application of force. Oblique fractures

are more commonly due to indirect force and the two bones give way at their point of least resistance, which in the case of the tibia is at the junction of the middle and lower third; in the case of the fibula in the upper third. In general, displacement is always favored if both bones are fractured (Fig. 201).

The diagnosis of these injuries usually offers but little difficulty. The deformity, loss of function, pain and crepitus, and preternatural



FIG. 202.—Fracture of upper end of tibia, involving the joint.

mobility leave but little doubt except when the injury is at the upper end, and where the joint may be involved (Fig. 202), or when the fibula alone is fractured. A useful test for fracture of the fibula is compression of the two bones some distance from the suspected site; the pain occurs not at the point of pressure but at the point of fracture.

If there is great displacement of the fragments the deformity is pronounced, the foot turns to the outside, the fragments may be

felt projecting under the skin which soon becomes greatly discolored and often covered with blebs.

Reduction.—The assistant grasps the leg at the knee, the surgeon grasps the foot with one hand and the heel with the other; or two assistants may make the necessary traction while the surgeon manipulates the fragments.

What is the test of good coaptation? The crest of the tibia forms a continuous line without projections or depressions. This line prolonged strikes the first metacarpal space. The internal surface of the tibia is smooth and uniform. With the foot at a right angle, a line dropped from the anterior-superior iliac spine to the inner border of the great toe touches the inner border of the patella.



FIG. 203.—Cloth cut to fit the limb and notched at the ankle in order to be more easily adjusted to the malleoli when it is soaked with plaster. (*Lejars.*)

The reduction is by no means so simple as it seems and even when easily accomplished may be difficult to maintain while the dressing is applied. A maneuver which often succeeds without the use of great force is that which is practiced in the open operation. The limb is flexed at the line of fracture and the two fragments brought into contact along the line of their lower borders. This affords a leverage when traction is applied. Coincident with traction the limb gradually straightens and the lower fragment adapts itself to the upper.

Dressing.—This will vary somewhat, depending upon the situation and tendency to displacement. In the simple case of fracture of the shaft of the tibia, following the counsel of Stimson, it is best to put the patient to bed with the limb in a Volkmann splint for about a week until the swelling has subsided, and then to encase it in plaster of Paris. Immediate application of the plaster of Paris is objectionable because it cannot be determined from the first whether the

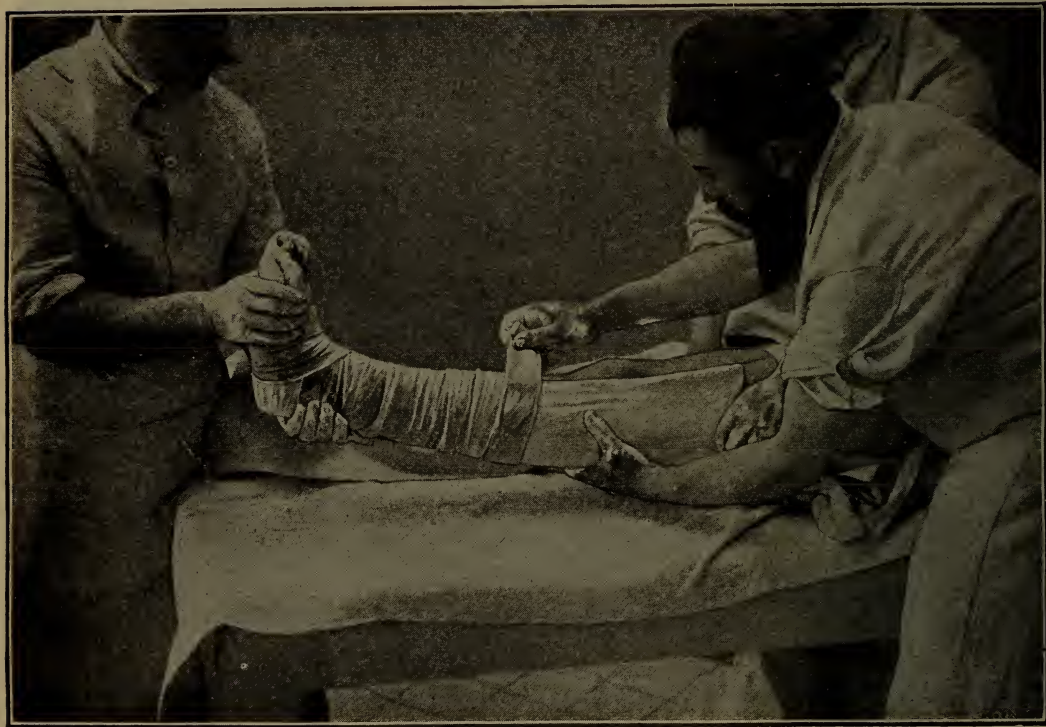

FIG. 204.—Plaster splint applied and fixed with roller plaster bandage. Note manner of supporting limb and applying roller. (*Lejars.*)

swelling will increase or diminish. The two dressings may be combined by applying a plaster splint from the first, and this we prefer.

Lejars describes the construction of such a splint. He measures from the middle of the thigh down to the heel and up the sole to the toes, and this will be the length of the sixteen layers of crinoline from which the splint is to be made. Take the circumference of the thigh, the knee, the middle of the leg, the ankle, and transfer the measures to the crinoline which was cut wide enough in the first place to en-

circle the thigh. Connect the ends of these cross measurements with a chalk line and in this manner one forms a rough outline of the limb, and the bandage is cut accordingly. Some prefer to apply the material to the sound limb and mark it off in that way.

Opposite the ankle a notch should be cut in the dressing, running toward the heel, that the dressing may be more readily fitted (Fig. 203). This is soaked with liquid plaster and applied while the extension and counterextension are maintained and the foot fixed at a right angle. This tension must not be relaxed until the plaster has hardened. The dressing is completed by applying a roller bandage (Fig. 204).

While the plaster is hardening it is necessary to test the reduction by the measurements indicated and to readjust the alignment, the assistant must be warned not to carry the foot forward in making traction lest angulation occur.

The plaster must be well molded about the knee and the ankle in order that shortening may not recur.

Oblique fractures (Fig. 205), hard to hold, are likely to be near the lower end. The quadriceps extensor pulls the upper fragment forward, and the gastrocnemius pulls the lower fragment backward. The special form of dressing which Scudder recommends for this form of fracture is made by a combination of plaster and adhesive strips. The adhesive strips are applied as indicated (Fig. 206). A thick roll of sheet wadding is applied to the sole of the foot, and a



FIG 205 — Typical oblique fracture of the shaft of tibia.

plaster bandage applied from the toes to above the knee. A buckle looking upward is incorporated in the plaster just above the level of the knee. A slit is left in each side at the ankle for the lower extension

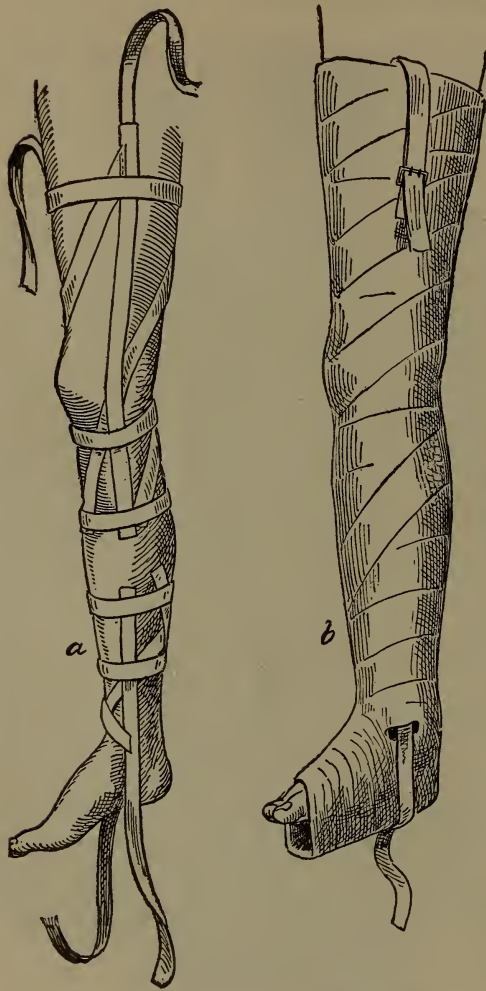


FIG. 206.—Plaster traction splint; *a*, Application of adhesive-plaster extension strips; *b*, plaster bandage allowing exit of extension straps. Note space left below the sole to allow for effective traction and buckles to which the upper extension is attached. (*Scudder.*)

strips to come through. When the plaster has hardened, the upper extension strips are fastened in the buckles and the lower extension strips pulled out through the slits and drawn tight around the foot piece after the wadding at the sole has been removed. The purpose of this arrangement is to maintain extension.

Whatever form of dressing is used the limb must be watched to see that no displacement occurs. While a simple fracture usually firmly unites within six weeks, those which have been hard to keep reduced will remain weak much longer. As soon as there is sufficient union to prevent displacement, then massage should be begun and continued till the limb's functions are restored.

Whether it is safe to leave off the dressing is to be determined largely by the character of the callus which should be fusiform and of moderate volume. The pain on pressure and movement must be slight and of course there

must be no mobility of the fragments.

Crutches must be used to begin with and light, easily removable splints must be worn.

Marked swelling may always be expected as soon as the patient

begins to get about on crutches, a condition which may alarm him greatly but this and the pain will gradually subside with increasing muscular and articular activity.

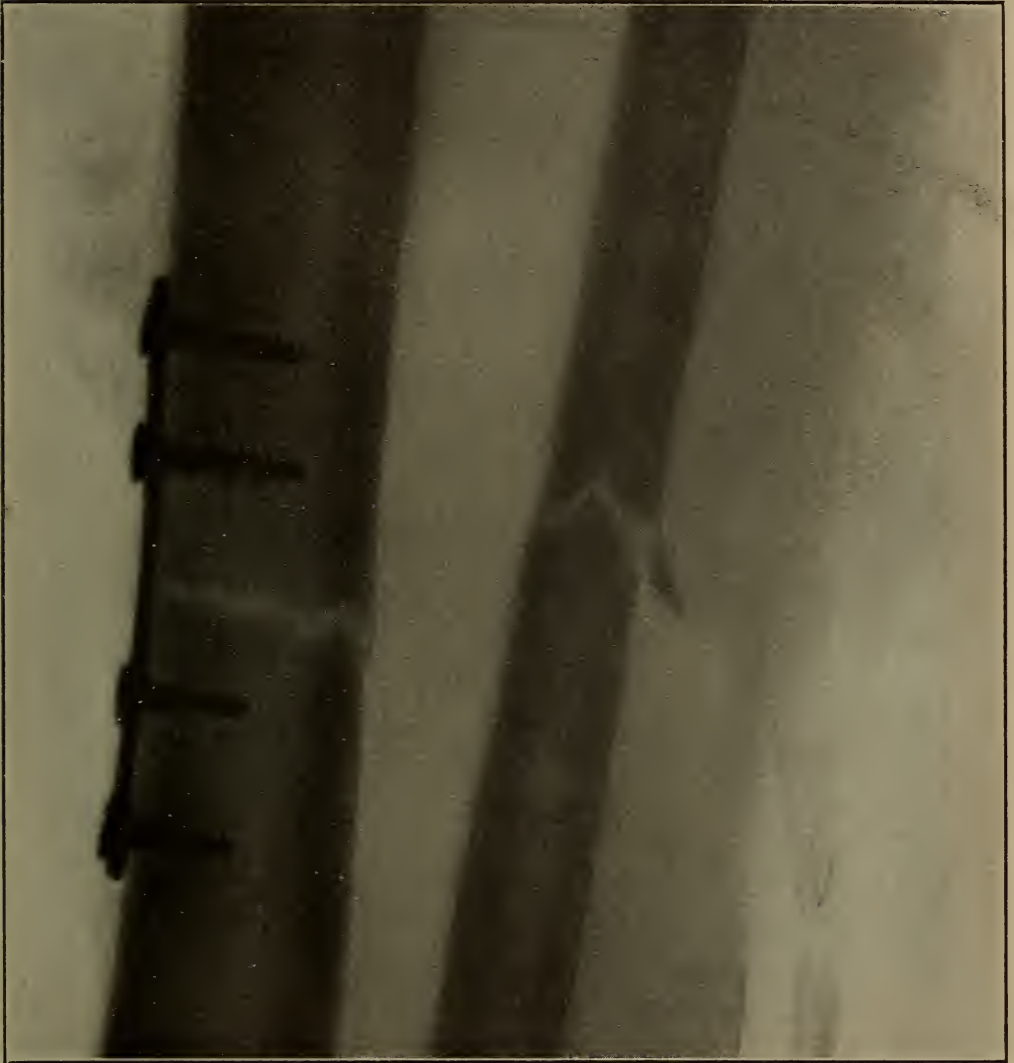


FIG. 207.—Perfect coaptation secured by plating, but in this case same results would probably have followed non-operative treatment since the fracture was not oblique. If the fracture requires plating at all a longer and stronger plate than is shown should be used.

The muscular atrophy and joint stiffness are not the least to be considered of the complications of convalescence and it is to be remembered they are aggravated by prolonged immobilization.*

*For remarks on plating see Fig. 207; fracture of the anterior tuberosity of the tibia, Fig. 208; and page 207.

POTT'S FRACTURE.—Fracture of the fibula with eversion and abduction of the ankle has a character of its own. As Stimson remarks, the diagnosis can usually be made at a glance (Fig. 210). Three points of tenderness on pressure are constant and characteristic: one

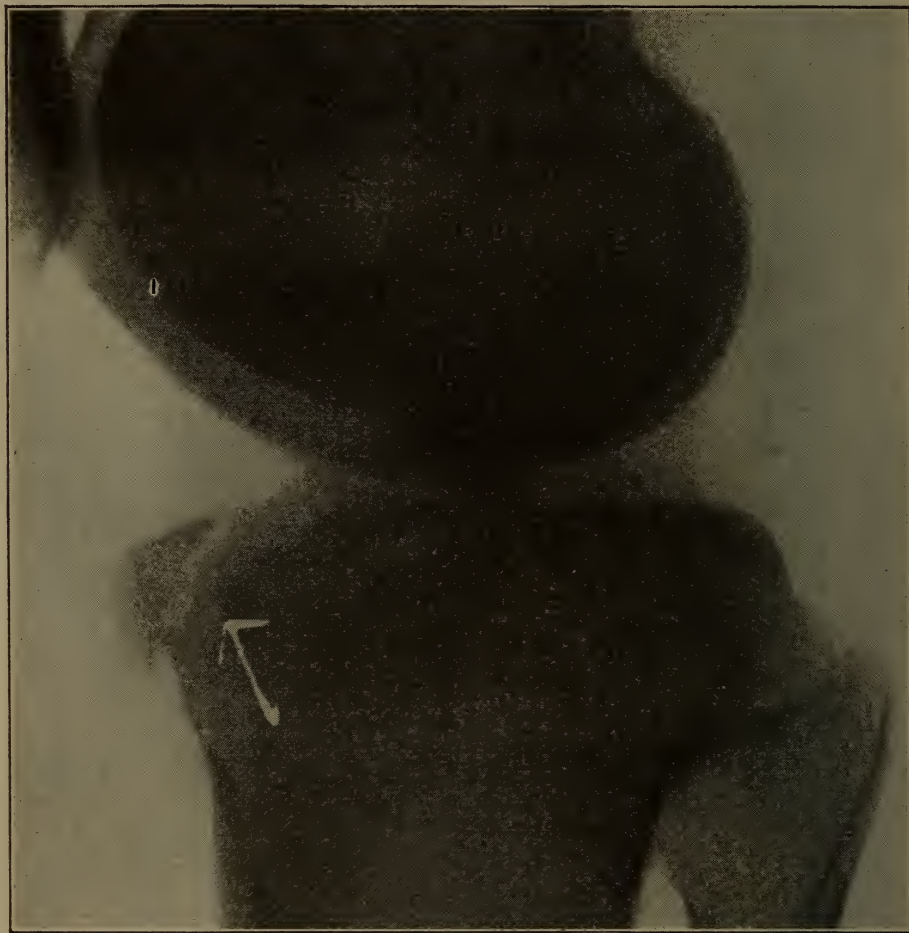


FIG. 208.—Fracture of the tubercle or anterior tuberosity of the tibia, point of insertion of the patellar tendon is not rare and usually due to striking the knee while strongly flexed.

There may be considerable displacement and disability and in some cases it may be necessary to wire the fragment. Usually fixation of the extended leg for three weeks is sufficient for a union.

in the groove between the tibia and external malleolus; another at the base of the internal malleolus; the third over the outer aspect of the fibula, marking the point of fracture. Marked ecchymosis appears beneath the external malleolus and sometimes beneath the internal (Fig. 211). Immediate reduction should be the rule.

Reduction.—Grasp the foot in one hand, the heel in the other, and while the leg is steadied by the assistant, draw the foot forward and

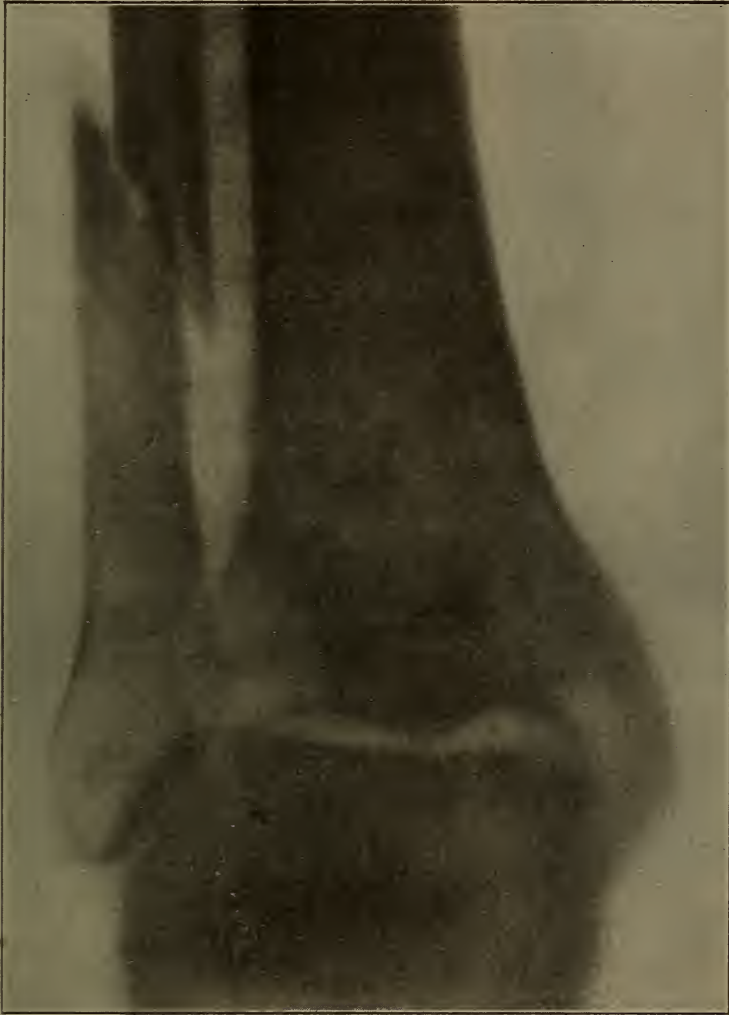

FIG. 209.—Fracture of the fibula in its lower third or near the malleolus may be unsuspected and the symptoms be attributed to a sprain of the ankle. But swelling and tenderness above the ankle with much pain on walking will give rise to the suspicion of fracture which the X-ray will confirm.

The patient must keep off his feet for three weeks with the leg lightly splinted with the foot in good position, massage. The nearer the fracture is to the joint the greater the tendency to flat foot.

inward. If this does not entirely succeed, the fragments may be pressed into place. With the foot at a right angle and the malleoli in their normal relations, the dressing is applied. This dress-

ing, to quote Stimson further, is preferably a posterior and lateral plaster splint although the plaster cast may be used.

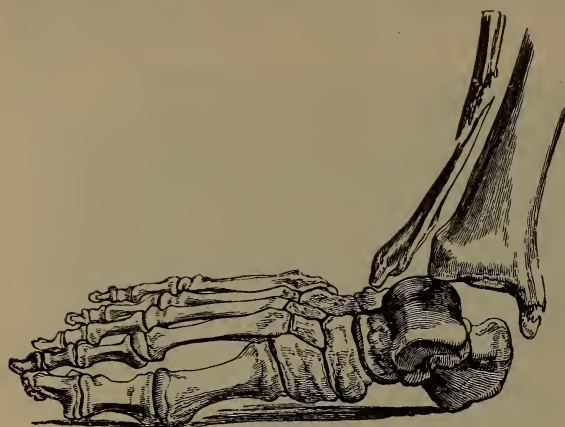

FIG. 210.—Pott's fracture.

olus, pass over the dorsum of the foot to the inner side, under the whole and up along the outer side of the leg to the same height as the posterior (Fig. 213). They are snugly molded and bound to the limb while still wet, with a roller bandage.

In the meantime, till the plaster sets, the reduction must be maintained.

Dupuytren's splint is often of great service in this fracture, especially as a temporary dressing. It consists of internal lateral splint, well padded over the ankle and which extends from above the knee and projects beyond the foot. It is held in place by a bandage at the knee and above the ankle. The foot is then abducted, flexed to a right angle to the leg and secured to the splint by a third bandage (Fig. 214).

These fractures are always serious from a functional point of view and the after treatment is of the utmost importance.

The plaster splint may be made from twelve to thirteen layers, cut from a 4-inch plaster roller. The posterior splint should be long enough to extend from the toes along the sole and up the calf nearly to the knee (Fig. 212). The lateral one should begin just in front of the external malleolus,



FIG. 211.—Pott's fracture. Note fracture of internal malleolus.



FIG. 212.—Posterior splint applied.
(*Stimson.*)



FIG. 213.—Lateral splint
[applied. (*Stimson.*)




FIG. 214.—Dupuytren's splint. Temporary dressing for Pott's fracture.

Flat foot is likely to occur from too early use not less than from imperfect reduction.

Six to twelve weeks is required for a repair sufficient to bear the patient's weight.

FRACTURE OF THE FOOT

Fracture of the *astragalus* may occur independent of injury to the other bones and may occur with or without displacement of

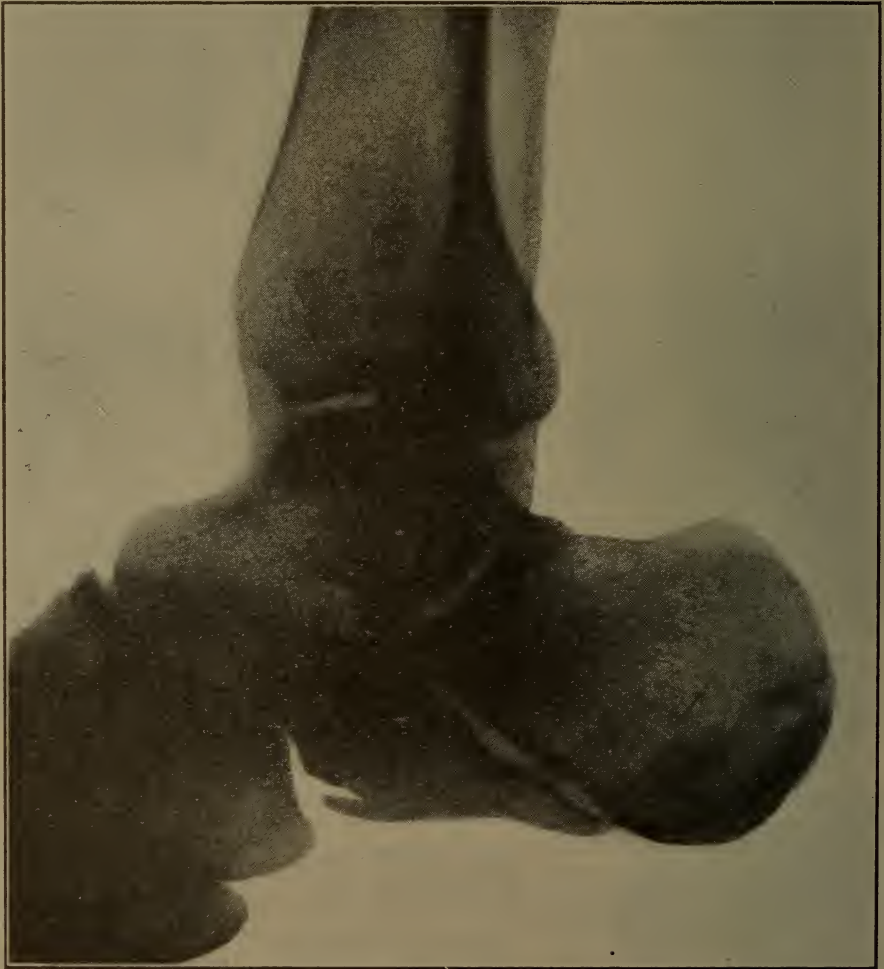

FIG. 215.—Fracture of os calcis; result of fall, landing upon the feet.

the fragments. The swelling of the ankle, the pain on pressure on the heel suggest the nature of the injury but only the X-ray can make a definite diagnosis. Fracture of the body usually calls

for enucleation because of the non-union which is the usual event and is accompanied by a persistent but low grade of arthritis. Fracture of the neck is more favorable under proper treatment which consists in prolonged immobilization in forced extension. Six weeks at least must elapse before any weight is borne. It is essential that this condition be not mistaken for a sprain.

Fracture with displacement may give rise to various deformities but the most common is lateral dislocation of the foot. Its inner

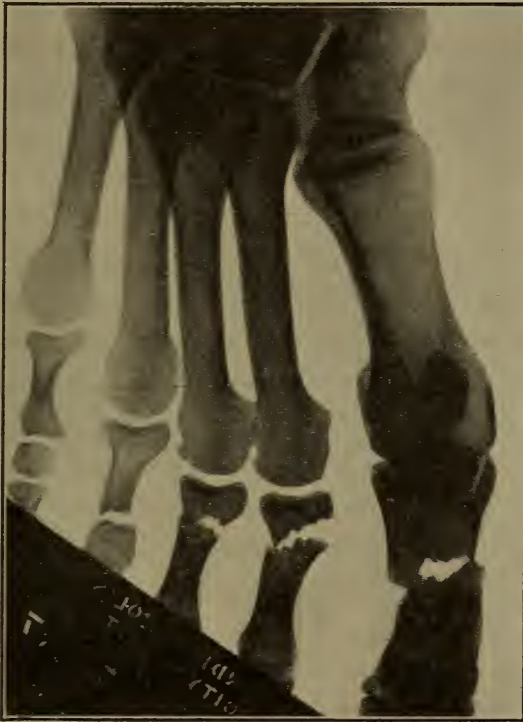

FIG. 216.—Fracture of phalanges of the foot.

border is markedly curved, the outer malleolus projecting and the dislocated fragment palpated in front or behind the joint. Under such circumstances an open operation is indicated with the purpose of replacing the fragments or performing a partial or complete astragalectomy, and in this latter the operation will usually terminate.

Fracture of the *os calcis*, due to falls, the patient landing on his feet, produces an impaction which flattens and widens the heel and lowers the malleoli. The pain, swelling and disability are con-

stant but an accurate diagnosis can be made only by the X-ray (Fig 215).

The prognosis depends in some degree upon the line of fracture, but on the whole the outlook is bad.

Prolonged rest, massage, hot baths, etc., may eventually overcome a large part of the lameness but under certain circumstances an operation with readjustment and suture of the fragments will produce an excellent result.

Fractures of the bones of the *toes* require much longer immobilization than corresponding fractures in the hand (Fig. 216). The deformity and callus formation may produce points of pressure that become serious impediments. These fractures should therefore be treated with circumspection.

CHAPTER XV

COMPOUND FRACTURES

It were perhaps better at once to proscribe the ancient term "Compound" as applied to open fractures; but after all it conveys an idea of duplication of traumatisms. And it is only within a recent period that a compound fracture did not mean also an infected one.

Thanks to antiseptics, most open fractures at this time, progress toward repair as rapidly as the closed.

But these open fractures require a particular care, and without appropriate treatment, are as prone to give rise to dangerous complications as in former times. The outcome in a given case depends largely on the *first treatment*. The indications are various, determined by the amount of fragmentation, the degree of destruction of the soft parts, the injury to the blood vessels and, based upon these factors, several clinical groups may be distinguished.

I. *Compound Fracture, Small Skin Wound; no Injury to Blood Vessels.*—The first point to be determined is whether the skin lesion communicates with the bone lesion. Often a fragment of bone projects; in other cases an undue amount of bleeding suggests perforation of the soft parts. In any event, the wound must not be probed and if there is doubt the fracture must be regarded as open. The treatment is simple and exact. Cover the wound and proceed to paint the field with iodine. Wait five to ten minutes for the solution to penetrate the skin and then proceed to sterilize the wound itself, injecting it with iodine from a medicine dropper and subsequently, if the size of the opening permits, wipe it out with a gauze swab saturated with iodine. A sterile dressing is applied and from this point the fracture is treated as if it were closed, and appropriate splinting employed.

II. *The Wound is Large, the Bone Exposed and Soiled.*—In this case, under general anesthesia, the wound must be freely enlarged and the ends of the bone, as well as the soft parts, painted with iodine. If every angle and corner of the wound and the bone is

particularly and carefully cleaned with the solution, infection is only remotely probably. The bones are to be adjusted, fixed with a bone clamp if the apposition is difficult to maintain, the muscle and fascia sutured without drainage, and the skin wound with drainage.

Some form of splint is applied which will readily permit inspection of the wound, and the bone clamps removed. The dressing must be ample.

III. *Large Wound, much Crushing of the Soft Parts, much Fragmentation.*—The principle of antiseptics is the same as in the previous case, but the disposition of the fragments presents a new problem. It is best, we think, to proceed in this wise: Sterilize the skin and other soft parts with iodine, enlarge the wound, sterilize the bone fragments with the iodine and then douche the cavity with hot normal solution until all the clots and débris are removed and all the oozing checked. Next proceed to restore the outline of the bone, replacing the fragments as nearly as possible in their normal relations, suturing them to the main body of bone with chromic gut or securing them by bands of the same material, encircling the shaft.

These cases are better drained for the first two or three days after which, if there are no signs of infection, the drain should be left off.

Formerly, it was the practice to discard the fragments of bone. If infection can be avoided or reduced to a minimum the fragments will live and add greatly in restoring form and function. Even if the periosteum is denuded, the fragments, though destined to be absorbed, will serve as scaffolding for the new bone cells, greatly promoting osteogenesis.

IV. *Extensive Fragmentation, Extensive Destruction of the Soft Parts, Obliteration of the Principal Arteries.*—In such cases it is the part of wisdom to amputate. Occasionally the limb may be saved but the attempt exposes to an infection that may cost the patient his life. The recovery of a useful limb in these circumstances is so rare as scarcely to justify assuming the septic risk.

V. *Infected Compound Fracture.*—If infection occurs by reason of no treatment, or unsuccessful treatment, the temperature rises, the limb swells, the pain augments—in short, the local and constitutional signs and symptoms of infection supervene. These must be

watched for in every case, and the patient kept under close surveillance.

Once infection manifests itself, the wound must be opened, removing the sutures if necessary, and the wound irrigated with peroxide of hydrogen. Oftentimes it is only the skin wound which is infected and the deeper levels of the wound should not be disturbed until it is certain they have been invaded.

Even if the bone itself is involved an excellent result may still be obtained, provided the splinting is efficient, the drainage ample, and the general treatment sensible.

So much cannot be said if the infection is from the *gas bacillus*. This extremely dangerous form of sepsis develops usually the second or third day and is preceded by pain in the wound, out of all proportion to its apparent seriousness. The wound looks red and angry and exudes a bloody, fetid serum; presently the limb begins to swell, the skin is crepitant, and blebs form. These manifestations extend with the greatest rapidity, accompanied by grave constitutional manifestations which end in death in twenty-four to seventy-two hours. The diagnosis must be made at the very beginning of the process if the treatment is to be of any use. Severe pain, an unexpected rise in temperature the first days should put one on his guard and at the first appearance of crepitation in the skin an amputation well above the infected site must be performed. If the case is untreated or if the treatment is ineffective the progress of the disease is extremely rapid although there is nothing else characteristic of this form of toxemia.

A workman was brought to the City Hospital with a compound fracture of the lower end of the radius. The injury was twenty-four hours old. The wound was cleansed, the fracture splinted; but the patient suffered extremely, out of all proportion to his injury; his temperature began to rise and at the end of the second day it was clear that a gas bacillus infection was under way. He understood no English, but an interpreter explained that he must loose his arm or his life. He chose the latter. At the end of the third day the arm and shoulder were immensely swollen, the skin crepitant and covered with blebs and a few hours later he died in great agony.

An almost identical injury occurred in a fall from a cherry tree.

The signs of the infection promptly developed, the end of the bone having been covered with soil. The patient, a middle aged woman, consented readily to amputation at the shoulder. The flaps were left open and packed with gauze saturated with peroxide. She made an uninterrupted recovery.

In the young and healthy patient in the very early stages of the disease a more conservative treatment may succeed. Multiple deep incisions, packing the wounds with peroxide gauze or injecting the

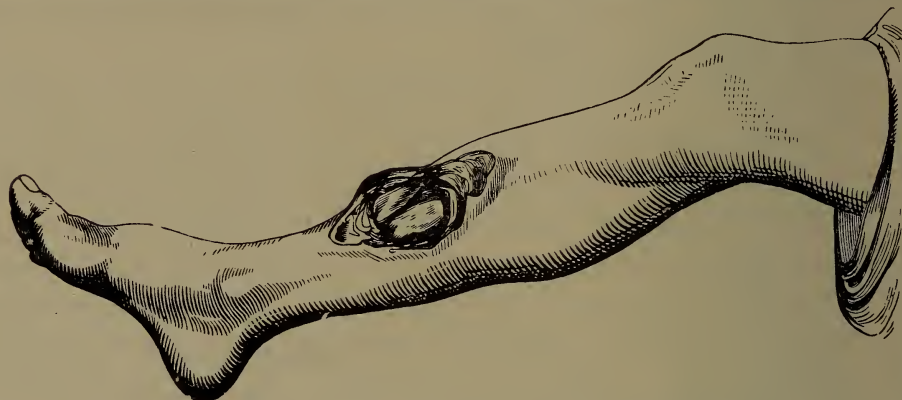

FIG. 217.—Compound fracture of tibia. (Moullin.)

soft parts above the level of infection with the peroxide. Finally the danger of *tetanus* is to be emphasized and in every case of compound fracture which has not been treated from the first in the manner described, a prophylactic dose of antitetanic serum should be administered.

COMPOUND FRACTURE OF THE TIBIA

These are by far the most frequent and require a special attention both that infection may be avoided and that the limb's functions may be preserved. (Fig. 217, 218) The tibia is so near the surface and the line of fracture is so likely to be oblique, producing sharp points of bone, and displacement is so common; these facts explain the frequency of open fractures of the tibia.

The antisepsis in these cases presents no special feature; the chief problem is in maintaining coaptation. If the fracture is oblique or the bone much splintered, it is best to proceed in this manner; after cleansing both outside and inside the wound with iodine, enlarge

the wound freely, clean out all the clots and débris. The amount of injury to the soft parts is often surprising. Expose the bone sufficiently to secure an accurate coaptation of all the fragments. Now apply a bone clamp in order to force the bones into intimate contact and to hold them in that position until the dressing is applied.

Before beginning the operation, have fifteen layers of crinoline cut from a pattern for a posterior splint and saturated with dry plaster of



FIG. 218.—Compound comminuted fracture of tibia and fibula.

Paris. The dressing having been applied to the wound in such manner as not to interfere with the removal of the clamp, the posterior splint is soaked and then molded to the leg and fixed with a few layers of roller plaster. In the course of fifteen minutes the plaster is hardened and the clamp may be loosened and removed. Interrupted sutures placed but not tied can now be tightened and an additional cover of gauze applied to the wound.

Usually there is considerable oozing for the first few hours, necessitating frequent change of dressings, the best form of which is gauze saturated with alcohol, this covered with absorbent cotton and the whole firmly bandaged. With a properly applied and effective splint the limb can be handled and the dressings changed with but little difficulty. Special care must be taken to prevent soiling of the plaster splint since changing this short of two weeks may result in recurrence of some displacement. Mild infection may occur but is easily managed on general principles. Our results by this method have been excellent.

COMPOUND FRACTURE ABOUT THE ANKLE AND FOOT

Fractures of this variety are frequent; always serious; and the prognosis more or less uncertain, depending upon the degree of infection and destruction of the soft parts.

Suppose a fracture of the inner malleolus; the soft parts are widely separated, the joint cavity exposed, the astragalus dislocated. Such an injury must be as conservatively treated as an abdominal wound. Under no circumstances must the wound be explored with unclean fingers or without careful cleansing of the field. Only after all the preparations for definite treatment are made is the wound to be examined. If transportation is necessary, a temporary splint is provided, but at least do not cover the wound with a dirty handkerchief. If there is much hemorrhage, circular constriction of the leg about the knee will temporarily suffice.

The first dressing will determine the future of the limb, perhaps even the life or death of the wounded. The whole foot and the lower half of the leg are most carefully disinfected and the fracture and joint cavity swabbed with iodine, enlarging the wound if necessary to expose every nook and corner in order to wipe out foreign bodies, splinters of bone and clots of blood. In this case, merely chosen for example, the destruction of tissue is usually slight. After the cleansing, replace the parts, leave one or two drains in the partly sutured wound, bandage amply and place the limb at rest.

The situation is less simple where there is much destruction of tissue, as in the case where the ankle is crushed.

Begin with hot irrigations of normal salt solution. Do not fear to enlarge the wound freely. It is of great importance that one be able to determine definitely the conditions in the wound and to see what he is doing.

You may find large fragments deformed and overlapping. Try to replace them and often you will be thus enabled to restore the contour of the joint. To retain these fragments, wiring or nailing the fragments will often be an almost indispensable aid.

Another case: The epiphyses are reduced to fragments of various sizes and forms. In irrigating, they flow away with the solution, so loosened are they. The rest hang by a mere shred.

Reposition is here useless. The wreck is too great. You must proceed to do an *atypical resection*. Do your best to spare the malleoli or at least two processes which will serve to prevent lateral dislocation when the joint is healed.

After this operation insert two drainage-tubes, one on either side; and if there is considerable oozing, add an aseptic tamponade.

The prognosis is worse if *infection has developed* and there is fever, redness, and swelling in the limb. Amputation will be the measure of last resort and yet do not amputate until free opening has again been tried. Irrigate with peroxide. The removal of dead bone, etc., is followed by deep drainage but this must be done without delay. It is not union, or consolidation, or function of the limb which is the chief concern. It is infection against which all the forces of antisepsis are marshalled.

Osteomyelitis is the contingency feared. In such a case, do not employ a typical amputation or resection, but an atypical one, removing only such tissues as must be removed, and later when the infection has disappeared, the necessary operations may be done. For additional remarks on treatment of compound fractures see *Gunshot Fractures* (page 155).

CHAPTER XVI

FRACTURE OF THE CLAVICLE, SCAPULA, RIBS, SPINE, PELVIS

Fractures of the *clavicle* formerly occurred more frequently than any other, but are not now so frequent. One-half of the cases are in children. The break very much more often occurs in the middle third, occasionally in the outer third, but rarely in the inner third. In the middle third, the inner fragment overrides the outer, the re-

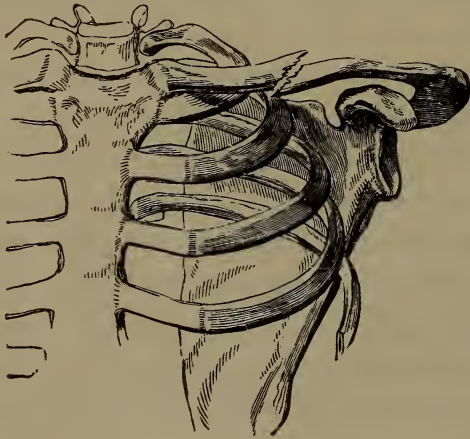


FIG. 219.—Fracture of clavicle. Inner fragment lifted upward by sterno-mastoid. (*Moullin.*)



FIG. 220.—Velpeau's bandage for fractured clavicle. (*Stewart.*)

sult of the action of the sterno-cleido-mastoid and the muscles that pass from the thorax to the humerus, and the weight of the shoulder (Fig. 219).

The patient leans his head toward the injured side and supports the elbow, the position of greatest comfort. The nature of the accident, the pain, deformity, crepitus, and mobility determine the diagnosis.

Reduction.—Seat the patient on a low stool; direct the assistant to stand behind and to grasp the patient's shoulders, steadying the sound one with one hand and lifting the injured one *upward, back-*

ward, and outward. At the same time the operator stands in front, helping move the shoulder; and, by pressure and manipulation of the clavicle between finger and thumb, molds the broken ends into place.

The reduction is complete when the injured shoulder is as long as the sound one, measuring each from the sterno-clavicular joint to the tip of the acromion, landmarks which can always be defined. Feel along the injured clavicle for any irregularities. Apply the dressing. (1) If the patient is to be kept in bed for other reasons

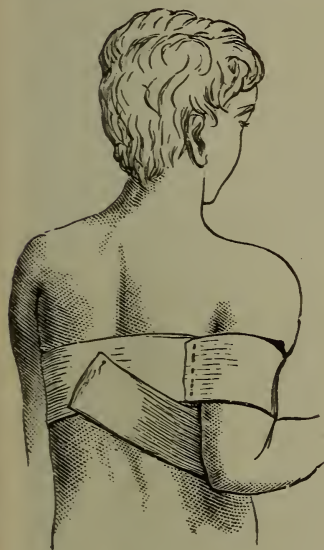


FIG. 221.—Sayre's dressing.
First stage. (Moullin.)

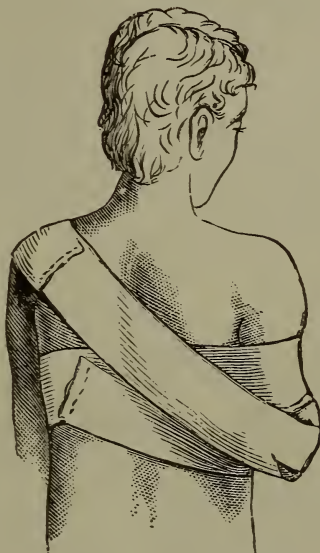

FIG. 222.—Sayre's dressing completed. Posterior view. (Moullin.)

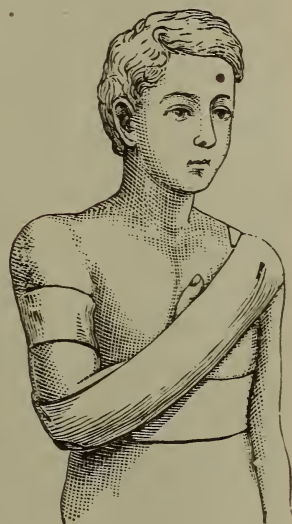

FIG. 223.—Anterior view. (Moullin.)

than the clavicular fracture, it will be sufficient to keep him on his back with a small pillow between his shoulders and with the hand lifted to the chest.

(2) Any bandage or dressing which draws the shoulder upward, outward, and backward, and holds it in that position will serve. Of the dressings, a number are especially recommended, among them, the Velpeau type of bandage (Fig. 220). They need to be applied for three or four weeks.

In ordinary practice, the Sayre's dressing is excellent. The essentials are two adhesive strips 3 inches wide and long enough to go once and a half about the body, absorbent cotton, roller band-

ages. Begin by fixing the end of one adhesive strip loosely about the injured arm just below the armpit. The loose end carried around the body will pass over the lower ends of the scapulæ. Before completing the turn about the body, place layers of cotton wherever the cutaneous surfaces are to be in contact. The turn of the adhesive strip about the body is completed. This holds the shoulder in the backward and outward position (Fig. 224). The hand is drawn across the chest toward the sound shoulder and the second adhesive

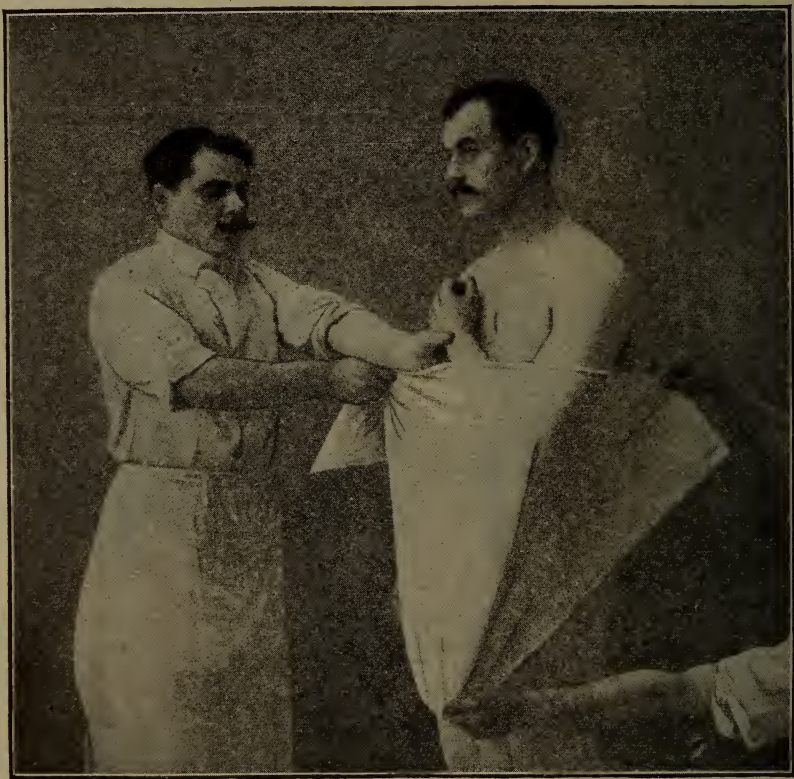


FIG. 224.—Mayor's sling. First stage. (*Lejars.*)

strip is applied. Fix one end over the sound shoulder and pass it across the back to the elbow (Fig. 222). It covers the point of the elbow and follows the arm across the chest to the starting-point (Fig. 223). It is designed to lift the shoulder upward. A few turns of roller bandage around the chest lend additional support and complete the dressing.

Romer describes a method of dressing with adhesive strips which does not require the arm to be fixed to the side (*Lancet*, London,

March 31, 1909). Three strips of Z. O. plaster, each an inch and a half in width, should be applied from a point immediately above the nipple, passing over the clavicle to a point below the angle of the scapula. The middle strip should cover the site of the fracture and should be first applied, the lateral ones overlapping it. The strips should be firmly applied while the fragments are kept in apposition.

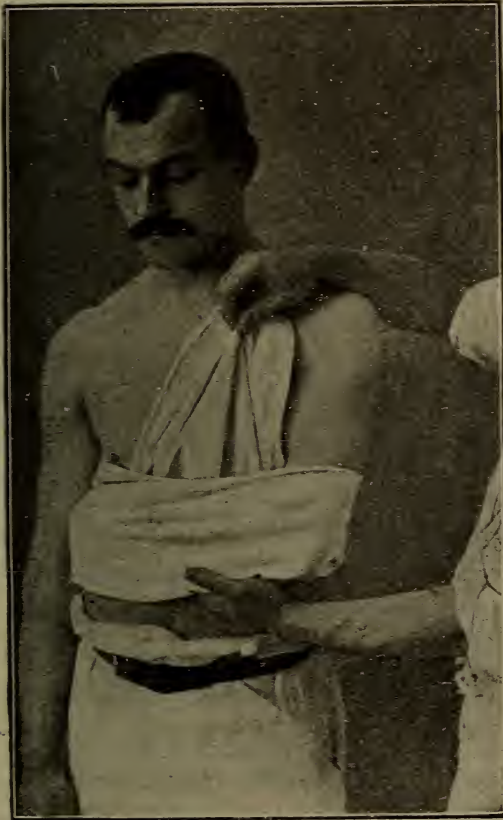


FIG. 225.—Mayor's sling. Second stage. The bandage is molded snugly to the arm. (Lejars.)



FIG. 226.—Mayor's sling completed. (Lejars.)

The scapula may be steadied by a strip crossing its lower angle laterally. The arm is to be carried in a sling.

Mayor's sling serves an excellent purpose here as well as in certain injuries to the arm. It is applied in this manner:

Take a square of strong, unbleached muslin, or similar material, large enough to reach easily about the body; fold it into a triangle.

The elbow having been flexed to an acute angle and the hand carried toward the sound shoulder, the bandage is carried across the flexed arm and around the chest, its upper level being just below the level of the axilla (Fig. 224). The two points are fastened behind with a safety-pin or tied.

Now turn the third point of the triangle upward between the flexed arm and the body, and carry it up over the shoulder of the injured side (Fig. 225). Mold the bandage well, so that it fits and supports the forearm snugly. The dressing is completed by bands crossing over the shoulders and connecting the anterior and posterior parts of the bandage after the manner of suspenders (Fig. 226).

FRACTURE OF THE SCAPULA

These fractures are comparatively rare, about 1 per cent. of all fractures.

The body, the spine, the acromion process, the coracoid process may be involved and the fracture is usually due to direct violence.

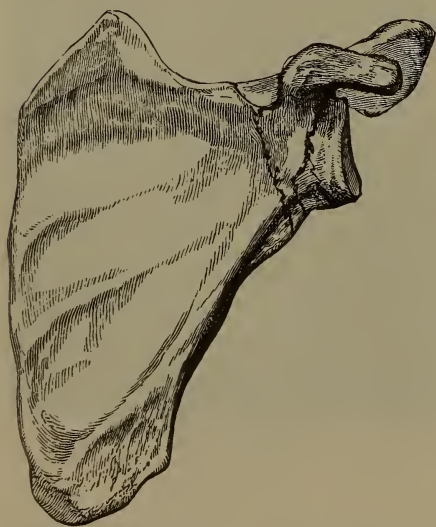


FIG. 227.—Fracture of the neck of the scapula.

The X-ray will often be necessary to locate the lesion definitely although the pain, tenderness, and perhaps crepitation will determine the presence of some kind of fracture. In the case of the acromion process the functions of the deltoid are disturbed; in the case of the coracoid, the biceps and pectoralis minor. Respiration may be painful by reason of the pull on the latter muscle.

The action of these muscles must be considered also in instituting treatment. It is sufficient usually to fit the arm in a sling and immobilize the scapula by adhesive strapping.

Fracture of the neck (Fig. 227) is of importance because it may be mistaken for fracture of the surgical neck of the humerus but in such

a case the head can be felt to rotate, which it would not do in dislocation. The deformity disappears on lifting the arm forcibly upward with the elbow flexed, which does not happen in a case of fracture of the humerus; the arm hangs vertically at the side and is mobile. There is no notching of the deltoid.

In the case of fracture of the surgical neck of the humerus with overriding, the arm is shortened. In case of fracture of the scapular neck, the arm is lengthened.

Generally speaking, the diagnosis of any fracture of the scapula is to be made from crepitus, abnormal mobility, local tenderness, and more or less complete loss of certain functions. Begin the examination by inspection and measurement. Note any loss of contour; any lengthening or shortening of arm. To elicit crepitus, apply one hand to the body of scapula and with the other make traction on the arm. In thin subjects the lower end of the scapula may be readily grasped.

Treatment.—The flexed elbow should be well supported by a sling, and the arm fixed at the side. Massage will relieve the pain and hasten repair. Mayor's sling furnishes an excellent dressing.

FRACTURE OF THE RIBS

Fractures of the ribs occur most frequently between the fifth and ninth, and are usually single and without displacement. If the violence is sufficient to break a number of the ribs simultaneously, it may cave in the chest wall; and, by perforation of the lung, produce emphysema, hemoptysis, pneumothorax. Pain and crepitus point to the presence of fracture. Detect crepitus by laying the palm over the site of the pain or by the stethoscope.

Slight displacements may be reduced by making pressure over the site of fracture during inspiration, or perhaps by compressing the chest from front to back between the two hands. Apply adhesive strips 2 inches wide over the injured side, beginning at the scapula, and following the course of the ribs around to the sternum.

Three or four strips may be necessary, and they must be applied at the end of expiration.

The pain will almost always be relieved by such immobilization

of the chest wall. Those fractures which involve the viscera are considered with injuries of the thorax.

FRACTURES OF THE VERTEBRA

Fractures of the vertebra derive their chief importance from the accompanying injury to the spinal cord and are serious in proportion to the amount of injury to the cord, ligaments, and tendons.

Aside from local pain and deformity, the symptoms are such as arise from compression or laceration of the cord and vary somewhat, depending on the particular portion of the cord involved. Fractures

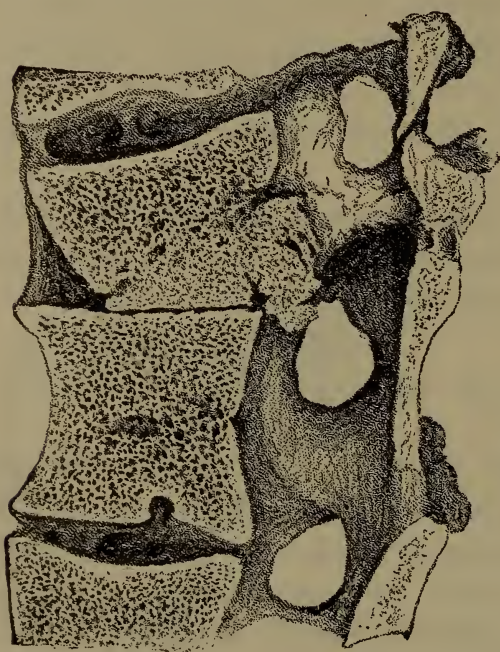


FIG. 228.—Fracture of vertebra. (Moullin.)

of the cervical vertebra are at once the most common and fatal. Fractures in the lumbo-dorsal region occur next in frequency. The break which usually involves the body of the vertebra, but may include the lamina or transverse or spinous processes, is generally due to forced flexion. Along with the fracture the ligaments are lacerated, the muscles torn, the vertebra displaced and the blood vessels opened. There may be present paraplegia and disturbances of the functions of bowel and bladder; and in addition to these symptoms

there are certain others which are common to fractures of the vertebra wherever located, such as pain, tenderness to pressure and motion. Occasionally one will find deviations and angular deformities (Fig. 228).

The *prognosis* in a well-defined case is always bad, although by no means always hopeless.

The *emergency treatment* is limited generally to transportation and securing the proper bedding. The patient must be handled with the

greatest care. Sometimes the least added pressure on the cord by the movements of the spine may produce immediate death.

The bed must be uniformly soft and smooth. A water bed is ideal. If the symptoms of compression are urgent, it is necessary at once to make an effort to reduce the fracture by simultaneous traction and pressure. While the assistants pull on the head and feet, the doctor attempts, by pressure, to correct the deformity. There is some danger of a fatal asphyxia where the fracture is high, in making these manipulations, as the patient is turned on his face and the movements of the diaphragm may be interfered with. Laminectomy is not to be considered when the indications point to complete crushing of the cord. In other cases where the pressure symptoms are obvious, a laminectomy should be done with delay. (See Wounds of the Spine.)

FRACTURE OF THE PELVIS

Fracture of the pelvis may be suspected from the character of the injury, which is usually a fall or a crush. The diagnosis is to be confirmed by external palpation of the ilium, pubes, and ischium on each side, and by careful rectal and vaginal examination. Disturbance of normal relations, tenderness on pressure, crepitation perhaps, and difficulty in walking indicate fracture (Fig. 229).

The prominence of the symptoms will depend in some degree upon the amount of displacement.

The X-ray of course will be used whenever available.

The treatment in the uncomplicated cases is simple. Usually nothing can be accomplished in correction of the displacement and simple rest in bed with adhesive strapping represent the elements of relief. Two recent cases in the City Hospital treated in this manner recovered in six weeks. It is quite different if there are complications.

If a catheter cannot be passed (and this should always be tried), it will be necessary to do an external urethrotomy for the ruptured urethra. If the catheter finds the bladder empty and ruptured, a laparotomy is imperative. If the exact complications cannot be determined and yet shock, pain, and increasing abdominal tension,

with signs of sepsis, point to a lesion of bladder or rectum, the abdomen must be opened, and the visceral injury found and repaired.

A woman was brought into the City Hospital the victim of an automobile collision. She was in full shock and the pelvis was plainly disarranged. The shock improved a little but the pulse remained rapid and weak. A catheter brought only a little blood from the bladder. A laparotomy showed the bladder to be greatly

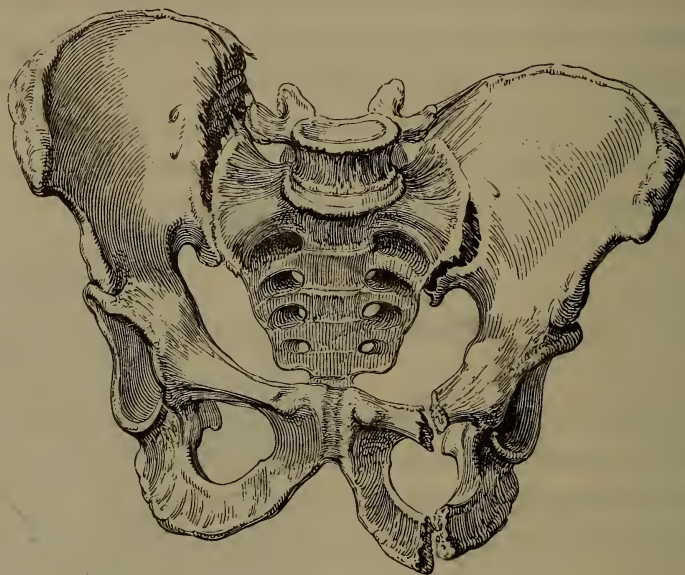


FIG. 229.—Fracture of the pelvis through the obturator foramen and dislocation at the sacroiliac joints. (Moullin.)

contused, but not torn and there was much blood in the cellular tissues around; a large hematoma had formed under the pelvic peritoneum. Suprapubic drainage was applied but the patient lived only a few hours. Shock, the hemorrhage, and beginning infection were beyond the limits of her resistance.

Following a variety of traumatisms there is often a condition now well recognized as *relaxation of the sacroiliac synchondrosis* which simulates fracture and which may become quite chronic. It is relieved by adhesive strapping.

CHAPTER XVII

FRACTURES OF THE SKULL AND FACE

Fractures of the skull are important practically only from the point of view of their complications, which number three; *infection*, *hemorrhage*, and *injury to the brain*.

In a given case, one or all of these complications are possibilities, although for the development of each, certain combinations of circumstances are peculiarly favorable.

With respect of these variations, fractures of the skull are of two classes: fracture of the base and fracture of the vault. Each has its special symptomatology and prognosis, though the one may merge into the other and the clinical picture be more or less blurred.

Either may be fissured, fragmented, or compound, with or without depression. *In either the immediate gravity depends upon the nature and extent of the injury to the brain, and fractures of the base are the more serious, merely because the more important areas of the brain are there.*

With regard to the remoter consequences also, fractures of the base are less favorable; hemorrhage and its resultant complications are more to be feared; and infection is a more certain eventuality owing to the communications opened up between the cranial cavity on the one side and the ear, the nose, or the pharyngeal region on the other.

The symptoms in either kind of fracture are such as arise from concussion, compression, or laceration of the brain and are general or focal, that is to say, emanating from certain cerebral areas.

FRACTURES OF THE BASE

Fractures of the base of the skull are more frequently indirect, the force being transmitted through the spinal column from some part of the vault or the ramus of the jaw; occasionally direct by a thrust

through the mouth, a blow on the root of the nose, or upon the mastoid process.

Any or all of the fossæ may be involved. Fracture through the middle fossa is most frequent, and the most serious is fracture through the posterior fossa. These fractures are usually linear because the force is indirect and because there is only one determinable table instead of two, as in the vault.

These fractures are nearly always compound, which adds to the gravity of the prognosis. The external meatus, the nasal cavities and the naso-pharynx are all prolific sources of meningeal infection.

The *diagnosis* is usually by inference, often impossible. There are certain symptoms always suggestive of fracture at the base, but not to be relied upon exclusively.

Ecchymosis in the tissues about the orbit, or hemorrhage into the sclerotic, appearing first some little time after the injury, and gradually progressive—fracture through the anterior fossa suggests itself. Persistent bleeding from the nose following head injury must be given due consideration. Bleeding from the external meatus, copious and persistent, suggests fracture through the middle fossa. Late ecchymosis over the mastoid or into the tissues of the back of the neck suggests fracture through the posterior fossa. The discoloration follows the posterior auricular artery. However, these hemorrhages must not be mistaken for local rupture of mucous membrane or other soft parts and their absence does not necessarily mean absence of fracture.

The bleeding, if intra-cranial, may come from rupture of the middle meningeal, or the internal carotid, or the sinuses. Instead of the bleeding, or accompanying it, there may be escape of *cerebro-spinal fluid*. Its presence is pathognomonic of fracture of the skull, and it must be distinguished from ordinary serum and the fluid of the middle ear by these characteristics: the flow begins at once and continues for several hours; the quantity is considerable, sometimes a tablespoonful in fifteen to twenty minutes; the flow is temporarily increased by the increase of intra-cranial pressure, sneezing, coughing, and vomiting; alkaline in reaction; contains only a trace of albumin and is rich in sodium chloride.

Useful in definite diagnosis are the paralyses of the cranial nerves.

Recall their origin, course, and functions. The facial, optic, and tri-facial nerves are especially likely to be involved. For example, the optic nerve will be involved if there is a fissure of the optic canal. Vision may be lost totally and immediately; even though total at first, the blindness may gradually pass away. It will be impossible for some time to say whether the recovery will be permanent. Added to these nerve symptoms, but not particularly helpful in the diagnosis of fracture, may be those of concussion, compression, or laceration. All these conditions may exist with or without fracture.

The *treatment* has two ends in view, the prevention of further irritation of the brain and the prevention of infection.

Keep the patient absolutely quiet in bed with the head elevated, apply ice-bags, and keep the bowels open.

Whenever fracture of the base is even merely suspected, carefully wipe out the external meatus and pack lightly with sterile gauze. Do not syringe the meatus or at least only very gently, lest infection be forced through the fissure.

Remove the gauze as often as it becomes soaked with blood, which may be at frequent intervals for several days. Spray the nose and throat with peroxide of hydrogen or a similar mild antiseptic. These regions cannot be sterilized, but bacterial activity may be minimized. Do not pack the nares except for persistent nasal hemorrhage, as the packing irritates the mucosa and unduly stimulates secretion, and this is undesirable. Again, such packing may excite a sneeze which by its explosive effect may carry infection through the fissure to the meninges. If packing is deemed necessary, pack with sterile gauze saturated with sterile vaseline. In the great majority of cases, *active intervention* is quite out of the question either for the relief of infection or for hemorrhage. But this is true merely because the technic is not definitely worked out. The principle of drainage for infection and removal of compressing clots applies with as much force here as in fractures of the vault (see Craniectomy).

FRACTURES OF THE VAULT

Fractures of the vault of the skull may be fissured, comminuted or compound, any one of which may be complicated by concussion, compression, contusion, or intra-cranial hemorrhage. The symp-

toms belong to the brain complications rather than to the fracture itself.

Simple, fissured fracture without depression is practically impossible of diagnosis. The diagnosis is easier if depression is present, and yet certain injuries to the scalp simulate fracture with depression. A blow crushes the soft tissues and around the crushed area marked swelling ensues. The sensation to the examining finger is that of a depression of the bone. Do not be misled.

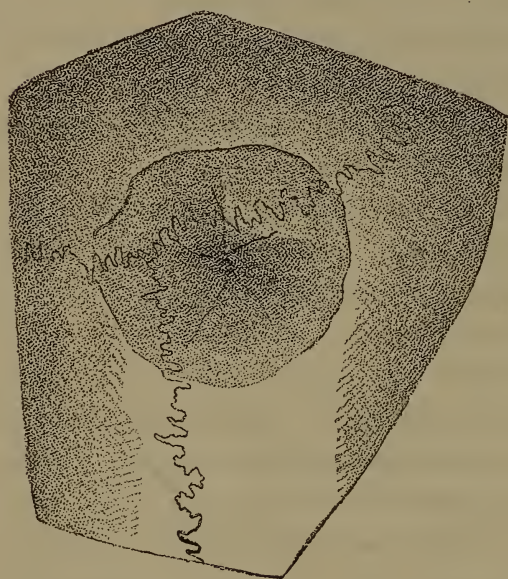


FIG. 230.—Fracture of outer table from impact of a hammer. (Moullin.)

Comminuted fracture of the skull even without depression is generally diagnosed, and yet a hematoma may mask the fragmentation. Be on your guard in that matter.

The inner table is always more injured than the outer (Figs. 230, 231).

The prognosis is good and the treatment simple in fissured fracture without depression and without symptoms indicating compression.

Put the patient to bed, keep the bowels open, limit the diet, and await developments. Un-

interrupted recovery usually follows, yet the exceptions to this rule are not infrequent and one must be on his guard for intra-cranial hemorrhage. Or later, there may develop symptoms which are explainable only on the hypothesis of contusion of the brain.

If at any time symptoms arise indicating the occurrence of hemorrhage, say from a rupture middle meningeal, immediate intervention is indicated. Some surgeons go so far as to recommend trephining for every fracture of the skull and exploratory operation in every suspected case, but that seems at the present time too radical, especially for the general practitioner left to his own resource.

If the fracture is comminuted or even only fissured, with depres-

sion, the chances are so great that there is an injury to the brain that even with no symptoms present, immediate operation is indicated. (See Urgent Craniectomy.)

COMPOUND FRACTURES OF THE VAULT

Much more serious from every point of view are the *compound* fractures of whatever origin. The constant element of danger is *infection*. Add to this concussion, contusion, or laceration of the brain, and the outlook is grave indeed. The treatment is not so simple, but its purpose is quite definite, viz.: to prevent infection.

This is accomplished not by keeping the bacteria out of the wound—they are already in; not by destroying them with strong antiseptics, as these are too injurious to the brain tissues, but rather by removing the conditions favorable to bacterial growth.

To this end operation is imperative. As in gunshot fractures, enlarge the wound, remove extraneous matter, elevate depressed fragments, check the hemorrhage and remove clots, trim away devitalized tissues and provide drainage (*See Craniectomy*). Careful attention to these details results in the starvation of the germs present, with the result that repair proceeds.

Skill in diagnosis, prognosis, and treatment in fracture of the skull depends upon a clear understanding of the mode of causation and the symptoms of *contusion, compression, and concussion* of the brain.

Although presenting quite a diverse clinical picture, separately considered, these three conditions are nevertheless of the same origin fundamentally. They are each merely a complex of symptoms expressing, on the one hand, varying degrees of either functional

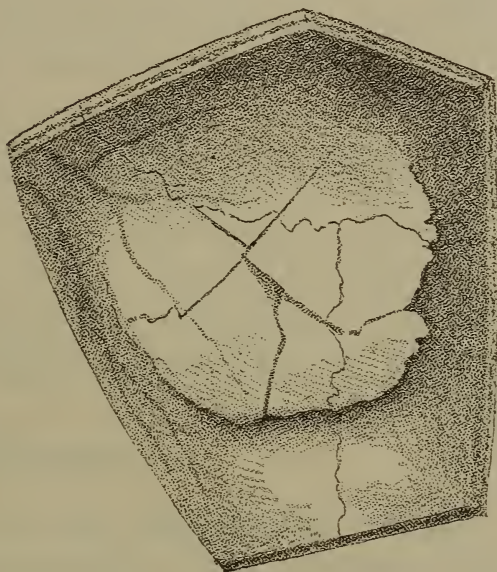


FIG. 231.—Same; fracture inner table. Note greater comminution and depression. (Moullin.)

depression or stimulation of the cortex of the brain or, on the other, of the deeper centers of the cerebrum and medulla. The cortex is the seat of consciousness and at the same time the most sensitive part of the brain; therefore it is the first to be affected by conditions disturbing the circulation of the brain.

The deeper centers, those governing respiration and circulation, are not so readily affected. The result is that loss of consciousness is the first phenomenon following a general disturbance of traumatic origin. This trauma may not be sufficient to reach the cardiac and respiratory centers at first or at all; or it may only stimulate them; or finally it may paralyze them as well as the cortex. It must likewise be constantly remembered that stimulation of these basal centers means retardation of pulse and respiration; depression of the same centers means acceleration of pulse and respiration, and acceleration is an indication of approaching failure.

It is only by reference to these first principles that one may explain and reconcile the variations in the derangements of these functions of consciousness, circulation, and respiration in different cases.

CONCUSSION

This is in all probability due to a molecular disturbance of the brain substance, and is accompanied by neither microscopic nor macroscopic change. The disturbance may be (a) moderate, (b) severe, or (c) profound.

(a) The disturbance is *moderate*. Under these circumstances, the trauma diminishes the function of the cortex, but does not affect the deeper centers of the brain and medulla, so there is therefore only a fleeting loss of consciousness without any change whatever in the pulse and respiration.

(b) The disturbance is *severe*. The force depresses the cortex, but only serves to stimulate the deeper centers, and, as before, there is loss of consciousness, but there is this time slowing of pulse and breathing. Very soon the normal rate returns and a little later consciousness is restored.

(c) The disturbance is *profound*. The cortex is paralyzed and profoundly depressed as are also the deeper centers. The result

is loss of consciousness and this time rapid and weak pulse and shallow breathing which may terminate very shortly in death. In doubtful cases, then, the heart is the chief element in prognosis. The pulse immediately grows either worse or better.

Therefore the symptoms of concussion are distinctly fugacious. This is its chief criterion.

If the symptoms once improve and later recede, one may be sure the primary concussion is complicated by compression or contusion. Added to these phenomena of concussion, though not particularly helpful in diagnosis or prognosis, are certain other occasional symptoms, referable to the reflexes.

In the severe cases this will usually be the picture: At the moment of injury, unconsciousness occurs, immediate and complete. The patient is more than unconscious, he is anesthetized. The face is pale and sunken and the whole body cool. The pulse is small, rapid, and irregular. The temperature is subnormal. The breathing is shallow and sometimes sighing. The urine and feces may be retained or pass involuntarily. Repeated vomiting is quite common, especially as consciousness begins to return. Following the return of consciousness, a stage of excitement occurs. The symptoms of this stage are those of meningeal irritation, and in uncomplicated cases rapidly subside.

The *treatment* is quite definite. Disturb the patient as little as possible in getting him into bed. Lower the head at first and try to maintain the body heat with woolen blankets and hot-water bottles. Carefully stimulate the heart. To this end, apply a mustard draft over the heart and inject ether hypodermically or a 10 per cent. solution of camphorated oil. Repeat these injections frequently, being guided by the pulse. Von Bergmann recommends inhalations of ether for the very weak and failing pulse.

Do not forget *artificial respiration*. In those severe cases where the respiration is dangerously low, it will sometimes tide the patient over the danger-line.

In the subsequent stage of congestion, keep the head elevated and apply ice-caps if the dressings will permit. Keep the bowels open. If the excitement and restlessness are pronounced, morphin hypodermically is indicated.

COMPRESSION

Any condition, traumatic, inflammatory, or neoplastic, which diminishes brain room, may induce symptoms of compression of the brain. The symptoms and their course will vary according to the manner in which the pressure is produced.

What is said here applies particularly to the pressure symptoms originating in depressed fracture or traumatic hemorrhage, though much would apply equally well to the pressure of brain abscess or brain tumors, or meningeal exudates and similar conditions.

Pressure symptoms have fundamentally the same origin as concussion symptoms, that is to say, they are an expression of depression or of stimulation of the functions of the cortex and the automatic centers. In both there may be initial stimulation and terminal paralysis. However, this depression or stimulation is produced differently in the two conditions, concussion and compression.

In the first case, the disturbance of function is brought about by mechanical injury and in the second by interference with the blood supply. Sudden diminution in the circulation modifies the functional activity of the brain centers.

The cortex, the most sensitive, is first affected, followed by loss of consciousness. The automatic centers are next affected, at first stimulated, though each reacts differently; thus the respiratory center is the first to be stimulated and by the presence of carbon dioxide which was its primal stimulus. The vaso-motor centers are next invaded, and finally the vagal and convulsive centers.

In those cases where the circulation becomes gradually slower, the order in which these centers and areas are successively affected is as follows: the cortex, the corona radiata, the gray matter of the spinal cord, the pons, and finally the medulla. Now the symptoms originating in these various areas as a result of pressure are of two kinds:

(a) General or indirect.

(b) Focal or direct.

Each may manifest itself in two stages:

(1) Stage of stimulation.

(2) Stage of depression or paralysis.

It is the knowledge of these facts which enables us to harmonize and reconcile the diverse statements of various observers regarding the character and cause of the symptoms of compression. It is in the hemorrhage arising from the middle meningeal artery that the emergency surgeon is chiefly interested. Traumatic compression sufficiently serious to require immediate operation in nine cases out of ten originates in:

BLEEDING FROM THE MIDDLE MENINGEAL ARTERY

This may follow injury to the head with or without fracture. The fracture may or may not be diagnosed.

In a typical case the concussion symptoms which supervened immediately upon the injury disappear after a half-hour. The patient regains consciousness, and the pulse and respiration approximate the normal.

In the meantime, however, the blood from the torn meningeal is slowly oozing into the space between the dura and the skull, and the "free interval" is interrupted by headache, irritability, perhaps delirium (stimulation of the cortex). The epidural clot grows larger, the intra-cranial circulation is more impeded and complete loss of consciousness occurs (depression of the cortex). Coincident with this, the pulse grows slower and stronger, the respiration deep and stertorous (stimulation of automatic centers). A little later coma is profound, the respiration begins to fail, and the heart's action grows rapid, weak and irregular (depression of both cortex and automatic centers), and finally all the functions of the entire organ are suppressed and paralyzed, and death ends the scene.

Along with these general symptoms there frequently occur at various stages certain *focal* symptoms, monospasms, convulsions; monoplegia or hemiplegia.

Usually at the time the decision to operate is made, this will be the condition of the patient: He lies inert, unconscious, the pulse full and bounding, the respiration deep and stertorous, the skin hot and perspiring, the pupils irregular, usually dilated on the side of compression, partial or complete hemiplegia of the opposite side.

Treatment.—With a definite diagnosis once made, there is no

difference of opinion as to the treatment. It is *imperative to operate*, and to do so without delay. Every additional hour adds to the certainty of a fatality. The nature of the injury and the focal symptoms point to the site of the clot or the branch of the meningeal most probably involved.

By trephining, the clot is exposed, and removed, and the bleeding vessel discovered and ligated. (See Craniectomy.)

The pressure symptoms of hemorrhage from injuries of the sinuses are identical with those from meningeal bleeding except that they develop much more slowly and are likely not to be so typical. Hemiplegia is not always in the side opposite the clot.

FRACTURE OF THE SUPERIOR MAXILLA

Fracture of the superior maxilla occurs alone or with fracture of the malar or other bones of the face. It may be accompanied by splintering of the bone, caving of the antrum, loosening of the teeth, and disfigurement generally. The alveolar process may be broken off. If this is the case, it may be replaced without great difficulty.

Oftentimes little can be done to correct the deformity. The lower jaw can be used as a splint and very little force is needed to retain the fragments in position.

If the fracture is compound, the fragments should be treated conservatively. It is surprising how perfectly they may sometimes be repaired. The vascularity of both bone and periosteum favors this result.

With the jaw at rest, a liquid diet should be maintained, frequently cleansing the mouth with alkaline antiseptic fluids. Be on guard for fracture of the base of the skull.

FRACTURE OF THE MALAR BONE

Fracture of the malar bone seldom follows the suture lines. The whole bone may be dislocated in a direction corresponding to the force. In this manner, the violence may be transmitted to the superior maxilla, its sinus and infra-orbital canal, to the nose, the orbit, or to the base of the skull.

Uncomplicated fractures of the malar bones require little treatment. Compound fractures must be treated on general principles.

It may be possible to replace a depressed fracture of the zygomatic process by pressure through the mouth.

FRACTURE OF THE NASAL BONE

Aside from gunshot fractures (see page 190), the bones of the face suffer occasionally from direct violence.

The *nasal bones* may be fractured alone or in connection with the ethmoid. Bleeding is profuse and deformity apparent. On account of infection from either the outside or inside of the nasal cavity, inflammation and necrosis may be a sequela.

An attempt should be made at once to elevate the depressed fragments by pressure within the nasal cavity. The reduction may be both difficult and painful. General anesthesia may be necessary.

Check the hemorrhage by mopping the nasal cavity with a solution of adrenalin chloride, or pack temporarily with sterile gauze. Subsequently douche the nasal cavity frequently with glycothymoline or Seiler's solution to prevent infection.

FRACTURE OF THE INFERIOR MAXILLA

Fractures of the inferior maxilla occur most frequently just in front of the mental foramen, and are usually compound, opening into the mouth.

The deformity is determined chiefly by muscular action and the degree of obliquity.

The diagnosis is rarely difficult.

Reduction, which is indicated by a correct alignment of the teeth, may be accomplished by bimanual manipulation with the fingers of one hand in the mouth. This is usually easily done, the chief difficulty being to retain the fragments in position. The prevention of infection is likewise important (Fig. 232).

Oliver, of Indianapolis (Ind. Med. Journal, 1906), has described the mode of treatment most applicable in the emergencies of general practice. He recommends, as the result of his experience, that in

the ordinary case, when the patient retains the majority of his teeth, the upper jaw be used as a splint.

This is his procedure: before attempting reduction and without anesthesia, if possible, he begins by passing a loop of wire (soft iron wire, gauge 26 or 28) around the neck of the most available tooth behind the break in the lower jaw; a similar loop is thrown around the corresponding tooth in the upper jaw. Coming forward of the fracture the first solid tooth and its fellow above are both looped in the same manner.



[FIG. 232.—Fracture of lower jaw.
Temporary bandage. (Moullin.)

Next a similar loop is adjusted above and below on the opposite side of the jaw—on the sound side. Altogether six separate wires have been used. Each loop is now twisted down tight with a pair of pliers, so that the teeth are firmly encircled and the free ends of the wires left projecting from the mouth (Fig. 233).

Reduce the fracture as the next step. This is done by pressure and traction with the fingers inside and outside of the mouth.

Immobilize.—This is accomplished by twisting firmly together by means of the pliers the corresponding upper and lower wires, which brings the lower jaw into intimate contact with the upper.

Liquid diet sucked through the teeth.

Antisepsis.—Direct the patient to fill his mouth with the antiseptic fluid and to churn it vigorously backward and forth between the teeth. This washing should be done frequently each day, and especially after each feeding. If necessary, as additional support, a plaster-of-Paris or Barton's bandage may be applied.

The wires are left for three weeks, or longer in the severe cases, and after their removal a bandage should be kept on for another week. The patient should be supplied with a small pair of wire cutters and direct how to use them in an emergency, such as serious vomiting which might result in asphyxia.

As Oliver observes, this formula may be varied to suit the individual case. The many forms of splints need not be here considered. The cases of special difficulty in reducing and retaining, those which are compound and those in jaws practically edentulous, require wiring. This is an operation simple in theory, but more difficult in practice.

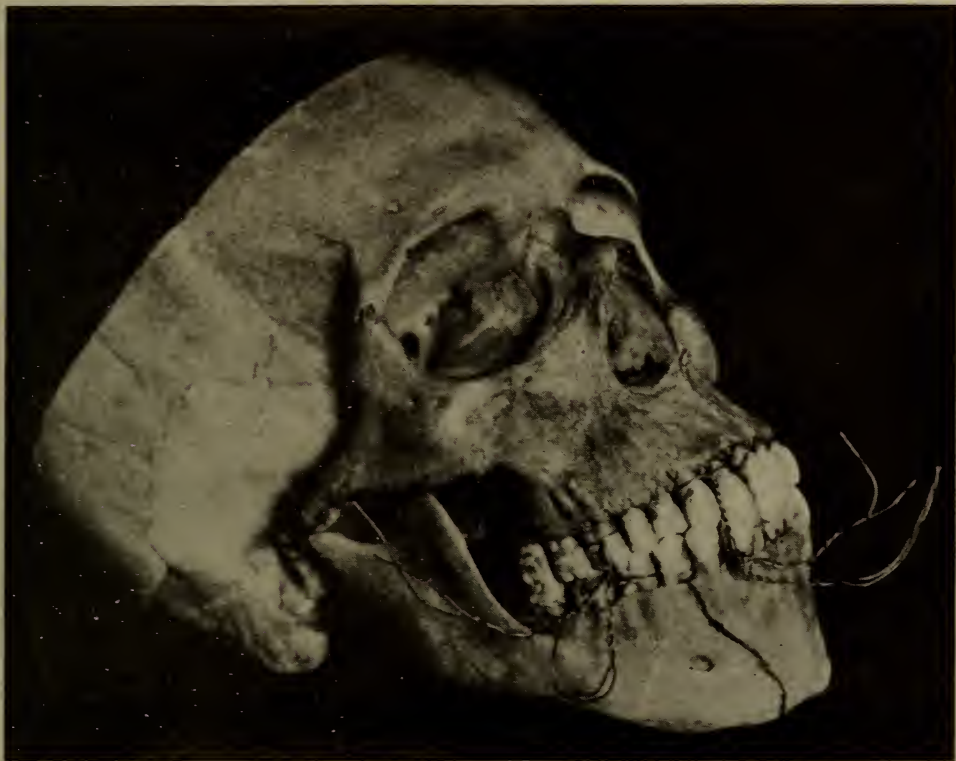

FIG. 233.—Wiring the teeth for fracture of the lower jaw. Note the manner in which the wires encircle the upper and lower teeth before and behind the line of fracture. The upper wire is subsequently twisted with its corresponding wire below, so that the lower jaw is splinted against the upper.

The main points are to make the incision along the lower border of the jaw, cutting to the bone and letting the middle of the incision fall over the line of fracture. The bone is carefully denuded of periosteum. The sutures are not to come in contact with the buccal surfaces. The bones are drilled; the sutures passed and tied, the periosteum drawn over the sutures, and the soft parts partially repaired.

CHAPTER XVIII

INJURIES TO JOINTS

Dislocations; Compound Dislocations; Open Wounds; Contusions;
Sprains

DISLOCATIONS

Shoulder-joint.—Of all the joints, the shoulder is by far the most frequently dislocated. Of these dislocations, there are several forms, and yet only one variety is likely to be met with by the general practitioner—the *sub-coracoid*. A clear conception of the conditions and of the maneuvers necessary to a reduction presupposes a very definite notion of the *anatomy* of the joint.

Recall the relation of the acromion and coracoid processes to the glenoid fossa, to the head of the humerus and to the capsular ligament; the relation of the long head of the biceps to the joint and the attachments and actions of the various muscles surrounding the joint, particularly the subscapularis, the spinati, the pectoralis major; and the relations of the axillary vessels and nerves.

However simple a case may appear, do not begin any maneuver until a complete diagnosis has been made.

Diagnosis.—Begin by *inspection*. The patient is in evident pain; his head is inclined to the injured side and he supports the injured member with the other hand; the shoulder is flattened, the rounded prominence of the deltoid has disappeared and the acromion projects; the elbow is abducted and the patient is unable to bring it down to the side.

Palpation reveals the axis of the humerus pointing to the middle of the clavicle; the examining finger can be pushed under the acromion where the humeral head should be. The humeral head itself may be felt below or to the inside of the coracoid, and rotates with slight rotation of the arm.

The fingers in the axillary space feel the rounded head of the humerus projecting inward more noticeably when the arm is slightly abducted.

These questions arise: "Is it a case of simple dislocation, or is it complicated by a fracture of the upper end of the humerus, of the great tuberosity, or the rim of the glenoid fossa?" "Have the arteries or nerves been injured?" You must test particularly for laceration of the circumflex nerve. Do this by pin pricks over the deltoid; if the skin is insensitive, forecast paralysis and atrophy of the deltoid, and thus anticipate and disarm censure.

Whether any of the other complications mentioned are present or not is to be determined by the methods already described in connection with fractures of the upper end of the humerus.

Reduction.—(Lejars.) The method of Kocher seldom fails, if properly applied, and if the various movements are modified to suit the individual case. Its purpose is to put the head of the humerus in the position at which it left the capsule. Through the relaxed tear the head is then to be levered into the socket.

Seat the patient in a chair facing a little to one side. Let a strong and able assistant, standing behind, seize the patient's shoulder firmly and make pressure downward and backward. Place yourself before the dislocation, and seizing (in the case of the left arm) the forearm at the elbow with the left hand, and the wrist with the right hand, direct the patient to hold the head up and look straight ahead.

First Stage: Flexion, Adduction.—The elbow is flexed and then gradually adducted until it touches the body, the wrist held firmly meanwhile. The elbow is now pushed backward beyond the axillary line—the first stage is not complete without this. Neglecting this part of the first maneuver is a frequent cause of failure. Do not get in too great a hurry. Remember that the larger part of the resistance is due to the muscles and that they yield only gradually. Too sudden and too violent traction on them augments the pain and their resistance. To pause a little now, gives them time to relax (Fig. 234).

Second Stage: External Rotation.—Hold the elbow fast and flexed at a right angle, and now with your right hand, swing the forearm outward and backward until it lies in the transverse vertical plane

of the body (Fig. 235). Its axis lies directly in front of you. Perform the maneuver cautiously and smoothly. Again pause until the muscles are relaxed. Do not be alarmed by the snapping distinctly heard in the movement. One may follow the movement

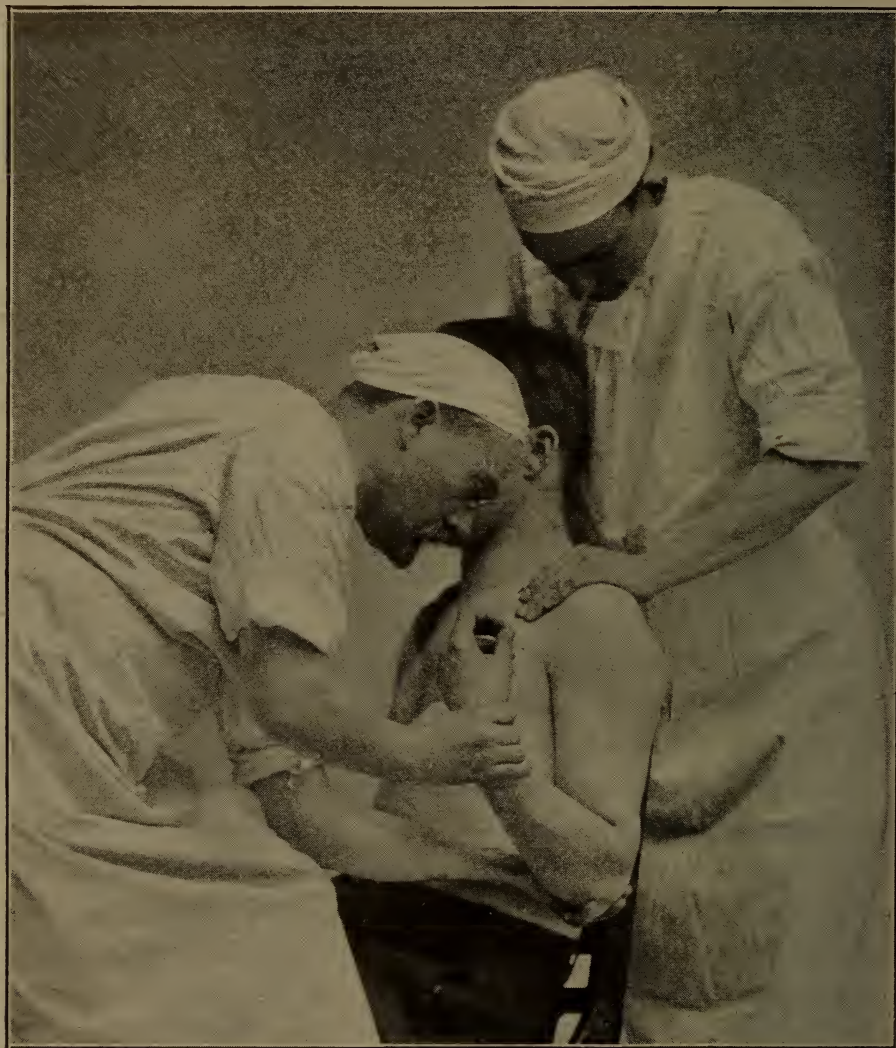

FIG. 234.—Reduction of shoulder. First stage: Flexion; adduction; elbow a little posterior to the axillary line.

of the bulging head of the humerus with the eye. Occasionally reposition occurs at the end of this movement, if it has been carried out methodically. If it has not proceed to the third stage of the maneuver.

Third Stage: Elevation.—Maintaining flexion and external rotation, next lift the elbow upward and forward—upward and forward exactly—do not permit the elbow to move outward. Abduction will spoil the maneuver (Fig. 236). Lift upward and forward till

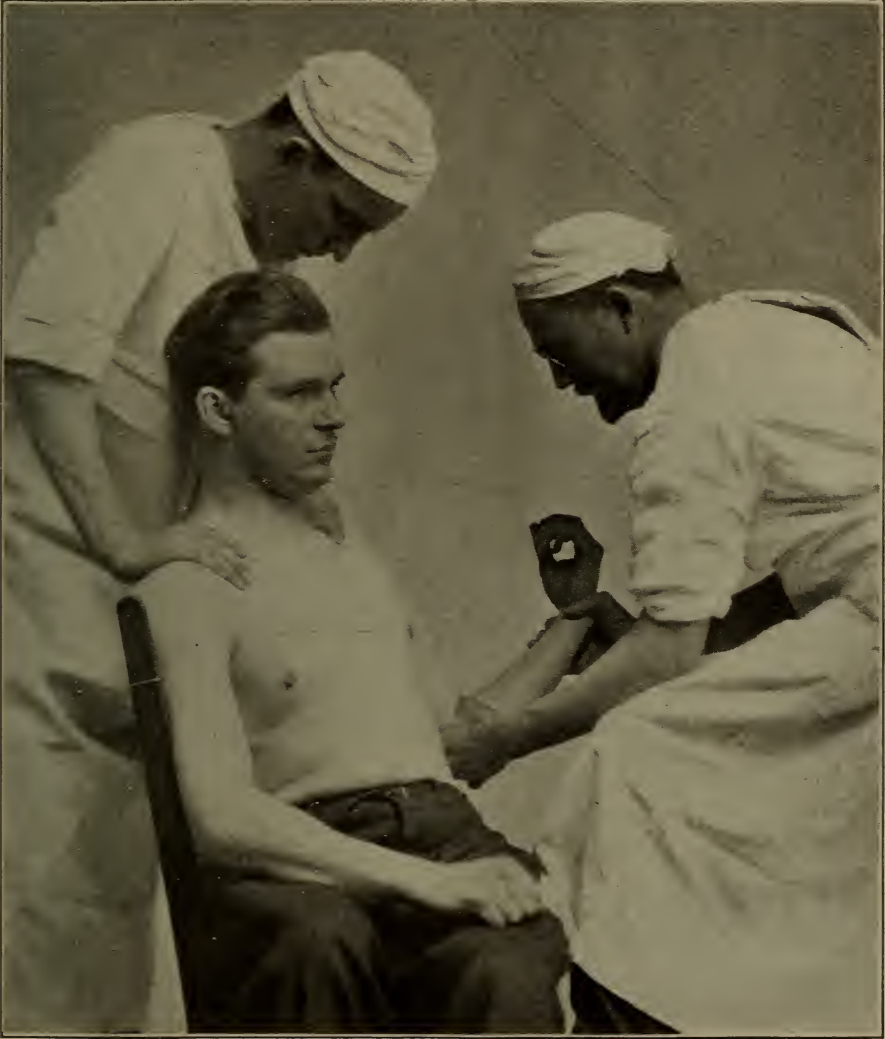

FIG. 235.—Reduction of shoulder. Second stage: External rotation until forearm stands at right angle to body.

the arm reaches the horizontal—a sudden snap indicates that the head has slipped into the socket.

Fourth Stage: Internal Rotation.—Proceed now rapidly to swing the forearm inward and across the chest until the hand rests on the

opposite shoulder (Fig. 237). The movement is made rapidly but with no great force. This latter holds good with respect to all the movements. It must be observed that the surgeon's hands do not change their hold at any stage of the reduction.

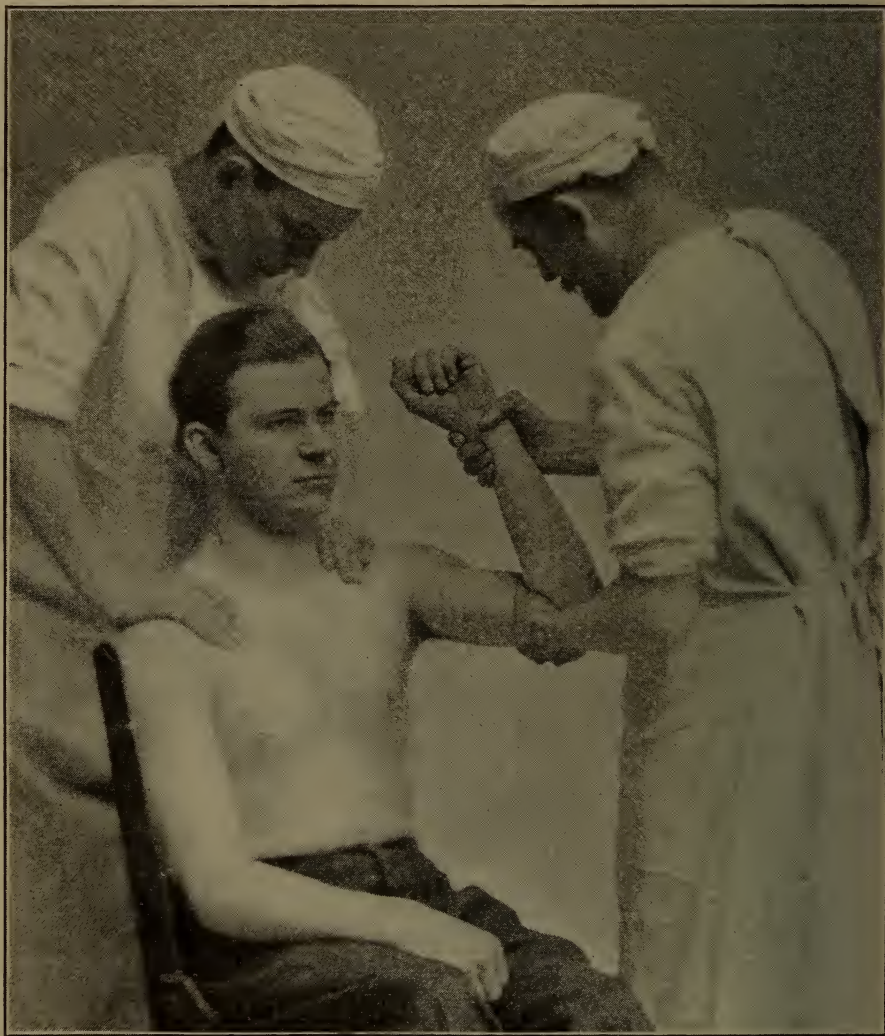


FIG. 236.—Reduction of shoulder. Third stage: Elevation while maintaining external rotation.

If these maneuvers fail, repeat them in the same order, using a little more force in the second and third stages and pausing a little longer at the end of a stage.

In the *subclavicular* form also this maneuver will succeed, but

should be modified to this extent: prolong the second stage two or three minutes, using more force to obtain external rotation and the backward position of the elbow. In this wise, the muscles are re-

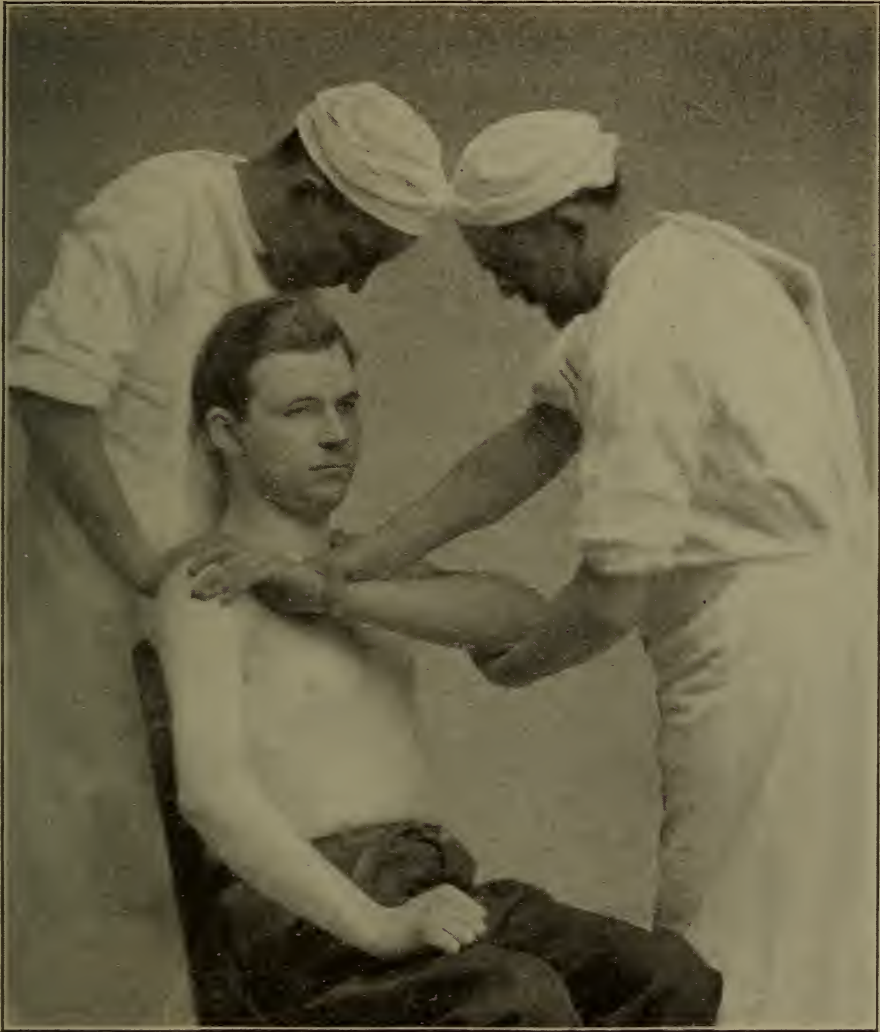

FIG. 237.—Reduction of shoulder. Fourth stage. Internal rotation.

laxed more completely. Without changing the external outward rotation, the elbow is lifted upward and forward as before.

Not less efficient in certain cases of subcoracoid dislocation is the *method of Mothe, or traction in extreme abduction*. It is also applicable in all other forms of inward and downward dislocation.

In this procedure, counter-extension is indispensable. A long towel will serve. It encircles the injured shoulder, passing under the armpit, and the two ends cross the back toward the south side. While the assistant makes forcible counter-extension, the operator manipu-

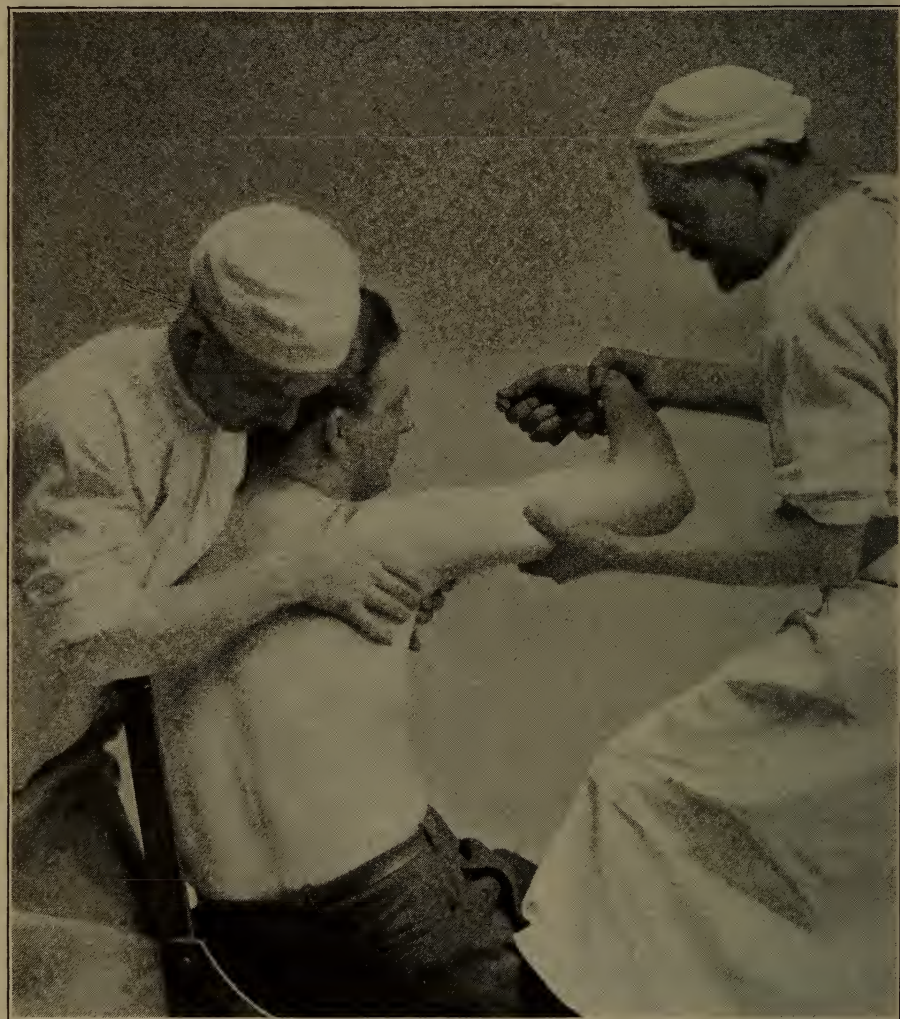


FIG. 238.—Reduction of shoulder. Traction with high abduction. The axis of the humerus should be in line with the spine of scapula. Assistant steadies the shoulder.

lates the arm. It is best that he stand on a stool or chair if not tall enough to make good traction upward. Now seize the arm above the elbow and the forearm near the wrist (Fig. 238). Flex the elbow. Next elevate the arm by extreme abduction until it is in line with the spine of the scapula. The arm, you must observe, does not reach the

horizontal merely, it is elevated beyond that level. This is of the greatest importance. With the arm thus in extreme abduction, next make strong traction in that direction (Fig. 239). Assistance in traction may be necessary; or one may confide the traction to an assistant,

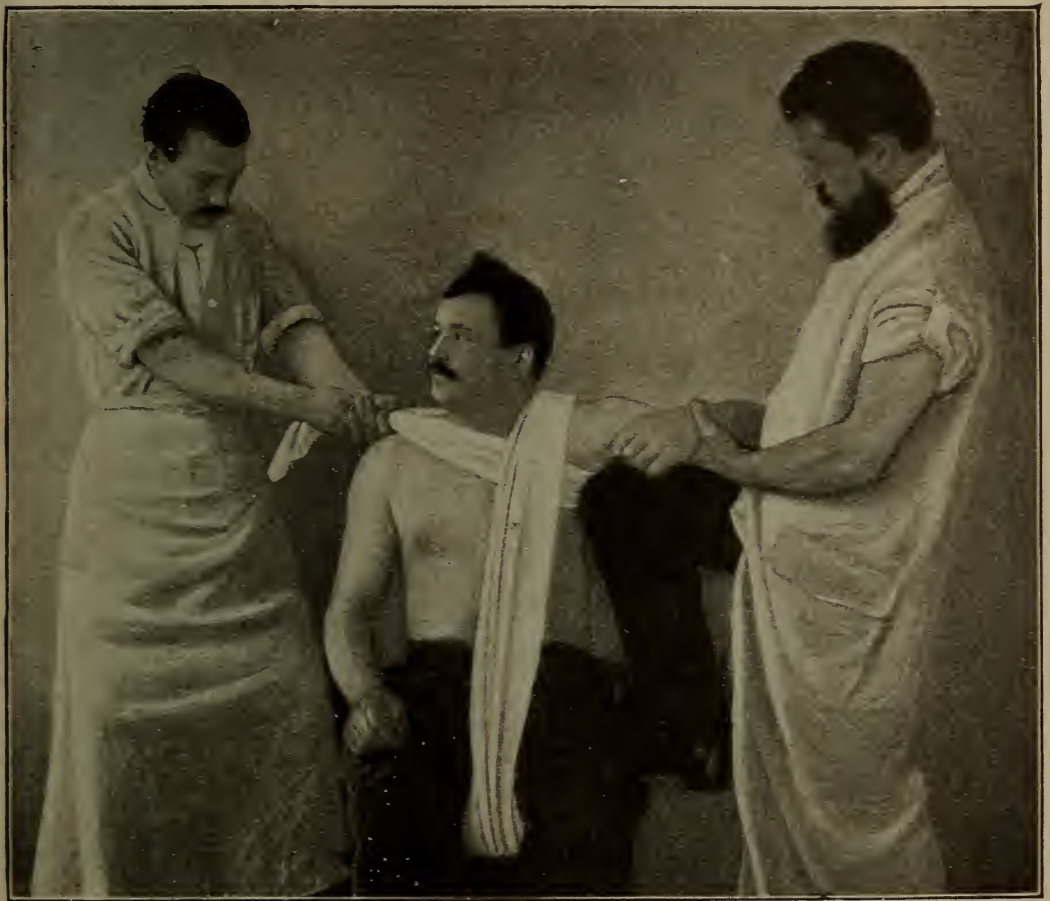

FIG. 239.—Reduction by high abduction and traction. Note manner in which the assistant steadies the shoulder. (*Lejars.*)

while with the thumbs, one pushes against the humeral head in the axillary space.

If this does not succeed, begin the second stage:

Depress the arm rapidly and smoothly, letting the point of the elbow pass in front of the chest, all the while maintaining traction. This method occasionally fails for these reasons:

(1) Traction with high abduction is not long enough continued.

The arm is depressed before the head has been sufficiently elevated by traction.

(2) The arm is lowered too slowly.



FIG. 240.—Chipman's method of reducing dislocated shoulder. First stage.
(*International Journal of Surgery.*)

In neglected cases or in the very muscular, *general anesthesia* may be indispensable whatever the method, but force must then be employed with still greater care, and it must be borne in mind, too, that incomplete anesthesia here is as dangerous as it is useless. The particular danger of this method is laceration of the axillary structures. If general anesthesia is strongly contra-indicated, *local anesthesia*

may be employed, injecting the joint and the tendons near their lines of insertion. How long after the injury reduction may be attempted cannot be determined by any rule, but by the conditions in the individual case.

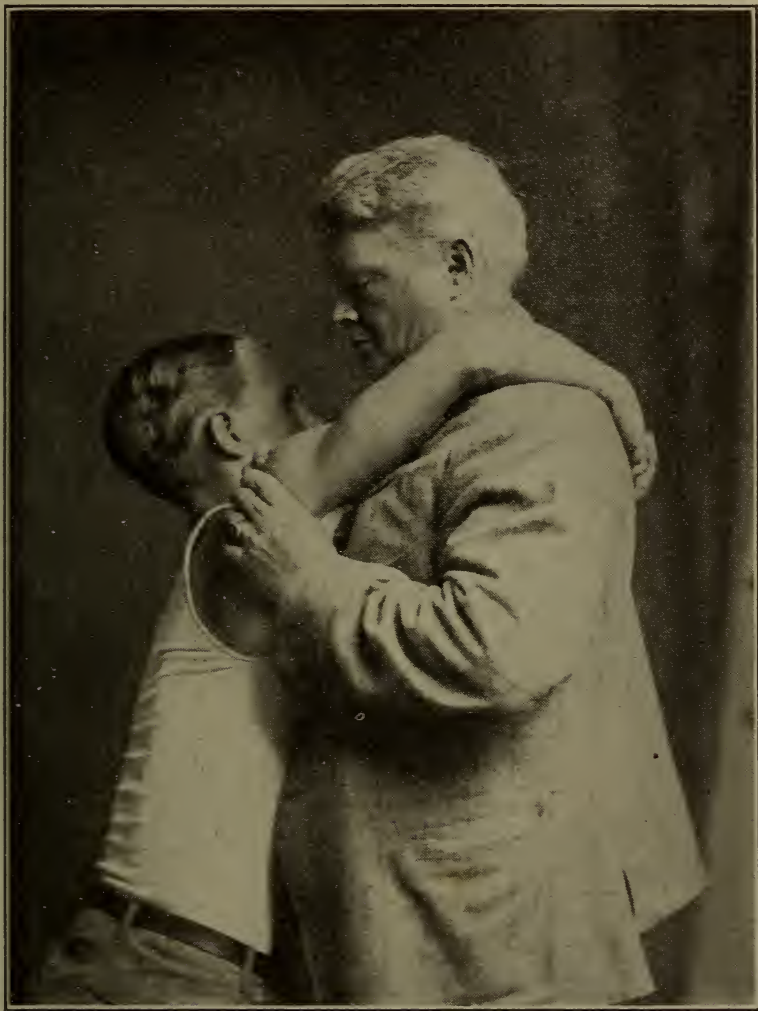

FIG. 241.—Chipman's method of reducing dislocated shoulder. Second stage.
(*International Journal of Surgery.*)

Chipman, of New London, Connecticut, suggests a method which must prove of value, especially to the doctor compelled to act without assistance.

He describes his method thus (*Int. Journal of Surgery*, November, 1906): Stand facing your patient. Gradually raise the dislocated

arm to a horizontal position and place it on your shoulder with forearm flexed on your back. Direct the patient to pass the well arm under your arm and grasp the wrist of the injured arm with the well hand. Thus the patient's arms encircle your body, the injured one passing over one shoulder, the sound passing under the other (Fig. 240).

Second Stage.—Now direct the patient to sag downward, and the weight of the body drags the head of the humerus outward and upward, when you can easily return it to the glenoid cavity with your hands (Fig. 241). The dislocation is so easily and expeditiously re-

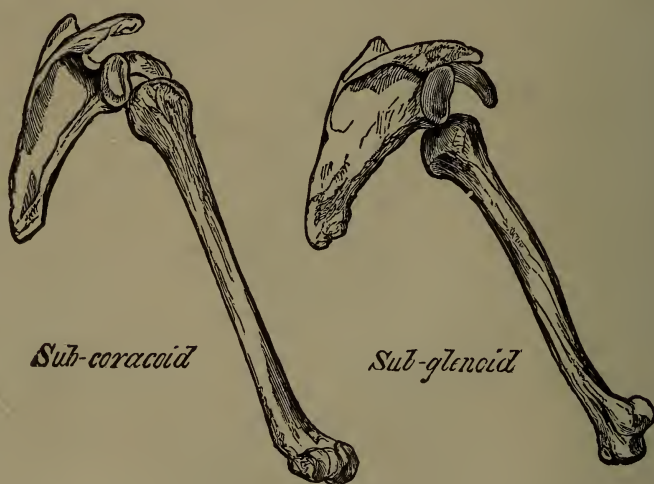


FIG. 242.—Dislocation of shoulder. (Walsham.)

duced that even the surgeon himself is surprised. There is the least possible additional injury, the least possible pain; there is no need of an assistant or an anesthetic.

SUBGLENOID DISLOCATION

This variety is always the result of forcible abduction of the humerus, the tear in the capsule falling below the glenoid cavity, and the head of the humerus remaining fixed there (Fig. 242).

The *diagnosis* is to be made from the symptoms already described for the subcoracoid form, the only difference being that the elbow is further from the chest, the flattening of the shoulder more pro-

nounced, the head of the humerus more readily felt in the axilla (Fig. 243).

The *reduction* may be affected by Kocher's method, but perhaps the best method is that of extreme abduction with traction, which has

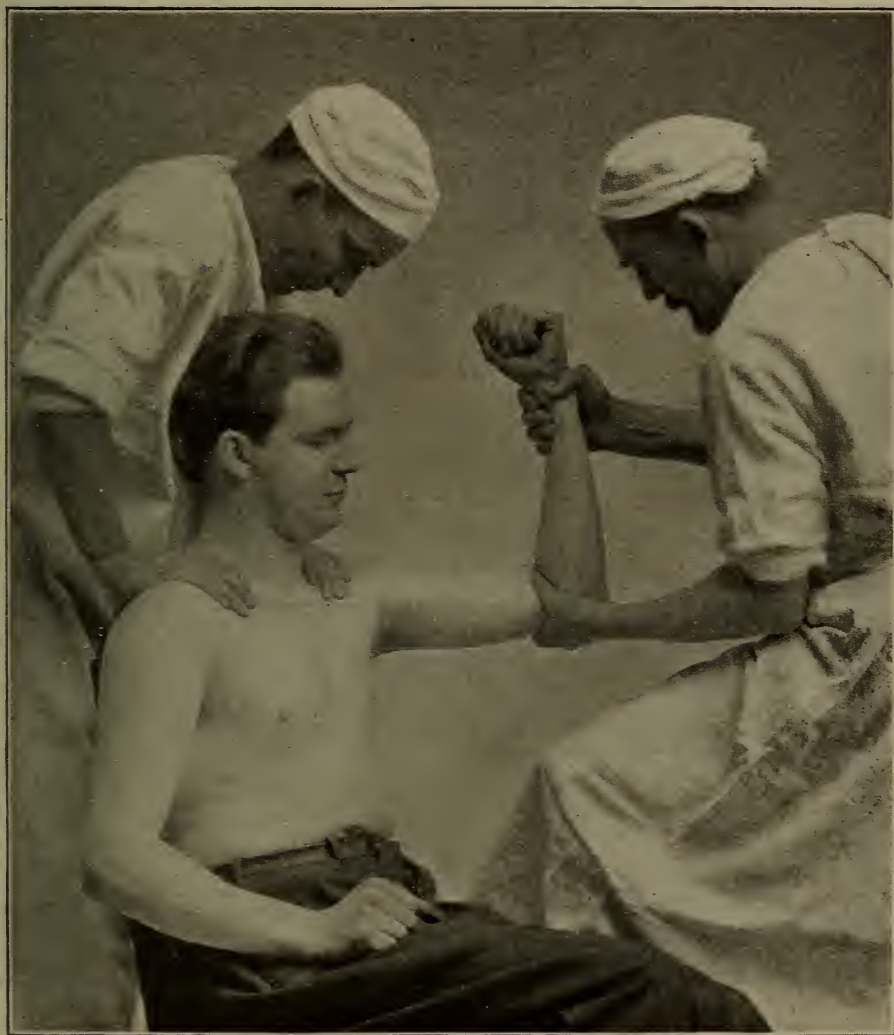


FIG. 243.—Reduction of a subglenoid dislocation. Second stage. Gradual elevation with constant traction.

already been described. The patient may be seated, but often must recline, for the weight of the pendent limb may be very painful. The injured member is grasped above the elbow with one hand, below the wrist with the other, flexed, slowly raised to form an obtuse angle

with the chest. In this position strong traction and counter-traction are to be made. Usually this succeeds, though it may help to press the head into place (Fig. 244). If traction and pressure are not suf-

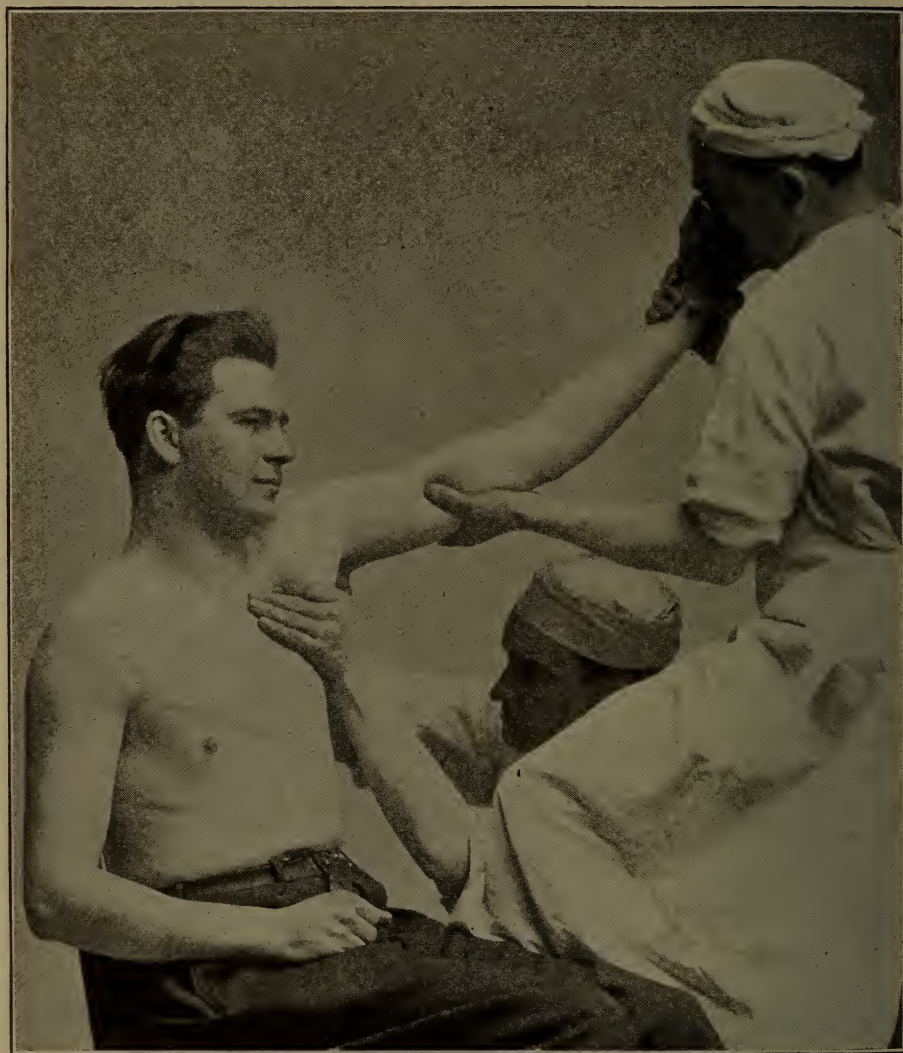


FIG. 244.—Reduction of subglenoid dislocation. Third stage. Traction with high abduction and pressure on the humeral head.

ficient to effect reduction after the muscles have been thoroughly relaxed, the arm is to be depressed as before described.

Subspinous Dislocation.—In this case the shoulder is flattened in front and the examining finger finds a marked depression between the tip of the acromion process and the coracoid. The elbow is carried

slightly forward and the arm rotated inward. The head of the humerus can be felt below the spine of the scapula.

Reduction.—General anesthesia is usually necessary. Grasp the arm above the elbow; slightly abduct the arm; slightly increase the inward rotation (never rotate outward); make traction in a direction downward and forward. Pressure forward on the head is helpful.

AFTER-TREATMENT OF SHOULDER DISLOCATIONS

The task in any form of dislocation does not end with reduction. There is still the duty to restore usefulness as completely as possible, and to that end the subsequent care must be minutely regulated. The inclination is to immobilize the joint too completely and too long, fearing a recurrence of the dislocation. This enforced rest combined with injury is liable to produce atrophy of the muscles, stiffness of the joint, and protracted loss of function. The indications for after-treatment are various, depending upon clinical conditions.

(A) An uncomplicated, easily reduced dislocation in a healthy strong adult:

Begin by immobilizing the shoulder, but take care that after three or four days of complete rest massage and passive motion shall be begun. The joint is cautiously put through all its motions, the deltoid, and pectoralis major, and the scapular muscles carefully massaged; a daily séance gradually prolonged.

In the interval the arm is bandaged, but gradually the dressing is relaxed and, after a week, movement left quite free. In two weeks of such treatment the function may be entirely restored.

(B) The case was complicated with injury to the soft parts, was with difficulty reduced, and only after a number of attempts; it is likely that the capsular ligament was extremely lacerated:

Under such circumstances not only partial displacement, but actual dislocation is to be feared. Immobilize the joint with a Mayor sling or Velpeau bandage and let it so remain a week. But this will not prevent massage over the shoulder after four or five days. Do not prolong the fixation, remembering that a dislocation accompanied by great violence furnishes the condition most favorable to adhesions and weakness, and against these evils we have no remedies but massage and gymnastics, which must be early begun and long continued.

A man was brought to the City Hospital with a pronounced subcoracoid dislocation. The radiograph showed a part of the greater tuberosity scaled off. The injury was a crushing one, a great stack of sacks filled with flour having toppled over and pinned him against the wall. The tendon of the biceps was probably torn from its groove carrying a fragment of bone with it. Under general anesthesia the dislocation was easily reduced by traction with high abduction combined with pressure on the head of the humerus. After two weeks, immobilization the tenderness on pressure over the greater tuberosity was still marked and it was assumed that the fragment was not

yet reunited. Movement at the elbow also excited pain at the shoulder. After another ten days' massage and passive motion was tried again with better results and at the end of five weeks he had regained the functions of the joint in fair degree.

DISLOCATION OF THE LOWER JAW

This accident, which may happen at most unexpected times, when yawning or laughing, for instance, might be confused with certain fractures of the inferior maxilla. The opened mouth, the loss of power to close it, are characteristic (Fig. 245). The

reduction is usually easy. Both sides may be reduced simultaneously. Wrap the thumbs; you have to deal with the powerful muscles of mastication, which, when the dislocation is reduced, are likely to close the jaws with much force.

The thumbs, passed into the mouth, press downward and backward on the molar teeth; at the same time, the fingers hooked under the chin pull upward. In the muscular, considerable force is required.

The jaws should be moved only slightly for several days.



FIG. 245.—Dislocation of jaw. (Moullin.)

DISLOCATION OF THE ELBOW

Dislocation of the elbow, which occurs with considerable frequency, especially in children, nearly always assumes the form of backward displacement.

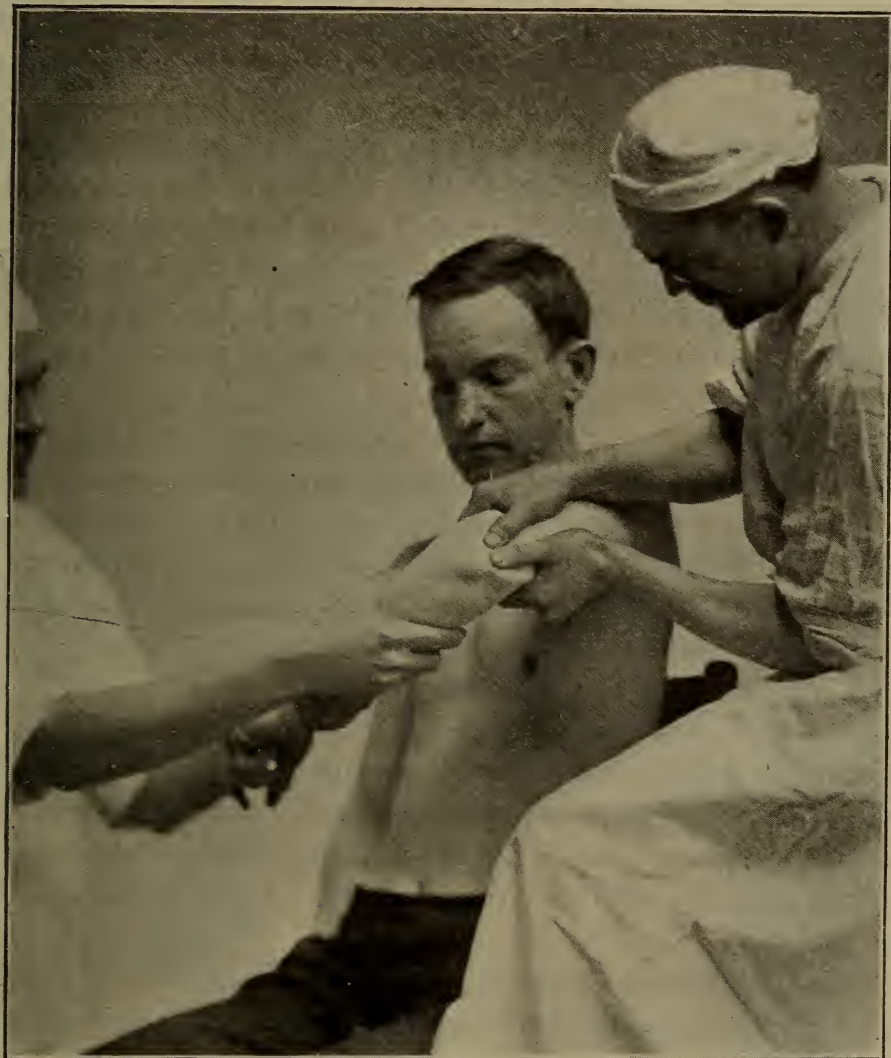


FIG. 246.—Reduction of the elbow-joint. Traction with gradual flexion combined with pressure forward on the olecranon.

Diagnosis.—The elbow is increased in thickness antero-posteriorly. The flexure of the joint is depressed. Where the head of the radius should be there is a depression. The olecranon is abnormally promi-

ment. Compare the relation of the olecranon to the inner condylar lines on the two sides. Flexion is quite painful and practically impossible.

If the diagnosis is doubtful, as it often must be when swelling is great, one thinks of supra-condylar fracture. But in the case of fracture, the relation of the olecranon to the condylar line is unaltered; the humerus is shortened; the deformity disappears with traction.

Reduction.—(A) Standing on the injured side, seize the arm above the elbow with both hands, and as an assistant makes traction on the forearm, steady the arm and press with both thumbs on the olecranon. The traction is made at first in the direction of the long axis of the forearm, but as the limb yields, the forearm is rapidly flexed—continuing the traction and pressure. By this means reposition is usually quite easy (Fig. 246).

Traction and counter-traction as before, except that the traction which began in the direction of the long axis of the forearm and produced flexion, now produces hyper-extension. In the meantime, press on the olecranon and the head of the radius. In this way, one will sometimes succeed, but do not forget this method is available only for those who have supple joints.

(C) Method of Astley Cooper:

The patient is seated on a chair—you place yourself on the side opposite the injured elbow. If it is the right, for example, stand upon the left side and place a foot upon the chair. Get the bend of the elbow over the knee. Steadying the humerus with one hand, draw on the flexed forearm with the other, at the same time flexing the elbow over the knee.

Generally speaking, however, if the first method fails, it is better to give a general anesthetic, with which the chief difficulties disappear.

Lateral dislocations are usually replaced without much trouble by pressure combined with extension.

After-treatment.—This must be begun even earlier than for the shoulder—massage and passive motion—else a stiff joint is very likely to follow.

DISLOCATION OF THE THUMB

This accident, apparently simple, presents some peculiarities, which must be borne in mind.

These displacements at the metacarpophalangeal joint, are classified as incomplete, complete, and complicated, depending upon the relations which the articular surfaces assume and upon the disposition of the sesamoid bone (Fig. 247). *Incomplete* dislocations leave the articular surfaces in slight contact; *complete* dislocations find the articular surfaces at right angles, the phalanx standing upon the dorsum of the metacarpal (Fig. 248); and, if in addition to this, the torn anterior ligament and sesamoid bone, in attempt at flexion, are wedged between the articular surfaces, the dislocation is said to be *complicated*, a condition difficult to manage (Fig. 249). Since this condition is produced by maladroit attempts at reduction of

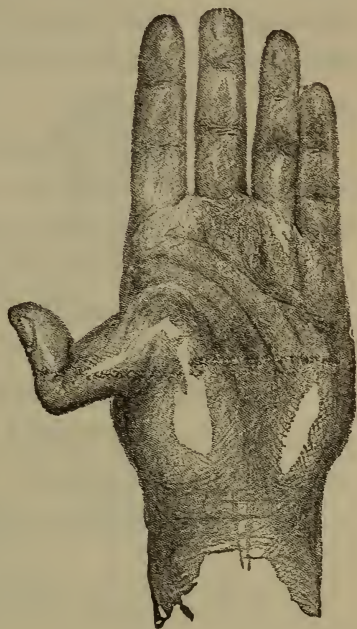


FIG. 247.—Complete dislocation of thumb. (Moullin.)

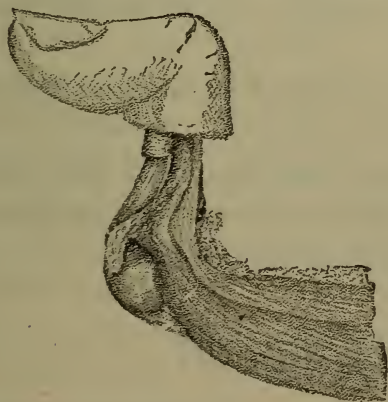


FIG. 248.—Complete dislocation of thumb. (Moullin.)

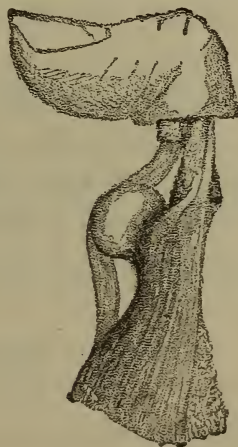


FIG. 249.—Complicated dislocation of thumb. (Moullin.)

the complete dislocation, it is especially desirable to understand the maneuvers.

Whether the dislocation be complete or incomplete, *never* attempt reduction by *flexion*. That is the thing to be avoided. Seize the thumb and slightly bend it still further backward, at the same time pushing the base of the phalanx obliquely downward and forward. Directly the phalanx will be felt to slide over the head of the metacarpal into its place.

Complicated Dislocation.—(Lejars.) Employ general anesthesia. Only the most carefully regulated maneuvers will succeed. Do not attempt the reduction unless the various steps are clearly in mind.

(1) Make traction on the digit in the direction of its axis until it is as long as normal.

(2) Seizing the thumb between forefinger and thumb in such manner that your thumb presses on the dorsal surface of the dislocated joint, bend it backward until it stands perpendicular to the metacarpal, or even further. The object is to put the thumb in the position of *uncomplicated* dislocation, and thus disengage the sesamoid bone.

(3) Still holding it at that angle, push the base of the phalanx forward.

(4) Having pushed the phalanx as far forward as possible in this manner, begin suddenly to flex it, in the meantime keeping the last phalanx extended and do not cease to push forward while flexing.

If failure attends two or three attempts, do not persist; proceed to operate.

Dislocations of the *fingers* should be treated in the same manner—never begin by flexing.

Reduce by first bending the finger backward and then pushing the base of the phalanx forward. In every case the purpose is to reproduce in reduction the movements of dislocation.

DISLOCATION OF THE HIP

These accidents are always serious, and yet are comparatively rare. Of the different forms of luxation of the femoral head, the *backward* on the dorsum ilii is by far the most frequent (Figs. 250, 251).

Diagnosis.—The thigh is adducted, rotated inward, and practically immovable. The leg is apparently shortened, the knee slightly

flexed. The trochanter rests above the line drawn from the spine of the ilium to the ischial tuberosity. The femoral head may be felt under the gluteal muscles on the dorsum ilii.

Reduction.—General anesthesia is usually necessary. Lay the patient on a pallet on the floor. A strong assistant, pressing on the iliac spines, immobilizes the pelvis.

First Movement: Flexion of Thigh.
—Grasp the thigh above the knee with one hand and with the other, the leg, and gradually flex the hip and knee. Flex the hip to a right angle.

Second Movement: Traction on the Flexed Femur.—When the hip is flexed at a right angle, begin traction, maintaining that angle. Do not be afraid to use force. This is the most important maneuver. Properly applied, that is to say, with powerful traction on the hip bent at a right angle, the effort will often be rewarded by a sudden snap, which indicates that the femoral head has returned to its socket (Fig. 252).

Third Movement: External Rotation with Abduction.—Persisting in the traction, the resisting muscles are felt to yield. Now carry out the final maneuver, which should guide the head over the rim of the acetabulum into place. Continue traction to some extent, but rotate the thigh outward and at the same time abduct. All the other methods proposed are but modifications of this (Fig. 253).

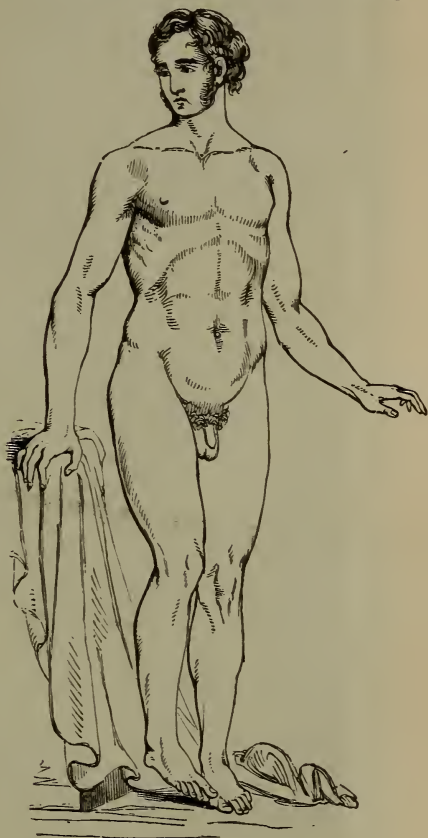

FIG. 250.—Backward dislocation, dorsum ilii; shortening, inversion. (Moullin.)

ISCHIATIC DISLOCATION

Diagnostic points: Adduction, inward rotation, marked flexion of both knee and hip (Fig. 254).

Reduction.—By the same method as the dorsum ilii. Do not begin the final movement of abduction and external rotation too soon.




FIG. 251.—Dislocation of the femur upward and backward in a child.
The arrow points to the acetabulum.

SUBPUBIC DISLOCATION

Diagnostic points: Compared with the ischiatic an opposite condition of affairs exists—abduction, external rotation and extension. The great trochanter cannot be located (Fig. 255).

Reduction.—Flexion is here illusory, and equally so, blind traction. Slightly lifting the extended limb, abduct it as far as possible; while

abducting continue to lift. The head rolls down toward the obturator foramen, and finally the thigh stands vertically. Now adduct and rotate inward.

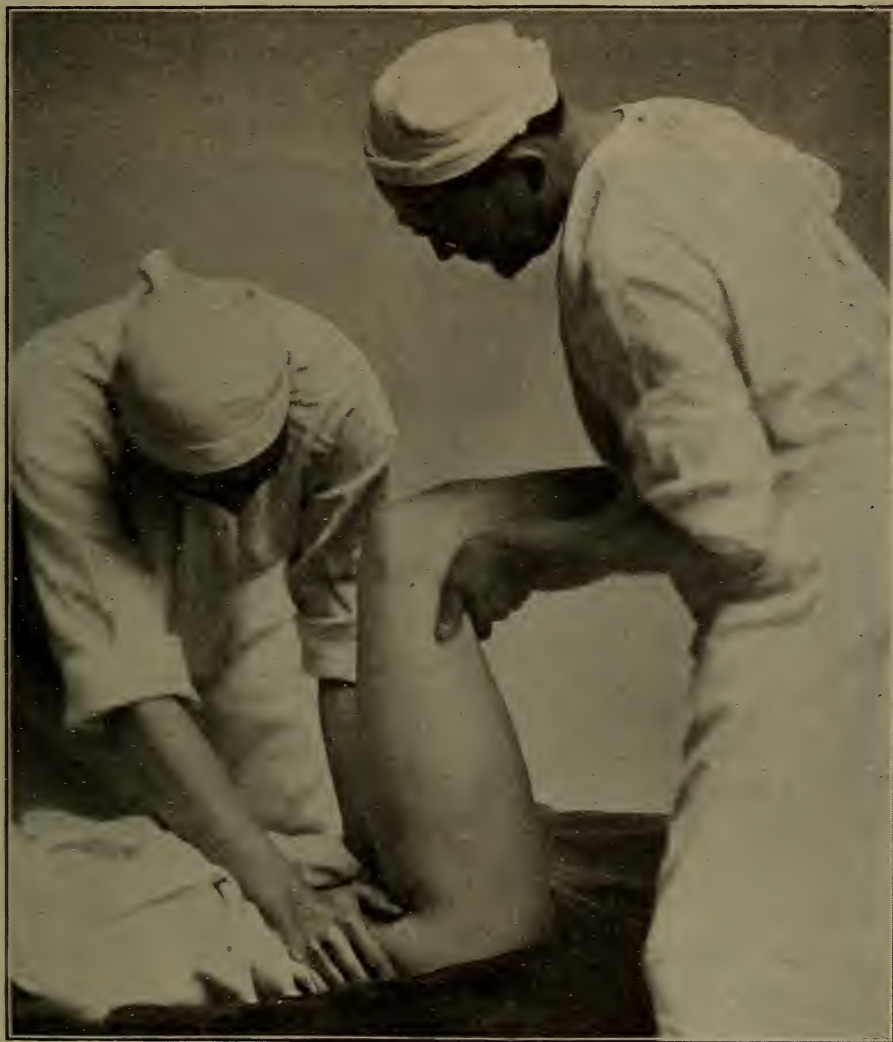

FIG. 252.—Reduction of the hip. Flexion of the knee. Gradual, flexion of the hip with traction on thigh.

OBTURATOR DISLOCATION

Diagnostic points: The hip is flexed, abducted, and rotated outward (Fig. 256).

Reduction.—Flexion of hip, traction on flexed thigh, adduction, inward rotation.

DISLOCATION OF THE KNEE

This accident is infrequent, easy of diagnosis, and comparatively easy to reduce.

General anesthesia is frequently necessary. Two assistants are needed, one for traction on the leg and one for counter-traction on the thigh, while pressure is applied at the joint.

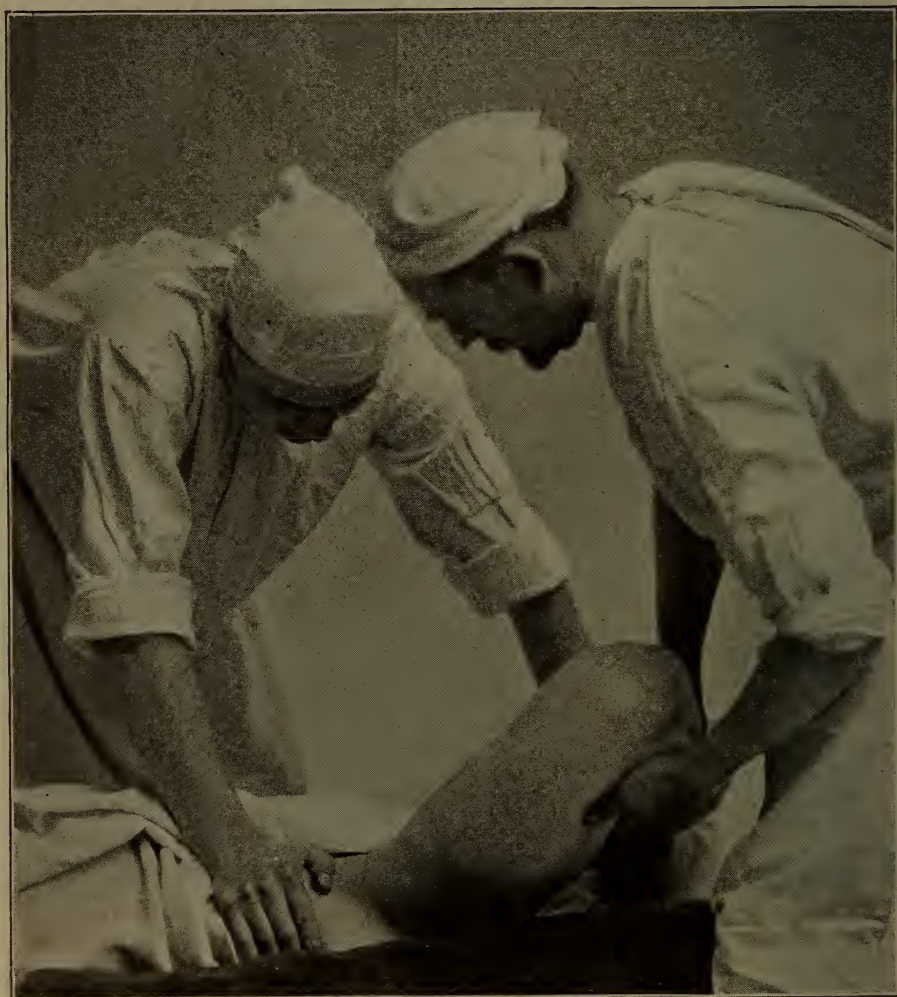

FIG. 253.—Reduction of hip. Third stage. External rotation.
Hip strongly flexed.

One must be concerned here with the condition of the blood vessels. Suppose there is no pulse at the ankle, the popliteal space is evidently filled with blood. Under these circumstances apply a

tourniquet, and, under rigid antisepsis, open up the space by a longitudinal incision, turn out the clots, ligate the torn vessels. Remove the tourniquet, complete the hemostasis, and sew up the wound. The limb is bandaged in cotton, elevated, and kept warm.



FIG. 254.—Dislocation of hip backward into the sciatic notch. Leg shortened, foot inverted. (Moullin.)

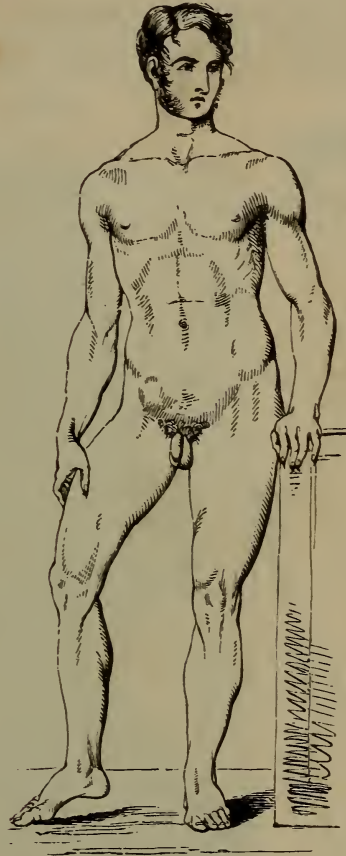


FIG. 255.—Forward dislocation: subpubic; extension, eversion. (Moullin.)

Time alone can tell whether or not the circulation will be restored and gangrene averted.

DISLOCATION OF THE SEMILUNAR CARTILAGES

This is an injury likely to be forgotten in making a diagnosis of disabilities of the knee.

The internal semilunar cartilage is much more likely to be in-

volved, the accident usually occurring in this manner: the individual attempts to turn suddenly while the knee is flexed. The cartilage, either as a whole or, more often, a part, projects to the outside or inside of the joint circumference. There is a sudden painful locking of the joint.

The patient himself is often able to relieve the condition by a little manipulation of the joint, combined with lateral pressure. The injury is a serious one, functionally, and demands prolonged rest, in the hope that union may occur. An elastic silk stocking for the knee gives support and tends to prevent recurrence of the trouble, but violent movements are almost sure to bring a return. If asepsis is assured, the joint may be opened and the cartilage sutured to the tibia—an operation to be advised by the general practitioner and yet scarcely ever necessary to be undertaken by him.

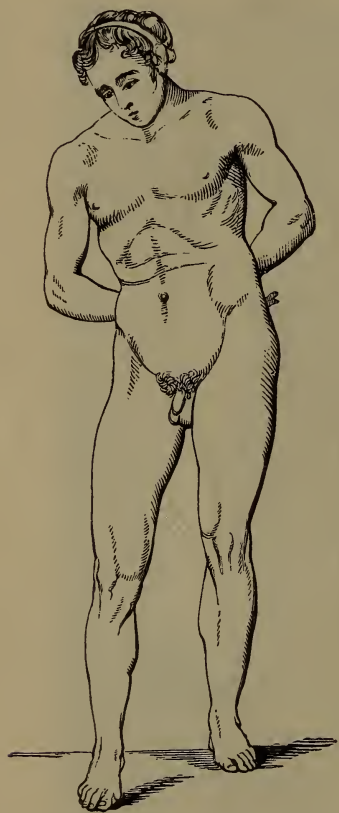

FIG. 256.—Downward dislocation. Obturator. (*Moullin.*)

DISLOCATION OF THE PATELLA

The difficulties in correcting the displacement of the patella are various, depending not only on the character of the dislocation, but also on the condition of the ligaments and muscles.

In general, there is one method of treatment, viz.:

Extend the leg completely and, holding it in extension, flex the thigh to a right angle. By this means the quadriceps extensor, in whose tendon of insertion the patella is lodged, is relaxed, permitting the bone to be manipulated into place.

DISLOCATION OF THE ANKLE AND TARSUS

The diagnosis and correction of these injuries are more especially matters of anatomy. Whoever has clearly in mind the relations of

the components of the foot, can determine the character of the disarrangement with the minimum difficulty.

If the diagnosis is wrongly made, correct reposition is lacking, and in consequence there persists a degree of deformity and loss of function.

One must begin his task of diagnosing a serious injury to the foot by recalling the relations of the malleoli and astragalus, the os calcis, and the other tarsal bones, to each other.

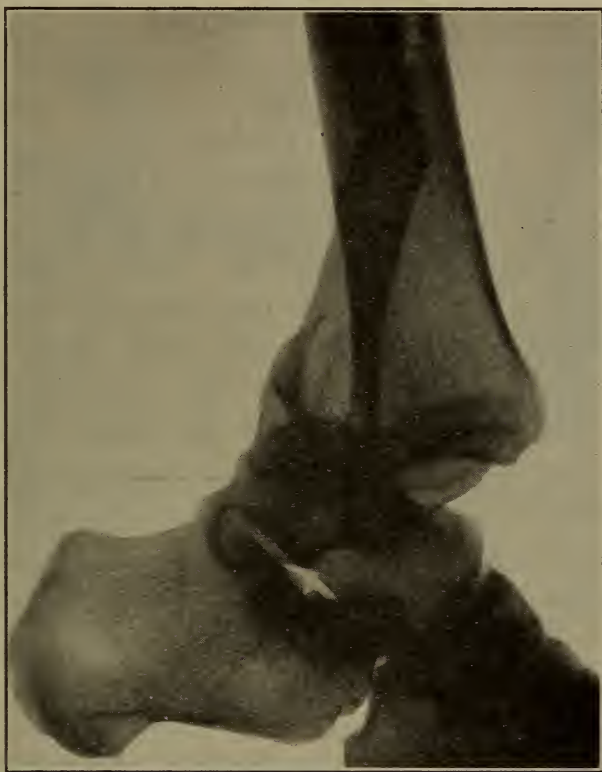

FIG 257.—Backward dislocation of ankle with fracture of the tibia.

Inspect the foot; the heel, the sole, the borders, the malleoli, the tendo achillis—and compare each of these, point for point, with the sound side. Remember that the line of the tibial crest, prolonged, falls on the second toe.

A dislocation of the ankle-joint assumes various forms. The other bones may be dislocated from the astragalus, which retains its normal relation to the malleoli. There may be solely a dislocation of the

astragalus, which may take almost any position imaginable. Less often one finds displacement of the metatarsals and phalanges. There may be a fracture of the fibula (Fig. 257).

It is scarcely possible to indicate an exact method of reducing such luxations. The surgeon's ingenuity must suggest the proper variations of *traction* combined with *pressure*. A type may be found in *backward dislocations of the ankle* (Fig. 258).

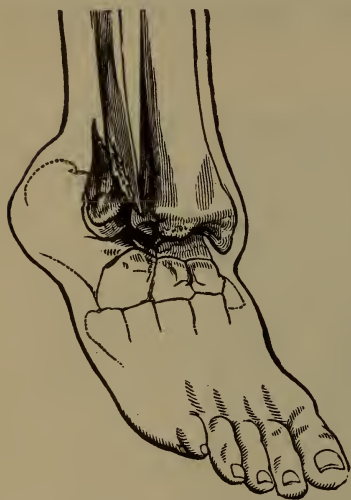

FIG. 258.—Backward dislocation of ankle. (Moullin.)

The malleoli are carried forward, the heel is elongated, the foot shortened. There is a transverse fold in front of the ankle, ridged vertically by the stretched extensor tendons.

Reduction.—The patient's foot projects over the end of the table, an assistant steadying the flexed knee. Grasp the heel with one hand and the middle of the foot with the other (Fig. 259). Make traction at first to reflex the opposing muscles and then shove the foot forward and at the same time flex it.

After-treatment.—The injured joint, carefully padded, must be fixed by a plaster splint. After eight to ten days, passive motion and massage must be begun.

COMPOUND DISLOCATIONS

These are accidents always to be dreaded, and yet they yield excellent results under antiseptic methods.

Before you is a joint wide open, the articular surfaces bare, perhaps protruding, and immediately you think of resection or amputation, and yet you will do neither. You will proceed to do a most careful disinfection and to secure a complete reposition and immobilization. The one chief concern is *disinfection*.

The same indications for treatment are present as in compound fracture into joints (see page 283) and depend upon the degree of injury to the soft parts and whether the infection is or is not obvious.

The skin about the wound is prepared as for a surgical operation, the wound is thoroughly flushed out with normal salt solution, foreign bodies are removed, and replacement is effected. The next step will vary, depending upon the degree of confidence in having completely sterilized the joint cavity. If the effort has been exacting in that regard, tightly suture the deep layers over the joint, close the superficial layers with interrupted sutures and apply drainage.

If the articular structures were impregnated with dirt, one will still fear suppuration despite the greatest care in cleansing, and will

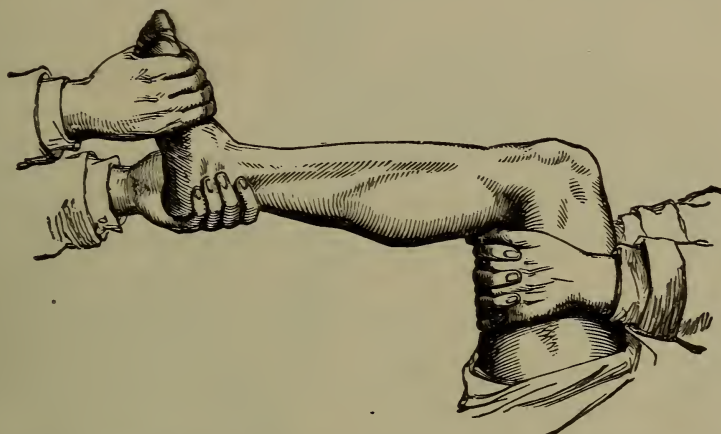


FIG. 259.—Reduction of dislocated ankle. The assistant steadies the flexed knee. (Heath.)

close the wound less firmly and provide for free drainage. Removing as many bacteria as possible, starving those that remain by removing their food supply—devitalized tissue and blood serum—are the principles of treatment; cleansing and draining, the means; healing without inflammation or suppuration, the end.

Dressing and After-care.—Having provided for drainage, cover the wound with sterile gauze, envelop the limb in absorbent cotton and immobilize the joint with a plaster splint.

As soon as the soft parts are healed and the danger of infection has passed, begin massage of the muscles and slight movement of the parts daily.

But in spite of careful cleansing, infection may develop. On the third day, perhaps, a chill occurs, the fever mounts rapidly and there are all the local signs of inflammation and sepsis. Do not temporize,

but immediately open the wound, douche thoroughly with peroxide or iodine water and leave the wound open. Immobilize. If the temperature does not fall and the local conditions do not improve in a few hours, proceed at once to do an arthrotomy (see page 440).

The thorough drainage by this means obtained will usually control the situation. The drainage is gradually withdrawn, and will not be necessary after about the tenth day. If, even then, the swelling and fever do not subside, there is nothing left to prevent a general infection but immediate amputation, and even that may be too late.

The *shoulder-joint* rarely suffers a compound dislocation. Such an injury is especially serious for the reason that there are so many complications; the shoulder muscles are torn, the axillary vessels and the nerves of the brachial plexus lacerated.

It must be treated on the general principles enumerated and the result is often surprisingly good. If traumatic aneurism exists, the pectoralis muscles must be divided, the space exposed and the vessels ligated.

The *hip-joint* is occasionally the site of a compound dislocation and nearly always the shock is fatal.

Elbow.—This is a comparatively frequent accident and is treated on the general principles outlined. If the injuries are severe, a partial excision may be required to perfect drainage and insure a better joint. Amputation will be indicated only in old age, morbid constitutional disability, or extreme local destruction.

An automobile overturning caught the driver in such way as to produce a compound dislocation of his elbow. He was brought in by the ambulance, with a tourniquet on the arm.

Under a general anesthesia the wound was explored after cleansing with tr. iodine.

The end of the humerus protruded through one ugly ragged rent. The brachial artery was torn, the ends widely separated. The brachialis anticus could scarcely be identified and the median nerve stood out prominently, stretched over the projecting bone.

Reduction was accomplished, the torn vessels ligated, the tourniquet removed and an effort made to suture the capsule.

Next the torn brachialis anticus and the group of muscles attached to the internal condyle were repaired in a fashion, with chromic gut;

the bicipital fascia was sutured also with chromic and the skin with silkworm-gut with slight drainage; the joint was fixed in flexion with plaster in the form of a posterior splint.

On account of the ruptured brachial artery gangrene was feared but at the end of thirty-six hours a slight radial pulse was felt. There was much swelling and great pain, but scarcely any rise of temperature.



FIG. 260.—Fracture and compound dislocation at the wrist. Hand saved. (*Scudder.*)

Eventually a considerable slough occurred in the wound, but without evidence of infection. A month was required for repair of the wound.

Under an anesthetic the limb was gradually extended and fixed in that position for a while. At the end of the sixth week it was flexed again, this time manipulated quite freely.

The whole forearm remained very painful and the patient was unable to move it. He insisted on amputation, but was encouraged to persevere with massage, the electric current and hot baths. Some improvement in the pain was secured and the patient began to work with the joint himself. From that time on the joint gradually re-

sumed all its functions and at the end of six months he was driving his Ford as swiftly as before.

The *wrist* should be treated conservatively. A loose carpal bone may require removal or partial resection. Amputation will be required if healing is obviously out of the question (Fig 260).

Compound dislocations of the *knee-joint* are very rare. If conservatism fails, amputation is the only alternative.

Ankle and Tarsus.—These dislocations are frequent and require much attention. Antiseptic foot baths serve an excellent purpose though the primary cleansing must be especially vigorous. The tarsal bones may need to be sutured to be retained in place. Especial care must be taken not to interfere with the circulation (see page 288, compound fractures).

CONTUSIONS OF THE KNEE-JOINT

These are so frequent as to call for a special word. The aim is to avoid an acute synovitis, which may become suppurative. In milder cases, rest in bed with some mild liniment and light massage will be sufficient, and the pain and stiffness will rapidly subside.

In the severer cases, indicated by pain and swelling, more active measures must be instituted.

Wrap the joint in absorbent cotton and apply a plaster bandage for two or three days. The uniform pressure will limit the effusion and hasten its absorption. After that you may begin hot sponging and very gentle passive motion with massage, applied at first only to the muscles moving the joint, and afterward, as the tenderness subsides, to the joint itself.

PUNCTURE AND STAB WOUNDS OF THE KNEE-JOINT

The treatment will depend largely on the instrument which inflicted the wound and the appearance of the wound. If the wound is clean-cut, and the instrument presumably non-septic, content yourself with sterilizing the field of the wound, enveloping the knee in an antiseptic compress and putting the joint at rest, preferably in a plaster splint. You will anxiously watch the temperature. If it does not rise within three or four days, one may cease to fear infection, and such swelling as appears is not significant.

It is quite different when the temperature begins to rise and the local symptoms gradually increase, or if the wound is seen after some days of neglect and the symptoms of infection are fully developed.

Under these circumstances, there must be no delay. Immediate operation is imperative; it is indicated to do an arthrotomy, disinfect and drain (see page 440).

This treatment, early and properly applied, will save the joint. As infection subsides, the drainage is gradually withdrawn.

There are cases, however, in which, unfortunately, even these strenuous measures fail. In spite of immediate recognition of the urgency, and immediate action, laying open the joint with the utmost freedom, followed by repeated irrigations—in spite of the utmost endeavor, the symptoms of grave general infection persist and it is necessary to amputate. This may save the patient's life—more often it will not.

EXTENSIVE INCISED OR LACERATED WOUNDS OF THE KNEE-JOINT

In these cases, it is never sufficient merely to cleanse the skin and seal the wound with antiseptic dressings. The wound must be enlarged, thoroughly cleansed, and the joint cavity irrigated with sterile water or normal salt solution and wiped dry with sterile gauze.

After the complete disinfection, the wound in the capsule is sutured and, perhaps, also the skin. More frequently, however, one will feel safer to leave drainage in the skin wound. The joint is immobilized, and if everything goes well, the drainage-tube is removed after forty-eight hours.

SPRAINS

In general, these conditions are to be treated by firm bandaging for two or three days, to limit the swelling and hasten the absorption of the effusion; and then massage and slight passive motion are begun. It is better to give the joint functional rest until at least the greater part of the pain has subsided.

The *ankle-joint* is more frequently sprained than any other, partly on account of its construction and partly on account of its function. The weight of the body falls on the insecurely poised foot and the

ankle gives way under the load. The ankle usually bends outward and the external lateral ligaments are subjected to great strain. They are undoubtedly often lacerated or the capsular ligament may be torn. The pain in the severe cases is immediate and intense; the patient may faint. If the joint is continued in use, the swelling is aggravated, but in any event swelling rapidly ensues.

Morphine may be necessary to relieve the pain. If seen at once, the ankle is immobilized in plaster of Paris for a few days, or bandaged tightly with a flannel or rubber bandage, or strapped with adhesive plaster, after which massage and passive motion are employed. The patient should walk with crutches at first. The joint will be stronger than if it was used before the pain and swelling had subsided, although excellent authorities advise walking from the first.

If adhesive strips are used, in order to avoid circular constriction, apply them in this manner: cut the adhesive strips $\frac{1}{2}$ inch wide and in two lengths, 12 and 18 inches.

(1) Begin with one of the long strips in front of the big toe, carry the strip back around the heel, keeping just above the contour of the sole, and bring the strip back across the dorsum of the foot to the starting-point. Overlap with this a similar strip. Both should be tightly drawn.

(2) Begin with one of the shorter pieces above the ankle and carry it under the heel to the opposite side.

The subsequent strips are applied alternately in this fashion, each overlapping the one preceding, until the foot is practically covered.

The whole is then enclosed in an ordinary roller bandage and the foot kept quiet. After two or three days, the patient may begin to move around a little, but the dressing must be left on till the pain and swelling have subsided. It may be reinforced by additional strips placed over the loose ones.

The manner of giving massage is also important. In the case of a tender joint, begin by gently stroking the healthy tissues just above the joint in the direction of the blood and lymph currents, and gradually approach the joint. The movements are gradually made more vigorous, using the palmar surface of the hand. After a few minutes of this work, the joint will usually permit a direct manipulation and finally slight passive movement is begun.

RUPTURE OF THE CRUCIAL LIGAMENT OF THE KNEE

An injury to the knee-joint often diagnosed as sprain, is rupture of the crucial ligament of the joint. This injury happens when violence is applied to the flexed joint at which time the anterior ligament is very tense.

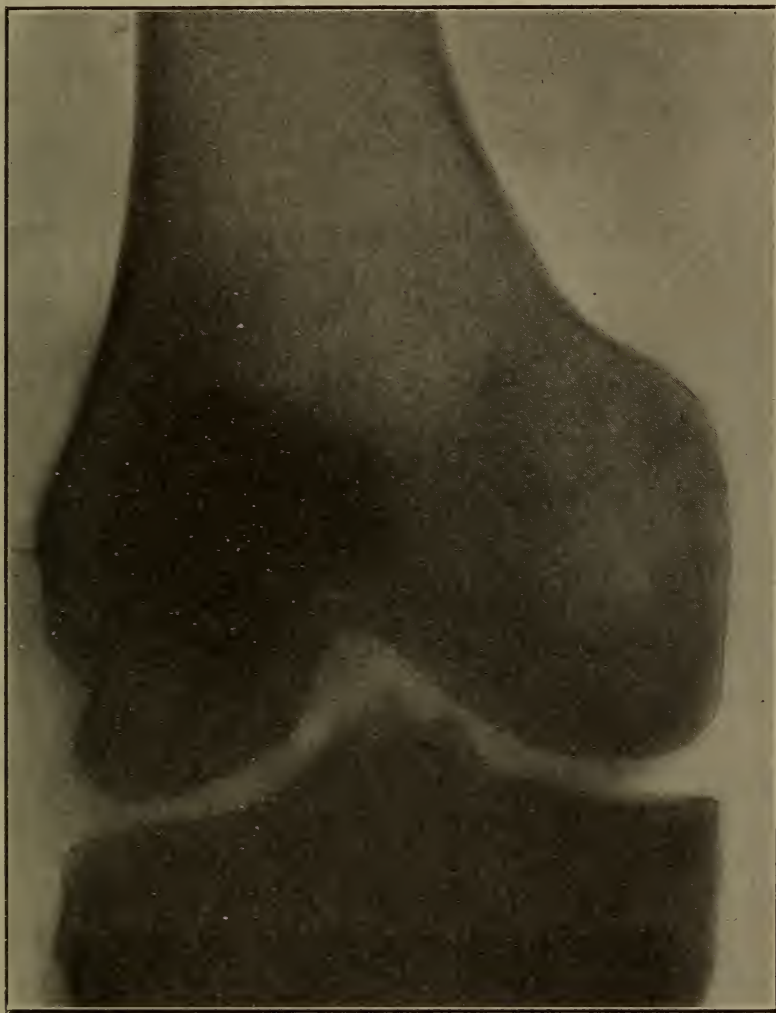


FIG. 261.—Rupture of the crucial ligament due to lateral blow on flexed knee. The X-ray usually shows a portion of the tibial spine wrenched off.

Turning suddenly on the flexed knee may produce the same result. The pain and disability are out of all proportion to the apparent injury, but the swelling is not extreme. The X-ray will usually indicate the nature of the trouble not because the ligaments cast a

shadow, but because some fragments of the bony attachments are avulsed. In fact in some cases "fracture of the tibial spine" is the better diagnosis (FIG. 261).

Prolonged fixation in plaster is the proper treatment. Massage, manipulation, or limited use should not begin until repair is practically complete, which will require at least two months; and even after that, a splint permitting restricted motion only may need to be worn.

CHAPTER XIX

INJURY AND REPAIR OF TENDONS

There are three kinds of injuries to tendons which it is practical to consider as emergencies: dislocated tendons, subcutaneous rupture, and divided tendons.

Dislocation of Tendons.—Dislocation is not a frequent injury, and yet it occurs and is to be considered as a possibility in making a diagnosis of disturbances of function after certain joint accidents. Every sprain should be examined with this point in view.

The tendons most frequently dislocated are those of the *peronei* muscles, especially the *brevis*. Following a severe wrench of the ankle, it is torn out of its sheath behind the external malleolus and carried forward onto the malleolus, where it can be felt and moved.

It is easily replaced, but it is with more difficulty retained. The ankle must be immobilized at a right angle to relax the calcaneo-fibular ligament, and the tendon retained by pressure until the ruptured tendon sheath or lateral ligament is healed, which will require about four weeks. It will sometimes be necessary to expose the tendon and repair the rupture tissues.

The *long tendon* of the *biceps* may be wrenched from its groove in the humerus and the loss of function and prominence of the head of the humerus may suggest dislocation of the humerus. As a rule, the tendon is easily replaced by a little manipulation, but the usefulness of the arm will be impaired for a long time.

The other tendons of ankle and wrist occasionally may suffer similarly, but not seriously.

Subcutaneous Rupture.—Subcutaneous rupture is especially likely to occur with the tendon of the quadriceps extensor or triceps cubiti or the tendo achillis. A sudden violent effort is the usual cause.

The pain, the loss of function, the gap between the ends of the ruptured tendon, and the history of sudden muscular contraction point to the nature of the injury.

There is only one logical treatment, viz.: by an incision to expose the tendon at once and by some of the methods shortly to be described, reunite the parts by suture. It is the duty of the doctor to insist on nothing less (Fig. 262). But it must be remembered that the synovial sac is peculiarly susceptible to infection and the skin over the patella difficult to sterilize.

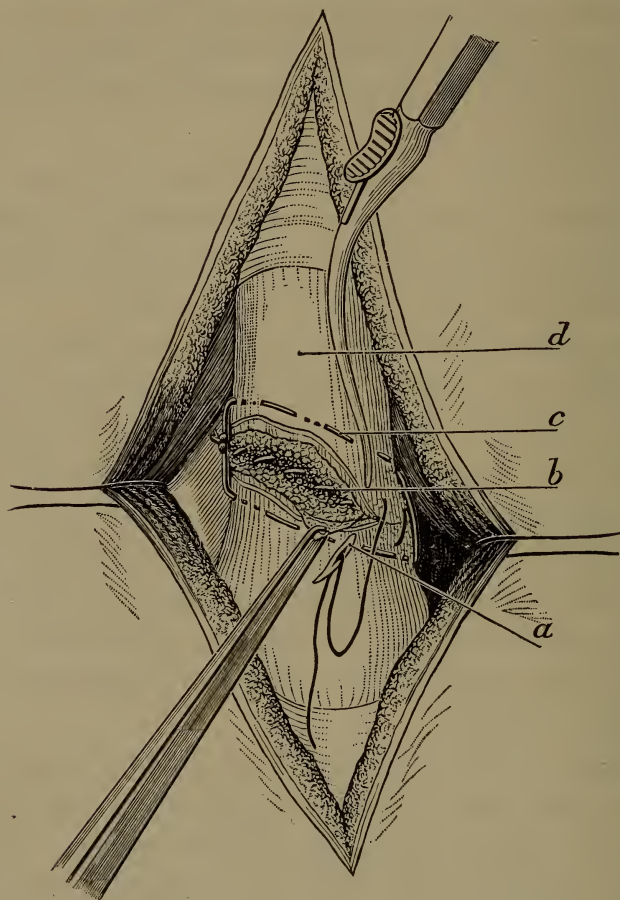


FIG. 262.—Repair of ruptured tendon of quadriceps extensor femoris. *d*, tendon; *c*, basting stitches; *b*, sutures uniting posterior edges; *a*, sutures uniting anterior edges of ruptured tendon. (*Bryant.*)

If this procedure is not followed, it remains only by position, rest, and massage to favor repair, which, at the best, will be uncertain and slow.

The position must be such as to relax the muscle, the limb must be immobilized, and after the first few days massage must be begun and carried out systematically.

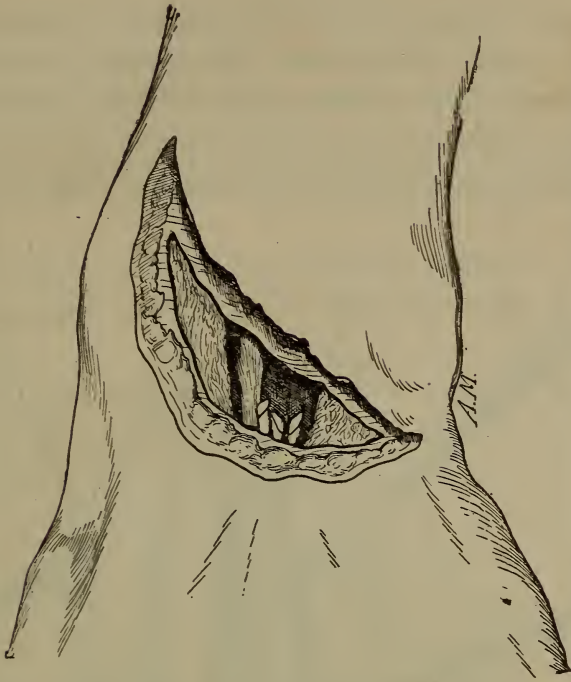


FIG. 263.—Incised wound of back of wrist. Divided tendons exposed. (*Veau.*)



FIG. 264.—“Expression” of retracted end of divided tendon by forced flexion and compression of forearm. (*Veau.*)

The history of a case reported by Gage, of Worcester, Mass., is typical. A man, fifty-seven years old, slipped and fell with his left knee doubled under him. He could not lift his leg from the ground. Examination an hour later showed a gap 6 cm. wide between the upper border of the patella and the retracted edge of the quadriceps tendon.

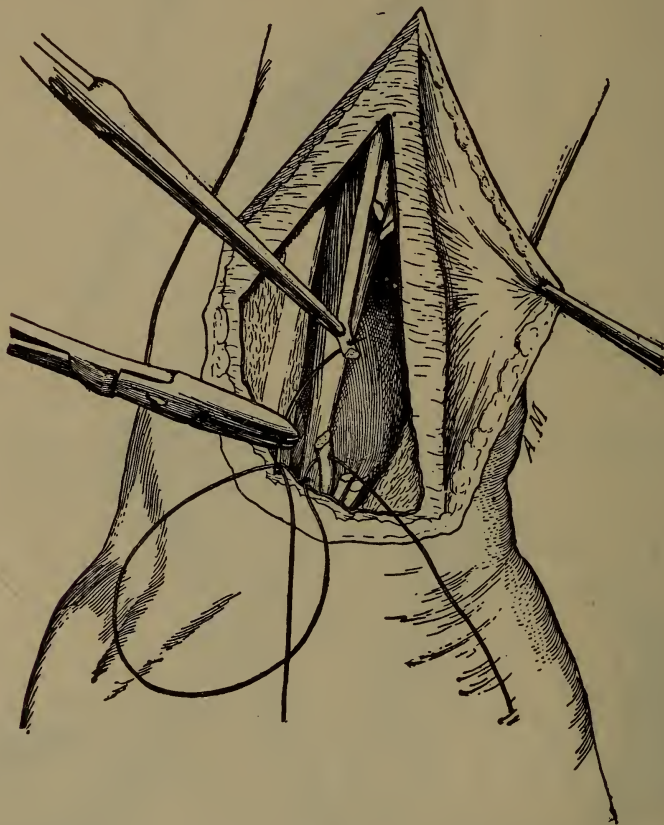


FIG. 265.—Exposure of tendons by enlarging wound in aponeurosis. Suturing tendons. (Veau.)

Operation.—A transverse incision was made across the front of the knee and the ruptured tendon exposed. The rupture was complete except for a few fibers on the outer edge. The joint was exposed, the clots wiped out. The edges of the tendon were then carefully coapted with interrupted catgut sutures. The leg was put up in plaster-of-Paris splint for seven weeks. After that it was massaged daily and the splint definitely removed at the end of twelve weeks. The leg became as strong and flexible as before the accident.

Divided Tendons.—These are found frequently, especially at the wrist. *They must be immediately sutured* for then it is relatively easy. Later they retract or acquire adhesions and it is difficult to approximate the two ends, and one must have recourse to special maneuvers.

Use No. 1 or No. 2 silk or chromicized catgut. A small curved needle or a straight sewing needle will serve.

Begin by carefully disinfecting the wound and securing complete hemostasis. The lower ends of the divided tendons will usually be found near the lower lip of the wound (Fig. 263). Identify each and count them to be sure none have been overlooked. At the same time, see if a nerve has been divided. Look for the others of the divided ends. If they are not in sight, do not reach blindly for them with forceps, but attempt to bring them into view by “expression,” and if this fails, boldly enlarge the wound.

Expression.—Direct the assistant to grasp the member above the wound with both hands and the pressure may force the tendons into view. If the extensor tendons are involved, employ forced flexion with the pressure. These muscular groups are more or less unified and the undivided tendons put on the stretch help to drag the divided tendons into view (Fig. 264).

If this method does not succeed, apply a roller bandage, beginning at the elbow-joint in the case of the upper extremity; at the knee in the case of the leg or foot, and carry it down to within an inch of the wound. If this, too, fails, make a *free incision* observing this point;

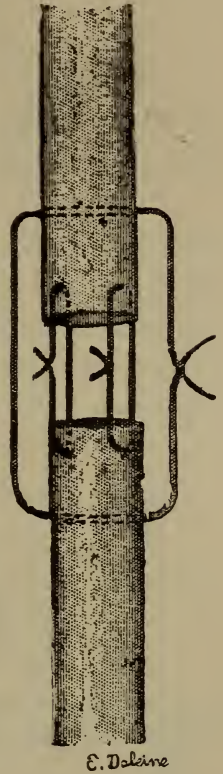


FIG. 266.—One method of suturing tendon of medium size. (Veau.)




FIG. 267.—Method of introducing suture for divided tendon. (Marsee.)

wound. If this, too, fails, make a *free incision* observing this point;

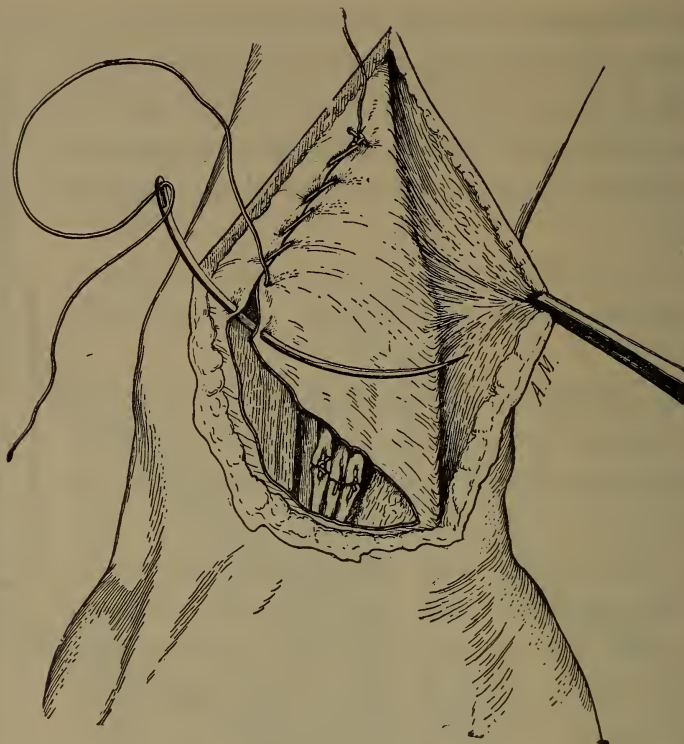


FIG. 268.—Suture of tendons completed. Repair of aponeurosis. The aponeurosis should not be divided directly over the tendons else adhesions may occur. (Veau.)

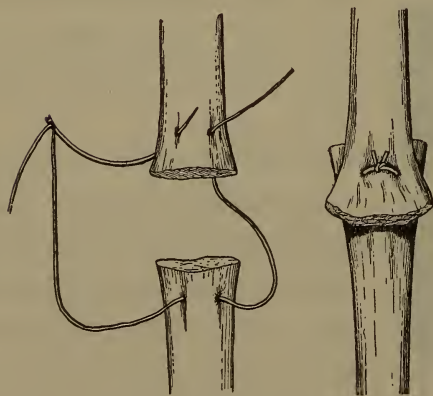


FIG. 269.—Suture of a flattened tendon. (Veau.)

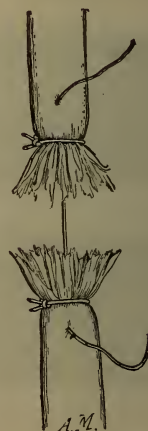

FIG. 270.—Suture of a lacerated tendon. (Veau.)

do not make the incision directly over the tendon for it may later acquire adhesions to the scar tissue, interfering with its free movement. Generally with a little patience the tendon is found. It is often practical after incising the skin to make a diagonal incision of the deep fascia or two incisions at a right angle, creating a flap which may be dissected up and the tendon group well exposed (Fig. 265).

Suture of the Tendon.—(A) *The tendon is round*, as at the level of the wrist-joint. Seize the tendon with a dissecting forceps, being careful not to bruise it. Pass a suture through the whole thickness $\frac{1}{4}$ inch from the end (Fig. 266), entering the superficial surface and emerging on the deep surface of the segment and carrying it then to the other part; entering the deep surface and emerging on the superficial surface. The ends of the divided tendon are then coapted and the suture tied.

The suture may be passed laterally instead of antero-posteriorly. If the ends of the tendon come together well, a suture may be entered $\frac{1}{2}$ inch from the divided end and passed obliquely in such a manner that it emerges from the cut surface and then is passed into the cut surface of the opposite end and emerges symmetrically with the original point of entrance. Marsee advises passing a separate suture three times through the tendon, tying the corresponding ends (Fig. 267).

Repair the wound in the deep fascia by a continuous suture, being assured once more that no nerve is divided (Fig. 268).

(B) *The tendon is flattened*. In this case, the ends must overlap. Make a latero-lateral anastomosis; pass the suture through the lower end from before backward, beginning near one border. Next pass the suture through the upper end from before backward and again from behind forward. Finally pass the suture from behind forward through the lower end. When the suture is ready to tie, the lower end overlaps the upper (Fig. 269).

(C) *The tendon is shattered or lacerated*. In this case before suturing tie a firm ligature around either end, which will prevent the suture from pulling out (Fig. 270).

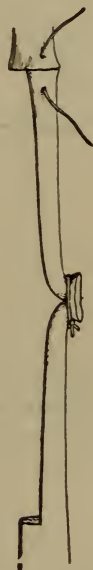

FIG. 271.—
Method of
elongating a
tendon.

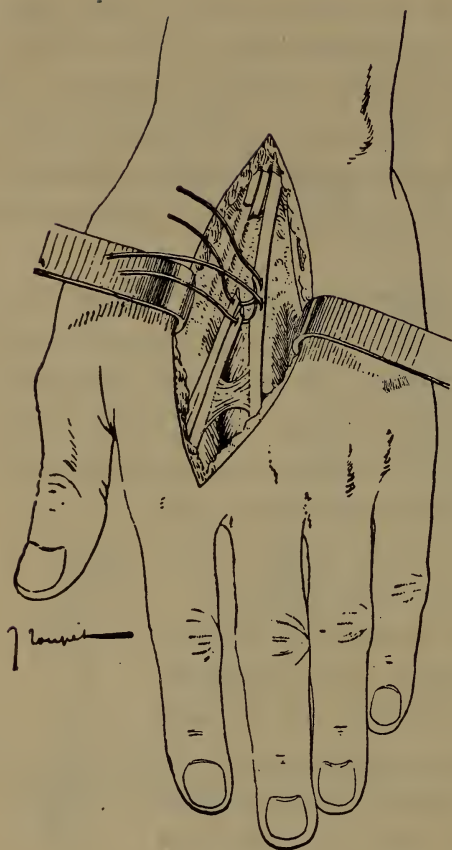


FIG. 272.—Suture by double anastomosis when the two ends of the divided tendon cannot be brought in contact. (Veau.)

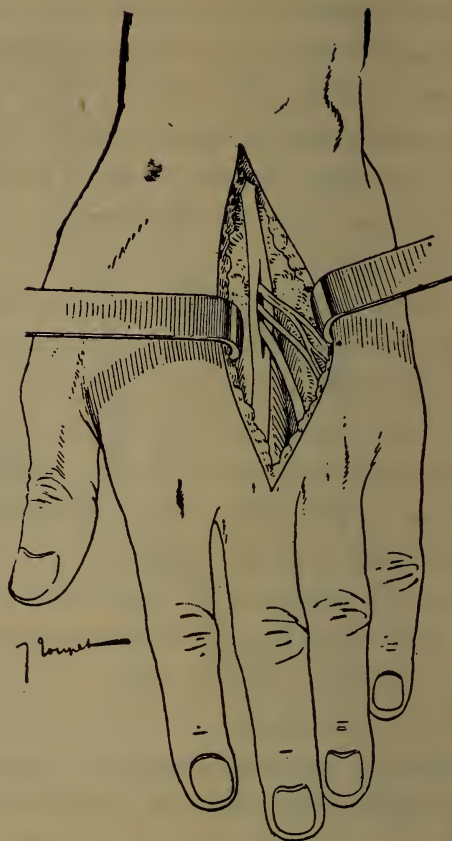


FIG. 273.—The upper end cannot be found. Suture to adjoining tendon. (Veau.)



FIG. 274.—The long extensor of the thumb divided, the upper end lost. The adjoining tendon is split and one segment sutured to long extensor. (Schwartz.)

(D) *The tendon is voluminous.* In this case it is better to vary the method a little. Pass the transverse suture as in Fig. 266. Before tying the suture, the posterior lips are drawn together as neatly as possible. When these sutures are all tied, finally suture the anterior lips together. Over all suture the deep fascia. The transverse suture must be strong, No. 3 silk for example, though the others may be finer.

(E) *The ends cannot be approximated.* This will not happen except in the neglected cases. Two procedures are practical.

(1) The space may be bridged by sutures, which will favor reunion by scar tissue. Begin by ligating both ends (Fig. 270) and then pass three to six sutures as the one is passed in the figure.

(2) The space may be bridged by splitting the upper tendon in the manner indicated in Fig. 271. Before the tendon is split, it

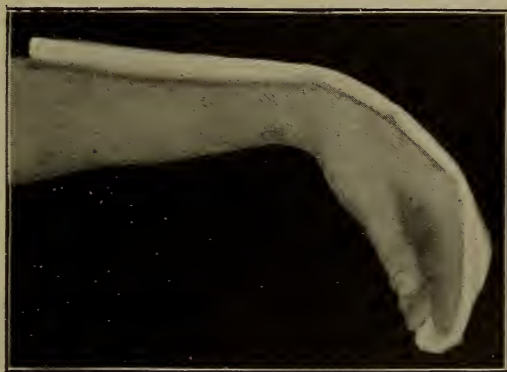

FIG. 275.—Plaster splint applied to maintain flexion.

must be ligated near its end. In the case of the tendo achillis, it may be lengthened by making several half cross sections at different levels, first one side and then the other.

(3) The two ends may be sutured to a neighboring tendon (Fig. 272).

(F) *The upper portion of the divided tendon cannot be found.* In this case, buttonhole a neighboring tendon, selecting one nearest resembling in function the divided one. Into the slit pass the end of the divided tendon and fasten with one or two sutures. The divided tendon should be slightly on the stretch when the suturing is completed (Fig. 273).

The healthy tendon may be split and the separated portion sutured to the divided tendon (Fig. 274).

Drainage.—Drainage is necessary if the wound was accidental. A small drainage-tube is left beneath the skin. The fascia has been completely closed. Apply a dry antiseptic and absorbent dressing.

Immobilize the part in a position, flexion or extension, to relax the tendons. If necessary, apply a plaster bandage over the dressing. An excellent splint is made by taking a plaster roller, properly soaked, and folding it back and forth, pressing the folds carefully together until a five- to eight-ply splint of proper width and length is made. This is slightly padded, bandaged in place and held at the necessary degree of flexion till the plaster hardens (Fig. 275).

CHAPTER XX

INJURY AND REPAIR OF NERVES

THE REPAIR OF DIVIDED NERVES

It is imperative to suture a divided nerve as soon as the condition is recognized. If the repair is made at once it is more easily done than the suture of tendons, for the ends are not so widely separated; but, on the other hand, it is more delicate work, for the trunks are smaller.

Do not handle these tissues roughly and, above all, do not cleanse the wound with strong antiseptics, such as bichloride and carbolic acid.

Remember that the upper part of the nerve retains its sensitiveness and in it are the essentials of repair. The lower segment degenerates if repair is neglected.

It is usually necessary to freshen the ends, but one must be very sparing of the tissues, removing less than a millimeter from each extremity, using fine sharp scissors. It is better to make the section oblique (Fig. 276).

Pass a silk (No. 0) suture or a small catgut with a round needle through the whole thickness, as in the case of a round tendon (Fig. 277), draw the ends together and complete the repair by suturing the lips, passing the suture through the nerve sheath only (Fig. 278). Adjust the ends exactly and always where possible make the suture an end-to-end one.

Repair the various layers of fascia with great care, so that the sutured nerve may be isolated and removed from the sources of infection. Employ drainage in suturing the skin.




FIG. 276.—Oblique section of the nerve ends.

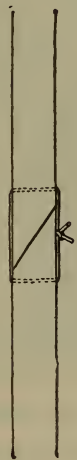

FIG. 277.—Through and through suture of nerve.
(Veau.)

For the rest, the treatment is the same as for any other wound.

Secondary Suture.—It may be found necessary to suture a nerve some time after the injury, and this operation will present difficulties. The ends may be separated or they may be imbedded in scar tissue.

A knob often forms on the proximal stump. In such a case, freshen the ends and pass the suture in the manner pictured (Fig. 279).

If the two ends are attached by a fibrous cord, split the scar tissue longitudinally (Fig. 280), and transform the longitudinal fissure into a transverse one and suture (Fig. 281). If the ends cannot be approximated or bridged they may be sutured at different levels to a neighboring nerve in the manner described under Repair of Tendons.

Warn the patient that it may be a long time before function is even partially restored. In the meantime, muscular atrophy must be prevented by persistent use of electricity, and massage.

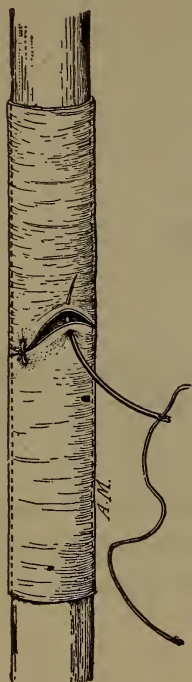


FIG. 278.—Suture of nerve through the sheath. (Heath.)

CONTUSION AND COMPRESSION OF NERVES

These injuries to nerves are by no means infrequent, following blows, gunshot wounds, machinery accidents, fractures, and dislocations.

The *symptoms* vary from slight tingling to complete loss of function. The loss of function is often a later development, due to a neuritis following the contusion, and is accompanied by neuralgia, muscular palsy and trophic alterations corresponding to the distribution of the nerve.

Treatment.—The immediate indications are to restore the parts to their normal condition as much

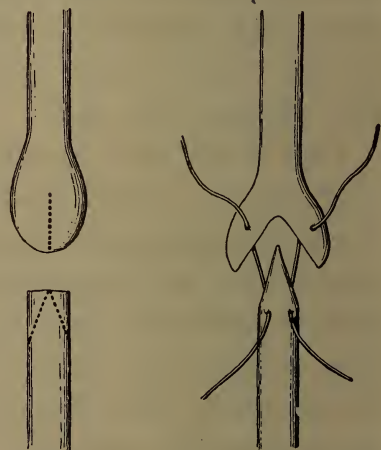


FIG. 279.—Secondary suture. Method of coaptation. (Veau.)

as possible, and to relieve the pain by hypodermic injections of morphine or by phenacetine and codeine. The nerve must be put at rest by immobilizing the limb. Later, alteratives, electricity, and massage are useful.

INJURIES TO INDIVIDUAL NERVES

Facial Nerve.—The facial is more frequently injured than any other cranial nerve: in fracture of the base of the skull; in the mastoid operation as it passes through the temporal bone; by shots and blows at its exit from the styloid foramen. Depending upon the distance of the lesion from the central origin of the nerve, there occur paralysis of the muscles of expression, disturbance of salivary secretion and the sense of taste, and paralysis of the palatal muscles. Injury to the facial nerve is often accompanied by injury to the abducens and auditory nerves.

To Expose the Facial Nerve.—The incision begins behind the external auditory meatus and extends downward and forward to the angle of the lower jaw.

Divide the integument, superficial fascia and the first layer of the deep fascia. This exposes the parotid gland, the sterno-cleido-mastoid and the mastoid process. The posterior auricular nerves and the vessels are to be avoided. Carefully dissect and draw forward the part of the gland exposed and the posterior belly of




FIG. 280.



FIG. 281.

The two ends of the nerve are connected by a fibrous cord which is split longitudinally and sutured as indicated. (Veau.)

the digastric appears, just above which the nerve lies upon the styloid process.

Optic Nerve.—The optic nerves are injured most frequently in connection with fracture of the base of the skull involving the anterior fossa, and especially when the fissure involves the optic foramen for there the nerve is firmly attached to the bone.

As a consequence of such injuries, there may be compression, laceration, or extravasation into the nerve sheath. As a result of these injuries, there are disturbances of vision of various degrees. *In obscure trauma of the brain, the ophthalmoscopic examination of the fundus of the retina should never be neglected as a means of diagnosis.*

Motor Oculi Nerve.—The motor oculi nerve may be injured by wounds penetrating the orbit and by fractures of the base. Its function may be disturbed by pressure following the rupture of the middle meningeal artery and often the only indication of this disturbance is a dilated pupil and drooping of the eyelid.

Patheticus and Abducens.—These nerves are often injured along with the third, producing loss of rotation and abduction of the eye ball.

Fifth Nerve.—The fifth nerve is rarely injured alone, but injury of single branches may occur.

“The usual consequence of anesthesia of the trigeminals following cranial injury is so-called keratitis neuroparalytica.”

Auditory Nerve.—The auditory nerve is rarely injured without other serious lesions, and since traumatic disturbances of hearing may be due to injury to the labyrinth or tympanum also, a diagnosis of injury to the nerve trunk must be uncertain.

The pneumogastric may be divided or contused by bullet or stab wounds in the neck. The injury is not necessarily fatal, but may be followed by difficulty in respiration and deglutition or by pneumonia. When the symptoms point to injury an effort should be made to repair it. It is reached by the same operation as that for ligation of the common carotid.

The phrenic when divided gives rise to disturbances of the functions of the diaphragm, cough, difficult respiration.

The recurrent laryngeal when divided gives rise to hoarseness and aphonia. If injured, an attempt should be made at repair. Laryngeal spasm may require a tracheotomy.

Median Nerve.—The median nerve is likely to be divided by stab- or gunshot wounds and may be exposed in any part of its course.

Injury to the median nerve results in impaired flexion of the hand and fingers and movements of the thumb.

To Expose the Median Nerve.—(A) *In the middle third of the arm* (Fig. 282): Place the patient on the back with arms abducted to a right angle, the operator standing to the inner side of the arm.

With the two hands define the biceps muscle. Along the inner border of the muscle, following the known line of the nerve (from the

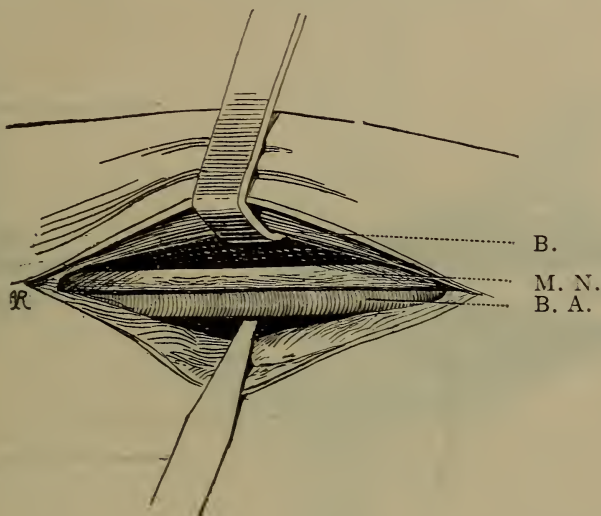


FIG. 282.—Exposure of the median nerve in the middle third of the arm. B. Biceps. M. N. Median nerve. B. A. Brachial artery. (Schwartz.)

middle of the axilla to the middle of the bend of the elbow) make an incision 2 or 3 inches long, dividing the skin and connective tissue. Divide the deep fascia over the biceps and open the sheath of the muscle. Isolate the border of the muscle and with the retractor draw it gently aside. Do not use force or the nerve also will be displaced or the musculo-cutaneous may be exposed instead of the median.

Now incise the deep layer of the muscle sheath exactly in the line that was occupied by the border of the muscle and the nerve is exposed lying a little to the inside of the vessels.

(B) *At bend of elbow* (see Brachial Artery).

(C) *In the upper third of the forearm* (Fig. 283): The incision begins

a little below the bend of the elbow, is 2 or 3 inches in length, and follows the line of the nerve, which lies in the middle line from the elbow to the wrist. Divide the skin and ligate the two superficial veins. Under the deep fascia define the external border of the pronator radii teres and over this border incise the aponeurosis and retract the muscle.

The nerve is immediately exposed, together with the ulnar artery, which crosses beneath it, running obliquely toward the inner border of the forearm.

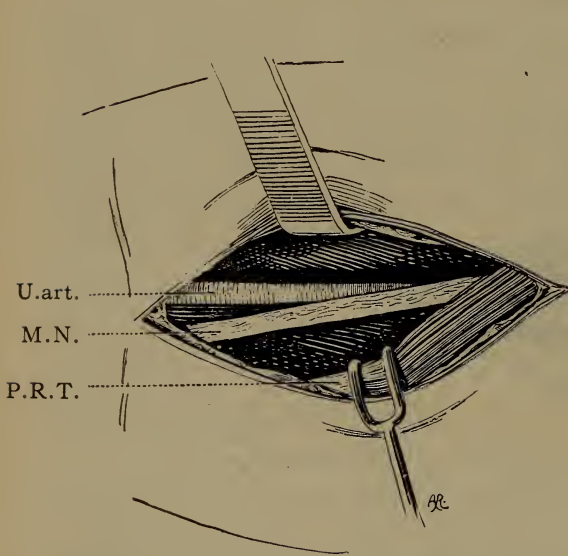


FIG. 283.—Exposure of the median nerve just below the elbow. The pronator radii teres (P. R. T.) drawn inward exposing the median nerve (M. N.), the ulnar artery (U. art.) being at outer side. (Schwartz.)

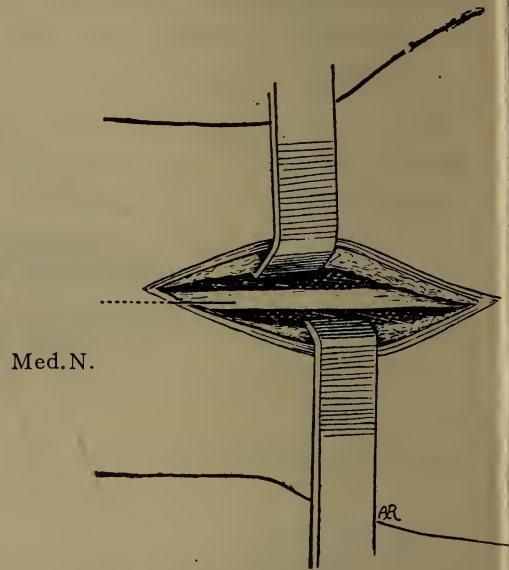


FIG. 284.—Exposure of the median nerve at the wrist. (Schwartz.)

(D) *At the wrist* (Fig. 284). Make an incision 2 inches in length in the middle line, the middle of the incision corresponding to the crease of the wrist. Divide first the skin and the fascia and then, very carefully, the anterior annular ligament, guarding the synovial sheath of the flexor tendons. Retract the lips of the wound, and the nerve is exposed, easily distinguishable from the adjacent tendons by its fibrillated appearance.

The Ulnar Nerve.—The ulnar nerve may be divided anywhere along its course, but is more likely to be contused in the ulnar

groove. There also it may dislocated by forcible flexion of the forearm. The loss of function of this nerve results in inability to extend the distal phalanges, to adduct the fingers and to flex the little finger. Eventually the "claw hand" appears as a result of atrophy of the muscles.

To Expose the Ulnar Nerve.—(A) *In the arm:* Make an incision 2 or 3 inches in length along the line of the nerve, which extends from the middle of the axilla to the internal condyle. Divide the skin and superficial and deep fascia. The brachial artery is about a finger's breadth to the outside of the line of incision. Draw the

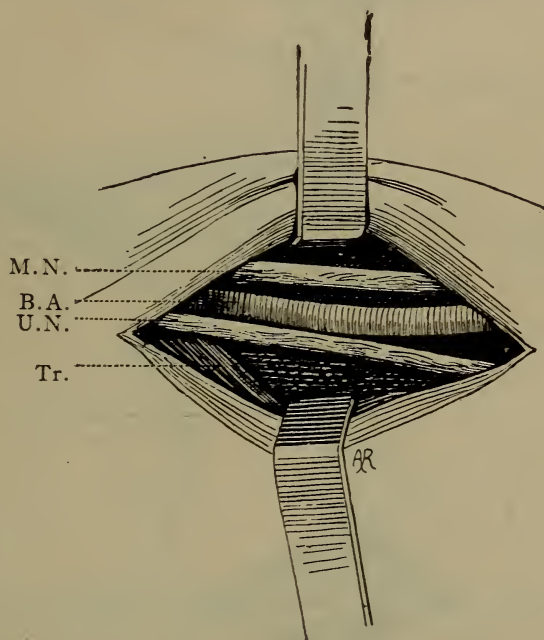


FIG. 285.—Exposure of the ulnar nerve in the upper third of the arm. M. N. Median nerve. B. A. Brachial artery. U. N. Ulnar nerve. Tr. Triceps muscle. (Schwartz.)

basilic vein to one side. Carefully divide the subjacent tissue beneath which is the ulnar and median nerves and the brachial artery; the ulnar nerve is to the inside and in contact with the long head of the triceps. (Fig. 285).

(B) *At the elbow* (Fig. 286): Place the patient on the back; abduct the arm; flex the forearm at a right angle; stand to the inner side of the arm and locate the inner condyle, the olecranon and the intervening gutter. Along the line of the gutter incise the skin and the

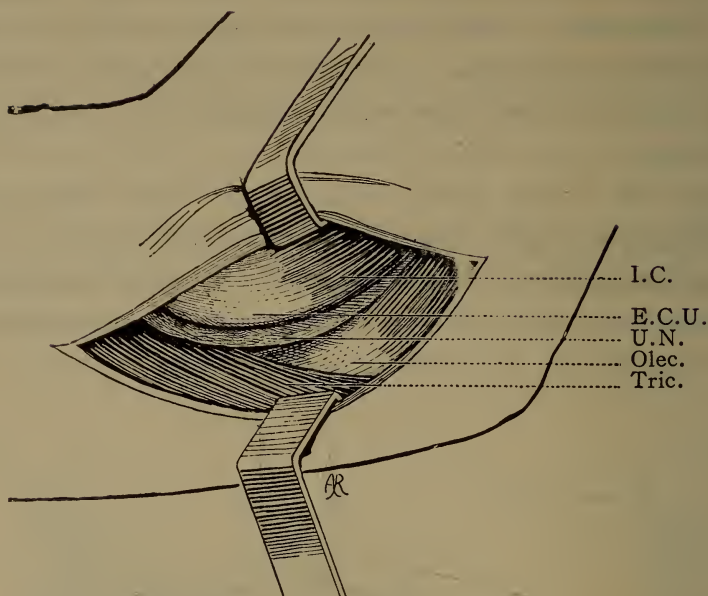


FIG. 286.—Exposure of the ulnar nerve at elbow. I. C. Internal condyle. E. C. U. Extensor carpi ulnaris. U. N. Ulnar nerve. Olec. Olecranon process. Tric. Triceps. (Schwartz.)

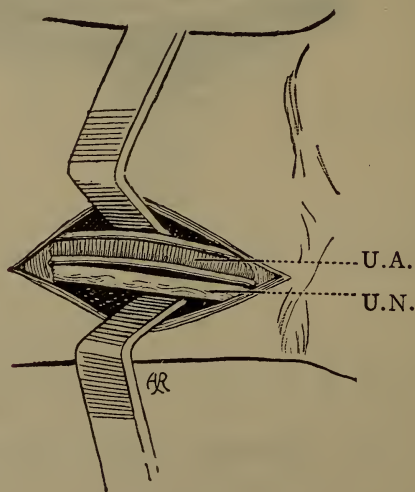


FIG. 287.—Exposure of the ulnar nerve at the wrist. U. A. Ulnar artery. U. N. Ulnar nerve. (Schwartz.)

(C) *In the lower third of the forearm:* Following the line of the nerve, from the internal condyle to the radial side of the pisiform, make an incision 2 inches long to the outside of the flexor carpi ulnaris, dividing the skin and superficial fascia. Retract inward the tendon of this flexor. Carefully incise the deep fascia and the nerve is exposed lying to the ulnar side of the ulnar artery.

fascias for 2 or 3 inches, and the nerve will be exposed, accompanied by the posterior ulnar recurrent artery.

(D) *In the wrist* (see Fig. 287).

Musculo-spiral.—The musculo-spiral, more than any other nerve of the arm, is subject to injury from stab, contused, or gunshot wounds or to fracture of the humerus. Very characteristic, too, are the symptoms resulting from its loss of function. The wrist and fingers cannot be extended and assume the attitude well known as the

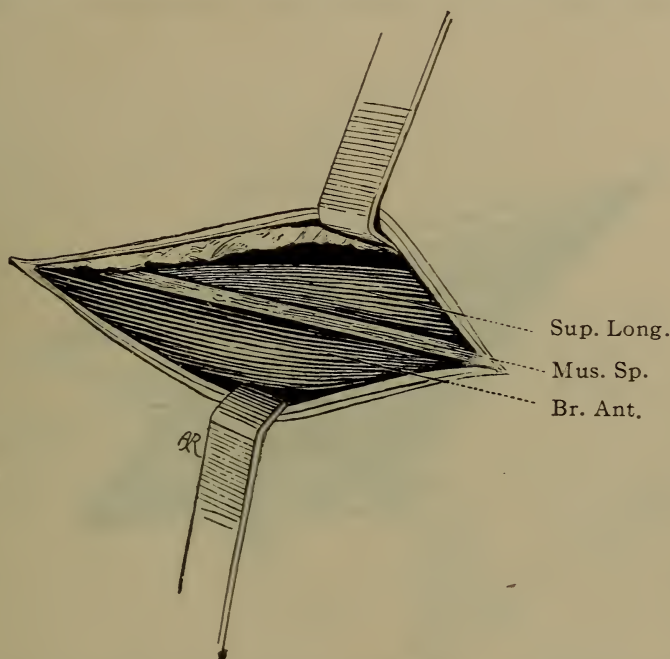


FIG. 288.—Exposure of the musculo-spiral in its lower third. The supinator longus is exposed and the nerve found to its inner side lying upon the brachialis anticus. (Schwartz.)

“drop wrist.” In every fracture of the humerus, the stability of this nerve should be tested. The nerve may be explored in any part of its course, but is most easily reached at the outer side of the arm just above the elbow.

To Expose the Musculo-spiral.—*In the lower third of the arm* (Fig. 288): The arm is abducted, the forearm extended and the hand supinated. Stand to the outside of the limb. In the line of the nerve, a line drawn along the middle of the external surface, beginning half-way between the shoulder and elbow and extending to a point $\frac{1}{2}$ inch from the center of the bend of the elbow, make an

incision 2 or 3 inches in length through the skin and superficial fascia. Retract the cephalic vein. Divide the deep fascia along the border of the supinator longus and expose the muscle fully. Retract it to the outside. At the bottom of the wound is the nerve lying upon the brachialis anticus (see page 139, Gunshot Wounds).

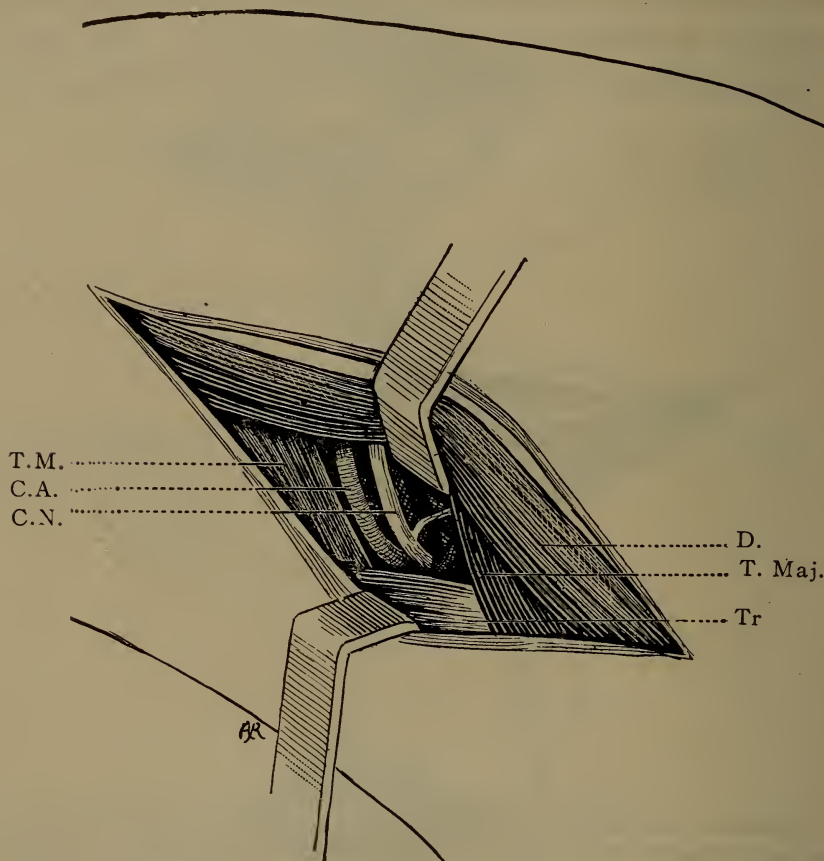


FIG. 289.—Exposure of the circumflex nerve. D. Deltoid. T. M. Teres minor. Tr. Triceps. T. Maj. Teres major. C. A. Circumflex artery. C. N. Circumflex nerve. (Schwartz.)

Circumflex.—In addition to such injuries as may be due to stab or gunshot wounds, the circumflex is liable to be lacerated in violent wrenching or in dislocation of the shoulder-joint.

The immediate result is loss of power to abduct the arm through paralysis of the deltoid. The nerve may be exposed as it winds around the humerus just below its head.

Operation.—The course of the nerve is in a line drawn from the inner end of the scapular spine to the point of insertion of the deltoid.

Place the patient on the sound side, exposing the shoulder well by rotating the arm inward a little and placing it in front of the trunk.

Along the line indicated make an incision 3 or 4 inches long, corresponding at its outer end to the acromion process, but an inch or two from it. This incision divides the skin and superficial and deep fascia and exposes the posterior border of the deltoid. Bring into view and draw upward this border of the deltoid.

Next locate the quadrilateral space, bounded above by the teres minor, below by teres major, posteriorly by the long head of the tri-

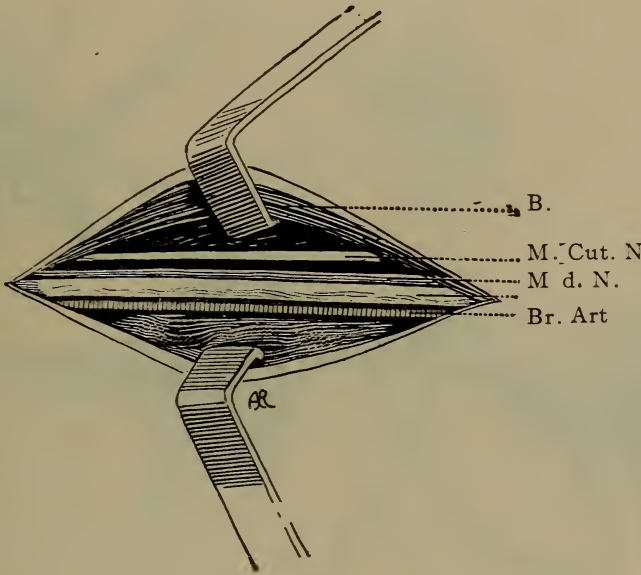


FIG. 290.—Exposure of the musculo-cutaneous nerve in the middle third of arm. The biceps (B) drawn outward exposes the nerve (M. Cut. N.) lying to the outside of the median nerve (Med. N.) and the brachial artery, Br. Art. (Schwartz.)

ceps, and anteriorly by the shaft of the humerus. By locating the tendons of these muscles define this space in which lie the nerve and the posterior circumflex artery (Fig. 289).

The musculocutaneous is exposed in the same manner as the median in the upper third of the arm (Fig. 290).

Anterior Crural.—The division of the anterior crural nerve means, among other things, loss of extension of the leg.

To outline it locate the spine of the pubes and the anterior-superior iliac spine, which points are connected by Poupart's ligament; under

this ligament a finger's breadth outside of its middle point the nerve passes (Fig. 291).

To Expose the Anterior Crural.—Make an incision from this point downward in the axis of the thigh, about 3 inches in length, dividing the skin.

At the upper end of the wound expose the lower border of Poupart's ligament. Immediately below this line, open up the sheath of the

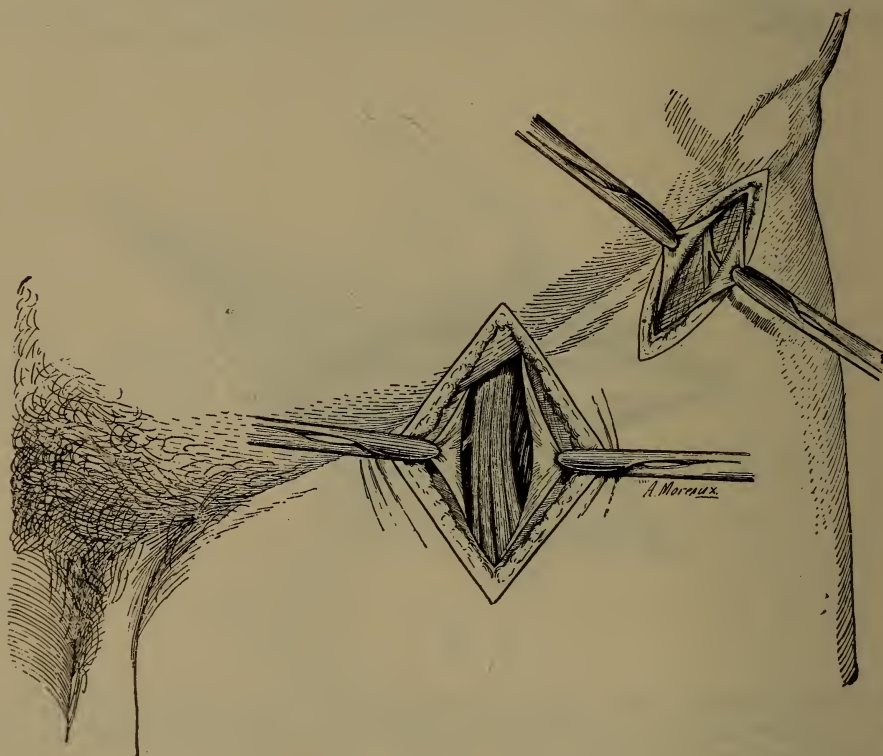


FIG. 291.—Anterior crural and external cutaneous nerves. (Labey.)

psoas magnus, pass a grooved director under the sheath, and divide it to the same extent as the skin incision. Separating the lips of the sheath wound, the nerve is seen lying on the fibers of the muscle and is to be distinguished by its whiteness and its subdivisions.

The Obturator.—If the obturator is divided, there follows loss of abduction of the thigh.

To Expose the Obturator.—Abduct the thigh until the border of the adductor longus can be clearly defined, and along this line make an incision 4 or 5 inches long, beginning an inch below the fold of the

groin, a little to the outside of the scrotal base. Divide the skin and superficial fascia, retracting to the outer side the internal saphenous vein, but ligating its cross branches (Fig. 292). Divide the deep fascia in the same line.

Separate the adductor longus from the pectineus by blunt dissection. A fairly well-defined gutter indicates the line of separation. Retract the two muscles and at the bottom of the upper part of the wound you will see the obturator nerve, consisting of a couple of flattened cords. Now extend the thigh to relax the abductors and

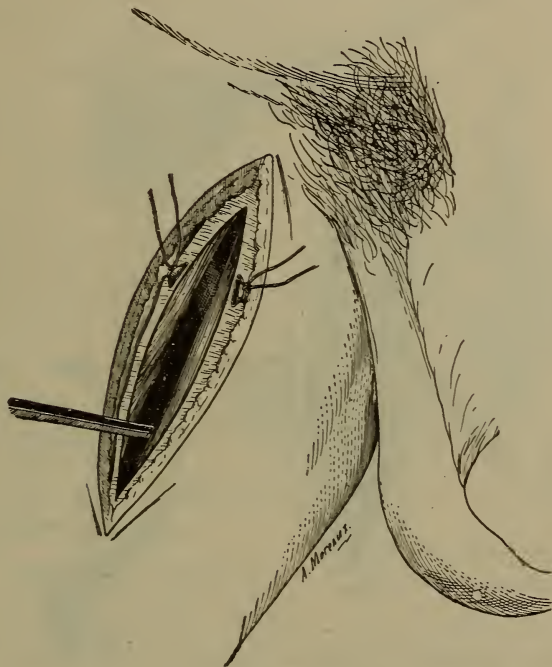


FIG. 292.—Exposure of the obturator nerve; separating the adductor longus from the pectineus. (Labey.)

separate more widely the two muscles mentioned and the nerve may be completely exposed, one branch lying upon the adductor brevis and the other passing under it (Fig. 293).

Ilio-inguinal and Genito-crural.—These nerves are frequently wounded in hernia operations, and may give rise to an obstinate neuralgia of the testicle requiring removal of this organ. In such a case an effort should first be made to repair the nerve or resect it.

The Sciatic Nerve.—The sciatic nerve may be injured in many

ways and from the functional point of view, these injuries are always serious. It may mean loss of extension of the thigh and complete paralysis of the leg.

It may be exposed at any part of its course down the back of the thigh.

Exposure in the Middle of the Thigh.—Place the patient face downward or on the sound side. Along the line of the nerve (a straight line extending from a point midway between the ischial tuberosity and the great trochanter to the middle of the popliteal space), make

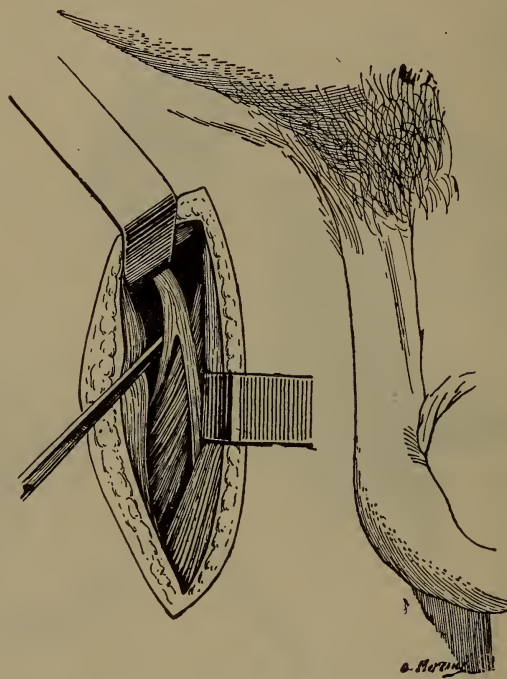


FIG. 293.—Obturator exposed. (Labey.)

an incision 3 or 4 inches long, dividing the tissues down to the deep fascia. Determine the interspace between the biceps and the internal hamstring, and over it divide the deep fascia and separate by blunt dissection the muscles of the space.

Flex the leg so as to relax them. They are then to be retracted widely and in the fatty tissues of the interval the nerve is usually easily found.

The External Popliteal, or Peroneal.—This nerve, like others, is liable to injury in fractures and wounds. When it is divided, “foot

drop" occurs. The patient cannot walk without stubbing the great toe and to prevent this, the whole leg is raised (steppage gait). This nerve bears an important relation to the knee-joint and to the tendon of the biceps.

To expose the peroneal behind the head of the fibula place the patient face downward or on the sound side. The line of the nerve corresponds to the tendon of the biceps, which may be palpated along the external border of the popliteal space, or the course of the nerve may be indicated by a line drawn from the tuberosity of the ischium to the head of the fibula. In this line, beginning at the neck of the fibula, make an incision upward 3 inches long, dividing the structures down to the deep fascia. Carefully divide the deep fascia over the tendon of the biceps and at once there comes into view the external popliteal, lying to the inner side of the tendon resting upon the external condyle of the femur above, and lower down winding about the neck of the fibula and disappearing in the peroneus longus.

To Expose the Musculo-cutaneous.—Place the patient upon his back, the knee flexed and rotated inward, and retained by a cushion placed under the thigh; in this manner exposing the external aspect of the leg.

The line of the nerve is drawn from the anterior border of the peroneal head to the anterior border of the external malleolus. Along this line, in the middle of the leg, make an incision 3 or 4 inches in length dividing the structures to the deep fascia.

Incise the aponeurosis of the peronei muscles, isolate the anterior border of the peroneus longus and draw it backward. The muscle may be previously relaxed by rotating the foot outward. The nerve will be seen resting upon the peroneus brevis (Fig. 294).

The Anterior Tibial Nerve.—The anterior tibial nerve is the

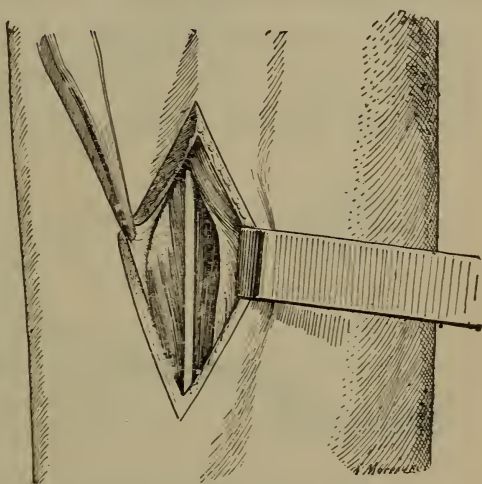


FIG. 294.—Musculo-cutaneous nerve lying upon the peroneus brevis. (Labey.)

continuation of the external popliteal nerve. The movements of flexion of the foot and extension of the toes depend upon this nerve.

To Expose the Anterior Tibial Nerve.—(A) *In the upper third:* Put the patient in the same position as for the musculo-cutaneous.

The line of the nerve is drawn from the front of the peroneal head to the middle of the anklejoint (Fig. 295).

In the line of the nerve make an incision beginning three fingers' breadth below the articular line of the knee. Divide to the deep fascia; next divide that and then patiently search for the intermuscular septum separating the wide tibialis anticus from the narrow common extensor. It will aid greatly in the search to seize with a forceps each of the lips of the wound of the sheath and retract. This will help to develop the line of cleavage.

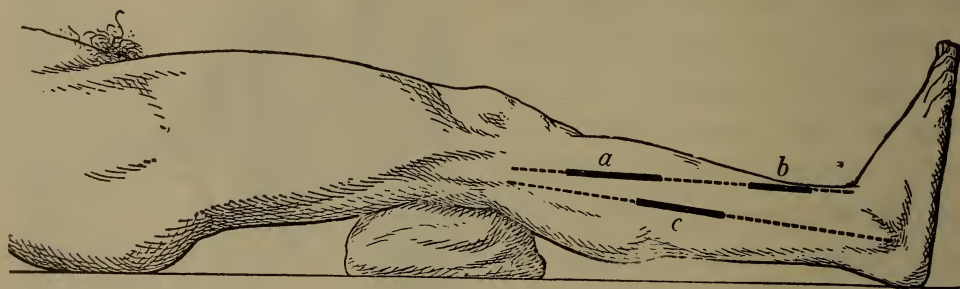


FIG. 295.—Lines representing the course (c) of the musculo-cutaneous; (ab) Anterior tibial nerves. (Labey.)

Remember that the tibialis anticus slightly overlaps the common extensor, so that the intermuscular space slopes inward and backward. Retracting the muscles, the nerve will appear as a small rounded white cord lying in front of the vessels.

(B) *In the lower third* (see Anterior Tibial Artery).

Posterior Tibial Nerve.—The posterior tibial nerve supplies the movements of the extension of the foot and flexion of the toes and may be wounded in any part of its course, although in the region of the calf it is deeply situated. Behind the internal malleolus it is superficial and easily exposed.

(A) *To Expose Upper Third.*—To expose the posterior tibial in the region of the calf is difficult (Fig. 296).

Position.—Place the patient on his back with the thigh in abduction

and external rotation, the knee flexed, and the foot lying upon its external border and held in this position by an assistant. Standing to the outside of the limb the operator with this arrangement can see quite well the internal surface of the leg.

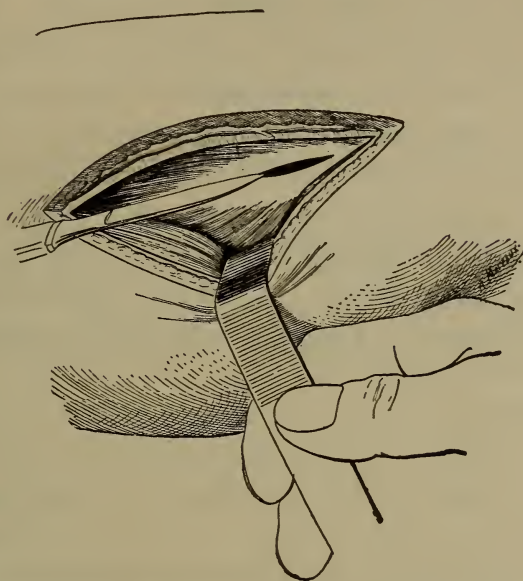


FIG. 296.—Exposure of the post. tibial nerve. Gastrocnemius retracted; soleus exposed. (*Labey.*)

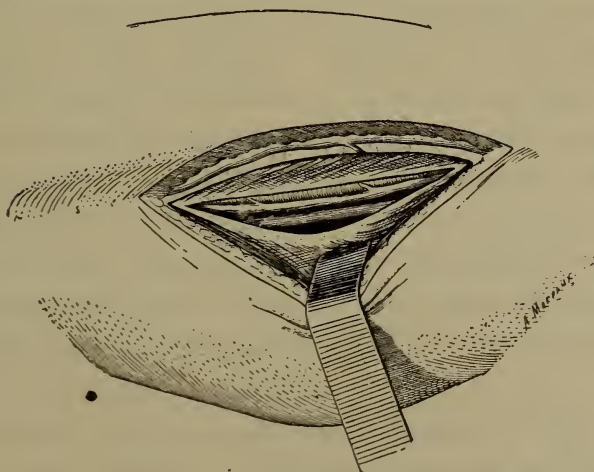


FIG. 297.—Fibers of the soleus divided and retracted, exposing deeply situated, the posterior tibial nerve and artery. (*Labey.*)

Locate first the sharp internal border of the tibia, and a finger's breadth behind it make an incision 4 inches long, beginning at the

level of the tuberosity. Divide the tissues down to the deep fascia, avoiding the internal saphenous vein, which lies close to the tibial border.

Slightly retract the posterior lip, which will include the gastrocnemius, and in this manner the soleus is exposed. Division of the soleus is the next step which must be carefully carried out. Divide it longitudinally, but further away from the tibia than the original incision. Cutting in this manner through the fibers of the soleus, the *yellow aponeurosis* covering the nerve and vessels is exposed (Fig. 297). It is important to expose this landmark well. Make an opening in it an inch and a half from the internal border of the tibia, and beneath the opening is the nerve, lying to the outer side of the artery.

(B) *Behind the ankle* (see Ligation of Posterior Tibial Artery).

CHAPTER XXI

ABSCESS

An abscess is a circumscribed collection of the liquefied products of infective inflammation.

There are two kinds of abscesses, differing in their etiology, clinical history, prognosis, and treatment. All these differences arise primarily in the nature of the infective agent. The acute abscess is due most generally to the activity of certain of the cocci. The chronic (or cold) abscess is nearly always due to the *Bacillus tuberculosis*. The chronic abscess may become infected secondarily with the germs of acute inflammation, in which instance it takes on the character of the acute abscess.

The content of the acute abscess is pus; that of the chronic abscess, though resembling pus, may be merely the liquefied caseated matter of the tubercle without any pus cells whatever. An acute abscess presents all the cardinal symptoms of inflammation: constitutional disturbance, pain, heat, redness, swelling, all in greater or less degree, depending on the locality. A chronic abscess may present none of these symptoms except swelling, and where swelling is not perceptible the abscess is frequently unsuspected. An acute abscess is of very rapid development—the chronic of quite slow growth, as a rule. An acute abscess demands immediate evacuation by free incision and drainage. The chronic abscess very often permits only of aseptic puncture, followed by the injection of detergent remedies, and aseptic occlusion.

Each occurs by choice in certain locations. The incision, the special dangers and details of treatment depend on the anatomy of the parts, so that the more common abscesses require individual consideration, and in that connection the general principles that underlie the subject may be elaborated.

The *prevention* of pus formation should be attempted in all acute

infectious inflammations by means of the timely application, in favorable localities, of hot antiseptic poultices or prolonged immersion in hot antiseptic solutions. Even though the treatment fails to prevent suppuration, it will at least limit it. Such an antiseptic poultice may be made by applying absorbent cotton soaked in hot boric acid solution and covering it with oiled silk or gutta-percha. In this manner heat and moisture are retained.

The old flaxseed-meal poultice is more often than not the breeder of germs and therefore distinctly non-surgical—a domestic make-shift. Some of the “antiphlogistic” glycerinated and sterile clay pastes often render an excellent service.

Treatment.—The evacuation of an abscess is by many regarded as a small procedure in minor surgery. It may be nothing more, and yet, as Lejars says, in certain cases it is a formidable task straining the resources of the most practised. It is an idea too long prevalent that there is a minor and a major surgery. There is only one kind of good surgery, whether the case is of great or little importance. It is that which recognizes the indications and meets them promptly, giving the patient relief with the least possible delay.

Abscesses have too much been regarded as simple conditions which the merest tyro might treat. We all know of patients who have died of these operations; of others who have been disabled by the failure to perform them, or by their being tardily or improperly done. And how often tardily done!

But what excuse can one make for delay after pus has definitely formed, for any attempt to bring about its absorption is futile. Delay merely means that the collection augments, destroys more tissues, acquires diverticula without end, which may need to be opened up time and time again, or may require months to heal, and eventually give rise to irremediable contractions and adhesions.

It is one of the most important and least varying rules of surgical practice that every acute abscess, superficial or deep, must as early as possible be *incised, emptied, and drained*.

Another point: do not wait for *fluctuation*, which is so commonly the practice. If the suppuration occurs in the deeper structures, fluctuation may be delayed. But there are ample indications

otherwise; the rapid increase of swelling, the radiating pains, fever, and subcutaneous edema give sufficient evidence that pus is present.

In certain regions, the thick and brawny skin and fascia is as significant as fluctuation itself. On the scalp, for instance, this brawny edema is a definite symptom of suppuration.

The edema is superficial; the suppuration, deep. The two processes go together and when the first is present, one may unhesitatingly diagnose the second.

To repeat, when the skin pits on pressure and is only slightly reddened even, the diagnosis is no longer doubtful and one may—one should—operate at once.

The *length* of the incision is of the greatest importance. Nothing is more unsatisfactory than the mere stab, or puncture, of an acute abscess. The incision, cutting through the middle, parallel with the most important structures, should open up the whole length of the cavity. In this manner no pockets are left behind, and, besides, a long, smooth incision will in the end leave the least scar. A counter-incision may be necessary.

Once the abscess is opened and the pus has ceased to flow, wipe out the cavity with sterile gauze and irrigate with sterile water or some antiseptic. If diverticula are found, they too must be freely opened up and irrigated.

Insert a drain. If the abscess was small and the incision made early, it is proper to dispense with the drain; but if the suppuration is extensive, the best means of preventing large scar formation is to employ drainage.

Observe, then, says Lejars, that the whole therapy of abscesses is contained in these two words, “empty” and “drain.”

You do nothing more—there is nothing more to be done—and it is sufficient. To attempt to make an abscess cavity aseptic is wasted effort. An abscess contains infection of limited virulence and when once it is emptied, the living tissues will do the rest, provided they are not embarrassed by new germs introduced by the operation.

With this notion in view, then, it must be an absolute rule of practice to operate for abscess with clean hands and clean instru-

ments in a carefully disinfected field. We may put away for all time the old dictum, "If pus is present, antiseptis is useless."

Disinfect the hands, or what is better, the gloves; boil the instruments; cleanse the affected area with soap and alcohol and bichloride or simply paint with Tr. iodine; then, and then only, are you ready to incise the swelling. Wipe out with sterile gauze; use sterile tubes. Do not pack with gauze; there is nothing more illogical than tamponade of an abscess cavity. Cover the wound with sterile gauze and absorbent cotton, and bandage firmly so that nothing may enter the wound; so that the dressings will not slip or rub.

The dressings are to be changed daily at first and the tubes every second or third day, and are to be shortened as the cavity fills up with granulations; are to be dispensed with when pus has ceased to form.

Treatment of Cold Abscess.—The treatment of a cold abscess differs from that of an acute abscess in that incision is not the method of choice.

There is always great danger of infection when the abscess cavity is opened up and for that reason incision must be done with circumspection—with an absolute asepsis. There is not the urgency present in the acute case.

Puncture is the method of choice. Employ the strictest antiseptis. Wash with soap and water, but not too vigorously lest the abscess wall be ruptured; complete the disinfection with alcohol and ether. Employ only such instruments as are carefully sterilized. Use a trocar of sufficient size that the grumous fluid will not occlude it. Do not puncture the summit of the tumor if the skin is quite thin, but select a point where the tissues are sufficiently resistant to close when the trocar is withdrawn. At the end of the evacuation the fluid may need to be aspirated. It may be discolored by some blood from the puncture.

Injection with some stimulating and antiseptic fluid should follow. Ethereal solution of iodoform has the advantage of distending the cavity by gas formation and reaching all the diverticula; but it has the disadvantage that it is toxic. Inject 5 to 10 c.c. of a 10 per cent. solution; leave the trocar in place, closing its orifice with the finger. When the cavity becomes distended, remove the finger and

the ether spurts out. Let all the gas escape. If one does not observe this rule there may be a slough.

A solution of iodoform in glycerine may be employed; inject 3 to 10 grams of a 10 per cent. solution, letting the surplus escape. Camphorated naphthol may be used in the same way. Bismuth paste in certain localities serves an excellent purpose. After the injection is completed seal the puncture with collodion. Several injections may be necessary for a cure. Constitutional treatment is of the greatest importance.

ABSCESSSES OF THE SCALP

These are found in three locations:

1. Superficial—that is, above the aponeurosis of the occipitofrontalis.

2. Subaponeurotic—that is, between aponeurosis and the periosteum.

3. Subperiosteal—between the periosteum and the bone.

1. **Superficial abscess**, due to staphylococci, is quite localized, and yet very painful on account of the resistance of the firm tissue. The lymph nodes behind the ear and in the back of the neck are enlarged and tender. The chief danger is in extension to the deeper layers; or the emissary veins may carry infection to the sinuses and produce thrombosis or pyemia. Evacuate immediately by free incision, first shaving the scalp in the immediate vicinity of the abscess.

Remembering the manner in which the occipital and temporal arteries converge toward the apex, the incision may be managed in such a way as to run parallel to the small vessels distributed to the area.

The cavity must be kept open by a strip of rubber tissue or a small drainage-tube. A dressing of gauze, absorbent cotton and bandage complete the treatment. Change the dressing every day at first.

2. **Subaponeurotic abscess** is likely to follow wound infection. The streptococci follow the areolar tissues that separate the aponeurosis from the periosteum, and the spread of pus is limited only by the attachments of the aponeurosis. Septicemia, meningitis, and

thrombosis are the actual dangers, and on these accounts immediate operation is demanded.

Make a free incision under antiseptic precautions; that is, after shaving and cleansing the part involved.

Do not attempt irrigations, above all, in these cases, for the fluid percolating through the loose areolar tissues spreads the infection. Good drainage alone will suffice. The dressings must be changed frequently at first and must be firm enough to prevent movement of the occipito-frontalis muscle.

If the abscess develops under the temporal fascia, it will not point toward the surface, owing to the extreme density of this fascia, but toward the mouth or neck through the ptergo-maxillary fossa. Even though there be no fluctuation (usually indeed, none can be detected), the diagnosis can, nevertheless, be certainly made from the presence of the edema, redness, and pain. Make a vertical incision an inch or so in front of the ear and with the center about the level of the eyebrow. It may be necessary to go through the substance of the muscle to the bone. A few small arteries will be divided and will require ligation. It may be necessary at the first dressing to pack the cavity with gauze to control slight but persistent bleeding. Drainage by means of tubes may be employed subsequently.

3. **Subperiosteal abscesses** differ from the others in that they are likely to be the result of bone inflammation, tubercular or syphilitic. The abscesses are limited to the area of one bone as the periosteum along the line of the sutures is continuous with the dura mater. This furnishes an easy means of entrance into the cranial cavity for the infection and in that manner meningitis may result. For this reason, these abscesses, of whatever origin, should be evacuated at once and appropriate constitutional treatment instituted.

ABSCESS AND FURUNCLE OF THE FACE

The danger in these conditions is that phlebitis beginning in the facial vein may spread to the cavernous sinus, so free is the communication by numerous branches between these venous channels. Especially to be feared are these *furuncles* beginning on the upper

lip or median parts of the face. They may be fatal in a few days. Nearly always the *staphylococcus pyogenes* is the active causative agent and one need not usually be at a loss to trace the mode of entrance of the infection.

Early incision is imperative in all such acute septic processes. The best form of local anesthesia in these conditions is by freezing with ethyl chloride spray. Hypodermic injections are best avoided here. The incision must be deep to be effective, and in making it two factors are to be borne in mind, the resulting scar and injury to the branches of the facial nerve. In severe cases even these points must be disregarded. Even more certain than free incision is *central puncture* with a fine thermo-cautery, followed by the Bier suction treatment. If it is a *carbuncle* of the diffuse type, accompanied by edema of the face and inflammation of the veins, crucial incision with curettement must be undertaken. The dressing of gauze may be held in place by adhesive strips.

ABSCESS OF THE NASAL SEPTUM

Following a blow upon the nose, bleeding ensues and, two or three days later, obstruction. Looking into the child's nasal fossæ, they are seen to be filled with a bright red, tender, fluctuating swelling, over the cartilaginous portion of the septum. The whole nose becomes hot, swollen, and painful.

The treatment is evacuation by a free incision of the mucous membrane over the septum at the point of greatest fluctuation.

To operate, apply a 4 per cent. solution of cocaine to the mucous membrane, and after waiting a minute or two, make an incision along the septal wall from above downward and forward with a slender, sharp bistoury. Douche the nasal fossa frequently with a mild, alkaline antiseptic. Recovery usually follows within a week, although in the neglected cases, necrosis of the cartilage may occur.

ABSCESS OF THE EYELIDS

The loose connective tissues of the eyelids favor exudation and edema. An abscess occurring here is usually due either to trauma-

tism or to septic infection entering from the face or scalp or to periostitis of the margin of the orbit. Early treatment of contusions may prevent not only the unsightly discoloration ("black eye"), but also a later abscess.

To prevent discolorations apply cooling or evaporating lotions or wring a gauze compress out of ice-water and apply to the lid, renewing the compress every two or three minutes. Do not allow the compress to cover the nose, else acute coryza may result. Apply in this manner for an hour and repeat every second or third hour for twenty-four hours. A solution of arnica (2 oz.), in water (1 pt.), may be applied, or

Ammonii chloride,	1
Alcohol,	1
Aquæ,	10

If discoloration appears, apply flannel cloths wrung out of hot water, for an hour at a time, three or four times daily, and follow with gentle massage for five to ten minutes. Before applying the heat it is better to smear the lid with vaseline. Ointment of yellow oxide of mercury is excellent to use with massage. If an *abscess appears* make an incision parallel with the muscle fibers. Apply antiseptic, absorbent dressings.

ABSCESS OF THE LACHRYMAL GLAND

Abscess of the lachrymal gland is rare, yet doubtless is often overlooked. It is seen in infancy, usually traceable to some of the infectious diseases. The abscess breaks into the superior cul-de-sac and recovery follows.

ABSCESS OF THE EXTERNAL AUDITORY MEATUS

Abscess of the external meatus is extremely painful and alarming, but in fact not particularly dangerous. The meatus is closed by the swelling, but a stab with the point of the knife or, if it is more deeply situated, an incision in the direction of the long axis of the meatus, will cause a speedy disappearance of the symptoms. Gentle

douching with an antiseptic solution, and, after drying, occlusion with absorbent cotton, will soon complete the cure.

ABSCESS OF THE PAROTID GLAND

An inflammation begins in the parotid gland, the result of local infection or secondary to an abdominal disease or injury (most frequently involving the pancreas, perhaps), and nearly always suppuration follows. The severe forms are dangerous; happily, however, the pus, even if left to take its own course, works its way to the surface or points at the pharynx. It may burrow down to the anterior mediastinum. The special dangers are meningitis, septic poisoning, and thrombosis. When the swelling is great, pressure interferes with the venous current and, as a result, cerebral congestion, headache, and finally delirium ensue. The pus may open into the middle ear and infection by that route reaches the brain. Suppuration of the temporo-maxillary articulation may follow.

Treatment.—If, when the swelling first appears, a probe be passed into Stenson's duct and the gland be pressed from the outside, a few drops of pus may be squeezed out and this may serve to head off a general suppuration. If the entire gland becomes involved, hot antiseptic poultices should be applied to hasten the localization of the pus. As soon as redness and edema indicate the most probable situation of the pus, an effort must be made to evacuate it. Several important structures are to be avoided; Stenson's duct (a fistula is likely to follow its division), the facial nerve, the carotid arteries, the temporo-maxillary vein and other vessels of lesser importance may be wounded.

If the *anterior* part of the gland is involved, the incision is made parallel with and below Stenson's duct. The skin and fascia are divided and retracted and an effort is made to burrow into the depths of the gland with a probe or grooved director. The pus follows the connective-tissue laminæ instead of the lobules of the gland, and it is better, if possible, to avoid dividing the glandular substance. If the *posterior* and lower part of the gland is involved, the incision should be vertical, with its center a little above and anterior to the angle of the jaw. The temporo-maxillary vein will be seen, running parallel

to the incision near the surface of the gland. A drainage-tube must be left in the deeper abscesses.

DENTAL ABSCESS

These painful affections are not to be neglected, for they may lift up the periosteum and result in necrosis of the jaw. Left to itself, the abscess may point in the mouth, less frequently on the face. It begins in the alveolar process from infection from a carious tooth. It makes its appearance at the junction of the cheek and the gum. Inspection and palpation make the diagnosis. A cotton

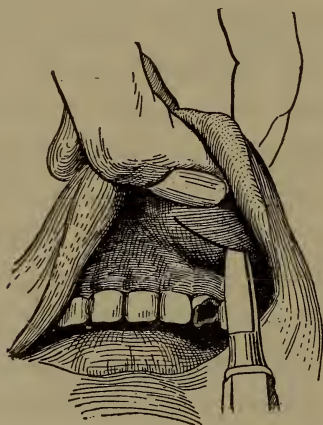


FIG. 298.—Dental abscess.
(Veau.)

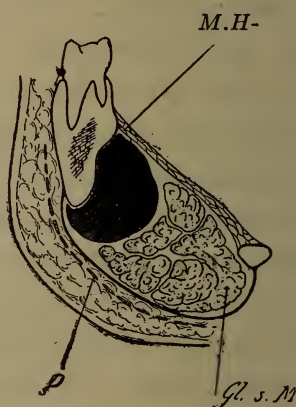


FIG. 299.—Submaxillary abscess in contact with inner surface of the inferior maxilla. *M.H.*, Mylohyoid muscle. *P.*, Platysma myoides. *GLs.M.*, Submaxillary gland.
(Veau.)

tampon soaked in 2 per cent. cocaine solution is laid on the gum for five or ten minutes, but analgesia will not be complete. Lift the cheek away from the gum as far as possible, and with a sharp-pointed bistoury, wrapped to within a half-inch of the point, make a horizontal incision and cut down to the bone. There is nothing to fear and without getting deep one may fail. The patient may resist further efforts or the field may be obscured by blood (Fig. 298).

Order an antiseptic mouth-wash to be used every half-hour at first, and the pain will rapidly disappear. In more extensive subperiosteal abscess of the jaws, the same principle of procedure should be carried out.

SUBMAXILLARY ABSCESS

Do not await fluctuation in acute inflammations in this locality. The pain, augmented by pressure, the brawny edema and diffuse redness are sufficient to demonstrate the presence of pus. The pus is not always easy to find, for it is deep, often subperiosteal and in contact with the internal surface of the jaw, and is generally due, in fact, to dental infection (Fig. 299).

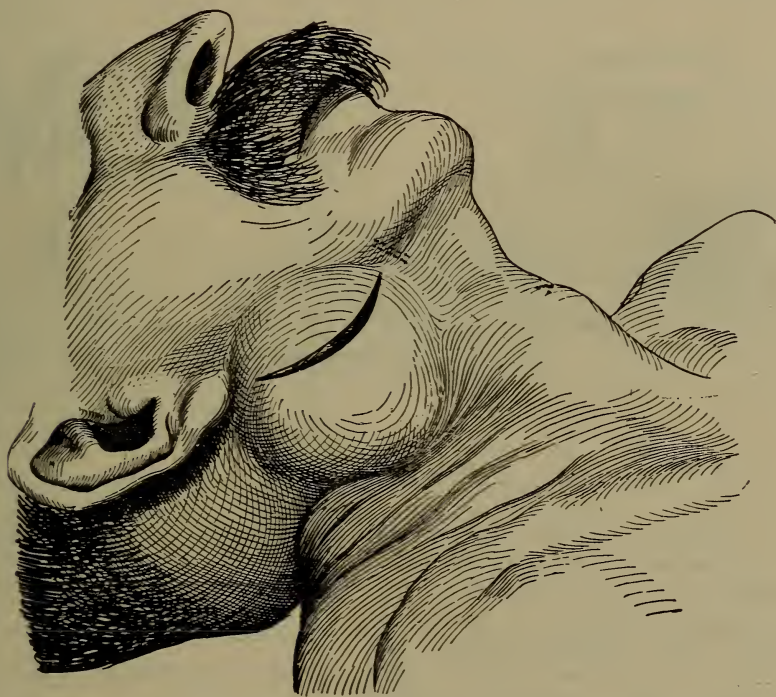

FIG. 300.—Incision of submaxillary abscess. Dotted line represents the facial artery. (Veau.)

Local anesthesia is often sufficient. Locate the angle of the jaw. This is often difficult on account of the edema. A finger's breadth below, and following the body of the jaw, make a curved incision (Fig. 300) with slight downward convexity about 3 inches in length. Remember the point at which the facial artery crosses the body of the jaw, just in front of the masseter. Do not cut deeper than the skin, for this is dangerous ground. Now dissect with forceps and grooved director the subjacent tissues, making haste

slowly and renewing from time to time the analgesia or injections as the patient complains of pain.

Carry the dissection upward and inward toward the inner surface of the jaw, and with patience the abscess will be located. As it is approached, the tissues will be found more and more edematous and filled with serum. Having once cut into it, enlarge the opening, always too small, by introducing and opening an artery forceps. Irrigate with normal salt solution, insert one or two small drains, dress with antiseptic gauze and absorbent cotton, and renew daily.

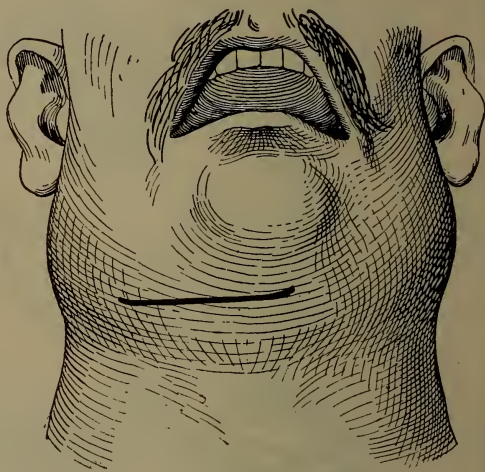
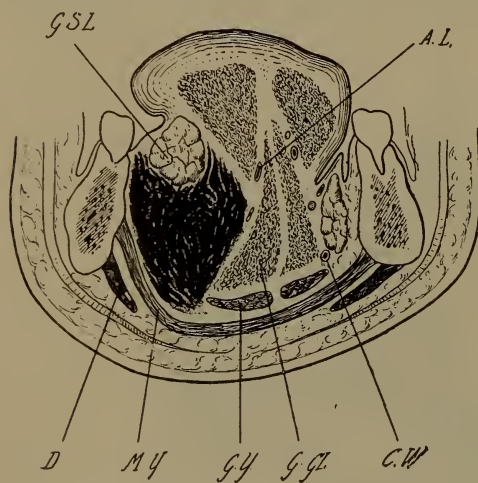


FIG. 301.—Phlegmon of the floor of the mouth. The tongue is pushed to the opposite side and the spread downward of the purulent collection opposed by the mylohyoid muscle. *GSL*, sublingual gland. *AL*, lingual artery. *CW*, salivary duct. *GGL*, genio-hyo-glossus. *GY*, genio-hyoid. *MY*, myo-glossus. *D*, diaphragm. (Veau.)

FIG. 302.—Incision for phlegmon of floor of mouth. (Veau.)

The temperature will fall rapidly. After five or six days the drainage may be diminished and after ten days entirely removed.

ABSCESS OF THE FLOOR OF THE MOUTH

(Ludwig's Angina)

This is a very grave, usually fatal condition, originating in streptococcal infection through the mucous membrane of the floor of the mouth. It more frequently occurs in adults, though childhood is

not exempt. Its tendency is to extend into the neck, following the cellular planes, and if the patient does not die early from septicemia, gangrene may occur. In a very few hours after the infection begins, the floor of the mouth becomes brawny, the tongue is thrust up against the hard palate, and breathing and swallowing markedly interfered with. If anything is to do good, it must be done at once (Fig. 301).

Try the antistreptococcic serum—if it does no good, it will at least do no harm. In the meantime, operate. Usually a general anesthesia is indispensable. Make an incision a finger's breadth below the body of the jaw about 3 inches long so that it reaches beyond the median line (Fig. 302). If both sides are equally in-

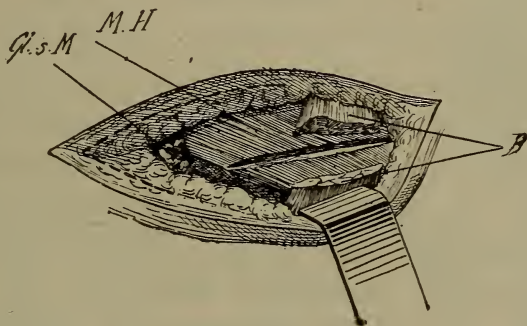


FIG. 303.—Deep incision for phlegmon in floor of mouth. *G.S.M.*, submaxillary gland *M.H.*, mylo-hyoid muscle. *D*, digastric muscle. (*Veau*.)

involved, make a bilateral incision. One may perhaps recognize the platysma, but the anterior belly of the digastric must be demonstrated and divided. Next expose the mylo-hyoid and divide completely (Fig. 303). Having now reached the sublingual space, you may find merely a serous exudate, characteristic of this form of infective inflammation. Do not stop until the mucous membrane of the mouth has been demonstrated, for otherwise one may mistake the submaxillary for the sublingual gland and not go deep enough.

Douche thoroughly with peroxide, place two or three large drainage-tubes, pack with gauze saturated with peroxide, and apply absorbent cotton. Renew the dressings and flushing three or four times daily and the serum injections as well. Possibly the patient will go on rapidly to death from septicemia. He is almost certain

to do so without the operation. The drainage may be diminished toward the tenth day. Several weeks will be required for a cure.

ABSCESSSES OF THE TONGUE

Abscesses of the tongue do not often occur, but when they do, may give rise to urgent conditions. They may develop suddenly with much pain, which may be variously reflected—to the ear, for example.

The tongue may be so swollen as to fill the mouth and severely disturb respiration. The location of the abscess is to be determined by palpation. If it is at the base of the tongue and pointing toward the surface, is it to be evacuated by a median longitudinal incision from behind forward and deep enough to reach the pus. There is no danger of wounding important structures if the incision follows the middle line. Leave a strip of gauze in the wound for drainage. Prescribe frequent antiseptic mouth-washes. If the abscess lies under the tongue and points downward, the incision must be made along the floor of the mouth, if the mouth can be sufficiently opened and fluctuation detected. The ranine artery may be wounded. If the mouth cannot be opened it is best to operate from the outside, making a median vertical incision from the symphysis of the chin down, getting between the two genio-hyo-glossi muscles and following this crevice up to the under surface of the tongue. Drainage-tube, antiseptic absorbent dressing.

TONSILLAR ABSCESS

“Quinsy” is an actue suppuration in the tonsil or around the tonsil following acute infection of the gland.

Often the suppuration occurs only on one side, though both tonsils are inflamed. At any rate the two tonsils do not suppurate simultaneously.

The temperature is high, the pain extreme, there is difficulty in swallowing and perhaps in breathing. There may be edema of the glottis. Often there is difficulty in opening the jaws. After the abscess is well formed, the soft palate is edematous and swollen.

Pus begins to form about the third day after the attack. Previous to this an effort should be made to *abort* the abscess. Give calomel in small frequent doses and follow with a saline purge, and in the meantime administer full doses of sodium salicylate. Phenacetine, 2 or 3 grains frequently, will make the patient more comfortable. Paint the tonsils and pharynx with argyrol once a day and use the peroxide spray (50 per cent. solution) every two or three hours. Apply hot antiseptic fomentations or poultices externally.

If these measures fail to relieve the symptoms after the third day, it is almost certain that pus has formed, even though fluctuation cannot be felt, and it is best to make an incision, but this must be free.

The operation is sometimes difficult. A general anesthesia will be necessary if the jaws are locked. Open the mouth wide. A mouth gag is often necessary. Depress the tongue as much as possible. Swab the tonsil with a 10 per cent. solution of cocaine. With a sharp pointed bistoury (wrapped), make an incision in the

soft palate just external to, and parallel with, the anterior pillars and extending as *low down as possible*. If the pus flows freely, some of it may be swallowed, to prevent which bend the head down. Continue the spray and antiseptic mouth-washes for a few days. Whether pus is located or not, free incision gives great relief (Fig. 304).

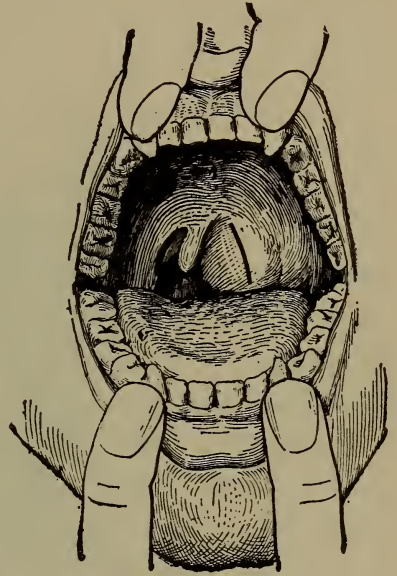


FIG. 304.—Tonsillar abscess. Incision should extend as low as possible. (Veau.)

RETROPHARYNGEAL ABSCESS

These conditions are treacherous and dangerous because (most frequent in infants) they may be overlooked and, bursting into the pharynx, may produce suffocation.

The pharynx is separated from the muscles covering the anterior

surface of the bodies of the cervical vertebræ by a loose connective tissue. One or two lymphatic glands lie in front of the bodies of the upper two cervical vertebræ on either side of the middle line. These receive lymph (and infection) from the nasal cavities and their accessory sinuses, the naso-pharynx, the Eustachian tube, the tympanum, and from the tissues lying on the bodies of the adjacent vertebræ. Septic conditions existing in any of these localities may be the source of the inflammation of these lymph glands, which may end in suppuration. These glands empty by several chains of lymph vessels into the deep cervical glands.

The suppuration begins on one side usually, but rapidly spreads toward the middle line, where the tissues are loosest. The abscess may be behind the palate; it may be opposite the larynx; in either case almost out of sight. Usually, however, it is seated in the posterior wall of the pharynx, opposite the oral cavity. When situated there, it gives rise to fewest symptoms, and for that reason its development is insidious, and in the infant unsuspected. The constitutional disturbance may be slight.

Obstructed breathing and hoarseness and a feeling of tightness in the throat may first suggest the difficulty. Inspection and palpation, always necessary, are not always easy and, in the case of infants, sometimes dangerous. Still, only by touch, with the finger in the mouth, can the exact condition be determined. To prevent asphyxia or syncope, the main thing is to be rapid in the examination. To facilitate this, the child must be prepared.

It is seated on the assistant's lap with its face turned to the light, its arms and body encircled by a towel, its legs held firmly between the assistant's knees. Its mouth is forced open by pressing the cheeks between the teeth. The finger is passed to the back of the tongue and rapidly palpates the walls of the pharynx. It is not difficult to determine the point of greatest swelling.

Operation.—1. Have already prepared a sharp-pointed bistoury wrapped with cotton close up to the point. The index finger in the mouth holds the tongue down and the bistoury is passed along the finger and plunged into the abscess in the *middle line*, that no blood vessels may be injured. This puncture is prolonged into an incision from above downward at least an inch; in fact, as low as

possible, that chances of a recurrence may be diminished. The patient is immediately inclined forward in order that the pus may pour out of the mouth (Fig. 305).

If syncope or spasm of the larynx occurs, do not lose your head, but proceed hastily to revive the patient by the ordinary means. Lower the patient's head, pull out the tongue, and employ artificial respiration.

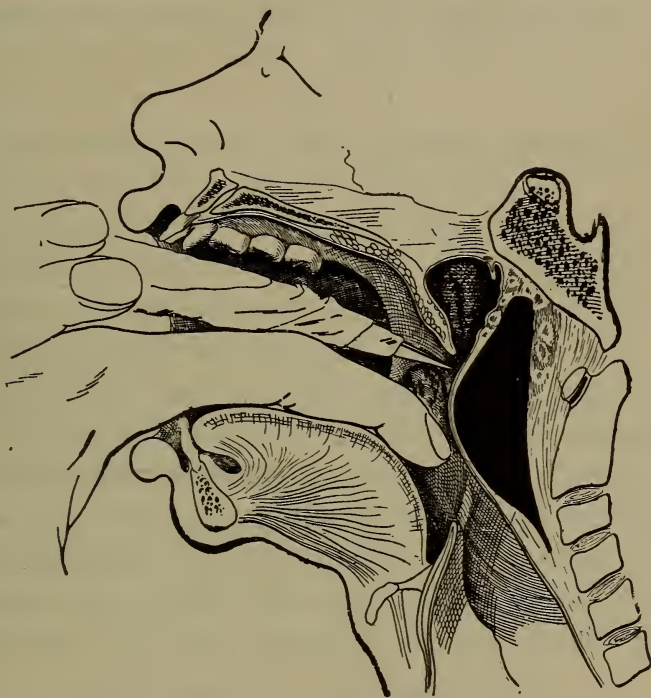


FIG. 305.—Retropharyngeal abscess. (Veau.)

As after-treatment, direct frequent irrigations or gargling with sterilized water. A peroxide spray may be used with good effect. Recovery occurs within a few days.

If the abscess recurs, or in the first place is situated too far down for oral puncture (which may sometimes be done by passing a curved director over the base of the tongue and then downward to the top of the abscess), or the jaws are locked, it will have to be reached from the side of the neck, an operation much more difficult in every way.

Operation.—2. Turn the patient slightly to one side, resting the neck upon a cushion to make its lateral aspect prominent; the sterno-

mastoid is the guide. Make an incision about 2 inches in length along the posterior border of the sterno-cleido-mastoid, which is exposed after the skin and fascia are divided. Ligate the veins; avoid the superficial cervical nerves; pull the sterno-cleido-mastoid forward and locate the scalenus anticus. Stick to the scalenus anticus, follow its anterior surface inward, displacing forward by careful dissection with grooved director, the common sheath of the great vessels and pneumogastric. The connective tissues are rather loose; the dissection is not difficult. Be on the watch for the spinal accessory nerve, which lies on the deep surface of the sterno-mastoid. Working inward in this manner reach the outer border of the longus colli which lies in the same plane as the scalenus anticus, and upon which lies the pharynx and the abscess. After opening and emptying, a drain must be left. Employ the usual dressings and after-treatment. Sometimes the abscess lies further forward and it will be necessary to go in front of the sterno-cleido-mastoid. After the skin and fascia are divided, the finger in the wound will be able to locate fluctuation and that will be the best guide in the subsequent dissection. It may be necessary to ligate several small veins. Retract the anterior border of the sterno-mastoid and with it the sheath of the common carotid, the internal jugular and pneumogastric; draw forward the thyroid, the larynx and trachea. The fascias are divided by blunt dissection until the abscess cavity is opened.

ABSCESS OF THE GLANDS OF THE NECK

Acute suppuration of the lymph glands of the neck is quite frequent and originates in infective disorders of the areas drained by the glands.

In treating these conditions, the source of the infection must not be overlooked. It is not always advisable to operate immediately, even though suppuration is believed to be present, unless, of course, the infection shows a tendency to become general.

In the ordinary case, the pus may be very deeply located or outside the capsule of the gland. It is better under these circumstances to apply hot antiseptic poultices for twenty-four to forty-eight hours. The whole gland then becomes softened, the pus is easily

evacuated and healing occurs rapidly; whereas a non-suppurating gland cut into may remain enlarged and indurated. Free incision is always out of the question as the many important structures of the neck have to be borne in mind. Use local anesthesia. In making the incision it is usually best to follow the posterior border of the sterno-mastoid. Make an incision about 2 inches in length. When the muscle is reached, draw it forward with a retractor and with a grooved director search for the pus cavity; drain; use absorbent dressings.

CHRONIC SUPPURATION OF THE CERVICAL GLANDS

There are various clinical manifestations of the tubercular processes, each of which demands a somewhat different treatment. It is assumed that the pus, gradually accumulating, has burst through the fascia and has begun to bulge the skin.

It is best to operate at once. The most careful asepsis should be maintained. The pus is evacuated by free incision and the abscess cavity wiped out with iodoform gauze. A 10 per cent. solution of iodoform emulsion with glycerine is poured into the cavity (2 or 3 drams are sufficient) and the wound sutured and treated as an aseptic wound, provided there is no evidence of secondary infection.

ABSCESS OF THE BREAST

Abscess of the breast may be either *parenchymatous*, originating in the substance of the gland; or *submammary*, originating in the areolar tissues separating the gland from the pectoralis major.

In either case infection nearly always begins at the nipple and follows the lymph vessels downward. The first form is usually due to staphylococcic infection, the second to streptococcic. These conditions are preventable in the greater number of cases and for that reason the nipple should be given special care both before confinement and during the first weeks of lactation.

Even when the breast becomes "caked" and tender and there is a little fever, antisepsis at the nipple and hot antiseptic poultices to the breast may prevent abscess formation. Continued rise in tem-

perature, slight chills, edema and pain, more or less localized, indicate the formation of pus, and immediate operation is necessary. A general anesthesia is best for thoroughness, though the work may be done under local anesthesia.

Under rigid asepsis, proceed to open up the cavity, and always remember, the earlier the better. An incision an inch or so long should begin near the nipple and radiate from it, as the spoke from the hub of a wheel. In this manner the least possible number of the milk ducts and vessels are divided (Fig. 306).

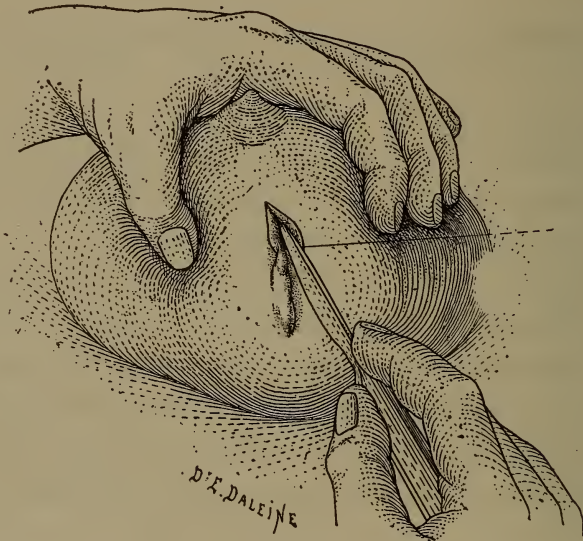


FIG. 306.—Abscess of the breast: incision. (*Lejars.*)

The first incision goes through the skin and fascia and then the abscess cavity is sought for by blunt dissection with a grooved director. Still there is nothing to fear in cutting boldly down to the abscess. Explore the cavity thoroughly for there may be pockets leading off from the main cavity. Do not neglect this point. If it extends deep, make a counter-opening at the base, being guided by the director introduced through the first opening (Fig. 307). Pushing a forceps through the channel, it seizes a drainage-tube which is drawn into place as the forceps is withdrawn. Dress with anti-septic gauze, which should be changed twice daily at first, care being taken not to disturb the drainage-tube.

If the temperature rises again after the second or third day, you

will have to re-explore. A new abscess is in process of formation. After five or six days replace the first drainage-tube with a smaller one. The drainage-tube can be entirely dispensed with after ten days or two weeks.

The *submammary abscess* develops without edema or redness because it underlies the whole breast. The condition can scarcely be mistaken, for the marked elevation of the whole breast, along with the constitutional symptoms point to the nature of the trouble. Make a curved incision following the base of the breast at its lowest

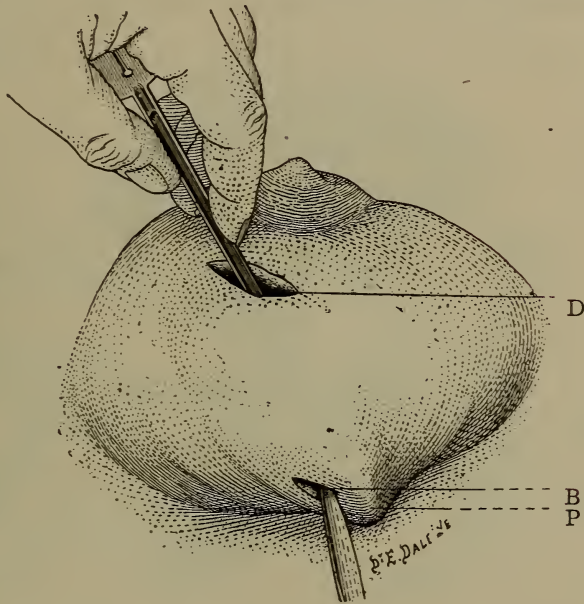


FIG. 307.—Abscess of the breast. Manner of making counter-opening. *D*, grooved director; *P*, its point; *B*, bistoury cutting down on to the point of director. (*Lejars.*)

part, dividing the skin and fascia. With a grooved director, dissect through the areolar tissues between the gland and the chest wall, working toward the center of the breast. These deep tissues are likely to be infiltrated. In this manner the pus is evacuated and the subsequent treatment will be practically the same as that prescribed for the preceding form.

AXILLARY ABSCESS

Three chains of lymphatic glands are found in the axillary space. One lies along the anterior fold of the axilla and drains the anterior

thoracic region; one lies on the posterior axillary wall and drains the posterior thoracic region; one lies alongside and externally is connected with the axillary vessels and drains the upper extremity. Axillary abscess usually results from inflammation of one or the other of these chains of glands, the infective agent having been carried to them from a distant point, such as the breast or hand, by the lymph vessels.

The inflammation spreads from the glands to the adjacent areolar tissue and pus formation follows. Abscess may also form by extension of pus formation from the base of the neck.

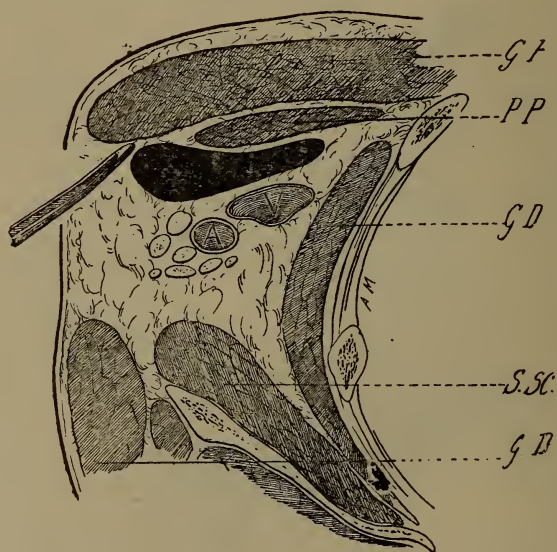


FIG. 308.—Cross section showing relations of axillary abscess. *G. F.* Pect. major. *P.P.* Pect. minor. *G. D.* Latiss, dorsi. *S.SC.* Subscapularis. *G. D.* Serratus magnus. (Veau.)

The most frequent sources of infection, probably, are the breast and the sebaceous glands in the skin of the armpit. Abrasions and small boils in this locality must be treated with circumspection, lest they terminate finally in axillary abscess. The ordinary symptoms of inflammation and pus formation, added to the painful abduction of the arm, indicate the nature of the trouble.

It is imperative to evacuate the pus promptly for the reason that it may burrow in various directions, usually upward toward the neck. The axillary vessels may be eroded.

The incision will depend upon the location of the pus—that is to

say, whether it lies under the pectoralis major or in the loose areolar tissues of the center of the space. Acute abscess more often lies in the first locality (Fig. 308); tubercular abscess in the latter.

(a) **Acute Abscess** (Fig. 309).—General anesthesia; place the patient on his back; abduct the arm as much as possible; and locate the border of the pectoralis major. Make an incision 3 inches in length along this line, cutting toward the thorax; expose the muscle border well; dissect along the under surface of the pectoralis major with the grooved director. In this manner you keep in front of the great vessels and nerves and will feel secure. When the pus once flows, enlarge the opening, and insert drainage-tubes.



FIG. 309.—Incision for acute axillary abscess. The blunt dissection should follow the anterior axillary wall. (Veau.)

To avoid the axillary structures, you must keep these two points in mind: (1) Make the opening large enough to see what you are doing—a blind stab in this region is exceedingly dangerous; (2) stick to the pectoralis major—the pus is in contact with its deep surface. Wash out the cavity and place two drains; use a gauze and absorbent cotton dressing daily for a week, after which remove the tubes, though the external opening must not be allowed to close until the cavity is eliminated.

(b) **Chronic Abscess**.—*Incision*. Begin in the middle of the floor of the space and follow the middle line away from the arm toward

the chest. In this direction alone is safety. In front are the long thoracic vessels; behind are the subscapular vessels; to the outside are the main axillary vessels and branches of the brachial plexus. The skin incision may occasionally divide a small artery, which will at first give some concern. It is best to divide the connective tissues layer by layer in the original line of incision. There is no danger if you keep in this line. Otherwise, the pus may be reached by Hilton's method. After the skin and fascia are divided, a dressing forceps is pushed up into the abscess cavity and the blades opened. Put in a drainage-tube; use absorbent dressings; maintain a careful asepsis throughout the process of repair.

PALMAR ABSCESS

These are always serious conditions, not alone on account of sepsis, but because the hand may be left permanently crippled or useless as a result of the destruction of tissue and inflammatory adhesions.

Immediate evacuation of pus is imperative. If the pus is limited to the connective tissues of the palm, has not reached the tendon sheaths, the incision should be made over, and parallel with, the interosseous space in the region of the greatest swelling.

If the tendon sheaths are involved, the incision should be made in the long axis of the metacarpal bone (see *Phlegmon*, page 424). Whether the condition is a diffuse inflammation (phlegmon) or an abscess will be determined by the history of the case.

In the case of abscess, make a longitudinal incision. The palmar arches are chiefly to be considered. Begin the incision just below a line drawn across the palm from the web of the thumb. Beginning nearer the wrist, the superficial palmar arch or the deep arch as well may be divided. Cut toward the finger, making the incision sufficiently deep to go quite through the palmar fascia. Insert a drainage-tube. Use antiseptic dressings, changing the dressings daily. (See also *Phlegmons*.)

POPLITEAL ABSCESS

Situated in the hollow back of the knee-joint in the superficial fascia are a few lymph glands which may suppurate following an in-

fective process in the foot or leg. Situated still deeper beneath the deep fascia are other glands which may similarly suppurate.

These may be described, then, as superficial abscess and deep abscess of the popliteal space.

The *superficial abscess* may be opened simply by a vertical incision over the point of greatest swelling. There are no important structures likely to be wounded by a superficial incision.

It is quite different with a *deep abscess*. The situation of a number of important structures must be borne in mind. In the center of the lower half of the space lies the short saphenous vein; to the outer side lies the external popliteal nerve, and running vertically through the center of the space, and deeply located, are the popliteal vessels and internal popliteal nerve. The space is roofed over by the dense popliteal fascia which is the chief factor in determining the direction in which the suppuration extends; thus the pus is more likely to point up in the thigh or down in the leg than in the integuments of the space.

A popliteal abscess may likewise be the result of the extension of a suppurative process in the thigh. These abscesses must be opened without delay for the reason that the joint may become involved, the vessels may slough, and there may be destruction of tissue. There may be permanent flexion of the leg due to scar tissue.

Before opening a popliteal abscess the diagnosis must be confirmed. It has happened more than once that a popliteal aneurism has been mistaken for an abscess and incised, a mistake serious indeed for both patient and operator.

Acute inflammation of the bursæ must not be mistaken for abscess. These bursæ are found in the boundaries of the space, separating the tendons from the protuberances of the femur, tibia, and fibula.

Operation.—Either general or local anesthesia may be used. Make a vertical incision in the center of the space, dividing the skin, the superficial fascia, and the deep fascia successively. With the grooved director separate the fatty tissues filling the space; keep in the line of the original incision. The pus will usually be located before the depth of the vessels has been reached. Enlarge the opening in the connective tissues, irrigate, search for diverticula, insert a drainage-

tube and pack lightly around the tube with aseptic gauze. Apply absorbent dressings and extend the leg on a *posterior splint*. This extension must be maintained until the healing is complete to prevent flexion.

PLANTAR ABSCESS

The deep fascia of the sole of the foot is especially developed. It extends as a broad, dense band from one end of the plantar arch to the other, from the os calcis to the base of the metatarsal bones. It is a broad band divided into three portions: outer, middle, and inner. The central portion alone is of much surgical importance. Its anterior extremity is broken up into five slips, and each slip branches and forms an arch for a flexor tendon.

The result of this arrangement is that here is a closed compartment between the fascia and the bones of the foot which is occupied by the muscles of the middle foot. Following an infection, pus forming in this compartment finds great difficulty in escaping. It burrows between the metatarsal bones and makes its appearance on the dorsum of the foot, follows the flexor tendons backward to the inner ankle, or may escape through the small aperture for the arteries into the subcutaneous fascia.

On account of the denseness of the fascia, the pain in plantar abscess is extreme, and for relief of this pain and to prevent destruction of tissue, an early incision is imperative. The incision should be made over the most prominent part of the swelling, its direction corresponding to the long axis of the foot.

The skin is divided and then the thick fatty tissues, until the white and firm plantar fascia is reached. After the fascia is divided, the dissection is completed with a grooved director until the pus cavity is located. In this manner no important structures are wounded. Wash out the cavity and insert a small drainage-tube. It is important that the cavity heal from the bottom.

ISCHIO-RECTAL ABSCESS

The ischio-rectal fossa is a wedge-shaped cavity, lying on either side of the rectum, between it and the pelvic wall. Its base is

covered by the integument and its sharp edge is directed upward and corresponds to a line drawn from the pubes backward to the spine of the ischium—the line of attachment of the levator ani muscle, the “white line” of the pelvic fascia. The levator ani muscle forms its inner boundary. The obturator fascia covering the bony pelvic wall forms its outer boundary.

The fossa is filled with fatty tissue which seems to form a packing and support for the rectum, but which at the same time forms a site of “lowered resistance” to infective agents.

These infective agents gain access to the fatty tissues of the fossa through ulcerations or abrasions of the rectal mucous membrane or from similar conditions in the integument around the anal orifice. For the most part the bacteria follow the lymphatics which have their origin in these localities and which follow the branches of the inferior hemorrhoidal vessels through the fossa. The abscess may be secondary to prostatic abscess.

The *symptoms* of acute abscess here are the ordinary constitutional symptoms in marked degree, accompanied by intense throbbing pain in the region of the anus. The skin becomes brawny and indurated but no fluctuation appears in many cases.

The symptoms of chronic abscess differ only in degree, and are often so slight as to be entirely overlooked. Abscess of any kind in this locality, when diagnosed, should be evacuated without delay. If let alone it will eventually open the rectum or through the skin if the patient should survive the general sepsis. But spontaneous evacuation is in every way to be avoided, if possible. A fistula is the inevitable sequel if the case is left to nature.

This fistula, opening into the bowel whether the abscess formed near the roof of the fossa or near the floor, is very likely to be just above the external sphincter. There the bowel wall is thinnest, and the fascias of the levator ani act as an inclined plane along which the pus moves toward that part of the bowel.

The examining finger in the rectum in the case of abscess will nearly always detect the threatened opening there and confirm the diagnosis.

Operation.—General anesthesia; lithotomy position; antisepsis.

The *incision* (Fig. 311), 4 or 5 inches in length, is made from

before backward and inclined a little outward midway between the ischial tuberosity and the rectum. Remember that cutting too near the middle line, you may wound the rectum; too near the pelvic wall, you may wound the internal pudic vessels. Some small hemorrhage will follow the skin incision. It may be necessary to cut deeper along the same line and you may wound some of the branches of the inferior hemorrhoidal arteries, but that is not a serious matter.

With a little patience, in this manner the pus is reached and it pours out, extremely fetid and often mixed with shreds of connective tissue.

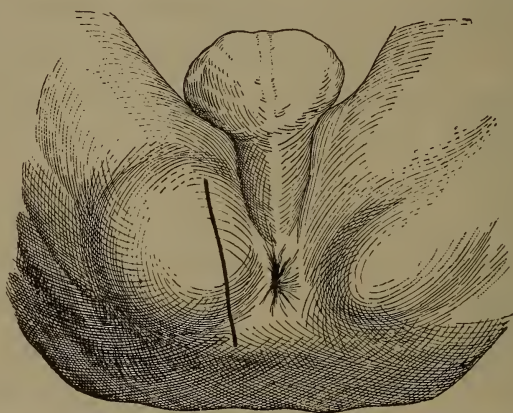


FIG. 311.—Ischio-rectal abscess. Incision. (Veau.)

Enlarge the wound so that it may be inspected and explore it with the finger. Irrigate vigorously. Being assured that all the minor cavities are opened up, introduce a large drainage-tube and pack around it with gauze. The dressing must be renewed daily at first. The tubes can be gradually withdrawn.

It is absolutely necessary that the wound heal by granulation from the bottom and this may be a matter of weeks or even months. Of this the patient should always be forewarned. During this time the dressings must be carried out methodically. Often following incision and drainage there is a tendency to relapse because the primary focus of suppuration in the prostate has not been recognized and relieved.

If a small opening is exposed high up in the cavity, through which pus drains, it indicates a *peri-rectal* abscess above the levator ani,

dangerous because it may become a general pelvic cellulitis or peritonitis. Enlarge the opening by the introduction of a dressing forceps, irrigate and drain.

These *peri-rectal* abscesses not involving the ischio-rectal fossa are difficult to diagnosticate, but when once determined they must be opened in the manner already indicated.

Again, the ischio-rectal abscess may have, unfortunately, already opened through the rectal wall. Make the skin incision as before, and then an additional step is necessary. Push a grooved director up through the abscess cavity and through the rectal opening and then, following along the grooved director, cut through the entire thickness of the rectal and anal walls, holding one finger in the rectum to guide the knife. It will look like a very long wound, and yet it has the excellence of favoring recovery and of preventing a fistula. However, under the most favorable circumstances, it may require several months to heal (Lejars).

PERI-ANAL ABSCESS

These are much less serious than those of the ischio-rectal region, both with regard to prognosis and treatment. However, if neglected, they are likely to result in fistula; even if not properly incised they may so result. The peri-anal abscess is in the glands surrounding the anal margin and lies under the integument or mucous membrane. Local anesthesia is all that is necessary except for those who are timid, and with them general anesthesia is indispensable.

Puncture the tumor at its apex. The pus is foul smelling. Irrigate; explore the cavity methodically with a grooved director. There is nearly always an ascending diverticulum on the anal side which communicates with the rectum. Having located the apex of the cavity, push the point of the director through the mucous membrane; in other words, make a fistula if one does not already exist (Fig. 312). Divide all the tissues over the director, in this manner laying open the cavity and anal margin. Carefully wipe out the walls of the abscess and pack with iodoform gauze. As important as the operation is the *after-treatment*. This the doctor

must attend to himself. The dressing must be made daily, washing and packing lightly. After each movement of the bowels, the wound must be washed and the packing replaced, if possible. It is essential that the cavity granulate from the bottom. Repress excessive granulation with tincture iodine.

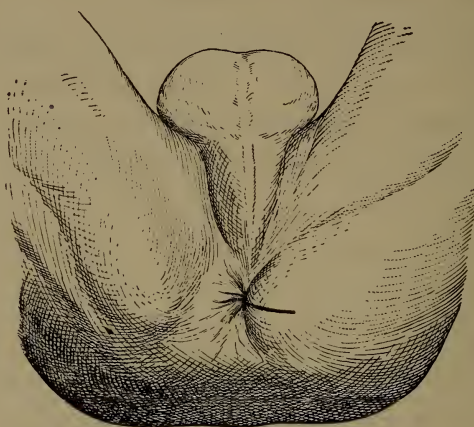


FIG. 312.—Incision for peri-anal abscess. (Veau.)

PROSTATIC ABSCESS

The prostate gland, about the size and shape of a chestnut, lies at the base of the bladder, claspings but not quite encircling the first portion of the urethra. The upper surface of the urethra is covered by fibrous tissues which connect the upper surface of the two lateral halves of the prostate, so that the urethra apparently makes a tunnel through the prostate. The ejaculatory ducts empty into this portion of the urethra.

The prostate is in contact with the second portion of the rectum $1\frac{1}{2}$ to 2 inches from the anal orifice. The apex rests against the triangular ligament, which separates it from the bulb of the urethra.

Suppurative inflammation in the prostate originates from infection caught up by the lymphatics of the prostatic and membranous portions of the urethra. These infective agents are the gonococci, staphylococci, streptococci, bacilli coli communis.

As might be expected, gonorrhea is the most frequent cause, both directly and indirectly. The passage of sounds, perineal bruises,

sexual excesses, and high living in one way or another favor the development of an inflammatory process which may result in abscess-formation.

The abscess may be limited to the gland substance or may develop in the connective tissue surrounding the gland. In this case it may be called a pelvic abscess. It may become an ischio-rectal abscess.

Chronic prostatic abscess may be overlooked and unrecognized as the direct cause of many conditions: chronic urethral discharge; vesical and rectal irritation; rectal fistula; chronic inflammation of the prostatic adnexa (the ejaculatory ducts and seminal vesicles); suppurating epididymitis and orchitis; nocturnal emissions.

Any abscess of the prostate may open into the rectum, bladder, urethra, perineum, or suprapubic region. Finally there is, in the case of acute abscess, the imminent danger of the general involvement of the pelvic fascia, ending in septicemia. It is manifest that a prostatic abscess is a constant menace. Its evacuation must not be delayed. It cannot be denied that oftentimes spontaneous evacuation is followed by a complete cure, but the outlook is many times more favorable with immediate operation. Sometimes the only cure is in complete removal of the gland.

Diagnosis.—There is usually a history of gonorrhea, recent or remote. Fever and a few chills; violent perineal pain, radiating to the rectum and thighs; painful and difficult urination and defecation point to probable suppuration in the prostatic region. A little later perhaps the perineum is reddened, swollen, and infiltrated. Complete the diagnosis by introducing a well-oiled finger into the rectum, which will excite much pain. On the anterior wall of the rectum will be found a large unsymmetrical swelling, more or less clearly fluctuating, and which loses itself in a doughy tumor extending toward the sides of the rectum and the anus. Now must one operate even though there be some pus discharging through the urethra, having begun spontaneously or following the passage of a catheter. Such drainage is quite insufficient.

There are two methods of *operation*: (a) the *rectal route* when the abscess is about to burst into the rectum; (b) the *perineal route*, under all other conditions. In either condition *general anesthesia* is

indispensable. The perineum and its vicinity are carefully sterilized and the patient placed in the lithotomy position for the perineal incision.

Rectal route: Place the patient on the right side, flex the left thigh on the abdomen and let the assistant hold up the left buttock. Dilate the anus and give the rectal mucosa a thorough lavage, washing with soap and water and gauze, followed by an alkaline antiseptic solution.

Retract the posterior wall of the rectum with a Sims' speculum. The anterior wall will thus be exposed to inspection. Locate by

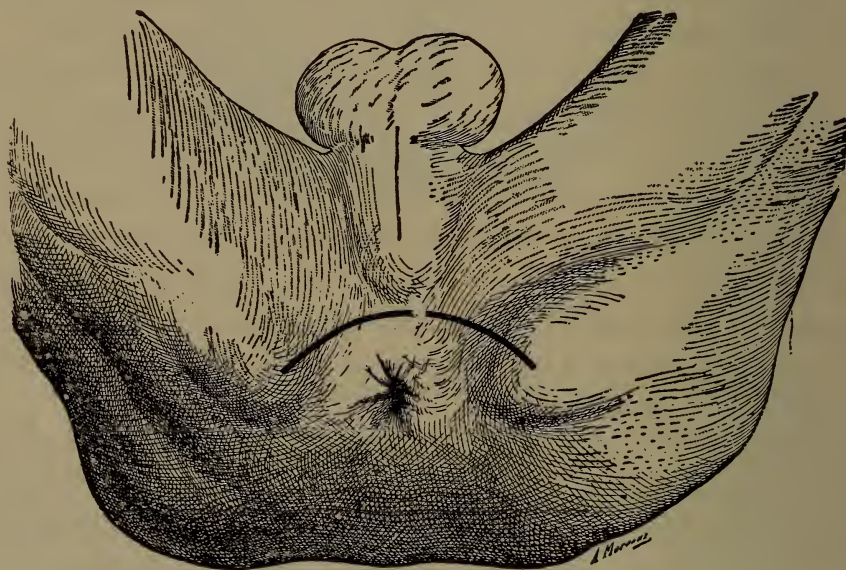

FIG. 313.—Prostatic abscess; patient in lithotomy position; incision between bulb and anus extending laterally to the ischial tuberosities. (Veau after Pierre Duval.)

touch the thinnest part of the abscess wall, for the tumor will not be so conspicuous to sight as it is to the touch. Without hesitation push the point of the knife $\frac{1}{2}$ inch into the tumor. This is to be done by sight and not by touch. When the pus flows, enlarge the opening, cutting toward the anus. Make the opening at least an inch in length. Favor the flow by slight pressure, and finally irrigate. You may be satisfied with that, leaving no drainage, but repeating the rectal flushing several times daily at first. If the cavity is deep and if there is considerable oozing, it is better to

pack very lightly with aseptic gauze, which will be expelled with the first movement of the bowels.

Perineal route: An incision 1 inch in front of the anus, transverse, slightly curved with convexity forward (Fig. 313). This incision divides the skin and superficial fascia—edematous, it may be. Separate the edges of the wound and identify, if possible, the muscular layers composed of the transversus perinei, the sphincter ani and accelerator urinæ, which, coming from the cardinal points, meet at the “central tendinous point of the perineum,” which is to be next

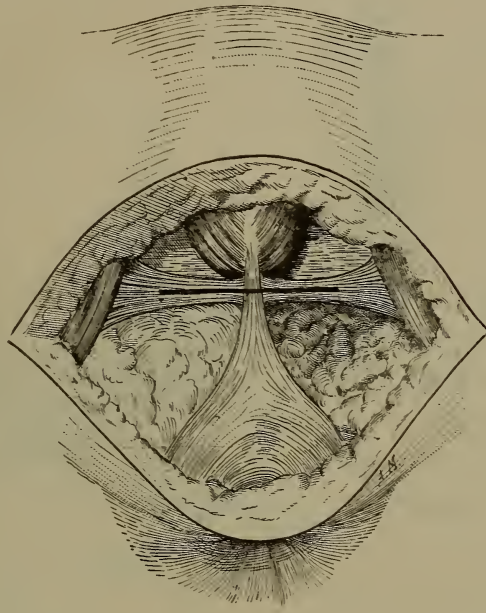


FIG. 314.—Prostatic abscess. Showing relation of structures concerned in operation; in front the bulb of the urethra, on either side of the erectors of the penis, transversely the transversus perinei which is divided parallel with its fibers. (Veau after Pierre Duval.)

incised. If these structures are not recognizable, the bulb of the urethra covered by the accelerator urinæ can at least be found. It is a prominence which the finger if not the eye will readily detect. Incise transversely through the middle of the transverse perinei (Fig. 314), or at least just behind the bulb. The transversus perinei artery will be divided. Now draw the bulb forward out of the way with a retractor and pull the posterior lip backward with an artery forceps.

Make the third transverse incision through the layer now well ex-

posed, viz.: the superficial layer of the triangular ligament, a dense, fibrous membrane. The abscess is now covered only by the deep layer of the triangular ligament, and this is best opened up with the grooved director, working *forward* in order to avoid the rectum, which lies immediately behind (Fig. 315).

As soon as the cavity is located, enlarge the opening with the forceps, irrigate gently, place a drainage-tube and use an absorbent dressing, which is to be removed each morning and evening and after stool.

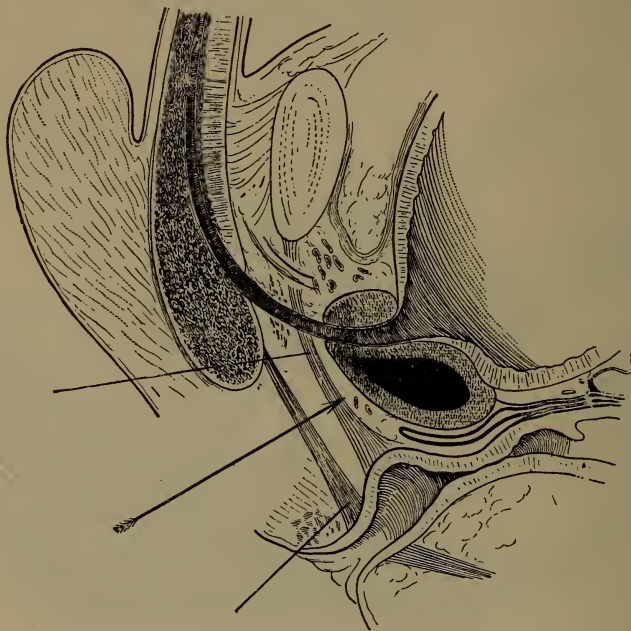


FIG. 315.—Prostatic abscess; showing relation to bladder and rectum and the muscular and fibrous layers to be divided. (Veau.)

Irrigation and Drainage of the Seminal Duct and Vesicle.—Purulent accumulations in the seminal vesicles demand relief on account of the frequent urination and other symptoms which sometimes may be attributed to the prostate itself.

Belfield, of Rush Medical College, accomplishes the relief of these conditions by drainage through the vas deferens.

The vas deferens is caught between the fingers at the base of the scrotum and brought up against the skin and held by a half-curved needle passed through the skin under the vas. A half-inch incision under local anesthesia is then made over the vas; it is exposed and

opened by a longitudinal or transverse incision. The blunted needle of a hypodermic syringe is then passed into the canal and the solution injected. The liquid traverses the vas and the ampulla, and distends the seminal vesicles.

If necessary the vas may be stitched to the skin by a fine silkworm-gut suture, and a fistula thus established, through which daily injections may be made. By this means, too, the vas is made to serve as a drainage-tube for the ampulla.

A fine silkworm-gut may be passed into the canal and left until the next injection. Belfield recommends the procedure for chronic gonorrheal infections of the seminal canal; chronic pus infections in the elderly (often mistaken for enlarged prostate); for acute gonorrheal spermato-cystitis; and for the abortion of threatened epididymitis.

VULVAR ABSCESS

The labia majora are composed of areolar and fatty tissues, bounded on one side by skin and on the other by mucous membrane. These integuments have many sebaceous follicles and are exposed to various forms of infection and traumatism. Along these sebaceous follicles and the lymphatics, agents of suppuration may travel to reach the areolar tissues, which are so prone to yield to the attack.

The traumatisms of accident and brutality and excessive coitus then are the *predisposing* causes; the streptococci and gonococci, the *specific* agents of inflammation of the vulva, which may end in abscess. The suppuration takes on the diffuse rather than the circumscribed form. The labium majus of the affected side is swollen, doughy, reddened, dry, and there are the other local and constitutional signs of suppuration. The skin, apparently more than the mucous membrane, is involved and the lesser labium, scarcely at all. In order to avoid general infection, or an ugly slough from spontaneous evacuation, the abscess must be incised immediately. The presence of pus can nearly always be determined by fluctuation. After careful antiseptic preparation, a vertical incision in the site of the greatest swelling, usually in the integument, will be sufficient. There are no vessels to fear. Ordinarily, a strip of iodoform gauze

will furnish sufficient drainage. An absorbent dressing and rest will soon bring about a cure.

VULVO-VAGINAL ABSCESS. (ABSCESS OF BARTHOLIN'S GLAND)

Beneath the vaginal mucous membrane, near the junction of the lateral and posterior walls, between the lesser labium in front and the triangular ligament behind, is Bartholin's gland, one on each side. The gland is normally about the size of a small almond, and is about 1 or 1½ inches from the vulvar orifice. Its duct opens into the vulvar canal just external to the hymen or its remains, the carunculæ myrtiformes. Its lymphatics empty into the superficial glands.

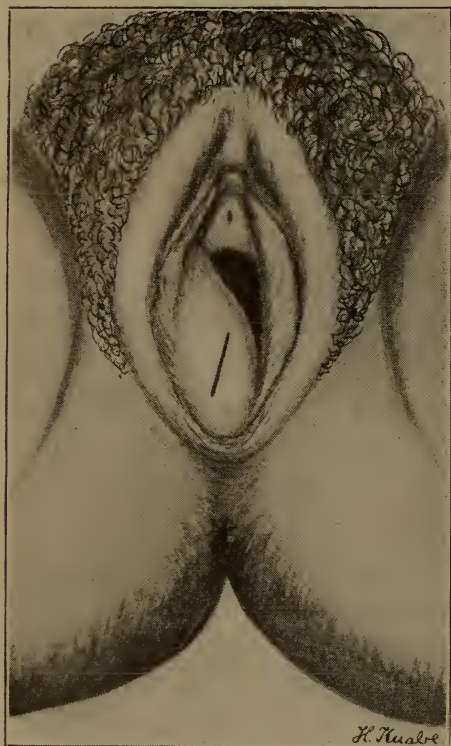


FIG. 316.—Vulvo-vaginal abscess.
Direction of incision.

Its relation of greatest surgical importance is with the venous plexus (the bulb of the vagina), which covers its upper half and which may be wounded by too free incision. As in the case of vulvar abscess, the cause of supuration is an infective agent, most frequently the gonococcus, which reaches the gland by way of the excretory duct. Excessive coitus is a predisposing cause.

The symptoms at first are those

of acute inflammation of the vulva or vagina; finally the symptoms become localized.

On examination the vaginal orifice is found to be almost closed on account of the swelling, and the mucous membranes hot and dry. The examining finger detects on the affected side a well-defined body varying in size, perhaps no larger than a chestnut, perhaps as

large as a hen's egg. It is clearly circumscribed. The labium majus is only slightly edematous ordinarily, the lower part more so. The abscess must be incised as soon as fluctuation is present in the slightest degree. Several serious consequences may attend delay. The inflammation may follow the vaginal areolar tissues into the pelvis; there may develop a phlebitis, or sloughing of the veins, or lymphangitis, or, what is more common, there may result a recto-vaginal fistula.

Operation.—Cleanse the parts carefully under local or general anesthesia, incise the tumor in the direction of the long axis of the vagina from within outward (Fig. 316). Incise thoroughly, as this is the means of securing the drainage that will prevent a fistula. The incision must not be deep near the vaginal orifice for fear of wounding the bulb of the vestibule. A strip of gauze will favor healing from the bottom of the abscess. The region should be frequently douched.

PELVIC ABSCESS

Separating the pelvic peritoneum from the organs of this region are loose areolar tissues which are prone to suppurate when attacked by infective agents.

Pelvic cellulitis usually begins as a lymphangitis, following the absorption of bacteria from some pelvic focus, usually the Fallopian tubes. A salpingitis is the most frequent cause of pelvic abscess. The arrangement of the fascia and organs is such that the inflammatory exudates gravitate to the cul-de-sac of Douglas.

Left to its own course, the abscess may open into the vagina, rectum, or bladder; less frequently through the abdominal wall, saphenous opening, pelvic floor, obturator foramen, sacro-sciatic foramen, or into the peritoneal cavity.

Diagnosis.—The history usually given points to an attack of pelvic cellulitis, following an abortion or complicated confinement, or some pelvic or abdominal traumatism. The temperature remains about 100° with exacerbations reaching 103° to 104°. There are all the symptoms of septic abortion.

On pelvic examination you are able to define a mass bulging down into the recto-uterine pouch. This taken with the fever and pain,

and perhaps some *edema of the vulva*, points without doubt to the nature of the trouble. A colpotomy should be done as soon as possible. The instruments needed are a speculum, a vulsellum forceps, a long artery forceps or dressing forceps, curved scissors, a scalpel, an irrigator, drainage tube, and iodoform gauze. General anesthesia is usually necessary, though in the simpler cases local anesthesia will suffice. Lithotomy position; the thighs held well apart, the shoulders lowered, the pelvis slightly elevated.

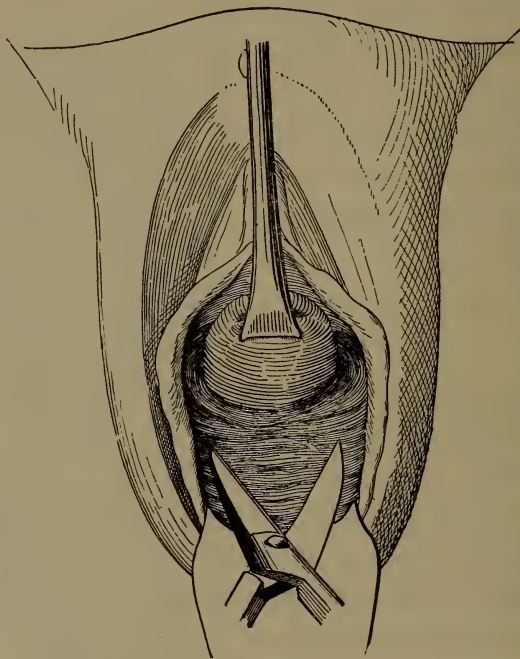


FIG 317.—Incision of the vaginal mucous membrane for abscess in the posterior cul-de-sac. (Veau.)

A careful antisepsis: Shave the vulva and disinfect the inner surface of the thighs, and the pubic region as well. Disinfect the vagina, rubbing it with soap and water first and being careful to reach every part of the mucous membrane, using the finger wrapped with sterile gauze. Finally irrigate with 1 to 2000 bichloride or other antiseptic solution. Cover the outside parts with sterile towels. Now retract the posterior vaginal wall with a Sims' speculum. With the vulsellum forceps seize the posterior lip of the cervix and pull the cervix forward (Fig. 317). You will now be able to see the site which

is to be incised. The tumor may be conspicuous, the edema and fluctuation well defined; or nothing but some edema may indicate the presence of the deeper seated inflammation. Do not attempt a mere puncture, however well defined the pus cavity may be. With a curved scissors or scalpel incise the mucous membrane of the vault of the vagina 1 inch behind the base of the cervix. Make an incision from side to side, but do not approach too near the vaginal walls else the arteries there may be wounded. Enlarge the wound by stripping its edges back a little. The abscess wall is exposed and with a little puncture the pus will flow. However, it may be that the

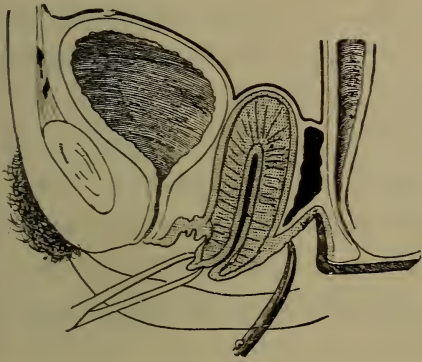


FIG. 318.—Showing the uterus pulled down, preparatory to opening the abscess in the posterior cul-de-sac. (Veau.)

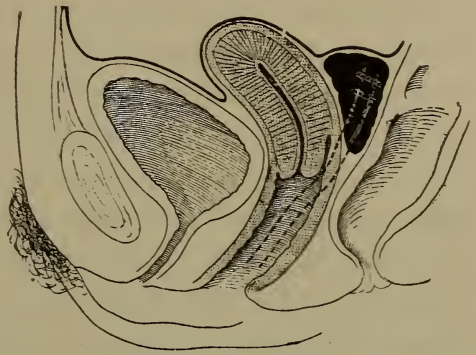

FIG. 319.—Showing relations of abscess in the posterior cul-de-sac. Dotted lines represent drainage tube. (Veau.)

pus is higher up and separated from the mucous membrane by thick and edematous areolar tissues, and this must not be taken for the abscess. From it will flow a serous fluid which must be accepted as a proof of pus higher up.

With the finger or an artery forceps follow the posterior wall of the uterus upward. Do not dissect backward. The rectum is there (Fig. 318). Follow the posterior wall of the uterus to avoid danger. There is always some hemorrhage, in nowise dangerous. It may be necessary to dissect upward for an inch; it will seem further than it really is.

When once the cavity is opened into, enlarge the orifice and with the finger make careful search for a secondary cavity. If you irrigate, do not employ much pressure. Do not pack the cavity with

gauze. Introduce a long drainage-tube to the top of the cavity. Its lower end must not protrude at the vulva (Fig. 319). Pack the vagina lightly, changing the packing every day without disturbing the drainage-tube. You may wash out the vagina, but do not use much force. Replace the drainage-tube by a smaller one about the tenth day if the temperature is normal. It is likely that it will be pushed out spontaneously, and if it cannot be reinstated and the temperature is normal, it is certain that it is no longer necessary.

SUBPHRENIC ABSCESS

A localized peritonitis is possible only in those localities not occupied by coils of small intestine. The region immediately below the diaphragm is of this character, and it is practically shut off from the general peritoneal cavity by the transverse colon and its mesocolon. This space is subdivided by the falciform ligament into a right, occupied by the liver; and a left occupied by the stomach, pancreas, duodenum, and spleen. Guibal describes five subdivisions of the subphrenic space, in any of which pus may collect (Revue de Chirurgie, April, 1909).

One is retro-peritoneal; four are peritoneal. The retro-peritoneal space contains the termination of the esophagus, the posterior border of the liver, the pancreas, duodenum, colon, and kidneys.

Of the peritoneal spaces two lie between the liver and diaphragm and may be the seat of abscesses following lesions of the liver, gall-bladder and ducts, pylorus, stomach, and duodenum. The third or perisplenic space, may be infected through the greater curvature of the stomach, the spleen or splenic flexure of the colon. The fourth space, or the posterior gastro-hepatic, may be infected through the posterior surface of the stomach, the pancreas, or liver.

In effect, subphrenic abscess is a localized purulent peritonitis, and whatever part the various adjacent organs may play in its production, yet the most frequent cause of subphrenic suppuration is *appendicitis*. The pus forming around the appendix, or behind the cecum, follows the ascending and then the transverse colon to reach that region.

Sometimes it is impossible to determine the original focus of in-

flammation. Usually, however, if the history of the case is sufficiently definite, one may arrive at a conclusion. For example, if we find a patient with subphrenic abscess and there has been a history of gastric discomfort, vomiting of blood, etc., one would decide upon perforating gastric or duodenal ulcer. If there has been a history of jaundice and symptoms pointing to the right hypochondrium, the liver, or its ducts, should be accused; if there has been clear history of previous attacks of appendicitis one need not be in doubt as to the starting-point of the condition with which he has to deal.

Diagnosis.—You will have, then, usually, a history of some visceral disturbance followed (very quickly in case of perforation of the stomach) by a chill, fever, malaise, pain in the upper abdominal pole. The symptoms, to be brief, are those of peritonitis anywhere. Suspecting from these symptoms an accumulation of pus in the region just below the diaphragm, proceed to a methodical examination by means of inspection, percussion, and palpation. The quantity of pus may be so great, or so near the front, that the bulging of the anterior abdominal wall may settle the matter without further examination. In obscurer cases it will be necessary to recall the normal limits of dullness, or tympany of the various organs, in order to determine the nature and degree of their displacement. Remember, too, that in all cases following perforation the abscess cavity will contain gas which will be another source of confusion. But after all, in the typical cases, guided by the history, the symptoms of sepsis and the local signs, one can rarely go astray. Aseptic aspiration may be resorted to in the doubtful cases, and *one need not hesitate to aspirate several times.*

But previous to aspiration the patient should be prepared and should be operated upon immediately if pus is found. The X-ray may be helpful in diagnosis, since it shows an abnormal conformation of the diaphragm, and that it is immobile on the affected side.

The great majority of sufferers from this condition not operated upon die from sepsis. A general peritonitis may supervene. Left to itself, the pus may open into the alimentary tract, which is to be regarded as a complication rather than a cure, for such cases usually terminate fatally from slowly increasing sepsis. In rare instances

it may open through the abdominal wall. Most often, however, it extends toward the thorax, opening through the diaphragm into the lung to be coughed up. Oftentimes the imminence of rupture into a bronchus may be predicated from increased pain in the shoulder of the affected side, increased cough and muco-purulent or sanguineous expectoration, and heightened temperature. The pleurisy nearly always present may be fibrous, serous or purulent. An empyema, so originating, may even mask the primary condition. But whether the pus opens into a bronchus, or the digestive tube, or through the abdominal wall, the result of nature's drainage is too doubtful. It is imperative to operate as soon as a diagnosis is made, for even a latent case may fire up suddenly and march to rapid death. The prognosis, in fact, does not depend more upon the character and skillfulness of the operation than upon its timeliness.

Operation.—The method of operation depends upon the location of the pus; it may be (A) near the anterior abdominal wall, or (B) it may be inaccessible from the front.

(A) If the epigastric region is bulging, the incision should be over its greatest prominence or where the abscess seems to point. Redness and edema of the skin should be taken as an indication that the pus is well walled off and that there is no danger of the incision opening into the general peritoneal cavity, which is an accident always to be guarded against. One may cut directly through these tissues whether it be in the linea alba or the line of either border of the rectus.

Once the cavity is opened and emptied, it is to be carefully wiped out, for there are usually collections in its deeper parts; and before drainage is inserted it should be cautiously irrigated with normal salt solution. Moynihan recommends the "cigarette drain" which may be well saturated with boracic acid. A counter-opening in the loin may be required for efficient drainage. The cavity must fill in by granulation which may require six or eight weeks.

(B) 1. If the abscess is behind the liver on the right side, an incision along the costal margin is perhaps the best. Divide the muscles, or even resect the twelfth rib, and then, by blunt dissection, follow the under surface of the diaphragm until the abscess cavity is reached. If the abscess is retro-peritoneal it may be nec-

essary to expose the upper pole of the kidney and to draw it downward and forward, exposing the renal fossa on the under surface of the liver, and thence work upward between the posterior margin of the liver and the diaphragm. Insert drainage-tubes packed about with iodoform gauze.

2. More often it is best to employ the *transpleural route* (Fig. 320), which will require resection of a rib or perhaps more than one. The incision exposes the eighth or ninth rib—right side; eighth or seventh—left side. (For technic of resection of rib, see page 506.) The center of the incision lies in the axillary line and about $3\frac{1}{2}$ inches of rib are to be removed.

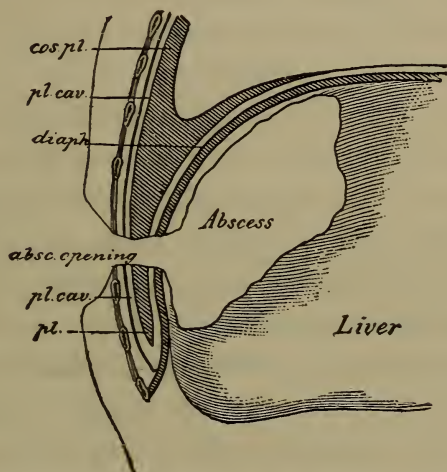


FIG. 320.—Subphrenic abscess. Opening in the mid-axillary line. (Bryant.)

Now determine the condition of the pleura of which the cul-de-sac is exposed. In this region the pleura is easily stripped away from the chest wall, and so room may be made to open the diaphragm without opening the pleural cavity. If this can be done, evacuate and drain the abscess as described above.

Ordinarily it will be necessary to *open the pleural cavity*, which is first to be aspirated if it contains serum; or opened and wiped out if it contains pus. If it is not purulent it is likely to become so unless steps are taken to prevent its infection by suturing the diaphragm to the upper lip of the opening in the chest wall.

You are now ready to *open the diaphragm* and the pus cavity. In some cases a perforation will be found in the diaphragm, and this is

to be merely enlarged; or, if inconvenient for drainage, may be disregarded and the incision made lower down. Drain.

A single case will exemplify some of the characters and progress of the disease. A farmer, thirty years of age, had suffered for several years with a severe affection of the stomach, of which no definite diagnosis had been made. Though debilitated, he was yet able to do his work about the farm. Without warning he was suddenly seized with a violent hematemesis.

The attack continued for some hours without relief and the total amount of blood vomited was appalling. But gradually the bleeding ceased, leaving the patient prostrate. A tardy convalescence followed, interrupted by an intermittent fever diagnosed as malaria. A month elapsed and he was brought to bed with a fresh access of "ague"—chills, fever, and exhausting sweats. At this time a consultation exposed the real character of the process. There was a vast accumulation of pus in the left side involving the abdomen and thorax. A constant irritating cough, a bloody sputum, severe pain in the left shoulder, and increased fever and dyspnea seemed to indicate the nearness of rupture into a bronchus. In fact this occurred within a few hours after our examination. A large amount of pus was coughed up and with temporary relief. An operation was refused. Indeed, it offered but little hope so late in the course of the disease. A week later he died. Had the perforation of the gastric ulcer been recognized, or even later the character of the sepsis been understood, an operation would have saved his life.

PSOAS ABSCESS

Psoas abscess is a term sometimes rather loosely applied to purulent collections in the iliac region. Properly speaking, it is a tubercular abscess having its origin in caries of the lower cervical, dorsal, or lumbar vertebræ.

It is necessary to recall the arrangement of certain muscles and fascias. The psoas muscle, a rounded fleshy mass, lying alongside the bodies of the lumbar vertebræ, extends across the pelvic brim, and passes in front of the hip-joint to be inserted into the lesser trochanter. The iliacus, its companion muscle, occupies the iliac

fossa and converges below in a tendon which merges with that of the psoas. These muscles are covered by the iliac fascia which is so attached as to make the iliac fossa practically a closed compartment.

The fascia is separated from the muscles by a loose areolar tissue in which suppuration may originate the which constitutes an iliac abscess. This fascia on its other side is separated from the peritoneum by another layer of connective tissue—the subperitoneal areolar tissue, which is liberally supplied with fatty tissue and constitutes a site of lowered resistance to germs originating in the pelvic viscera, the cecum, the sigmoid, and the appendix. Suppuration under this layer usually ends as a pelvic abscess.

It is evident, therefore, that an iliac abscess beginning as such, and abscess in the subperitoneal tissues, are quite distinct from psoas abscess, expect that all have common points of possible opening. The iliac fascia covers the muscles in the iliac fossa, but it also extends upward in such manner as to ensheath the psoas and separate it from the bodies of the vertebræ.

In the case of caries, the products of decomposition may burst through the vertebral ligaments and the sheath, and thereafter follow the psoas muscle downward. The muscle itself may be decomposed in whole or part, and the accumulating pus may be directed by the tubular sheath to its point of termination below Poupart's ligament to the outer side of the iliac vessels. Or, again, the abscess may burst through the sheath higher up and point in the loin (lumbar abscess); or may point just above Poupart's ligament in the gluteal region, the pelvis, the scrotum, or thigh.

The diagnosis of psoas abscess rests upon the history of the case, which points to spinal trouble, and upon the presence of fluctuating swelling in the iliac fossa, or below Poupart's ligament. Usually the hip is flexed in some degree, as by that position the tension in the psoas is relieved.

This flexion and some apparent stiffness in the joint might lead to a mistaken diagnosis of hip-joint disease. The swelling is to be distinguished, also, from a hernial tumor, by the fact that it is fluctuating and lies at the outer side of the iliac vessels.

Treatment.—As in all cases of tubercular abscess, secondary infection and amyloid degeneration are most to be dreaded. For

that reason, spontaneous rupture and treatment by small incision and prolonged tubal drainage are equally dangerous.

As early as possible an aseptic evacuation must be practised. This may be accomplished by puncture and the subsequent injection of iodoform emulsion; this seems the advisable procedure, if the abscess is pointing in the region of Poupart's ligament, and it is likely that the destructive process in the vertebra is an abeyance. In general, most authorities recommend the operation of Treves, by the lumbar route.

Operation.—Begin by locating the last rib, the crest of the ilium, and the outer border of the erector spinæ. The incision, $2\frac{1}{2}$ inches long, with its center half way between these bony landmarks, follows the outer border of the erector spinæ and exposes at first the lumbar fascia.

Divide the first layer of the lumbar fascia and expose the erector spinæ. Develop its outer border the whole length of the wound and retract the muscle inward, exposing the middle layer of the lumbar fascia. Divide this layer which exposes the quadratus lumborum.

Divide the quadratus lumborum along the line of its attachment to the tips of the transverse processes, which exposes the deep or anterior layer of the lumbar fascia. Divide this layer and finally the psoas magnus is exposed. Divide the attachment of the psoas magnus sufficiently to introduce the finger, which opens up the abscess cavity and determines the condition of the carious vertebra.

The abscess cavity is to be treated by thorough irrigation with an antiseptic solution, wiped vigorously, or even curetted. The various layers are sutured without drainage and an antiseptic dressing applied.

Previous to suturing, the cavity may be filled with iodoform emulsion; or, as Walsham suggests, after the cavity is cleansed it may be packed with strips of iodoform gauze, which are to be changed on the third or fourth day. If at the end of a week no pus has appeared and the cavity is lined with healthy granulations, the wound may be closed by secondary suture.

CHAPTER XXI

PHLEGMON: ACUTE SPREADING INFECTIONS

The areolar tissues are less resistant than others. The streptococci in their mode of development tend to spread out so that, under favorable circumstances, the streptococcic infection of the subcutaneous connective tissues becomes one of the most dangerous conditions, demanding immediate and radical surgical intervention.

The rapid development of toxins makes death from septicemia to be feared; or, short of this, there may be great destruction of tissue and subsequent loss of function.

Certain regions, owing to the opportunities for infection and the arrangement of the tissues, are more likely to be affected than others; but the general symptoms and the principles of treatment are the same.

One peculiarity of this inflammation is that pus is often slow to form, so that when the engorged tissues are incised in the earlier stages, merely a serum exudes. It is innocent-looking, but it is toxic in the extreme.

The point, then, is this—do not wait for pus formation and fluctuation, before evacuating these products. If pus has formed, *immediately* is none too soon to operate.

In the case of superficial phlegmon of moderate severity, it will often be harmless to try to localize the process by the use of hot antiseptic poultices or baths, but the safest thing is free incision for drainage.

The incision must reach the deepest layer of the affected tissues, as anything less is useless; it may even be harmful by introducing a new infection to tissues which were not previously involved.

Slight injuries, with subsequent localized accumulations of pus, are often the source of an infection which attacks the connective tissues, reaching them by way of the lymphatics, and then what was

a mere local and harmless infection at first, becomes a very dangerous diffuse phlegmon.

These minor conditions, therefore, are emergencies from the point of view of prevention. A few examples will serve to emphasize the principles governing their treatment.

PANARIS

This is an infection involving the tissues about the finger-nail. It may be limited to the epidermis, the dermis, the subcutaneous tissues, or the periosteum, the last condition being usually called a felon.

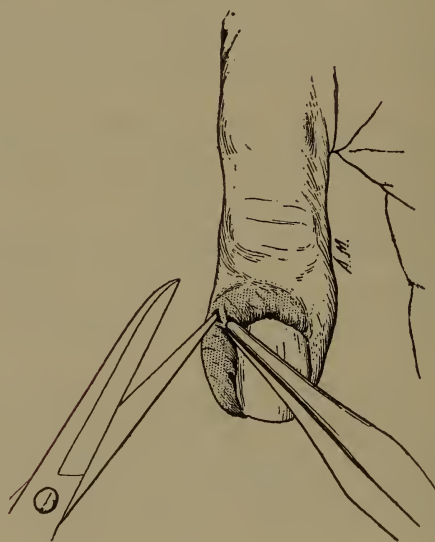

FIG. 321.—Opening a purulent phlyctena or “run a round.” (Veau.)

Panaris, Subepidermic.—The appearance at first is almost that of a blister, and all of the loosened tegument must be removed. No analgesia is necessary, as the epidermis is non-sensitive.

Begin by pricking the phlyctena with the point of the bistoury, and then trim around its whole circumference with pointed scissors (Fig. 321).

Carefully observe the denuded surface, and a small opening may be found, leading to a deeper cavity (button-hole abscess) which will require incision.

Complete the treatment by a prolonged antiseptic bath and antiseptic dressing.

Panaris, Subungual.—In this form the pus accumulates under the nail and loosens it. It will be necessary to remove the part of the nail lying over the pus accumulation. A cure can be obtained only at that price.

If it is confined to one side only, the skin is removed as described above, the sharp point of the scissors introduced under the nail, and enough of it resected to expose the suppurating surface. If both sides are involved, remove the nail completely.

Panaris, Subcutaneous (Felon).—Incise as soon as pus is suspected. No harm can be done even if there is no pus, while a day's delay after pus has formed may make a great difference.

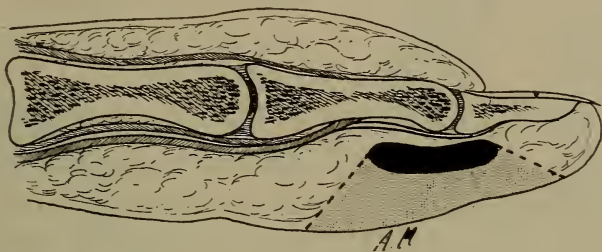


FIG. 322.—Illustrating the situation of the pus in a felon; the dotted lines represent the limits of the incision. (Veau.)

Under local anesthesia (Figs. 8, 9), make a longitudinal incision in the middle of the palmar surface where the pain is greatest (Fig. 322).

Do not make a mere puncture, as the whole pus cavity must be exposed. Incise deliberately and let the first stroke cut long and deep enough, after which explore the cavity with a small probe.

If there is a palmar prolongation, enlarge the opening, and if there is a dorsal prolongation, which is quite rare, make a counter-incision on the dorsum of the finger.

Immerse the hand in an antiseptic or normal salt solution for an hour. A drainage-tube is unnecessary, if the incision is properly made.

Dress with moist antiseptic gauze and give the hand a hot bath with each daily renewal of the dressing.

After two to eight days, or when suppuration has ceased, employ a dry dressing. The dry dressing favors cicatrization, but the moist dressing best relieves pain.

SUPPURATIVE INFLAMMATION OF TENDON SHEATHS

Every neglected infection of the fingers or palm may become a phlegmon of the tendon sheaths.

The great danger of these phlegmons is destruction or adhesion of the tendons, so that the finger remains permanently flexed or extended, unsightly, and more or less useless.

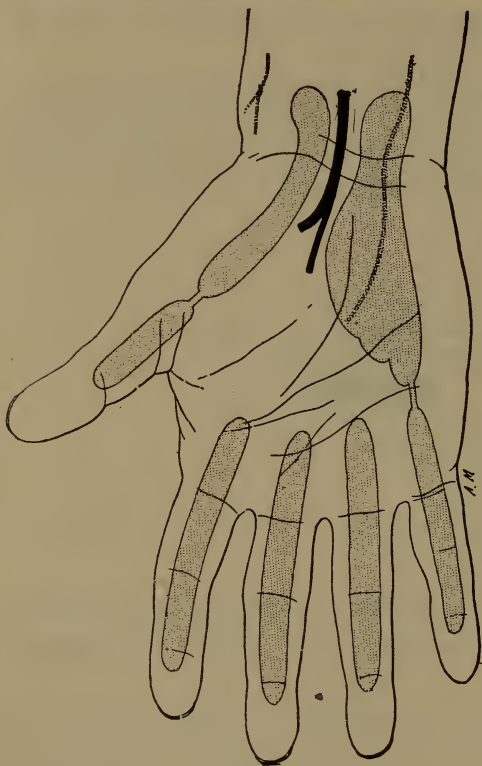

FIG. 323.—Diagram illustrating the arrangement of the synovial sheaths in the hand. Note that the sheath of the tendon of the little finger communicates with the sheath common to all the flexors of the fingers in the wrist and palm. Note also that the sheath of the flexors of the thumb extends into the wrist beyond the annular ligament. The median nerve passes under the annular ligament between these two common sheaths. (Veau.)

A threatened suppuration may often be prevented by a prolonged immersion in hot antiseptic or normal salt solution. This should be continued for an hour and used twice daily.

The Bier treatment is excellent for this purpose. This treatment is to be applied after suppuration occurs, but not until the pus is evacuated. It shortens the incision required and the time of repair.

As soon as pus is suspected, incise freely. Recall the anatomy of the parts (Fig. 323). The sheaths of the flexor tendons extend into the palm, whence the necessity of a palmar incision. The tendon sheaths of the thumb and of the little finger communicate with the common tendon sheaths in the palm, whence the additional gravity when they are involved. The common sheaths extend from the

palm under the annular ligament above to the wrist-joint, whence the necessity of incision in the forearm. There is in this incision an element of danger by reason of the median nerve, which lies on the middle of the front of the wrist between the two common sheaths.

The ulnar artery lies on the common sheath on the ulnar side. The incision must pass between the artery and the nerve.

Phlegmons of the sheaths of the first, second, and third fingers are not likely to extend further than the middle of the palm, while, on the contrary, phlegmons of the sheaths of the thumb and little finger are likely to point above the wrist.

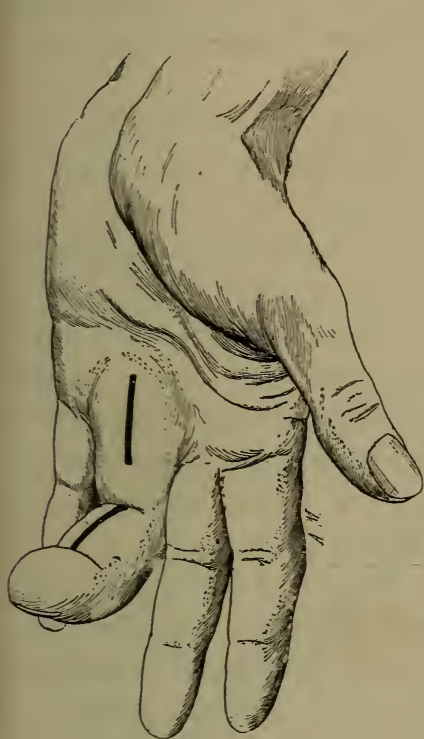

FIG. 324.—Suppuration of digital synovial sheath. Incisions. (Veau.)

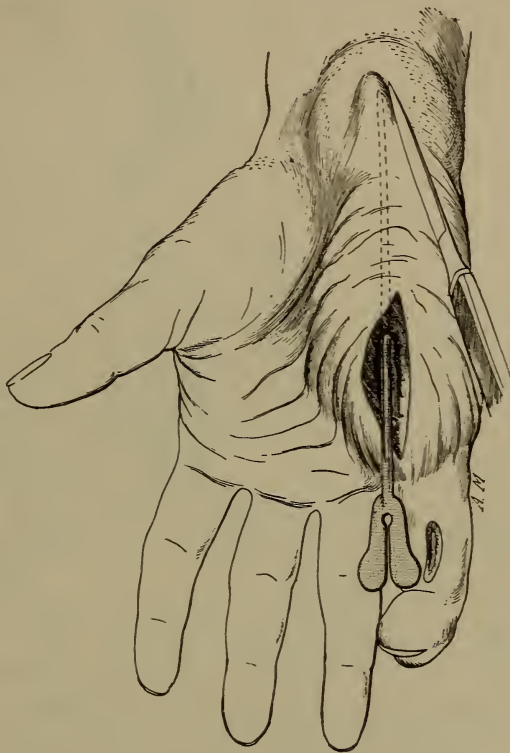

FIG. 325.—Opening into the upper part of the ulnar synovial sheath. (Veau.)

Operation for Phlegmon of the Synovial Sheaths of the Flexor Tendons in the Fingers.—A general anesthesia is usually necessary, for the pain is great. Make an incision about an inch long in the middle of the palmar surface over the point of great swelling. Incise to the bone to be sure of opening the tendon sheath. The wound must be of uniform length in the superficial and deeper tissues (Fig. 324). If necessary, make a similar incision over each of the phalanges and in the palm, but avoid opening into the joints. If the sheath is distended with pus, a drainage-tube is easily passed through from one incision to the other.

When the pus has been located, immerse the hand in a hot normal salt solution for an hour and repeat twice daily. This greatly favors the evacuation of pus and subsequent repair.

Employ moist antiseptic dressings at first.

Operation for Phlegmon of the Ulnar Synovial Sheath.—Continuous with the synovial sheath of the flexor tendon of the little finger, the ulnar synovial sheath is larger than the radial and its suppuration more serious.

These phlegmons are usually consecutive to neglected infections of the little finger.

Complete drainage is indispensable. Begin by making an incision over the radial border of the minimal metacarpal (Fig. 325). Avoid wounding the palmar arch, which might require ligation; but, after all, this is not a serious accident and permits a freer incision.

When the pus is reached, enlarge the incision so that the tendon may be seen the entire length of the wound.

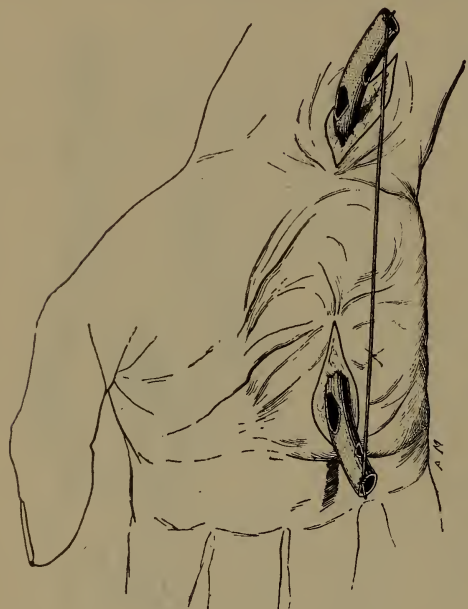
FIG. 326.—Drainage of phlegmon of the ulnar synovial sheath. (Veau.)

Superficially and deep, the incision must be of the same length.

Next introduce a grooved director into this incision and push it through the synovial cavity until its point, passing under the annular ligament, can be felt beneath the skin of the wrist. Incise carefully over this point until it is exposed, keeping to the inside of the tendon of the palmaris longus to avoid the median nerve. When the point of the grooved director is fully exposed, enlarge the incision to an inch and a half.

No artery of importance will be wounded. Pass a drainage-tube through from one incision to the other (Fig. 326).

Operation for Phlegmon of the Synovial Sheath on the Radial Side.—The palmar incision may be made through the muscles of the thumb along the line of the metacarpal, but it is preferable to make it in the commissure between the thumb and index finger.



Make an incision two fingers' breadth in length. At the depth of 1 or 2 inches you will find the pus. Pass a grooved director along the sheath as in the preceding case. It emerges beneath the skin above the annular ligament. Locate and expose the point of the director; in incising keep to the outside to avoid the median nerve. The radial artery is in no danger, as it is too far to the outside (Fig. 327).



FIG. 327.—Drainage of the radial synovial sheath. (Veau.)

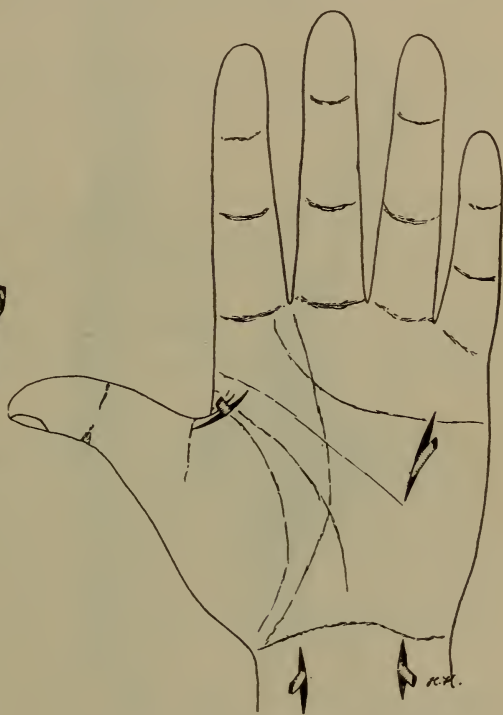

FIG. 328.—Drainage completed.

In the same manner as before, pass a drainage-tube. Immerse the hand twice daily for an hour in hot normal salt solution, and employ a moist antiseptic dressing. The drainage-tube will probably be unnecessary after the eighth or tenth day (Fig. 328).

SUBAPONEUROTIC PHLEGMON OF THE FOREARM

By direct infection, or by extension of infection from the hand, the areolar tissues beneath the fascia of the forearm may become the site of a diffuse suppurative inflammation.

If neglected, it follows the connective tissues into the intermuscular spaces and finally all the soft parts are more or less involved. Free incision must be resorted to without delay. In the earlier stages no pus will be present, but a straw-colored serum pours out along the line of incision.

Operation.—General Anesthesia. Over the site of the greatest swelling, make a free incision in the long axis of the member. This

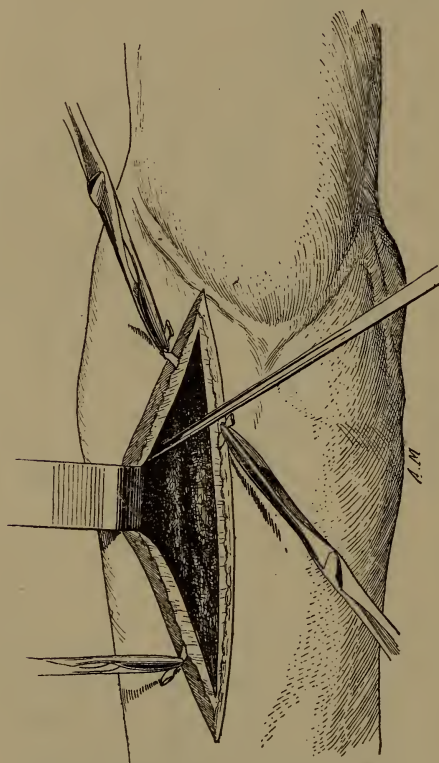


FIG. 329.—Incising the forearm for deep phlegmon. The grooved director searching for posterior prolongations of the pus formation. (Veau.)

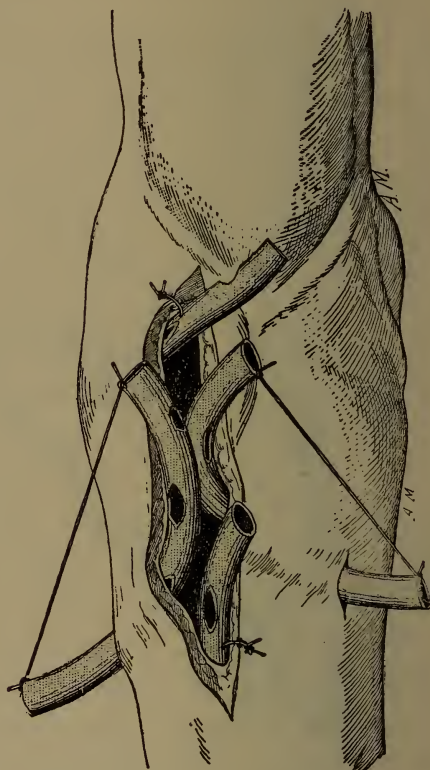

FIG. 330.—Note manner of fixing tubes in drainage for phlegmon of the forearm. (Veau.)

incision will traverse a thick, infiltrated layer to reach the aponeurosis, which incise carefully, when, in most cases, the pus will pour out. Enlarge the opening sufficiently on the grooved director.

Irrigate thoroughly with hot normal salt solution and mop out with sterile gauze. With a grooved director explore all the parts of the cavity for a diverticulum (Fig. 329).

If necessary make a counter-opening. Tie such of the larger vessels as are divided and place several large drains (Fig. 330). Change the dressing twice daily, irrigating each time with hot normal salt solution.

About the eighth day, smaller drains may replace those first employed and these are usually unnecessary after two weeks. Watch the temperature closely. If it rises, there is a retention of pus, the site is not sufficiently drained, or there is a new infection.

DIFFUSE PHLEGMON OF THE ARM

All the soft parts are involved and infiltrated with serum. The arm is greatly swollen, edematous, and there are marked symptoms of septicemia.

General anesthesia is indispensable. The freest kind of incision, even down to the bone from above downward, is essential. Three or four such openings are not too many.

Irrigate freely with hot normal salt or bichloride solution. Moist antiseptic dressings should be used and at first should be changed several times daily.

Incision with the Thermo-cautery, Lejars.—With the *thermo-cautery* make several large incisions in the axis of the member, each at least four fingers' breadth in length and about two fingers' breadth apart (Fig. 331). Under the skin will be found a thick layer, infiltrated with bloody serum. Cutting through this, the aponeurosis appears, which incise and thus expose the muscles.

On the inner side avoid the vessels. If some of the large subcutaneous vessels are opened and bleed too freely, tie them. Irrigate and dress with sterile gauze saturated with peroxide of half strength.

Change the dressing and irrigate two or three times daily. Change to dry dressings when granulation is well under way. Later, skin grafting may be necessary. In the long time necessary for repair, massage and passive motion must be given the muscles.

PHLEGMON OF THE NECK

An infection in the floor of the mouth may become diffuse and spread rapidly down the neck. The symptoms of sepsis will be

aggravated in the extreme and death may rapidly supervene, either from sepsis or asphyxia. The whole neck may be brawny and edematous, and the patient's condition is pitiable indeed.

Lejars recommends the thermo-cautery as offering the best hope of a cure, though seemingly brutal.




FIG. 331.—Incising a phlegmon of the arm with the cautery. (*Veau.*)

Under general anesthesia several deep vertical incisions are made with the thermo-cautery with numerous punctures between (Fig. 332). Do not go too deep over the anterior border of the sternomastoid, for the great vessels are there.

Pack each incision and puncture with gauze saturated with peroxide of hydrogen, and cover the whole with a similar dressing

and absorbent cotton. The dressing must be kept saturated with the peroxide. In the meantime use the antistreptococcic serum.

Watson Cheyne also urges the use of the serum, but does not use the thermo-cautery. His plan is to incise through the deep fascia

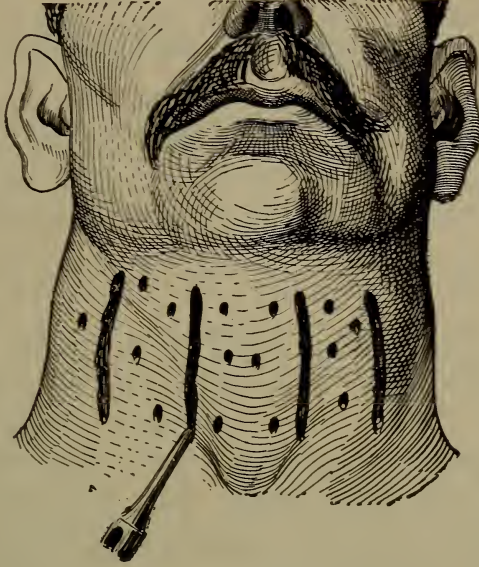

FIG. 332.—Manner of incising phlegmon of neck with the cautery. (*Veau.*)

in several places, enlarging the openings by blunt dissection. The wounds are to be freely sponged with undiluted carbolic acid, powdered with iodoform, and packed with strips of iodoform gauze.

CHAPTER XIX

ACUTE OSTEOMYELITIS

This is an acute infection of great gravity, more often due to the staphylococcus or the streptococcus; but, in rare instances, the pneumococcus, bacillus coli communis, or tubercle bacillus may be the exciting cause.

Usually the germ reaches the affected site by way of the blood current, originating in a focus quite unsuspected. In every case of bone infection especially where first one bone and then another is involved, the middle ear conditions must be investigated.

In many of these cases a quiescent mastoid abscess is the focus constantly supplying the blood stream with new crops of the infective agent. The patient recovers completely only after the mastoid is drained. In other cases the germ reaches the affected site by way of the lymph channels or by continuity of tissue, the primary focus not having revealed itself. But in all cases the predisposing causes are found in certain constitutional states and slight traumatisms.

The diagnosis is not always easy in the beginning, as the constitutional symptoms may be marked before the local signs are quite definite.

Acute infectious arthritis, the so-called inflammatory "rheumatism," is the wrong diagnosis most often made but this affection does not have the symptoms of sepsis, though, indeed, the fever may be high. The pain is usually in the joint and usually in more than one joint.

Subacute arthritis likewise involves the joint, although it is to be remembered that an arthritis may be secondary to osteomyelitis and overshadow it clinically, but the history of the case will usually decide between arthritis and osteomyelitis.

Erysipelas may be thought of when, after a little while, the skin becomes brawny and edematous, but in erysipelas the skin is so involved from the first.

The symptoms may seem to suggest *typhoid fever* or other infectious fevers, but these may usually be ruled out by the absence of characteristic features.

The symptoms of *meningitis* are often present, but by the time they arise, the local conditions point to the nature of the trouble.

The general symptoms are those of sepsis; high fever beginning with a chill, rapid pulse, foul tongue, and in the severe cases, profound prostration, and finally delirium.

Locally the pain over the affected area is often extreme, and the least pressure tends to aggravate it. Gradually, as the inflammation spreads from the marrow through the bone to the periosteum, the skin begins to swell, redden, become edematous, and finally shows fluctuation.

In the virulent cases not operated upon, the patient dies within the first few days from septic infection. In the milder cases, even, large areas of the bone necrose.

The treatment, then, must be prompt. It is an emergency. There is only one thing of any use to be done. The suppurating marrow must be evacuated and the medullary canal freely opened and cleaned out. Local applications, poultices, or even incisions through the periosteum are illusory. The bone must be *trephined*, its cavity opened up at its most accessible part, and all the inflamed tissue scraped away. The whole extent of the canal may need to be opened, irrigated, drained, and treated with vigorous antisepsis. Free incision over the affected area, choosing the easiest and least dangerous approach, if possible reaching the bone through inter-muscular septa; incision and stripping of the periosteum over the proposed site of trephining; opening the bone cavity freely, wiping out the pus, curetting and chiseling away the necrotic bone, swabbing out the cavity with pure carbolic acid followed by alcohol; obliterating the larger cavities partially with muscle or fat when possible and employing tubal drainage—these are the *principles of treatment*, and aided in this way nature usually effects a cure.

In the case of long standing where the cavity is surrounded by new bone sclerosed and lacking in osteoblasts it may be necessary to use an artificial filling.

Mosetig-Moorhof's¹ iodoform-plombe is applicable to such cases as these. It is prepared as follows:

Equal parts of spermaceti and sesamoil are melted in an evaporating dish, then filtered into a Florentine flask and sterilized in a water-bath; 40 grams of finely powdered iodoform (not crystallized) are put into a sterile flask, and 60 grams of the hot fat mixture are added, under constant agitation. This agitation must be continued without interruption, until the mass solidifies. The flask is closed with a sterile rubber stopper. Before using, the plombe is to be heated in water-bath to a little above 50° C.

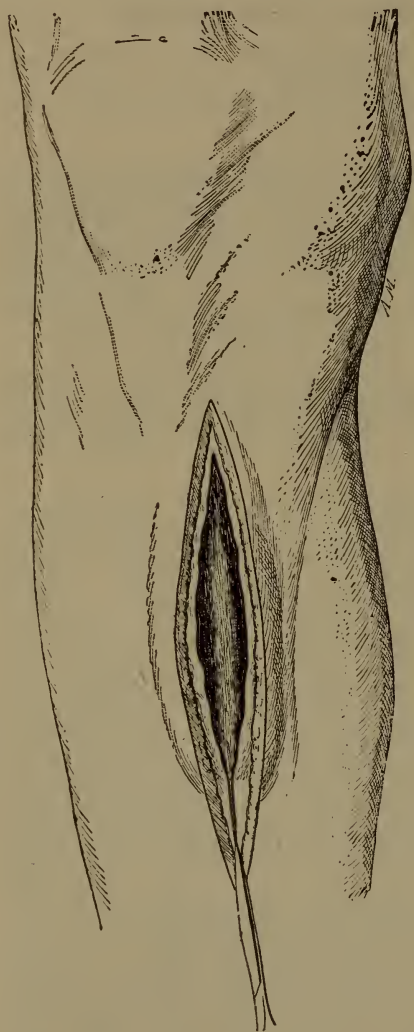


FIG. 333.—Exposing the tibial crest, opening into the subperiosteal abscess. (Veau.)

The bone cavity is most carefully prepared for the reception of the filling. Everything must be removed down to sound bone. The laws of gravity must, of course, be observed in filling the cavity. If the cavity is large, it is advisable to fill it in several steps, letting the plombe solidify in one portion, before any is poured into another. The cavity must be dry before the mixture is poured in. This may be accomplished by sponging, by the application of adrenalin to oozing points, by hot air, etc. The course of healing after iodoform filling is aseptic as a rule. Sometimes the temperature rises within

the first two or three days—so-called aseptic fever—which yields to a cathartic. The disposition of the sprouting granulations toward the solidified plombe varies between complete closure of the wound and healing by primary intention, and incomplete closure. In the

¹ Surgery, Gynecology and Obstetrics, Vol. 3, No. 4.

first cases, absorption of the plombe is effected through the steadily advancing granulations by vital phenomena; in the second, by partial displacement and expansion.

OSTEOMYELITIS OF THE UPPER END OF THE TIBIA

Here the disease occurs more frequently and here, fortunately, is most easily operated upon.

General anesthesia; special instruments: a mallet, a gouge, a periosteal elevator or rugine, and curette.

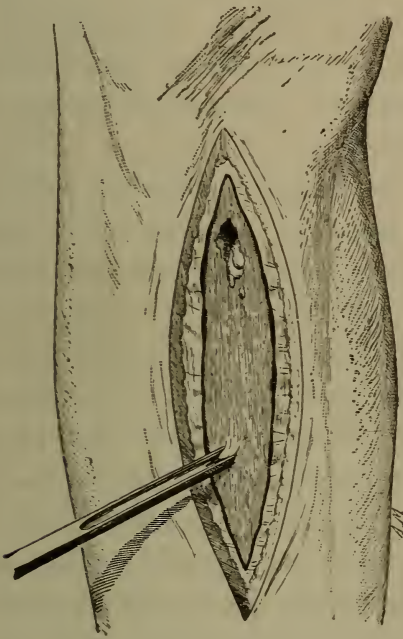


FIG. 334.—Trephining of the tibia: making the orifice. (Veau.)

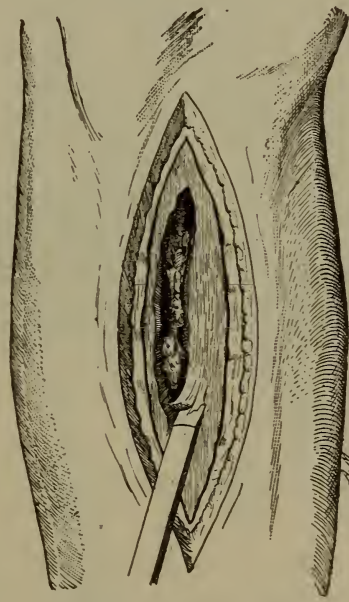


FIG. 335.—Enlarging the orifice and exposing the medullary canal. (Veau.)

Begin by elevating the limb to empty the blood vessels. About the middle of the thigh apply an Esmarch tube. Do not apply an Esmarch bandage, beginning at the toe and extending upward, for that only spreads infection.

On the right side, *the incision* commences at the level of the tuberosity and extends to the middle of the leg, following the sharp crest of the tibia just to its inner side. However engorged the tissues may be, this first incision reaches to the bone (Fig. 333).

Often by this first stroke, one opens into a pus cavity. Do not be

beguiled by this into thinking the operation completed. This collection is to be evacuated and drained, of course, but there is another one in the central canal. Extend the incision to the limit of the loosened periosteum. With the rugine, expose the anterior surface

of the bone. A fistulous opening leading to the medullary canal may possibly be found. In any event, proceed to trephine.

At the upper end of the incision make an opening with the gouge down to the canal. The pus will be almost certain to flow, but it is often difficult to distinguish from the marrow.

At the lower end of the incision, make another opening (Fig. 334). If again pus appears, it is certain that the lowest limit of the suppuration has not been reached and you must lengthen the incision. Continue to expose the canal until the full extent of inflammation has been exposed. It may require the removal of the whole anterior surface of the tibia, but you are engaged in saving life, so that bone is a minor consideration. Chisel away, then, all the anterior wall between the two limits of suppuration (Fig. 335). Curette vigorously

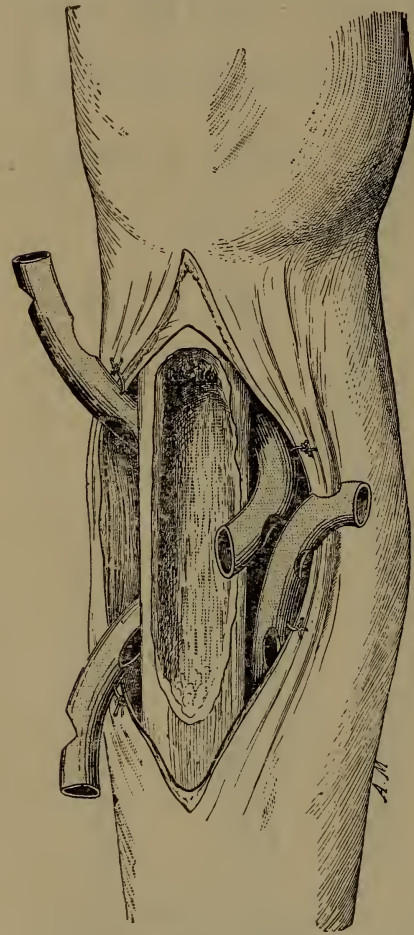


FIG. 336.—Trephining of the tibia completed. Tubes in place. (Veau.)

the medullary canal down to firm and uninflamed bone, and especially curette the upper part, for there the suppuration is greatest.

In the case of a child, the epiphyseal cartilage is quickly reached, and this one should try to avoid, since too free removal will end linear growth.

Mop the cavity with sterile gauze, swab with carbolic acid followed by alcohol or Tr. of iodine. If considerable oozing persists it may

be necessary to pack with iodoform on sterile gauze, otherwise simple tubal drainage is sufficient.

The drainage, however, must include the subperiosteal areas as well as the medullary canal in the septic cases (Fig. 336).

If the operation has been delayed, the muscles of the calf may be infiltrated with pus and will require drainage as in diffuse phlegmon.

If there is serous effusion into the joint, it will require no especial treatment, for it will gradually be absorbed as the osteomyelitis is cured.

If the joint is *suppurating*, it is quite different and another operation is required (see operation for Purulent Arthritis).

Over the trephined area, apply a moist dressing and change daily. As the exudate becomes less abundant, change to a dry dressing and change the packing in the canal every other day. Smaller drains may be inserted about the tenth day, and are removed entirely when the suppuration shall have ceased.

As Veau says, this intervention is only the first act of a prolonged and tedious process and this the family should understand beforehand. After several months, it may be necessary to remove some necrosed bone; and, long after the cure appears complete, the trouble may recur.

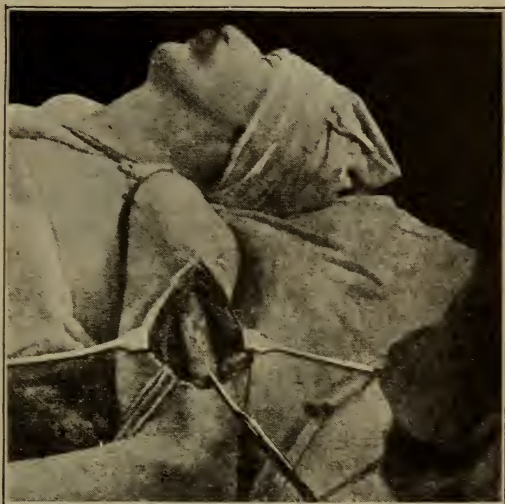

FIG. 337.—Osteomyelitis of the humerus.
(Marsee.)

OSTEOMYELITIS OF THE UPPER END OF THE HUMERUS

Begin the incision a finger's breadth below the clavicle, following the axis of the humerus. Prolong it downward 5 or 6 inches. The incision will traverse the deltoid near its anterior border. Separating the lips of the wound, divide the periosteum and proceed to trephine and drain as in the preceding case (Fig. 337).

OSTEOMYELITIS OF THE LOWER END OF THE HUMERUS

Make an incision 8 to 15 inches in length in the line of, and ending below at, the external condyle. The incision will traverse the thick fibers of the triceps. Trephine and drain. If it is neces-

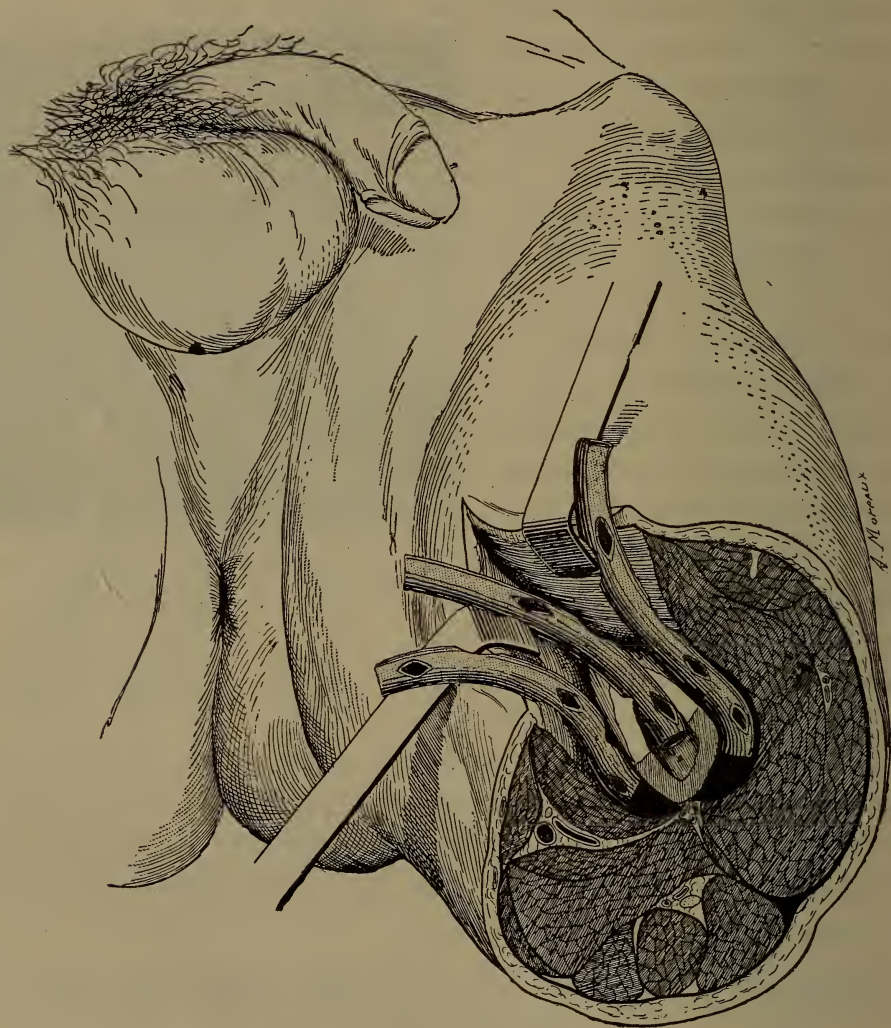


FIG. 338.—Cross section showing manner of placing drains after trephining the femur. (Veau.)

sary to make an internal counter-opening for a drain, remember the situation of the ulnar nerve. If the whole bone is affected, the same principles are involved. The prognosis is exceedingly grave.

OSTEOMYELITIS OF THE LOWER END OF THE FEMUR

Make the incision along the antero-internal border of the thigh, traversing the fleshy vastus internus.

The femoral vessels are behind this line. The bone is deeply placed and the operation difficult, but trephine thoroughly. Drain the medullary cavity and the periosteal abscess (Fig. 338).

OSTEOMYELITIS OF THE UPPER EXTREMITY OF THE FEMUR

Make the incision along the outer surface of the thigh over the great trochanter. Divide the aponeurosis of the gluteal muscle, trephine, and drain.

CHAPTER XX

SEPTIC ARTHRITIS

Septic arthritis is acute purulent inflammation of the joints, due to the presence of an infective agent, more frequently the staphylococcus or the streptococcus. The infection may reach the joint through a wound, by way of the blood vessels or through the lymph channels.

This purulent inflammation, therefore either follows direct injury, or is a sequel to various infective diseases, such as typhoid fever, gonorrhea, scarlet fever, or osteomyelitis; but by no means are all the joint inflammations following these conditions purulent.

Purulent inflammations are to be distinguished from non-septic inflammation both by the symptoms and the physical signs. The symptoms are those belonging to sepsis, for here it exists in a high degree. The tongue is brown and the temperature is very high, the pulse is weak and rapid, there are the appearances of prostration and finally delirium ensues. The pain is extreme and aggravated by the least touch. With respect to the physical signs, there is marked swelling of the joint and the skin is red and edematous, not only over, but above and below the joint, and fluctuation is usually to be detected.

Treatment.—This is an emergency of the first rank. It is an intervention designed to save the function of the joint; and sometimes even life is threatened.

There is but one indication, once the diagnosis is made, viz.: to open the joint by free incision and counter-incision, that every part of it may be reached and drained.

The most careful antisepsis is to be observed. The limb is to be as carefully cleansed as if no pus was expected.

Scrub the skin over the joint (the knee, for example), the upper third of the leg, and lower third of the thigh with soap and water and with ether and bichloride. Sterilized instruments are to be used;

they are simple, a scalpel, a few artery forceps, some rubber drains, and an irrigator. The whole aim is to secure ample drainage and subsequent antisepsis, and nature will take care of the rest. In certain of the joints, however, mere incision may not be sufficient and excision must be added.

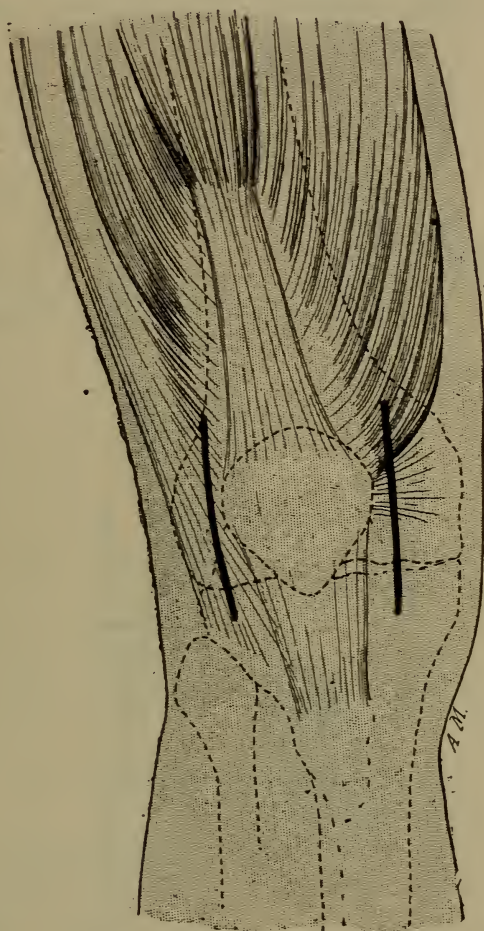


FIG. 339.—Septic arthritis. Incisions for drainage of the knee. (Veau.)

Arthrotomy of the Knee.—Sepsis affecting the knee-joint causes the knee to become enlarged, globular in outline, painful, reddened, edematous, with constitutional symptoms of sepsis. The operation, under general anesthesia, is very simple and without danger. The important thing is to open freely. Two incisions are to be made, one external and one internal (Fig. 339).

External Incision.—Locate the lower border of the patella; and, be-

ginning a little below this line, make an incision parallel with the external border of the patella and ending about two fingers' breadth above its upper border, which will be near the upper limit of the synovial sac. This incision traverses the integument and beneath it the firm aponeurosis of the vastus externus. As the joint cavity is reached, very often the pus spurts out with great force.

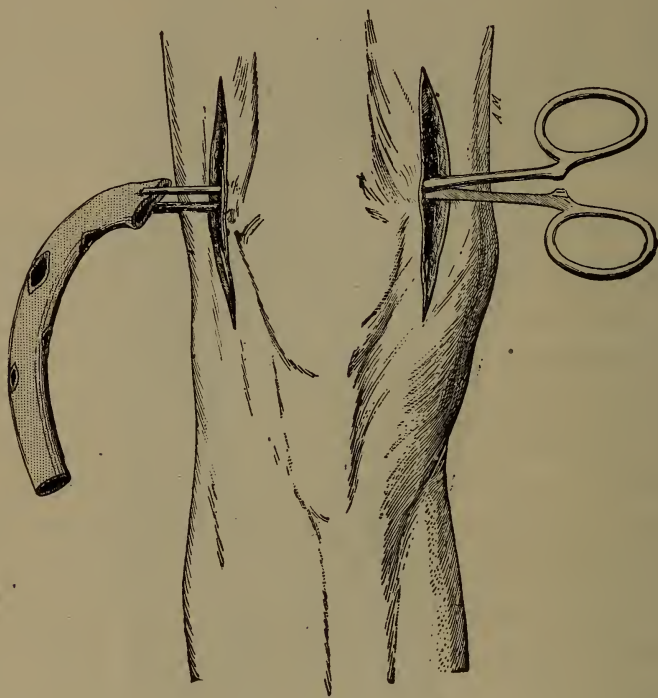


FIG. 340.—Drawing the transverse drain into place. (Veau.)

Internal Incision.—On the inside, make an incision symmetrical with the first, but a little further removed from the internal border of the patella. The aponeurosis is here less firm, but the synovial cavity is deeper; the swelling is usually greater on the inner side. Some of the fleshy fibers of the vastus internus are always divided. The cavity is not so easily reached as on the outer side.

Drainage.—Place a large transverse drain (Fig. 340). But in some cases this is not sufficient. The lateral diverticula of the synovial sac must be drained separately (Fig. 341). For this *two counter-openings* are required, one on each side. Into one of the incisions at its lower part, introduce forceps, and push backward and downward through the synovial sac at the level of the interarticular line (Fig.

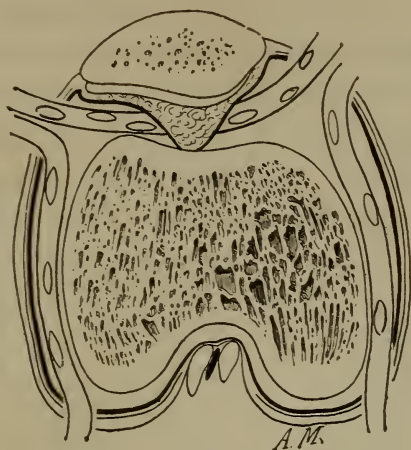


FIG. 341.—Cross section of knee-joint showing that the transverse tube drains the upper part; the two lateral tubes the inferior part of the synovial sac. (*Veau.*)

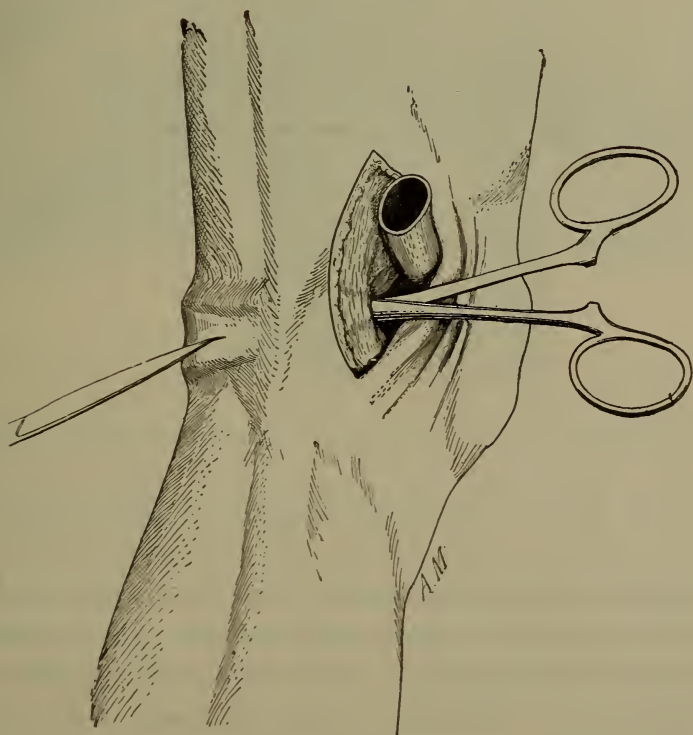


FIG. 342.—Manner of making posterior counter-opening for drainage of the knee. (*Veau.*)

342). If it is an old arthritis, this is not difficult; but in the case of a recent effusion, the ligaments are tense, and the articular surfaces are in contact so that the passageway is quite narrow.

When the forceps, pushed backward in this manner, bulges the skin, open the blades, and, between them, make an incision 1 or 2 inches long. Through this opening in the forceps, draw a drainage-tube into place. Repeat the maneuver on the opposite side.

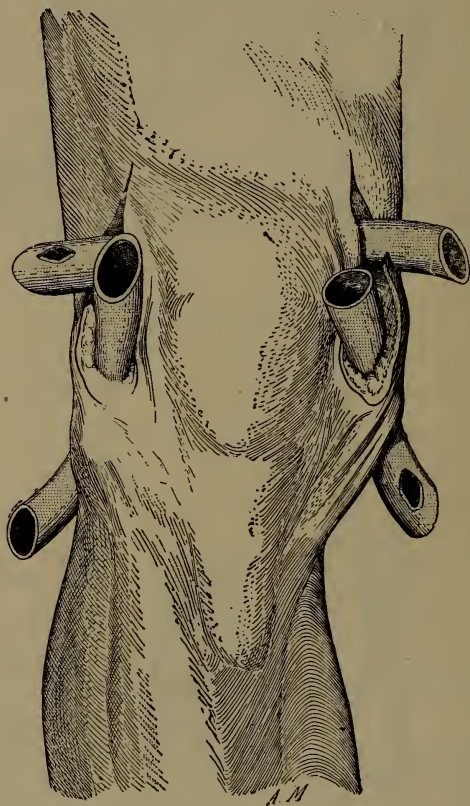


FIG. 343.—Septic arthritis. Drainage of the knee complete. (Veau.)

It is better to make the counter-opening on the external side first, as the ligaments there are less tense. The beginner is seldom successful in making the opening internally. He nearly always pushes the forceps backward at too high a level and the point engages in the tendon of the adductor magnus. It must be directed downward and backward (Fig. 343). When the joint is thus opened, irrigate freely with hot saline solution, reaching every recess of the joint and wiping with sterile gauze. Aim to clean the whole synovia. If the joint

is putrid, finish the irrigation with peroxide. Do not suture the wounds. Employ a moist antiseptic dressing. Immobilize the limb on a posterior plaster splint.

Subsequent Treatment.—Irrigate and dress twice daily for the first few days. However, if the temperature falls almost to normal and the pain ceases, do not be in a hurry to change the first dressing.

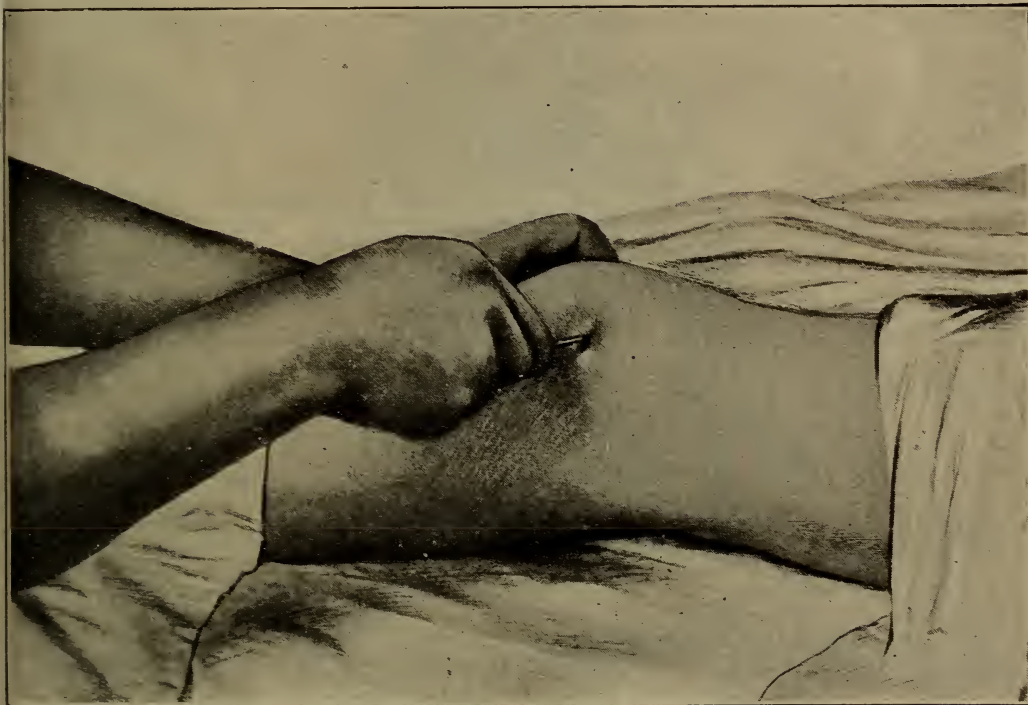


FIG. 344.—Puncture of the knee. (*Lejars.*)

Occasionally it is desirable to empty the knee-joint, as in the case of a voluminous hemarthrosis or serous exudation. The same careful asepsis is practised as for arthrotomy. Locate the upper external angle of the patella. A little above and to the outside of this point, plunge the trocar directly into the joint. The structures here are quite resistant, but there are no vessels likely to be wounded. As the exudate flows out, gently compress the joint to empty it. Withdraw the trocar with a quick movement, apply a sterile dressing, and bandage the knee in absorbent cotton.

If the suppuration diminishes about the end of the first week, put in a smaller drain in the same manner as before, and employ dry dressings. Watch the temperature. A rise indicates a retention of pus and calls for new drainage. Endeavor to avoid permanent flexion of the knee, a matter of the greatest difficulty and of the greatest importance, for such flexion cannot be corrected.

After the second week the lateral drains are removed; and, some days later, the transverse drain. After a month, if the inflammation is all gone, attempt passive motion; but it is almost a certainty that the joint will be stiff; still if it is stiffened in extension, there is no occasion for reproach.

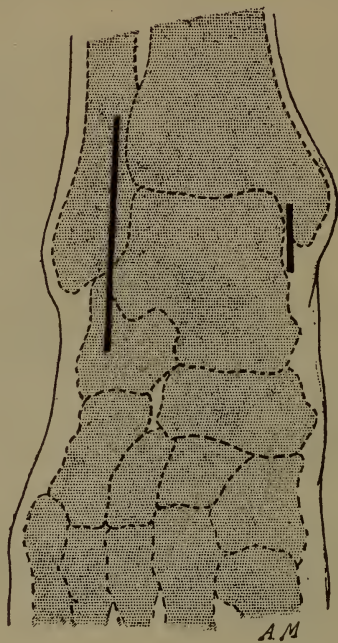


FIG. 345.—Arthrotomy of the ankle. Trace of the incisions. (Veau.)

ARTHROTOMY OF THE ANKLE-JOINT

This operation is not so frequently required as for the knee. Often local anesthesia will suffice. Make the first incision, 2 inches in length, over the anterior border of the external malleolus and reaching a little below its tip (Fig. 345). In the upper part of the incision, one may cut freely down to the bone, but in the lower part more care must be used. Some small arteries may be divided if one goes too deep.

In the middle of the incision, open the joint, enlarge the orifice, and mop out the cavity.

Introduce an artery forceps and carry it through the joint cavity to the opposite side, and over its point make a counter-opening (Fig. 346). This opening should fall over the tip of the inner malleolus.

As the forceps is withdrawn, it pulls a drainage-tube into place (Fig. 347).

Dressing and subsequent care are the same as in the knee.

ARTHROTOMY OF THE ELBOW-JOINT

Make a vertical incision 3 inches in length, with its center over the outer border of the apex of the olecranon, dividing some of the

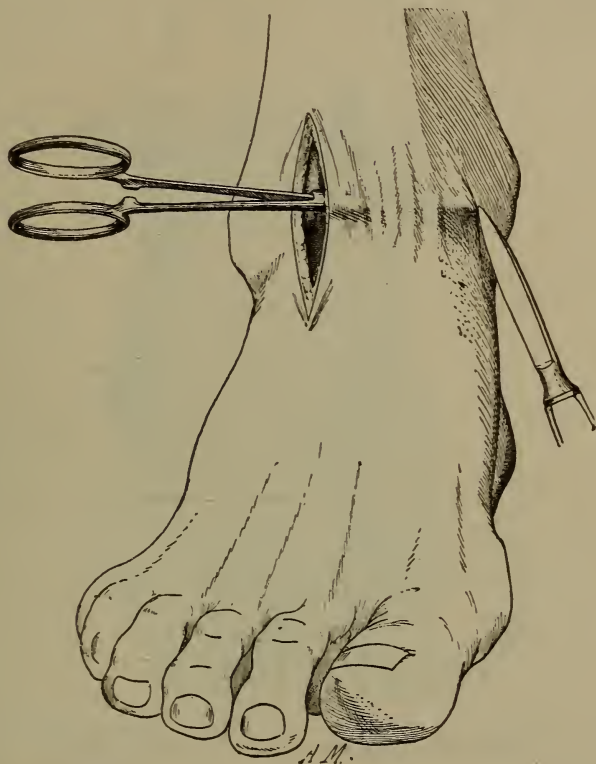

FIG. 346.—Septic arthritis. Drainage of ankle-joint. (Veau.)

fibers of the triceps and anconeus (Fig. 348). Puncture the synovial cavity at the middle of the incision and enlarge the opening to correspond with the incision. Push a forceps transversely through the joint at the upper level of the olecranon. Over its point make the internal vertical incision. Cut carefully, for the ulnar nerve is here in close contact with the posterior surface of the inner condyle.

Draw a drain into place with the forceps. The dressing and subsequent care is the same as that described for the knee.

ARTHROTOMY OF THE WRIST

Make an external incision between the long extensors of the thumb and the extensors of the index-finger, lines which may always be determined. Make a second incision on the ulnar side between the tendons of flexor and extensor carpi ulnaris. The two incisions may be connected by pushing a grooved director through.

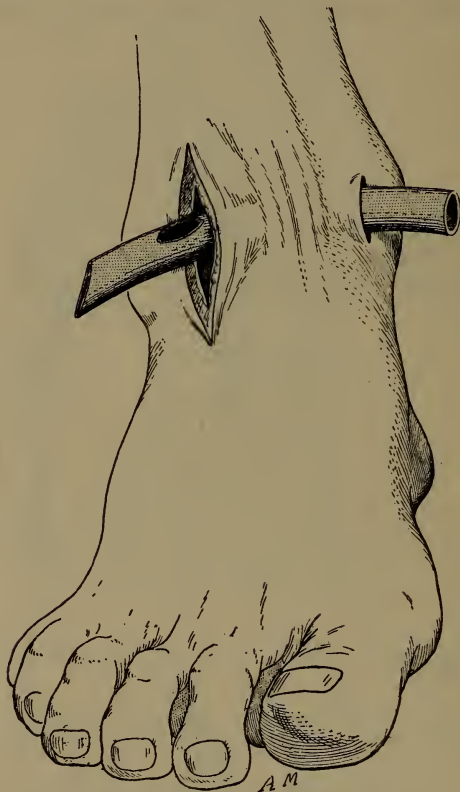


FIG. 347.—Septic arthritis of ankle. Drainage placed. (Veau.)

ARTHROTOMY OF THE SHOULDER

This joint may be opened by a vertical incision, beginning at the anterior angle of the acromion process and cutting downward in the line of the bicipital groove, or the joint may be opened behind along the posterior border of the deltoid, splitting the tendons of the infraspinatus and teres minor.

ARTHROTOMY OF THE HIP

The hip-joint, deeply set under a thick muscular mass, may be reached either from in front or behind. The aim of any procedure is

to reach the articulation in such manner as to produce the least destruction possible in these periarticular muscles; and, therefore, one must seek the intermuscular spaces, or split the various muscles in the direction of their fibers.

The study of the anatomy of the region demonstrates that several pathways to the joint, complying with the above conditions, can be found.

In front, the joint is covered by several muscles whose directions correspond to the axis of the thigh—the pectineus, the iliopsoas, the

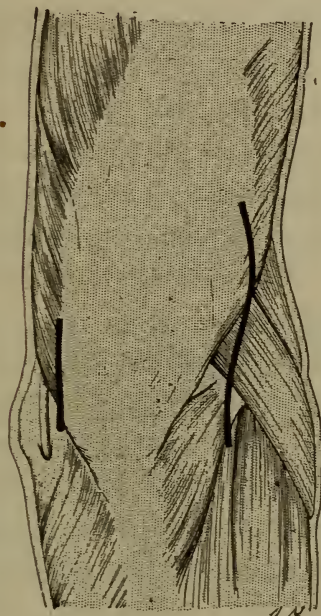


FIG. 348.—Septic arthritis of elbow. Incisions for drainage. (Veau.)

rectus femoris, in direct contact with the capsule; the sartorius and the fascia lata more superficially placed.

Behind, the joint lies under a group of muscles which are parallel to it when flexed at an angle of 45° . These are arranged in two layers; in the first, the g. maximus; in the second, the g. medius and the obturator internus and gemelli; while below and behind is the tendon of the obturator externus.

ANTERIOR ARTHROTOMY.—If one wishes to reach the joint from in front, he may pass (1) in between the fascia lata and the gluteus medius externally and the rectus and sartorius internally.

(2) Between the rectus and sartorius externally and psoas internally.

(3) Through the sheath of the psoas.

In the first case, the outer end of the neck and the great trochanter is exposed. In the second, the inner end of the neck, and in the third, the head of the femur.

Position.—On the back with legs extended. Operator stands at outside with assistant opposite, and second assistant moves the leg as directed.

Incision.—(1) Incision begins above, and finger's breadth inside, of ant. sup. spine, and extends downward and inward parallel to the sartorius, for 4 inches. Expose the internal border of sartorius, draw it outward. Below it will be exposed the rectus to be drawn outward also. The psoas is exposed and drawn inward to expose the capsule.

(2) The incision begins directly over the ant. sup. spine, and descends nearly vertically, bisecting the angle between the sartorius and tensor fascia lata. The sartorius and rectus are drawn inward and the capsule exposed.

(3) Finally, the incision, to follow the outer border of the psoas, may begin at the inner third of Poupart's ligament and extend downward and slightly inward. The psoas is exposed near its inner border and opened, avoiding the anterior crural nerve.

Open the Capsule.—Once the capsule is exposed, whatever the route, the muscles are to be relaxed by flexion, abduction, and external rotation which favors their retraction. The capsule thus freely exposed is incised to any extent necessary.

Counter-opening in Capsule.—It may be advisable to make an internal incision to secure complete drainage. Make an incision from the external border to the pubes downward and outward, exposing the space between the pectineus and adductor longus. Avoid the obturator nerve. Next introduce a forceps into the opening already made in the capsule and let the point emerge at the second opening; and, on this point as a guide, the counter-opening is made. The forceps is used to draw a large drainage-tube into place.

CHAPTER XXI

FOREIGN BODIES

THE EYE

Foreign bodies lodged on the conjunctiva or cornea are painful, and may soon provoke a conjunctivitis, more or less severe.

The offending particle may be concealed under the lid or be imbedded in the cornea. The latter is especially likely to be the case with those who have to do with emery wheels.

The patient's sensation is a very poor guide in locating the object; if it is on the cornea, he is likely to be certain it is under the upper lid.

Begin by inspecting the eye under a good light and at various angles. Pull down the lower lid, instructing the patient to look upward. Evert the upper lid. This is done by grasping the eye-lashes between the thumb and fore-finger and pulling downward, at the same time making pressure upon the tarsal cartilage of the lid with a pencil, stylet, or the opposite thumb. Instruct the patient to look downward. Combined with this pressure, the eyelashes are now pulled upward and in this manner the lid is everted and exposed to inspection. The novice does better, perhaps, to stand behind the patient, but the specialist sits in front of the patient and turns the lid with one hand.

If the foreign body is free, it is readily picked up with the point of the stylet wrapped with cotton, but if it is imbedded in the cornea, considerable curettement may be required to dislodge it. The instrument must be sterile, otherwise corneal ulcer may follow the manipulation. In the case of nervous or sensitive individuals or when the conjunctiva is much congested, the manipulation must be preceded by the instillation of a few drops of a 4 per cent. solution of cocaine, which should be fresh and must be sterile. Everything used must be sterile—hands, instruments, cotton, and solutions.

Following the extraction, irrigate with normal salt solution and instill two drops of 2 per cent. collargolum solution or 10 to 25 per cent. argyrol solution and direct the patient to wash the eye frequently with boracic or normal salt solution; if there is much congestion, bandage the eye for one or two days.

If the foreign body has *penetrated* to the anterior chamber, the iris, or the posterior chamber, the immediate treatment must be limited to such measure as will prevent infection—boracic irrigation and bandage—until the case can be placed in the hands of a specialist or until special text-books can be carefully consulted.

It may be necessary to employ the X-ray in diagnosis in these cases. The extraction may require a delicate operation or the use of the electro-magnet, and finally the removal of the globe may be necessary.

Chemical irritants should be removed by free irrigation. For lime in the eye, a solution of sugar in vinegar is recommended, the sugar forming a soluble compound with the lime. A few drops are used, followed by free flushing with water. Afterward atropine, gr. 1 to the ounce is imperative.

THE EAR

The foreign bodies most frequently found in the ear are pebbles, shoe-buttons, peas, beans, pens, pieces of tooth-pick, pieces of cotton, etc., etc.

Children may place these objects in their ears in play or innocent experimentations or adults may meet with the accident, attempting to relieve an itching in the auditory canal. A tampon may be left in the ear by the doctor. The body usually lodges in the outer part of the canal, and only reaches the tympanic membrane after ill-advised efforts at extraction.

The pain and discomfort are usually moderate; and, as a rule, there are no very urgent indications for intervention. But if the object rests against the drum, the pain is severe and may even produce mental disturbance.

The first thing to do, then, is always to confirm the diagnosis. The patient's belief in the matter must, under no circumstances, be ac-

cepted as final. There is only one way to confirm the diagnosis and that is by careful inspection of the whole canal, if the object is not seen in the outer portion.

Draw the external ear upward and backward, and the tragus forward. Under good illumination and with the aid of a head-mirror and otoscope, the drum is readily seen. If no foreign body can be seen, and provided there have been no blind efforts at extraction, it may be definitely concluded that the patient is mistaken.

If, on the other hand, you locate the object, do not hurriedly introduce a forceps into the ear; unless, indeed, the offending body is of such a nature that it may be easily seized, for you will almost always make matters worse, pushing it further into the canal. Remember

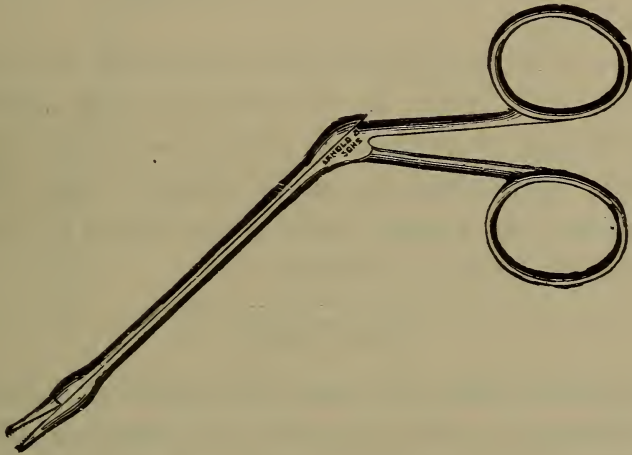


FIG. 349.—Ear forceps.

that however desirable it may be to empty the ear, there is, as a rule, no great urgency in the matter and you have plenty of time to take counsel with yourself (Fig. 349).

In some cases, a small hooked instrument may be cautiously pushed past the object and withdrawn, pulling the object out, or a small blunt curette may be similarly employed. Usually a *large syringe* is the proper instrument. Throw a stream of warm, sterile water into the ear with the purpose of forcing the body out by the "*vis a tergo*."

To inject the stream properly, lift the pinna upward and backward as in inspection, and direct the stream along the posterior superior

wall, using moderate force. Use one syringe after another, until the offending substance is washed away or the patient is tired out.

If you have failed, instill into the ear a few drops of glycerine or warm oil, lightly tampon, and direct the patient to sleep on the affected side, returning the next day for another trial. The chances are greatly in favor of ultimate success without injury to the ear.

In the case of a live insect in the ear, fill the ear with oil and subsequently the "cadaver" may be removed by irrigation.

If "instrumentation" seems advisable, there must be no blind grasping for the object—it must be kept clearly in view. It has happened, in violation of this rule, that the middle ear has been invaded and the ossicles dragged out. Death has occurred from such manipulation, though the post-mortem showed that no foreign body had ever been present.

In the case of children, instrumental extraction will, as a rule, require an anesthetic. If the ear has become much inflamed or the body pushed through the drum, the case is one for the specialist.

On the whole, the practitioner might adopt the rule, that if left in the ear, untouched, the foreign body is less likely to do harm than rude and maladroit efforts at removal.

THE NOSE

The catalogue of bodies, recorded as lodged in the nose, is long. Naturally, children are more frequently the subject of these mishaps although lunatics and hysterical women may intentionally plug the nose. Occasionally, a foreign body previously swallowed, may be coughed up and lodge in the posterior nares. Pledgets of cotton and pieces of gauze, which have been used as tampons, may be overlooked and act as foreign bodies.

In the case of the irresponsible, the presence of a foreign body may not be suspected, so few are the symptoms, until there develops a profuse sero-mucous discharge. There may be frequent attacks of sneezing; and, if the body remains long, the mucous membranes become swollen and perhaps the skin of the affected side also. There may be headache or facial neuralgia. These foreign bodies should be removed as soon as possible, first having determined their nature, size, and situation.

Begin by a careful examination of the anterior nares; and, if this is not sufficiently instructive, examine the posterior nares by hooking the finger up behind the soft palate. The examination and removal are often facilitated by the use of cocaine, and in the case of children, a few whiffs of chloroform may be necessary.

Chloroform is also the effectual remedy for animate foreign bodies, such as insects and maggots. Used for this purpose, it is not inhaled, but is shaken up with an equal amount of water and syringed into the nose before the two ingredients separate.




FIG. 350.—Angular forceps for foreign body in the nose.

A body lying in the anterior nares is usually readily removed by a mouse-toothed forceps; or a curved probe or small curette may be necessary to dislodge it. An angular forceps is sometimes convenient (Fig. 350). In other cases, the obstruction may be removed by drawing a tampon through the nasal cavity from behind, as recommended by Sajous.

If the body is lodged in the posterior nares, it is usually pushed backward into the pharynx, care being taken that it does not drop down into the larynx or esophagus.

“In the case of infants, a small body may be removed by blowing forcibly into the mouth.” (John J. Kyle.)

PHARYNX AND ESOPHAGUS

Many diverse objects may lodge in these passageways, either through ineffectual efforts at swallowing or by inadvertently slipping

from the mouth. False teeth are often loosened and carried into the pharynx or esophagus during sleep.

The point of lodgment, the immediate effect, the dangers, and the difficulty of removal, depend upon the size and shape of the object.

The pharyngo-esophageal canal is narrowest behind the larynx, opposite the cricoid cartilage and the sixth cervical vertebra; at this point a large body is likely to lodge. A second constriction lies $2\frac{3}{4}$ inches further down, behind the left bronchus; and a third where the esophagus passes through the diaphragm. Larger bodies, then, are liable to lodge opposite the larynx. Sharp and pointed objects, such as needles and fishbones, may anchor at any point without reference to the caliber of the conduit.

The immediate effects of the lodgment of a foreign body vary from instant asphyxia to merely slight difficulty in swallowing. Later there may occur, even in the case of a slight obstruction, the dangerous conditions following infection—erosion of the walls, perforation of the bronchi or lungs, of the pericardium, the aorta, or carotids—one has but to think of the numerous relations of the esophagus in the neck and thorax to understand how diverse the consequences of such spreading infection might be in various cases.

Very naturally, the deeper down the object lodges, the greater the difficulty in locating and reaching it.

Treatment.—*Asphyxia*, due to occlusion of the lower part of the pharynx involving the larynx, demands immediate action. The patient is livid, gasping, and struggling. Run the finger into the throat over the epiglottis, where the body may be felt and hooked out. If you fail in this, do not waste time in these cases of extreme urgency, trying tentative measures, such as inversion, but do a *tracheotomy*, or laryngotomy in the adult (see page 477). After the operation, the foreign body may be expelled spontaneously in the efforts of coughing or vomiting.

In the less urgent cases, the first indication is to confirm the diagnosis and definitely locate the object. The sensation of the patient is not sufficient index as to the presence and situation of an obstruction in the gullet, for the pain may be due to a wound made by the foreign body in passing.

Inspect the mouth, the fauces, and the tonsils. Palpate the region of the glottis and behind the soft palate. Palpate externally along the anterior border of the sternomastoid, pressing deeply to reach the esophagus, most superficial on the left side. Even if, as a result of this palpation, the foreign body is believed to be located in the neck, it is better to make certain by passing an esophageal sound.

In certain instances, the X-ray will be invaluable, though not always to be relied upon. In the hands of the expert, the esophagoscope has proved to be useful. In the course of time this instrument will probably come to be a part of every doctor's "arsenal." It not only makes exact diagnosis possible, but enables the foreign body to be removed by sight, avoiding thus the injuries to the esophagus which blind efforts often produce.

The presence and location of the foreign body once established, extraction is indicated. Inversion is illusory and emesis dangerous.

If the body is in the *pharynx*, it may be seized with curved forceps, or dislodged with the finger or an improvised hook. To employ the forceps, seat yourself before the patient, whose mouth is propped wide open. When the object is once seized, incline the patient's head forward as the forceps is withdrawn. If you lose your hold, rapidly withdraw the forceps and remove the mouth gag and often the loosened object will be coughed out.

In the case of an infant, place the patient on its back with the head hanging over the edge of the table, thus preventing the body from dropping into the larynx. (Have everything ready for tracheotomy.)

In extracting a body from the *esophagus*, the greatest caution is necessary to prevent laceration. Rough manipulation only aggravates the *muscular spasm*, which is always present in some degree, and which, more than anything else, prevents the body safely reaching the stomach; and these esophageal muscles are exceedingly strong. The esophageal forceps is used as in the pharynx.

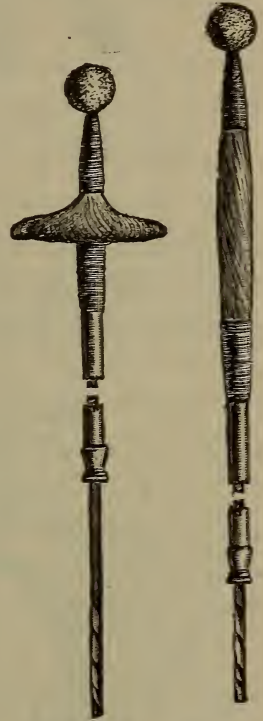

FIG. 351.—Horse-hair probang. Open and closed.

The horse-hair probang (Fig. 351), introduced past the object, opened up and then withdrawn, often succeeds in removing an implanted needle or fish bone.




FIG. 352.—Coin catchers.

In the case of a coin or similarly shaped object a “coin catcher” may be employed (Fig. 352). Introduce the left indexfinger as a guide and pass the instrument along its posterior wall until the coin is felt, when the catcher is passed on beyond it. Now tilt the handle forward and slowly withdraw the instrument until assured by the

sense of touch that the coin is engaged. Completely withdraw the instrument by steady, continuous, vertical traction. When the pharyngeal orifice is reached, it is necessary to accelerate the movement to achieve the final extraction (Fig. 353).

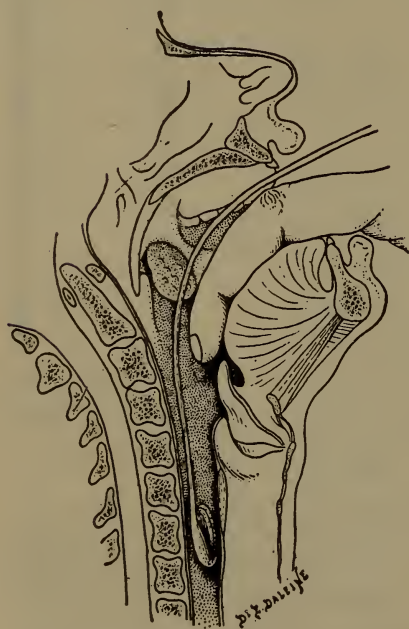

FIG. 353.—Extracting a coin from the esophagus. (Lejars.)

If, in the course of the manipulation, the foreign body is dislodged and slips on down into the stomach, do not regard it as a calamity, unless the object is very pointed. Indeed, if the object is deeply located, is known to be harmless in character, and extraction seems impossible, an effort should be made from the first to push it on into the stomach with the esophageal bougie. This should never be done, if the

character of the substance is unknown. No effort should be prolonged and above all else, no violence, is permissible. Finally, if extraction fails and propulsion into the stomach is out of the question, there is only one thing left to be done—an *esophagotomy*.

In certain cases where the body is firmly implanted, or when it is pointed and dangerous to move, resort must be made to the operation at once (see page 484).

LARYNX AND TRACHEA¹

The air passage is frequently involved, an accident always of concern, often serious, and sometimes fatal.

The bodies finding their way into the larynx and trachea are of great variety, fluid and solid, animate and inanimate; most often aliments perhaps, and after these, the list may be indefinitely extended.

Children are more often sufferers, because of their habit of putting objects into their mouths at random. Many times particles of food "go the wrong way," the result of the patient's speaking or laughing during the act of swallowing: the epiglottis is raised inopportunately, and the morsel drops into the larynx. Small bodies are inhaled in ordinary breathing. The accident sometimes happens during sleep, through the dislodgment of false teeth or something held in the mouth; it may follow an attack of vomiting, or it may occur during some operation about the mouth; conditions such as anesthesia, which diminish the reflex irritability or motility of the larynx, favor it.

The point of lodgment depends chiefly upon the size and shape of the object. Pointed objects, such as pins and fishbones, frequently stick in the supraglottic portion of the larynx; flat bodies, coins and buttons, usually lodge in the ventricles, while small globular, heavy bodies descend into the trachea or bronchus, usually the right.

The symptoms and sequelæ, and therefore the dangers, may be grouped under two heads, obstructive and inflammatory.

(a) If the body is large and lodged in the larynx, *asphyxia* may be the immediate result and may be almost immediately fatal. Even small bodies may produce fatal asphyxia through reflex spasm of the glottis, though usually the reflex spasm subsides. Reflexly, also, coughing, sometimes violent, is induced, and this may be the case whether the body lies in the larynx, trachea, or bronchus. Some-

¹Quotations are from Von Bergman.

times the body may lodge between the vocal cords, thus preventing their closure and allowing some air to pass so that life may be sustained for some time.

If the body is lodged in the ventricles, there may not be so much obstruction, but there is hoarseness or aphonia and cough.

If the body descends into the trachea, there may be no indication of obstruction, but there is much reflex irritation, evidenced by pain and cough. If the body is light, it may move backward and forward in the trachea, following the current of air.

If a bronchus is obstructed, a whole or a portion of the lung may collapse, evidenced by altered auscultatory sounds.

(b) The body may become encysted if not removed, or inflammation may ensue with the most diverse sequences, depending upon the location of the object: edema of the glottis, diphtheritic inflammation, abscess of the larynx, phlegmon of the neck, hemorrhage due to erosion of the large vessels or even of the heart, tracheitis, bronchitis, bronchiectasis, pneumonia, gangrene of the lung, empyema, purulent pericarditis, mediastinitis, or phthisis.

Treatment.—Asphyxia demands immediate action; there is no time for examination and inquiry. Make a hurried effort to remove the body by passing the finger into the larynx, and if this fails, without further delay do a tracheotomy (see page 481).

In the less urgent cases, one may be more deliberate, endeavoring to ascertain the character of the object and to locate the point of lodgment. The history of the case, the symptoms and the physical signs derived from auscultation, will furnish valuable information.

Various procedures are recommended.

“Inversion and violent shaking of the body do not enjoy their former popularity. Even the conservative Weist considers manipulation of this sort dangerous and only justifiable after tracheotomy.”

Still it does not seem likely that it can result in harm if the body is known to be small so that it may readily pass between the vocal cords.

“The simplest way is to follow the suggestion of Sanders, and let the body hang over the edge of the bed and rest on the hands during the attack of coughing.” “Generally speaking, emetics are unreliable and their use not without danger.”

If there is time, the laryngoscope may be of great aid in diagnosis and extraction, employing cocaine in the adult and chloroform in children.

In the hands of the skilled, the bronchoscope often furnishes a happy solution to the difficulty (Fig. 354). It is to be hoped that the technic of bronchoscopy, now familiar only to the specialists, will soon be popularized with the profession at large. In cases less urgent, the X-ray may be used to locate the substance.

But after all, tracheotomy or laryngotomy is the chief reliance of the practitioner left to his own resources, and he must be prepared for immediate operation while other measures are tentatively tried. Lejars urges that an attendant be at hand ready for instant operation as long as the body is known to be free in the bronchus or trachea.

"It makes no difference what one's views are regarding tracheotomy in general; the fact remains that no physician will deny the necessity of this step when the danger of suffocation is great."

"The author has become convinced that the danger of tracheotomy nowadays is insignificant compared with that of a foreign body in the air passages and does not hesitate, even when the body is situated in the larynx, to remove the offending material through an incision should extraction *per vias naturalis* be impossible."

"Tracheotomy is positively indicated when the foreign body is movable in the trachea."

In any case after the urgent symptoms have subsided, "operative

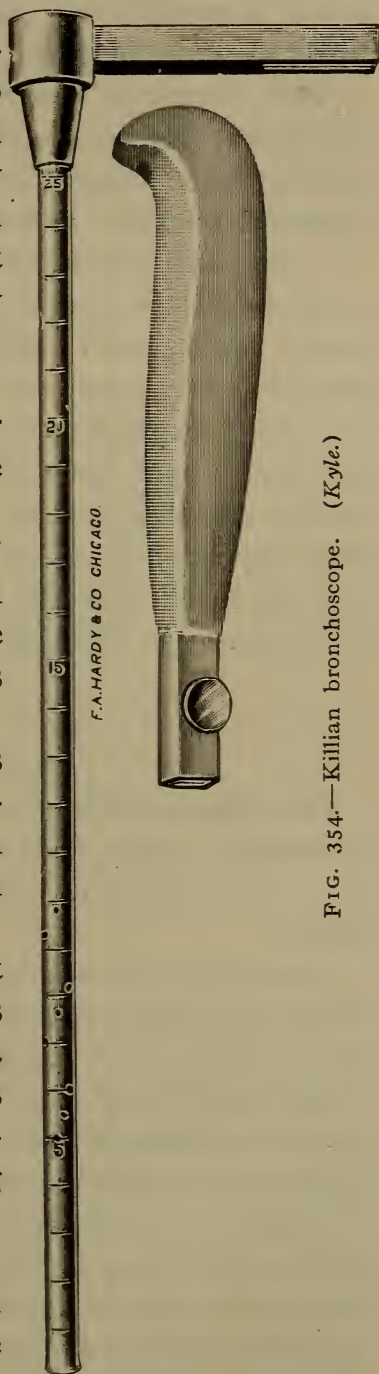


FIG. 354.—Killian bronchoscope. (Kyle.)

interference is the special form of treatment most rational and the form of operation depends upon the situation." "If the extraction means laceration, it is justifiable to split the larynx itself or a sub-hyoid pharyngotomy may be indicated."

"The expectant treatment, to which so many patients formerly fell victim, is to be condemned. This method is only justifiable in a small number of cases, in which the body has fallen far down into the bronchus where it cannot be reached.

"The death rate shown by statistics should not decide the question of operation: the clinical picture of the particular case and the unfortunate cases should guide the surgeon. Those that died after the operation did not do so because they were operated upon, but because they were operated upon too late. In an individual case the doctor can never count upon spontaneous expulsion. Every hour the offending material remains *in situ* lessens the chances more and more, while operation furnishes conditions most favorable for its removal. Opening the air passages, then, is the most rational procedure except for the cases in which endolaryngeal methods can be used."

RECTUM

The objects which have been removed from the rectum at one time or another, cover a wide range—bottles, pieces of wood, etc., pushed in to stop a diarrhea, to satisfy a perverted sexual impulse, or by the insane.

It is scarcely necessary to indicate all the instruments and artifices which have been employed in their extraction, but it is helpful, as Lejars points out, to formulate certain general rules of procedure.

The necessity of these formulæ cannot be doubted when one considers the difficulties of extraction, often considerable, and the frequency with which the rectum is lacerated by misguided effort.

Often the patient does not admit the nature of his difficulty, consulting the doctor on some other pretext, such as constipation or some rectal trouble quite different from the real condition. In the case of obscure trouble in the natural orifices, the doctor should be on his guard. If the nature of the complaint is admitted, proceed to a methodical examination and endeavor to get your bearings.

Introduce a finger, which has been well oiled, into the rectum. Sometimes you will find the object just within the orifice, of such size and shape that it can be readily extracted with the finger or with a forceps without further trouble, but you cannot count too much on that.

If the examination shows it to be lodged high up in the concavity of the sacrum, impacted and perhaps completely filling the rectum, make no effort at extraction, but prepare for a formal operation.

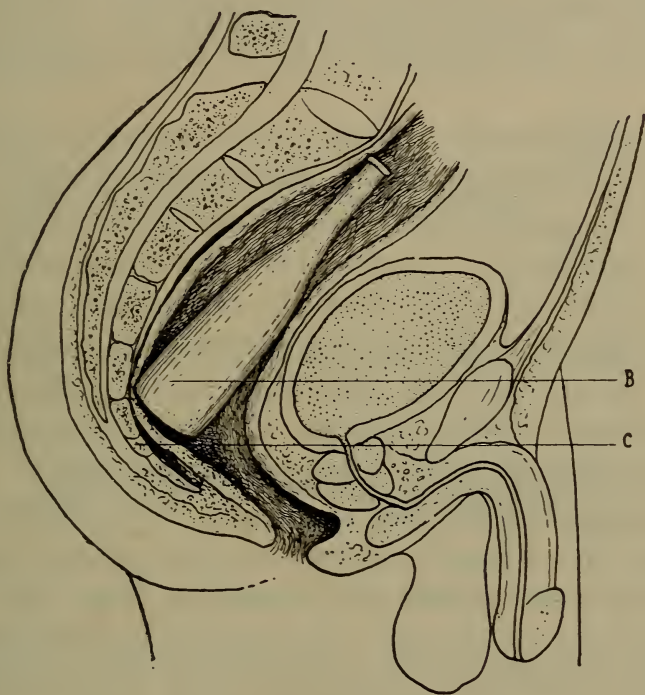


FIG. 355.—Foreign body in the rectum. B. Bottle; c. Coccyx. (Lejars.)

Under a general anesthetic, put the patient in the lithotomy position with the thighs well flexed, the hips elevated, and the anal region in a good light. Dilate the anus with the fingers as completely as possible and then determine the exact "presentation" of the body. Introduce a Sims' speculum, passing it, under the guidance of the finger, beyond the coccyx, and then retract as widely as possible. This is easily done in the young, but may be difficult in the adult.

When the coccyx is thus sprung back, the body must be seized and traction made in the axis of the outlet if the body is long (a bottle for

example) and firmly fixed (Fig. 355). The fingers or forceps may be used. If you are dealing with glass, the blades of the forceps must be covered with rubber to prevent slipping. If the ends of the foreign body are pointed, and imbedded in the rectal wall so that traction is dangerous, great care must be exercised. In some cases morcellation will be possible.

If the coccyx cannot be retracted and serves as the direct impediment, it will have to be resected. If the body has found its way up into the left iliac region into the sigmoid, it may possibly be worked down into the rectum by external manipulation. Finally, in such a case, laparotomy and opening the bowel may be the only means of relief.

Combs, of Indianapolis, reports a case which illustrates the principles of treatment involved (J. A. M. A., Oct. 23, 1909).

After a drinking bout and a drunken sleep in the woods, the patient awoke with a pain in his rectum and found it impossible to empty his bowel. He applied to a physician who discovered a beer glass in the rectum, inserted there during the victim's drunken stupor by brutal comrades. An attempt was made to remove the glass without preliminary divulsion of the sphincter. During traction with forceps the glass was broken and the attempt failed.

Some hours later he was seen at the hospital by Combs who found the small end of the glass resting on the promontory, and the large end imbedded in the hollow of the sacrum (Fig. 355), its broken edges buried in the soft tissues. By reason of the edema and swelling, divulsion was insufficient for removal, and consequently the contracted muscles were divided in the middle line posteriorly, when the glass, which was four inches long and seven inches in circumference at its large end, was readily removed. On account of the swelling and evident infection, the incision was left to heal by granulation, and on discharge from the hospital the patient had a perfect control of the sphincter. Combs remarks that the shape, size, and nature of the foreign body, the edema and swelling, and the degree of traumatism will be the guiding indications for the course to pursue. It would certainly seem a rare instance in which amputation of the coccyx would be required. Adequate division of the muscles posteriorly with quick removal is advised in lieu of prolonged efforts at re-

moval by traction, especially of an object with cutting edges from which fatal wounds may result.

THE URETHRA

A piece of sound may be broken off in the urethra. Boys or the insane may lose various objects in the urethra, slate pencils, pipe stems, pieces of watch chain, etc.

As a rule, the accident is not immediately disastrous, for generally the impediment to urination is not complete. The object should be removed as soon as possible and with as little irritation to the urethra as possible.

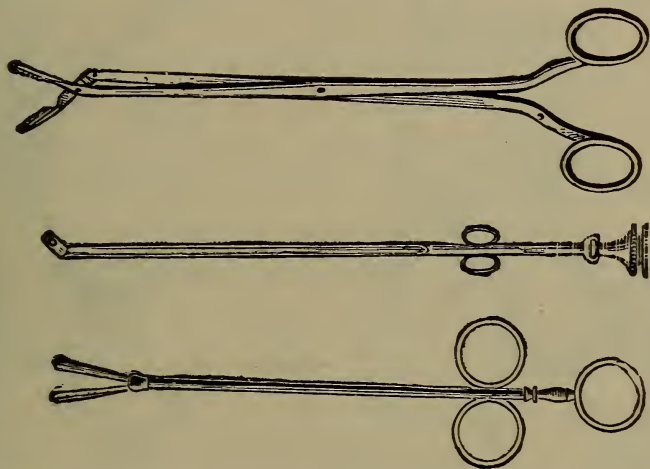


FIG. 356.—Urethral forceps of Collin (a), Leroy d'Etiolles (b), and Hunter (c).

It is necessary merely to enumerate some of the methods employed successfully in various cases, and each case must be treated on its own merits. Often the body may be easily reached and extracted with forceps (Fig. 356). In certain instances, it may be gradually worked forward by external pressure; or in urination the meatus may be pinched up and when the urethra is ballooned out by the pressure of the urine, sudden release may result in the body being washed out.

In case the body is in the deeper part of the urethra, and considerable manipulation is necessary, pressure should be applied over the urethra on the bladder side of the foreign body, to prevent its being pushed deeper. A piece of hollow sound or catheter may sometimes be removed by passing a smaller sound down into its lumen;

or the urethral speculum or a larger hollow sound may be passed down to, and over the body, which permits its more ready seizure by a forceps passed through the speculum.

Dayat shaped a lead sheet into the form of a hollow sound and, passing it beyond the object in the urethra, closed its lower end by pressure over the urethra and in removing the lead catheter the foreign body came out with it.

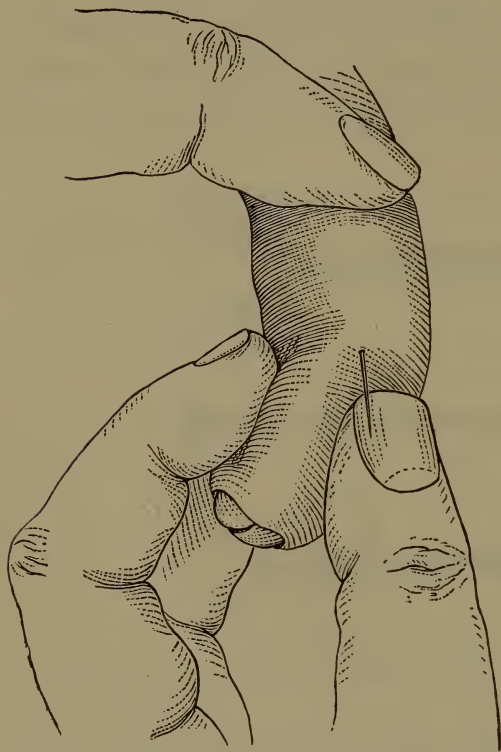


FIG. 357.—Extracting a pin from the urethra by "version." Protruding the point through the skin. (*Bryant.*)

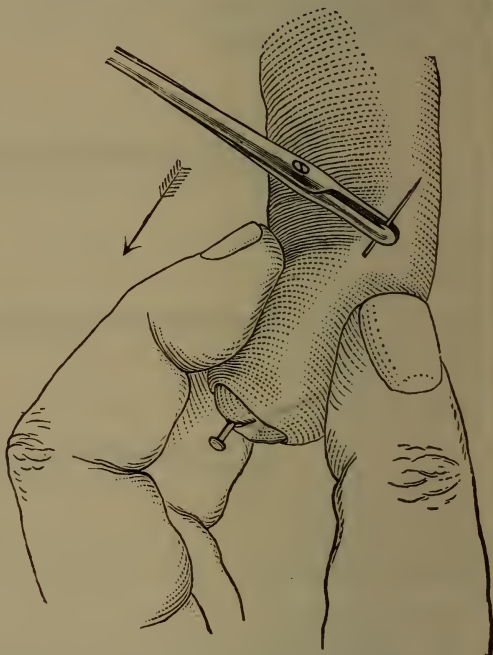


FIG. 358.—Point grasped with forceps. Its direction reversed and head brought out through the meatus. (*Bryant.*)

In another case, a stick forced into the urethra could not be withdrawn on account of a hook on its lower end, but after being split into many pieces, its extraction was accomplished piecemeal.

In the case of a pin lost in the urethra head downward, its point may be driven through the skin and "version" accomplished and the head brought out through the meatus (Figs. 357, 358).

In other cases it may be necessary to do an external urethrotomy, and finally the object may have to be pushed into the bladder and removed by suprapubic cystotomy.

Hazzard describes a case in which a hat pin was lodged in the urethra, its head too high to manipulate. He bent the penis at a right angle to the direction of the pin and thus thrust its point through the skin, which enabled him to practise version (J. A. M. A., May 29, 1909).

Hyde, of Kansas City, reports a shawl pin slipped, head first, down the urethra and into the bladder. The point could be felt at the penoscrotal angle. An incision was made down to the urethra, the point was forced through the urethral wall into the incision, and the pin drawn out till the head reached the urethral floor; it was then reversed and delivered through the meatus without opening the urethra. The wound was closed by three deeply placed silkworm-gut sutures with prompt repair (J. A. M. A., March 13, 1909).

Charlton of Indianapolis operated on a case at the City Hospital in which the patient, a man of fifty had lost the bony portion of a dog's penis in his urethra, having inserted it as was his custom to relieve an itching. Painful micturition was his chief symptom. The bone was located in the bladder, a cystotomy performed, the foreign body removed, with complete recovery.

CHAPTER XXII

BURNS, SCALDS, AND FROSTBITE

From the point of view of prognosis and treatment, burns are of three degrees:

(1) Transient application of heat, something below the boiling-points, produces *hyperemia*.

(2) A greater degree of heat or a longer application produces a more definite vaso-motor paralysis and there is *exudation*, particularly into the Malpighian layer, and the epidermis is lifted up in the form of blisters.

(3) The albumen of the tissues and fluids is coagulated. This *necrobiosis* may be superficial or it may involve the deep structures as well.

Symptoms.—Even in slight burns, *pain* is always a prominent symptom. In the severer burns, *shock* is always present in some degree, and as the shock disappears, reaction comes on, with rise of temperature, and the symptoms resolve themselves into some form of internal congestion, or systemic intoxication, characterized by hemoglobinuria or albuminuria, vomiting, or bloody diarrhea. After a few days the symptoms may be those of septic infection.

The cause of death from burns falls into four groups:

(a) *Shock*. This may be rapidly fatal, sometimes as late as twenty-four hours. Death may be due to cardiac paralysis, the result of over-heating of the blood.

(b) *Toxemia*. The tox-albumens resulting from the chemical changes in the tissues find their way into the circulation and overwhelm the heart and kidneys, usually within the first two or three days. It has been demonstrated that these toxic substances are hemolytic and cytotoxic for the parenchyma cells and are eliminated from the body by the kidneys and intestinal tract.

(c) *Internal congestion and inflammation*, involving the cerebral, thoracic, or abdominal structures.

(d) *Septic infection or its sequelæ.* This may be fatal after the first few days or only after a prolonged struggle.

Factors Determining the Prognosis.—(a) Area and depth of burn.

(b) Age and general condition of patient.

(c) Region.

(d) Degree of infection.

The rules for determining the prognosis can be formulated only in a general way with reference to these various factors, and yet keeping them in mind, a quite definite forecast may often be made in a given case.

(a) It is the area rather than the depth of the burn which determines the danger. An extensive superficial burn is more dangerous than a limited but deep one. It appears that under the effect of heat muscular tissue generates a poison much less toxic than that from the skin. Mere reddening of two-thirds of the cutaneous surface will almost inevitably result in death, while destruction of one-third of the skin will probably produce the same result, yet most burns of the first and second class commonly met in practice will recover.

(b) The age and general condition involve the question of the ability to rally from shock and to resist infection. By reason of their lack of resistance to these forces, the young or the aged may succumb to even slight burns of the third degree.

(c) Burns over the head are dangerous for the reason that meningitis may develop, and similarly burns of the thorax and abdomen are likely to result in lesions of their contained viscera. Burns about the face are often accompanied by corresponding injury to the air passages by inhalation of smoke or flames.

(d) The most important factor, however, in the process of severe burns is *infection*. Such injuries, in fact, are infected wounds. The coagulated albumens of the destroyed tissues are not favorable soil for the development of the bacteria, but around the circumference of the burn are tissues of lowered vitality which are not only unable to resist the encroaching germ, but, more than that, actually nourish it.

The serous exudates of superficial burns are likewise culture media, so that in severe burns as well as in other wounds it may be said that the patient's fate lies in the first dressing.

Treatment.—*Slight burns* of the first degree require protection,

which may be furnished by vaseline; by gauze saturated in boracic acid solution; by carron oil; by dusting powders of various kinds, boracic acid, dermatol, bicarbonate of soda, flour.

In severe burns the indications are to combat the shock, to relieve the pain, and to prevent infection. In the matter of the local treatment of these conditions, the final word has not yet been spoken. The most divergent opinions appear in current literature, and of these various lines of treatment perhaps none are wholly bad, certainly few are altogether good.

Begin, then, by combating shock and relieving pain. These two conditions are usually relieved at once by frequent but small hypodermic doses of morphine, supplemented by subcutaneous or venous injections of salt solutions. If parts beneath the clothing are involved, use the greatest care in removing so that the skin will not be removed with it.

To cut the clothing is safer than to attempt to undress the patient. Always remember that contact with the clothing may be the chief source of infection.

Now, what will one do to prevent infection? This is the chief problem.

If the burn is of large extent and depth as well and has been in contact manifestly with sources of infection, there is but one thing to do if the aseptic method is to be employed. *Anesthetize* the patient after the shock has passed and proceed to *sterilize* the parts. Scrub the uninjured skin around the wound with soap and water and then alcohol and bichloride. Next proceed to irrigate the burned area with normal salt solution, in the meantime carefully rubbing with sterile gauze, to the end that every bit of foreign matter may be removed. In those parts that are merely blistered, the blebs are to be punctured and the serum washed away. It may be advisable, even, for the sake of thorough disinfection, to make no effort to spare the cuticle of the blisters in rubbing with the sterile gauze.

Not hurriedly, but patiently complete this cleansing. It will probably require from one-half to three-quarters of an hour, but it is time well spent. You have now to deal with an aseptic wound.

Next cover the area with plain sterilized or borated gauze and over this apply absorbent cotton and bandage snugly.

If much cuticle has been removed, cover with sterile vaseline before applying the sterile gauze.

The aid of a splint may be required to prevent deformity. If no fever arises the dressing need not be changed for eight or ten days.

It may not be practical to institute the thorough disinfection which anesthesia alone permits, but one can at least cleanse the adjacent area as before described. Prick the blisters and irrigate the burnt area with normal salt solution, but in this case sterilization is not so much a certainty.

Therefore, you must employ an *antiseptic dressing*. Whatever dressing you select should have these properties at least; it should be *antiseptic*, *analgesic*, and *keratogenic*. A number of substances possess these properties in various degrees and are otherwise more or less unobjectionable.

Picric Acid.—This is employed in solutions of 1 or 2 per cent. A good solution is made by dissolving $1\frac{1}{2}$ drams in 3 ounces of alcohol and adding some of this solution to two parts of water. After cleansing the surface apply strips of sterile gauze, soaked in the solution, cover with absorbent cotton and bandage. Change the dressing in three to four days, soaking it loose with the same solution. Picric acid stains are removed by an alkaline sulphide followed by washing with soap and water or by a paste of manganese carbonate and water.

Turpentine.—This is an excellent domestic remedy, antiseptic and analgesic, but only to be employed in slight burns of the first degree. Cover the area with absorbent cotton and saturate with the turpentine, and bandage.

Aristol.—This, too, renders excellent service. Use as an ointment mixed with sterile vaseline or zinc ointment in the proportion of 8 to 10 grains to the ounce and apply spread on sterile gauze.

The Ointment of Reclus.—This, perhaps better than any other ointment, meets all the indications. It is applied in a thin layer directly to the surface or spread on sterile gauze and the dressing completed with cotton and bandage. Here is the formula of the ointment as modified by the author and prepared by the Pitman, Myers Co., and which should be ready for instant use:

R—Hydrarg. Chlor. Corros.,	1 part.
Acid Carbol.,	30 parts.
Aristol,	30 “
Acid Boric,	90 “
Salol,	90 “
Antipyrine,	150 “
Petrolatum,	576 “

Carron Oil.—This is an old and useful remedy, but, as ordinarily used, unqualifiedly to be condemned. It favors suppuration because it is in nowise antiseptic and perhaps may—indeed often does—carry infection. If the oil is sterilized and then applied to the surface which has been made as clean as possible, it is an efficient dressing.

Granger, of Rochester, Minn., uses equal parts of lanolin and zinc ointment spread thickly on gauze, covering the ointment with the waxed paper sold by instrument dealers, and applying the dressing with the paper next to the burned surface. The dressing is next covered with a thin layer of cotton. He claims that it is soothing and easily removed.

The frequency with which any dressing must be changed will depend on the pain or infection. If the secretions are excessive and, by drying and stiffening the dressing, aggravate the pain, the dressings must be frequently changed.

If there is infection, the rise of temperature will be the index. The same care must be exercised in changing the dressings as in treating any other wound.

BURNS OF THE MOUTH

Burns of the mouth and air passages are not infrequent. These may be the result of taking hot substances into the mouth or the inhalation of hot gases in explosions. Pain and difficulty in swallowing are the most frequent symptoms. In addition there may be edema of the glottis or finally acute bronchitis may develop. Cold water and bits of ice give the most relief. The edema of the glottis may require tracheotomy. The various forms of inflammation, such as bronchitis or pneumonia, must be treated on general principles.

ELECTRICAL BURNS AND SHOCKS

Electrical burns are painful out of all proportion to the size of the lesion and require two or three times as long as the ordinary burn for repair.

Begin the treatment with hypodermics of morphia and strychnia (1/30). Cleanse the wound by the ordinary surgical methods and dress with sterile gauze, cotton, and bandage.

The resuscitation of persons shocked by electricity is necessitated much more often than formerly by reason of the widespread use of the electric current. Spitzka has lately outlined the course to pursue in the treatment of such cases. He remarks, in the first place, that one cannot safely predict exactly what will happen in any case of shock by electricity, for many factors modify the action of the current: its nature, tension, intensity; the resistance and susceptibility of the individual; the duration, location, and area of contact. Broadly stated, the effect is the more severe, the greater the voltage, the greater the amperage, the longer the period of contact, the greater the area of contact, and the longer the path of the current through the body.

Death by electrical contact would appear to be due to heart paralysis or to asphyxia, or a combination of both. In certain cases there is no paralysis of the heart, but only respiratory failure.

The symptoms of electrical shock in cases which are not immediately fatal, vary greatly in form and degree.

I. *Local signs:*

- (a) Burns and superficial necroses.
- (b) Puncture and rupture of tissues.
- (c) Hemorrhages.
- (d) Edema and erythemas.

II. *General effects:*

- (a) Loss of consciousness.
- (b) Paralysis and spasms of muscles.
- (c) Disturbances of respiration and circulation.
- (d) High temperature.

Later there may develop disturbances of the bowels, kidneys, special sense organs, the central and peripheral nervous system.

The prognosis is good only in cases where there is some heart action and respiration and where treatment can be promptly applied.

Treatment.—If the stricken man is not out of the circuit, some caution must be exercised in accomplishing his relief. The rescuer should have on rubber gloves or have his hands wrapped in thick dry, woolen material, to avoid shock from handling the victim. He may be freed by pulling at his clothing or using sticks of wood. If it is necessary to cut a wire, the nippers must have insulated handles and the eyes should be protected from the blinding flash.

Once freed, the patient should be laid with *head elevated* and *artificial respiration* at once begun. This is more effectively done by compressing the chest with the hands applied flat against the sides of the lower part of the thorax. The tongue must be drawn forward so as not to obstruct the larynx. Massage over the heart and faradism help to stimulate its action. Arterial infusion of adrenalin has been proven by Crile and Dolly to have a direct effect.

Other methods which have been suggested are lumbar puncture, venesection, and the high-tension shock of short duration (Jour. Med. Soc. New Jersey, Jan., 1909).

FREEZING

The effects of very low temperature on the tissues are practically the same as those of heat. The ultimate effect is death of the tissues or gangrene.

The treatment of patients overcome by cold must be circumspect. The main point is to go slow in warming the parts. The patient should never be brought directly from outdoors into a warm room. Sonnenburg advises that a cold bath, the temperature of the cold room, be used, and the temperature gradually raised until in two or three hours it reaches 80° F. Where life seems extinct, artificial respiration should be practised, and sometimes the circulation may thus be re-established. Subsequently hot rectal enemata of whiskey or coffee may be employed. The limbs and other frozen parts should be covered with moist compresses for the first forty-eight

hours and then dusted with boracic acid and encased in a thin layer of wool.

If the trouble is only local—a frozen ear or foot—begin by rubbing the part with snow or ice and then with cold water and finally apply cold compresses, gradually raising their temperature until the circulation is restored. Subsequently cooling lotions may be employed to allay the inflammation.

The frostbite of the feet so common in the trench fighting of the European war, resulting often in gangrene is not due so much to the cold as to interference with the circulation, the result of wearing soggy socks and shoes unchanged, perhaps, for days.

PART II

CHAPTER I

TRACHEOTOMY, LARYNGOTOMY, ESOPHAGOTOMY

Tracheotomy is often performed in general practice as an operation of the greatest urgency, and one should be prepared to do it anywhere, at any time, and, if necessary, with a pen-knife. Yet it is not so simple a procedure as one might infer. To do it properly and quickly, requires coolness, knowledge, and method. It is the measure of relief indicated in every case of *laryngeal asphyxia*, whether due to *spasm* of the larynx, *edema* following burns, injuries, or disease such as diphtheria or cancer; or to the presence of *foreign bodies*. In the case of diphtheria, intubation is always preferable to tracheotomy, but the necessary appliances may be lacking. The essential equipment for tracheotomy is a sharp pointed scalpel and a tracheotomy tube, and to these as mere conveniences, may be added scissors, artery and dissecting forceps, tenacula, mouth-gag, and tongue forceps.

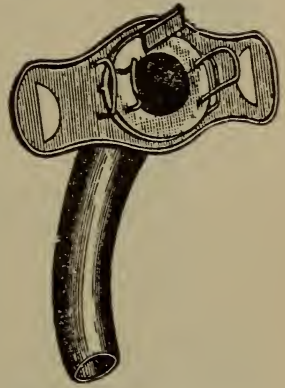


FIG. 359.—Tracheotomy tube.

The tracheotomy tube (Fig. 359) should be of simple construction, easy to introduce, and as large as the diameter of the trachea will admit. Treves furnishes the following table relative to the age of the patient and the diameter of the tube:

AGE	DIAMETER OF THE TUBE
Under 18 months,	4 mm.
1½ to 2 years,	5 mm.
2 to 4 years,	6 mm.
4 to 8 years,	8 mm.
8 to 12 years,	10 mm.
12 to 15 years,	12 mm.
Adults,	12 to 15 mm.

Every practitioner should have tubes of various sizes in his "arsenal;" Senn recommends Trousseau's, while Lejars prefers those of Krishaber, because less likely to become occluded.

Anesthesia is often unnecessary, owing to the condition of the patient. Otherwise a few whiffs of chloroform should suffice. It need scarcely be said that under these circumstances, free use of the anesthetic will only hasten the fatality.

The preparation of the field can be hastily but sufficiently done by painting with iodine.

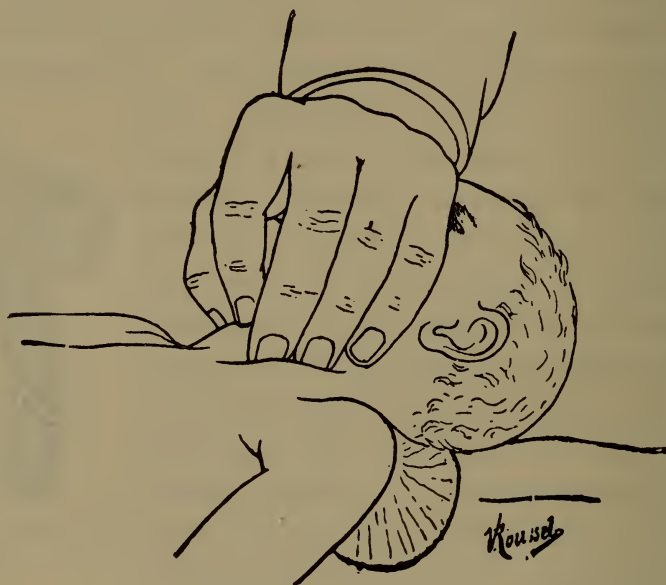

FIG. 360.—Locating the cricoid cartilage. (Veau.)

The little patient's arms should be pinioned to its sides with a towel or sheet, it should be placed on its back with a cushion under its shoulders to drop the head backward and bring the trachea into bolder relief.

Operation.—Stand at the right side of the patient; locate the hyoid bone, the thyroid prominence, the cricoid cartilage, and the sternal notch; and steady the trachea, holding the cricoid between the middle finger and the thumb of the left hand, while the index finger locates the middle line (Fig. 360).

It is along the middle line that one must incise, and the aim is to divide the upper rings of the trachea and to avoid the thyroid isthmus (Fig. 361).

Make the incision from the index finger downward exactly in the middle line for 2 inches (Fig. 362). Incise rapidly with a single sweep of the knife. The left index finger in the upper angle of the wound hooks up the cricoid and still locates the middle line. Pay no attention to the bleeding, and without hesitation push the point of the bistoury through the upper ring and cut downward through the second and third if necessary. The air hisses through the opening. It is a moment of confusion, but one must keep cool.

Insert the tube. Without changing its position, the left index finger presses the tracheal wound open and the right hand introduces the tube. It is held horizontally at first, until the point is well in the trachea, and then is carried upward in a curve until its beak corresponds to the lumen of the trachea (Fig. 363). The patient's gasps expel blood and perhaps false membrane, which the attendants must avoid inhaling. The tapes attached to the tube are fastened behind the neck. Apply artificial respiration if the patient's condition is not satisfactory. Let the air pass through a warm, moist compress until the temperature of the room can be regulated.

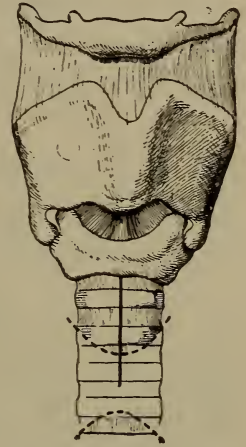


FIG. 361.—Tracheotomy. Dotted lines represent the thyroid isthmus. (Veau.)

As Veau points out, the operation may fail for several reasons, all within the control of the operator. The most frequent cause of failure is faulty introduction of the tube; it does not enter the tracheal canal, but is pushed down between the mucous membrane and the tracheal wall. These structures are loosely connected. The error is to be recognized by the absence of the characteristic sound of escaping air.

The orifice is to be inspected, and, if too small, enlarged, before trying the second time to introduce the tube.

Again, too much force in making the incision may result in wounding the posterior wall of the trachea. Excited operators have split the trachea its entire length, or wounded the vessels of the neck. There need be but little hemorrhage in the operation, if one but keeps in the middle line; and, as Senn says, that is the secret of success in performing the operation quickly and safely.

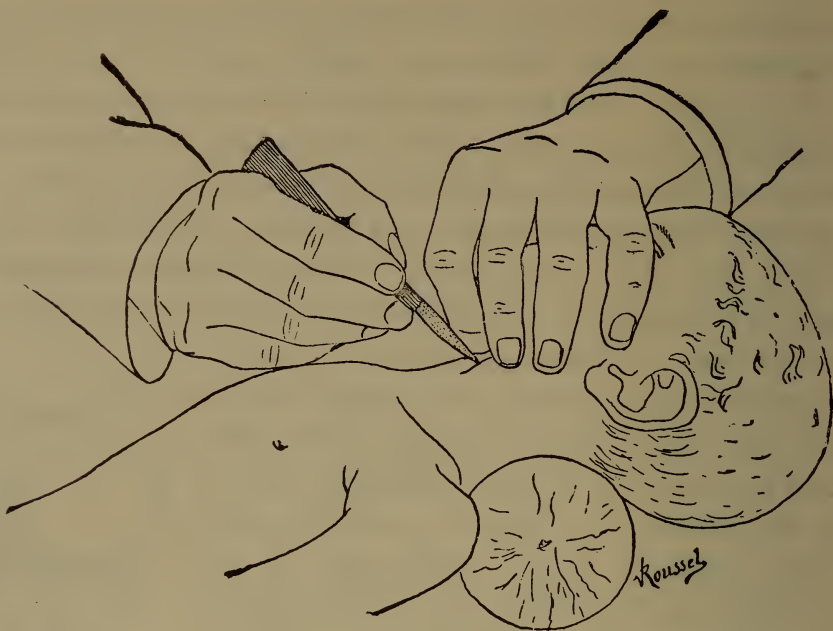

FIG. 362.—Tracheotomy. Incision. (Veau.)

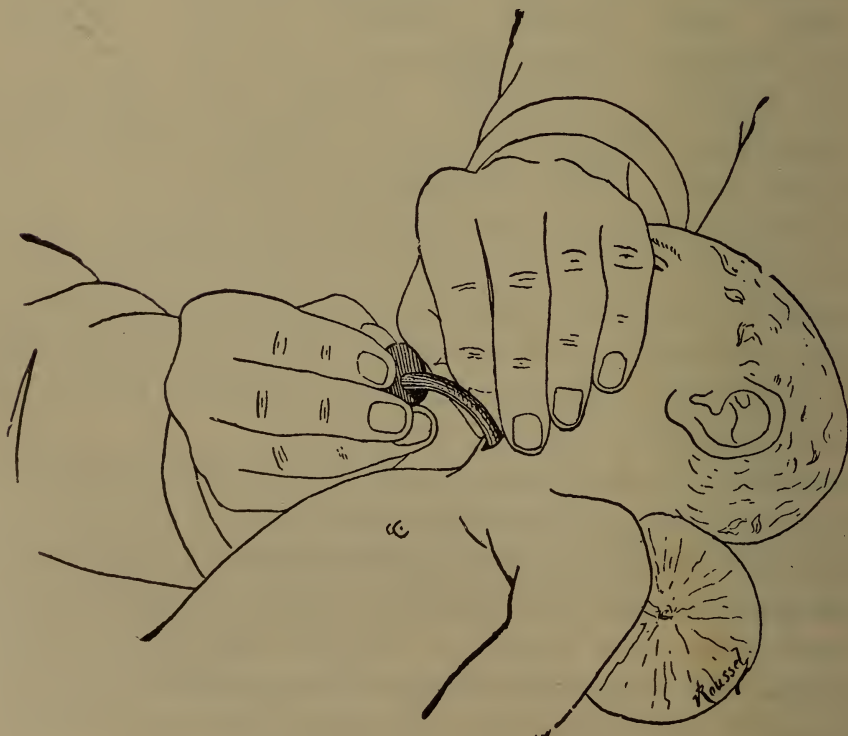


FIG. 363.—Introducing the tracheotomy tube. (Veau.)

The operation may be varied somewhat, depending, of course, upon the conditions. The cricoid may be divided if necessary. In other cases, before cutting downward it may be necessary to draw downward the isthmus of the thyroid gland before enlarging the opening.

In any case where time does not press, as when the tracheotomy is done preliminary to some other operation, the various steps may be carried out with more detail, the incision made by layers, vessels clamped, and the rings exposed, steadied with hoods and incised.

The tracheotomy may be done below the isthmus of the thyroid, but the higher operation is much the easier anatomically, although the principle is the same.

Tracheotomy for foreign bodies differs in some respects from the ordinary technic. Westmoreland, of Atlanta, who has had a large experience with this class of cases has recently emphasized some of these points (Amer. Jour. of Surg., Nov., 1909).

The incision should vary in length depending upon the size and character of the foreign body. If the opening is sufficiently large the foreign body is easily expelled by the respiratory effort; usually the opening is made too small and the trachea is injured by the forcible extraction of the body. In the young the thyroid isthmus is usually in the way and should be divided between forceps and ligated. Even the thymus gland may intrude and is to be depressed with a narrow retractor. A tenaculum should not be employed lest it excite a troublesome bleeding.

The incision in the trachea itself begins at the first ring. If asphyxia should occur in the course of the operation, the result of fixation of the object in the glottis, the operation should be rapidly finished, a tube or catheter passed into the trachea and the lung inflated by blowing through the tube—a great help in artificial respiration which soon resuscitates the asphyxiated child.

Tracheotomy tubes are not to be used. Once the trachea is opened the body may be coughed out which a tube would prevent. The wound may be held open if necessary by silk threads passed through its edges.

If the foreign body is expelled the trachea is to be sutured at once, employing a mattress suture of silk which is not to pass through the

mucous membrane. Whether the tracheal wound is made air-tight or not is to be tested by filling the wound with normal salt solution and obstructing the nose and mouth which will force some bubbles through if not tight. The fascia, muscles and isthmus, and finally the skin are repaired. The dressing is held in place by adhesive strips.

If inflammation exists, even though the body is expelled, do no suturing; cover the wound loosely with bichloride gauze to keep out cold air and to absorb the discharges. Change the dressing frequently.

If the foreign body is not expelled the protective dressing is to be applied which will not prevent the escape of the object if it should be coughed up later, and under this treatment the inflammation will probably rapidly subside.

After-treatment.—The success of tracheotomy rests largely on the care with which the after-treatment is conducted. There is no operation, perhaps, in which care and skill are better rewarded and negligence and ignorance more severely punished. If the temperature of the room cannot be kept at close to 65°, the tube should be kept covered with a warm, moist compress. The wound must be kept clean. For the first few days, the inner tube must be removed and cleansed several times daily. This should be done rapidly, and the tube disinfected and oiled before being reintroduced.

Morse (Post-operative Treatment, page 174) says, unless the cause of obstruction is a permanent one, it is often advisable to remove the tube after twenty-four to forty-eight hours; but the patient should be allowed to try breathing through the mouth before removing the tube, testing his capacity by stopping the cannula. In any event, he should be gradually accustomed to breathing through the mouth by plugging the canula.

Morse advised that soup, milk, or broth should be given at first, if necessary through a nasal or esophageal tube, although this is not often required. Difficulty in swallowing is likely to occur on the third or fourth day, but encouragement will enable the patient to overcome this. Nutrient enemas are rarely necessary.

Link, of Indianapolis, relates an experience (Medical Record, March 2, 1907) which illustrates at once the value of the operation,

the improvisation of instruments to meet an emergency, and one of the rarer forms of suffocating edema.

At midnight he was called to see a patient said to be choking to death and whom he supposed had an attack of asthma. He found the patient, a man weighing 250 pounds, cyanosed and laboring for breath. One hour previously, it seems, his throat had been lanced for the eleventh time in the course of a ten days' attack of tonsillitis.

A hurried examination found the pharynx too tightly swollen to pass a finger. How much laryngeal edema there might be could only be guessed. Thinking to intubate past the swollen pharynx, Link used the only thing available, the vaginal tip from a hard-rubber syringe, bent at nearly a right angle. The attempt failed. While preparing for a local anesthesia to do a tracheotomy, the patient's neck was surrounded with iced cloths, but this seemed to aggravate the asphyxia; the patient became unconscious and ceased to breathe.

The anesthesia was no longer necessary. All had fled but one woman, and while she held the patient's head, the doctor did a low tracheotomy.

He says, kneeling in front of the patient, who was in a sitting posture, he incised the skin and deep fascia in the median line 2 inches above the sternal notch, working with his finger down to the bronchial rings. With the finger as a guide, the knife was introduced, the trachea stabbed and cut slightly upward. A closed hemostat was then introduced and opened. Very little blood was lost. A female silver catheter from his pocket case was introduced and held in place by the assistant, while the doctor performed artificial respiration.

The patient soon began to breathe, but his convulsive movements threatened the loss of the small tube in the throat. The hard-rubber vaginal syringe tip was brought into use again, whittled and inserted. The elbow shape fitted perfectly. In half an hour the patient asked to be put to bed, and breathing entirely through the tube, slept the first sleep for several nights.

The edema declined as fast as it had arisen, and, within a few hours, the patient could breathe through the mouth when the tube was closed, and recovery was uneventful.

LARYNGOTOMY

As an emergency operation, this is most frequently done in an adult for cancer, but one need not wait until the patient is asphyxiated for there is nothing gained thereby. Therefore one may operate deliberately, for there is not the extreme urgency as with the infant.

Local anesthesia may be sufficient. Define as before the inferior border of the thyroid cartilage and the upper border of the cricoid, between which is the crico-thyroid membrane which is to be incised

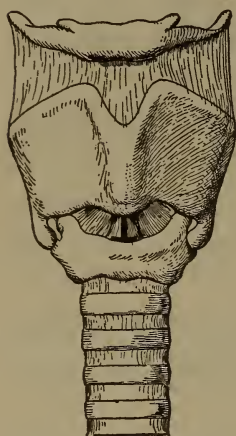


FIG. 364.—Laryngotomy. Incision of crico-thyroid membrane. (Veau.)

(Fig. 364). In the middle line over the space, make a vertical incision an inch long. Catch the bleeding points and retract the lips of the wound. Carefully incise the fascia until these cartilages are exposed. Now incise the crico-thyroid membrane *transversely* and open into the larynx (Fig. 365).

Introduce the tube as in tracheotomy. Remove and cleanse the inner tube on the first two days and the large tube on the third day.

Of course, if the operation is for cancer, it is merely palliative and the patient will continue slowly to die. If the operation is for edema of the larynx, the cause must be treated and the proper time finally to withdraw the tube determined by the conditions. If the operation is for a foreign body, the wound may be sutured at once.

ESOPHAGOTOMY (Cervical Region)

This is an operation only exceptionally of value for the esophagoscope will usually enable the foreign body to be removed without operation even after the ordinary maneuvers have failed (see Foreign Bodies). Nevertheless in the case of irregular bodies fixed in the lower cervical region it is preferable to open the esophagus rather than lacerate the mucosa in dragging the object out. A skiagraph will help to locate the body definitely preliminary to operation.

Position.—Place the patient on his back with shoulders elevated and the neck resting on a sand-bag with head turned to the right.

Incision.—Begin opposite the upper border of the thyroid cartilage and continue downward along the anterior border of the left sterno-mastoid for 3 or 4 inches, incising the skin, superficial fascia, and platysma. Ligate the veins and draw the sterno-mastoid forward and the depressors of the hyoid downward (Fig. 366). The wound is thus enlarged and at the bottom is the layer of cervical fascia connecting

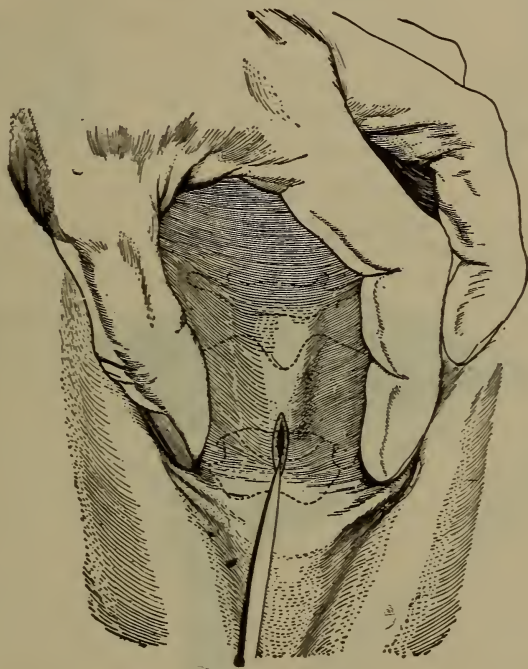


FIG. 365.—Laryngotomy. Incision of the crico-thyroid membrane. (Veau.)

It is better to cut transversely in order to avoid the crico-thyroid artery.

the thyroid gland and the sheath of the large vessels. Incise it and again enlarge the wound by drawing forward the thyroid gland, trachea, and larynx, and backward, the great vessels in their sheaths.

At this stage, in the bottom of the wound are the inferior thyroid, which must be ligated, and the recurrent laryngeal nerve, which should be drawn forward.

The esophagus now appears as a red tube. To steady the esophagus and define its walls, an esophageal bougie may be inserted. The wall of the esophagus is raised with mouse-tooth forceps (Fig.

367) and incised along its lateral wall. A suture is passed through each lip of the incision, that they may be readily retracted while the foreign body is located and removed, not always the easiest part of the task.

The wound of the esophagus is repaired with sutures of catgut and the rest of the wound lightly packed with gauze until all danger of infection is passed.

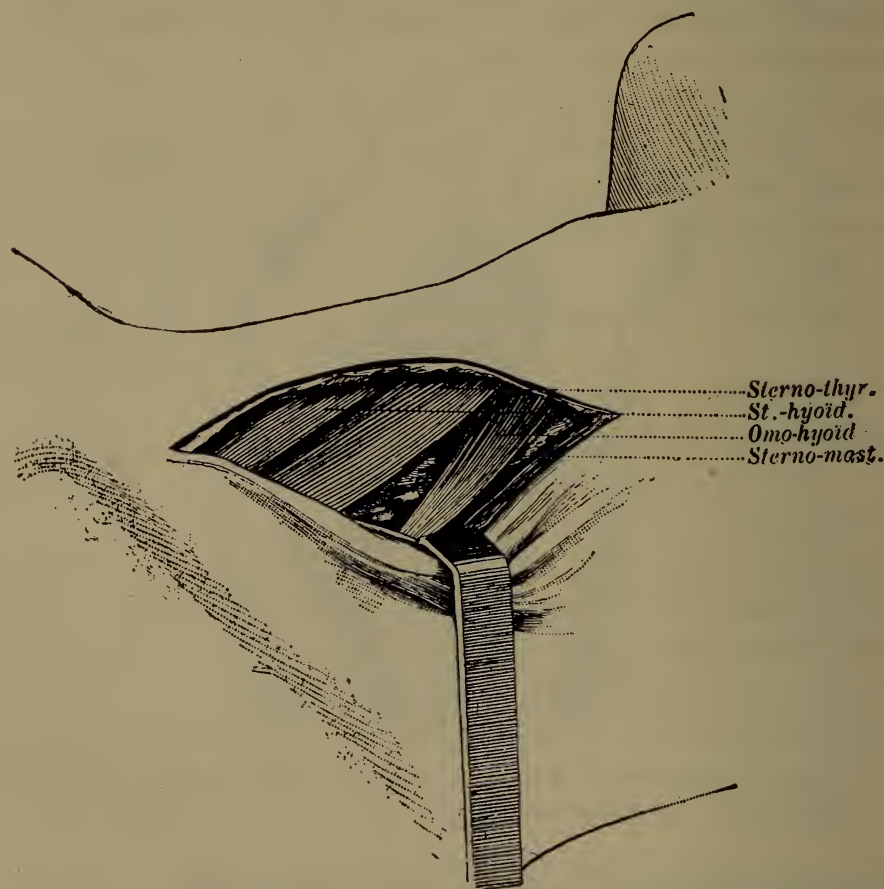


FIG. 366.—Esophagotomy: exposing the infra-hyoid group of muscles. (*Lenormaut.*)

As Bryant says, ordinarily the operation of cervical esophagotomy is not a perplexing procedure, but when the neck is short and fat, the vessels and thyroid gland enlarged, the detection and removal of the foreign body difficult, or the patient exhausted, the operation often taxes the patience and fortitude of the surgeon.

After-treatment.—The patient must be kept in bed with shoulders

raised. Nourishment should be given at first by enemata, and later, if necessary, by the esophageal tube.

Nassau reports a case illustrating the subject. A child swallowed a five-cent piece and thereafter could take only liquid foods. "X-ray" examination showed the coin lodged at the level of the suprasternal notch or just above.

Removal was attempted with forceps but without success, although the coin could be felt. An esophagotomy was done. The operation was completed in fourteen minutes. No vessels require ligation. The esophagus was not sutured and the superficial wound was closed with drainage. There was no leakage and the child made an uneventful recovery. Nassau does not regard esophagotomy as a serious operation, but believes it should not be considered until efforts at extraction have failed.

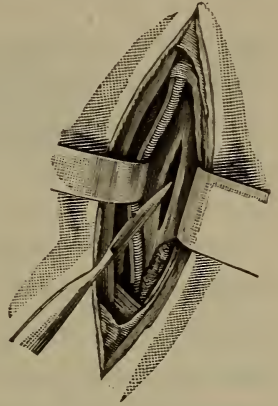


FIG. 367.—Esophagotomy. Final incision. (Bryant.)

CHAPTER II

URGENT THORACOTOMY. REPAIR OF INJURY TO THE LUNGS. REPAIR OF INJURY TO THE PERICARDIUM; OF INJURY TO THE HEART. PUNCTURE OF THE PERICARDIUM

As has been indicated elsewhere (see Injuries of the Thorax), urgent intervention for injuries of the thorax is a form of operative procedure at this present time with but a limited field. Whatever may be the apparent gravity of the case, it is far from being the rule to operate, for such operations require trained assistants, a special equipment, and a superior surgical skill. Of necessity, then, in general practice, the treatment must, generally speaking, be conservative: that is to say, cleansing of the external wound with enlargement and trimming up if necessary, reunion and aseptic occlusion, firm bandaging of the thorax, and an absolute quiet in bed. These measures along with stimulation with caffein and camphorated oil and normal salt solution, represent the elements of treatment which are within the scope of all.

But there are cases so manifestly fatal without operation that, as Lejars says, one cannot evade the question, "operate or let die?"

Grave rupture of the lung indicated by an immediate flooding of the pleural cavity, followed by urgent symptoms of asphyxia and syncope, is the signal for *immediate operation*. Again, repeated attacks of *secondary hemorrhage* call for operation.

URGENT THORACOTOMY

The technic of this operation can be exactly defined only in a general way and will need to be modified to suit the individual case.

Lejars insists that the opening must be large, that anything less will be a disappointment and the operation might as well not be undertaken.

The operation may proceed in one or two ways: (1) by a permanent resection of the ribs necessary to be removed, or (2) by temporary resection with the formation of a thoracic flap.

(1) Make a *U-shaped incision* forming a flap with its base posterior, and of which the two arms run parallel with the ribs and are wide enough apart to include at least three ribs.

The incision reaches to the ribs. Rapidly dissect up this musculo-cutaneous flap, exposing the ribs and intercostal muscles. With the flap held out of the way, begin the *resection of the ribs* by incising the periosteum of the lowest rib along its middle line, the full length of the exposed part. Denude the rib with the rugine. Take special care in the denudation along the lower border that the artery and nerve removed with the periosteum are not wounded. Divide the inner and the outer end of the denuded segment. (See Operation for Empyema.) Resect the other ribs exposed in the same manner.

Raise the musculo-pleural flap. Begin by dividing the upper border; then the lower border; and finally the anterior border, catching each intercostal artery as cut. When this flap is lifted the lung is exposed.

This procedure has the advantage that it can be rapidly carried out; the disadvantage, that it permanently sacrifices a part of the bony wall of the chest, but that is a small matter in the face of such emergencies.

(2) A *thoracic flap* may be formed. Make the same "U"-shaped incision and expose the ribs as in the preceding operation. Each costal segment is then denuded of periosteum at either end sufficiently for the passage of the bone-cutting forceps. In this manner each rib is divided at each end.

Next carefully divide the intercostal muscle parallel with, and above, the first segment, and lift the anterior end of this rib, and begin the *separation of the pleura*.

Work along the front at first, dividing the intercostal muscles and arteries and ligating as necessary. The liberation of the flap along the lower border next follows and, as the musculo-osseous flap is more elevated, the separation of the pleura is more and more facilitated.

Finally the flap is freed and turned back and the pleura is left

bared. The pleura is next divided and the wounded lung is now freely exposed.

Wipe out the clots and search for the bleeding surface. If necessary a hand may be slipped under the base of the lung pulling it forward for inspection.

Repair the lung. The ideal method is by *suture*, employing a No. 1 or 2 silk thread and passing it through the parenchyma with a round curved needle. If this is not possible *tamponade* is the next resort. If a border is lacerated and projecting it may be ligated *en masse* and resected.

Whether or not drainage is employed depends upon the amount of oozing and the probabilities of infection. If infection subsequently develops, the infected area is to be opened and drained as any other empyema.

REPAIR OF INJURIES TO PERICARDIUM AND HEART

The general practitioner does not see many injuries to the heart. Gunshot wounds are, of course, usually immediately fatal; so that the form of cardiac injury most likely to present itself for treatment is a stab wound. Occasionally the heart is lacerated by a broken rib. The sudden death from cardiac wounds may occur in several ways. It may occur from syncope arising from the pressure of the blood within the pericardium; or the heart may be unable to contract because of its divided fibers and cerebral anemia follows; or shock or pulmonary edema may be the immediate cause of death.

Even if death does not immediately occur, hemorrhage and infection may later provoke a fatal issue (see Injuries to the Thorax, page 110).

The treatment of traumatisms of the heart and pericardium has three ends in view; to combat shock, to control hemorrhage, and to prevent infection.

Keep the patient absolutely quiet, lower the head, apply artificial heat, give morphine in small doses ($\frac{1}{8}$ gr.) hypodermically; and, if there is an open wound in the chest, disinfect and dress aseptically, but do not operate merely to disinfect.

If the heart is injured sufficiently to bleed, *operate*. The sole indication, then, for operative treatment is *hemorrhage*.

The patient will probably die even if operated upon, but he will most certainly die without the operation; so that it is our duty to give him the additional chance which intervention offers.

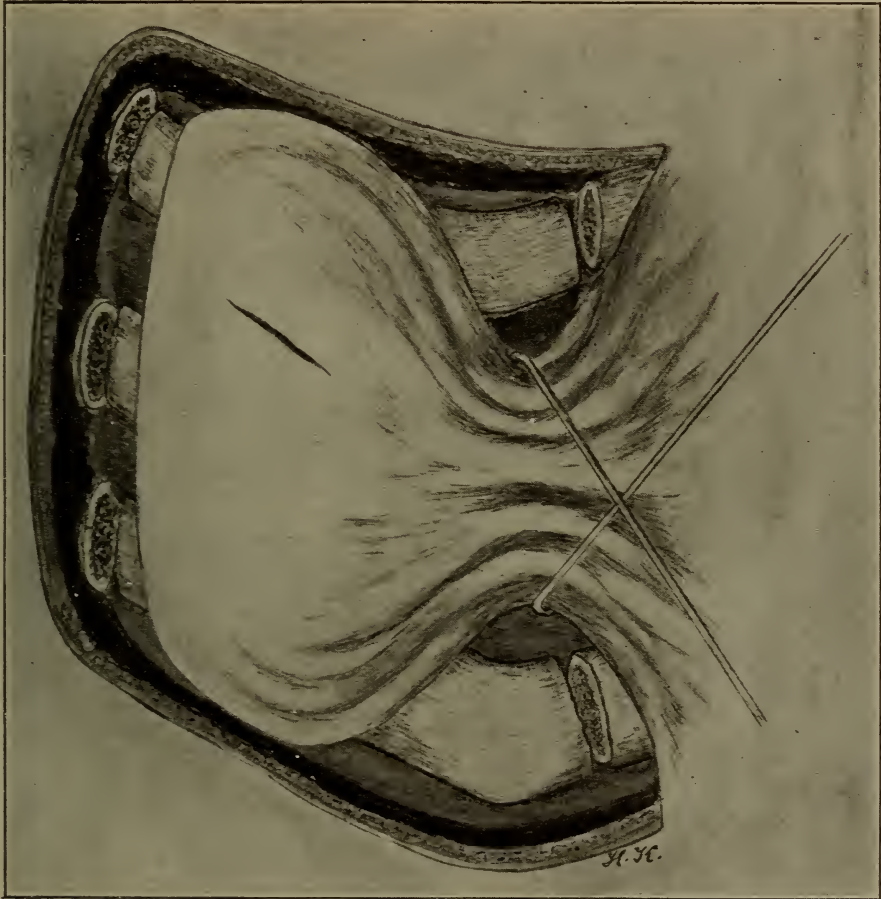

FIG. 368.—Forming the costal flap. The three ribs in the flap are divided near the sternum, and the upper and lower ribs divided at the outer limit of the flap. The middle rib to be fractured by raising the flap.

If the wound seems likely to have reached the heart; if there is bleeding; if there is pain and precordial oppression; if there are frequent attacks of syncope; if there are signs of increase of fluids about the heart; then one is justified in believing that the heart has been wounded sufficiently to produce hemorrhage and must prepare immediately for the operation. There must be no delay.

Nevertheless in the haste nothing in the matter of asepsis must be omitted.

The field may be hurriedly and yet sufficiently prepared by scrubbing with alcohol followed by iodine. There is little use to stop the bleeding if the patient is to die later from sepsis and that he is certain to do if a faulty technic is followed.

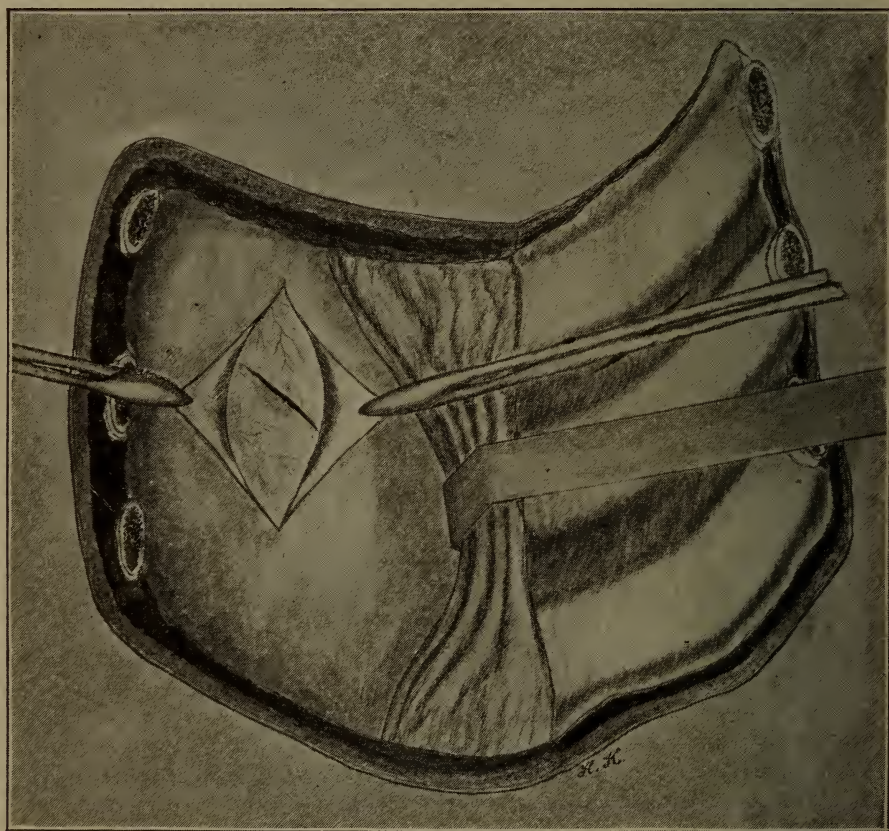


FIG. 369.—Costal flap reflected. Pleura retracted. Edges of pericardial wound held in forceps and heart wound exposed.

General Anesthesia.—Ether should be employed if the patient's condition will permit.

The *operation* proposes to make a thoracic flap, to open the pericardium and expose the heart, and to repair the injury. There is no operation that requires more decision, courage, and self-control.

Incision.—Begin in the third intercostal space just in front of the

anterior axillary border and cut inward to the border of the sternum abruptly curving there and following the sternal border downward to the sixth space; again abruptly curving and following that space outward (Fig. 368). These incisions expose the ribs and intercostal muscles.

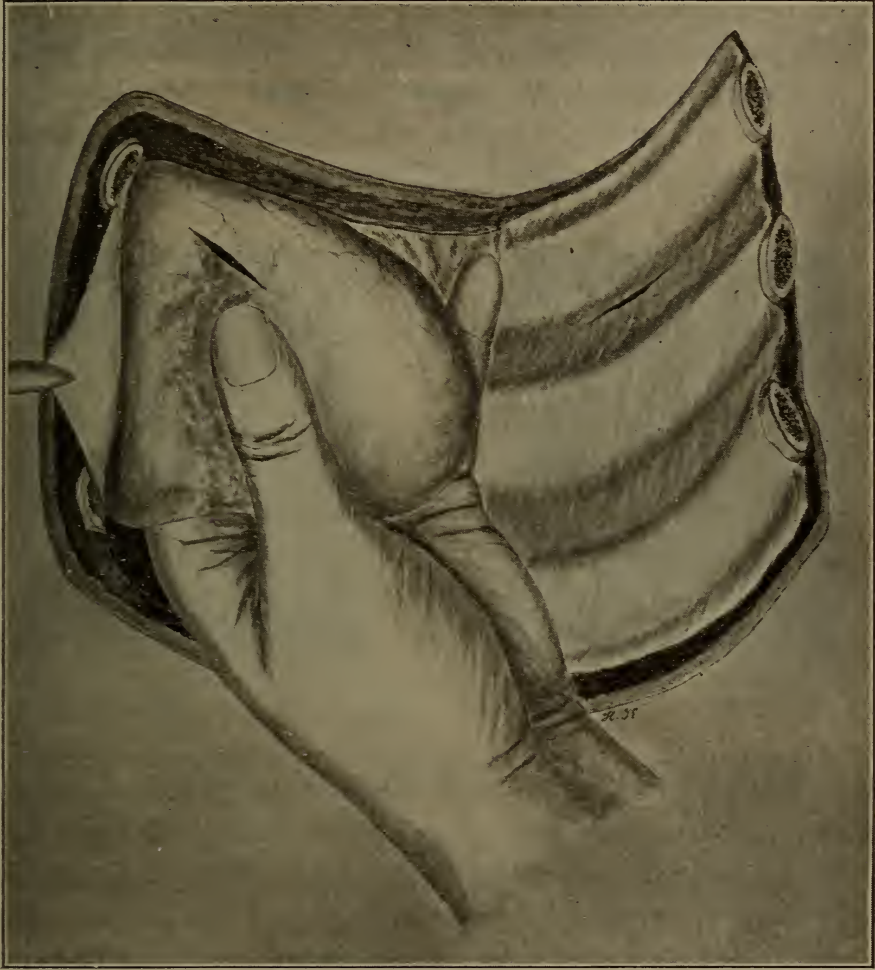

FIG. 370.—Heart supported in palm of hand preparatory to suturing. (After Lejars.)

Formation of the Flap.—Divide the fourth, fifth, and sixth cartilages near the sternum and also the intercostal muscles, along the line of the original incision.

At the lower outer angle of the incision, expose the sixth rib by pulling the tissues upward. Incise the periosteum over its external

surface and with the rugine free the rib of periosteum and divide it. At the upper outer angle expose the fourth rib, free it of periosteum, and with the costotome or a bone-cutting forceps, divide it in the same way. The flap is now attached only by the fifth rib which is to be fractured. Raise the sternal end of the flap with the left hand and press on the fifth rib with the right hand and with a little force the rib is broken in the line of section of the other two ribs.

The flap is now gradually raised as its adhesions to the subjacent structures are freed, and the pleura is exposed.

If there is a wound in the pleura, enlarging it, the pericardium may be reached; otherwise proceed to the *liberation and retraction of the*



FIG. 371.—Suture of wound of heart.




FIG. 372.—Suture of heart completed.

pleura. With a grooved director, liberate the fibrous attachments of the triangularis sterni to the posterior surface of the sternum, which at the same time liberates the pleura. With the fingers, draw outward the free border of the pleura with its covering, the triangularis sterni (Fig. 369). In this manner is the pericardium exposed. The assistant holds the pleura with a retractor.

Incision of the Pericardium.—Enlarge the wound in the pericardium and in that manner expose the heart. Retract the edges of the pericardial wounds with forceps. Locate the wound in the heart. Slip the left hand under the apex and pass the first suture, and the heart may be thereafter steadied by traction on the threads of the first suture (Fig. 370).

Suture the wound in the heart. Use either interrupted or continuous suture of catgut. There is no particular advantage in passing the suture in diastole. Pass them deeply, but not to the endocardium (Figs. 371, 372).

Now wipe out the pericardial cavity with sterile compresses and *repair the pericardium* by continuous catgut suture. Next, wipe out the adjacent portion of the pleural cavity, repair any part of the lung that may be injured and *repair the pleura* without drainage. Finally, replace the thoracic flaps, and suture. It is generally wise to excise the tissues along the track of the wound.

No drainage is to be employed *except* under these circumstances: if the case was operated on late and there is great probability of infection, it is better to leave drainage in the pleural wound, projecting from the thorax at the lower angle of the skin wound; if there is much oozing, it is better to leave a wick of gauze in the pleural wound.

A case of successful suture by Gibbon, of Jefferson Medical College, illustrates the subject (Jour. American Medical Assn., Feb. 10, 1906). Patient, aged thirty-eight, healthy colored man. Stab wound of chest, a few moments after which he fell unconscious. An hour later at the hospital his condition was very grave: unconscious, cyanosed, pupils dilated, skin cold and moist, respiration rapid and shallow. No pulse in the peripheral vessels and the heart sounds were distant, rapid, and irregular.

Vigorous stimulation was employed with morphine and atropine and his condition slightly improved. Operation about one and one-half hours after the injury. Only a small quantity of ether required.

The fourth costal cartilage was found and divided and the entire cartilage and a part of the rib was removed. The pericardium was explored and a wound located which would only admit tip of index finger. This pericardial wound was enlarged and the sac emptied of clots and liquid blood. It began rapidly to fill again. Two fingers passed under the heart lifted it up into the pericardial opening and with rapid sponging, the wound was located. It was situated in the right ventricle near the auriculo-ventricular groove. It bled freely, controlled by pressure; was about $\frac{3}{4}$ inch in length. The wound in the endocardium was about one-half as long.

A traction suture of chromicized catgut was passed through both edges and by that means the heart was held in position, while four other sutures were passed and no effort was made to avoid the endocardium. A small gauze drainage was applied to the line of sutures and brought out through the pericardial wound which was not sutured.

During the subsequent twelve hours there was enough oozing to require a change of dressing. His general condition was fairly good. The second day his condition was alarming; respirations 62. The gauze was found to be interfering with drainage and removed. The respirations fell to 38 in a short time.

Large quantities of salt solution were given by rectum. Liquid food on second day. The dressings were changed every other day. Six days after the operation the skin wound was sutured almost completely, the wound in the pericardium being practically healed. In six weeks he returned to work completely recovered, with heart's action regular and normal.

Gibbon does not advise an osteo-plastic flap unless a pleural wound is demonstrated, believing it best to excise as much of the sternum or cartilage or rib as may be necessary to give free access. He emphasizes the value of the traction suture, and advises the repair of the pericardial wound without drainage, but would always drain the external wound.

Travers (Lancet, Sept., 1906) operated upon a case in which the patient was impaled upon a spike fence. The right ventricle was torn, the spike penetrating the sternum to reach it. The wound in the heart was closed by twenty sutures. The patient did very well up to the eleventh day, when he died from heart failure, due to the pressure of a slowly forming clot.

Travers notes that the suturing seemed to stimulate the flagging heart.

Stewart, among the first in the United States to suture the heart successfully, turned the musculo-cutaneous flap to the left and the thoracic flap to the right, fracturing the cartilages near the base of the sternum.

The pericardial wound was enlarged in the axis of the heart. The heart wound, produced by a stab with a long, rusty pen-knife, involved

the thickness of the left anterior ventricular wall, ran parallel with the axis of the heart, and was about $\frac{3}{4}$ inch in length, was larger than either the skin, pleural, or pericardial wound. The heart bled freely and continuously, and resembled a mere quivering mass of muscle.

The wound was closed with a continuous silk suture, the pericardial cavity cleansed and the sac sutured with silk. A gauze drain was left at the lower angle. The pleural cavity was cleansed and irrigated with salt solution. The thoracic flaps were sutured with silk-worm-gut and a gauze drain left also in the pleural cavity.

During the operation, which lasted about forty-five minutes, 24 ounces of salt solution and adrenalin were injected, and strychnin and atrophin given hypodermically.

Some infection followed, and by the eighth day, the temperature was 103° , pulse 150, and respiration 50. From that time, the symptoms of sepsis gradually declined until at the end of three weeks, these conditions were practically normal; at the end of the fifth week, the patient was out of bed.

Stewart, discussing the operation (*American Journal Med. Sciences*, Sept., 1904), notes that the size of the heart wound cannot be predicted from the external wound; and concludes that the only safe procedure in doubtful cases is to enlarge the wound and ascertain if it penetrates the chest wall; and if there be symptoms of hemorrhage—of heart tamponade—operate.

In all of these cases already mentioned, it was the ventricle which required repair. Peck, of New York, describes a case in which it was necessary to suture the auricle (*Annals of Surgery*, July, 1909).

The patient, a colored girl twenty-four years of age, was brought to the hospital suffering from a stab wound over the third costal cartilage at the left border of the sternum. Her condition was grave: no radial pulse; the heart sounds could not be heard; respiration faint and shallow, and the extremities cold; operation begun about forty-six minutes after the receipt of the injury.

A quadrangular flap of the soft parts with base external was dissected back. The third, fourth, fifth and sixth cartilages were divided at the sternal junction, and the third, fourth, and fifth ribs near the costo-chondral junction, and the flap turned out and the internal mammary ligated above and below. The pericardial wound was

near the border of the sternum, a part of which was resected with rongeur forceps to give a better view. The tense pericardium was incised and the clots emptied out, whereupon the radial pulse could be felt.

The bleeding seemed to come from the upper part of the cavity but the rapidly beating heart, churning the free blood, made it impossible to locate the wound until a transverse cut in the sac gave a better exposure.

Lifting the heart forward and slightly rotating it to the left, a wound of the right auricle was brought into view. With each systole a stream of dark blood spouted 2 or 3 inches. Four sutures of chromicized catgut passed on a curved intestinal needle controlled the bleeding. The pericardium was cleansed, close without drainage with continuous chromic catgut suture. The cartilaginous flap was carefully sutured with No. 3 chromicized gut and the soft parts with catgut and silkworm-gut. No drainage was used. The operation lasted sixty-five minutes, during which time 1900 C. of normal salt solution was given intravenously. For the first six or seven days there were signs of mild pleurisy and the temperature ranged from 100 to 102.8, pulse 116 to 136; but, at the end of two weeks, these were practically normal, and at the end of another week, she was discharged, quite well.

It will be observed that the incision and flap formation differed with each operation, no one method can be insisted upon to the exclusion of all others.

PUNCTURE OF THE PERICARDIUM

Puncture of the pericardium—paracentesis pericardii—is indicated in those cases of hemo-pericardium and serous effusion in which the accumulating fluids dangerously interfere with the functions of the heart. The physical signs and the symptoms point to the nature of the difficulty. The symptoms may be overlooked in those which pertain to the primary infection. The patient breathes with difficulty and complains of pain and tenderness over the heart, the pain radiating down the left arm or the epigastrium; the temperature is variable; there is leucocytosis.

The physical signs are significant: The pulse is weak and rapid, there is often precordial bulging; the dullness of the heart area is increased the heart sounds are faint; and in some cases the first rib is pushed away from the clavicle (Ewart's sign). The exploratory puncture will confirm the diagnosis. It is not more frequently done because of the instinctive fear that one may wound the heart; indeed there are three structures which may be wounded with serious

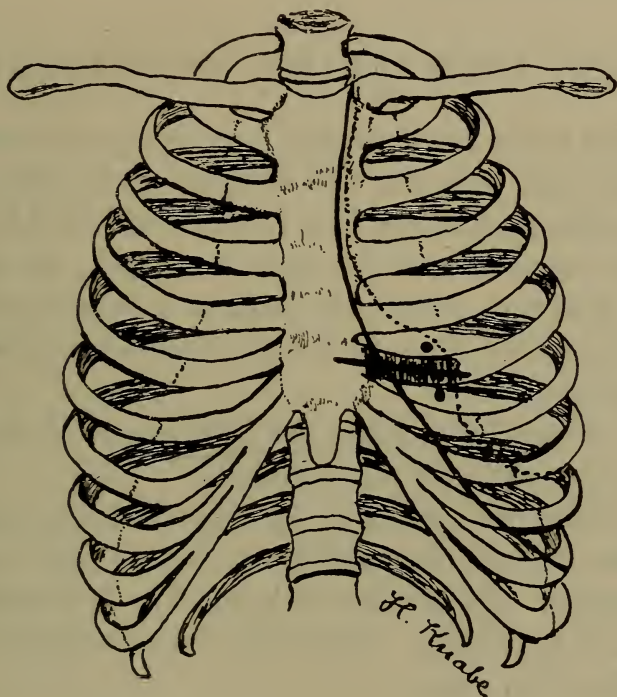


FIG. 373.—Puncture of the pericardium and pericardiotomy; vertical lines, represent the anterior border of pleura and lung. The • represents sites of puncture. —, line of incision for, and portion of rib resected in; pericardiotomy.

consequences; the heart, the pleura, and the internal mammary artery.

The puncture may be made near the sternum to the inside of the internal mammary; it may be made to the outside of the internal mammary, between it and the line of the lung. The latter is perhaps the better (Fig. 373).

The point of entrance of the needle is in the fifth left intercostal space, 6 cm. from the sternal border. Use a small trocar or an as-

pirator. Cleanse the field thoroughly. Put the patient in a half reclining position on his bed and mark with the left index finger the site of the puncture.

Direct the needle obliquely downward and inward and do not penetrate deeper than 2.5 cm., holding the needle so as to regulate its progress.

As the pericardium empties itself, gradually elevate the trocar so as not to wound the heart.

PURULENT PERICARDITIS. PERICARDIOTOMY

If in addition to the physical signs pertaining to effusion, there are edema of the chest wall and the symptoms of sepsis it is almost certain a purulent pericarditis is to be dealt with and if the exploratory puncture demonstrates the presence of pus, the only rational treatment is drainage, unless the patient is moribund. To incise and empty the pericardium is the only procedure that offers any hope of permanent relief.

Operation.—Begin by locating the attachment of the fifth costal cartilage and the middle of the sternum.

Incision.—From the middle of the sternum horizontally outward over the center of the fifth cartilage on the left side, to the costochondral junction. Deepen the incision so as to divide all the soft parts down to the cartilage. Strip back the covering of the cartilage with the rugine (Fig. 373).

Resect the cartilage at its sternal junction and, gently lifting up, gradually detach its coverings behind out to the junction of the rib. Here it may be fractured or permanently resected. Dividing their sternal attachments, retract the intercostal muscles with the arteries in the space opened up and thus expose the pleura.

Detach the pleura by loosening the sternal attachments of the triangularis which allows the pleura to be drawn outward. This should be done with the finger passed under the sternum and hooked around the border of the pleural sac. The pericardial sac is now exposed.

Incise the pericardium, first catching up a fold between two forceps,

and dividing it with scissors. If possible, the edges of the pericardial wound should be stitched to the margin of the skin wound.

Insert gauze drainage: A rubber tube is too likely to irritate the heart. This operation is often followed by recovery without any impairment of the heart's action.

CHAPTER III

EMPHYEMA—PURULENT PLEURISY

Various bacteria may attack the pleura, most frequently they are the pneumococcus, the streptococcus, the staphylococcus, the bacillus tuberculosis, or the bacillus communi coli.

The pneumococcus is usually present in the empyema of childhood. Be on your guard for empyema especially in whooping-cough.

The clinical history and the prognosis vary in different forms of the disease and are directly dependent upon the form of the infection.

But, whatever the pyogenic agent, when pus has once formed in the pleural cavity, it seeks for an outlet in various directions. It may rupture into a bronchus and escape by the mouth, and, under these circumstances, pneumothorax may ensue; it may perforate the chest wall, manifesting itself as an external abscess of various forms; it may open into the pericardium, esophagus, or stomach.

In every case, the longer relief is delayed, the greater the probability that the lung will be permanently collapsed or bound down by adhesions. Finally, in some degree, there are always the evil results of sepsis. There is every reason, then, when pus is known to exist in the pleural cavity, *to drain without delay*.

The *diagnosis* rests upon the history of the case (remembering that this history will vary with the form of infection), upon the pain, the constitutional symptoms which are those of sepsis generally, and upon the physical signs. These are: distention of the thorax accompanied perhaps by edema of the chest wall; flatness on percussion and evident displacement of neighboring organs; absence of the vesicular murmur, and the presence of bronchial breathing.

Taylor, of Springfield (Illinois Med. Jour., 1907), attributes the most frequent source of error in diagnosis to a misconception of the position assumed by the exudate.

Physicians are observed trying to establish a horizontal line for

the exudate with the patient in the sitting posture, under the impression that the fluid will follow the influence of gravity. But this is the exception rather than the rule. The dullness is usually higher posteriorly. The "S"-shaped line of Ellis, if present at all, is so variable from day to day as to be of minor importance. Taylor remarks further that the character of the fluid is often a matter of doubt. Chills and variable temperature point to pus, although he

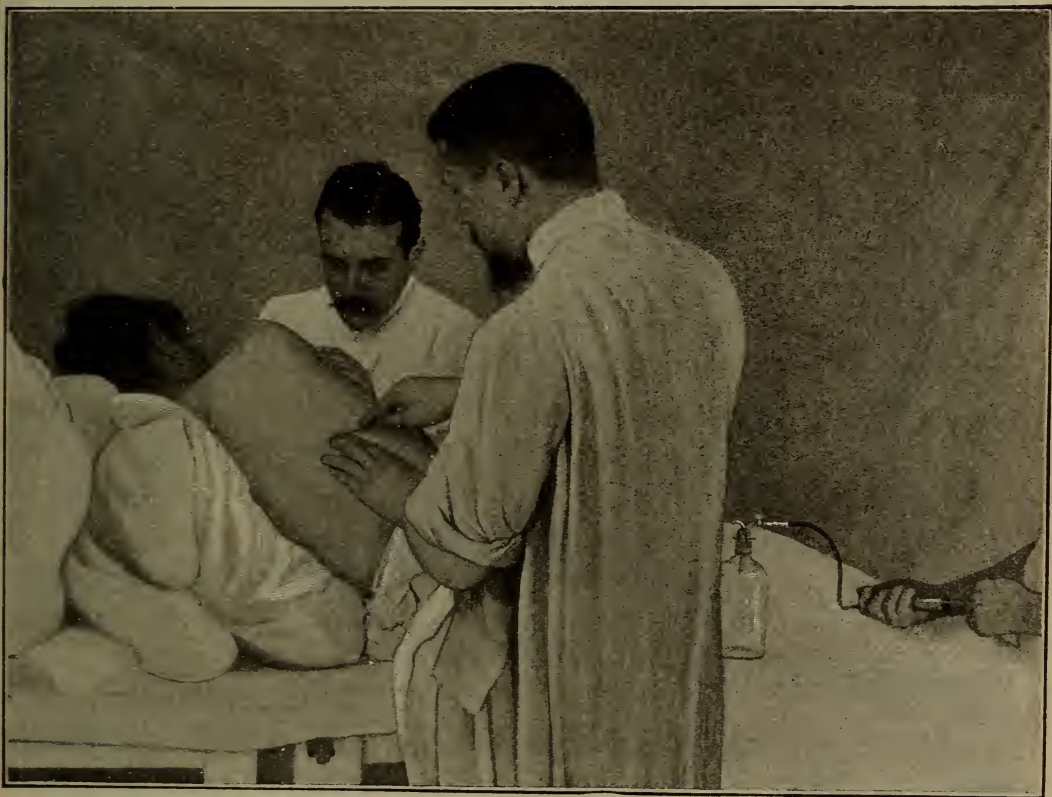


FIG. 374.—Puncture of the pleura. (*Lejars.*)

has seen patients recovering from pneumonia who had none of these symptoms and yet carried around three pints of pus in the pleural cavity.

Most of the signs and symptoms may occur as well with pleurisy with effusion, and it is only by exploratory puncture that the matter may be definitely determined.

Exploratory puncture, then, is the court of final resort and must always be employed before deciding upon the form of treatment.

PUNCTURE OF THE PLEURA

Let the patient lie on the sound side with his shoulders elevated and the arm of the affected side extended above the head, the effect of which is to widen the intercostal spaces. Locate, for example, a point in the axillary line and the sixth intercostal space. Freeze the skin with ethyl chloride or inject a little cocaine at the site of puncture. Press a finger into the intercostal space and locate the lower border of the rib. With the finger as guide enter the needle so as to avoid the rib and thrust it inward and slightly upward. One can readily determine whether it has reached the pleural cavity by the

degree of resistance. Enough fluid, whether pus or serum, will escape through the aspirating needle to make its presence certain; but in order to draw off any quantity an aspirator, of which Potain's (Fig. 374) is the best type, must be attached. A serous pleuritic effusion is relieved by aspiration. Sometimes removal of even a small quantity will start absorption in a case of long standing. If the fluid is pus, the subsequent course of events is quite different.

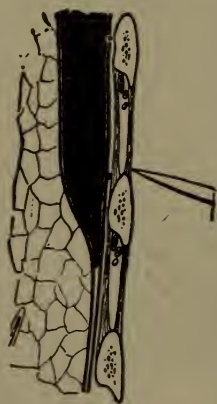

FIG. 375.—Emphyema: Relation of the pus cavity to the chest wall and lung. (Veau.)

As has been said, every purulent pleurisy must be opened as soon as possible, must be opened freely and at its lower point.

In the case of a child, it suffices usually to incise the intercostal space in order to perfect a cure. In the case of the adult, it is necessary to resect a rib for adequate drainage, and even then the patient may shortly die or retain a chronic sinus. These possibilities should always be explained before the operation, necessary but disagreeable, is undertaken.

Site of the Incision.—The cavity must be opened where it will drain best in the recumbent position. The lowest level of the abscess can be determined only by exploratory puncture; any other method is useless. Having already confirmed the diagnosis by puncture, now at the beginning of the operation, make another exploratory puncture in the space next lower. If pus is found there, puncture again

in the space below, and so on until no pus is found. The last puncture producing pus will be the site of the incision.

Anatomy (Fig. 375).—The aim will be to incise parallel with the rib. In going through the structures of the intercostal space, remember that the vessels and nerve lie in or near the groove in the lower border of the rib. Incising any space, therefore, keep close to the lower line of the space, keep near the upper border of the rib forming the lower boundary of the space. If a rib is to be resected, it should be denuded of its periosteum, which is loosely attached and on that account easily stripped off.

EMPYEMA IN THE CASE OF A CHILD

In the case of a child, simple incision of the pleura will suffice. Under general anesthesia, if the condition of the patient will permit, make an incision 3 or 4 inches long, parallel with the ribs. The incision traverses the skin, and beneath it a cellular layer, often edematous. Next divide the muscles, letting the rib serve as a resist-

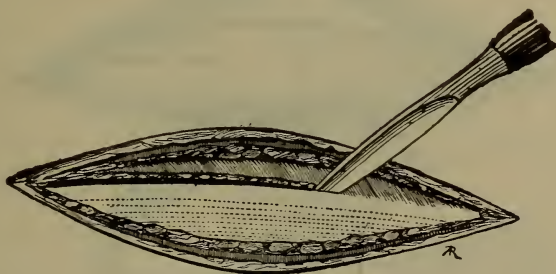


FIG. 376.—Incision of the pleura without resection of a rib. (*Schwartz.*)

ing plane. In front they are thin (*pectoralis major*); behind, thicker (*latissimus dorsi* and *serratus magnus*). Divide them at a single stroke and without concern. A small artery may need to be clamped.

Having exposed the rib (Fig. 376), retract the upper lip of the wound and locate the upper border of the rib; below, it bounds the space about to be penetrated. Following this border, incise layer by layer, the intercostal muscles. There is never any serious hemorrhage. As you approach the pleura, be prepared for a sudden spurt of pus, and, when the pus flows, it is evident the pleura is opened. Enlarge the opening, using the left index finger as a guide. Incline the patient so that the cavity may be entirely emptied. Fix the drainage-tube (Fig. 382).

EMPHYEMA IN THE CASE OF AN ADULT

In the case of empyema in an adult, it is usually necessary to resect a rib. One needs a bone-cutting forceps or a costotome and a curved periosteal elevator or rugine in addition to the ordinary instruments.



FIG. 377.—Incision of the costal periosteum. (Veau.)

Local anesthesia is preferable and with a little patience will be made to serve. Having determined the line of the incision inject with novocain, intradermically. Next infiltrate the subcutaneous

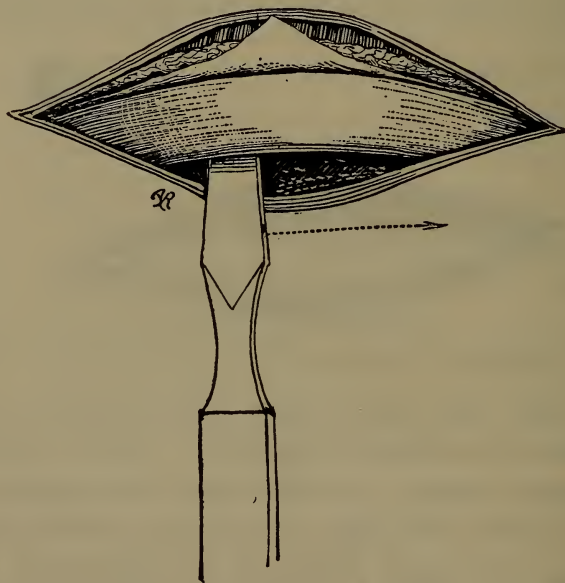


FIG. 378.—Uncovering the posterior surface of the rib with rugine. (Schwartz.)

tissues along the same line. Usually after a wait of five minutes the skin and fascias may be divided without pain.

An injection is next made in the periosteum and the tissues adjacent to the site to be sectioned. With the timorous, ether may be necessary but it can never be considered safe in such conditions.

Having determined, then, the site of incision by exploratory puncture, incise the skin and muscles as in the case of a child. The

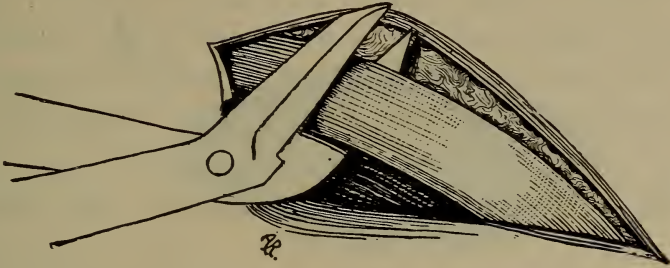


FIG. 379.—Section of the rib. (Schwartz.)

length of the incision will equal four fingers' breadth. When the rib is exposed, divide its periosteum in the middle line (Fig. 377).

The *denudation of the rib* is an important step. With the rugine or curved periosteal elevator, uncover the upper half of the external surface of the rib first and then the lower half, keeping very close to

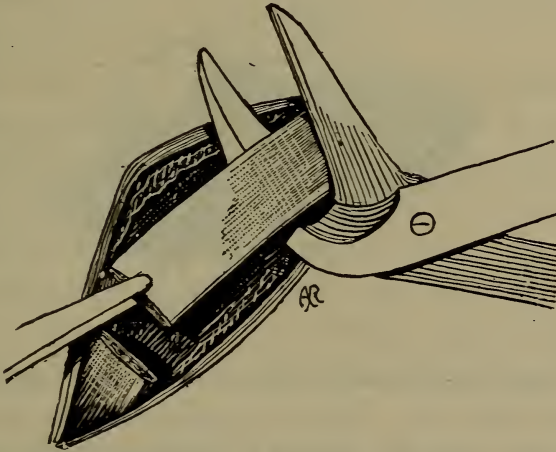


FIG. 380.—Section of the rib. (Schwartz.)

the rib as you reach the lower border, so as not to wound the intercostal vessels or nerve, which are closely attached to the periosteum and are removed with it. Finally, uncover the deep surface of the rib. Carefully slip the elevator upward between the bone and its periosteum, which is loosely attached (Fig. 378). Carry the elevator to one end of the section and then to the other and the part of the rib to be removed is thus entirely freed from its periosteal attachment.

Divide the rib. Introduce one blade of a bone forceps or costotome under one end of the section to be removed and divide it (Fig. 379).

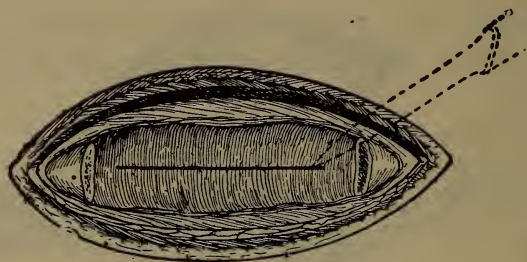

FIG. 381.—Rib removed, pleura incised. (Veau.)

Then divide the other end (Fig. 380). The bone removed should be $2\frac{1}{2}$ to 3 inches long. The stumps should not project beyond the limit of the flesh wound, else necrosis is favored.

Incise the pleura. With the rib removed, the periosteum remains attached to the pleura and this periosteal layer is incised along its

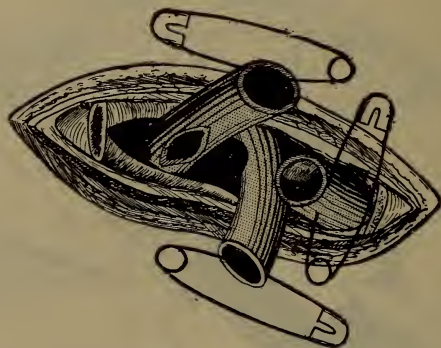


FIG. 382.—Drainage of the pleural cavity. (Veau.)

middle (Fig. 381), and the pleura is divided at the same time. Be on your guard, when making the incision, for a spurt of pus.

Empty and drain the cavity. Incline the patient to one side and instruct him to cough. The pus pours out, often offensively fetid. Take plenty of time. Finally, wipe out the cavity with sterile gauze. Irrigation is usually inadvisable; but, if used, employ only warm, sterile water, salt solution, or a weak solution of peroxide. The stronger antiseptics are dangerous. Do not suture the wound except to cover over the projecting end of the divided rib. The difficulty is to keep the wound open.

Drainage must never be neglected. Employ two large and long tubes placed in different directions and anchor with safety-pins (Fig. 382) or by a suture, else they may be lost in the abscess cavity.

Dressing.—This is important. Pack moist sterile or boracic gauze all around the tubes, between the lips of the wound. Apply an ample dressing of absorbent cotton, which covers half the thorax, and hold all in place with a large flannel bandage maintained by suspenders. Let the patient occupy the half-sitting position, inclined toward the affected side and supported by pillows at the back.

Subsequent Care.—After a few hours, change the dressing, which is usually saturated, but do not disturb the drains. Change the dressing twice daily until the discharge diminishes and about the third day withdraw, cleanse, and replace the tubes in the *same place* and to the *same depth*; else look for trouble, if you fail to accomplish this.

Do not irrigate while making these dressings, unless the discharge has persisted undiminished for a week and continues fetid, when it is best to use a sterile wash of salt solution or dilute peroxide, which is to be injected under very slight pressure.

The *end results* vary with the nature of the infection.

(1) The meta-pneumonic pleurisy of children is usually cured. About the fifteenth day, smaller tubes may be used and are gradually to be shortened as granulation proceeds. In the fortunate case, the opening will close in something like two months.

(2) In tubercular pleurisy with secondary infection, cure scarcely ever takes place. The patient will probably die in a few months of amyloid degeneration. Even if the patient does not die soon, the suppuration shows little tendency to yield. In these cases with persistent sinus, the bismuth paste injection often hastens a cure.

(3) Streptococcic or staphylococcic pleurisy: The patient may go on to death or else recovers with persistent sinus. Keep the orifice open, for if the pus is allowed to accumulate, it will be necessary to operate again. Keep watch on the functions of the kidney and liver. Remember the frequency of metastatic abscess, as of the brain, for example.

After two to four months, the case may be referred to a specialist for a plastic operation.

CHAPTER IV

URGENT CRANIECTOMY: TREPHINING

FRACTURE OF VAULT OF THE SKULL

There are two conditions which may accompany fracture of the skull, singly or together, either of which demands immediate relief. (See Fracture of the Skull.)

(A) The *depressed fragments* have contused and lacerated the brain; consciousness was immediately lost and was not regained. Under these circumstances, the fragments must be elevated without delay.

(B) *Hemorrhage* has occurred within the cranial cavity and the clot compresses the brain. In this case, there is a "free interval." The patient regains consciousness and, perhaps, for a time—two to twenty-four hours—appears not to be seriously injured, but little by little the signs of "compression" develop, namely: restlessness, dullness, stupor, coma; normal pulse at first, but which finally grows slow, full and bounding; and slow and stertorous breathing. Delay is dangerous. The clot must be removed and the hemorrhage checked.

Nearly always it is the *middle meningeal* which is at fault. There is in consequence an *extradural hematoma*. Once in a while, however, the bleeding will be found to proceed from a ruptured sinus or from the pial arteries and there exists at the same time an injury to the brain substance. There is, in this case, an *intradural or intracerebral hematoma*.

Whatever the form of compression, one is compelled to operate, but he must first get the anatomy of the middle meningeal artery clearly in mind.

The middle meningeal, a branch of the internal maxillary, is the size of the radial, entering the cranial cavity at the base of the skull, through the foramen spinosum. It is embedded in the dura and grooves the inner surface of the skull.

Above the level of the zygoma, the artery divides. The *posterior* branch

the smaller, is directed upward and backward, and the *anterior* branch (Fig. 383), the more important, ascends vertically to the fronto-parietal suture, which it follows upward, passing a little posterior to it. As it reaches this suture, it gives off constantly a posterior branch. The anterior branch is accompanied by veins which occasionally assume the importance of a sinus.

The directions for trephining over the middle meningeal are quite definite, but usually unnecessary to regard in emergency surgery, for it is a mistake not to follow the exterior indications and guides furnished by the traumatism. Still one should be able to locate these points readily.

Two horizontal and two vertical lines are employed to locate the paths of the two branches of the middle meningeal. Draw the first (A) from the inferior border of the orbit along the zygoma to the external meatus. Draw the second (B) from the upper border of the orbit backward, and parallel with the first, ending beyond the line of the mastoid. To locate the path of the anterior branch of the middle meningeal, draw a perpendicular line from A upward from a point corresponding to the middle of zygoma; and where it cuts B is the point most advantageous for exposing the anterior branch. This vertical line is about two inches in length or approximately equal to the length of the last two joints of the index finger. To locate the track of the posterior branch: From the apex of the mastoid, draw a second vertical line upward; its point of junction with B indicates the path of the posterior branch. These lines may be marked off on the skin by tincture of iodine.

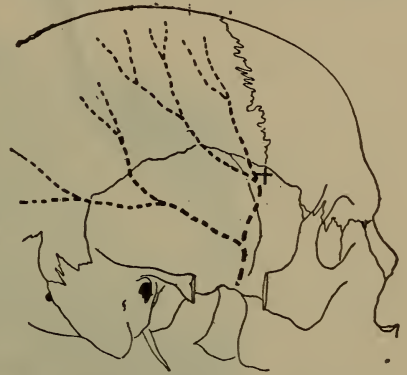

FIG. 383.—Outline of the middle meningeal artery. (Veau after Cuneo.)

Operation.—Provide, besides the ordinary instruments, Rongeur forceps, a mallet and chisel, or a trephine. Carefully shave the half of the head corresponding to the traumatism or, even better, the whole head. Sterilize the field. Scrub with soap and water, followed by ether, which in turn is followed by bichloride solution. There must be no relaxation in the disinfection, whether exploration is to be extensive or not, for asepsis is the best means of preventing a hernia of the brain.

General Anesthesia.—Often the sensibility is so benumbed, the patient so depressed, that anesthesia is both unnecessary and dangerous. Chloroform is generally best for brain surgery, but ether is safer in these urgent cases with much shock.

Incision.—The incision will vary with the conditions. We will suppose three circumstances: (a) there is an extensive skin wound; (b) there is a bullet wound; (c) there is no wound of the soft parts.

(a) If there is an extensive and ragged skin wound, it is better to enlarge it at once by *crucial incision*. This has the advantage of being rapidly done, but has the disadvantage that it interferes with the blood supply of the flaps (Fig. 384).

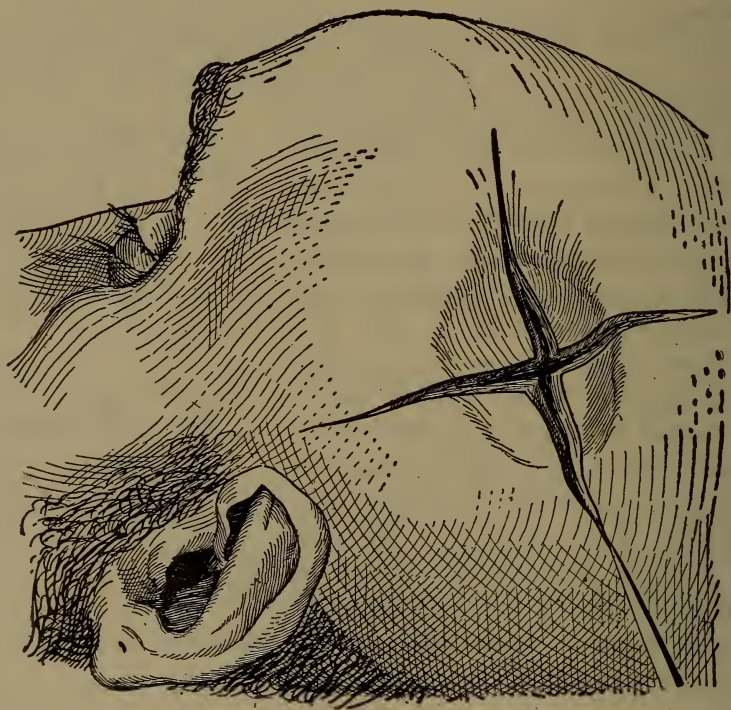


FIG. 384.—Depressed fracture of the skull. Crucial incision. (Veau.)

(b) If there is a bullet wound, make a “U”-shaped flap with the bullet wound in the center, and which retains its attachment below, the better to conserve the blood supply.

(c) If there is no open wound, make the same sort of “U”-shaped flap with its pedicle downward, over the site of the contusion.

Cut boldly to the bone if it is resistant. If the fragments are mobile under the scalp, proceed cautiously, but do not stop until on the pericranium. The incision will often traverse a zone which is contused and infiltrated, the various layers being indistinguishable.

If possible, form the flaps first and then catch the bleeding points

along the edges of the flaps. In some cases it may be necessary to clamp a vessel before the incisions are completed.

As soon as the bone is reached, hurriedly strip back the flaps, including the periosteum. The site of the fracture is now exposed (Fig. 385). One of two conditions presents: (1) there are *depressed fragments* which must be removed, or (2) there is a *fissure* without depression, but beneath the bone there is a clot to remove and a hemorrhage to check.

(1) The fragments are often superimposed in two layers and those of the internal table are usually the most extensive. In some cases

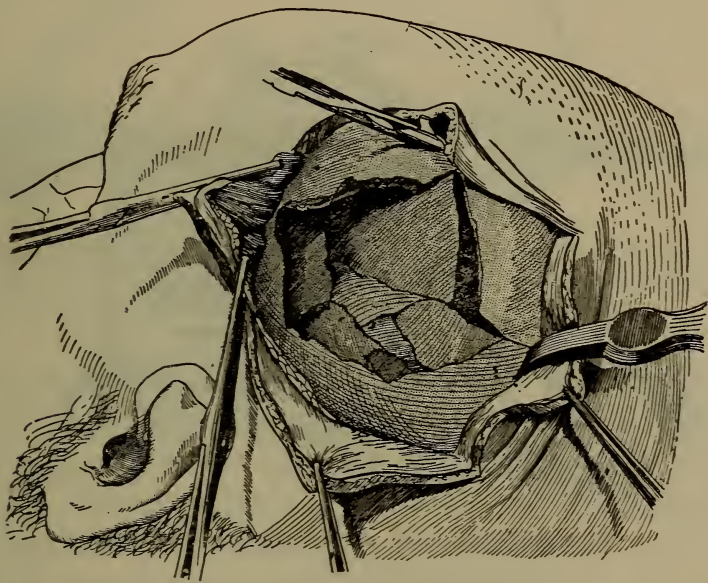

FIG. 385.—Stripping back the periosteum to expose the field of fracture. (Veau.)

the fragments are easily extracted, but in others the bony fragments are so wedged in that it is difficult to induce any instrument to pry them loose. Failing in this, notch the sound bone along the line of fracture with the chisel, and in this manner open up a way to introduce the elevator. Be careful not to further bruise the brain in extracting the fragments, employing only horizontal traction. Never wrench or twist the fragments (Fig. 386).

The deeper fragments are usually adherent to the dura mater and, if so, require to be stripped loose before attempting extraction.

(2) If there exists merely a *fissure*, it will be necessary to trephine.

At the possible site of the hemorrhage, create an orifice in the skull, either with the trephine or with mallet and chisel.

Trephine.—(A) The ordinary Galt trephine may be employed. Begin by protruding its sharp point about $1/16$ inch and boring it into the skull at the selected site. As soon as the cutting edge of the trephine has grooved the skull, retract the point, and proceed to deepen the groove by rapid half-rotations of the wrist. From time to time, test the groove with the point of a probe to be sure that one

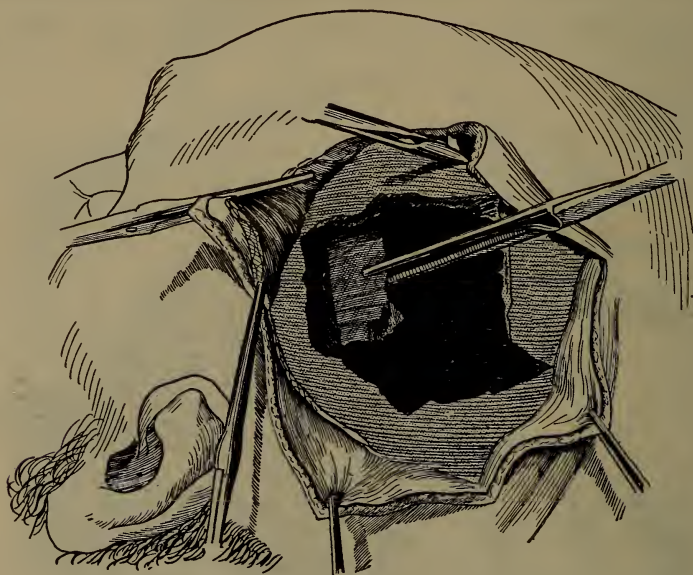


FIG. 386.—Removal of the fragments. (Veau.)

side is not cutting faster than the other. If there is any difference, regulate the pressure accordingly. Diminished resistance and increased blood flow indicate penetration of the outer table.

The inner table is more resistant, and, when it is reached, one must proceed more cautiously. When it is judged that section is complete, the trephine may be removed and gentle effort made to elevate the button. If the bone is completely divided, the button is easily removed.

(B) Doyens' instrument is in less common use, but is simple and efficient. It consists of a brace, a perforator, and burrs of various sizes (Fig. 387).

Begin by attaching the perforator and drilling a shallow hole,

steadying the brace with the left hand. The instrument must always be kept perpendicular to the skull. Next replace the perforator with a burr and rapidly ream out the opening begun by the perforator. As before, one recognizes the approach to the diploe and the inner table.

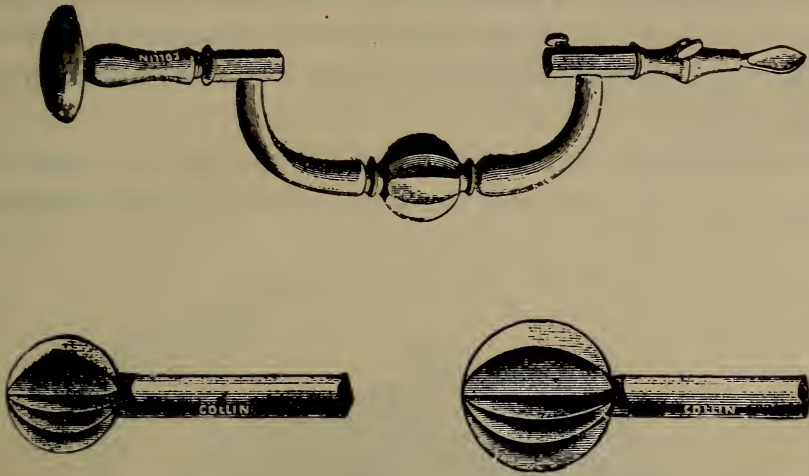


FIG. 387.—Doyen trephine. The perforator attached to the brace is used to cut through the outer table; the opening subsequently enlarged by burrs of various sizes, replacing the perforator on the brace.

The burr pushes the dura before it without injury (Fig. 388). A quadrilateral or circular flap may be outlined by additional openings, and the chisel or rongeur used to complete the section of the flap.

(C) The mallet and chisel may be used and, while not so efficient as the trephine, will serve the purpose. Begin by cutting a narrow groove in the skull, deepening it gradually until the inner table is reached and divided. The chief point to be emphasized is that the chisel is to be held quite obliquely to avoid concussion and unexpected penetration.



FIG. 388—Doyen trephine; showing manner in which the burr approaches the dura.

Detach the dura mater. Whatever the means employed, the dura is now exposed, and if the opening, which should have a diameter of at least 2 inches, needs to be enlarged, the dura should be detached from the edge of bone and the chisel or rongeur employed. Enlarge so as to expose as much as possible of the middle meningeal artery.

Treat the hemorrhage. Once the cranial cavity is well exposed, the

next concern is the hemorrhage. (a) There is a clot to be removed; (b) a bleeding vessel to control.

(a) The clot may be removed with the finger or with a dull curette. The amount of the accumulated blood may be astonishing, but one must work patiently. The clot must be removed to the last particle, remembering that toward the base there is the greatest abundance. The white and resistant dura mater must be exposed in every direction (Fig. 389).

(b) Next look for the bleeding vessel. A jet of blood may indicate the proper point at once, and the vessel is caught with forceps and a

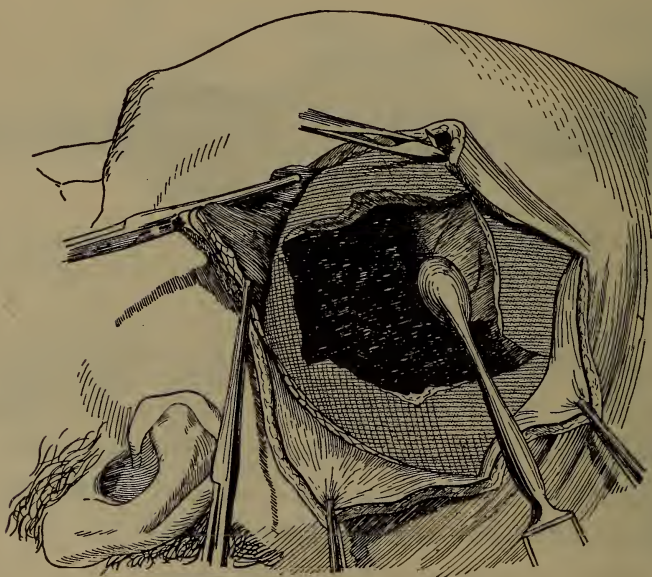

FIG. 389.—Removal of the clot. (Veau.)

ligature passed with a needle (Fig. 390). If the bleeding point is too deep, the forceps may be left in position for twenty-four hours. More often, perhaps, the source of the hemorrhage cannot be definitely determined and as soon as the compress is removed, the blood wells up from the bottom of the cavity. Depressing the head, the change in the stream's direction may reveal its source which is liable to be the middle meningeal vein; it is to be caught up and ligated like the artery. If the blood comes from a sinus, pack the cavity with sterile gauze. The hemostasis must be complete. If there is only slight, yet persistent oozing, leave a gauze tampon for twenty-

four hours. *Suture* the angles of the wound and apply a dry dressing.

Another case, more rare: The *dura mater* is *lacerated* and the brain, more or less contused, is exposed. Catch the edges of the dural wound with forceps and, raising the membrane, gently wipe out the clots with sterile gauze.

A mere slit in the dura may be repaired by catgut suture, but if there is loss of tissue, it is useless to attempt suture of this inelastic membrane. The hemorrhage must be cared for in the manner already described.

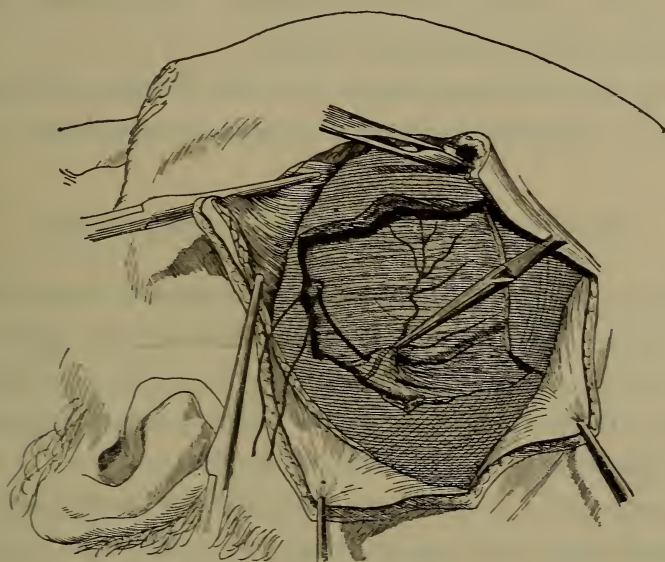


FIG. 390.—Ligation of the middle meningeal artery. (Veau.)

Most trying are those cases presenting a *subdural hematoma*. Trephining is completed and the dura is exposed, but there is no clot. Instead, the dura, tense and darkened, bulges toward the orifice. Make a crucial incision in the dura, or raise a flap with its base above, and wipe out the exudate, usually diffused. Be very careful not to give additional injury to the contused brain tissue. Leave a strip of sterile gauze in the wound for drainage, removing it on the second day.

After-treatment.—Following the operation, it may be necessary to inject 1 or 2 quarts of salt solution in the first thirty-six hours. No alcoholic stimulants must be used. Keep the patient

absolutely quiet, the head slightly elevated, and change the dressing as often as soiled. If sepsis occurs, open up the wound. If there is hernia cerebri, Treves advises a gauze pad saturated with alcohol held on under light pressure.

Results.—The patient may die without regaining consciousness, owing to the shock of the traumatism, aggravated perhaps by that of the operation; for this reason, it is absolutely necessary to give as little chloroform and to do the operation as rapidly as possible.

He may die the next day from persistent hemorrhage. He may die between the third and eighth day from septic meningitis, due to infection from the injury or the operation. Watch the course of the temperature in order to forecast sepsis.

Finally, he may recover, and even then he may develop a Jacksonian epilepsy, delayed perhaps as long as ten years.¹

FRACTURE OF THE BASE OF THE SKULL

It has already been said it would seem that the only way, as certainly as may be, to forestall infection in fracture of the base is to trephine and drain, leaving a permanent escape for microbes and their toxins. If there is evidence of compression originating at the base, the trephining is even more imperative.

Cushing recommends drainage through the lower temporal region for the reason that very much more frequently the middle fossa is involved, the middle meningeal artery ruptured, and the tip of the middle cerebral lobe contused.

Operation.—Make an incision from the middle of the zygoma directly upward to the temporal ridge. Clamp the divided branches of the artery. Divide the temporal fascia and split the muscle in the same line and cut through to the bone. Strip back the two halves of the temporal by free use of the rugine. If there is a line of fracture, or some indication of pressure, trephine accordingly. Otherwise, aim to make the opening near the junction of the temporal with the great wing of the sphenoid. An extradural hemorrhage may be brought

¹ It occasionally happens that the hemorrhage occurs on the side opposite the traumatism. There is nothing to do but repeat the trephining on the opposite side, for the matter cannot be determined beforehand.

to light and a ruptured middle meningeal found. In other cases, the effusion will be reached only after the dura is divided. The escape of the bloody cerebrospinal fluid will be favored by passing a curved blunt dissector down under the temporal lobe. If the effusion is merely serous, the wound may be closed; if there is any persistence of oozing, a strip of rubber tissue should be left in the lower angle of the wound, extending into the cranial cavity under the temporal lobe.

Vincent (*Revue de Chirurgie*, Aug., 1909) concludes that this intervention will reduce materially the sequelæ so common to fracture of the base not treated by operation. But with this conclusion the majority of surgeons do not agree and the tendency is to treat these cases by non-operative methods. Certainly for the general practitioner operative procedures will remain a method only to be employed when focal signs of brain pressure are present.

TREPHINING THE SUBOCCIPITAL REGION

A case of Ford's illustrates this procedure: A man of fifty years fell from a street-car, striking upon his head. He was only slightly dazed; insisted he was not hurt and walked home. An hour later, his head began to pain severely and in the course of a couple of hours he began to grow drowsy and so gradually lapsed into unconsciousness. He developed a divergent strabismus, but his pupils remained normal and there were no signs of motor paralysis. There were no marks about his head to indicate injury.

After twenty-four hours, Ford was called in. He found the patient still unconscious and with the pulse and respiration of compression. He was removed to the hospital for operation. After the head was shaved, a flatness was noticed below the occipital protuberance, though there was no depression or evidence of contusion. It was decided, however, to trephine over this point. A semilunar incision, convex upward, mapped out a flap with the base downward, and the skull was exposed. A stellated non-depressed fracture was found. A trephine button removed revealed the presence of a large clot. A large area of bone was removed with rongeur forceps and an immense subdural clot cleaned out of the posterior fossa. A strip of iodoform gauze was left for drainage. Uninterrupted recovery.

We might add that in all cases of head injury followed by compression symptoms, but in which there is no evidence of rupture of the middle meningeal artery nor any focal symptom, the suboccipital operation is preferable to the subtemporal. It will give easier and safer access and more efficient drainage.

TREPHINING THE FRONTAL REGION

A case reported by Axtell, of Bellingham, Wash. (Northwest Medicine, Nov., 1908), illustrates the procedure:

A laborer received a violent blow from a cable hook above the left eye. In spite of the severity of the injury, the man walked a mile to camp. Traveling by a logging train, by boat, and by street car, nine hours later he reached the hospital, showing no indication of collapse till he reached his destination. He had a marked depression over the left orbit, a swollen eyelid, and a protruding eyeball.

A semicircular incision extending from the bridge of the nose to the external angular process exposed the shattered supraorbital ridge. The orbital plate of the frontal bone was broken into fragments and a large blood clot was found filling the upper and back portion of the socket, forcing the eye onto the cheek.

Three lines of fracture extended from the supra-orbital ridge across the frontal, which was depressed in several places. The fragments of the orbital plate were removed; and, on removing the depressed portions of the frontal, the dura mater and subjacent portion of the brain were found mangled. The brain tissue was trimmed out, the dura adjusted, and the fragment of the supra-orbital ridge that remained attached to the pericranium was so turned and fastened that it covered the supra-orbital ridge that had been destroyed. This was retained in place by sutures passed through the skin flap which was drawn into place. The recovery was uninterrupted, and a year after there was nothing to indicate the injury but a puffiness of the upper lid.

Trephining for Gunshot Wounds.—Every case of gunshot wound of the skull must be explored; though, of course, no trephining is necessary unless there is perforation of the skull or unless there are evidences of gunshot fracture without perforation.

When it has been determined that there is perforation, raise a flap of the scalp with the bullet wound in the center, as has been already described. The flap must be larger than the possible trephine opening in the skull. Enlarge the opening in the skull with trephine, chisel and mallet, or with rongeur forceps. Remove all fragments of bone and foreign matter, wipe out the dural and cerebral wounds with sterile gauze. Be patient and persistent in this cleansing. Do not explore the bullet track or attempt to remove the bullet unless, of course, it is within easy reach. A case operated by the author illustrates the matter.

A countryman was shot in the top of the head with a 38 revolver by a circus employee, the outcome of a drunken brawl. He was carted home to die but after forty-eight hours he was still alive and surgical aid was called. He had never regained consciousness and he had the pulse and respiration of compression. His kitchen was converted into an operating room and the skull trephined. The bullet ranged from the center of the vault through the brain to the base. Through the ragged hole in the brain the bullet could be felt and was removed only to be followed by serious hemorrhage, controlled by packing with a long strip of iodoform gauze which was brought out through the bullet opening in the skin flap in the course of repair.

In an hour after the operation the patient was conscious, his pulse and respiration much improved. In a few hours, however, he grew restless, and his temperature and pulse rate began to rise and at the end of twenty-four hours he was in active delirium.

The gauze packing was removed followed almost immediately by improvement. There was only slight oozing from the wound which proceeded to repair without the least sign of infection.

The man's recovery was rapid and apparently complete, except that for some time he had slight disturbance of sight due possibly to some traumatism of the visual centers in the occipital lobes.

CHAPTER V

MASTOID ABSCESS

The tympanum, and likewise its accessory cavities, are normally sterile, but there are two highways by which infection may reach this site; the Eustachian tube, and the external auditory canal. The Eustachian canal is the much more common route, the infection first gaining a foothold in the mucous membrane of the naso-pharynx, so that an inflammation of the mucosa of the middle ear is often only a step further in the ordinary pharyngeal catarrhal process.

Finally, the *catarrhal* inflammation may become a *purulent* one, in either case, running an *acute* or *chronic* course. Again, the pyogenic germ may not long limit its operation to the tympanum; but eventually invades the pneumatic spaces adjacent, the antrum and mastoid cells; and then there may develop a mastoid abscess, a condition full of potential danger. The thin roof of the middle ear is the dividing line between the posterior and middle cerebral fossæ, and through it, infection may reach the cerebellum or the middle lobe of the cerebrum. Meningitis, epidural, cerebral, or cerebellar abscess is the immediate result.

The mastoid cells are separated from the lateral sinus by a bony partition, so that through the small venous channels or by necrosis of the bony wall, infection may reach the sinus. Finally, general infection and sinus thrombosis may ensue, followed perhaps by metastatic abscess.

These are the actual dangers of mastoid abscess and one can never tell how fast the pathological process may extend, aided by bone erosion or by the escape of the infectious matter through apertures in the bone or by way of the blood vessels and lymphatics.

Acute purulent mastoiditis, then, is an emergency, and every doctor should feel himself prepared to trephine the mastoid if it becomes his duty, and it is his duty if no one more skilled is at hand.

How shall one recognize this emergency?

The pain, sleeplessness, prostration, fever, together with the history of the case, point with a great degree of probability to the nature of the trouble. Now, if the examination adds certain other signs to these symptoms, the indications for intervention are definite:

(1) You find the upper and posterior quadrant of the ear drum (Shrapnell's membrane) bulging and perhaps the superior and posterior walls of the canal are swollen.

(2) You find persistent tenderness over the mastoid process.

(3) You may observe that a previously free discharge has suddenly diminished and this is an added warning that delay is dangerous.

To repeat, the cardinal symptoms are pain, redness, swelling, bulging of the drum, and fever. The first thing to do is a paracentesis.

PARACENTESIS

Douche the auditory canal gently with warm, sterile water; cocaineize the canal with a 10 per cent. solution and wait five or ten minutes. With the otoscope, expose the drum and locate the bulging area. Puncture it with a small pointed bistoury making an incision 3 or 4 mm. long, downward and forward.

There is nothing to fear. Even if the drum has spontaneously ruptured, it is often an advantage to enlarge the opening. Usually a few drops of pus escape. Follow with irrigation.

If, at the end of twenty-four hours, the symptoms have not subsided, proceed without further delay to trephine the mastoid.

OPERATION FOR MASTOID ABSCESS

The operation is easy and without much danger if one but knows the anatomy (Fig. 395). The sigmoid sinus is more shallow in children than adults. Recall the situation of the spine of Henle, the facial nerve, and the lateral sinus. The spine of Henle marks the upper limit of the external meatus; $\frac{1}{4}$ inch above it is the middle cerebral fossa; the mastoid antrum is $\frac{1}{2}$ inch posterior.

Shave the temporo-parietal region and scrupulously prepare the field. General anesthesia is indispensable.

Special instruments necessary are a Macewen seeker, a chisel (1

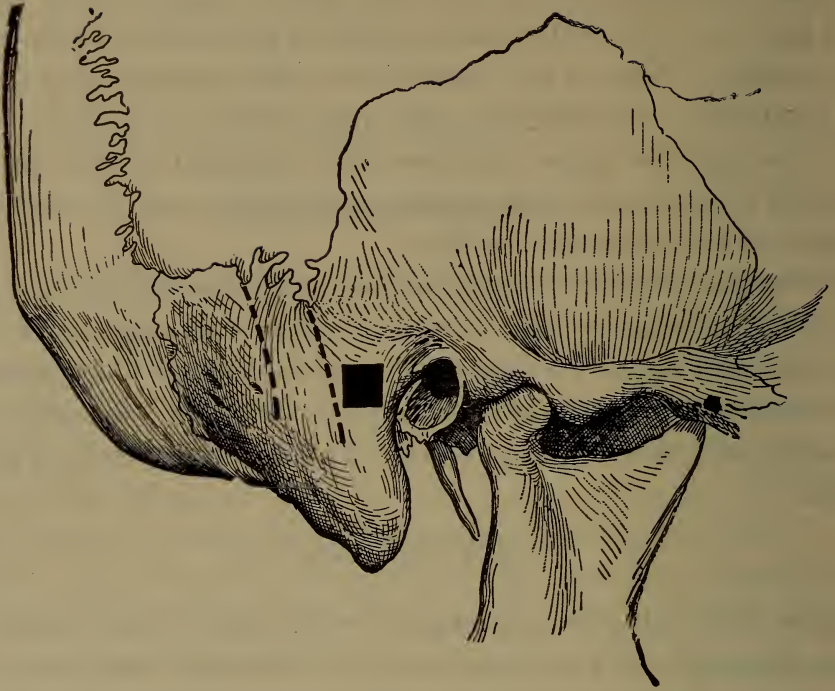

FIG. 391.—Landmarks of the mastoid. The square represents the area to be trephined; the dotted lines, the course of the lateral sinus. (*Veau.*)

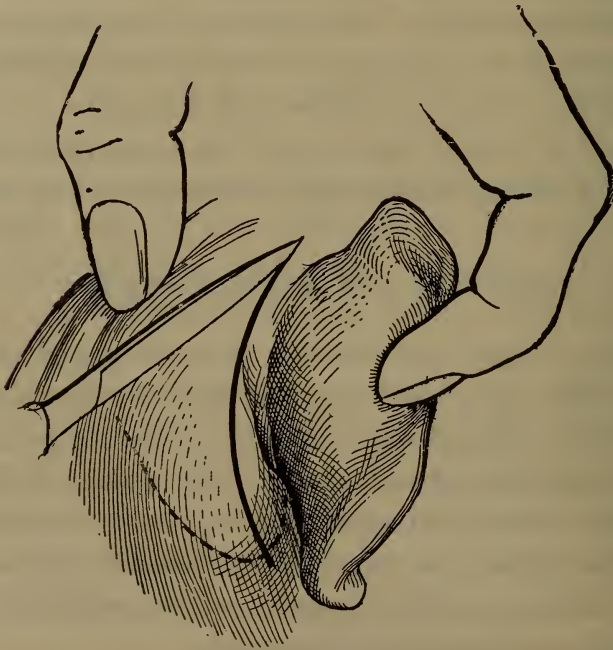

FIG. 392.—Incision for mastoid operation. (*Veau.*)

cm. wide), a small gouge, mallet, curette, curved periosteal elevator, and probe.

Incision (Fig. 392).—Begin at the apex of the mastoid and follow the curve of the external ear to the level of its attachment above. This incision reaches to the bone; and, when operating on children, be careful not to cut through the bone. Catch the bleeding vessels in the gaping wound. Rapidly denude the bone, an undertak-

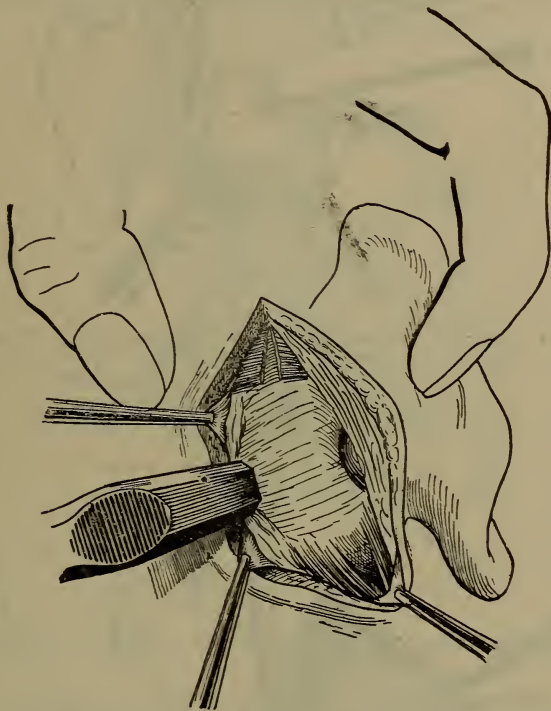


FIG. 393.—Denuding the mastoid with the rugine. (Veau.)

ing somewhat difficult below where the sterno-mastoid is attached (Fig. 393).

Introduce a sound into the external auditory canal to determine its direction. Expose the spine of Henle.

Trephine. Start the chisel *vertically* 5 mm. behind the meatus; two or three slight blows of the mallet will be sufficient. In a child, a bistoury may be used. Make the second trace with the chisel horizontal and on a level with the spine of Henle. The third is parallel with the second, and finally the fourth, parallel with the first, completes the outline of chip. This fourth line of section is

in the danger area, nearly over the lateral sinus. In making it, hold the chisel obliquely instead of vertically as in the first (Fig. 394). By slight and rapid blows, remove this chip.

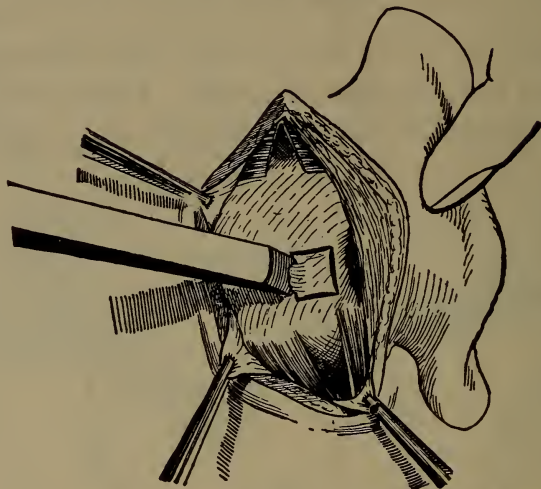


FIG. 394.—Outlining the chip to be removed. (*Veau.*)

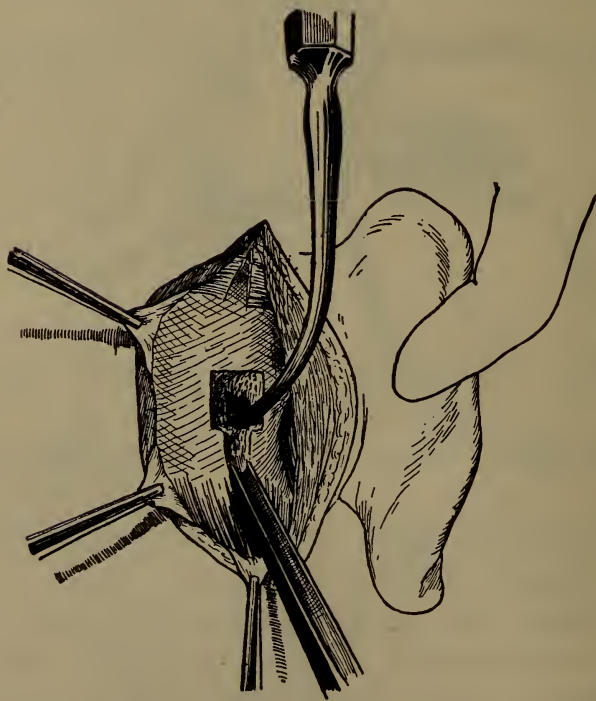


FIG. 395.—Exposing the lower mastoid cells. (*Veau.*)

If this does not expose the cells, deepen the opening carefully with the gouge. Pus will often be found at the first incision into the bony wall.

Introduce a seeker or blunt probe, which will locate the various cavities and canals leading to the cells of the mastoid and antrum. Their coverings are then chipped off, or they may be merely curetted.

Chisel below first (Fig. 395), and then, with the guide, locate the posterior limit of the cells and chisel off the bone lying over the point of the guide. A trough may be trephined downward toward the tip. Remember that posteriorly there is the lateral sinus (Fig. 396). Do not stop until all the cells are freely exposed.

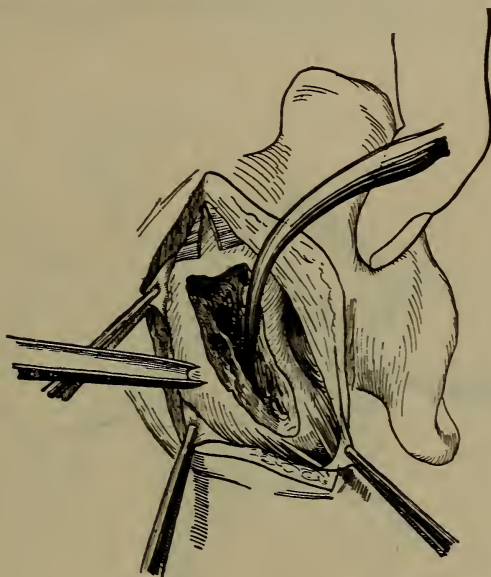


FIG. 396.—Exposing the posterior cells. The lateral sinus must be avoided. (Veau.)

When the mastoid cells are thus opened up, it remains to expose the antrum (Fig. 397). It lies in the direction upward and forward at what seems a considerable depth, 1 to 3 cm. Locate the cavity with the guide, and enlarge freely. The mastoid cells and the antrum are now a single cavity. Carefully curette the necrosed bone and fungosities, but be very careful when curetting over the posterior wall, for the lateral sinus may be exposed. Throughout the operation, one may be disturbed by the hemorrhage, always considerable, and it will be necessary to sponge continually, for it is indispensable that one see what he is doing.

Certain accidents may occur in the course of the operation.

(1) The *lateral sinus* may be wounded, immediately recognized by the excessive hemorrhage; but do not be perturbed, for it is easy

to arrest the bleeding. Pack the point or apply hot moist applications with sterile gauze and continue the operation. If you find thrombosis, it will be necessary to open the sinus.

(2) The *cranial cavity* may be opened, but neither is this particularly serious. However, you should avoid, if possible, an injury to the meninges, for there is danger of infection. Chisel discreetly, therefore, at the upper angle of the opening.

If you do wound the dura, disinfect and tampon, but do not attempt suture. It is scarcely possible at that depth in a cavity so narrow.

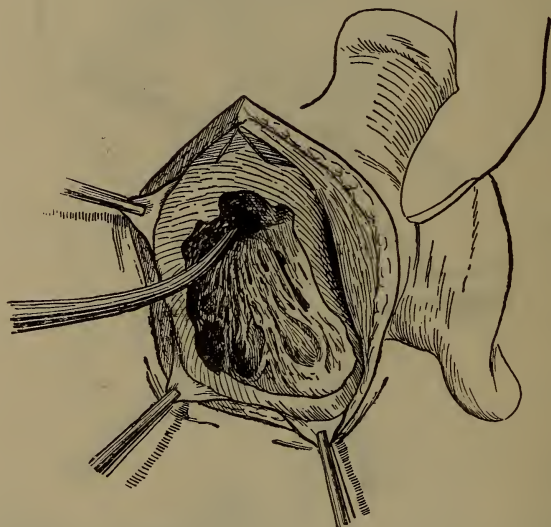


FIG. 397.—The operation completed, the guide is in the antrum. (Veau.)

The *facial nerve* may get in the way, and if wounded, that is indeed a serious matter, for you can do nothing to remedy it. It is deeply situated and if you follow the guide, you are scarcely likely to reach it with the gouge. It is almost certain to be injured if the mastoid is fractured in the course of the trephining, and this will happen if the mallet and chisel are recklessly used. Injury to the facial nerve is really the one danger of the operation. Close approach is indicated by twitching of the facial muscles, and for this the anesthetist should be instructed to watch while you are working in the nerve zone.

Dressing and Subsequent Treatment.—Partially suture the wound and pack with iodoform gauze. The dressings are as important as the operation. If neglected, a fistula may form or the suppuration may

recur. Instruct the patient that repair may require six to eight weeks, or longer.

On the second day after the operation, remove the gauze and irrigate with warm sterile water, dry carefully and repack methodically so that all the diverticula are filled. They must not be allowed to close over. Granulation from the bottom is indispensable.

Change the dressing every other day. Repress excessive granulation with tincture of iodine or nitrate of silver.

Keep the patient in bed for one week; keep the bowels open, and regulate the diet.

CHAPTER VI

GENERAL TECHNIC OF LAPAROTOMY

Since so many urgent conditions require a laparotomy, every doctor should be familiar with the general technic of the procedure without regard to any particular purpose for which the abdomen may be opened.

For the purpose of ready review, the various difficulties and their management and the after-treatment are briefly outlined.

Preparation of the Patient.—Whenever possible, the patient should be under a preliminary treatment for two or three days in order that the bowels may be thoroughly cleansed, the field of operation sterilized with certainty, and the functions of the organs noted. In emergency work, these details cannot, of course, be so definitely regulated, but to omit any of them is a handicap.

To have the bowels emptied by castor oil and enemata is the best prophylaxis against meteorism, which may be a source of embarrassment to the operator in the course of the operation, and a source of discomfort and perhaps danger to the patient subsequently.

However urgent the operation may be, the sterilization of the field must be definite, even though the methods be abbreviated. To scrub with soap and water, shave, wash with alcohol or ether to remove the oils, and finally bathe with bichloride solution and cover with bichloride compresses until ready to make the incision is to realize a practical asepsis so far as the skin is concerned; or the sterilization may be even more rapidly accomplished by washing the skin with alcohol and ether, shaving and drying; and then painting with tincture of iodine.

To have a definite knowledge of the patient's temperament, of the action of his circulation and respiratory organs and of his kidneys is to forestall many difficulties and dangers. At least, a full stomach should be washed out, and the bladder emptied before the operation is

begun. After the skin is prepared and before the incision is made, the field is covered with sterile towels and the whole body with a sterile sheet, split over the site of the proposed incision. Small towel clamps may be used in fastening the towels to the skin.

Incision.—The operator may stand on either side. It is preferable to stand to the patient's right and cut from above toward the pubes, supposing a median laparotomy.

The *skin* and *subcutaneous fatty* tissues are divided first. Clamp the small vessels and gently sponge. In the case of abscess and chronic inflammation, the bleeding is likely to be rather free but never dangerous.

The *aponeurosis*, when possible, should be divided in the linea alba, because the bleeding will be less and the access to the peritoneum readier. If made on either side of the middle line, the incision opens into the sheath of the rectus, whose inner border should be displaced to the outer side or its fibers split. The edges of this fascia should be caught with forceps in order to be more readily recognized in the course of repair.

The *peritoneum* is now exposed, covered usually by fatty areolar tissue, more or less thick and which may confuse the novice, but it is to be cut through without fear until the peritoneum itself appears. Catch up a fold of it between two forceps and make a small opening with either knife or scissors, using caution not to cut into the bowel or omentum.

The lips of the peritoneal wound are controlled with forceps which are to be left attached; and now enlarge the opening in either direction, using the finger as a guide and as a protection to the bowel. Approaching the pubes, guard against wounding the bladder, of which there is no danger if it has been previously emptied. In any event, it can be readily located by the sense of touch.

Protect the Cut Surfaces.—When the peritoneum is opened to the necessary extent, apply two wide compresses of gauze, so as to completely cover the incisions and attached forceps, tucking the edge of each compress under either side of the peritoneum. This is to diminish the chances of infection and to prevent bruising the peritoneum.

In like manner, and for the same purpose, the parts that are to be

dealt with are packed off from adjacent structures with large compresses which are not only more efficient than small ones, but also are less likely to be lost within the peritoneal cavity. The surgeon or a responsible assistant must always know how many compresses are brought into use, and they must be accounted for before the cavity is closed. It is remarkable how easily a large compress may be lost to sight in the abdominal cavity. It is an added precaution to have a tape sewed to each compress, to which a forceps is applied after the compress is placed.

The aim is completely to isolate the part operated on, and once this packing is complete the compresses are not to be removed until the operation is finished. If infection is present it is well to have two or three layers of compresses so that the soiled ones may be removed without the bowel being allowed to project into the field. In pelvic operations the Trendelenburg position is of great advantage, permitting the bowel the more readily to be displaced and packed off.

Management of Peritoneal Adhesions.—The novice and even the most practised surgeon may experience the greatest difficulty in separating adherent organs, their peritoneal surfaces glued together as the result of inflammation.

In the case of recent adhesions, they are soft and easily broken. In other cases, they consist of bands which need only be divided with scissors; but finally they may bind together large areas of adjacent structures so as often to render them indistinguishable.

Even here with a little patience one may often find a plane of cleavage, especially if the parietal peritoneum is involved. If the organ cannot be separated from the parietal peritoneum, a segment of this latter is to be cut out and left attached to the viscus concerned. In the case of the omentum it is to be ligated twice and cut between. In the case of the intestine, the greatest care must be used not to break through its wall.

In general, intestinal adhesions discovered in the course of operation are not to be broken up except as they interfere with the work in hand or are likely to obstruct the bowel.

If no plane of cleavage can be found, then the other organ involved must be deprived of its peritoneal coat to protect the gut. If the surface of the intestinal loop is left raw after the separation, the Lembert

suture should be employed. If the bowel wall is torn through, it must be repaired by two rows of suture, a through-and-through and a Lembert suture.

Hemorrhage.—The visceral blood supply is complex; to have its anatomy clearly in mind is a great advantage in the case of hemorrhage from larger vessels. To locate the vessel at fault, to clamp it and ligate quickly, speeds the operation. Capillary oozing can generally be controlled by a few moments' application of hot compresses. A compress wet with alcohol will often promptly check free bleeding. If the oozing is persistent at the end of the operation and measures applied have failed to check it, the abdomen must not be closed without drainage.

To insure against recurrence of hemorrhage as well as to prevent infection and adhesions, all raw surfaces should be covered over with a peritoneal coat. It is never desirable and seldom necessary to leave a denuded area in the peritoneal cavity. Use of the Lembert suture and of the free omentum enables one to obliterate them. Such as must be left should be sprinkled with aristol.

Drainage.—The old dictum, "When in doubt, drain," does not apply with such force to laparotomy as formerly. In fact, there are those bold enough to say, "When in doubt do not drain." Still it must be admitted that, in spite of drawbacks, drainage is a real safeguard against infection. One should drain, then, when any septic process is present or is likely to develop, as in the case of perforating wounds of the intestine.

Drainage must be employed whenever it is impossible to control bleeding from raw surfaces. If there is no infective process present in the peritoneal cavity, if there is no obvious reason for any to develop later, the abdomen is to be closed completely.

The preferable method of draining the abdominal cavity is by *rubber tubes*. This is the only method available if pus is present. If the main object is to get rid of blood, then the tube should contain a wick of gauze which should rest upon the oozing surface that it may serve the double purpose of hemostasis and drainage.

As soon as the oozing has ceased the gauze wick is to be withdrawn and usually it is ineffective after twenty-four hours. The removal of gauze drains is often difficult and the traction must be gentle.

The tubal drains are to be removed as soon as the danger of sepsis is passed, which is usually after the third day. If at this time infection has developed the tube is withdrawn, sterilized, and replaced and so on daily thereafter until the suppuration is under control. It is in these cases that Balsam Peru is of service in checking the pus formation.

Repair of the Abdominal Wall.—Suppose the operation complete. The final inspection of ligatures and sutures is made, the cavity is

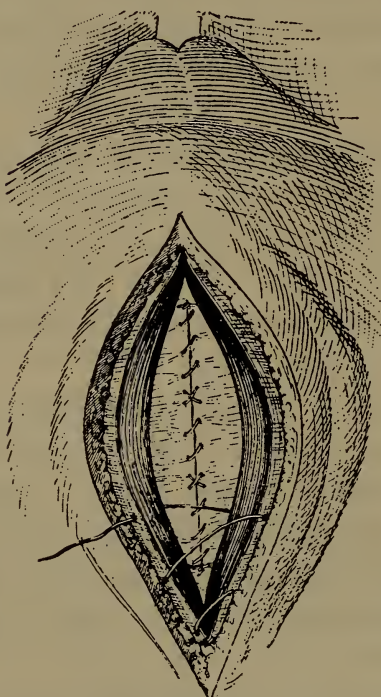


FIG. 398.—Repair of the abdominal wall. Peritoneum sutured. Continuous suture of recti and fascia begun. (*Guibe.*)

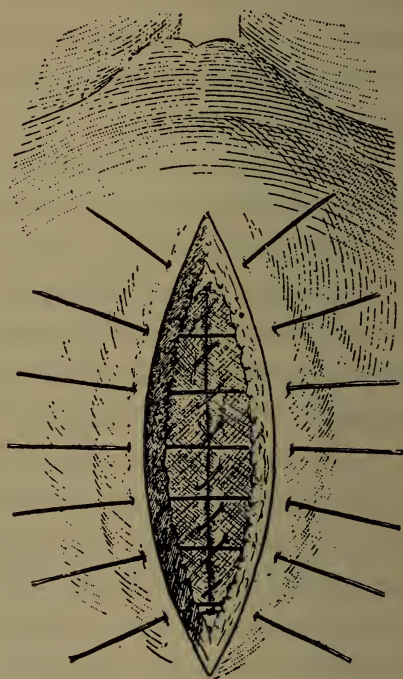


FIG. 399.—Fascia repaired. Interrupted skin sutures placed, ready to tie.

wiped out, the compresses are removed and counted, the vessels in the abdominal wall that were clamped are ligated, if necessary, and repair of the abdominal wall is begun.

The peritoneum, to which the forceps still remain attached, is pulled up into view. If the Trendelenburg position has been used, the table is now brought to the horizontal; the intestines are brought back into place, the omentum spread out over them, and a compress applied to protect the bowel while the *peritoneum* is repaired with a

continuous No. 1 catgut suture. The compress is withdrawn before the last two or three stitches are passed.

The *aponeurosis* and *muscles* are now repaired with *continuous chromic gut suture* (Fig. 398).

The *skin*, finally, is to be repaired with *interrupted silkworm-gut sutures*, passing some of them deep enough to include the muscles and aponeurosis so as to obliterate any dead spaces. If coaptation is not perfect, a few superficial catgut sutures may be used as necessary. One may close the skin simply by the continuous catgut or chromic gut suture or, as many prefer, by the subcuticular stitch (Fig. 399).

Of course, if drainage has been employed, the closure cannot be complete, though the suturing is to be carried close up to the tube. In case great haste is required, the abdomen may be closed by through-and-through sutures of silkworm-gut.

After-treatment.—In the uncomplicated case, the after-treatment is simple. The patient is put to bed with hot-water bottles at his feet and provision made for proper ventilation. Fresh air is of the utmost importance. As he recovers from the anesthetic, he is given water cautiously for the first twenty-four hours. After that, liquid nourishment should be given in small quantities at frequent intervals. The bowels should be moved on the second day by a light soapsuds enema.

It is rare, however, that these patients do not have some complication. If there was much *shock* or much *hemorrhage*, or if the anesthesia was prolonged, give normal solution by one of the three methods, hot coffee by the rectum and whatever cardiac stimulant may seem indicated, strychnia, brandy, or camphorated oil.

If the *pain* is severe, small doses of morphine hypodermically should be given until the patient is comfortable.

If there is much *nausea*, try a glass of warm soda-water which will probably be thrown up, and thus washes out the stomach. If the nausea is quite severe, wash out the stomach and put the patient in a half-sitting position. If the thirst is extreme along with vomiting, enemas of normal salt solution give the most relief.

Sometimes 5–15 minims of aromatic spirits of ammonia, given hypodermically, tend to relieve the nausea, while acting as a diffusible stimulant.

If there is much *flatulence* or *meteorism*, give minute doses of calomel and empty the bowel with soapsuds enema. If this does not give relief, the enema consisting of 2 ounces of Epsom salts and glycerin and 1 ounce of turpentine may be employed.

Acute dilatation of the *stomach* must be watched for. If discovered at once and properly treated it is not a serious complication. Otherwise it may be a large factor in determining a fatality.

Gastric lavage with alkaline solutions, followed by small doses of calomel, usually speedily controls this complication.

A special line of treatment is required if *post-operative ileus* develops (see page 586).

CHAPTER VII

LAPAROTOMY FOR TRAUMATISM

The *indications* for *laparotomy* following traumatism are as follows:

1. Perforating gunshot wounds.
2. Perforating stab wounds likely to have wounded a viscus.
3. Contusions of the abdomen presenting symptoms of dangerous lesions of abdominal viscera or vessels; not always definite, but operate at once if you find these appearances following contusions:
 - (a) The *abdominal walls* are resistant some distance from the injury; a progressive meteorism reaching the hepatic region; dullness over the iliac fossæ or the flanks, indicating hemorrhage.
 - (b) The *pulse* is weak and rapid, and growing worse.
 - (c) The *general condition* of the patient is alarming, pallor, pain, excitement or delirium, subnormal temperature.

But whether it be an open wound or a contusion, do not wait for the symptoms of peritonitis, for it will then likely be too late. The operation is delicate and dangerous in the hands of the unskilled, and yet the patient's life depends upon it. There is no time to send for a specialist unless he is right at hand, and, as Veau says, it is better for the patient to be operated on early by an inexperienced surgeon than to be operated on too late by the best surgeon in the land. It is an intervention in which one never knows what he is going to find.

The *steps of the operation* are:

- (1) A *laparotomy*.
- (2) Search for the *hemorrhage* if there is blood in the abdomen.
- (3) Search for *visceral injuries*.

General anesthesia is indispensable, and ether is preferable unless compelled to operate in close quarters by lamp light. Every precaution must be taken not to aggravate shock; the limbs should be wrapped and the chest protected. The whole anterior abdominal

wall must be sterilized. Be prepared for normal salt injections, often necessary throughout the operation.

(1) *Laparotomy.* Whatever be the site of the wound or contusion, make an incision in the middle line; below the umbilicus, usually; above, if the injury points to the epigastrium. The incision at first should be about 3 inches long. It will be necessary to extend it if the preliminary examination reveals visceral injuries. Divide the skin and fatty tissues and catch up the bleeding vessels. Look

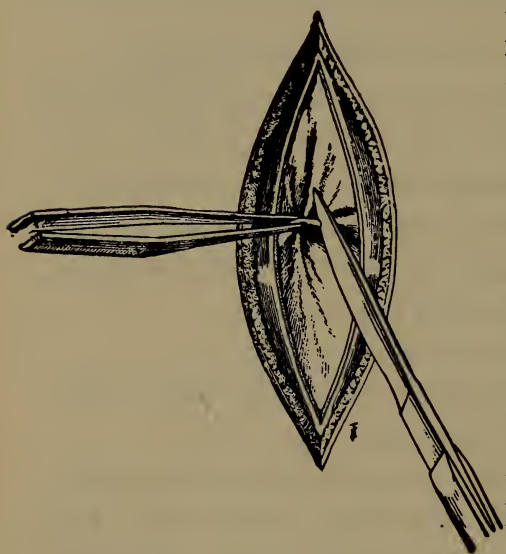


FIG. 400.—Incising the fold of peritoneum. (*Guibe.*)

for the linea alba, but if not readily found, go through the muscle; it does not greatly matter. Divide the transversalis fascia and expose the subperitoneal fatty tissue. It may be quite thick.

The peritoneum will probably not be recognized by its appearance, but rather by observing the tissues gone through. It is usually bulging. One may be able to see free blood in the cavity by reason of its transparency.

Catch up the peritoneum with dissecting forceps and incise the cone thus formed, with the cutting-edge of the scalpel turned away from the abdominal cavity, that the bowel may not be wounded (Fig. 400). Enlarge the small opening thus created, and direct the assistant to seize the lips of the peritoneal wound with forceps.

Pay no attention to the blood which may pour out, but proceed rapidly to elongate the peritoneal wound with the scissors, protecting the bowel with the left index finger (Fig. 401). Remember the peritoneum envelops the bladder, so do not open the peritoneum down to the pubes, although the skin wound should be carried thus far in order to give the best view (Fig. 402).

Carefully catch up the lips of the peritoneal wound with forceps which may also serve as retractors; such control of the peritoneum will also facilitate its suturing at the end of the operation. It may

now be necessary to push the anesthesia a little if there is much resistance.

(2) *Locate and check the hemorrhage.* Do not be in a hurry to put a hand in the cavity but observe closely, sponging gently. The character of the fluids may be helpful in diagnosis. The examining

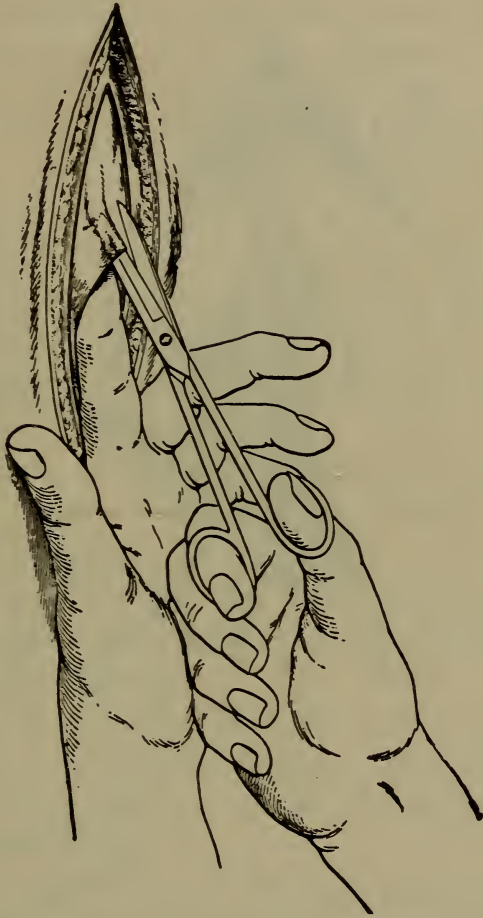

FIG. 401.—Enlarging the peritoneal opening with the scissors on the index finger to guide. (*Guibe.*)

finger may detect lesions, or the injured viscera may push up into the wound.

The hemorrhage may come from the following: (a) omentum; (b) mesentery; (c) the vascular organs, liver, spleen, kidney; (d) the vessels of the posterior abdominal wall.

(a) The great omentum should be gently lifted out of the cavity.

It may contain a hematoma and the divided vessels be hard to find. Tie them with No. 2 catgut. If the omentum is torn and lacerated, resect the injured portion (Fig. 410). It may be split; the large vessels opened must be tied; the small will be controlled by the continuous suture, which should reunite the edges of the wound. If the

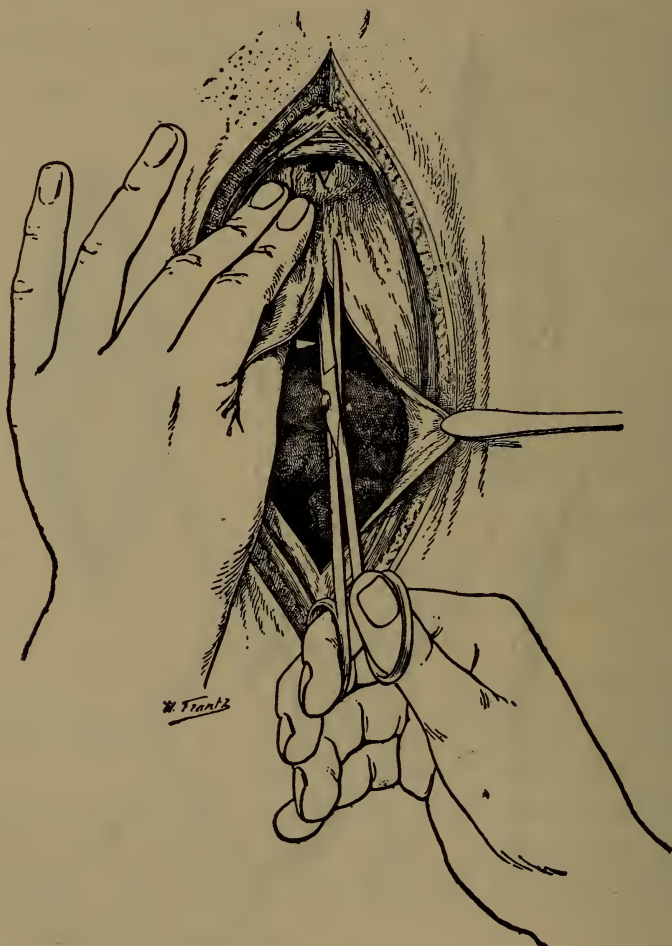


FIG. 402.—Enlarging the opening toward the pubes, the bladder must not be wounded. (*Guibe.*)

omentum is detached from the greater curvature, the stomach should be exposed, and the omentum sutured thereto.

(b) The hemorrhage from the mesentery may be arrested in the same manner, though one may not find it until in the course of inspecting the gut. Mesenteric wounds often exist without visceral injury. In suturing the tear, the needle must be passed close to the

edges of the wound so that no vessel may be wounded or included in the tie.

If its attachment to the bowel is disturbed for, say, more than 3 inches or if it is necessary to tie a branch as large as the radial, the integrity of the corresponding section of gut is compromised and it will be advisable to resect. If unable to do that, treat it as the doubtful bowel is treated in strangulated hernia (see page 609).

(c) If the hemorrhage proceeds from a wound of the *liver*, *spleen*, or *kidney*, tampon methodically and firmly with sterile gauze.

If the liver is ruptured extensively and tamponade has no effect, try deep suturing. If this does not succeed, the wound is probably beyond surgical aid.

If the spleen is extensively lacerated, remove it (see page 549).

(d) If the *vessels* of the *posterior abdominal* wall are involved or the splenic, mesenteric, or renal, it will often be very difficult to find the starting-point¹⁹ of the hemorrhage, for it is in the midst of a great clot. Begin by applying a large compress to the suspected point and make firm pressure. Following this, rapidly wipe out all the clots and reapply the compress. Raise its edge gradually and as each bleeding point appears, clamp it. It will often be impossible to ligate at that depth and forceps are left attached. The forceps are to remain twenty-four to thirty-six hours. These must be removed without violence.

(3) *Wounds of the Intestine*: Do not forget that intestinal perforations are often multiple, are usually so after gunshot wounds, so that it is absolutely necessary to inspect the whole intestine that no wound may be overlooked.

(A) *Examination of the Bowel*.—The procedure must be *methodical*. Do not pick up first one segment and then another indiscriminately; in this way one part may be examined several times and another part not at all.

Begin by picking up with forceps any part of the bowel that may present; these forceps will serve as a starting-point and landmark. It will not hurt the bowel with its pressure, as it includes in its hold only the serous and muscular coats (Fig. 403).

Begin at this point, then, pulling up to view segment after segment, and as it is inspected, return it to the cavity. The ma-

neuver may be attended with difficulty especially if one is compelled to operate late, when peritonitis has begun and the partially paralyzed bowel is greatly distended. If several folds of the bowel should escape and there is difficulty in returning them, the procedure as described on page 131 will be helpful.

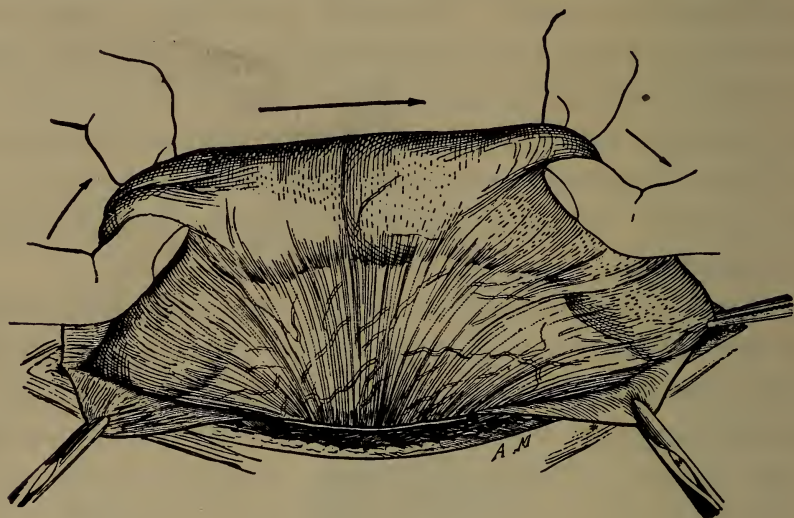


FIG. 403.—Examining the bowel. (Veau.)

Begin by lifting up the abdominal wall by means of the retractors. Cover the refractory mass with a wide compress and then tuck each border of the compress into the wound, gradually working it into the abdominal cavity. It will carry the bowel along. Then carefully withdraw the compress.

Examining thus the small intestine, one of its fixed points will finally be reached, either the cecum or the duodenum; return then to the forceps and work in the other direction.¹

¹ In the case of gunshot wounds penetrating the abdomen from behind, the difficulties in locating the injuries may be greatly increased, a fact illustrated by the following case:

A colored man was brought to the City Hospital with a gunshot wound in the back, the bullet entering the right lumbar region about 2 inches from the middle line. Progressive abdominal distention and tenderness with symptoms of hemorrhage pointed to a visceral injury. He was immediately operated upon; the abdomen was opened below the umbilicus. The pelvis contained considerable blood, but there was not the quantity expected. A systematic examination of the intestine from the cecum to the duodeno-jejunal juncture revealed no per-

Whenever a perforation is found, it must be repaired before looking further.

(B) *Repair of the Intestinal Wound*.—When an intestinal wound is located, seize its edges with two forceps, including only the serous and muscular coats, draw the part outside the cavity and isolate it with compresses and then suture.

(a) *Non-perforating wounds* are sufficiently repaired by two or three Lembert sutures.

(b) *Small perforating wounds*, such as bullet wounds, must be

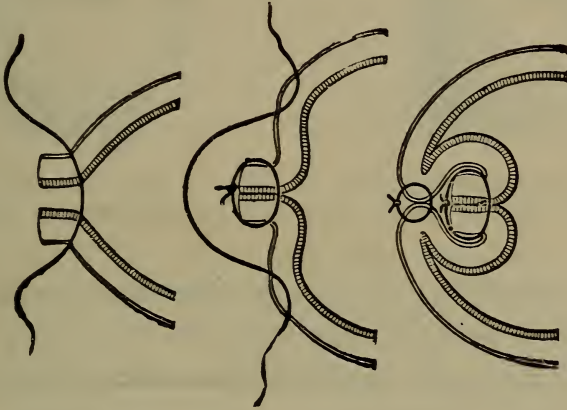


FIG. 404.—The inclusive suture passed; tied and Lembert suture passed; Lembert tied.

repaired by suture in two layers (Fig. 404). With fine silk, No 1, make a suture which includes all three coats, serous, muscular and mucous (Fig. 405). If the wound is longer than two-thirds of an inch use two such sutures, etc. These sutures are to be covered in and buried by the second layer, which involves only the serous coat (Lembert suture). In introducing them, begin at least $\frac{1}{2}$ inch

foration. No opening in the posterior abdominal wall could be found below the level of the umbilicus. The incision was extended and the examining finger located a tear behind the stomach. At this time the patient's condition grew so bad it was necessary to cease the search and before the abdomen could be completely closed, he died.

The post-mortem revealed a long tear in the transverse portion of the duodenum. The bullet had struck the transverse process of a lumbar vertebra, had deflected to the left, wounding the ascending vena cava and the duodenum, and had lodged in the anterior abdominal wall. The blood escaping from the vena cava had not emptied into the abdomen, but had followed the vein along the spine and had flooded the posterior mediastinum.

back of the first line and use either a continuous or interrupted suture (Fig. 406).

(c) *Large Perforating Wounds*.—If the wound is an incised one,

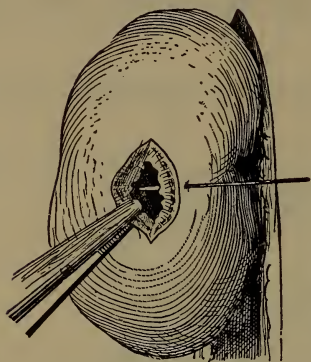


FIG. 406.—The first layer of sutures include all coats. (Veau.)

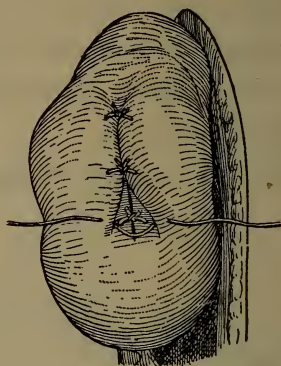


FIG. 407.—Applying sero-serous (Lembert) sutures. (Veau.)

suture without refreshing the edges, but if it is contused or lacerated (Fig. 408) it will be necessary for repair to trim away to the sound tissue; but take care not to diminish the caliber of the gut.



FIG. 408.—Trimming away the bruised tissue. (Veau.)

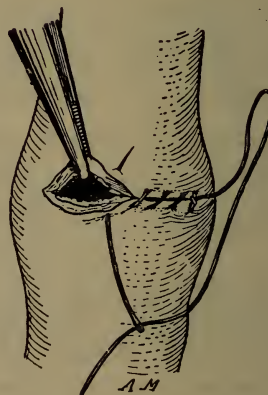


FIG. 409.—Transverse suture to prevent narrowing of the bowel. (Veau.)

As before, beginning at one angle, introduce the first line of the suture, including all the coats, and using, if possible, a continuous suture (Fig. 409).

The second line of (Lembert or sero-serous) sutures must begin and end $\frac{1}{2}$ inch beyond the limits of the first and the needle must be entered far enough away from the first line that the peritoneal surfaces may be well apposed and the first layer completely covered (Fig. 410).

(C) *Resection of the Gut*.—If the wound involves more than two-thirds of the circumference or if there is a contusion of the whole or a large part of the segment, it will be necessary to resect and do a circular enterorrhaphy or some other form of anastomosis. If the operator cannot undertake that, then the gut must be treated as in the gangrene of strangulated hernia, making an artificial anus (see page 651). For resection of gut, see page 609.

Drain the peritoneal cavity with a Miculicz drain where there is oozing, and with a drainage-tube if infection is feared (see Chapter V on Drainage).

Close the abdominal wall by three tiers of suture; the peritoneum with a continuous suture of catgut, the muscles with chromicized catgut, and the skin with silkworm-gut. Apply a dry dressing.

Subsequent Care.—Order complete rest and absence of food for forty-eight hours, not even excepting milk. To quench the thirst, let the patient suck a cloth saturated with water. It will nearly always be expedient to give salt solution either by rectum or subcutaneously; in the worst cases by intravenous infusion.

Change the dressing the following day. It will probably be saturated with bloody serum. On the second day remove the tampons and replace with smaller ones. On the fourth day remove the drainage-tube, if employed, and replace with smaller one, which may be dispensed with after the eighth day.

Prognosis.—The prognosis will depend upon the extent of the injuries and the skill of the operator.

Death may occur from *hemorrhage* or *peritonitis* shortly after the operation, or about the eighth or tenth day if the suturing has been imperfectly done.

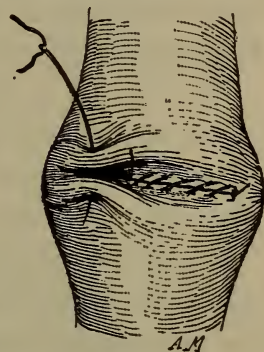


FIG. 410.—Applying Lembert sutures. (Veau.)

Fecal abscess and fecal fistula may result, requiring a later operation, or which may eventually cure themselves.

Complete recovery happily very often occurs and would be the rule if the doctor had the judgment or authority to operate within the first few hours after the traumatism.

WOUNDS OF THE STOMACH

If the injury involves the upper pole of the abdomen, the stomach must be examined carefully. Extensive injuries are often overlooked. An escape of gas and bleeding may point to the situation of the lesion.

Pick up the stomach with gauze to get a firmer hold, and examine the anterior surface systematically. Repair any wounds, as in the intestine, by two rows of suture; the one including all the coats, the other only the serous and muscular.

In the case of gunshot wounds, examine the posterior surface. To reach the posterior surface, Auvray insists upon a large incision in the gastro-colic omentum along the lower border of the stomach, for a large incision facilitates examination and does not compromise the vitality of any structure. If even then one cannot gain full access, he advises an exploratory gastrotomy (*Revue de Chirurgie*, Nov. 10, 1906).

The posterior surface may be reached another way, by turning up the transverse colon and opening the transverse meso-colon. To prevent the spread of fluids which may escape from the stomach the field must be carefully walled off with compresses as the exploration proceeds. If the wound can be felt but is impossible to be seen, then no attempt must be made to suture, but the cavity is to be thoroughly drained.

If there has been much loss of substance, it may be necessary to do a gastro-enterostomy.

WOUNDS OF THE LIVER

If the nature of the abdominal injury leaves no doubt that the liver is wounded, it may be advisable to vary the procedure as already described. A support under the back tilts the abdomen so that the intestine drops down toward the pelvic cavity, and at the same time the liver is bulged forward and made more accessible.

The incision beginning at the ensiform cartilage may follow the costal arch, dividing, if necessary, the right rectus muscle. It may even be necessary, in order to reach the upper surface of the liver, to resect the tenth, ninth, or eighth rib.

You may find on examination of the viscera that the liver has been

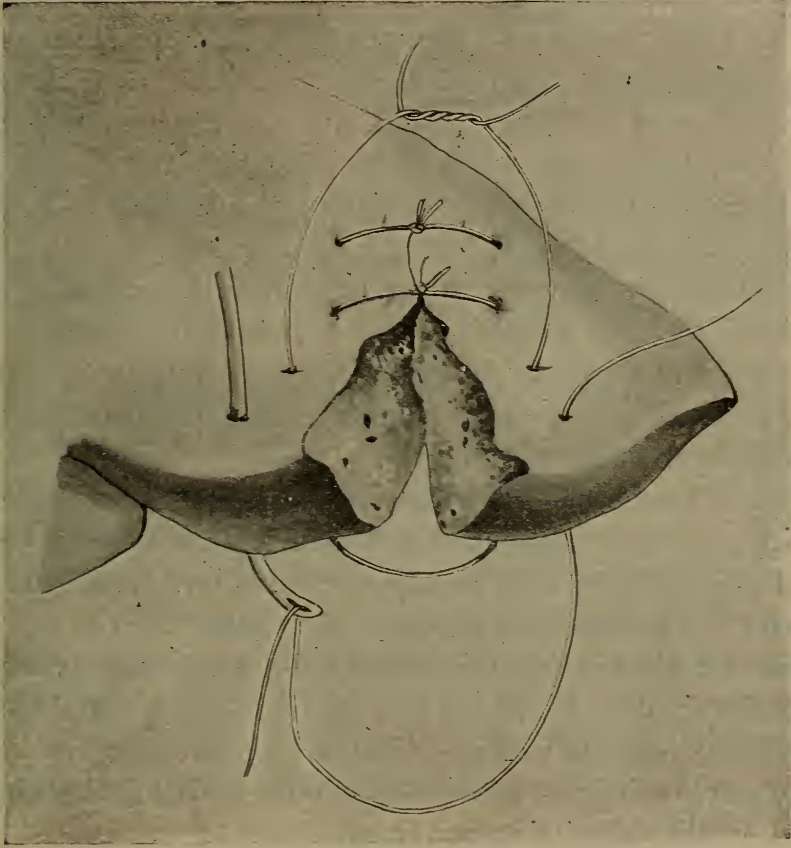


FIG. 411.—Suture of the liver. (Moynihan.)

contused, and there is evidently a hematoma formed beneath the capsule. It is better not to disturb it unless the conditions seem to indicate continuation of oozing.

There may be an *open wound* of any character or extent with great hemorrhage. One should attempt to catch up and *ligate* the bleeding points, employing a fine clip or artery forceps. The veins, as well as the arteries, will stand the strain of a ligature, but may need to be

dissected loose from the liver substance before the ligature can be applied.

If the patient is not too weak, attempt repair by suture. It is a little difficult, but quite possible and certainly desirable.

Employ a blunt-pointed needle and do not push it through boldly, but slowly, and as you push, gently oscillate the needle. In this manner, the point may slip by the vessels. Employ a large catgut suture, as a fine suture cuts through the soft tissue (Fig. 411).

Van Burén Knott (Iowa Med. Journal, Oct., 1907) recommends inserting a strand of catgut parallel with the liver wound, tying the ends of the strand over small skeins of catgut to prevent tearing. Transverse interrupted sutures are then passed so as to include the parallel sutures first passed.

Failing to suture, there is nothing left but the tamponade, and this, of course, is the only thing available in lacerated wounds.

Haynes, of New York (Annals of Surgery, July, 1907), describes a case illustrative of some of the difficulties of treatment and the sequelæ of liver wounds.

Patient, a man of twenty years, was brought to the Harlem Hospital with gunshot wound just below the tip of the ensiform cartilage. The bullet was found to have traversed the liver from before backward, and it was necessary to get at the wound of exit.

From the median incision, a second incision was made transversely, dividing the right rectus and the seventh and sixth costal cartilages. The falciform ligament was also divided. With strong traction upon the costal arch, the posterior wound could be reached and felt but not seen, readily admitting two fingers.

By the sense of touch, an iodoform wick was packed into this wound and a smaller one introduced into the anterior wound, and both brought out through the abdominal incision. This did not entirely control the hemorrhage, and so the liver was forced up against the diaphragm and held by a large Miculicz tampon below the liver.

The rectus was sutured. The peritoneum was repaired with the falciform ligament included; the abdominal walls sutured above and below the gauze wicks.

On the tenth day the tamponade was removed; and a few days

later, the gauze wicks, for which rubber tubes were substituted, a discharge of bile and pus being present.

At the end of the third week it became necessary to secure additional drainage, and the ninth rib was resected in the axillary line, where, in the meantime, the bullet had been located; the costal and phrenic pleura were sutured, and the pleural cavity thus shut off. The diaphragm was opened, the pus drained out and a long tube passed from the anterior to the posterior abdominal wounds, and a smaller one left in the posterior wound.

The progress of repair was slow but sure, five months elapsing before the cure was complete.

It should be remarked that very rarely after gunshot wounds of the liver is there notable external hemorrhage. One must determine the degree of injury from the signs of internal hemorrhage and the evidences of peritoneal reaction which later develop.

WOUNDS OF THE PANCREAS

Do not forget to examine the pancreas in wounds of the upper zone of the abdomen. Reach the pancreas from above the stomach, opening through the gastro-hepatic omentum.

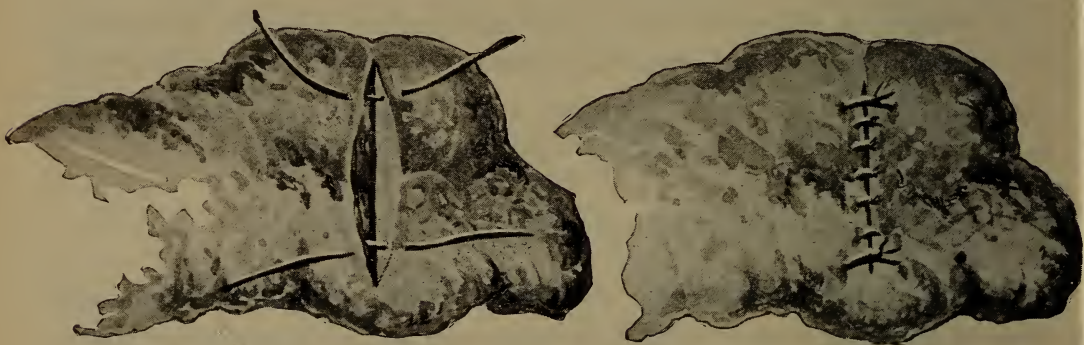Carefully mop out the fluids, blood and pancreatic juice. Pack around the site with compresses and try to *suture*. Sometimes two or three deep sutures will coapt the wound surface and completely check the hemorrhage. If the tail is much crushed, resect it and suture the stump. Use gauze and tubal drainage. If the patient does not die, he may have a subphrenic abscess (Figs. 412, 413).

WOUNDS OF THE SPLEEN

Any but the slightest wound of the spleen is universally and rapidly fatal from hemorrhage unless treated. One naturally thinks of suturing. If that and tamponade are not effective to stop the bleeding, it is indicated to try to remove the viscus. This is not difficult if there are no adhesions, though, if there are, failure is almost certain. Under such circumstances, as Moynihan suggests, the only thing left is to pack with gauze, soaked, if necessary, in adrenalin solution.

Noetzel reviews his experience with six cases in which he removed the spleen for injury and concludes that splenectomy is the only safe way of securing hemostasis. Suturing and tamponing may arrest bleeding for a time, but there is danger that it will return.

Holliday, of Portsmouth, Virginia, reports a case illustrating the subject (Virginia Medical Semi-monthly Journal, January 11, 1907); patient, boy, age 15, was struck in left side by a flying pulley, fracturing his arm in several places and contusing the abdominal wall. His condition shortly became serious; temperature subnormal, absolute dullness on the left side, and marked rigidity. Immediate



FIGS. 412 and 413.—Method of suture of a wound in the pancreas. Two or three deep sutures of stout catgut or silk are passed, and wound-surfaces drawn together. The wound-edges are then sutured with fine catgut sutures. (*Moynihan.*)

operation. The patient was almost eviscerated before the bleeding could be located, but which was finally found to proceed from the lacerated external surface of the spleen; a splenectomy was quickly done, and the abdomen closed without drainage. Convalescence was easy and uneventful.

Splenectomy.—The operation following rupture generally finds the incision made in the middle line on account of the indications for hemorrhage.

The spleen is brought up into view and delivered from the abdominal cavity and clamped, avoiding any strain upon its pedicle, for the veins have extremely thin walls (Fig. 414).

Ligate and divide the pedicle. Transfix the pedicle with a double ligature and tie each half separately, and finally tie the whole pedicle in a single ligature. If the ligament is large and thick it may be

necessary to ligate it "enchaine" (Fig. 415). The pedicle is next divided, the spleen removed, and its bed examined for any bleeding points. The under surface of the diaphragm is very likely to present some oozing.

Fiske, of Brooklyn, describes a case which illustrates the variations in the procedure. (Annals of Surgery, Jan., 1908.)

A man of twenty-five years was brought to the Kings County Hospital with a bullet wound in the left side corresponding to the

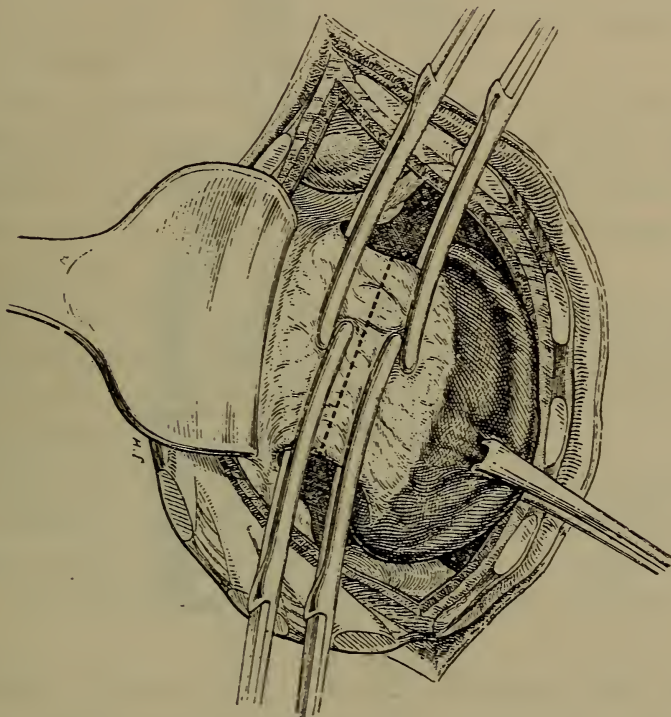


FIG. 414.—Splenectomy: Clamps applied to pedicle preliminary to section along dotted line. (Guibe.)

spleen. The symptoms pointed to visceral injury and intra-abdominal hemorrhage. An incision was made over the outer border of the left rectus muscle from the costal arch to a point midway between the umbilicus and symphysis. The stomach and intestine were found to be uninjured. A perforation in the transverse meso-colon was repaired, but the hemorrhage continued. A transverse incision was made and the spleen examined, revealing a rent which admitted two fingers. The spleen was pulled up into the wound, the pedicle

clamped and ligated *en masse*. After removing the spleen, the vessels were ligated separately, the abdomen was flushed with saline solution, a small gauze drain left in contact with the stump, and the wound closed with through-and-through silkworm-gut sutures. The temperature subsequently did not rise above 100° . The drain was permanently removed on the fifth day. The patient left the hospital at the end of the third week, entirely recovered.

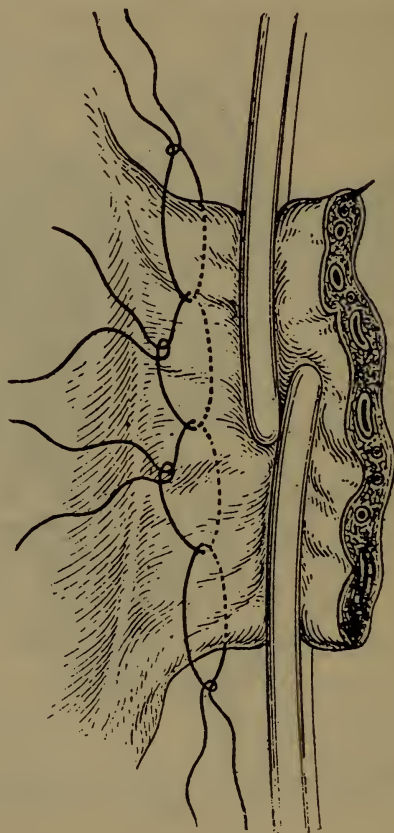


FIG. 415.—Pedicle of spleen ligated "enchaine". (Guibe.)

WOUNDS OF THE KIDNEY

If, while examining the viscera in the course of the laparotomy, you find a ruptured renal pelvis or a seriously lacerated kidney bleeding into the peritoneal cavity, remove the kidney. Make a longitudinal incision in its peritoneal covering, strip the organ out of its bed and, lifting toward the surface, free the pedicle.

Ligate the ureter first and then, if possible, each of the vessels separately. If the oozing persists, leave a Miculicz drain or a rubber tube.

Intra-peritoneal rupture without injury to other viscera is very rare.

Extra-peritoneal wounds of the kidney do not, as a rule, require intervention.

That the kidney has been involved will be suggested by pain, frequent micturition, and bloody urine.

Rest in bed, morphine, and limited diet are the special indications. An abdominal binder may give relief.

Eliot (American Journal Surgery, Nov., 1906) has observed twelve cases of subcutaneous rupture of the kidney. In seven cases there was not sufficient extravasation to make a perceptible tumor, and the diagnosis was made by the hematuria and the tenderness over the kidney and persistent rigidity for a number of days.

In the remaining cases a well-defined tumor appeared in the ilio-costal space, becoming more sharply outlined as the rigidity disappeared. In five or six weeks, the tumor disappeared. In no instance was operation necessary.

In such cases of extra-peritoneal rupture as require operation, the *lumbar route* should be chosen. Operation is indicated from the first if the violence was known to be great and a large tumor forms immediately. *An operation is indicated at any time symptoms of sepsis appear.*

Morris Miller reports a case (Annals of Surgery, Feb., 1908) of a man who fell, striking his left side over the lower rib. He felt faint, and almost immediately passed a quart of blood by the urethra and later may clots. Miller saw him at the hospital an hour and a half later. There was no shock, but the side was rigid and tender, and an indistinct dull mass could be felt in the loin. An oblique lumbar incision revealed an extensive rupture of the kidney with much hemorrhage. Wicks of gauze were placed in front and behind the kidney and the ruptured segments pressed together. The patient did well, the hemorrhage gradually ceased, though twice after the fifth day blood appeared in the urine. On the twelfth day the packing was all removed, and the opening finally healed. Gibbon, com-

menting on the case, remarks that hemorrhage severe enough to require operation does not usually mean injury sufficient to require nephrectomy. The question of nephrectomy must be decided when the kidney is exposed.

Stewart adds that the two early indications for operation are a progressively increasing hematoma and constitutional symptoms of hemorrhage. In several cases of moderate bleeding he had operated, and afterward been sorry he had interfered.

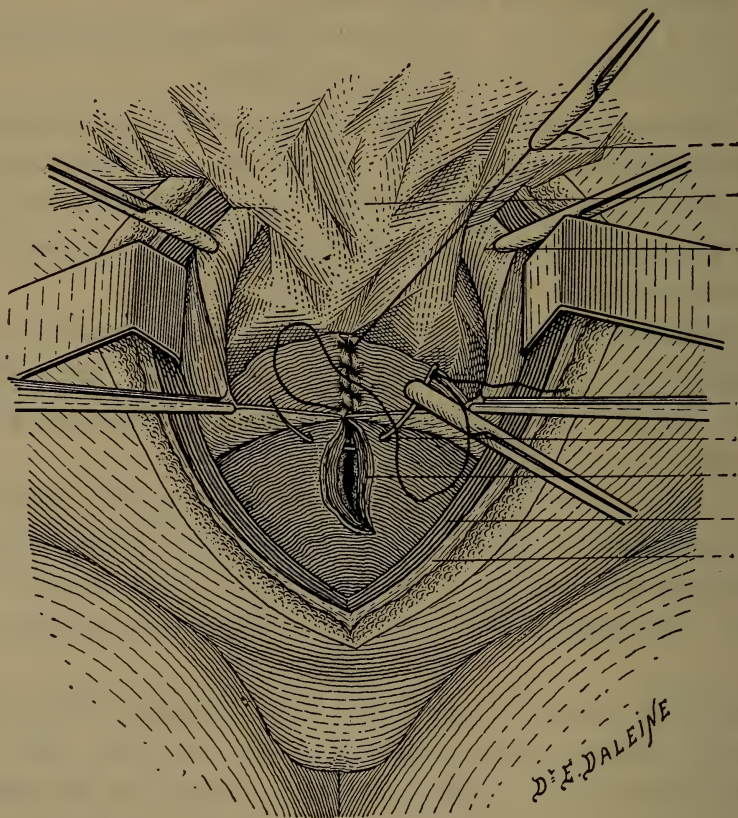


FIG. 416.—Repair of ruptured bladder. Applying through-and-through sutures. Subsequently Lembert suture will be applied and finally the parietal peritoneum will be repaired beginning at point of reflection onto the bladder. Peritoneum retained by forceps. (*Lejars.*)

WOUNDS OF THE BLADDER

Wounds of the bladder, if not previously suspected from the nature of the abdominal injuries, are inferred from the presence of urine in the peritoneal cavity. Sometimes the rent is hard to locate. Inject

the bladder with normal salt solution and observe its mode of entrance into the peritoneal cavity.

The wound is to be repaired by two rows of sutures, the first, of catgut, involving all the coats except the mucosa; the second, of silk, includes the peritoneum alone after the manner of the Lembert suture. The stitches of both rows must be closely placed to seal the wound. The result may be tested by filling the bladder with normal salt solution, and any defect repaired (Fig. 419).

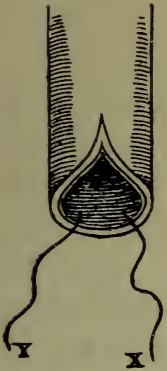

FIG. 417.—Van Hook's ureteral anastomosis. (Binnie.)

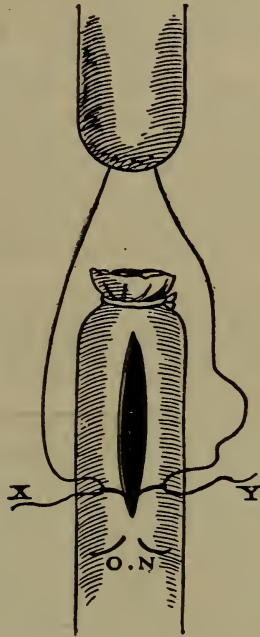


FIG. 418.—Van Hook's ureteral anastomosis. (Binnie.)

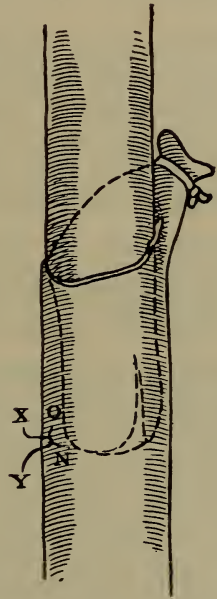


FIG. 419.—Anastomosis completed. (Binnie.)

A catheter should be left in the bladder for drainage and the siphonage kept up for two or three days. Subsequently, the bladder should be emptied by aseptic catheterization for a few days longer. The peritoneum should be drained for the first forty-eight hours.

This mode of treatment applies to the intra-peritoneal wounds of the bladder. The extra-peritoneal wounds should be treated on the same principle, but often, under such circumstances, the operator must be content with suprapubic drainage of the bladder until the wound has healed.

WOUNDS OF THE URETER

If it is discovered that the ureter is wounded either by the trauma or in the course of the operation, an effort should be made at repair. Several methods are available. If the injury does not amount to complete division, a few perforating sutures followed by Lembert sutures may succeed. Small wounds usually heal readily, but it is safer to use drainage.

If the separation is complete, both ends of the torn ureter may be ligated, or the kidney may be removed, but naturally it is preferable, if possible, to establish an anastomosis. Under various circumstances, the proximal end may be anchored in the bladder or in the bowel, or the two ends may be brought together.

Van Hook's termino-lateral anastomosis is generally applied. The technic may be briefly described in this wise:

Ligate the distal portion $1/4$ inch from the end and make a longitudinal slit in length double the diameter of the tube. Split the proximal end also for $1/4$ inch, beginning at the free end.

Pass the sutures. Employ a long catgut suture threaded on a needle at each end. One-eighth inch from the end of the proximal portion of the ureter, pass the two needles from without inward (Fig. 417). Carry the two needles through the split in the distal portion, into the lumen and let them emerge $1/2$ inch below the end of the split (Fig. 418). Tighten the suture, which will have the effect of invaginating the upper segment in the lower (Fig. 419). Around the line of contact run a Lembert suture, and cover with omentum or peritoneum.

CHAPTER VIII

APPENDICITIS. APPENDICIAL ABSCESS. PURULENT PERITONITIS¹

Inflammation of the appendix presupposes two factors, lowered resistance and a pathogenic germ.

The lowered resistance of the appendicial tissue may find its origin in many diverse conditions involving its morphology, anatomy, and physiology. It is generally agreed that it is an organ undergoing a retrograde metamorphosis, or, at any rate, one adapting itself to new functions.

There is a small facility for compensatory circulation if its main artery is blocked, and, in consequence, it is exposed to vicissitudes of nutrition.

Owing to its varying position, it is brought into contact and may acquire connections, vascular and lymphatic, with other abdominal and pelvic organs and structures and, by this means, be the recipient of pathogenic bacteria that had not elsewhere found a favorable soil.

The pathogenic organisms which, under favorable conditions, may here develop and produce various grades of destruction are the *bacillus communis coli*, the streptococci, staphylococci, and others less frequent.

Whatever part each of these causative agents may play in its development, the fact remains that appendicitis is one of the frequent and one of the most dangerous and treacherous diseases with which the general practitioner has to deal.

Diagnosis.—The diagnosis is not difficult in the typical cases, but exceptionally may be extremely difficult, or even impossible, until the progress of the symptoms has been observed.

A diagnosis should never be made from the mere presence of what

¹ So important is this subject to the general practitioner, that he should be satisfied to have and study no works less complete than the classic volumes of Deaver or Kelly.

are regarded as the cardinal symptoms; not until each symptom and sign has been weighed and accorded its proper significance, and all other possible conditions excluded, should it be decided definitely that the case is or is not acute appendicitis.

To discuss briefly the symptoms upon which one must rely: the *pain* in the milder catarrhal cases is limited usually to the right iliac fossa. In the ulcerative type, with sudden onset, or the perforative type, it is very likely at first to be general over the abdomen, but after a few hours, is rather definitely localized in the right side. In the gangrenous cases, it may be absent in one case or severe in another, depending upon the degree of active peritoneal inflammation.

Rigidity of the right rectus abdominis and pelvic muscles is an important sign, and its degree is some index to the amount of peritoneal involvement.

Gastric disturbance, nausea, and vomiting are fairly constant occurrences in the first stages of the attack, but last only a short time. T. B. Eastman has very strongly emphasized the frequent connection between the chronic forms of appendicitis and those appearances of gastric indigestion vaguely grouped as "stomach troubles."

Constipation is almost the rule, and Kelly adds further that it may amount to an actual obstruction. Only rarely does diarrhea appear with the attack, and if it does, may be regarded as indicating a grave form. Most rare of all is it for an attack even of the mildest type, to run its course without some aberration of bowel action.

Tenderness on pressure is a symptom upon which alone the diagnosis is too often made. It is scarcely possible for it to be wholly absent, and yet it can by no means be relied upon to indicate the severity of the attack. Rosving states that pressure on the left McBurney point always elicits pain in appendicitis, but not in other cases.

Robert Morris adds something to this phase of the diagnosis. He claims that tenderness upon pressure over a point opposite the umbilicus in the line of the anterior superior spine of the ilium has a special significance and is due to involvement of the lumbar ganglia. Thus Morris' point on the right side will be tender in appendicitis. If that point on both sides is tender, the trouble is located in the pelvis.

Tumor.—It is folly to wait for this sign to complete the diagnosis, for it means the certainty of a complicated pathology. It means peritoneal involvement with plastic exudates, or a pus formation, or both.

Disturbance of Pulse and Temperature.—There is no other grave disease, perhaps, in which the pulse and temperature make such limited excursions. The temperature in the most serious cases may not reach 103° . Its elevation is in no wise significant. The pulse in the milder cases holds a certain ratio with the temperature. A temperature of 101° , for example, should be accompanied by a pulse rate of 90 to 100. Any marked disturbance of this ratio is extremely significant; whether it is a low temperature with a rapid pulse or a high temperature with a slow pulse, the outlook is ominous. H. O. Panzter, from extended clinical experience, insists that we must rely largely upon the *rectal temperature* in making a differential diagnosis, and that the temperature should be invariably taken by both mouth and rectum. The temperature by mouth in such cases may be very deceptive.

Such, very briefly, are the principal symptoms and signs which, taken collectively, must serve to distinguish the disorder from acute intestinal obstruction, ovarian or tubal inflammation, cholecystitis, typhoid fever, pneumonia, and other acute diseases.

There is not much danger at the present time, so prominently is the subject before the profession, that an appendicitis will be overlooked. Only too often is an innocent appendix held to be the cause of the illness in hand. Lobar pneumonia, for example, is likely to give rise to appendicial symptoms, and such cases are likely to run an atypical course.

It is an appendicitis, but what is its character? Is it mild or dangerous? Is it a simple catarrhal trouble which will soon subside, or is it potentially a gangrenous process with general peritonitis ahead? These are the questions which confound the doctor and upon their answer rest the prognosis and treatment.

Four varieties are described (Fig. 420).

(1) *Catarrhal appendicitis*, in which the mucosa alone is involved, the predisposing causes are easily relieved, and the pathogenic agent

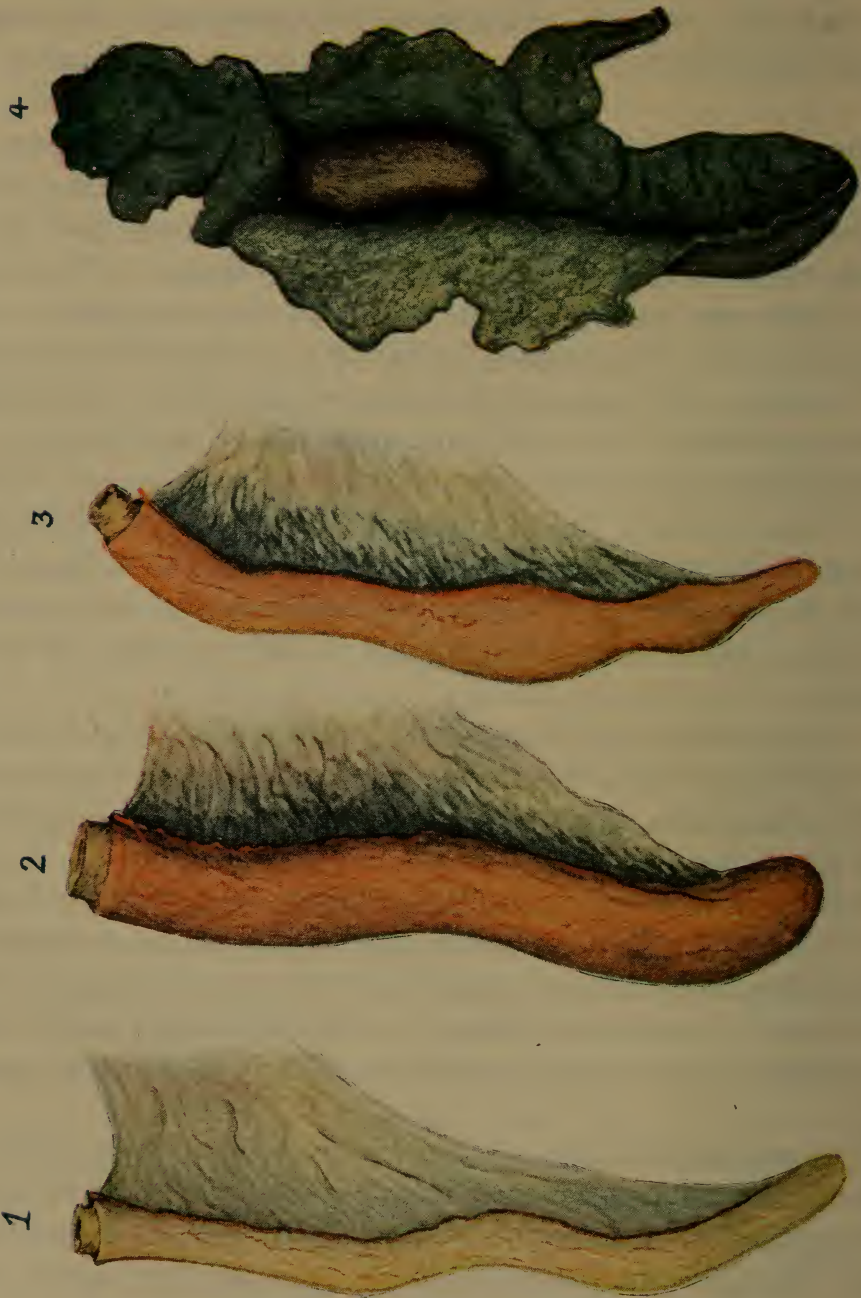


FIG. 420.—Types of appendicitis showing pathological changes. 1, Normal appendix; 2, acute appendicitis; 3, inflamed appendix containing large and small fecolith; 4, Ruptured gangrenous appendix containing large fecolith. (*Reed and Carnrick.*)

is of a low order of virility. Neither local nor constitutional symptoms are severe, and the attack very shortly subsides.

(2) In the *ulcerative* type the process extends deeper and involves the muscular and perhaps the serous coat to some extent and there is produced a mild form of peritoneal inflammation. There is usually a diffused swelling of the whole appendix.

(3) *Perforative appendicitis*, in which there is local destruction of all the coats and communication with the peritoneal cavity, is due to a sudden and virulent infection or an acute exacerbation of a slumbering process and begins abruptly with intense pain; and in a short time ends in peritoneal suppuration, local or general.

(4) *Gangrenous Appendicitis*.—This form, beginning as such, is the most treacherous, for often the symptoms are in no wise proportionate to the seriousness of the case. Death is impending, and yet neither the pain, pulse, nor temperature gives due warning. There is absolutely no way at this present time by which the doctor may recognize this condition *de novo*. It may be imagined that such a condition arises from sudden interference with the blood current to the organ, while infection plays the lesser part. On the other hand, gangrene which ensues from virulent infection begins at once with the characteristic symptoms of appendicitis added to those of sepsis and peritonitis.

It is from the point of view of these pathological variations that the most diverse opinions as to treatment have arisen.

It is evident that nature, unaided, may be able to take care of the milder type. It is a clinical fact that nature by means of her own, may sometimes control and keep the inflammation within bounds, even in the more dangerous cases. By means of plastic exudates, she walls off and limits the suppurating area and later provides a safe means of escape for the products of suppuration. But, unfortunately, such a happy issue can never be depended upon. On the contrary, the suppuration is more likely to become diffuse and there presents the picture of *purulent* peritonitis and the imminent prospect of a fatality. In such a case one loses sight of the local symptoms.

The abdomen is rigid, tympanitic and everywhere exceedingly tender. The temperature is high; the pulse rapid; the tongue coated, brown and fissured; and as the disease progresses, the symptoms of

circulatory collapse appear. The temperature then becomes subnormal, the pulse almost uncountable, and the features pinched and anxious, until finally a mild delirium with pleasant hallucinations ushers in the end.

The infection may be so severe, the toxemia so profound, that the patient may die of *septic peritonitis* before pus has had time to form. Indeed, death may come from sepsis before the ordinary signs of inflammation appear.

Such may be the outcome of what appears to be the mildest case. It is this prospect and the attendant uncertainties which have led many doctors to regard appendicitis as an emergency to be operated upon as soon as the diagnosis is made. As Pfaff, of Indianapolis, puts it, the difference between the mortality of 1 per cent. in the very early operations, and that of 15 to 30 per cent. in the abscess stage, is so frightful that, in comparison, an occasional unnecessary operation is of no consequence at all. If we are to fulfill our obligations, we must act vigorously and to-day.

This is undoubtedly a safe rule in the practice of the skilled operator, who has at his command all the facilities of the aseptic operating-room and trained assistants.

The case is quite different with the general practitioner, remote from these accessories. Moreover, it is known that 80 to 85 per cent. of these cases recover without operation. Even for the relapsing from, Treves says that much may be done by medical means, diet, attention to the bowels, and by placing the patient under conditions more favorable to a state of peace within the abdomen.

Whatever may be proper in hospital practice, it certainly cannot be imposed on the general practitioner that he operate at once. Even in connection with the skilled surgeon, it may be said that his technic has not yet reached such a degree of perfection that an operation is always safer than the milder form of appendicitis unoperated.

The doctor then will face his responsibility, a heavy one truly, knowing there is much to be accomplished by medical means and yet hoping that he will have the judgment to recognize the failure of nature and of his art, and the will to resort not too late to more radical measures.

Assume that the diagnosis is definitely made; assume that no sur-

geon is within beck and call (for appendicitis is strictly a surgical disease), what will you do? It is evident at once that this is a clinical hypothesis, and the question is to be resolved on a clinical basis.

I. You see the case from the first. The attack begins mildly or with only moderate severity; there was perhaps a single attack of vomiting; the pain, abdominal tenderness and rigidity are not marked, and the patient's general condition is good.

Under these circumstances, as Lejars says, it is perfectly legitimate to institute a medical treatment, in the meantime holding the case under the strictest surveillance. But this formula is null without the last provision. *If the march of the disease cannot be watched, it is better to operate at once*, and this rule may as well be made to apply to any case in which delay might otherwise be counselled. You decide to try medical treatment, but in what form? Like many others herein involved, the question brings forth a varied response.

Under these circumstances one may follow the plan of "*immobilization*," which Lejars and others so highly praise. But to be effective, it must be rigorously and consistently applied.

Keep the patient absolutely quiet in bed. Give no purgatives—and this means give neither calomel nor oil. Give no enemas. Suspend nourishment absolutely, relieving thirst by a few drops of water frequently given.

Ice to the Abdomen.—Not a handful of ice in a little bag applied over the iliac fossa, but two or three large bags covering the whole abdomen below the umbilicus and refilled as the ice melts.

Opium, in $\frac{1}{5}$ -grain doses in pill form every two hours for an adult; but it must not be pushed to the point of annulling all pain and suspending the functions of the kidney.

It is far from being the rule that the practitioner remote from the larger towns can have ice at his command. Likewise, opium in the hands of the inexperienced may be a two-edged tool. He must often, therefore, depend upon other modes of procedure, and for these, there is no lack of eminent authority. Under the circumstances indicated, begin with a single hypodermic of morphine if the pain is severe and with small doses of calomel ($\frac{1}{20}$ – $\frac{1}{10}$ gr.) frequently repeated, until a grain or two is taken; follow at the end of three hours with a large dose of castor oil or larger doses of albolene until

the bowels have moved freely. If the bowels are slow to move, supplement the internal remedies with enemas of normal salt solution. Give salol or carbonate of guaiacol every three hours. Apply hot fomentations to the abdomen, flannels wrung out of hot water and sprinkled with turpentine. Cover the hot flannels with several additional thicknesses and apply hot-water bottles filled with boiling water, and cover the whole to retain the heat. As the water cools, withdraw, one by one, the various layers so that the temperature may be maintained at the highest point of comfort. Hot kaolin cataplasms often render service.

As Oschner commands, food must be withheld absolutely, and if there is much gastric disturbance or pain, the stomach should be washed out. Opium is contraindicated under this form of treatment, for it is the purpose to cleanse the bowel.

McGrath, of New York, probably expresses the prevailing opinion, summing the matter up in this wise (Medical Record, Feb. 1, 1908):

"Only in the catarrhal cases can there be any question as to treatment once the diagnosis is made; whether it is better to operate without delay or seek to avail oneself of the advantage of an interval operation. If sure of the character of the lesion, we may temporize; it will do no harm watching the patient carefully for any sign of danger. Many of these cases resolve without going on to suppuration or gangrene, and therefore escape operation during the acute attack. Nature may be assisted in her efforts at spontaneous cure in these cases by enjoining complete rest, withholding all food and permitting only water to be taken, and by small repeated doses of calomel and sodium bicarbonate. An ice-bag may be applied over the region of the appendix. But if there is any doubt as to the exact pathological condition, operation should be advised unless marked contraindications exist."

George J. Cook, of Indianapolis, who has had as much experience with this disease as anyone in the Mississippi Valley, does not operate in mild attacks of primary appendicitis. If it is a second attack, he operates without delay. He says that not infrequently a mild catarrhal appendicitis does not recur. In such cases, he puts the patient at rest. He unloads the bowels with enemas merely. If the attack follows overeating, he employs a mild saline primarily. Nothing but

water is permitted. As an intestinal antiseptic, he gives 5 grains of carbonate of guaiacol three or four times in the twenty-four hours. If the patient should complain much, he gives small doses of opium, after the diagnosis is made. He gives it to quiet the pain and not the peristalsis, asserting that the bowel will of itself be quiescent if empty. Ice-bags applied to the abdomen as a routine measure represents to him the chief element in the relief of pain and control of inflammation.

Note that whatever the form of treatment, the case must be narrowly watched. If the pulse and temperature remain in harmony; if the abdominal tension and tenderness tend to grow less; if the bowels move and gas escapes per rectum; if the general condition is good; there is ground to expect a satisfactory termination, but no excuse to relax one's vigilance.

No nourishment should be given by mouth until defervescence is complete, and after that a liquid diet should be maintained for one to two weeks, depending upon the severity of the attack, and rest in bed as well. At the end of a few weeks, the appendix should be removed.

But the progress of the disease may suddenly change. All the symptoms may become aggravated and the dangerous nature of the case become at once obvious—immediate operation is indicated; or the change may be insidious (unsuspected by the careless observer) and in this instance the chief reliance must be placed upon the pulse. If the pulse is rapid and weak with a falling temperature, or if the pulse falls to 50 or 60 with a rising temperature; in other words, if there is any marked divergence between pulse and temperature, again the indications are to operate at once. To repeat, any marked aggravation of the symptoms after improvement once begins, or the occurrence of any marked disparity between pulse and temperature, however benign the other symptoms may be, are indications for operation without delay.

II. Another case: You have watched the case, but the temperature has persisted, and beyond, say the sixth day, when there should be a marked improvement, you find the temperature rising or fluctuating, the pain increasing, a tumor forming most painful at its center. In this case also the indication is for immediate operation.

III. Suppose you see the case only at the end of several days, during which time the disease has run a neglected course. May one at this time, with any effect, apply a medical treatment, or should one resort at once to an operation? The question can only be answered after a careful consideration of the history of the case, such as the patient or his attendants can give, and a thorough investigation of the present symptoms. Only when the case is obviously benign can one take the responsibility of further delay. For example, if the pulse and temperature are in accord, if the tenderness and tympanites are diminishing, then nothing better can be done than to follow the rules with regard to rest and diet already laid down. Yet one must be ever mindful of the treacherous character of certain forms of septic attack.

Again, you find the disease progressing and in the active stage of the third, fourth, or fifth day, with no indications of beginning improvement, but the symptoms are not aggravated, and there is a plastic exudate without softening: again it may be said that under these circumstances it is legitimate to wait.

Any continuance of the fever beyond the eighth or tenth day, even though the pulse is good and the exudate has not softened, is a matter of grave suspicion, and with the least enlargement of the tumor or disturbance of pulse, operate without delay, and it is more than likely you will find a large abscess.

IV. In any case, at any stage, if a diagnosis of abscess can be made out—a palpable fluctuating mass, in the iliac fossa—whatsoever the other symptoms may be, there is but one indication, immediate operation. No practitioner to whom the task falls, whatsoever his ability or training, can do anything else and do his duty. Even though you cannot detect fluctuation, but by vaginal and rectal examination determine that the mass is doughy and painful, operate and you will almost certainly find pus.

V. Finally, even if the case has progressed to a general peritonitis, it is one's duty to operate unless the patient be practically moribund, and even in these cases, as Lejars puts it, operation has rescued a certain number of patients from the very jaws of death, for without operation they would inevitably have died.

Even though the diagnosis is not definitely established and one

considers the possibility of meeting with a tubercular peritonitis or a salpingitis or similar condition, yet the rule should be to operate in any case of doubt.

Operation.—Two operations will be described: *A*, when no pus or other complications are expected; *B*, when pus, localized or diffused, is a certainty.

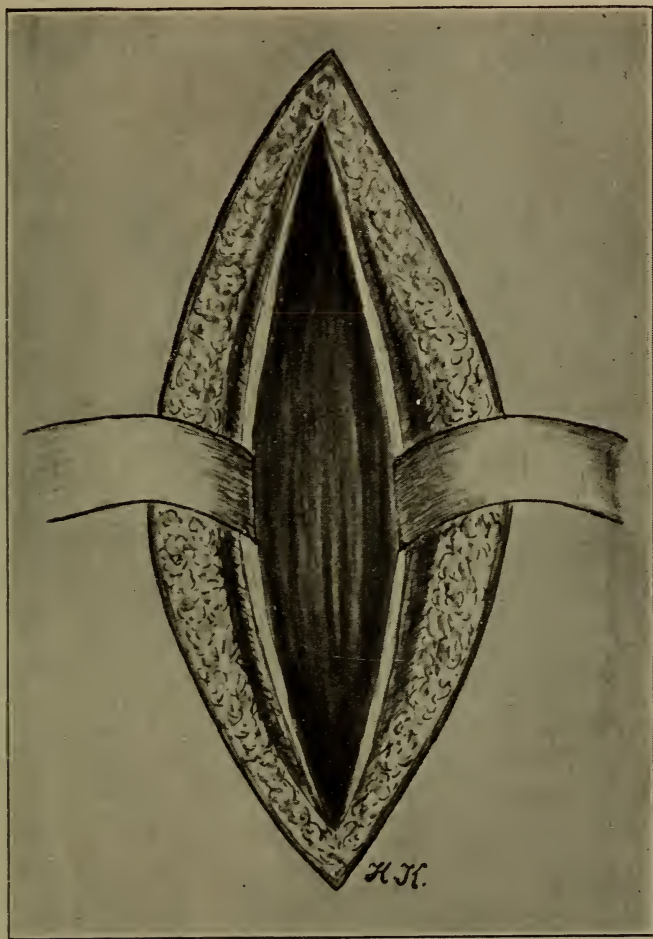


FIG. 421.—Vertical incision through skin, aponeurosis and sheath of rectus. Outer border of rectus exposed in bottom of wound.

A. Incision.—Begin 1 inch above or 2 inches below the line connecting the anterior superior iliac spine with the umbilicus. The incision crosses this line $\frac{1}{2}$ inch to its inner side of its middle point and follows, practically, the outer border of the rectus abdominis.

Divide first the skin and fat and expose the aponeurosis of the external oblique. Divide next the aponeurosis and under one lip is the edge of the rectus, and under the other, the transversalis (Fig. 421). Split the sheath of the rectus and retract the edge of the rectus exposing the transversalis fascia.

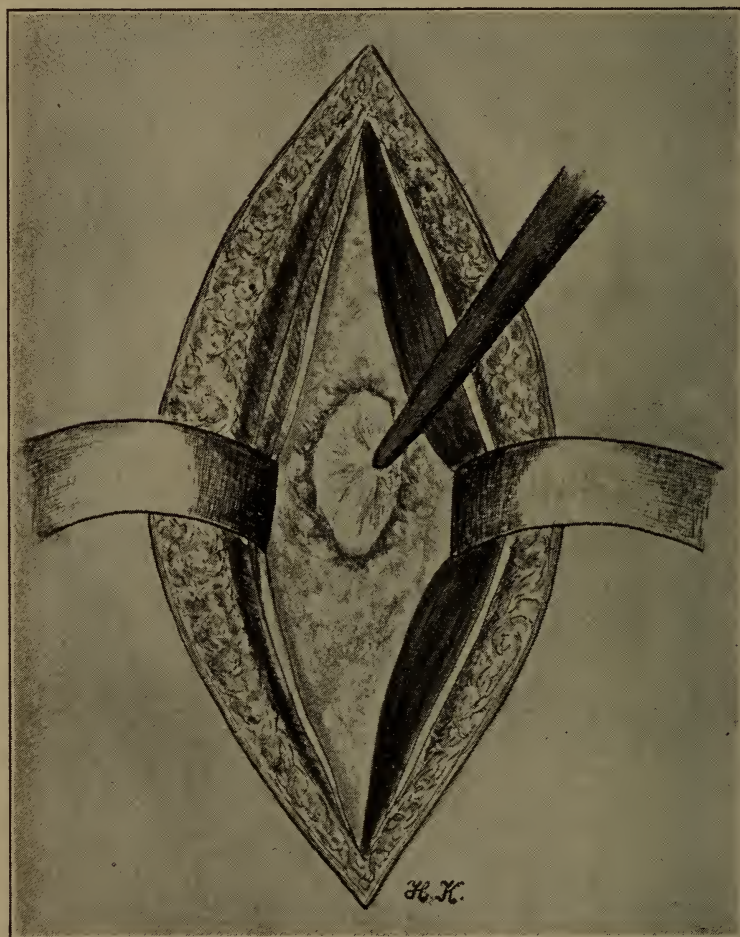


FIG. 422.—Rectus drawn inward. Posterior layer of sheath and transversalis fascia divided. Peritoneum exposed and cone lifted preparatory to dividing.

Divide the transversalis fascia, exposing the subperitoneal fat and pick up a fold of the peritoneum, and divide it, turning the cutting edge of the knife away from the abdomen (Fig. 422). Usually the great omentum will bulge into the wound after the peritoneal

incision is enlarged. Replace the omentum and, if necessary, hold it with a gauze pad.

Next introduce a finger and feel for the cecum, which will be recognized by its bands, and pull it up into the wound until the base of the appendix can be seen. The appendix may be adherent, and

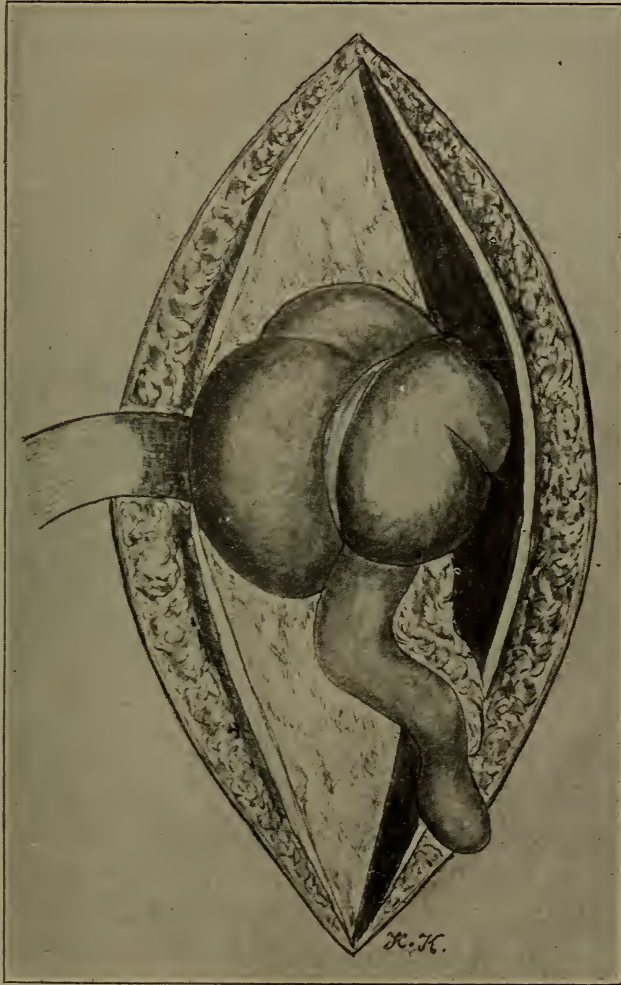


FIG. 423.—Appendix and part of cecum delivered and walled off with gauze.

the adhesions should be broken up very gently. Once the appendix is freed, it is to be brought up out of the wound and the cecum returned to the abdominal cavity and walled off with gauze pads (Fig. 423).

Tie off the meso-appendix with catgut, and cut it away from the appendix close to its line of attachment.

An incision is now carried around the base of the appendix, dividing only the serous coat, which is stripped back toward the cecum, forming a peritoneal cuff (Fig. 424). The appendix is now ligated

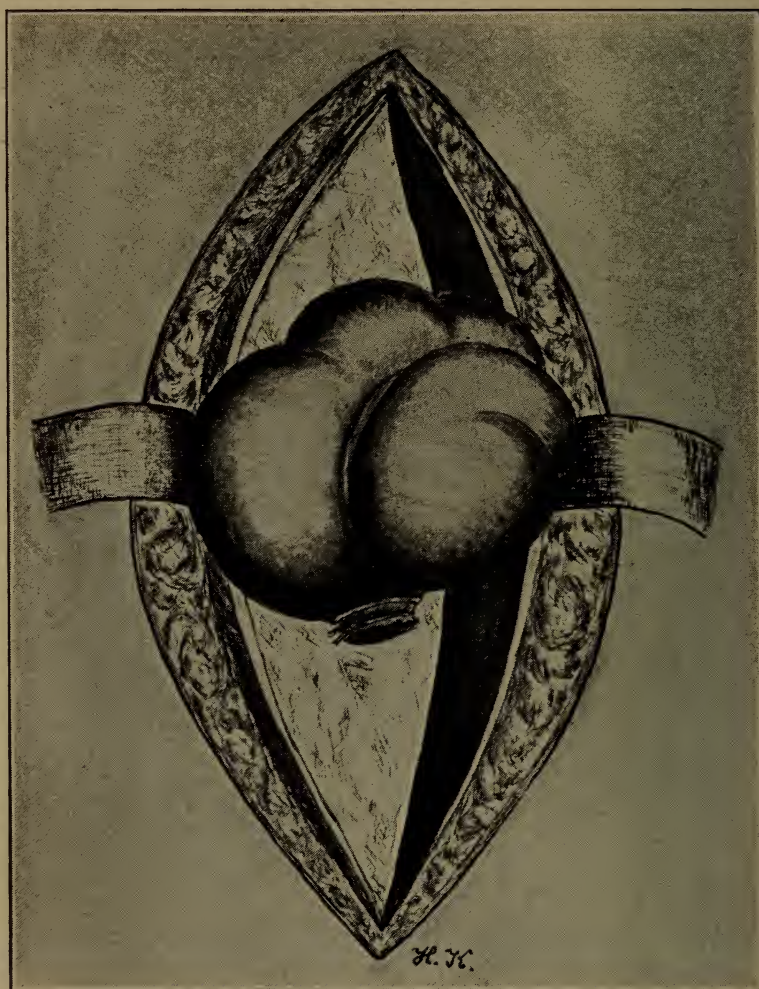


FIG. 424.—Peritoneal cuff turned back; appendix ligated and amputated.

and cut off, the mucous stump touched with carbolic acid and then with alcohol. The peritoneal cuff is drawn over the stump and sutured. The stump is now invaginated and buried with a row of Lembert sutures. The gauze pads are removed with the exception of one, which covers the cecum until the last stitches are placed in the

peritoneum. Repair by separate lines of suture the peritoneum, transversalis, aponeurosis, and skin. Drainage is unnecessary.

B. The incision, 4 inches long, is a finger's breadth to the inside of the anterior superior iliac spine, with its middle corresponding to the spine (Fig. 425).

The first incision traverses the skin and superficial fascia, which are likely to be very vascular in such a case. The external oblique appears, its fibers parallel with the incision. Divide it the whole

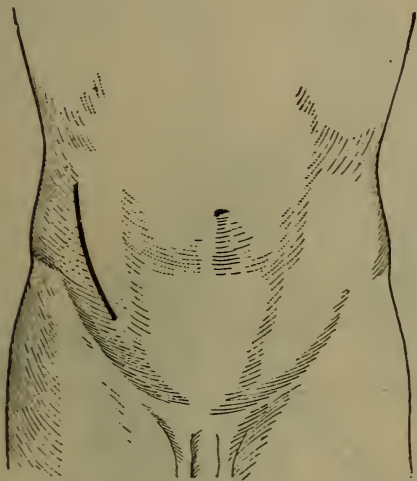


FIG. 425.—Appendicectomy incision. (Veau.)

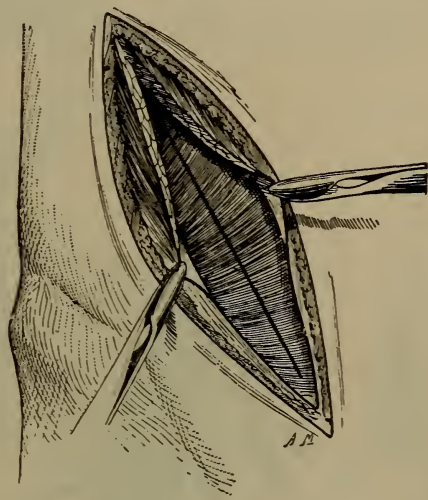


FIG. 426.—The external oblique divided; the internal oblique exposed. (Veau.)

length of the wound and catch the edges with forceps which will serve as retractors (Fig. 426).

Next divide the internal oblique and transversalis muscles, whose fibers run transversely. The layer is thick, and several vessels will need to be caught (Fig. 427).

Retract these layers and the transversalis fascia is exposed. This you divide, bringing into view the peritoneum.

Catch up a fold with the forceps, and divide its base with the scissors (Fig. 428). From the small orifice thus created, there flows a seropurulent fluid. Enlarge the peritoneal opening and hold back the intestine with compresses. Examine the cavity. It may be that the omentum, thickened and infiltrated, will cover the field, but do not disturb it.

Follow with the index finger the wall of the fossa until the cecum is reached. Wiping out the cavity, you may be able to see the bands of the cecum, which are to be followed downward by sight and touch, for they lead to the appendix.

Remove the appendix if possible. You may not be able to find it, but do not prolong the search and certainly do not break up adhesions in this search.

When it is located, gently draw it to the surface. It is exceedingly friable and should not be ruptured. Throw a catgut ligature about its base close up to the cecum and tie moderately tight (Fig. 429).

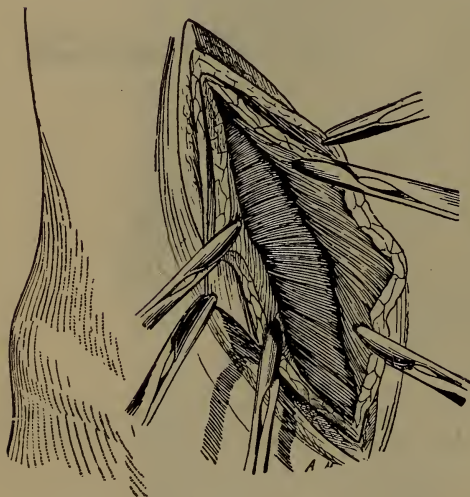

FIG. 427.—The two oblique muscles incised, the transversalis exposed. (Veau.)

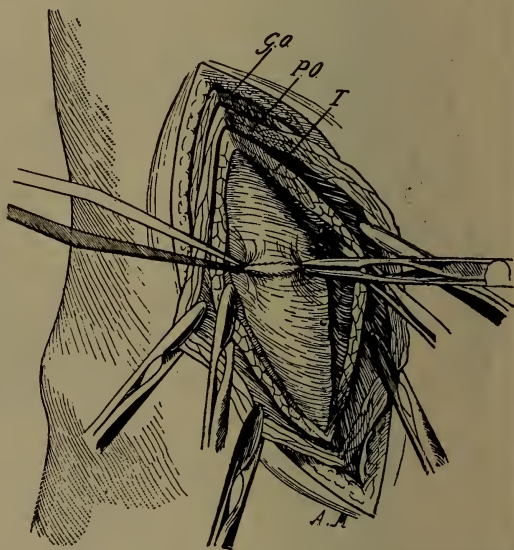


FIG. 428.—Showing the three muscular layers and the peritoneum incised. (Veau.)

Amputate the appendix, and if there is no bleeding cut the ligature short. Determine now the character of the suppuration, whether circumscribed or diffuse (Fig. 430).

(a) *It is Circumscribed.*—Wipe out the cavity very carefully with sterile gauze. Do not irrigate. Place a drainage-tube upward toward the diaphragm (Fig. 431). Do not use violence. There a new collection of pus may be found. Pass a second drainage-tube in the same manner down into the pelvic cavity. This is the most important, for the fluids tend to collect there. Leave the third in the iliac fossa and the fourth directed toward the middle of the

abdomen. Secure each with a safety-pin. Suture up to the drainage-tubes, so that the opening will be only large enough to accommodate the tubes.

If the patient is a female, after wiping out the cavity carefully, a counter-opening may be made into the vagina in favorable cases, and with efficient drainage secured by that route, the abdomen may be completely closed.

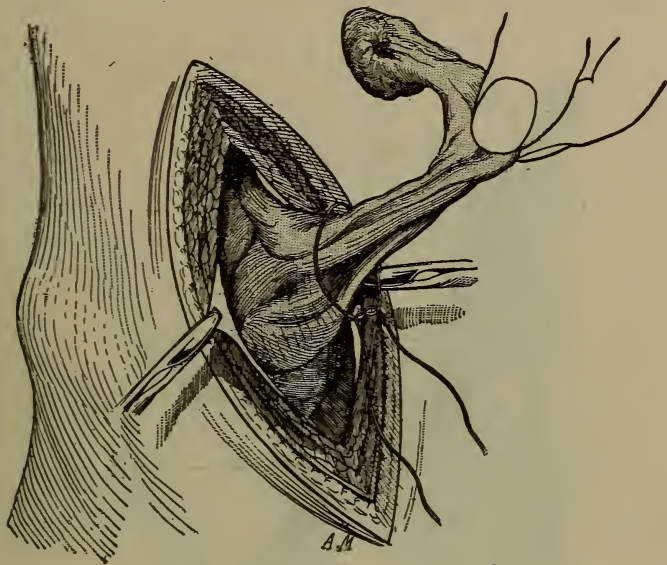

FIG. 429.—Throwing a ligature around base of sloughing appendix. (Veau.)

In many cases even without such drainage, the abdomen may be closed after cleansing the cavity, but it cannot be advised in the emergency work of general practice.

(b) *The Suppuration is Diffuse.*—Make a second incision from the umbilicus downward for a couple of inches, which is sufficient. When the peritoneum is opened, the fingers can touch through the two openings.

If the pus seems to have reached into the left side, it may be advisable to make a *third incision* over the left iliac fossa. Through these incisions irrigate the abdominal cavity with normal salt solution, using plenty, 3 or 4 quarts, and continue the irrigation until the fluid flows out clear. Unless it be complete, reaching every part of the cavity, irrigation had better be dispensed with. The addi-

tional incisions may even be unnecessary if the following treatment is pursued:

The patient is now put in the Fowler position and a continuous rectal enema of normal salt solution arranged for. The purpose of this treatment, instituted by Murphy with such signal success, is to secure a constant saline lavage of the peritoneal cavity. In other words, the fluid passes from the bowel into the peritoneal cavity, accom-

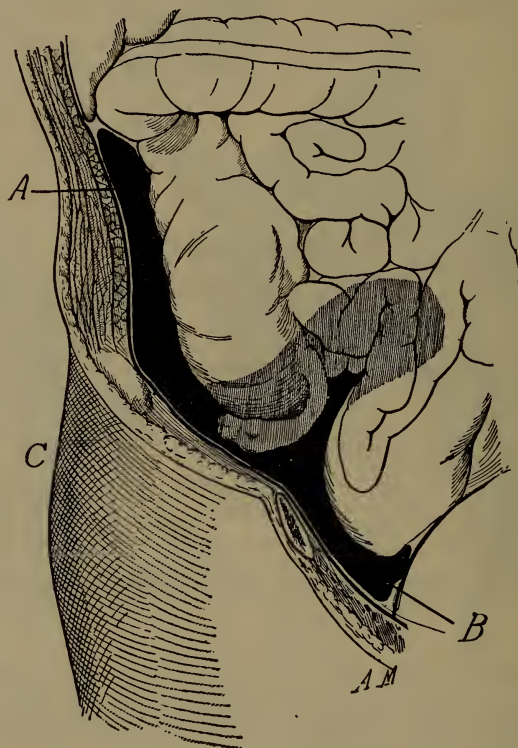


FIG. 430.—Diagram showing directions the pus may extend. A, Sub-hepatic; B, pelvic; C, iliac. (Veau.)

plishes its healing mission, and drains out through the abdominal wound.

The fluid should be maintained at a temperature of 100° F., and should be allowed to flow into the rectum at the rate of 1 pint per hour or thereabout. The patient's sensation should be consulted. If there is a feeling of tightness and distress, the flow should be lessened. After 2 or 3 quarts have been introduced, the flow

should be shut off for an hour or two. The injections may be continued one to three days.

Moynihan reviews his experiences with this treatment (*Lancet*, Aug. 17, 1907) and concludes that it has exceptional value. He insists upon attention to the details of administration and describes the methods found most useful. The largest quantity of the solution taken by any of his patients was 16 pints for the first twenty-four hours, and a total of 29 pints in three days. He

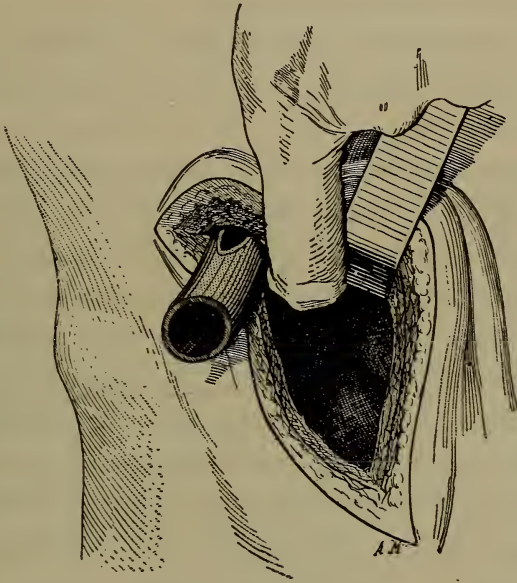


FIG. 431.—Placing a tube in the sub-hepatic space. (*Veau.*)

emphasizes the character of improvement in the appearance of the patient, in his pulse and temperature, and in the action of kidneys and skin.

The plan pursued by others aims to secure drainage by means of tubes passed in various directions into the intestinal mass and into the pelvic cavity. Under these circumstances, the enemas of normal salt solution should be used at intervals and the dressings changed on the second day. On the fifth day, the tubes should be removed, cleansed and replaced exactly as before. The patient must not strain while this change is being made and children may need to be given a few whiffs of chloroform. Cleanse the drainage-

tubes every third day, gradually shortening them as granulation proceeds.

If a new focus of infection forms, if the temperature reaches beyond 101° in the evening for two or three evenings, no matter what it was in the morning, one may be sure of suppuration somewhere. It will be necessary to re-operate and re-establish drainage.

Septic peritonitis, originating elsewhere than the appendix, ought to be similarly treated, but the results are so discouraging that the operation cannot be urged upon the general practitioner, however advisable it may be in hospital practice.

The principle of treatment is the same. Make a median incision below the umbilicus and search for the cause. It may originate from a ruptured Fallopian tube, it may follow perforation of the stomach or duodenum, and the break must be located and repaired. It may follow the perforation of typhoid fever and for this condition, the operation will be done more and more as time goes by.

Gerster, of New York, before the 1909 Congress at Budapest, summarizes the *treatment of diffuse free progressive peritonitis* thus: (1) Preliminary lavage of the stomach; (2) anesthesia by nitrous-oxid gas followed by ether; (3) rapid exposure of primary focus of infection; (4) stoppage of visceral leak by suture or tamponade; (5) gentleness and rapidity of procedure, avoidance of friction by wiping, etc.; (6) no irrigation; (7) soft rubber-tube drainage of right iliac fossa and, if necessary, of Douglas' pouch; (8) closure of external wound by three layers of suture; (9) for paralytic ileus repeated gastric lavage, low and high enemata, or systematic rectal lavage, enterotomy by stab done in intractable cases only; (10) rational administration of opiates; (11) withholding of all ingesta while vomiting is present; (12) Murphy's proctoclysis; (13) Fowler's position; (14) early incision and drainage of secondary abscesses; (15) laxatives, calomel and salts, to be given only after cessation of vomiting; (16) tampons used for walling off necrosed areas not to be disturbed without necessity till they become detached of themselves.

CHAPTER IX

ACUTE INTESTINAL OBSTRUCTION

Acute occlusion of the intestinal canal is a condition always to be dreaded, for it begins suddenly and unexpectedly and, unless relieved, hurries to a fatal issue, due either to shock or sepsis. Perhaps, as Bloodgood says, the condition is not a frequent one, yet, none the less, it is an emergency whose character must be thoroughly understood.

But for that matter its character is variable, depending upon the cause. To simplify the subject, the obstruction due to strangulated hernia is not considered here, for in such cases the cause of the obstruction is quite obvious; nor need we consider post-operative ileus, for it has a pathology of its own; again the obstruction which may accompany appendicitis is in a class by itself. The acute obstructions to be studied include those changes in the form or direction of the bowel, or those accumulations within its lumen, which completely and suddenly dam the fecal current. Whether it be a kink or twist in the gut; a volvulus or intussusception; an adhesive or constricting band, relict of a former peritonitis (Fig. 432); an accumulation of gall-stones or a cancer: whatever the source of the obstruction, the danger arises, as has been said, from two sources—*shock* and *sepsis*. By far the lesser of these two evils is shock. In many cases it may be absent, and even when it is the dominant feature early in the attack, it may gradually subside. The sympathetic plexuses seem able to regain their balance and adjust themselves to new conditions. For this reason attacks, which begin with collapse, often seem to improve in a short time. But such improvement is deceptive, for sepsis pursues its insidious course, the bowel becomes more distended, its peritoneal coat more permeable, and so the intestinal bacteria find their way into the peritoneal cavity and their toxins into the blood. It is stercoremia, therefore, which is to be dreaded, for there is no way to measure its progress with any certainty.

J. R. Eastman reports a case which illustrates the deceptive character of many cases of obstruction. The patient had undergone, some years before, three various abdominal operations. The attack came on suddenly, and on the third day the vomiting became stercoraceous. In preparing for the operation, high enemas were given, followed by escape of flatus. The operation was deferred, as the patient continued apparently to improve, the bowels moving, gas escaping freely, and the patient feeling quite comfortable. Two

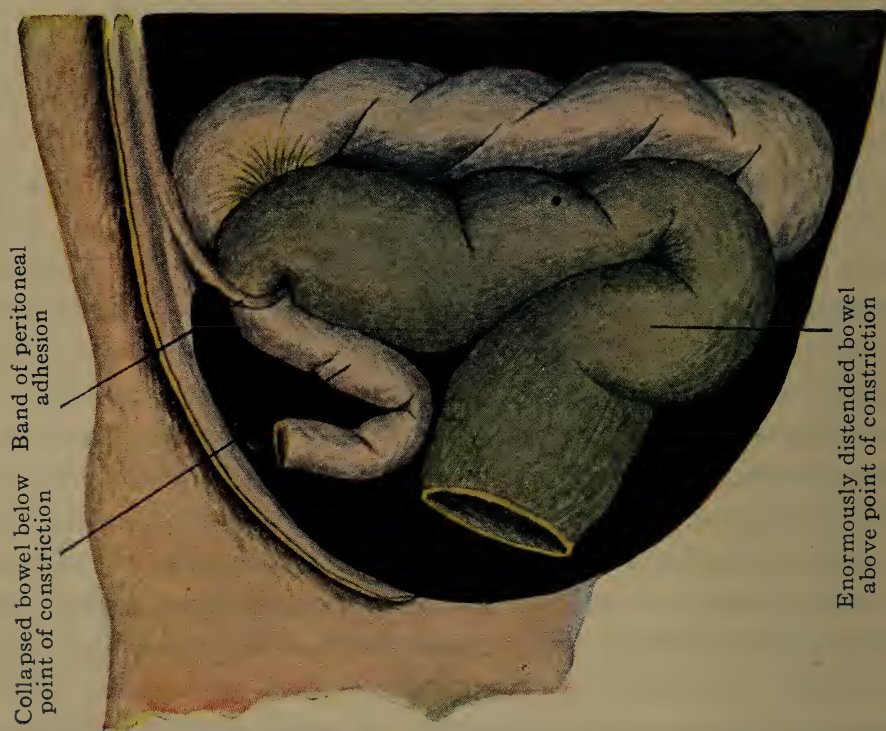


FIG. 432.—Intestinal obstruction due to band of adhesions. (Reed and Carnrick.)

days after, however, the fecal vomiting re-appeared and with it all the ominous signs of obstruction. At the operation, 4 inches of small intestine, adherent in an inflammatory mass, was found to be gangrenous. Resection, anastomosis, recovery. It is to be noted that the bowels had moved though the gut was strangulated and gangrenous, the gas and fecal matter undoubtedly passing the point of strangulation. (Indianapolis Medical Journal, July 15, 1909.)

The group of *symptoms* constitutes a very definite clinical picture:

(a) pain, (b) tympanites, (c) vomiting, (d) constipation, and (e) collapse.

(a) The pain develops suddenly and severely, often following some violent exertion, and takes the form of paroxysmal colic. There is localized tenderness.

(b) Tympanites is marked, the whole abdomen being distended, and often, on this account, the respiration and circulation are impaired. Peristalsis is exaggerated, and the violent movements of the bowel may often be noted through the abdominal wall. At the site of the greatest tenderness, a tumor may be found.

(c) There is often at first a rumbling of the bowels and nausea, soon followed by an incessant and distressing vomiting, at first gastric and finally fecal.

(d) Constipation is a constant feature, though at first there may be some movement from the lower bowel. In intussusception there is often all through the attack some discharge of bloody mucus and gas. This may be the case, too, in strangulation near the pylorus, but in such a case, the extreme distention of the stomach and the violence of its movements suggest the nature of the difficulty.

(e) Collapse is imminent from the first, and is indicated by the weak, thready pulse, the rapid breathing, the pale, pinched features, and the anxious expression.

These are the symptoms, whatever the form of the acute obstruction, whether it be strangulation, intussusception, or volvulus, and very rarely can the form of the obstruction be definitely determined before the operation or post-mortem.

Certain factors make one of the conditions the most probable. If it is a child under ten years of age, it is almost certain to be intussusception; if there have been previous attacks of some form of peritonitis, strangulating bands of adhesions are likely to be present; if the patient is forty or fifty years of age, with a history of constipation, volvulus suggests itself.

In addition to noting the symptoms and history, a careful search must always be made by palpation for an abdominal tumor, and finally the investigation is terminated by rectal or vaginal examination.

Treatment.—In the few hours that must elapse before one can

fully make up his mind that it is a case of acute obstruction, there are certain things to do, but, more especially, certain things not to do. Do not give purgatives. This is an axiom scarcely necessary to repeat. They can do no good and will most certainly do harm. Do not give large and repeated doses of morphine. It will help the patient to die easy, but in such a case, it is "not a remedy for the patient but a refuge for the doctor." It is doubtful even if it should be given at all. It is possible that minute doses may diminish the peristalsis, quiet the vomiting to some extent, relieve the shock a little, and ease the pain measurably without masking the true conditions, but under the circumstances, it is an edged tool. Give no nourishment by mouth. The two measures likely to be of the greatest benefit are *gastric lavage* and *rectal injections*.

The gastric lavage may in some measure diminish the vomiting; and, in case an anesthesia is necessary, it may prevent asphyxia from a gush of vomited matter.

Rectal enemas are sometimes effective in relieving the obstruction, but if used, it must be with the strict proviso that the injection be done carefully. If roughly given, if the fluid is thrown into the bowel with too much force, even if there is no danger of rupturing the bowel, it at least irritates it and defeats its own purpose. It is likely if the condition has existed more than twenty-four hours the enemata will be of no avail.

There is a *definite mode of procedure*: put the patient crosswise in bed in the lithotomy position, with the pelvis turned slightly to the right side. Anoint the anal region well with vaseline, and also the rectal tube, which should be of soft rubber, 3 or 4 feet in length. In the case of an infant, a rubber catheter will serve. Guide the catheter with the left index finger, and as it enters the rectum direct it backward at first and then slightly to the left. Keep hold of the tube close up to the rectum, the better to control it. Push the tube a little at a time, and if it meets with the obstruction, withdraw it slightly, and advance it with a boring movement. Any force may result in the tube merely coiling up in the rectum, the doctor in the meantime having the impression that it is ascending high in the bowel. Sometimes it is advantageous to let the injection flow as soon as the first part of the tube is intro-

duced, as by that means the rectum is dilated and Houston's valves are not so likely to intercept the tube. The tube must be introduced as high as possible without using force. In the great majority of cases it goes no higher than the sigmoid.

Attach the fountain syringe, holding it low at first and gradually raising it to increase the pressure. It should not be raised much more than 3 feet above the patient's level. The quantity of fluid, either warm salt solution or oil, which may be injected, varies with the age, say 1 pint for the infant and 4 to 6 quarts for the adult.

When the injection is completed, withdraw the tube rapidly, and lay the patient back in bed. The enema will be expelled sooner or later with severe colicky pains. If ineffective, it returns practically clear. If it has done good, it will be accompanied by flatus, and, at the last, there will be some hard lumps. The final evacuation may not take place for some time, but the escape of gas is a good indication that the obstruction has been at least temporarily relieved.

If this has not done good, the enema should be repeated with the patient in the *knee-chest position*.

Lejars recommends the "electric bath" as efficacious in many cases, but this treatment is scarcely applicable in general practice.

On the whole, the treatment is surgical; and the doctor must have it on his conscience that if the case is acute obstruction, delay is dangerous or even fatal. The point is to make the diagnosis quickly, and when that is made, there is only one thing to do, *operate*.

The practitioner will hesitate between two procedures, median laparotomy and artificial anus.

Median laparotomy is the ideal operation. It, alone, is curative, for the cause of the obstruction is found and relieved; but it is delicate and dangerous. These are the conditions which Veau formulates, under which alone the doctor must undertake it:

(a) The operator must be experienced and resourceful, for it is often difficult to locate the cause and equally difficult to remove it, and the distended bowel is always a source of embarrassment.

(b) The operation must be conducted where there are the surgical accessories and capable assistants.

(c) The diagnosis must have been perfected, so that the operator knows about what he will have to do.

(d) The patient must be vigorous and able to stand a tedious and prolonged operation.

These conditions are nearly always lacking when the doctor is thrown absolutely upon his own resources, so it may be laid down as a rule that the general practitioner must choose the second procedure.

An *artificial anus* will usually save the patient's life and is within the skill of any doctor under almost any circumstances. After the patient has later regained his strength, the operation necessary to complete a cure may be undertaken. It will not be an emergency operation, and the time and place may be chosen.

To make a temporary artificial anus will be the proper procedure under the circumstances indicated. There is a single notable exception: if the patient is a child with an undoubted attack of intussusception,

and if the enemata have failed to give relief, it is imperative to do a laparotomy (Fig. 433).

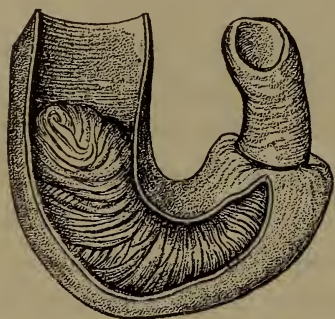


FIG. 433.—Intussusception.
(Walsham.)

LAPAROTOMY FOR INTUSSUSCEPTION

Intestinal invagination or intussusception occurs only in the first years of life for the reason that the mesentery lacks resistance at that age. It occurs at a point where a mobile part of the bowel joins a part more fixed and is most common at the ileocecal junction.

As a result of colic or spasm the ileocecal valve protrudes into the cecum and is followed by the ileum and its mesentery which alone limits the extent to which the large intestine may swallow the small bowel.

A thickened band or collar marks the line where the two parts come in contact, and this collar is usually tight; after a little while adhesions may here occur between the invaginating and invaginated parts.

Here the strangulation occurs and the symptoms are proportional to the degree of strangulation and the rapidity with which it occurs.

A case reported by Estes (American Journal of Surgery, August, 1906) illustrates the subject and emphasizes the danger of expectant treatment.

A girl of three years in fair health, three days before had been seized with violent abdominal pains with straining and tenesmus. At first the passages were fecal and then mucous, tinged with blood. She had intervals of apparent ease when she would play with her toys and ask for something to eat. After three days' treatment by enemas and light laxatives, she developed signs of complete obstruction. The abdomen was distended, vomiting frequent and at last feculent; there was persistent pain, rapid, weak pulse, and general weakness. At this time Estes was called and found a very pale, emaciated, weak, suffering baby, with pulse 130, and temperature 101°. She was vomiting every half-hour. No distinct tumor could be felt, but there was some thickening in the right iliac region. Through that night, while preparing for the operation next morning, she was given some strychnia and morphia and saline enemas, which produced an improvement.

Operation—median incision. A hand passed into the right iliac fossæ located the sausage-shaped tumor of an ileo-cecal intussusception. Turning the child to get the intestines out of the way, gentle milking motions were made and almost immediately the intussusception was reduced. Inspection showed a very much thickened and inflamed section of the ileum about 6 inches long. It was decided not to exsect the injured gut. The torn border of the mesentery was sutured, the peritoneal coat bathed with hot saline solution, dried, sprinkled with aristol and replaced, and the abdomen rapidly closed. The child made a rapid and uninterrupted recovery and has been quite well ever since.

The principal steps in the operation are as follows:

(1) *Median laparotomy.* Be careful in opening the peritoneum not to wound the distended bowel. Expect to find trouble in the management of the bowel. A skillful assistant is a great comfort in this matter.

(2) *Search for the obstruction.* The obstruction is usually easily found in intussusception. After the abdomen is opened, proceed directly to the right iliac fossa, having no fear to introduce the whole hand, if gently done. In any case the cecum is first to be examined, for by its condition one can determine whether the obstruction is in the large or small intestine.

The sausage-shaped tumor (in the case of intussusception) is pulled up into the wound and its topography carefully noted and the integrity of the gut determined. If there are no adhesions, if

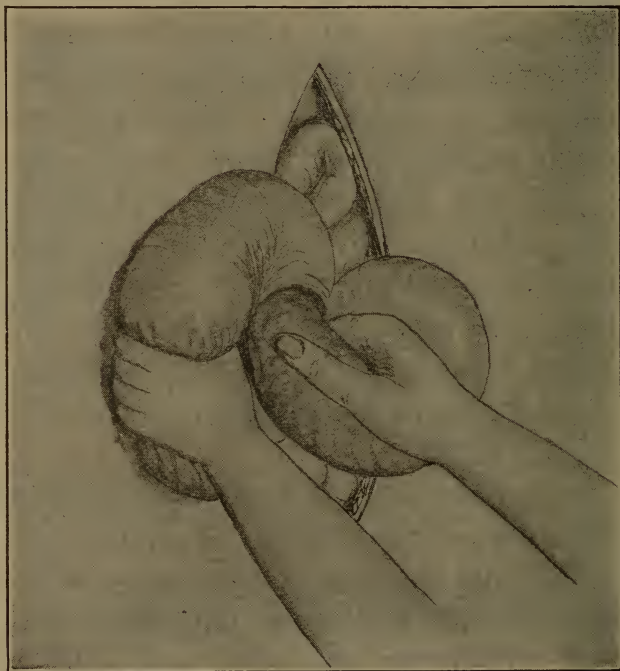


FIG. 434.—Senn's method of performing taxis in reducing an invagination.

there are no appearances of gangrene; in other words, if the accident is recent, try to reduce the bowel.

(3) *Disinvaginate*, following the procedure of Senn, which has for its aim first to reduce the edema. This is to be accomplished by steady and uninterrupted manual compression of the tumor.

As soon as the swelling is reduced, grasp the bowel below the tumor and press gently but firmly against the apex of the intussusceptum, at the same time making easy traction at the other end (Fig. 434). Remember it is easy to tear the bowel or mesentery.

When the bowel is reduced, examine again for gangrene. If there are points of disintegration, cover them in by Lembert sutures. If the whole segment of the bowel is gangrenous, it must be resected; or if doubtful, retained in the wound for further inspection. If the bowel is not impaired, wash and return; and the operation is completed by the repair of the abdominal wall.

If, as Senn says, repeated attempts at reduction fail, one of two courses must be pursued: the establishment of an intestinal anastomosis or resection of the invaginated portion; but the latter, on ac-

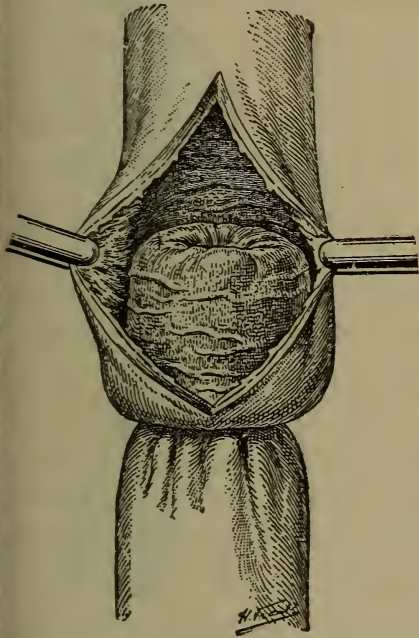


FIG. 435.—Intussusceptum exposed.
(Guibe.)

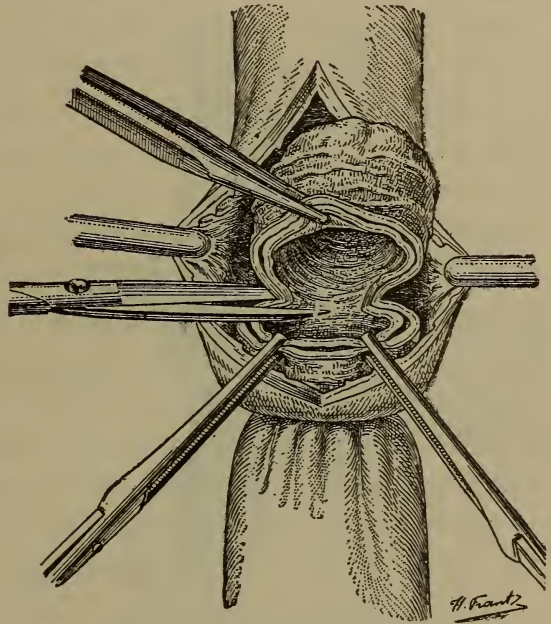


FIG. 436.—Intussusceptum resected.
(Guibe.)

count of the time required, must not be undertaken unless the invaginated parts are gangrenous.

The anastomosis between the parts of the bowel above and below the invagination may be accomplished by suture or the Murphy button. The technic of resection of the invaginated portion is represented in Figs. 435, 436, 437, and 438.

The predisposing cause of these attacks of intussusception is often acute indigestion.

The pain, which is the first symptom, is often merely colicky at first, but later may be persistent. Vomiting is common but not

nearly so severe as in other forms of obstruction, nor does it appear so early. The temporary relief following the vomiting is characteristic of intussusception. The nearer the duodenum the invagination is situated, the more severe the vomitus. Rigidity is not an early symptom. Distention is absent until late. Tenderness is also a late symptom; indeed, in the early stages, pressure may give relief.

The presence of a tumor is of great diagnostic value; it is usually movable, hard, and resistant. Its size gives no idea of the amount of

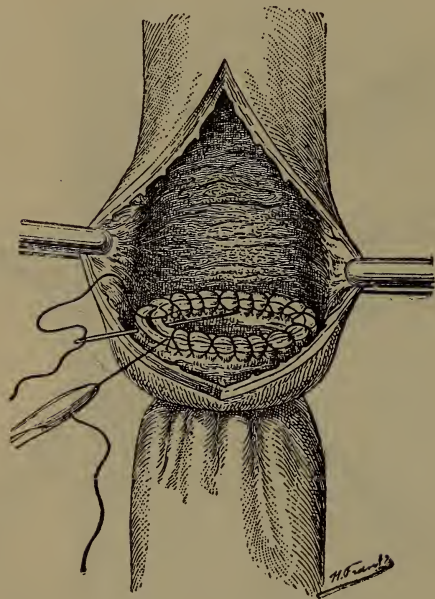


FIG. 437.—Anastomosis after resection.
(Guibe.)

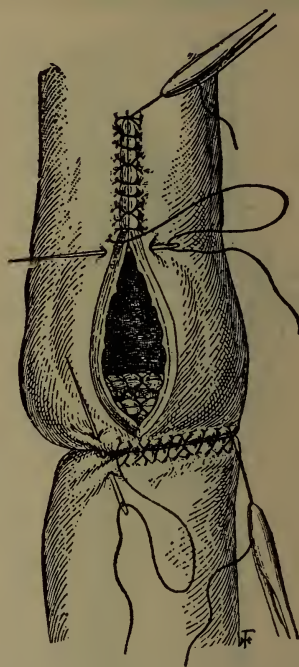


FIG. 438.—Repair of the bowel and application of Lembert sutures over the site of anastomosis. (Guibe.)

bowel involved. Tenderness is a severe and early symptom; thirst not marked. Early diagnosis and early operation are the life-saving factors in these cases.

POST-OPERATIVE ILEUS

The acute obstruction of the bowel which may—which too often does—follow laparotomy is one of the tragic accidents of surgery. An operation of comparative simplicity may terminate uneventfully; the patient rallies from the anesthetic, seems to feel well, and with

the family is happy at the thought of danger passed. Twenty-four hours pass and it is noticed that the temperature falls to subnormal perhaps, and then begins slowly to rise. The pulse, at first 90 to 100 and of fair volume, slowly increases in rate while decreasing in force. The patient's mind, perfectly clear in the first instance, begins in a little while to be disturbed, and he grows anxious as to the outcome or perhaps calmly forecasts the end.

In the meantime the tympanites has become marked, but no gas passes per rectum; and there is no sign of movement or peristalsis, in the distended gut. The pain is not severe, the chief distress is want of air; the patient complains that he cannot get a good breath; nausea develops, and finally continuous vomiting. If, now, the ordinary means of relief of gaseous distention fail and the symptoms do not in any respect improve, one may conclude that he has to deal with an intestinal paralysis. In simple tympanites the pain is colicky in its nature, there is little disturbance in pulse and temperature, the vomitus is more nearly normal in character. But in spite of these distinguishing features, it may be impossible to say, during the first few hours, whether the obstruction is serious or not. In any event, certain measures should be employed: If there is much nausea or any evidence of gastric dilatation the stomach should be washed out and $\frac{1}{20}$ grain calomel given every half-hour for at least ten doses. At the other end of the alimentary tube, the attempt at relief is begun with an ordinary soapsuds enema. If no flatus passes, a Watkin's enema is next to be tried, or one which consists of

Magnesia sulphate,	
Glycerin,	āā 3ij
Turpentine,	3j

A large tube should be employed, but no effort made to introduce it high. Elevate the hips and inject the fluid slowly, and thus let it find its own way up the bowel. If gastric lavage and the persistent use of enemas fail to give any relief, if the judicious use of hypodermic injections of morphin and atropia, eserine, and pituitrin are without effect to awaken the intestine or to sustain the patient's vitality, the only thing left which offers any hope is an enterostomy. This may be done under local anesthesia. The bowel through this open-

ing is to be kept washed out with normal salt solution. By this means the toxemia may be kept under control until the patient's forces rally.

But, after all, the chief treatment of post-operative intestinal paralysis is prophylactic and preventive. By washing out the stomach, by having the bowel well emptied with castor oil, by treating the exposed gut with scrupulous care, one may hope to reduce these accidents to the minimum. Slight traumatism of the mesentery in the course of the operation, slight infections introduced in the clean cases are at the bottom of these surgical disasters. If they result from infections already fixed upon the peritoneum before operation, the surgeon may have a balm for his conscience but no excuse to relax his precautions.

In all operations in which there is a diffused peritonitis in order to, prevent post-operative ileus, Heile injects 50 to 100 c.c. castor oil in a loop of the small intestine. The puncture of the gut is closed by a small silk suture. He claims excellent results. (*Zeitblatt f. Chirurg.* Leipsic, July 31, 1909.)

CHAPTER X

ARTIFICIAL ANUS: TEMPORARY; PERMANENT

TEMPORARY ARTIFICIAL ANUS—ENTEROSTOMY

An acute obstruction of the bowel may necessitate a temporary drainage through the abdominal wall. This will be the case when circumstances such as environment, lack of experience, assistance, or equipment preclude a laparotomy; or even when a laparotomy is done and it is found impossible at the time to remove the cause.

Enterostomy is therefore a life-saving operation which every practitioner must know how to perform.

The operation proposes opening the abdomen, anchoring a loop of intestine in the abdominal wound and opening this loop to secure drainage. The incision will be made ordinarily in the right iliac fossa and the opening in the bowel made above the obstruction. For that matter, one need scarcely fear that he will open into the bowel below the constriction, for it is only the distended portion that will present. It is preferable to open the cecum, but if it is not available, whatever loop presents will do.

No special instruments are required. It is a good idea to have several needles already threaded with silk No. 0 or No. 1. Local anesthesia may suffice.

Incision.—Begin by dividing the skin and fat along a line two fingers' breadth from the anterior superior iliac spine, parallel with the fibers of the external oblique—an incision about 3 inches long, whose central point corresponds to the anterior superior iliac spine (Fig. 439). Catch up the two or three bleeding points.

This first incision exposes the external oblique (Fig. 426) and the second divides that muscle in the same line. Catch up the edges of the divided muscle. In the same manner, the third incision divides the internal oblique and transversalis, and finally exposes a fibrous layer, the transversalis fascia, which is carefully divided in order to

reach the peritoneum (Fig. 428). Pick up a fold of that membrane with the dissecting forceps and incise it at its base, remembering that the distended bowel is in close contact (Fig. 422).

A reddish fluid escapes as soon as the peritoneum is opened; seize each lip with forceps and enlarge the opening, but not to the full extent of the skin wound. Restrain the bulging gut with compresses. Introduce the index finger and examine in various directions for a source of obstruction. Happily it may be found and relieved with-

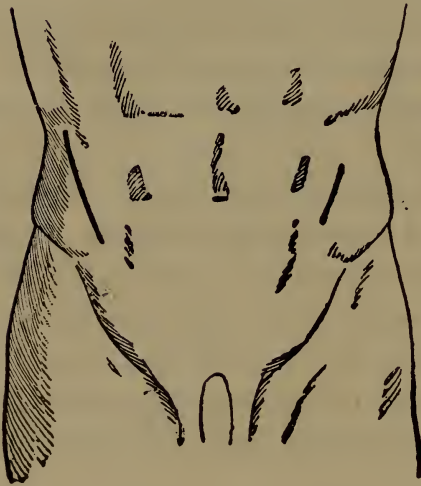

FIG. 439.—Trace of incisions for artificial anus: on the right, temporary; on the left, permanent. (Veau.)

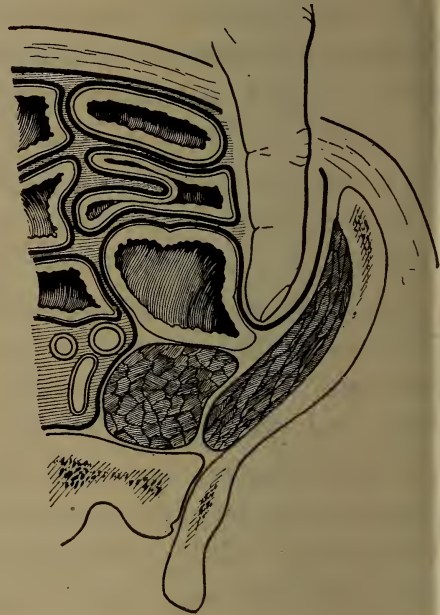

FIG. 440.—Locating the cecum. (Veau.)

out loss of time. Usually, however, it will not be and one must not persist in his search or effort at relief. Attempt next to locate the cecum, passing the index finger down into the iliac fossa, following the external wall (Fig. 440).

If successful in locating it, pull it up into the wound with index finger and thumb and hold it with two artery forceps. It is easily identified by the appendices epiploicæ and by its bands. If the cecum cannot be reached, employ any loop which presents.

Anchor the bowel. The bowel is sutured to the abdominal wall in this manner: Commence at one angle, passing the needle through

the parietal peritoneum of one side, through the serous and muscular coats of the bowel, and through the peritoneum of the opposite side.

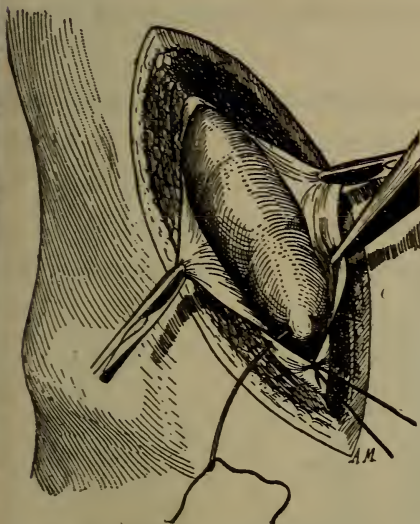

FIG. 441.—Attaching the bowel in the angle of the wound. (Veau.)

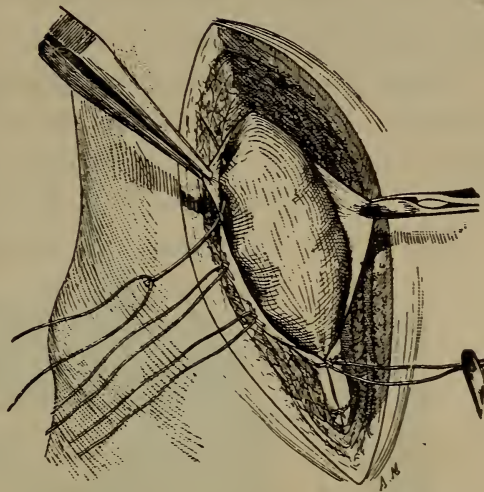


FIG. 442.—Attaching the bowel laterally. (Veau.)

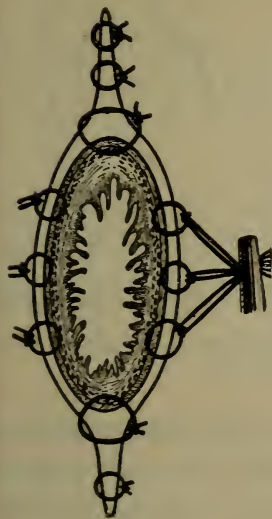


FIG. 443.—Diagram showing disposition of sutures. (Veau.)

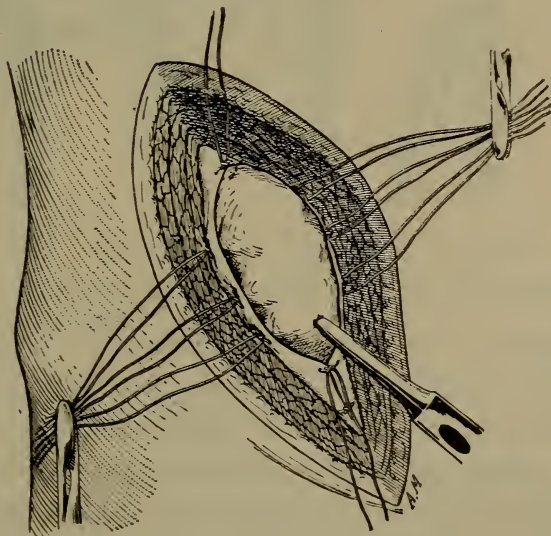


FIG. 444.—Opening of the bowel with thermocautery. (Veau.)

Tie, but do not cut the threads (Fig. 440). Now make on each side three or four "U" sutures $\frac{1}{2}$ inch apart in this manner: the needle passes through the parietal peritoneum, the mucous and

muscular coats of the bowel, and out through the parietal peritoneum of the same side. Do the same on the opposite side (Fig. 442). Collect the loose ends of the sutures of the same kind in one forceps. In placing the sutures, do not let the protruding segment of bowel get folded or wrinkled.

Suture the remaining angle in the same manner as the first and complete the repair of the peritoneal wound. The loop of bowel may not occupy all of it and these peritoneal sutures are cut short at once. (The relative position of the sutures is represented in Fig. 443.)

Now repair the superficial wound by interrupted sutures in two

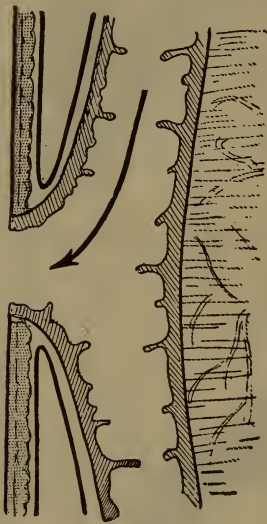


Fig. 445.—Temporary artificial anus. (Veau.)

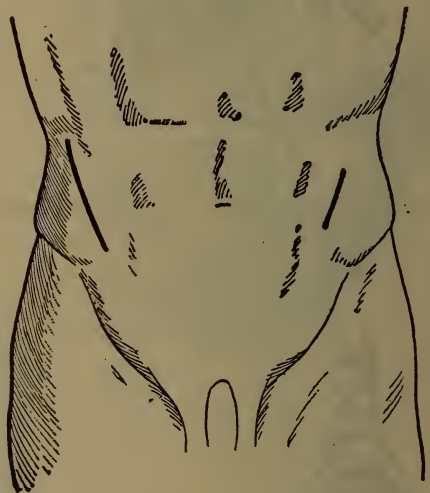


FIG. 446.—Incisions for temporary and permanent artificial anus. (Veau.)

layers, one reuniting the muscles and fascia; the other, the skin. The opening left immediately over the anchored gut is about an inch in length. Cut the threads short.

Open the bowel. This is reserved for the last, and here the long threads of the lateral bowel suture, left until this time, are used to pull the bowel well into view (Fig. 444). Incise it with the bistoury for about an inch, and there is an immediate escape of gas.

Cut short all the sutures. The bowel will not immediately empty itself. It will require possibly twenty-four hours, during which time the dressing should be changed every half-hour, afterward twice daily is sufficient.

Remove the cutaneous sutures on the sixth day, else later they will become septic. Apply ointments to the inflamed skin.

When the bowel is once emptied, which may require as long as twenty-four hours, seek to locate the site of the obstruction and to determine its nature. See if an enema will find exit at the wound or if an injection at the wound will discharge per anum (Fig. 445). A

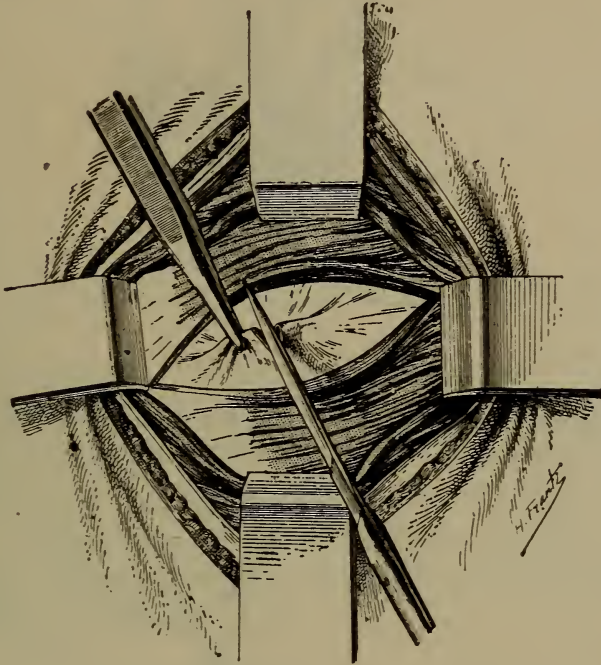


FIG. 447.—Opening the peritoneum. (*Guibe.*)

month later when the patient has regained his strength, if the bowel has not become normal, send him to a specialist.

PERMANENT ARTIFICIAL ANUS

This operation, palliative in the treatment of cancer of the rectum, comes within the scope of every doctor. It may even be regarded as an emergency. There may come a time in the history of the case when the content of the bowel can no longer pass and the pain is unbearable. Then the operation will give great relief. The patient suffers little pain after the operation, gains in weight, believes that he is going to get well, and so dies happy.

In this case, the opening is to be in the sigmoid; it may need to be

large. The bowel is completely divided transversely and the two ends anchored separately in the wound.

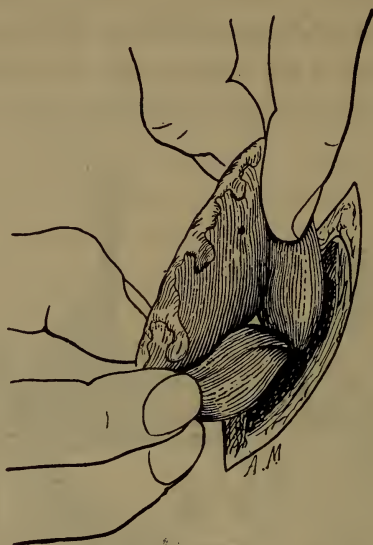

FIG. 448.—The sigmoid flexure drawn out through the incision. Note the appendices epiploicæ. (Veau.)

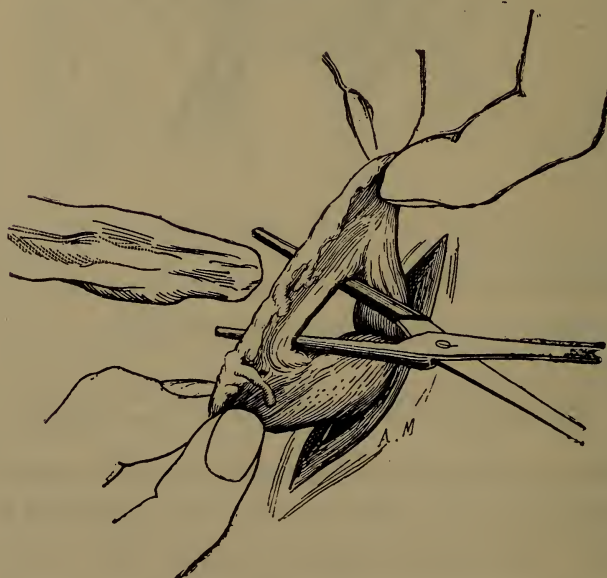


FIG. 448.—A forceps used to make an opening in the mesentery. (Veau.)

The operation is best done in two stages. In the first, the sigmoid is drawn out and permitted to acquire adhesions. Subsequently the loop is resected.

First Stage.—An *incision* 2 inches in length is made obliquely over the left iliac fossa, a couple of fingers' breadth within the anterior superior spine. The lower end of the incision reaches to just above the level of the spine (Fig. 446). Dividing the skin and cellular tissue, there will be some small vessels to ligate. The fibers of the

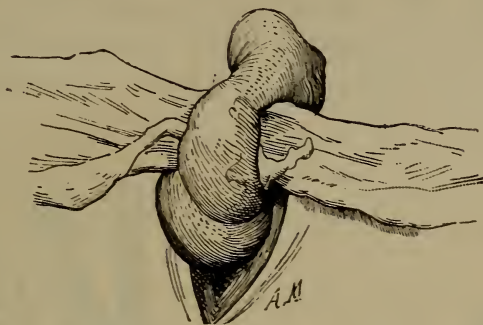


FIG. 450.—Bowel retained by strip of iodoform gauze. (Veau.)

external oblique appear, running parallel with the incision. Separate them in the line and length of the skin incision by blunt dissection. Widely separate the two portions of the muscle with retractors.

In the bottom of the wound are seen the fibers of the internal oblique and transversalis which lie at right angles to the external oblique. Open through them by blunt dissection in the direction of their fibers and retract (Fig. 447).

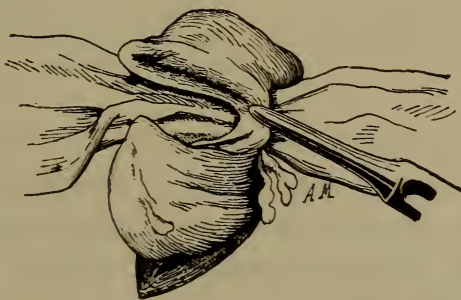


FIG. 451.—Dividing the loop with the thermocautery. (Veau.)

Divide the transversalis fascia and expose the peritoneum. This is opened and its lips seized with the forceps. Remove the retractors

Search for the sigmoid. Introduce the index finger into the iliac fossa, following the posterior wall until arrested by the meso-sigmoid. In this manner locate the sigmoid flexure, and with finger and thumb.

draw it to the surface by gentle but persistent traction. It can be felt to yield. Once the loop is exposed, the only difficulty is overcome. The sigmoid is identified by the appendices epiploicæ (Fig. 448).

Spread out the gut and find the least vascular part of the exposed mesentery and this part transfix (Fig. 449) with a closed forceps. Opening the forceps, let it seize a roll of iodoform gauze of the caliber of the index finger and draw it into place. It will hold the bowel in position (Fig. 450).



FIG. 452.—Upper orifice communicates with bowel; lower with rectum. (Veau.)

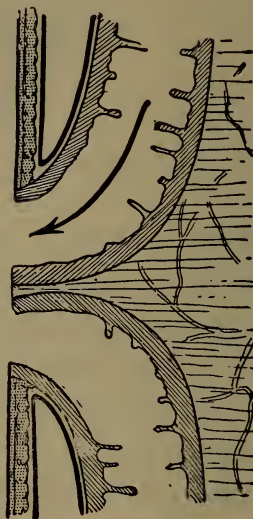


FIG. 453.—Permanent artificial anus. External opening of bowel with spur leading to rectum. (Veau.)

If the cutaneous wound is too large and does not fit closely to the projecting loop, it may be diminished by a suture or two.

Dress with sterile gauze and do not change until ready to resect, unless the dressing becomes loosened or soiled. Keep the patient on a light diet, chiefly milk.

Second Stage.—Resect the bowel. On the second or third day, when the bowel has acquired adhesions, return with a thermo-cautery and artery forceps; there might be an arteriole to ligate. No anesthesia is necessary, for the gut is quite insensitive.

The thermo-cautery is heated to a dark red (if at a white heat, there may be a little bleeding), and with it the bowel is completely

divided. Do not stop until the roll of iodoform gauze is completely exposed. The few minutes required will necessarily seem a long time, but do not get disturbed (Fig. 451). When the section is complete, the gauze may be readily removed (Veau).

Apply a dry dressing. On the second day give a laxative. After a while the patient will be able to regulate his passages to a degree.

Through the lower orifice the cancer may be douched and the fluids will find their way out per anum (Figs. 452, 453).

Do not neglect to warn the family that the end must come within from eight to fifteen months. As for the patient, it were better to ease his mind by vague references to the future closure of the wound so repulsive to him.

CHAPTER XI

STRANGULATED HERNIA

What doctor in general practice has not had his experiences with strangulated hernia? And how many have escaped the conviction that it is an emergency deserving its evil fame?

But, after all, its sinister reputation our predecessors have bequeathed us and, along with it, interminable discussions touching the agent of constriction and the indications for taxis.

To-day we reverently lay aside those old notions, for we know that no other equally dangerous condition yields better results to appropriate treatment. By "appropriate treatment" is meant *early operation*. The indications for operation there is no need to discuss, for operation is always indicated.

Taxis is an exceptional procedure, permissible only as a tentative measure under certain well-defined restrictions; and even then to be used with fear, for who can certainly tell that he has not reduced a gangrenous and perforated gut; and who but the most experienced may not be misled by certain forms of incomplete reduction?

The danger from strangulated hernia was formerly supposed to arise solely from interference with the circulation and the consequent gangrene of the incarcerated loop, and the attention was centered chiefly upon the mechanical element. It was perhaps legitimate upon that hypothesis to treat expectantly or by repeated efforts at taxis an incompletely strangulated hernia.

But now it is definitely determined that the chief source of danger is *septic absorption*, and in a given case long before the incarcerated bowel has ceased to be viable, the patient may be overwhelmed by toxins of a virulent type. It is this systemic poisoning that makes strangulated hernia dangerous, and which especially makes the operation dangerous. It is for that reason that procrastination is

so often fatal. So frequently it happens with these attacks that after hours of waiting, or after repeated efforts at reduction, the patient is finally turned over to the operator; and though the operation be of short duration and simple, yet the patient dies, for the reason that his powers of resistance were paralyzed by sepsis unsuspected. He was a veritable victim of delay.

The thought to be kept uppermost, then, in treating strangulated hernia is not so much that the bowel is becoming gangrenous as that sepsis is imminent.

The diagnosis is not difficult, as a rule. Usually the patient is known to have a hernia; suddenly it becomes painful and irreducible; the bowels refuse to move and become tympanitic; nausea and vomiting ensue; and there are signs of circulatory depression. The general symptoms are, in fact, those of *intestinal obstruction*. The face is drawn and pinched, the lips white and the eyes sunken. There is a clammy sweat. The symptoms may all be mild at first, especially when the obstruction is not complete, or in the aged or debilitated, or if the bowel is surrounded by omentum which at first bears the brunt of the compression. It must be kept in mind that this mild onset may be wholly deceptive.

It may be necessary to distinguish between an inflamed and obstructed irreducible hernia on the one hand and strangulated hernia upon the other; in the first, pain and vomiting are not so severe, there is no collapse, and an impulse in coughing can always be detected. If a hernia was not before suspected, a careful examination for one must be made in cases of intestinal obstruction. Small sciatic or obturator herniæ are easily overlooked. This is likewise true of small femoral hernia in fat subjects.

Torsion of the spermatic cord or strangulation of an undescended testicle may simulate strangulated hernia, but the indurated and very painful inguinal tumor, together with the cryptorchism, should suggest the nature of the attack.

As Senn says, the differential diagnosis between a suppurative lymphadenitis in the groin and a strangulated inguinal hernia may be very difficult. He points out the necessity for caution in using the knife if the inflammatory swelling is single and occupies the site of a femoral hernia. In such a case the supposed gland should be

approached by a careful dissection. If it proves to be a hernia no harm is done.

An accumulation of peritoneal fluid in the imperfectly closed processus vaginalis in the very young may give rise to symptoms of strangulation, but strangulated hernia is rare in infants. In such a case, inversion of the patient for a few minutes will often empty the sac and clear up the diagnosis.

As has been said the indication for *treatment* is *operation* as soon as the diagnosis is made. There are, however, exceptional instances in which judicious efforts at taxis may be applied without greatly prejudicing the prognosis. But it is recommended without enthusiasm and only out of due respect to those circumstances of time and place which seem to preclude immediate herniotomy.

Taxis and operation, then, represent the sole measures of relief. Certainly no doctor at the present time would expect anything but harm from the use of drugs.

As Senn says (Practical Surgery), no modern physician would for a moment consider seriously the therapeutic value of nauseating enemata, or the internal use of relaxing antispasmodic remedies, so much relied upon in facilitating taxis before herniotomy was shorn of its great mortality by the introduction of antiseptic surgery.

Taxis.—Taxis, or the reduction of a hernia by methodical manipulation without instruments, is permissible only under these circumstances: (a) The case is seen soon after the strangulation began; the hernia is of moderate size; the abdominal symptoms are not severe.

(b) The patient is an old man debilitated, manifestly a poor subject for an operation; he has had trouble before; it is only a few hours since his hernia became irreducible.

Under these circumstances use taxis, and it will not be dangerous if properly applied and *not repeated*. The further proviso must be made that if it fails an immediate operation must be done. In the milder cases Senn advises that taxis may sometimes be facilitated by administering a dose of opium and giving a high enema. A full hot bath in many instances has an excellent effect.

In the severer cases a general anesthesia is always required. Before beginning the anesthesia prepare the patient for operation so that

if taxis fails no time need be lost and a single anesthesia will serve both for the taxis and the operation. Chloroform is usually preferable to ether if it is expected that taxis will succeed. It permits a greater relaxation.

Technic of Taxis: Inguinal Hernia.—Elevate the hips, flex and separate the thighs in order to relax the external ring. Grasp the tumor with the right hand (hernia on right side) so as to compress it uniformly with the tips of the fingers and thumb. Seize the neck at the external ring between the thumb and forefinger of the left hand. While the right gently compresses the tumor, the left empties the gut by stripping in the direction of the external ring at first, and later along the inguinal canal. The sole aim of this first maneuver is to empty the gut. The manipulations must be made methodically, without interruption and without force. If compression reveals the presence of a doughy mass, it is omentum, and as it probably occupies the lower part of the sac it will be better to compress nearer the neck in order to deal more directly with the intestine. Sometimes, to make traction on the tumor while the fingers at the neck continue the kneading will start the bowel contents toward the abdominal cavity. If the tumor under these manipulations grows smaller and softer, it is some guarantee of success. When the bowel is sufficiently emptied, it then becomes reducible and its return to the abdominal cavity is announced by a gurgling or a marked sense of yielding.

When the bowel is reduced, the omentum, if present, should be returned in the same manner. One should not persist if the mass is thick and adherent for there is risk of rupture of an omental vessel, which may be followed by hemorrhage, all the more grave because unperceived.

After the hernia is reduced the patient must be put to bed and no food by mouth permitted for at least twenty-four hours. Before getting about, a truss must be fitted.

If after ten or fifteen minutes of gentle effort the hernial tumor remains unchanged in size and hardness, it is a waste of time to prolong the procedure. It cannot be said too often that repeated attempts are injurious, becoming with each repetition more and more harmful and illusory.

It may happen that after the hernia has been apparently reduced the *symptoms of obstruction still persist*, or even if at first relieved, appear again. The tympanites augments, the nausea and vomiting continue, and the signs of sepsis progress. It is evident that something is amiss. One of several things may have happened, but no time is to be wasted in conjecture, for only the operation which must follow will definitely clear up the doubt.

It may be that the hernial tumor has been reduced *en masse*. The hernial sac and its contents have been carried through the external ring without having changed their relations and the constrict-

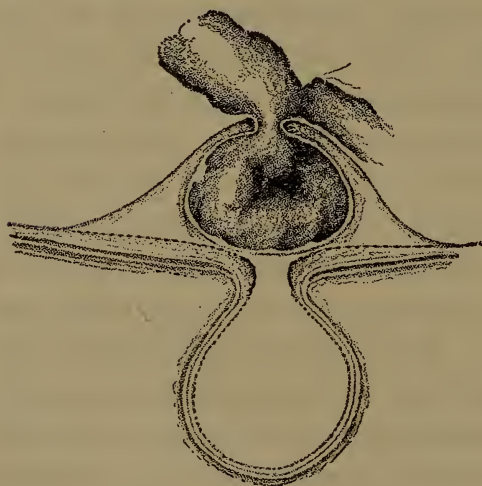


FIG. 454.—Strangulated hernia reduced
“*en masse*” (Moullin.)

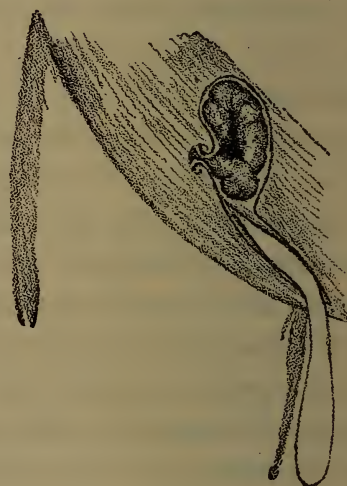

FIG. 455.—Incomplete reduction of strangulated loop. Hernia in a diverticulum. (Moullin.)

tion persists (Fig. 454). This can occur in recent hernia in which the sac is not adherent and is most common in the direct form of inguinal hernia.

It may be that instead of entering the peritoneal cavity the herniated loop has entered a diverticulum of the sac near the neck and there becomes once more strangulated (Fig. 455).

It may be that the neck of the sac has torn loose from the rest of the sac and has been reduced with the gut, the strangulation still being maintained (Fig. 456).

Again, a rent may be torn in the sac and the gut escaping there-

from pushes up between the peritoneum and the abdominal wall (Fig. 457).

Finally the reduction may have been complete, but the gut was gangrenous or ruptured and a general peritonitis follows, due to the escape of the intestinal contents; or the peritonitis may even be due to the infection from the septic fluids in the sac.

Femoral and Umbilical Hernia.

—These forms of strangulated hernia require the same modes of procedure as the inguinal but are likely to present more obstacles. In the case of femoral hernia, if complete, the pressure must be made downward toward the saphenous opening at first, and then upward along the femoral canal.

In the case of umbilical hernia the pressure must be made toward the umbilical ring. Often the Trendelenburg position is helpful. The constant effort is first to empty the gut and then reduce it.

In both these forms of hernia the gut may be enveloped by a mass of omentum which may not be reducible and thus gives rise to some doubt whether the gut has been reduced.

Operation for Strangulated Hernia: Inguinal Hernia.—To repeat, as soon as a hernia habitually reducible becomes painful and irreducible and is accompanied by the signs of beginning prostration, regard it as strangulated, and, aside from the exceptional cases indicated, operate at once. Do not wait for fecal vomiting for that is the last signal of exhausted nature—the precursor of death.

General anesthesia is usually necessary, although in some cases of

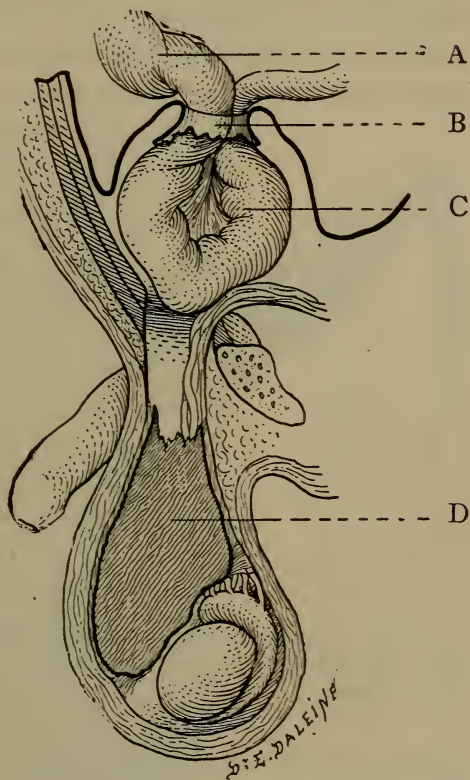


Fig. 456.—Strangulated hernia reduced "en masse." A. Upper end of the loop. B. Neck of the sac torn off and reduced with the bowel. C. Reduced loop still strangulated. D. Scrotal portion of sac. (Lejars.)

profound sepsis local anesthesia with cocaine or stovaine suffices, using Schleich's formula and injecting the various layers just before dividing. No special instruments are necessary.

Surgical Anatomy.—The special points to be remembered are the situation of the abdominal rings, the relations of the external and internal oblique and transversalis muscles to the inguinal canal, and the location of the deep epigastric artery.

The external ring in the aponeurosis of the external oblique lies just above the spine of the pubes. The internal ring in the transvers-

alis fascia lies $\frac{1}{2}$ inch above the middle of Poupart's ligament. The deep epigastric artery passing vertically between the two rings, lies between the transversalis fascia and the peritoneum.

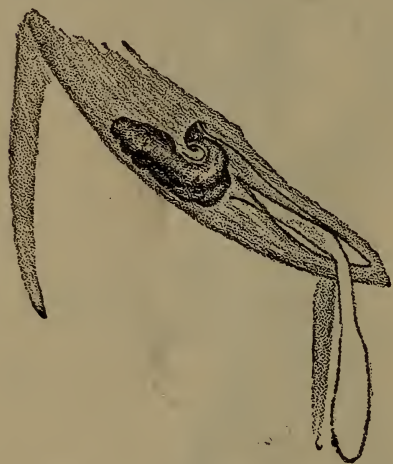

FIG. 457.—Imperfect reduction by taxis. Hernia outside the ruptured sac. (Moullin.)

The chief condition of operating well is to see and recognize what is to be divided. The coverings enumerated with such care by the textbooks will not be distinguished, but there is little danger of cutting into the intestine, for before it can be reached the sac must be opened, and that is announced by the escape of a

characteristic sero-sanguineous fluid. The greatest injury to the bowel is at the site of constriction, which may be at the external ring, the internal ring, or the neck of the sac.

The preparation of the field of operation must be painstaking. The pelvis must be shaved and scrubbed; the adjacent abdominal and inguinal regions and the scrotum must be thoroughly disinfected; and the penis after cleansing wrapped in a sterile compress.

First Step. Incision. Exposure of the Sac.—Begin with a skin incision extending from the internal ring down to the spine of the pubes; if it is a scrotal hernia, down to the middle third of the scrotum (Fig. 461). Go directly through the skin and layers of fat to the aponeurosis of the external oblique, dividing the branches of the superficial epigastric artery.

Expose the aponeurosis thoroughly and incise it from one ring to the other. It is easily recognized by the oblique direction of its fibers and its shiny look, and will serve during the operation as an important landmark. The lips of this wound should be caught up with forceps, especially at the external ring, to serve later as a guide in beginning repair.

Once the aponeurosis is opened the sac is exposed and the next effort is to isolate it preparatory to its incision. Separate it from

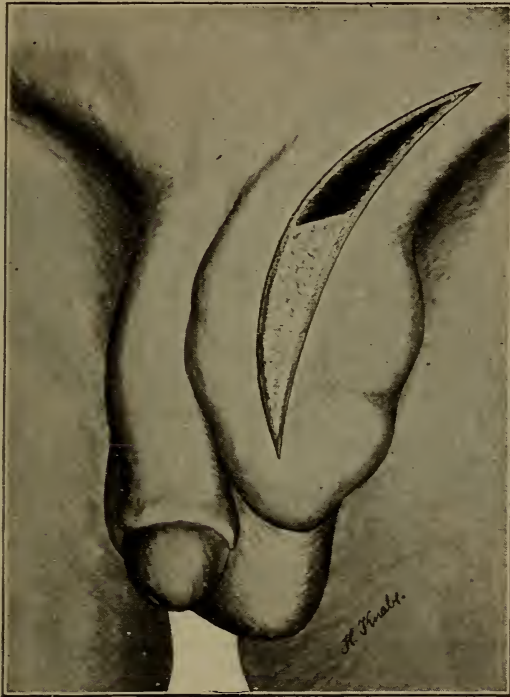


FIG. 458.—Strangulated inguinal hernia; primary incision.

the aponeurosis by careful blunt dissection around its whole circumference and divide the remaining coverings layer by layer until the sac is exposed and identified. Strip these coverings by blunt dissection, isolating the tumor up to the internal ring.

If these layers are much adherent one may be in doubt as to whether it is the sac or the intestine which he has exposed. The nature of the blood supply will settle the question, for the vessels of the sac stand out distinctly, whereas those of the bowel are not distinguishable in the uniform congestion.

Second Step. Opening the Sac.—Catch a fold of the sac with dissecting forceps and cautiously divide the base of this fold with scissors or scalpel (Fig. 459). It may be one of the connective tissue coverings that is opened; divide it the full length of the wound and so proceed until finally the hernial sac itself is opened, which will be announced by a gush of bloody serum. Occasionally this serum will be lacking, the bowel being in intimate contact with the sac, or even adherent to it, but the bowel will be recognized by its uniform coloring and will be separated as the opening in the sac is enlarged. Cautiously enlarge the opening till a finger can be introduced, and on

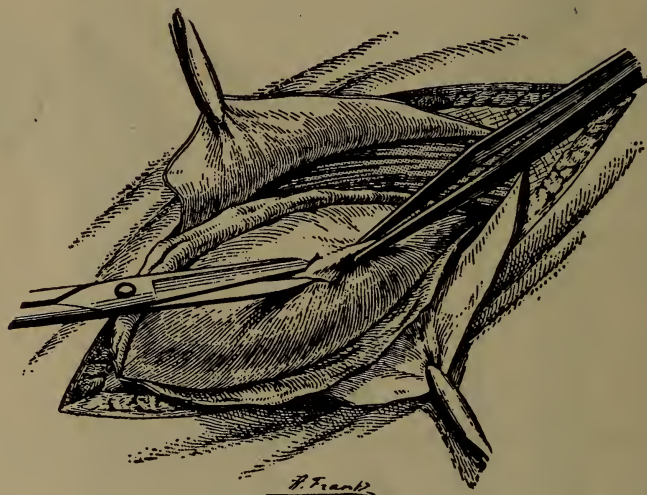


FIG. 459.—Opening the sac of a strangulated hernia. As soon as the sac is opened a sero-sanguineous fluid escapes. (*Guibe.*)

it as a guide, split the sac close up to its neck (Fig. 460). When the constricting band is reached slip the finger under it, if possible, and divide it completely. If too tight for the finger, pass a grooved director as a guide. In some cases it may be better to use a herniotomy knife, but wherever possible avoid cutting blindly. The constriction must be freely divided so that the intestine can be readily drawn down for inspection. This step is not complete till that is possible.

It may happen that there is a second constricting band higher up; in such a case the forceps, which should always be attached to the

lips of the incision in the sac, are useful in pulling it down so that what is to be divided can be seen.

Third Step. Examination of the Intestine.—It is of the greatest importance that the site of the constriction be examined, for the chief lesions will be found there. Pull the gut down and observe the line of demarcation between the healthy and injured tissue (Fig. 461).

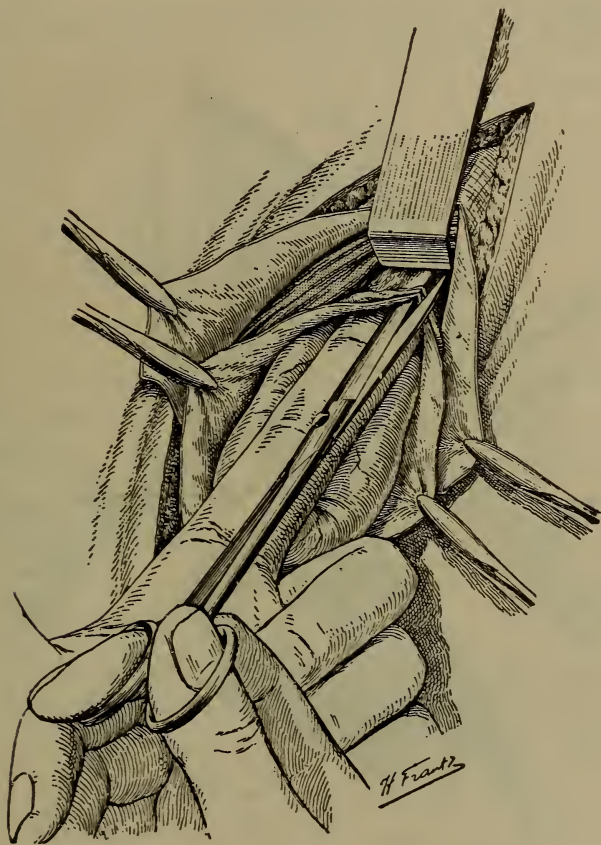


FIG. 460.—Dividing the constricting fibers of the strangulated inguinal hernia. The parts should be well exposed. (Guibe.)

One of the several conditions will be present and the line of procedure will depend upon the one which is found.

1. *The intestine is sound;* that is to say, it has a uniform, dark violet color, most marked at the site of the constriction where it is lustrous. There is no erosion of the serous covering. Douching the bowel with warm normal salt solution restores its tonicity, its rounded outline, and after a few minutes it assumes a redder color

and is to be returned to the abdominal cavity. Following this the omentum which usually presents is to be inspected. If there is a considerable mass or if its vitality has been compromised it should be resected, using one or several ligatures as the case may require. Before the stump is dropped back into the peritoneal cavity it must be carefully inspected for bleeding points and should be sponged with salt solution.

2. *The intestine is slightly injured*; that is to say, there may be

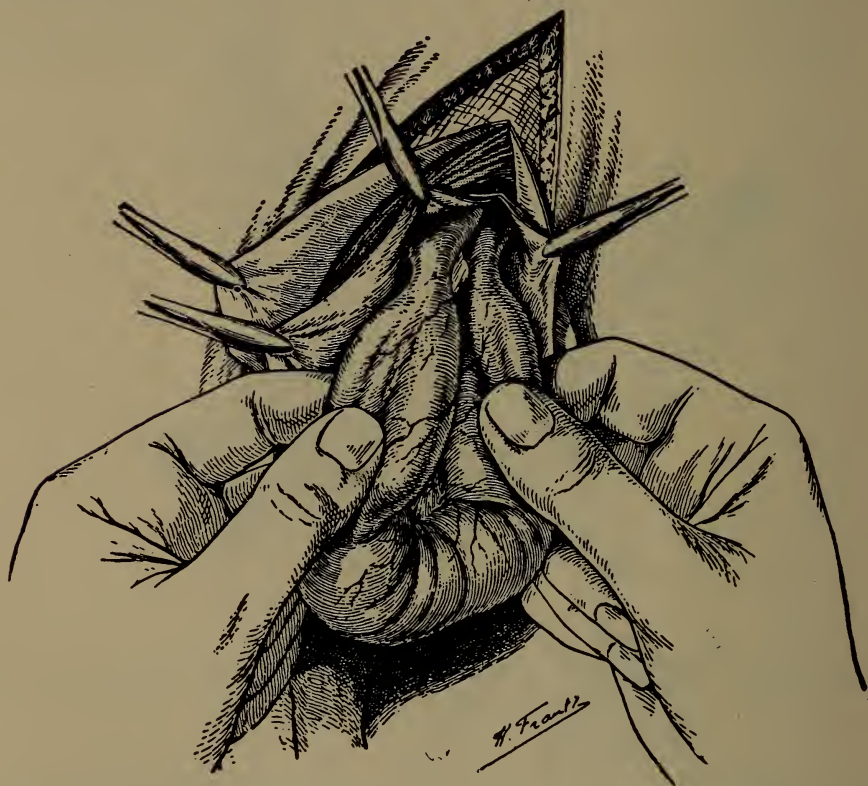


FIG. 461.—Examination of the strangulated loop. (Veau.)

several small zones of erosion exposing the muscular or even the mucous layer. Bury these areas with a few Lembert sutures, repair any injuries to the mesentery, and reduce. If the intestinal loop is long, a methodical procedure may be required to prevent further injury to tissues already compromised. The posterior segment of the loop should be reduced first, as it probably was the last to come down; in the meantime the anterior segment must be carefully supported. The least rudeness may result in a tear.

3. *The intestine is doubtful*; that is to say, it has a color mottled gray and purple. It does not recover its form under the douching, but stays collapsed and flattened. Under these conditions it may not be possible to say whether it is gangrenous or not, but it should not be reduced.

Treves, however, advises reduction under these circumstances, remarking (Operative Surgery, p. 534, Vol. II) that whatever theoretical objections to this procedure may exist, practice has shown that it may be safely carried out, assuming that this applies to a bowel which is not actually gangrenous, but in a condition which may be termed "doubtful." It is remarkable to what extent these doubtful intestines recover. The idea is that the peritoneal cavity is the most favorable site for recovery.

If the operator is inexperienced and not certain that he can distinguish between the bowel, possibly gangrenous, and that which has actually lost its viability, he must wait. Wrap the loop in moist gauze, and after twelve hours examine again. It may be gangrenous or it may be viable, lustrous, reddened, rounded, and impels the belief that it will become normal. With that belief, reduce it slowly and carefully, breaking up the slight adhesions which have already formed.

4. *The intestine is obviously gangrenous*; that is to say, the serous coat has lost its luster, is blistered in spots, and can easily be stripped off with the fingers; its color is ashen or even black, sometimes mottled with white patches; there is a characteristic odor; the tissues are friable; and there may be perforations.

In this case there is but one of two things to do: either anchor the gut in the wound and make an artificial anus, or resect the bowel.

There can be no doubt that an enterectomy is the ideal procedure since it eliminates a source of danger and permits the radical cure of the hernia, but it is best not to undertake it unless skilled in intestinal suture (which for that matter every doctor should know thoroughly how to do) for the time required may aggravate the shock and insure a fatality; but the first consideration is to save life. (See Enterectomy.) Allison, of Omaha (Jour. Minn. State Med. Assn., Jan., 1908), takes a different view: "We believe primary end-to-end anastomosis unjustifiable for, though we escape shock and peritonitis,

there yet remains the danger of permanent obstruction due to circulatory and septic changes, or a fatal paralysis due to distention and toxemia. Artificial anus offers the best way out. The two-stage operation is safer than the primary."

If an artificial anus is considered safest, pull enough of the gut out to reach sound tissue. Pass a catgut suture through the abdominal wall—that is, through the aponeurosis and the parietal peritoneum—and then through the superficial coats of the bowel, then out through the abdominal wall again to make the letter "U." Employ four such sutures at the cardinal points. To the gangrenous loop apply a moist antiseptic dressing, changed hourly if the intestine was perforated. If the intestine was not perforated, do not open it at once, but wait a few hours till adhesions form.

It is then to be opened and the dressings must be frequently changed, for the discharge will be abundant. Later the fistula may gradually close of its own accord, more and more of the bowel contents passing by the rectum; or to cure the fistula a difficult operation may be necessary. (See Temporary Artificial Anus.)

Fourth Step. Ligation and Amputation of the Sac.—In every case where the bowel may be returned to the peritoneal cavity, the treatment of the sac is of the greatest importance. After the intestine and omentum have been reduced proceed to disinfect and to dissect the sac, if this has not already been done, remembering that the structures of the cord may be very intimately connected with it and hard to separate. In the strangulated cases the sac is usually thick, but in the congenital cases it may be thin and friable. It is best to begin by separating the sac completely from the cord at one point, and then the dissection may proceed first toward the scrotum and then toward the peritoneum. In some cases it is best to make an incision through the whole circumference of the sac being careful not to divide the main vessels of the vas, the two portions being then dissected separately, carrying one down to the scrotum if necessary; the other, to the internal ring. Dry gauze dissection is the best method of separating these structures, as a rule. When the sac is completely isolated the neck is to be freed quite into the abdominal cavity, and then a finger is to be passed into the opening that any omental adhesions may be detected or any concealed hemorrhage.

Next, the sac is to be twisted and then ligated; or simple ligated as high up as possible, and amputated.

In freeing the neck at the internal ring the subperitoneal fat is usually seen; at this stage the bladder may be injured, and the point is that any fatty tissues at the inner side of the ring must not be included in the ligature, for this fat may conceal the bladder.

In ligating the sac it is best to transfix it rather than use the circular ligature. If the sac has been split so high that the neck cannot

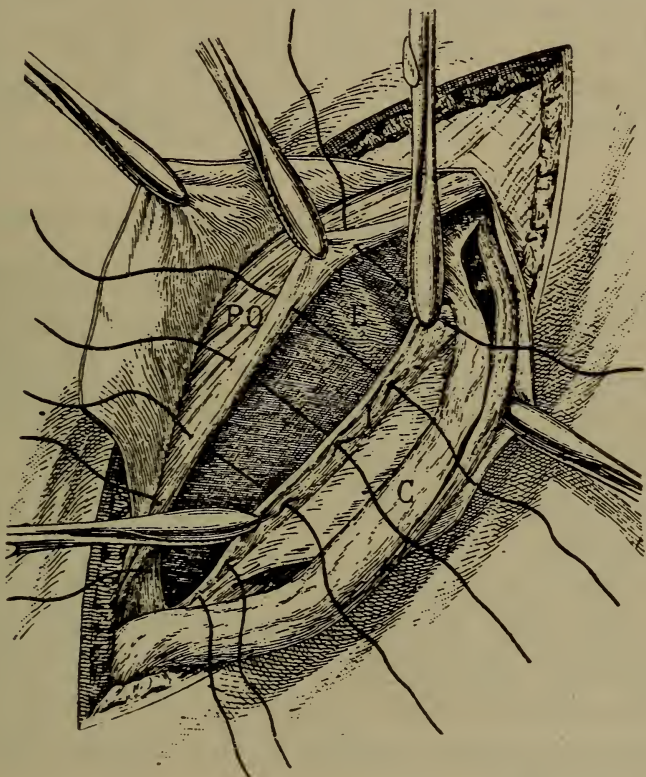


FIG. 462.—Repair after relief of strangulated inguinal hernia. Suture of conjoined tendon to Poupart's ligament. C, Cord; E, epigastric artery; PO, internal oblique. (*Guibe.*)

be defined, then the upper end of the peritoneal wound should be repaired with a few stitches so as to reconstruct the neck which is then to be ligated.

Fifth Step.—This will depend upon the condition of the patient. If his condition is serious, it is sufficient rapidly to reunite the aponeurosis and repair the skin incision. If a little more time may be used, proceed to do the *radical cure* (Fig. 462). Unless this is done

recurrence is almost certain, but the operator cannot be held responsible for that. In the urgent cases it is sufficient to have saved a life.

Whether the radical operation is attempted or not, employ drainage. The dressing must be carefully applied.

Subsequent Treatment.—The patient must have no food for twenty-four hours. It may be necessary to employ salt solution freely. A little ice may be given to quench the thirst. At the end of twenty-four hours begin with small quantities of milk. Change the dressings the second day, or sooner if much soiled. On the third or fourth day give a laxative. Remove the drain on the fifth. Remove the sutures on the eighth or ninth. Peritonitis may supervene if the gangrenous areas have not been properly treated.

POSSIBLE COMPLICATIONS IN THE OPERATION

In the operation just described, the ordinary difficulties are indicated. But there are others, rarer, which may arise to disconcert the casual operator not forewarned. The actual operation is always easier if one has in mind all the possibilities. There may be unexpected adhesions; there may be anomalies with respect to the sac or its contents, or there may be unsuspected conditions produced by attempts at taxis.

Adhesions must be anticipated when the hernia is large and has been for a long time irreducible, and under these circumstances special precautions must be taken not to wound the bowel in opening the sac. The adhesions if recent and soft may be broken up with the finger or grooved director keeping in close contact with the sac so as to avoid the bowel.

If the adhesions are old and the union between the bowel or omentum with the sac firm and fibrous, it will be necessary to divide them with scalpel or scissors, but this is a procedure requiring patience and a delicate touch. If necessary, long, band-like adhesions may be divided between forceps and subsequently ligated.

If, following the decortication, the raw surfaces ooze to any serious extent, apply hot, moist compresses for a moment, and either this will check the bleeding or at least reveal the site of the larger vessels to be caught up with forceps. Usually a few applications of the hot

compresses will entirely suppress the oozing, or at least to such degree as not to contra-indicate reduction; for when the bowel is no longer bent and the circulation no longer interfered with the oozing will spontaneously cease.

But it is chiefly injury to the bowel which is to be feared, not so much because the rent may be difficult to repair as that some of the septic contents of the bowel may escape.

If the adhesions *cannot be broken up* the only thing left is to remove the source of the strangulation and leave the bowel outside. Occasionally it will be found that the source of strangulation is in some of the adhesions rather than the rings, or the neck of the sac; or, again, so much scar tissue in the bowel wall leaves it inert and paralyzed. All these difficulties are more likely to occur in the neglected cases.

A hernia of the cecum or sigmoid may present difficulties depending upon adhesions. It must be remembered that these two portions of the large intestine are not completely invested by peritoneum; and, in consequence, it may come to pass that when they slide down through the inguinal canal a point is reached where a part of the bowel is outside the hernial sac, and this surface acquires adhesions to the scrotal tissues. In such cases these adhesions cannot be divided for fear of wounding important branches of the mesenteric arteries, so that to effect reduction a special procedure must be employed.

In the first place, when, on opening the hernial sac, these parts of the large bowel are recognized, the neck of the hernia must be freely incised and the abdominal walls as well. In fact, one does what Lejars calls a *hernio-laparotomy*.

Next the hernial sac is separated from the spermatic cord and then an effort is made to reduce the hernia *en masse*, returning, if possible, the bowel and the peritoneal prolongation at the same time. It will be a slow and tedious process. It is greatly aided by the Trendelenburg position. If the attempt fails, an artificial anus is the last resort.

Among the *anomalies of the sac* which may bother the operator are diverticula and double compartments. One may open into what appears to be the hernial sac and find it empty. In encysted hernia the processus vaginalis may be filled with fluid which surrounds the

true hernial sac. A little study of the conditions will lead one to go ahead and find and open the true hernial sac.

The hernial sac may push in between the peritoneum and the muscular layers, bulging toward the iliac fossa or the bladder. This is the *pro-peritoneal hernia*, and when it becomes strangulated it is not likely a diagnosis will be made. Yet the presence of a tumor in the inguinal region and the signs of intestinal obstruction will demand an operation and again a hernio-laparotomy is indicated. The site of strangulation is located and the bowel treated as in the ordinary form of strangulated hernia.

In the *interstitial form* of hernia great difficulties may arise. The incision is likely to be quite different from the ordinary since it follows the long axis of the tumor. Once the hernial sac is exposed it must be freed from its adhesions to the muscles. The neck of the sac corresponds to the internal ring, and if that is the site of constriction it must be divided by cutting outward. The deep epigastric artery lies to the inner side.

After the bowel is reduced and the sac ligated, the break in the abdominal wall must be sutured, repairing the opening in each layer separately.

The contents of the hernial sac may be abnormal. At some time or other each of the abdominal organs except the pancreas have been found herniated. It is the *bladder* which most often gives rise to trouble.

It may be in the sac and appear as a second "sac" when the hernial sac is opened. It presents as a rounded, reddish tumor, perhaps as large as a hen's egg. Such a tumor should never be opened on suspicion, but a careful effort must be made to locate its limits by blunt dissection. The fact that it leads down to, and behind, the pubes clears up any doubt. It is to be reduced in the same manner as the intestine. In other instances it is without the sac, lying to the inner side of its neck and is perhaps intimately connected thereto. It may be mistaken for a thickened portion of the sac or an adherent mass of fatty tissue.

If it is opened into, the escape of urine and the evidence to the examining finger of a large mucous-lined cavity reveals the nature of the accident and imposes immediate repair.

A large hernia, easily reducible, or one whose size diminishes, following urination or the use of the catheter suggests hernia of the bladder; but, unfortunately, these signs are not available in strangulation. In every herniotomy the danger of wounding the bladder must be kept in mind.

Another point Lejars makes: One may expose a thin-walled transparent cyst at the inner side of the neck of the sac, and unwittingly open it only to find oneself working into the bladder. This transparent cyst, in nowise resembling the bladder, is due to a hernia of the mucosa of the bladder between the fibers of the muscularis.

Following the separation of the bladder from the hernial sac the urine may be bloody for a day or two. This hematuria is of little moment and soon clears up.

If the bladder is wounded its repair must precede everything else. As soon as the injury is discovered, pack around the site with sterile gauze, catch the edges of the wound with small forceps and suture, uniting the mucosa first with a continuous catgut suture, and the muscular coat with interrupted sutures, accurately applied; a third line connects the superficial tissues.

The appendix may be found in the hernial sac, either inflamed or normal. If the latter, it is to be removed in the ordinary way unless time presses, in which case one must be satisfied with reducing it.

If the symptoms of strangulation arise in consequence of an inflamed and herniated appendix, they may differ somewhat from those ordinarily observed. There will be the same tendency to collapse, the vomiting, the tympanites; but constipation may not be complete, and the hernial tumor, in addition to being swollen and painful, may be reddened and edematous.

No one should think of taxis under these circumstances: as immediate operation is indicated. Regarding these grave cases, Kelly says (*Vermiform Appendix and its Disease*, page 793) where there is suppuration in the sac it must be drained, and here as well as in the cases where there is gangrene in the appendix, resulting from strangulation, the utmost care must be observed in handling the diseased tissues in order to avoid inoculating the peritoneal cavity. If the diseased portion is found to extend up into the peritoneal cavity, the

operator must at all hazards discover the upper limits of the infection and resect the bowel in its healthy portion.

Moreover, he must do this with the least possible manipulation and traction upon the parts, preferably by enlarging the abdominal opening in the direction of the inguinal canal while protecting the healthy regions and keeping the disease well isolated by abundant gauze compresses.

When infection extends still further up into the abdomen an even wider incision must be made, if necessary, in the form of an inverted L in order to provide abundant drainage after removal of the disease. In such cases the cure of the hernia becomes a matter of secondary consideration to be taken up after recovery.

In a case seen by the author the patient was an old woman, for years affected with an inguinal hernia usually easily reduced. It became strangulated, presenting a hard painful, inflamed lump, the size of a hen's egg.

She was nauseated, in much pain, slightly febrile, only slightly tympanitic, and enemas were effective in moving the bowel. The operation revealed a strangulated appendix and nothing more. It was well exposed and resected without difficulty and with complete relief. In repairing the abdominal wall the sutures were passed through the lower edge of the external oblique, through Poupart's ligament and out through the upper edge of the aponeurosis, completely obliterating the inguinal canal. This combination is unusual—an old woman, an inguinal hernia and a strangulated appendix.

McEwen (London Lancet, June 16, 1906) reports a case in which the patient, a man of sixty-two, presented himself for an operation for strangulated hernia. Two weeks previously his hernia (of twelve years' standing) had begun to give him pain, which had gradually increased.

A large pyriform tumor occupied the right inguinal region and the scrotum, which was much inflamed. The mass was dull on percussion, there was no impulse on coughing, and it was irreducible. On opening the sac the hernia was found to consist of the appendix, held in position by a pin protruding through its wall. There was no abscess formation, yet it was not deemed advisable after removal of the appendix to proceed with the radical cure.

Regarding these unusual conditions, Lejars remarks that in beginning an operation for strangulated hernia we should expect everything and be surprised at nothing; laying aside for the moment all theoretical discussions and applying ourselves to the chief indication, not deeming our work complete until the bowel is properly reduced and lost to view in the abdominal cavity.

Oliver, of Indianapolis (Ind. Med. Jour., March, 1908), reports a case in which the hernia had grown to remarkable proportions extending as low as the knee. The mass had long been irreducible. The patient was a butcher of about fifty years of age. Following a heavy meal of "pigs' feet" and a lift, his hernia suddenly became painful and he experienced the sensation of something giving way; symptoms of strangulation in mild form gradually developed; taxis being out of the question, immediate operation was practised. On opening the hernial sac it developed that its content was the stomach in its entirety, but no gut was present. With great difficulty it was reduced. The patient's condition did not permit of any further manipulation, and shortly afterward he succumbed. Oliver expresses the opinion that the stomach had been forced down into the sac by the strain, replacing the gut.

Strangulated Femoral Hernia

Operation is even more urgent in the case of strangulated femoral hernia than in strangulated inguinal hernia. Gangrene is likely to develop earlier, and taxis is all the more ineffectual by reason of the anatomical arrangement. Especially must one be on his guard in the case of small hernia for the ring is unyielding. It is essential to have the anatomy in mind to understand this and especially in order to operate without embarrassment.

Surgical Anatomy.—Poupart's ligament stretches across the front of the pelvic region from the anterior superior spine of the ilium to the spine of the os pubis. The space between this band and the ramus of the pubis is occupied by several structures—from without inward, the iliacus and psoas muscles on their way to the lesser trochanter, the crural nerve, the femoral artery and vein, the femoral canal, and Gimbernat's ligament.

Gimbernat's ligament is a firm triangular fascia with its base directed outward and abutting the femoral canal.

The femoral sheath, a prolongation of the iliac fascia, encloses the femoral vessels. In the thigh it fits closely about the vessels.

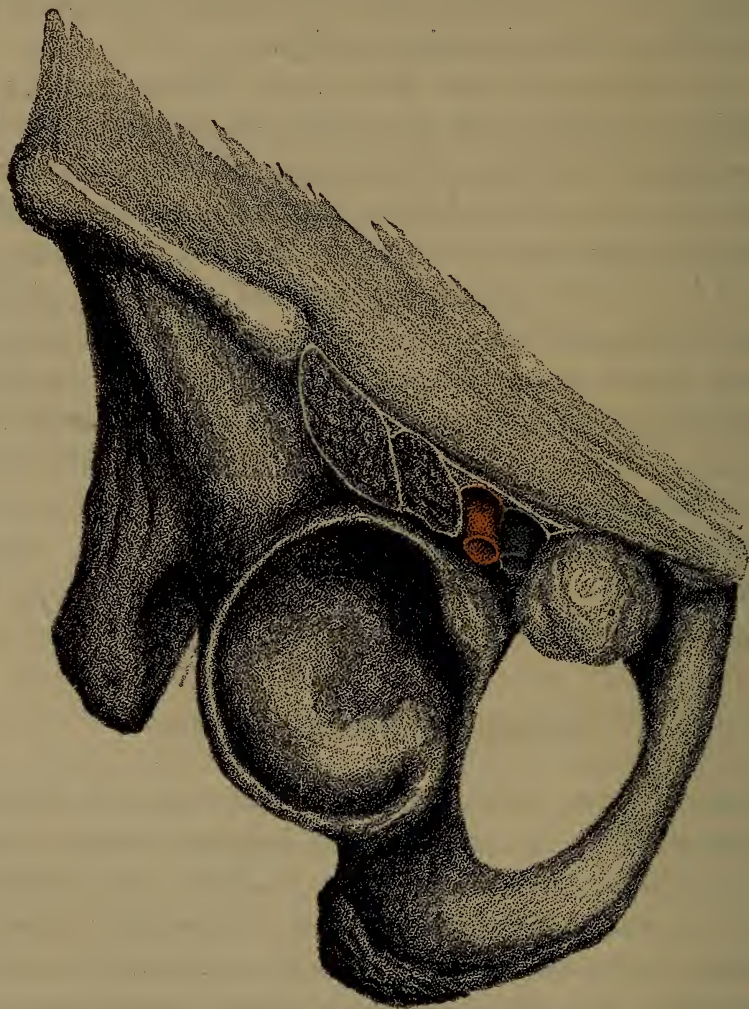


FIG. 463.—Relations of the neck of a femoral hernia under Poupart's ligament. Beneath Poupart's ligament from without inward; the iliacus, the psoas, the femoral artery, the vein, the hernia, concealing Gimbernat's ligament which is between its neck and the pubes. (*Moullin.*)

In the groin the sheath is more capacious so that there is a space left between its inner wall and the femoral vein. This space constitutes the femoral canal. The femoral canal is, therefore, conical in shape with its base above and its apex below where the sheath gets in contact with the femoral vein. The circumference of the base

constitutes the femoral ring which is bounded internally by the base of Gimbernat's ligament; above, by Poupart's ligament; below, by the ramus of the pubes; externally, by the femoral vein. The narrow orifice bounded by these structures is the usual site of strangulation of a hernia descending along this slender channel.

It is Gimbernat's ligament whose sharp edge is most likely to shut off the circulation of a loop of intestine bulging past it and which is most likely to cut into or bruise the bowel in efforts at taxis (Fig. 463).

In other cases the hernia descending lower finds the direction of least resistance toward the surface and bulges out through the saphenous opening and the cribriform fascia.

Operation.—If the operation is done early before complications, such as gangrene, have arisen, the operation for strangulated femoral hernia is simple and without special danger. Begin by *disinfecting* the whole field; the inner surface of the thigh, the groin, the abdomen, the genitals.

The *incision* may be vertical following the axis of the tumor, or oblique, below and parallel to Poupart's ligament; Lejars prefers the latter, claiming that it gives freer access to the femoral ring, facilitates the dissection of the sac and the procedures in the radical cure.

The vertical incision is probably better for large and lobulated hernia which extend well below Poupart's ligament. But whatever incision is employed must be of ample length.

The incision traverses the skin, and then a fatty layer through which ramify a number of veins tributary to the long saphenous. Having divided this layer, the sac is exposed; or, at least, the fatty envelope in which so often it is enclosed—a collection of fat which at times amounts to a veritable lipoma. The hernial sac lies immediately beneath this fat—sometimes in thin subjects immediately beneath the skin—and presents itself in divers aspects. Usually it looks like a tense and reddish cyst; often it is lobulated (Fig. 464).

Second Step.—*Isolate the sac.* Proceed to separate it from the adjacent tissues by blunt dissection, peeling it out with the fingers, and disengaging it quite up to the neck. It is essential for the later

steps of the operation that this be thoroughly done and is complete when Poupart's and Gimbernath's ligaments are well in view.

This dissection of the sac takes less time than one might expect and is greatly facilitated if one is able to find a line of cleavage between the tissues. Sometimes bursæ intervene between the sac and adjacent tissues and favor a rapid separation.

Third Step.—Open the sac; examine the contents. Once the hernial tumor is well exposed up to the constricting ring, cautiously incise the sac. Caution is required because often it is difficult to know when one has penetrated the sac and an adherent intestine may be

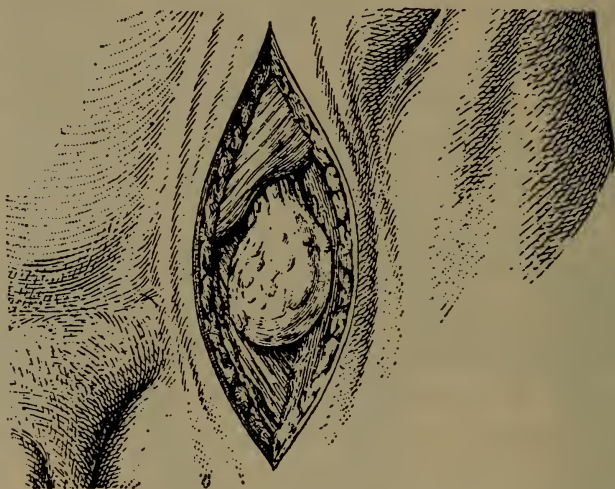


FIG. 464.—Strangulated femoral hernia: primary incision exposing hernia and Poupart's ligament. (Guibé.)

wounded. In this form of hernia the true sac may be covered by a cyst, which may be filled by bloody serum and thus simulate the appearances of the hernial sac. A moment's examination, however, shows that it is a small closed cavity without communication with the abdomen. The layers are to be cautiously divided one by one until the sac is opened into and the opening enlarged.

Catch up the lips of the wound of the sac and examine its contents. Usually, in this form of strangulated hernia, one will see a small loop of intestine, darkened, tense, and tightly constricted. Occasionally along with the omentum there may be several loops of small intestine, or the cecum, or the sigmoid flexure. Irrigate the cavity and

its contents with normal salt solution and prepare to relieve the constriction.

Fourth Step.—Relieve the constriction. The first effort should be to relieve the strangulation by stretching the offending fibers, to this end introducing a finger, if possible, into the ring along the inner side of the hernia.

Oftentimes the pressure thus exerted will, with a little effort, stretch and enlarge the opening sufficiently to relieve the constriction and to permit the necessary manipulation of the bowel.

It may not be possible to introduce a finger, and then one must resort to incision. To accomplish this a grooved director may be

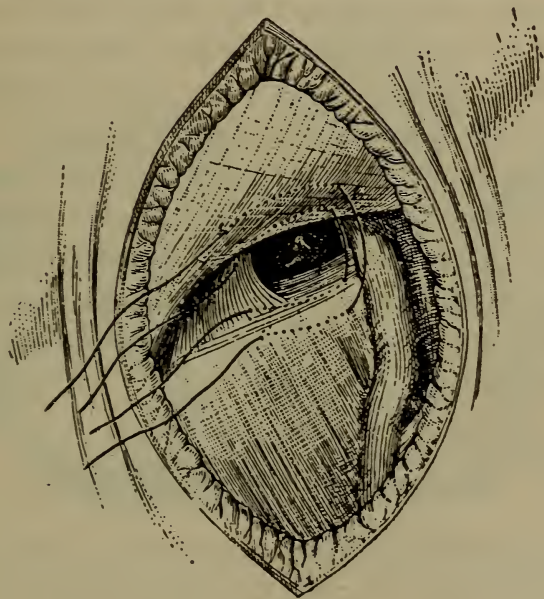


FIG. 465.—Strangulated femoral hernia: closing the femoral canal. Note manner in which sutures are passed, avoiding femoral vein at outer border.

slipped up alongside the bowel and the fibers divided with scissors or bistoury; or if the fibers are in plain view, as they should be, they may be nicked with the point of the bistoury and when room is thus made the finger may be introduced as before. The use of the herniotomy knife should be reserved for exceptional cases, where the subject is fleshy and the obstruction beyond reach and very tight.

But whatever method may be practised, one must keep to the inside, cutting inward or upward to avoid injury to the bowel or the femoral vein.

When the obstruction is removed pull the bowel down and examine it. If it is suspicious or gangrenous, treat it after the manner indicated under Strangulated Inguinal Hernia.

If it is sound, reduce it; liberate the sac around the femoral ring, ligate and resect it; and close the femoral canal. The *after-treatment* is the same as for inguinal hernia.

Fifth Step.—Close the femoral ring. Two circular sutures acting when tied after the manner of a purse string are to be passed: one including the pectineal fascia and the fascia of the external oblique; the second, more deeply placed, including the pectineal fascia, Poupart's ligament and Gimbernat's ligament.

Avoid wounding the femoral vein, which lies in contact with the outer border of the femoral ring. When these sutures are tied the external oblique is pulled down into close contact with the pectineal fascia and the canal obliterated (Fig. 465).

It remains to be said that in exceptional cases it may be necessary, in order to see what to do, to divide Poupart's ligament; or, in the male where the cord is to be avoided, to make another incision along the inguinal canal, exposing the neck of the hernia; or, following the method of Tuffier, to open directly into the peritoneal cavity through the inguinal canal.

Strangulated Umbilical Hernia

A strangulated umbilical hernia is peculiar in two or three respects. It is likely to be deceptive in that the characteristic symptoms of intestinal obstruction may be wanting. The site of strangulation is more likely to be in the sac than at the umbilical ring. But because the absolute signs of obstruction are absent and because the opening at the umbilicus seems patent, one has no excuse to delay when an old and long irreducible rupture becomes suddenly painful, with vomiting and partial constipation.

Too often, as Lejars says, we call these attacks with comparatively mild onset, *pseudo-strangulation*; and so the case drifts along while septic absorption goes on insidiously but surely. From day to day the circulation grows weaker, the abdomen more tympanitic, the vomiting more pronounced, until the vital forces are practically over-

come, at which time, too late, it is decided to operate. The expectant treatment and repeated taxis in these cases are merely methods of "losing time."

Following such practice one can confidently expect a large percentage of fatalities, though one should not hesitate to operate even in the face of such odds. Operating early, one may give assurance of excellent results. To quote Lejars again, it is not the operation which is to be feared: it is the delay.

Operation.—Careful disinfection of the whole abdominal wall; a prudent and cautious anesthesia. The *incision* may follow the

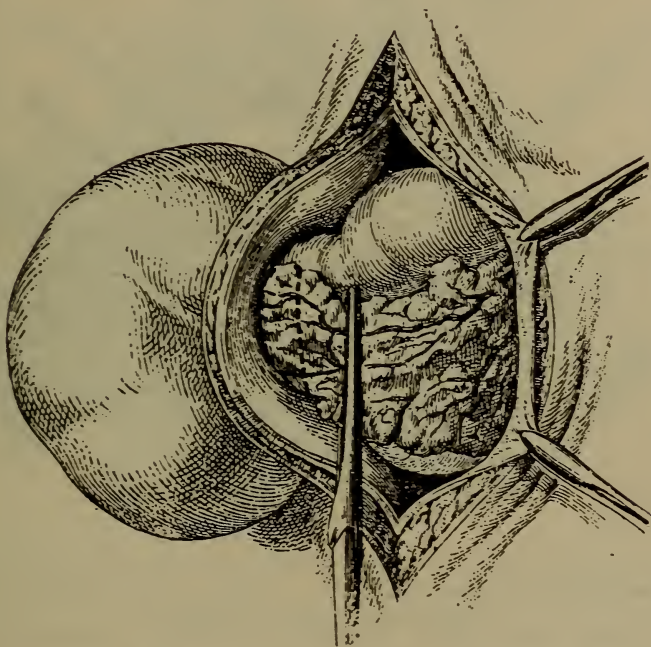


FIG. 466.—Strangulated umbilical hernia: incision skirting the base of the tumor. The peritoneum opened in the same line exposes the omentum and bowel. Omentum clamped and divided along dotted line. (Guibe.)

median line extending well beyond the tumor above and below (Fig. 466); or in the case of a large tumor, may consist of two semilunar incisions on either side of the middle line which enables one to get rid of redundant tissue.

In either case the incision must not go deep from the first for often the skin is quite thin, often adherent to the sac, and it is easy to go directly into the sac. By reason of this adhesion at the center

of the tumor, begin the dissection at the poles of the incision and work toward the center.

As soon as the skin is detached proceed to isolate the tumor, if possible, up to its point of emergence. It may not be practicable if the tumor is large and lobulated to take the time, and in such a case the sac may be opened into at once.

Second Step.—Open the sac. Detach the omentum. Nearly always on first opening the sac only omentum can be seen. It completely envelops the bowel. The fingers are gently insinuated between

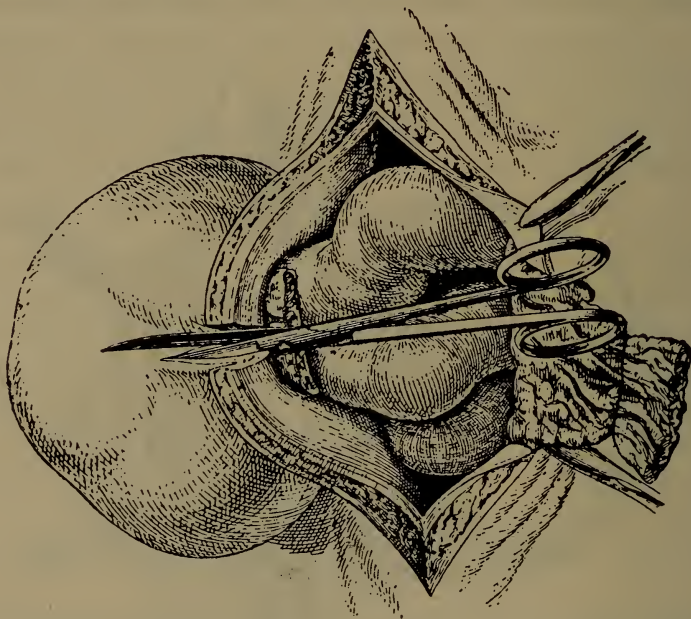


FIG. 467.—Strangulated umbilical hernia: the sac laid open to relieve the strangulation and free the bowel. (Guibe.)

the omentum and the sac, and the adhesions progressively broked down. Wherever a lobule of omentum is found encysted in a diverticulum of the sac, it must be dissected out in the same manner. Finally the entire omentum will be freed, may be lifted up, and the gut exposed. In other cases divide the omentum as indicated in Fig. 489.

Irrigate both the bowel and omentum with normal salt solution, wipe with sterile gauze and examine the bowel carefully to see that there is no danger of perforation and of soiling of the peritoneum in the process of reduction.

Third Step.—Relieve the strangulation. Oftentimes the umbilical ring may need only to be stretched a little to permit the free manipulation of the bowel; again, it may be necessary to divide the constricting fibers. This may be most readily accomplished by pulling down the omentum, slipping a finger between it and the upper part of the ring to the left of the middle line. If this nick does not give sufficient release, repeat on the opposite side.

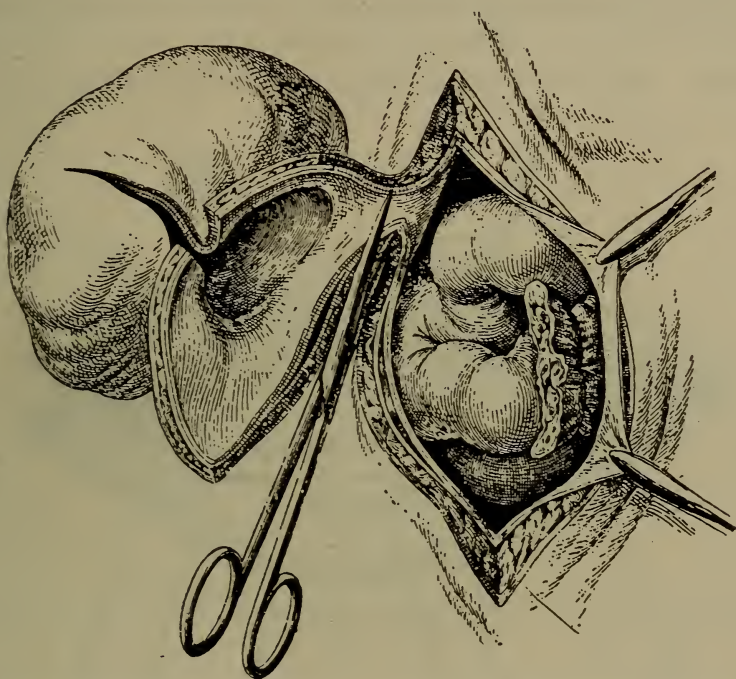


FIG. 468.—Strangulated umbilical hernia: completing section of base of the tumor. (Guibe.)

When the necessary room is obtained, ligate the omentum, resect it, cleanse the stump and reduce it that there may be nothing to interfere with the treatment of the bowel. If the omentum has been resected in the manner indicated, the tumor mass may be laid wide open in order that the strangulated loops may be well exposed and freed (Fig. 467).

Following this the incision is continued around the base of the tumor, completely removing it and leaving the various layers of the abdominal wall exposed ready for repair (Fig. 468).

With respect to the bowel, the same principle of treatment holds good as in inguinal hernia. Repair any slight defects or abrasions.

If its viability is doubtful, keep it under observation for a few hours. If gangrenous, either anchor it in the wound and make an artificial anus or do an enterectomy.

It may be that in very large umbilical hernia it is better to modify the procedure, following the plan of Mayo and others, in order to gain time.

A transverse elliptical incision is made around the tumor at such distance from the center that the redundant tissue shall be removed. Cut down to the sac. Next cautiously open the sac following the skin incision. Apply several forceps to the edges of the sac so that it

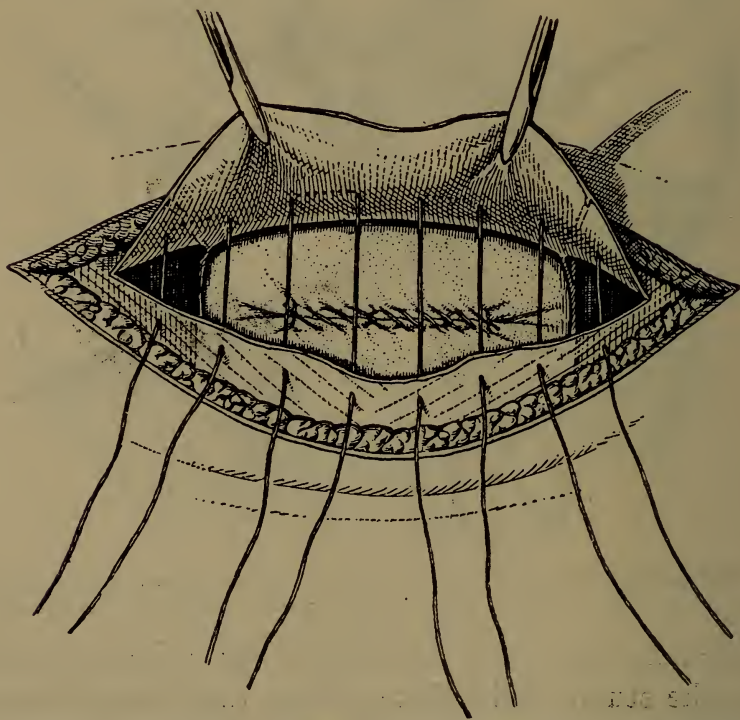


FIG. 469.—Peritoneum closed and first layer of mattress sutures for fascia passed. (Guibe.)

is constantly under control. Detach the omentum, freeing it completely up to the neck of the sac. Ligate and resect it, and working along its under surface free it from the bowel. Once detached the paquet of omentum carries with it a segment of the skin and of the sac.

The bowel is next treated and reduced. This may not be as easily done as said, for there are several circumstances under which the

bowel may push out and threaten eventration. But no effort should be made to push back the rebellious loops *en masse*.

Proceed at once to enlarge the opening, lift up the edges of the peritoneum by the attached forceps and cover the bowel with a wide compress, tucking its edges under the belly walls on all sides, as described elsewhere. As little by little the bowel is returned the edges of the compress are slipped farther under. When reduction is complete the compress is left *in situ* until the sutures are placed.

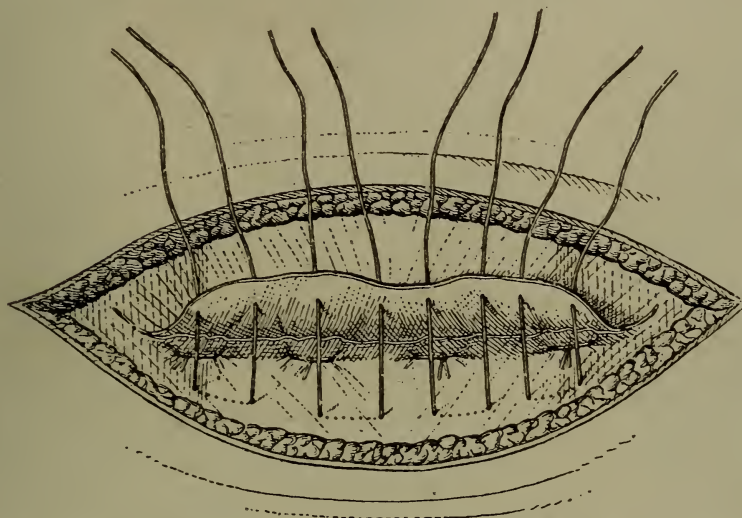


FIG. 470.—Second layer of mattress sutures completing the overlapping of the fascia. (Guibe.)

Fourth Step.—The mode of *repairing the abdominal wall* varies with the circumstances and the operator, and depends upon how much time one may take. When the condition of the patient imposes great haste it must suffice to pass interrupted sutures through the whole thickness of the belly wall and draw the edge of the wound together so that the peritoneal edges point out and the two serous surfaces are thus brought into contact. Before the last suture is tied the compress is removed; and finally a continuous suture will complete the reunion.

If more time is available, the sac is trimmed down to the peritoneum proper and its edges sutured as after a laparotomy. The sheaths of the recti muscles are opened up and the inner border of each muscle exposed. The two sides are then brought in contact and three

tiers of sutures applied; one uniting the deep layer of the rectal sheath to its fellow of the opposite side; the second uniting the two muscles; the third uniting the two superficial layers of the sheath overlapping and securing them by mattress sutures (Figs. 469 and 470).

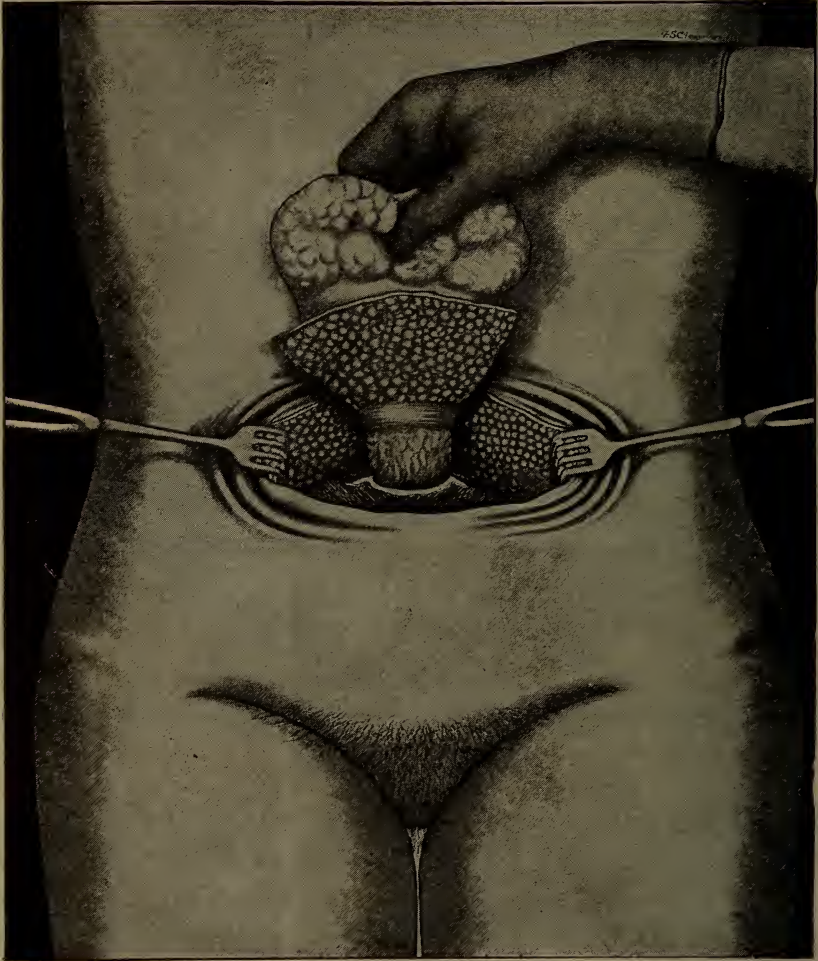

FIG. 471.—Umbilical hernia: dissection of sac. (Mayo.)

Finally the excess of subcutaneous fat is trimmed away and the skin sutured. The usual dressing is applied, held in place by a wide binder, and the after-treatment, already indicated, is instituted.

Figs. 471 and 472 show the manner in which Mayo perfects the radical cure.

Obturator Hernia.—A strangulated obturator hernia is rare, yet it is to be thought of and ruled out before opening the abdomen for

intestinal obstruction. Several points help to locate the trouble even when no marked tumor is present. The presence of pain over the region of the obturator foramen directs the attention to that point, and pressure made there projects a pain down the inner side

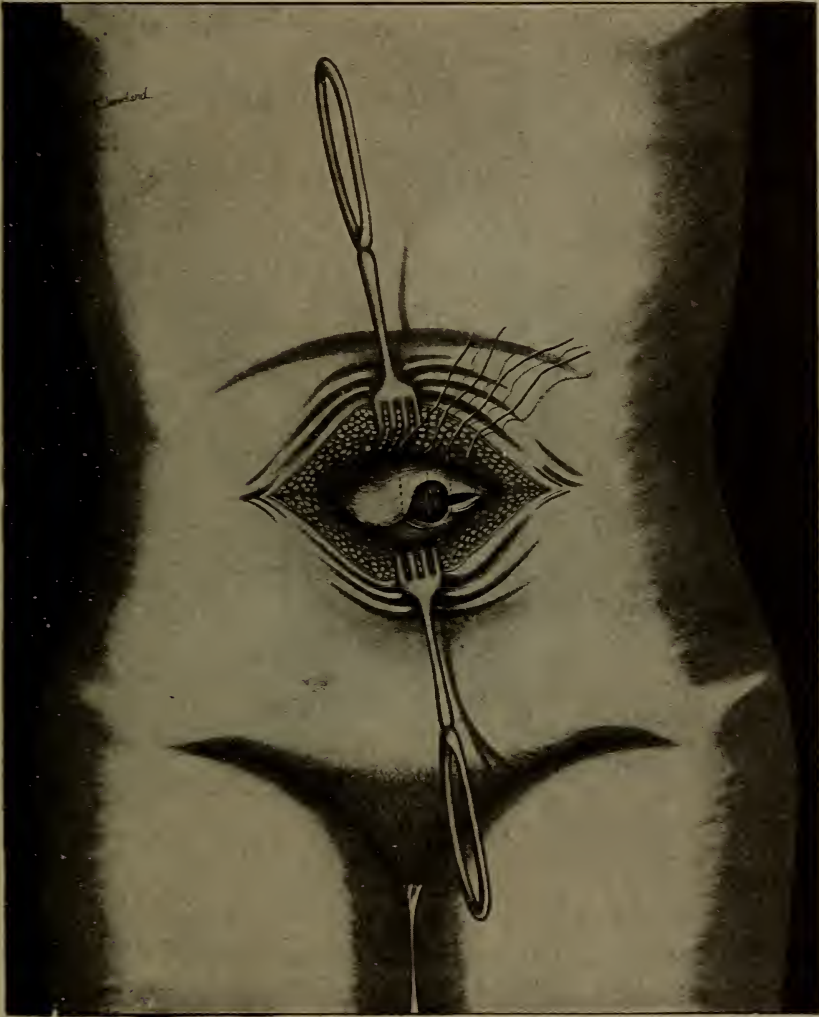


FIG. 472.—Umbilical hernia: repair of abdominal wall. (Mayo.)

of the thigh to the knee, along the course of the obturator nerve. In the female, vaginal examination will reveal the tumor.

In this form of strangulated hernia, taxis is useless and likely to be very harmful, and therefore must never be employed. A herniotomy must be done without delay, though in these cases it is a procedure

by no means simple. Several anatomical points must be borne in mind. The hernia usually comes out through the upper part of the obturator membrane and is covered over by the pectineus muscle. It may work into the pectineus or it may lie on a lower level, working into the obturator externus. The pectineus is usually the chief guide to the hernia.

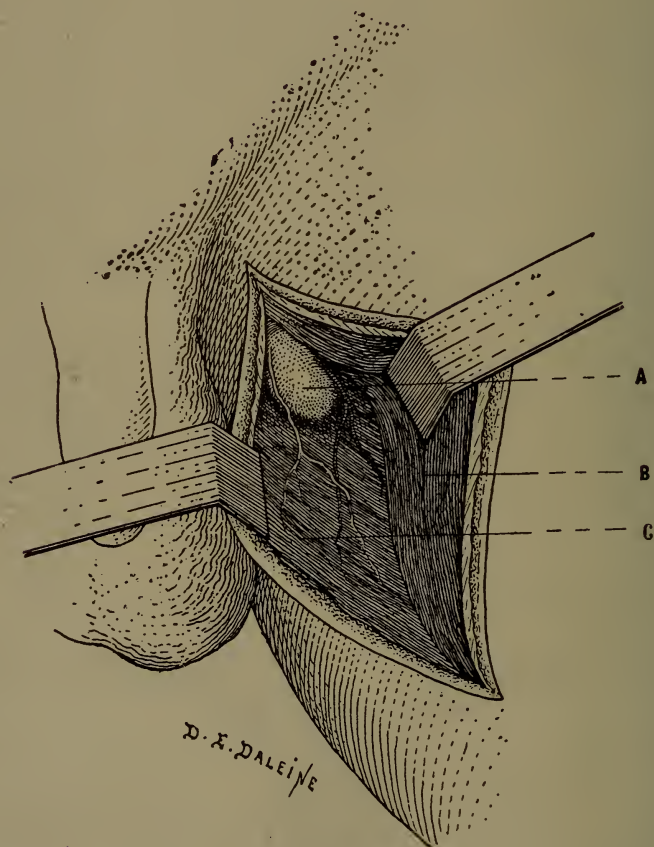


FIG. 473.—Obturator hernia. A, Hernial sac-obturator artery; B, pectineus; C, adductor longus. (*Lejars.*)

The obturator vessels and nerve are usually found behind and to the outer side of the neck of the hernia. The femoral vessels lie to the outer side. It is the obturator membrane which constitutes the constricting ring.

The *operation*, chiefly as described by Treves, is as follows: The pelvis is elevated, the thigh flexed and adducted, the femoral artery located, and about a finger's breadth internal, an incision is made from

the spine of the pubes downward for 3 or 4 inches. Incise the skin, the subcutaneous fat and the fascia lata, and expose the adductor longus. Catch up the deep external pudic artery. Retract the adductor brevis and beneath this is the pectineus whose fibers are separated by blunt dissection; or, if necessary, divided in order to expose the sac (Fig. 473).

When the sac is once in view, free it completely up to the neck. The obturator membrane is now to be nicked, observing first the course of the arteries. It may be better, however, to open the sac at once, cleanse the contents, and endeavor to insinuate the finger alongside the bowel and stretch the strangulating fibers; failing in this, to divide them, keeping in mind the possibility of a hemorrhage. If, in spite of precaution, this occurs, tampon firmly against the obturator membrane, and when the tampons are removed one by one, the bleeding points may be recognized and clamped. Finally the intestine, if sound, is reduced, the sac dissected and ligated high up, and the external wound sutured.

Lejars remarks that one may find in the sac of a strangulated obturator hernia not only bowel and omentum, but also the tubes and ovaries, the bladder and the appendix; and that it is well to be forewarned of these possibilities, which may greatly complicate an operation at best never simple.

Of strangulation of *other forms* of hernia—sciatic, lumbar, perineal, vaginal—it need only be said that they are too rare to be with profit considered here.

CHAPTER XII

RADICAL CURE OF INGUINAL HERNIA

The radical cure of hernia may be attempted at the operation for strangulated hernia under the conditions defined. But aside from those emergency cases there are others in which the family doctor will feel it his duty to recommend and to do the operation. His results will be excellent if he wisely chooses cases not beyond his skill. As Veau says, he should select only such as are *small, reducible, congenital*. The large hernias are difficult to handle and recurrence will be almost certain. The irreducible hernias may have acquired adhesions that can scarcely be broken up without severe injury to the gut. With respect to age, the ideal case is a young man fifteen to twenty-five years old, who has well-developed abdominal walls, a well-defined external abdominal ring, and a hernia easily controlled by a truss.

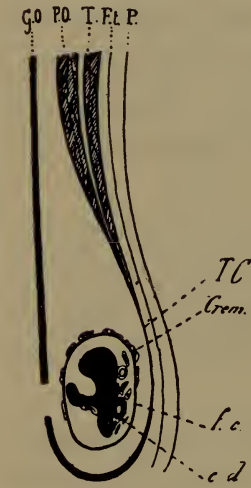


FIG. 474.—Transverse vertical section of the inguinal canal showing relation of the hernial sac. GO, external oblique; PO, internal oblique; T, transversalis; Ft, transversalis fascia; P, peritoneum; TC, conjoined tendon; Crem., cremaster; cd, vas deferens in contact with the hernial sac represented in black. (Veau.)

Under these favorable conditions, the hernia rarely recurs; but almost certainly it will recur if *suppuration* follows the operation, and therefore *absolute asepsis* is the *sine qua non* of success.

Surgical Anatomy.—The hernia, then, which the general practitioner should undertake to operate on is an external or oblique, which escapes from the abdominal cavity through the internal ring to the outside of the deep epigastric artery and follows the inguinal canal down to the external ring (Fig. 474).

Beneath the skin will be found only a few insignificant vessels.

The aponeurosis of the external oblique is easily distinguished, strong and resistant, and its fibers bounding the external ring are thickened to form the "pillars" of the ring. Behind it lies the cord, which includes the vas deferens and its accompanying vessels and nerves, all surrounded by a common sheath derived from the transversalis fascia, and in this case, it contains also the hernial sac. To reach the sac, the sheath must be divided and the elements of the cord separated from the sac.

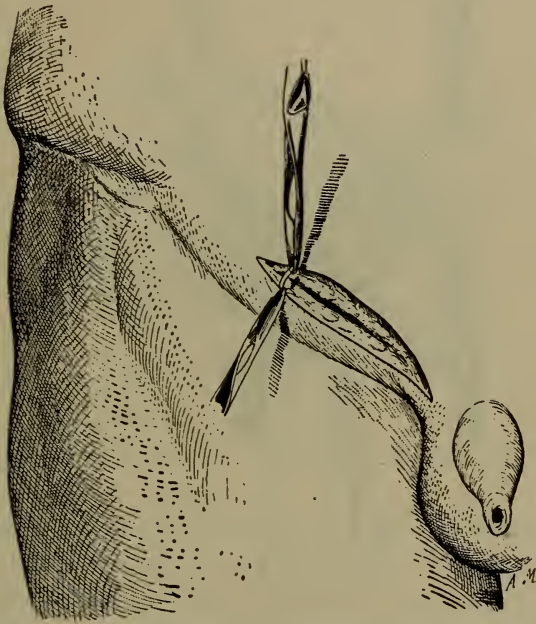


FIG. 475.—The primary incision for hernia. (Veau.)

In the case of congenital inguinal hernia, the sac is very thin and, in spite of precautions, it is sometimes torn or one even fails to find it. The chief difficulty of the operation centers around the recognition and dissection of the sac. The posterior wall of the inguinal canal is formed by the conjoined tendon, the transversalis fascia, and the peritoneum.

The purpose of the operation is to reconstruct the posterior wall and restore the obliquity of the canal, and the "Bassini" operation is the type the inexperienced operator can best imitate.

Operation.—Prepare the field most scrupulously—abdomen, thigh, and scrotum. Employ general anesthesia, as a rule, although local and spinal anesthesia are available.

Begin by locating the external ring, which is to be the first point of attack.

The incision will extend from this orifice to a point just over the internal ring, which lies $\frac{1}{2}$ inch above the middle of Poupart's ligament. The incision, then, beginning above (on the right), extends downward and forward to the spine of the pubes, where it bends a little to become more vertical and ends in the base of the

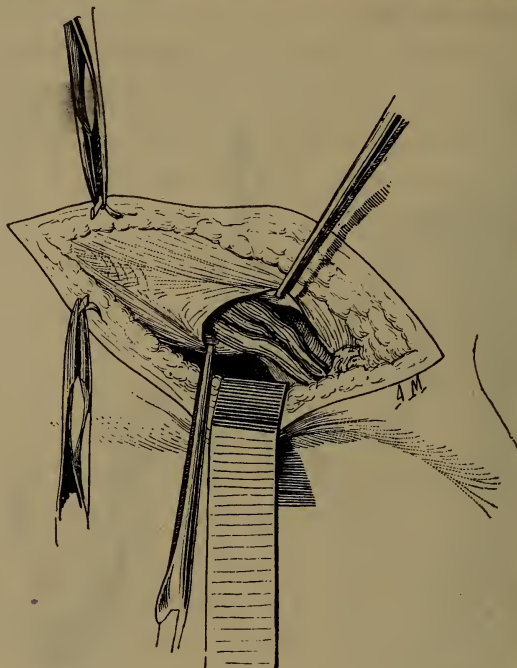


FIG. 476.—The external oblique exposed and the external ring developed. (Veau.)

scrotum (Fig. 475). However large the hernia may be, one need not extend the incision further, so lax and distensible are the scrotal tissues.

Having divided the skin and subcutaneous tissues, catch up and ligate the small vessels. Next divide the fatty tissues layer by layer down to the *aponeurosis* of the external oblique, which lies deeper than one may expect.

Now, with the grooved director, completely expose the pillars of the ring. Do not neglect this as it is a most important step in the operation. The inner pillar is easily found, but the outer pillar is covered by the cord and a little patience is required to get it well exposed. Catch up each pillar with forceps; these are not to be

loosened until, at the end of the operation, they have served as a guide in the repair of the external ring (Fig. 476).

Now comes the next step in the operation. Carefully divide the aponeurosis in the line of the pillars and to the full extent of the skin wound. Unless one cuts deeply, there is nothing to fear. You have now laid open the inguinal canal and have left to do the most difficult part of the operation.

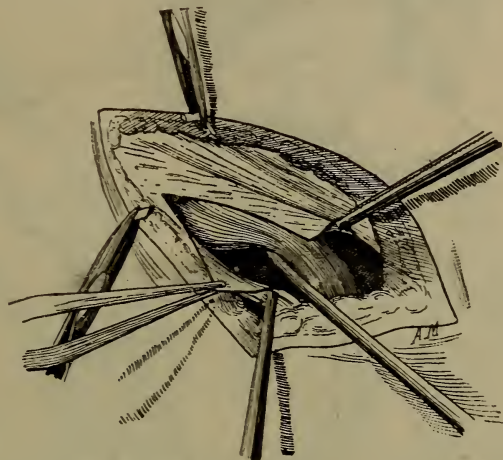


FIG. 477.—The external oblique divided, exposing the cord and hernial sac. (Veau.)

To Find and to Dissect Out the Sac.—The cord is covered by the cremaster which also covers the hernial sac. You may begin the search for the hernial sac without disturbing the position of the cord, but it is better to raise it up out of its bed. To do this follow along the external pillar and Poupart's ligament and you will find it easily disengaged by blunt dissection (Fig. 477). Slip the left index finger under and support the cord. The sac is enclosed in the fibrous sheath of the cord.

Very gently incise this sheath, using a sharp bistoury (Fig. 478), and the structures of the cord appear. Rolling them between the finger and thumb, you can recognize the vas deferens by its form and consistency. You can see the distended veins. You will see a whitish transparent membrane. Catch up a fold of it with the forceps and divide its base, and if it is the sac, you will open into a serous cavity (Fig. 479). Enlarge the orifice sufficiently to introduce a finger and, with that as a guide, dissect the sac from its associated

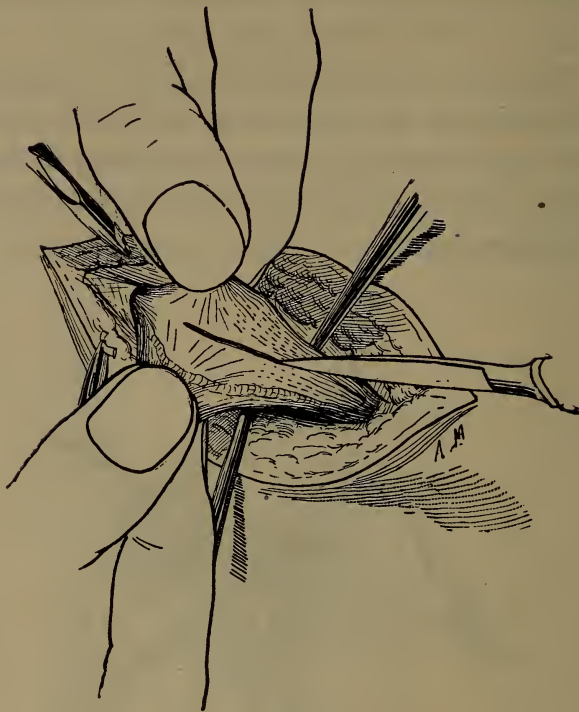


FIG. 478.—Dividing the fibrous coverings of the sac. (Veau.)

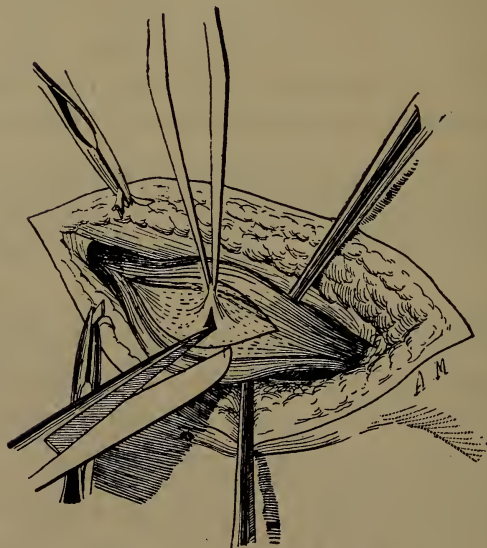


FIG. 479.—Incising the hernial sac. (Veau.)

structures (Fig. 480). It is often a difficult task, for the veins and vas deferens are glued to the sac, especially in the congenital hernia. Sometimes pressing and stripping the tissues back with a gauze compress facilitates the maneuver. Still there need be no great difficulty if only all the coverings are divided with the scalpel or scissors, exposing a plane of cleavage. Pulling and tearing and lacerating the tissues in the effort to liberate the sac, provokes a capillary oozing and predisposes to infection.

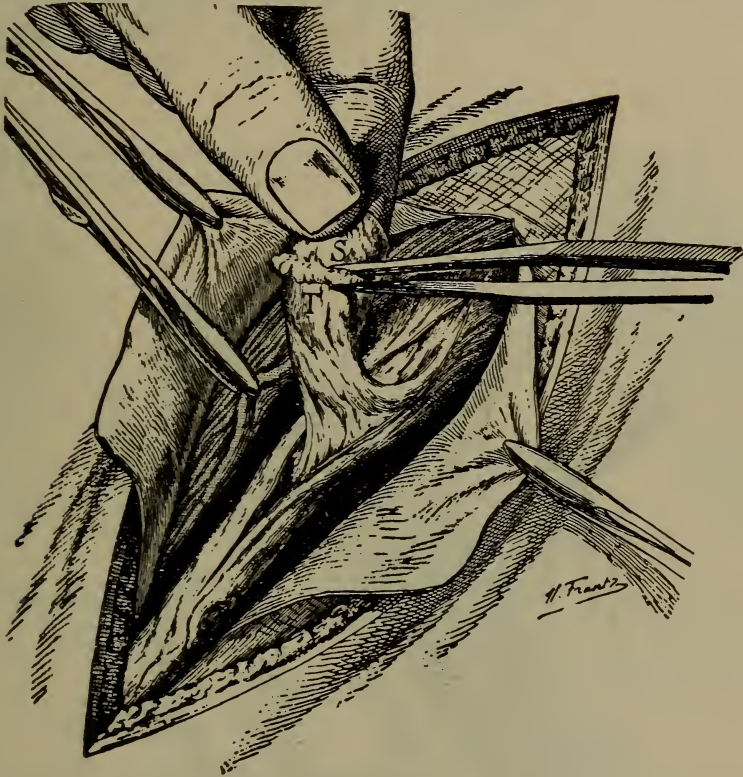


FIG. 480.—The index finger introduced into the sac which is being separated from the other structures of the cord. (*Guibe.*)

It is important that the sac be isolated quite to the internal ring (Fig. 481); otherwise when the ligature is applied there will be formed a peritoneal diverticulum, the starting-point later of another hernia. Do not carry the dissection further than the internal ring for fear of wounding the bladder.

Assure yourself now that the sac is empty by passing a finger up into the abdominal cavity. Now transfix the neck of the sac with a

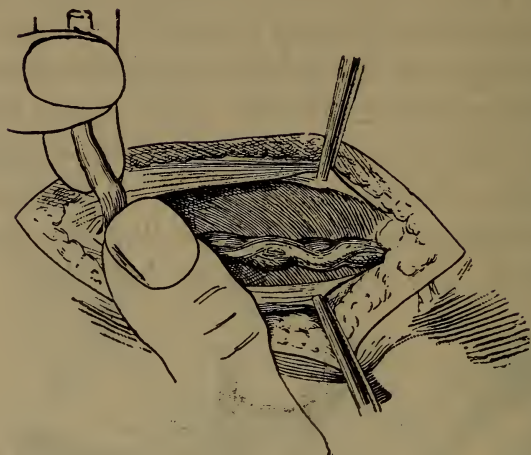

FIG. 481.—The sac separated from the cord; the cord in the bottom of the wound; on either side are the lips of the external oblique, the forceps still attached to the pillars of the external ring. (Veau.)

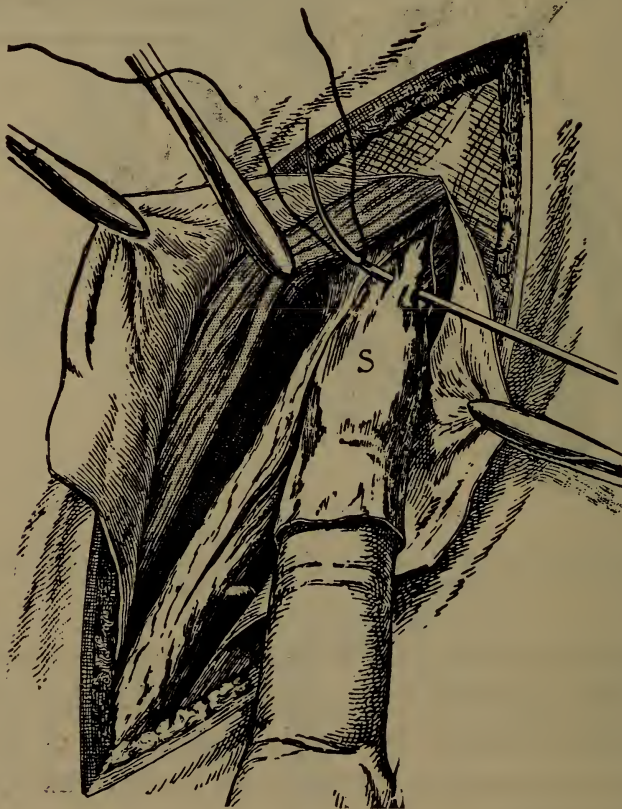


FIG. 482.—Ligation of the neck of the sac. (Veau.)

needle carrying a catgut ligature (Fig. 482) and tie in the manner indicated in figure (Fig. 483). If the ligature merely encircles the neck, it is too likely to slip off. Do not cut off the ends of the ligature until through dealing with the sack. Amputate the sac within $\frac{1}{2}$ inch of the ligature and, if everything is all right, cut the threads and the stump disappears in the cavity. Sellenings proposes to dispense with the dissection of the sac. After it is exposed, incised, and emptied, he obliterates it by passing a purse string around its neck at the internal ring and suturing the rest of its length (Amer. Jour. Surgery, March, 1909).

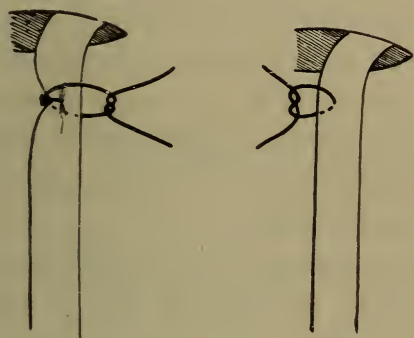


FIG. 483.—Illustrating method of ligating the sac. (Veau.)

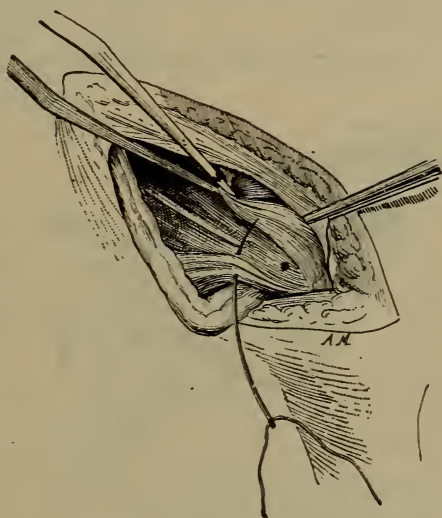


FIG. 484.—The cord drawn to one side while the posterior wall of the canal is restored by suture of the conjoint tendon to the shelving edge of Poupart's ligament. (Veau.)

Suture of the Abdominal Walls.—This is the next step. Draw the cord down out of the way for the moment and expose the shelving inner edge of Poupart's ligament, which is to be sutured to the free border of the conjoint tendon. In other words, the internal oblique and transversalis are to be sutured jointly to Poupart's ligament.

Through this shelving edge near the pubis pass a chromic catgut suture on a curved needle and carry it through the corresponding part of the conjoint tendon (Fig. 484), and apply three or four such sutures (Fig. 485). In this manner reconstruct the posterior wall of

the inguinal canal. Place the cord back in position upon this line of sutures.

Now draw the edges of the divided aponeurosis into position by means of the forceps attached to the pillars at the beginning of the operation. Begin the repair by a chromic catgut suture at the upper end of the wound (Fig. 486) and pass six or eight in this manner.

The last will rejoin the pillars and restore the external ring, and when these are all tied the anterior wall of the canal is thus reconstructed. There is some danger of making the external ring too small for the cord (Fig. 487), with the result finally that the testicle atrophies.

Complete the hemostasis. A scrotal hematoma may develop unless one is very particular about the oozing.

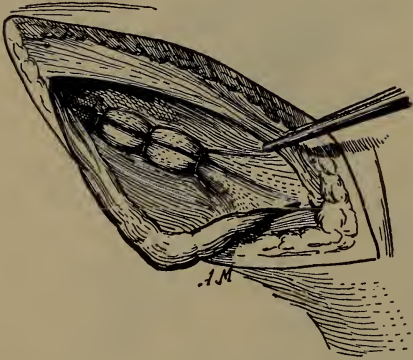


FIG. 485.—Posterior wall-repair complete. (Veau.)

Complete the operation by suture of the skin wound with silk-worm-gut, leaving in it a small drainage-tube if you fear infection or oozing; otherwise this is not necessary; still it does no harm.

The dressing is of extreme importance. Cover the wound with a strip of moist gauze, fix it with collodion, and then apply the ordinary gauze and cotton dressing. A double spica bandage will greatly diminish the chance of infection. If drainage was employed, remove the tube in two or three days under strictest asepsis. Otherwise do not disturb the dressing, but watch the temperature. If the temperature runs up to 101° on the third day, open up the wound by removing one or two sutures, and if there is any pus, drain.

Delay in this is likely to result in extensive suppuration, and a recurrence of the hernia is thus assured. If everything goes well, remove the stitches on the eighth day, but keep the patient in bed for three weeks. A truss is not necessary.

Rilus Eastman, of Indianapolis, recommends a modification of the final suturing especially applicable in the case of children. His method aims at the closure of all the layers by a single tier of easily

removable non-buried sutures. The method described (*Annals of Surgery*, Jan., 1906) consists in the reduction of the sac by the ordinary procedure. A Pagenstecher celloidin linen suture bearing a needle on each end is then first passed through Poupart's ligament

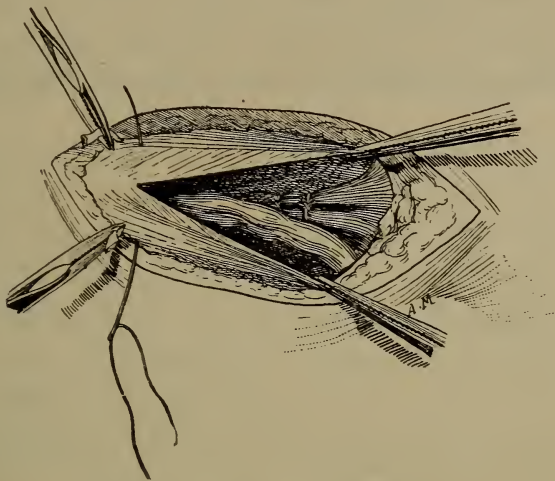


FIG. 486.—Reconstructing the anterior wall by repair of the external oblique. Forceps still attached indicate the position of the ring. (Veau.)

from without inward 1 inch from its free margin. It is next passed through the outer border of the obliquus externus and transversalis muscles and brought back through Poupart's ligament about $\frac{1}{3}$ inch nearer the margin than at its first point of passage.

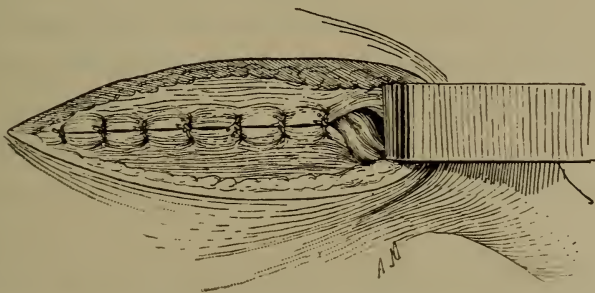


FIG. 487.—External oblique repaired. (Veau.)

The needle now external to, and above Poupart's ligament is made to overlap the free margin of the ligament and the aponeurosis of the external oblique by carrying the thread through in the form of a simple running mattress suture.

The needle is next passed through the superficial fascia, panniculus adiposus, and skin, emerging about $1/8$ inch from the skin wound margin upon the side opposite Poupart's ligament. When traction is made upon the two ends of the suture no kinks or curls remain, and the suture is tied up as a simple loop. Five or six such sutures are required to coapt the wound from the internal ring to the pubes. When union is complete they are easily clipped and removed.

CHAPTER XIII

RADICAL CURE OF FEMORAL HERNIA

Aside from the cases of strangulated hernia, the general practitioner should not undertake the operation for the radical cure of femoral hernia without due consideration and without warning the patient that relapse is possible and even frequent. The operation is not more difficult than that for inguinal hernia, but a cure is much less certain. As with inguinal hernia, he should select only such cases as are small and reducible.

Surgical Anatomy.—The sac of a femoral hernia is generally thick and imbedded in adipose tissue originating in the extra-peritoneal layer. (See Strangulated Femoral Hernia.)

The relations at the neck are of the greatest importance. To the outside is the femoral vein in direct contact, easily perforated by a careless needle and producing a hemorrhage that can be arrested only by ligature of the vein. To the inside is Gimbernat's ligament, sharp-edged and tense, the chief structure to be dealt with in strangulation. Above is Poupart's ligament, separating the femoral from the inguinal canal, and below is the ramus of the pubes, thinly covered by the pectineus and its fascia. These boundaries are unaccommodating structures in the matter of repair, and for this reason relapse is frequent.

Operation.—The anesthesia and preparation are the same as for inguinal hernia.

The *incision*, parallel with, and a finger's breadth below Poupart's ligament, begins (on the left side) at the spine of the pubis and is usually about four inches in length (Fig. 488).

Incise in the same manner the fatty tissues, layer by layer, until the easily distinguishable coverings of the hernia are reached. The line of cleavage between them and the fatty tissues is followed and the neck, lying high and deep, is exposed. Poupart's ligament is

next freely exposed. Where coverings seem thinnest, catch up a fold with the dissecting forceps and incise the base. It may be that the incision will only open into another fatty layer. Divide the next layer in the same manner, and so proceed until you have opened the sac; secure its edges with forceps and pass an index finger into the cavity. If omentum is found it must be resected (Fig. 489). Be sure there is no adherent bowel.

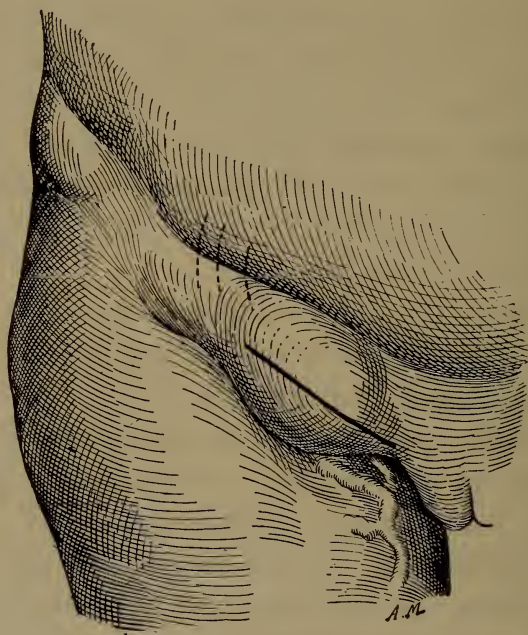

FIG. 488.—Incision for femoral hernia. (Veau.)

Now *dissect the sac*, proceeding slowly and methodically until the femoral ring is reached. Introduce a finger to be sure the bowel is protected, and transfix and ligate the neck of the sac as in inguinal hernia. Again recall the relations of the femoral ring (Fig. 490).

Obliteration of the Femoral Ring.—Retract the upper angle of the wound so that you can see, divide Gimbernat's ligament freely, cutting horizontally and toward the pubes (Fig. 491). Poupert's ligament can now be approximated to the pectineus. Protect the femoral vein with a retractor and pass the first suture adjoining it, using a strong curved needle and No. 2 or No. 3 catgut.

The needle enters the pectineal fascia, grazes the bone, comes out a little higher, and then passes up to the posterior surface of the liga-

ment and forward through it (Fig. 492). Place four sutures in this manner before tying (Fig. 493). Tie them successively from without inward. It is this line of suture alone that will be efficient, but suture the fascia if you wish, and finally the skin.

The subsequent treatment is the same as in inguinal hernia.

Such is the method which Veau recommends, and which has the great merit that it is anatomical. But there are many differences of opinion as to the best method of closing the femoral ring, and as to the advisability of even closing it at all.

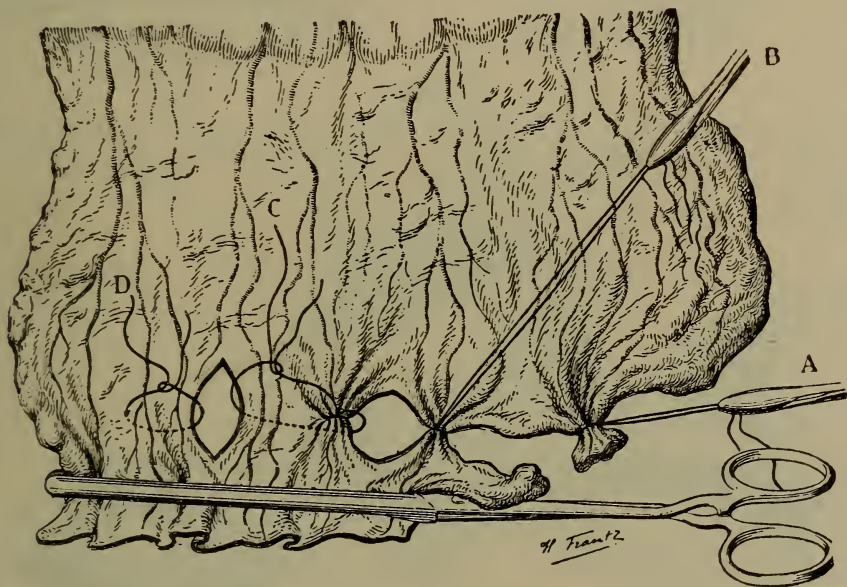


FIG. 489.—Resection of the omentum. (Guibe.)

Ochsner enunciates the principle, applying it to the radical cure of femoral hernia, that circular openings in any part of the body, will certainly close unless kept open by a mucous or serous lining. Wherever, therefore, the femoral ring is well defined, he is content with high ligation of the sac and dissection of all the fat and simple closure of the wound. With a technic thus reduced to the simplest terms, he obtains excellent results. Unfortunately, the femoral ring cannot always be defined as a circular opening, and especially after the operation for strangulated hernia.

Coley in the main agrees with Ochsner, but lays somewhat more stress on the closure of the femoral canal.

The cure is the more perfect and certain, we think, if a more particular care is given to the closure of the femoral ring, to obliteration of the femoral canal. Especially in case the hernia is of long standing, the opening large, the structures stretched and weakened.

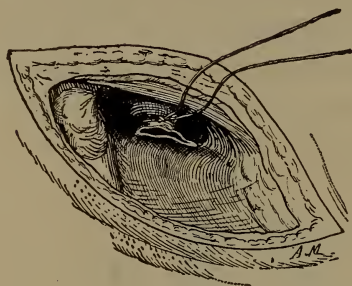


FIG. 490.—The neck of the sac ligated and cut off. Above, Poupart's ligament; below, the ramus of the pubes; internally, Gimbernat's ligament. (Veau.)

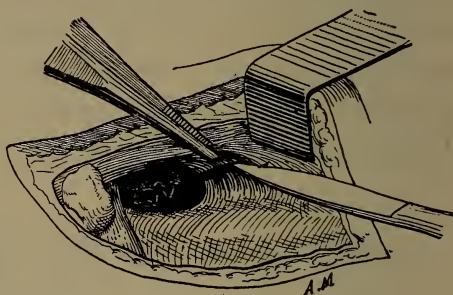


FIG. 491.—Femoral hernia; incision of Gimbernat's ligament. (Veau.)

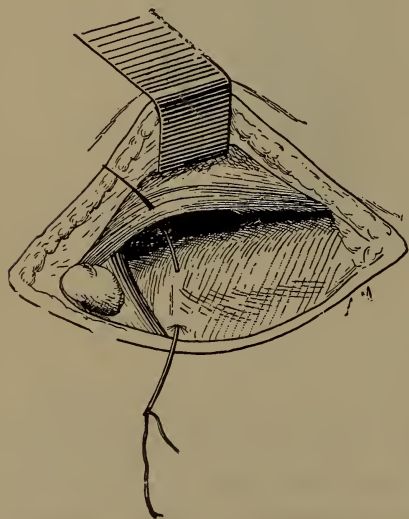


FIG. 492.—Suturing Poupart's ligament to pectineal fascia. (Veau.)

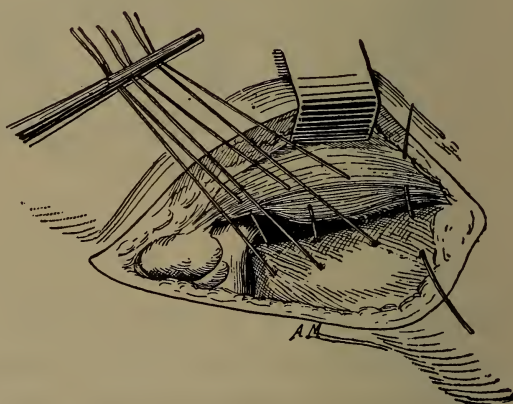


FIG. 493.—Suture of Poupart's ligament and pectineal fascia completed. (Veau.)

Proceed as described in the case of strangulated hernia, to expose liberate, and ligate the sac, dividing Gimbernat's ligament to give a good exposure. Ligate the sac high.

The peritoneum is now freed from contact with the abdominal wall, holding it back out of the way with a flat retractor. The vein which is freely exposed is drawn outward.

Poupart's ligament is now lifted up and the free borders of the internal oblique and the transversalis exposed above, and Cooper's ligament below. It is these structures which are to be drawn into contact. The first suture is passed close to the femoral vein. It is the most difficult because the structures from within outward become more deeply placed.

The remaining two or three sutures approach the pubes, the last reaching up behind Gimbernat's ligament (Fig. 494). Some difficulty may be experienced in passing these sutures, for Cooper's ligament is quite resistant.

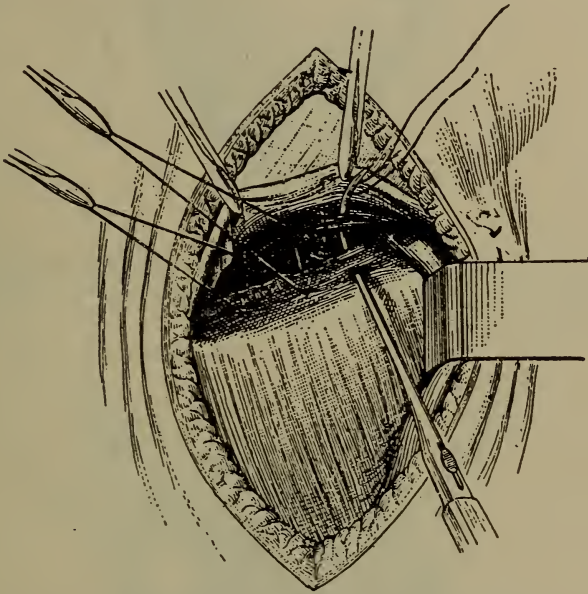


FIG. 494.—Radical cure of femoral hernia. The first plane of sutures approximates the border of the internal oblique and transversalis to Cooper's ligament—the periosteum of the ilio-pectineal line. Gimbernat's ligament divided, the femoral vein drawn outward. (Guibe.)

The second and superficial plane of sutures approximates Poupart's ligament to the pectineal fascia (Fig. 498). Thus the femoral canal is completely obliterated by two strong fascial planes. The superficial fascias are sutured to obliterate any dead spaces and the skin repaired.

In the case of the male or for that matter in the difficult cases in the female the inguinal canal may be opened exactly as in inguinal hernia. The cord is drawn down, the transversalis fascia divided, avoiding the deep epigastric artery, and the neck of the sac exposed. It is

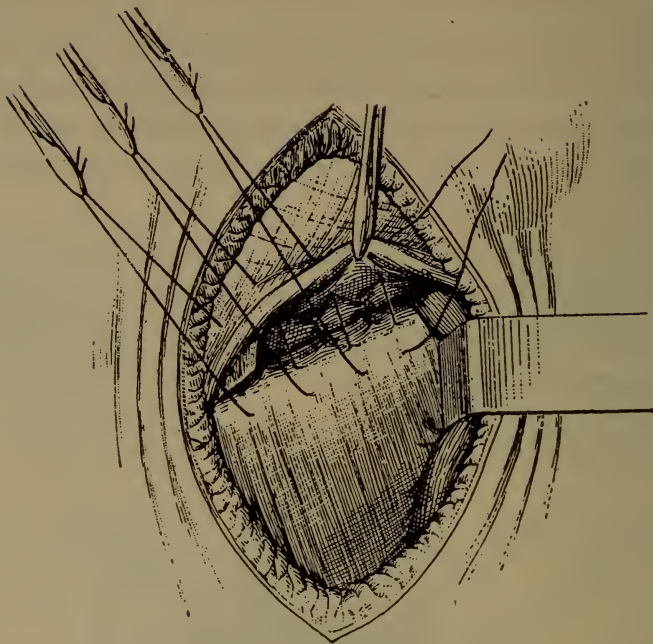


FIG. 495.—Radical cure of femoral hernia. The first row of sutures is tied and the second passed, approximating Poupart's ligament and the pectineal fascia. The femoral vein drawn to the outer side must be avoided. (*Guibé.*)

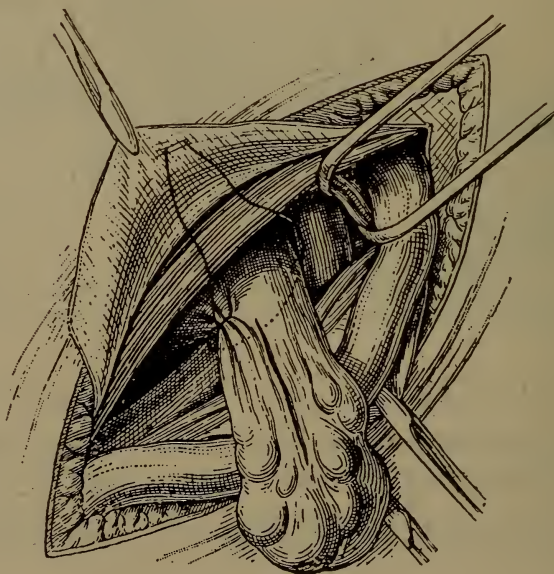


FIG. 496.—Radical cure of femoral hernia by the inguinal route. The sac is dissected out, opened, emptied, and ligated. The cord displaced downward, the vein outward. The border of the external oblique drawn upward exposing the internal oblique which will be sutured to Cooper's ligament after the sac is cut off.

freed from its pouch in the femoral canal, brought out of the wound, opened, emptied and ligated (Fig. 496).

The borders of the internal oblique and transversalis are approximated to Cooper's ligament—in other words, the periosteum of the ilio pectineal line, avoiding the femoral vein as described above. Poupart's ligament is next approximated to the pectineal fascia, the cord is replaced and the incision in the external oblique repaired and the operation completed as for inguinal hernia.

CHAPTER XIV

ENTERECTOMY. INTESTINAL ANASTOMOSIS

Resection of a segment of the small intestine may be a necessary part of several emergency operations. It may be required following gunshot or other lacerating wounds of the intestine; it may be necessary in certain wounds of the mesentery and in the gangrene of strangulated hernia.

Large wounds of the gut, those which carry away more than one-half the circumference, require resection, for any form of repair is likely to result in stricture. In the case of multiple perforations, it is safer to resect than to attempt separate repair of the orifices. A small wound of the omentum near the intestinal border may require an extensive resection, for an inch of mesentery at that level may contain the blood supply of 2 feet of intestine.

Resection of the bowel implies anastomosis, and this may assume one of three forms: it may be end-to-end—termino-terminal, termino-lateral, or latero-lateral.

The end-to-end anastomosis is preferable following resection. The method employed may be either by suturing—circular enterorrhaphy—or by the Murphy button or some of the other mechanical devices, such as Robson's bone bobbin or Frank's decalcified bone coupler. With the great majority of surgeons, suturing is the method of choice, although the casual operator may not yet be ready to discard the mechanical device.

Moynihan, in his great work on abdominal operations, sums the matter up in this wise: "The use of mechanical appliances is no longer necessary; these have played their part—a most important part, I gratefully admit—in the development of surgical work, and it is now time that their surgical use should be abandoned. They have been useful, nay, indispensable steps in the march of progress. To Murphy above all other surgeons—for his instrument is one of

the most ingenious mechanical contrivances ever invented—we should gratefully acknowledge the debt we owe. The weightiest argument against all mechanical aids to anastomosis is this—they are unnecessary. By their aid we do not accomplish anything which cannot be accomplished with equal rapidity and greater safety by simple suture. We have nothing to gain from their use and we risk much by leaving something behind which may be and has been the direct cause of danger and of death. The day of mechanical aids is over. The buttons and the bobbins, the elastic ligatures and the forceps of many forms have no more than a historical interest.”

Technic of Resection.—The *first essential* of this procedure is that all the impaired gut be removed. Otherwise subsequent slough and perforation are almost a certainty. There is a limit, of course, to the length of the segment which may be safely removed, but in the ordinary operation one need not fear to remove too much. Cases are on record in which as much as 10 feet of the small intestine have been removed with recovery. As Moynihan said, it is not so much a question of how much is removed as how much is left to carry on the intestinal functions.

A *second requisite* in resection is that the blood supply of the bowel be left unimpaired. Lack of precaution in this respect may nullify an otherwise careful operation.

The integrity of a given part of bowel is absolutely dependent upon the condition of the vessels which arise from the last arterial arch to supply it. It must be remembered that the vasa intestini tenuis break up into a number of freely anastomosing arches, but the terminal branches anastomose but little. It is this character of the circulation which determines the mode of section of the mesentery.

The *third principle* constantly to be borne in mind is that the peritoneum is to be completely protected from contamination by the bowel contents. It is true of all the hollow viscera that their contents are more or less septic, always sufficiently so to produce peritonitis. The bowel, then, must always be temporarily constricted beyond the limits of the section. This is ordinarily done by means of intestinal clamps or by elastic ligature or by gauze strips passed through a button-hole in the mesentery.

Not only must the intestinal contents be restrained, but also the field of operation must be shut off from the peritoneal cavity and from contact with the rest of the viscera by means of sterile compresses. The larger and more deeply placed of these are not to be removed until the end of the operation; the smaller and more superficial should be changed from time to time as soiled.

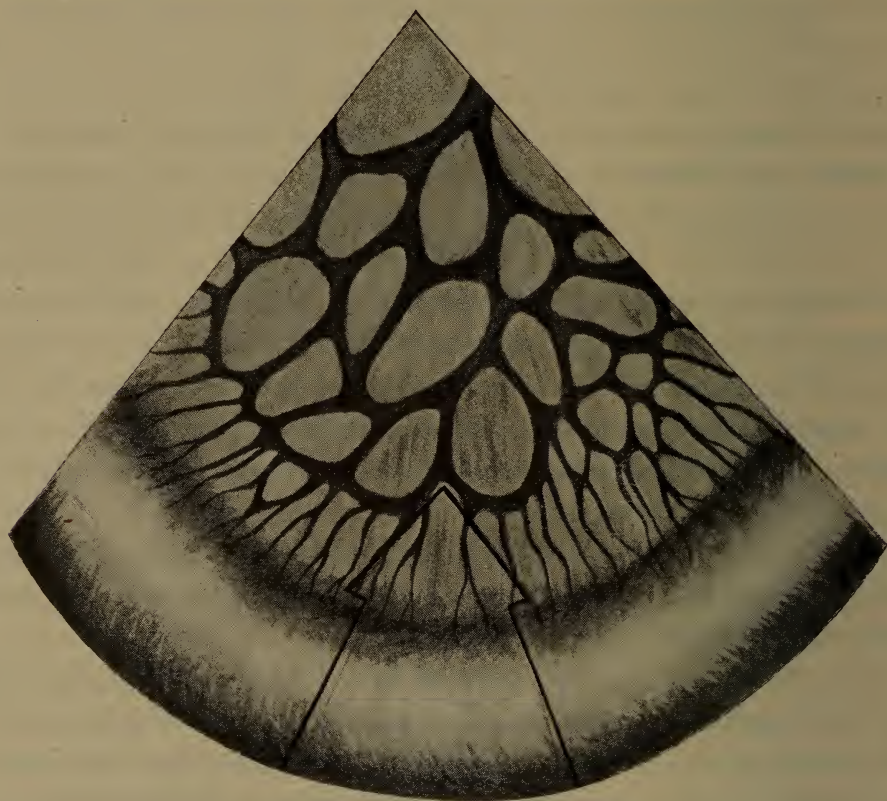


FIG. 497.—Resection of the bowel; showing lines of incision of bowel and omentum.

To resect a portion of the intestine, then, begin by getting the injured coil well into view and pack around it with sterile compresses. It may be advisable as a further security now to put the patient in the Trendelenburg position. Strip the portion of bowel to be removed, so as to empty it, and apply a clamp well beyond each end of the condemned segment. The clamps are not placed directly across the bowel, but obliquely, so that more of the convex than of the mesenteric border is included. A portion of the mesentery is included in the bite of the forceps.

The lines of the section are prolonged into the mesentery so that

they meet just short of the nearest arterial arch. It is better to make the base of the mesenteric wedge even narrower than the mesenteric margin of the intestinal segment. There is then scarcely any danger that the circulation will be impaired (Figs. 497, 498).

If a *lateral*, instead of an end-to-end, anastomosis is intended, the technic may be varied with great advantage. Under such circumstances *proceed in this manner*: Determine the

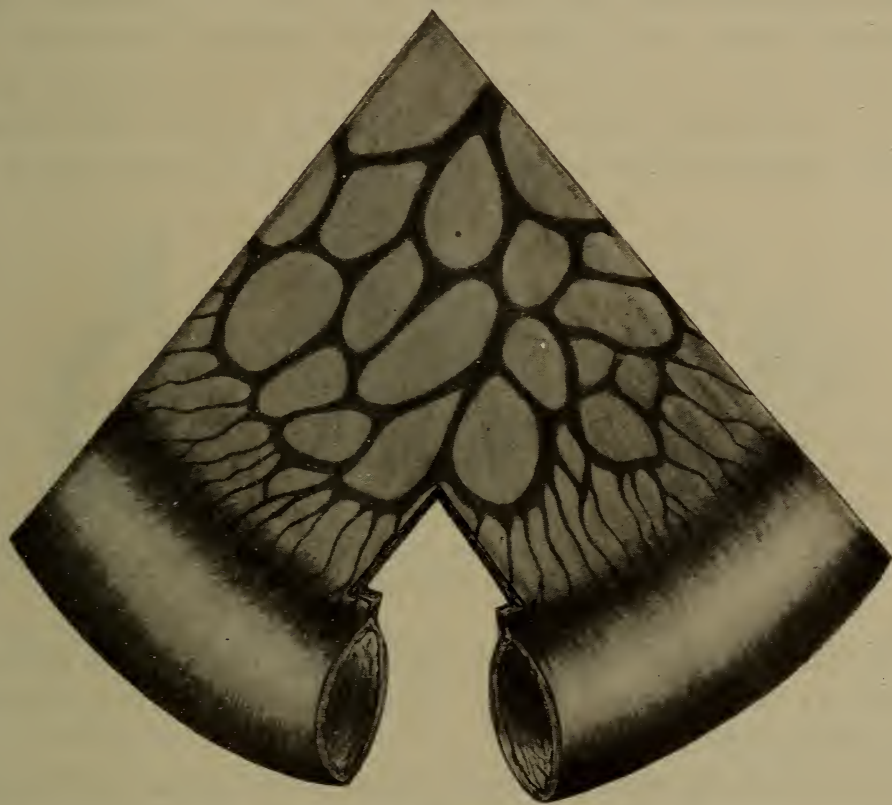


FIG. 498.—Resection of bowel; showing segment of bowel and omentum removed.

lines of section; free the mesentery opposite, for a short distance and apply a clamp to the bowel but not including the mesentery; shift the clamp so as to flatten a segment of the bowel an inch long. Ligate both ends of this segment and cut between the sutures, wrapping the stump of the healthy portion in sterile compresses. Pass to the other line of section and treat it in the same manner. The portion of bowel to be removed is now freed of its mesentery, dividing it parallel with, and an inch from, the gut, catching the vessels one

by one as divided. To each of the remaining stumps a purse-string suture is applied for the purpose of burying the ligated ends; are further closed by a row of Lembert sutures (Fig. 499). Following this step, the lateral anastomosis, to be described further on, can be carried out.

Technic of End-to-end Anastomosis.—(a) *By suture.* Employ two lines of suture. One perforates the bowel wall, brings the cut edges into accurate contact, and is hemostatic; it may be called the “perforating” suture. The other passes only through the serous and muscular coats—or even better the submucous—and after the manner of the Lembert suture brings the serous surfaces into contact, buries the perforating sutures and effectually prevents any of the

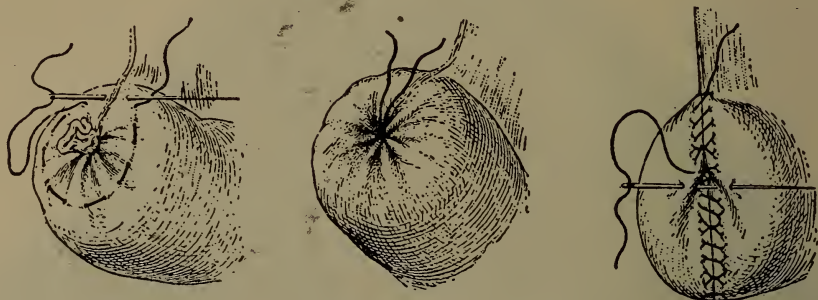

FIG. 499.—Resection of the bowel preparatory to lateral anastomosis, showing manner of treating the intestinal stump.

bowel content from reaching the peritoneal cavity. Most surgeons employ a straight needle and silk. Moynihan likes the curved needle and celluloid thread.

To introduce the suture begin by placing the clamps side by side, bringing the posterior surfaces of the bowel into contact. Connect these two surfaces by a continuous sero-serous suture, extending from the mesenteric border to the convex border (Fig. 500). Leave the thread long where tied at the point of beginning and catch it with forceps. On reaching point “B” leave the needle, still threaded, but wrap it in gauze and lay it aside for the moment.

Now begin the perforating suture at the mesenteric margin. The two leaves of the mesentery separate here to encircle the bowels, leaving a part of the surface bare. The stitch must be passed so as to bring the mesentery in contact with this bare area.

Proceed in this manner: Pass the needle through the bowel wall (beginning with the right side) about $\frac{1}{6}$ inch from the cut edge, entering the mucus, emerging from the serous coat just where the mesentery reaches the bowel. Carry the needle over and across to the left side, pass it through into the lumen, reversing the first puncture. Pass it next from within out, perforating the wall near the mesenteric juncture, and finally perforate the right bowel wall again, passing from without inward. The knot is tied within the lumen of the gut at the original point of entrance. The edges of the mes-

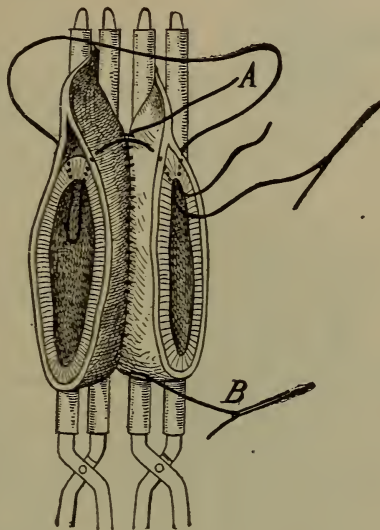


FIG. 500.—End-to-end anastomosis; the first part of the sero-serous or Lembert suture applied. Beginning the inclusive suture. (Binnie.)

entery being thus brought together, the suture is carried continuously around the whole circumference of the gut (Fig. 501). The punctures are $\frac{1}{10}$ to $\frac{1}{12}$ inch apart and the work is facilitated by keeping the thread taut, which at once tightens it sufficiently and brings into view the site of the next puncture. The end of the suture is knotted, the thread left long at the beginning and thus the perforating suture is completed. Remove the clamps.

It remains to complete the sero-serous suture which was temporarily abandoned. It is carried from the convex border on around to the mesenteric border, and when that point is reached the perforating suture is completely buried. Knot with the thread left long in the beginning and held with forceps, and thus the sero-serous suture is

completed (Fig. 502). Finally suture the rent in the mesentery. This must never be neglected, else it may be the site of a strangulated hernia. The line of suture is to be carefully wiped, the compresses removed, and the loop returned to the abdominal cavity.

(b) *By the Murphy button* (Fig. 503). The bowel is resected as described above. Begin by passing a purse-string suture around the bowel near its cut edge, involving all the layers. The chief concern

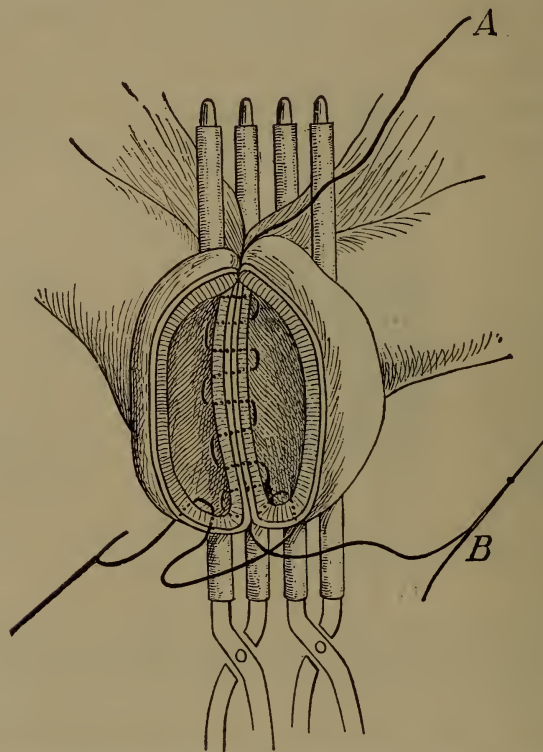


FIG. 501.—End-to-end anastomosis; the first part of the Lembert suture buried by the inclusive suture which will be completed before resuming the Lembert A B. (Binnie.)

is to get control of the mesentery where its layers separate. To do this pass the needle through one layer, on into the lumen of the bowel; out again through the bowel wall and through the other layer of mesentery (Fig. 504).

When the suture is puckered the intermesenteric space is obliterated. Now grasp one-half of the button with forceps and introduce it into the end of the gut so that when the purse-string suture is tightened it will fall into the groove in the button.

Adjust the other half of the button in the same manner. The male half is pressed firmly into the female half, noting that all the edges are turned in. Strengthen the union by a few Lembert sutures. Repair the rent in the mesentery and the anastomosis is

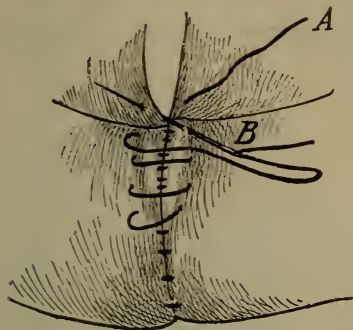


FIG. 502.—End-to-end anastomosis completed. A and B to be knotted. (Binnie.)

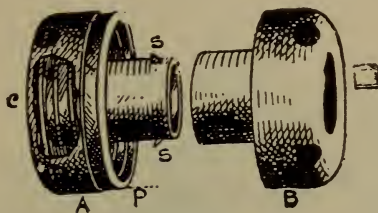


FIG. 503 —Murphy button.

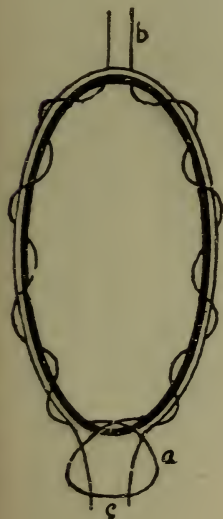

FIG. 504.—Purse-string suture (b) running over edge of bowel and closing space between mesentery (c) at (a). (Stewart.)

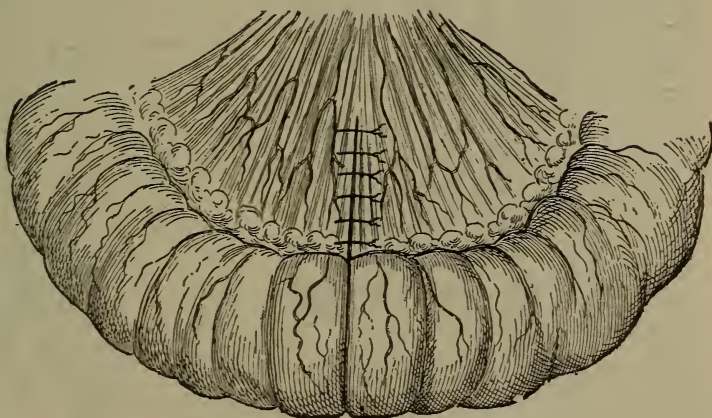

FIG. 505.—Anastomosis with Murphy button completed. (Binnie after DaCosta.)

complete (Fig. 505). It may be expected that the button will pass about the tenth day.

Lateral Anastomosis.—Proceed as before, bringing out of the abdominal cavity the loops to be anastomosed and pack with sterile

compresses. Each loop is clamped and the two clamps laid side by side so as to bring about 5 inches of the bowel walls in contact (Fig. 507).

The first line of suture is to be applied nearer the convex than the mesenteric border and should be about 3 inches in length. Unite the opposed surfaces then by a sero-serous suture. The line of

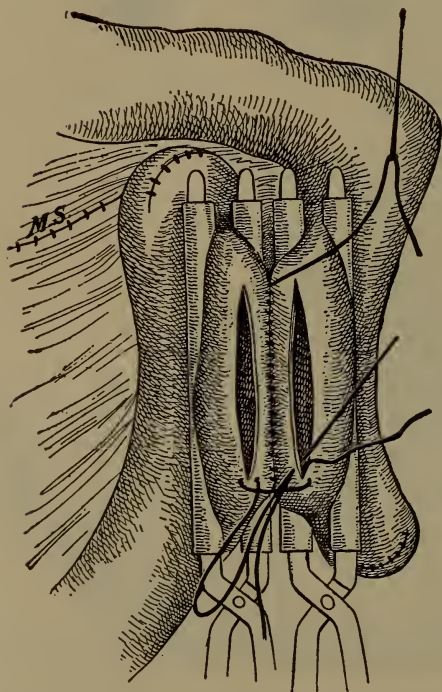


FIG. 507.—Lateral anastomosis facilitated by use of clamps. Continuous suture for both layers. (Binnie.)

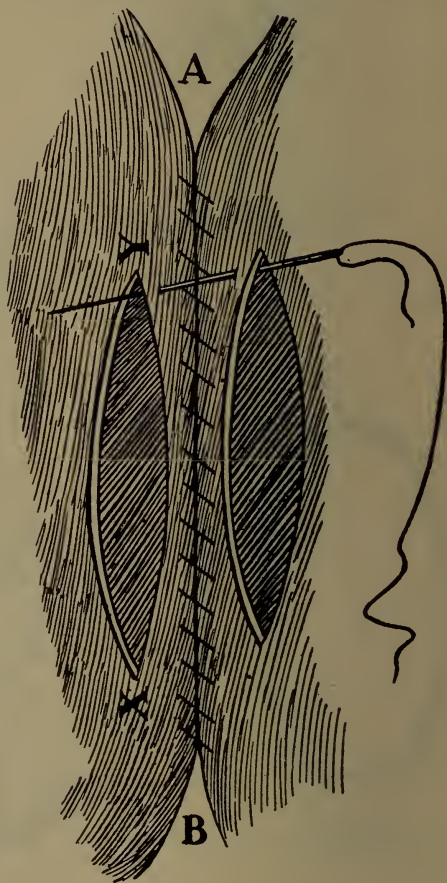


FIG. 508.—Lateral anastomosis; first row of Lembert sutures applied. (Binnie.)

suture runs toward the operator, and when the line has reached, say 3 inches, the needle is left, still threaded, and temporarily laid aside.

The next step consists in making the openings which are to afford the means of communication between the two loops. A straight incision about $\frac{1}{4}$ inch from and parallel with this line of suture lays open the bowel down to the mucosa. Section of these superficial

coats leave exposed an ellipse of mucous membrane, and this ellipse should be trimmed out with the scissors. The other loop is opened in the same way.

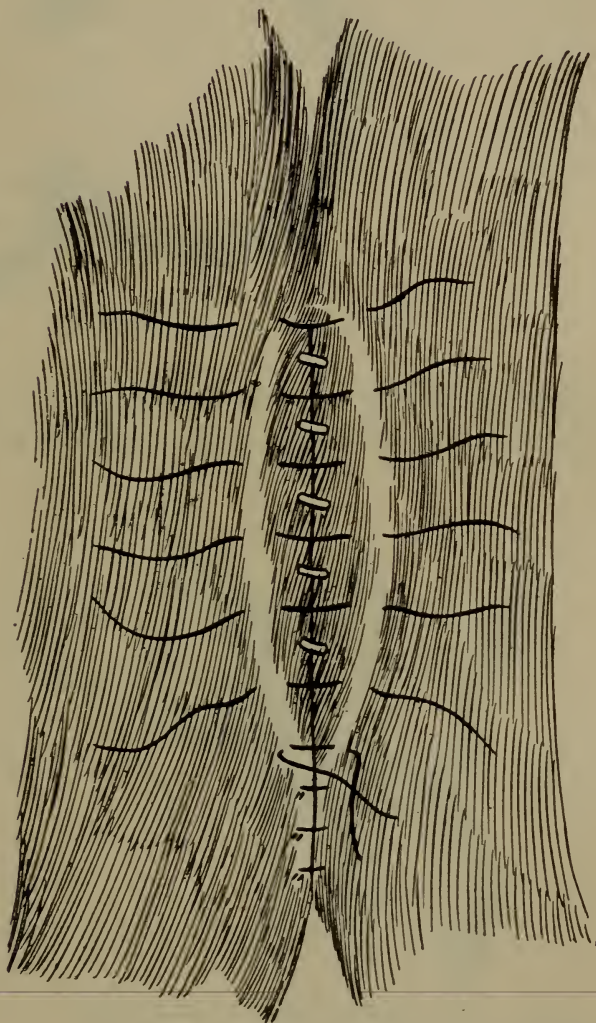
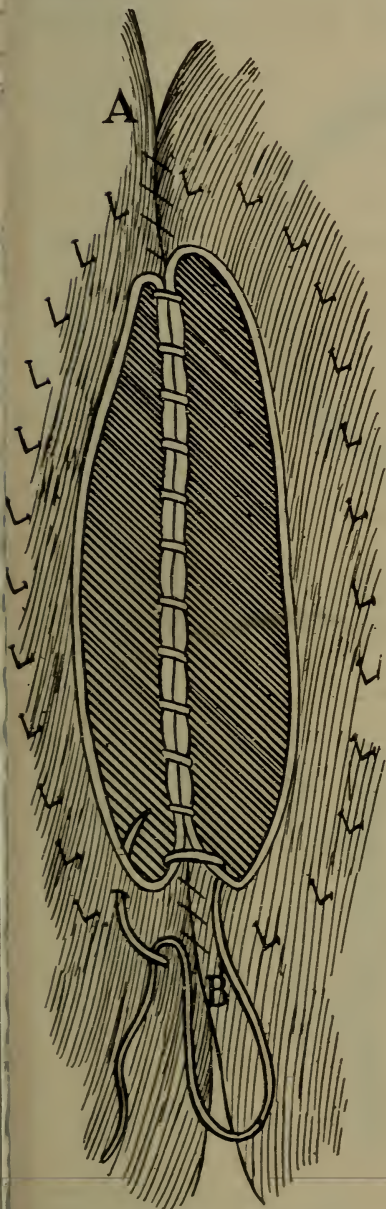


FIG. 509.—Lateral anastomosis; first part of the through-and-through suture applied (*Binnie.*)

FIG. 510.—Lateral anastomosis. Applying last of the Lembert sutures. Interrupted in this case, use the continuous instead. (*Binnie.*)

The adjoining edges are now to be coapted by continuous perforating suture (Fig. 508). As this suture progresses the opposite

angle of the wound is reached, but without interruption it continues to draw together the more widely separated borders (Fig. 509).

When it has reached the point of beginning, the terminal thread is knotted with the first which was left long, and so the perforating

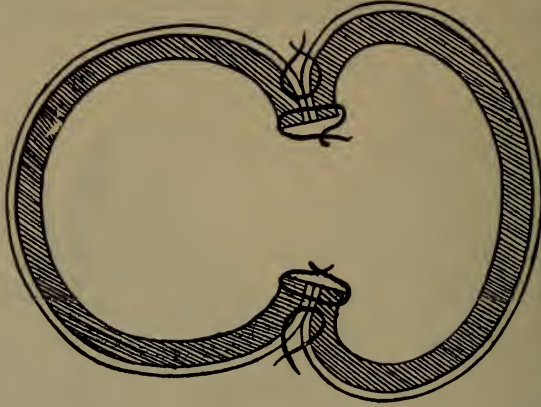


FIG. 511.—Cross-section of lateral anastomosis. (*Binnie.*)

suture is finished. Remove the clamps, wipe the bowel, and now return to the sero-serous suture and continue with that until the per-

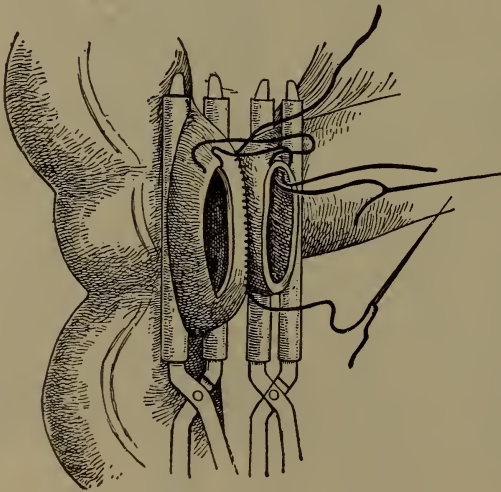


FIG. 512.—Termino-lateral anastomosis. Clamps and continuous suture employed. (*Binnie.*)

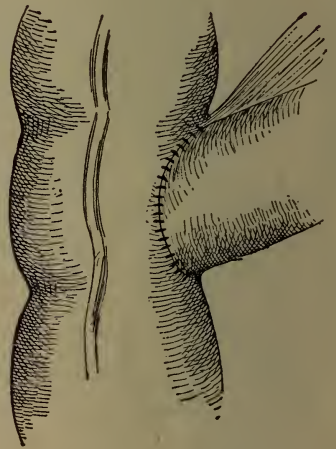


FIG. 513.—Termino-lateral anastomosis completed. (*Binnie.*)

forating sutures are completely buried or, in other words, until the sero-serous suture has traveled completely around the bowel and the terminal thread knotted with the primary suture.

If preferred, this sero-serous suture may be an interrupted instead of a continuous stitch (Fig. 510), but the continuous suture is more rapidly passed and is in every respect as secure. The main thing to be attained, however, is that the serous surfaces be brought into contact through the whole circumference of the bowel.

Fig. 511 shows the appearance of the bowel on cross section after such an anastomosis. This method may be modified in many ways, but exemplifies really the fundamental principles involved in any anastomosis of the digestive tube. It is purposely stated in its simplest terms and shorn of detail.

The technic of the termino-lateral form of anastomosis does not differ in any essential detail from that just described for the latero-lateral form (Figs. 512 and 513).

CHAPTER XV

IMPERFORATE ANUS

A correspondent addresses the editor of the Journal of the American Medical Association (September 8, 1906) to this effect:

“Mrs. B., a perfectly healthy woman of twenty-eight years of age, after a normal pregnancy, gave birth to a fine eight-pound boy, well nourished and healthy looking, and perfect in every way except there was no anus nor sign of any. A small amount of meconium was being passed through the urethra. The next morning a local surgeon was called in counsel and an incision was made through the floor of the pelvis and dissected up along the coccyx, but no rectum was found nor trace of a gut until the sigmoid flexure was reached in the free peritoneal cavity. A large opening in the sigmoid was followed by a discharge of feces. No attempt was made to stitch the gut to the wall or the integument. The opening was not closed in any way and no dressing applied, except that the nurse was directed to keep the site of the operation sponged with a saturated solution of boracic acid after each evacuation of the bowels. The child nursed well after the operation and has continued to do so. It sleeps nearly all the time, but has had no elevation of temperature; the passages come free and the urine is passed normally. Can you suggest any means of treatment that will permit the child to grow up with at least a slight control of bowel movement?”

That is the question which occurs to every doctor compelled to deal with these cases, which are fortunately rare. The little being's life rests upon the doctor's readiness to act; and if it survives, whether or not it carries a life-long disability depends largely upon his skill.

It usually happens in the course of such cases that no meconium passes within a reasonable time after the baby's birth. It grows restless, perhaps vomits, and for the first time it is suspected that there is some abnormality about the rectum or anus, which an exam-

ination verifies. It is imperative to relieve the condition at once and if no specialist is within reach, the doctor must undertake it. He may find it quite easy or he may find it impossible.

In the first instance, the anus and rectum may be both fully developed, but in passing a finger or probe into the orifice, a thin bulging membrane can be felt, apparently almost ready to burst when the infant cries. A sharp-pointed bistoury, wrapped and introduced along the finger or a grooved director, easily punctures the membrane followed by a free passage of meconium; and thereafter the bowel

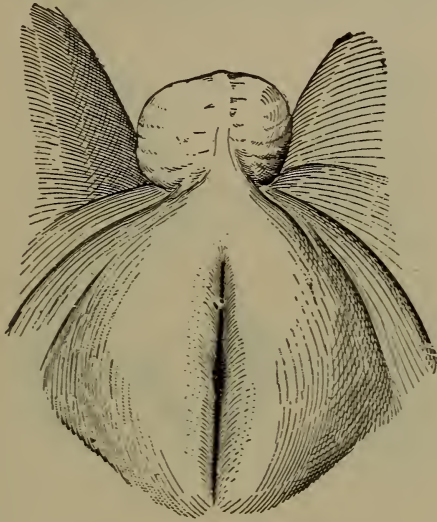


FIG. 514.—Incision for imperforate anus. (Veau.)

readily empties itself. The mother is directed to dilate the opening daily with her little finger, and that, with an occasional stretching with a bougie, is sufficient.

In another case there may be no depression where the anus should be. The median raphe extends unbroken from the scrotum to the coccyx. The anus is absent and it may be practically impossible to tell how high up in the pelvic cavity the rectal cul-de-sac may be; and yet it is one's duty to hunt for it *through the perineum*.

Operation.—Put the patient on its back with thighs flexed and pelvis elevated—in short, in the lithotomy position. Employ a light chloroform anesthesia, not that there is any danger if the anesthesia is carefully conducted, unless, indeed, the operation has been too long

delayed, but that a little straining on the patient's part may help to locate the bowel.

Make a *median incision* from the base of the scrotum or from near the posterior vaginal wall to the coccyx, which must be exposed (Fig. 514). A number of eventualities may present:

(1) One may find immediately beneath the skin some of the fibers of the external sphincter, a favorable indication. Split these fibers by blunt dissection. Free incision may spoil their usefulness. Beneath the muscular layer appears the lobulated fatty tissue peculiar to the new-born, which is to be next divided. Here one must go

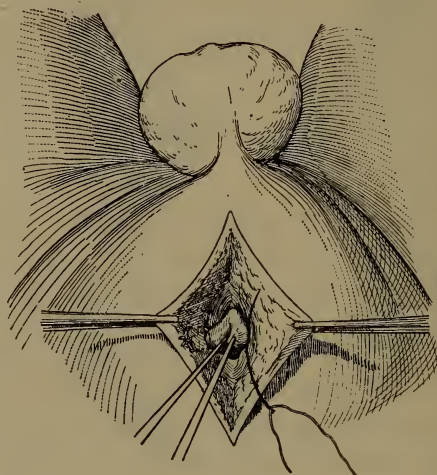


FIG. 515.—Retention suture. (Veau.)

slowly, keeping in the middle line and all the time working toward the coccyx. The danger is in front. If toward the hollow of the sacrum, a fluctuating pouch is felt or a brownish rounded tumor is seen, one breathes easy, knowing that the imperforate gut is within reach. But do not be in a hurry to open the gut. It is first to be secured by passing a suture on each side of the middle line or by catching the bowel wall with forceps. The suture should not perforate the bowel.

Making gentle traction on the bowel, proceed to free it by careful blunt dissection. Do not use knife or scissors to divide what seem to be fibrous bands, for it is possible they contain the blood supply of the bowel; and, if divided, dangerous bleeding may occur or the tissues become gangrenous.

As the pouch is freed, it is gradually pulled down into the wound; and if they were not passed before, two sutures are now passed with which eventually to fasten the gut to the skin opening (Fig. 515). Now is the time to open the pouch and let the meconium flow out. It may require several minutes for the bowel to empty itself. Evert the mucous membrane, enlarging the bowel wound a little if necessary. Suture the mucous membrane directly to the skin; no other tissues should intervene (Fig. 516).

Irrigate thoroughly and apply a gauze dressing, which is changed as often as soiled. The functional result is often surprisingly good.

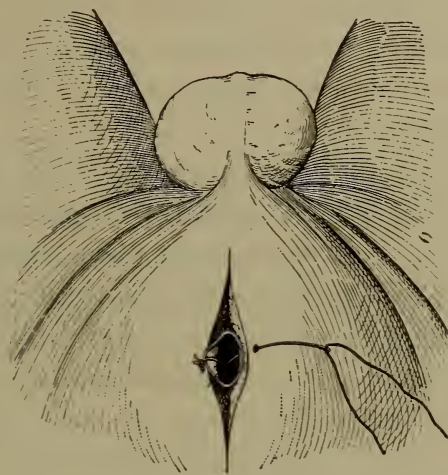


FIG. 516.—Muco-cutaneous suture. (Veau.)

Broncho-pneumonia may develop when the operation has been too long delayed and septic absorption has begun.

(2) *The pouch cannot be drawn down.* In that case when the bowel is opened the discharge will have to flow over the raw surfaces of the flesh wound which will need to be kept open with bougies. Infection is a constant danger, not to speak of lack of control of bowel movement.

Better than to leave the wound in this condition, the coccyx and a part of the sacrum may be removed and the gut brought out posteriorly. Still better, open the peritoneal cavity, find and draw down a loop of the sigmoid to fasten in the wound.

(3) *The pouch cannot be found.* Obtain more room by resecting the coccyx, follow the sacrum a little higher, open the peritoneal

cavity and search for the cul-de-sac; if possible, draw it down into the wound and suture.

If all these measures fail, there is nothing to do but make an *artificial anus* in the inguinal region. Indeed, there are those who advise this from the first with the idea that later the operation for the construction of a normal anal orifice can be better undertaken.

Tuttle says (Diseases of the Anus, Rectum, and Pelvic Colon) that where there is no evidence that the rectal pouch can be easily reached, and where the child is in an enfeebled condition with distended abdomen, fecal vomiting, and nausea in progress, one should not hesitate to choose the abdominal route, perform an inguinal colotomy at once and thus afford an immediate exit to the intestinal contents, and an escape for the gases which are causing the distention and the constitutional disturbance.

To this same volume the reader is referred for a full discussion of these problems, and for consideration of those other forms of imperfect development in which the anus has abnormal openings. Such cases are not strictly emergencies, for usually there is a partial means of escape for the bowel contents.

CHAPTER XVI

TORSION OF THE PEDICLE OF OVARIAN OR UTERINE TUMORS; OF THE SPERMATIC CORD; OF THE PEDI- CLE OF THE SPLEEN; OF THE OMENTUM

Torsion of the pedicle of an ovarian or uterine tumor may be either chronic or acute; in the one case developing so slowly as to produce no symptoms or even no effect upon the tumor unless merely to inhibit its growth, for in the adhesions are new sources of nutrition; in the second case developing suddenly and producing a train of symptoms that demand immediate relief. The acute cases alone, then, are to be regarded as emergencies.

Cysts of the ovary, especially those which are spherical, non-adherent, and connected by a long pedicle, are most liable to this accident.

Kelly finds two causes for this rotation. The first of these is in the effort of a large cyst to accommodate its convex surface to the concavity of the distended anterior abdominal wall. The second cause is found in contractions of the anterior abdominal wall, which act upon the part of the tumor nearest the middle line. The effect of the force thus applied is to rotate the tumor. In the case of smaller tumors lying in the pelvic cavity it is likely that unusual movement in the intestine or readjustments of the pelvic viscera may produce the same effect. Kelly quotes Küstner to the effect that tumors of the right side, as a rule, rotate from left to right, while left ovarian tumors rotate from right to left.

The *diagnosis* of acute torsion is not difficult if an ovarian cyst is known to be present. If such a tumor was previously unsuspected the certain diagnosis may be impossible, especially if the case is seen late and general peritonitis is developing.

The symptoms, as a rule, arise without warning. There are severe colicky pain, vomiting, marked constipation, and the appearances of collapse. Abdominal rigidity and tension rapidly increase. This is

true of the more urgent cases. In general, the severity of the symptoms vary with the degree of torsion.

Appendicitis and acute intestinal obstruction present the greatest difficulties in differential diagnosis which it is desirable to make, not to determine the advisability of operating, but to determine beforehand the kind of operation one is to undertake. Ranzi (Berliner klin. Wochenschrift, Jan. 6, 1908) reports four cases of torsion of ovarian cyst which were not differentiated from appendicitis, except in one case, before the operation, and in this case by the pains in urinating. In three of the cases there had evidently been mild attacks of torsion which had subsided and which had been diagnosed as catarrhal appendicitis.

The treatment is operative, and, as has been indicated, the operation must often begin as an exploratory laparotomy, for though the symptoms indicate the seriousness of the case they may not reveal its character. Delay is dangerous in these cases, and seldom will one regret having operated early, for nearly always the lesions found exceed the expectation.

The appearances once the abdomen is opened will depend upon the size of the tumor, the degree of torsion, and the time of intervention. Usually the tumor will be found enveloped in loops of intestine bound together by soft adhesions (Fig. 517).

These adhesions are to be carefully separated, and one must proceed with prudence for the cyst may be filled with pus and its walls may be friable. The intestines, detached, are to be held out of the way with compresses and the tumor thus brought into view. Its nature may be at once apparent in spite of the fact that it is discolored, dark red, or even black. If it is a cyst not quite so large, it may resemble a dilated cecum. Its attachments are carefully broken up, and gradually working toward its base the pedicle is finally defined.

An effort is now made to lift the tumor out of the abdominal cavity, and there need be no hesitancy in enlarging the abdominal incision if necessary. Usually it is to be lifted out with the two hands applied to its base. Occasionally only after its pedicle is untwisted is it possible to deliver it.

Next the pedicle is tied near its point of implantation, divided,

and thus the tumor is removed. If there are no evidences of infection the abdomen is to be closed without drainage.

Tumors springing from the *uterus* are much less likely to become twisted. Yet, in the case of large non-pedunculated fibroids, the

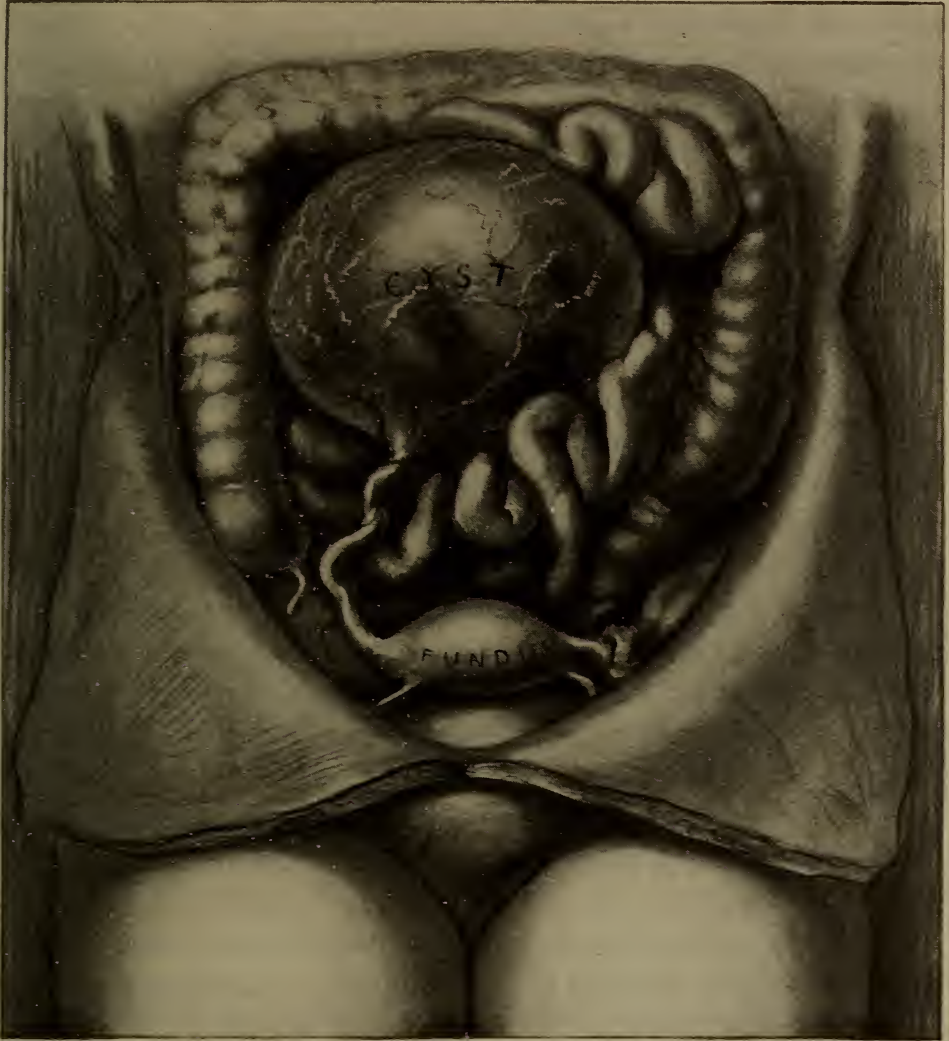

FIG. 517.—Torsion of the pedicle of an ovarian cyst. (Montgomery.)

uterus itself may be rotated and give rise to symptoms which demand relief. In such a case the intervention may be quite complex.

In some instances a *myomectomy* may be sufficient. The uterine wall is incised over the long axis of the tumor, which is exposed and peeled out, and the hemorrhage checked by suture of the uterine

wound. The uterus may still tend to rotate and may require fixation.

In still other instances, *hysterectomy*, either supra-vaginal or complete, may be the procedure necessary for relief. This will be the case when the condition of the uterine wall after removal of the tumor would preclude repair.

Harsha reports to the Chicago Medical Society (Annals of Surgery, Nov., 1905) a case of torsion of the pedicle of an ovarian cyst in a woman of thirty-three, who for several years at intervals had had attacks of intestinal obstruction, accompanied by pain and vomiting, lasting for three or four days.

Her last attack began suddenly with pain, vomiting, constipation, tenesmus, accompanied by the symptoms of shock. At the end of four days the abdomen was opened. A cyst, the size of an orange, with twisted pedicle was removed. There was neither peritonitis nor gangrene. There had been no further indications of obstruction.

In a second case the cyst was as large as a fetal head and black to within an inch of its implantation.

Ochsner, commenting on these cases, says that symptoms of obstruction are not uncommon in such cases and that the history is often that of volvulus.

He cites a case in which the abdomen had been opened by a practitioner who believed he was dealing with intestinal obstruction. Having opened the abdomen, however, he discovered a large black tumor. Disconcerted, he stopped his operation, hurriedly transported the patient to the Augustana Hospital where Ochsner completed the work.

The doctor performing an emergency laparotomy must not have his mind too definitely fixed on one diagnosis. Expecting one thing, he must still have in view the possibility of having to deal with one or more of a variety of conditions, and so will not be taken completely unaware.

John Cahill and Sir William Bennett give the history of a case which well exemplifies the difficulties of diagnosis, the occasional complexity of treatment, and the dangers of delay (London Lancet, Dec. 8, 1906).

The patient, aged seventeen, was suddenly seized with abdominal

pain. There was some tenderness and resistance over the right iliac fossa. The temperature was 98.8° , the pulse 90. Bowels were emptied by enemata, but the pain continued. On the third day the temperature ran up to 101.8° and the pulse to 120.

An operation was still refused until at the end of a week the patient's condition had become very grave. An operation for appendicitis was then performed and the appendix found adherent and filled with pus, in addition to other evidences of chronic disease. Further examination revealed a dark, firm mass occupying the upper part of pelvic cavity and intimately adherent to the bladder and uterus. Exposed by extending the incision, it proved to be an ovarian cyst the size of a cocoanut with a thick pedicle twisted upon itself for three-fourths of a turn. Its walls were thin and blackish, and its contents mainly decomposed blood. The cyst was removed and the patient recovered.

Dr. Cahill, commenting on the case, remarked that the situation of the cyst was unusual in that it was wedged between the bladder and uterus, whereas one expects to find such a tumor in Douglas' pouch.

Sir William Bennett says that although cases not infrequently operated upon for appendicitis prove to be cases of torsion, yet the coexistence of the two conditions must be very rare. He suggests that in this case the appendicitis, by aggravating the intestinal peristalsis, had displaced the tumor with consequent torsion of its pedicle.

Angus (*British Medical Journal*, Jan. 27, 1906) reports an attack in a child of six, beginning with pain, vomiting, and abdominal distention. By the rectum a mass was palpable in the cul-de-sac. A diagnosis of appendicitis with abscess formation was made. Operation. The appendix was inflamed at the end where it was attached to a dark cystic swelling in Douglas' pouch. It was the right ovary darkly congested, large as a duck's egg, and with twisted pedicle. Its contents showed it to be an ovarian dermoid.

TORSION OF THE SPERMATIC CORD

Malformations and imperfect descent predispose to rotations of the testicle—an accident rare yet none the less to be borne in mind

as a possibility. The exciting cause is usually to be found in trauma. A heavy lift or strain may produce it.

It is readily comprehended that an incompletely descended testicle shifting backward and forth through the external ring could be forcibly rotated. The rotation may occur in two ways: either the testicle with its tunica vaginalis may be turned or the testicle alone may rotate. The spermatic vessels, nerve, and vas deferens are all involved in the resulting torsion.

The symptoms range from moderately severe to grave. Pain, nausea, vomiting, constipation, and tympanites signalize the attack, and soon the signs of local inflammation appear.

In the more serious cases the pain begins abruptly and persists. It usually radiates from the inguinal region and lower part of the abdomen, and may be intense or even produce shock. The constipation is usually relieved by enemata.

The presence of a painful tumor in the inguinal region together with the symptoms point to strangulated hernia and torsion of the spermatic cord equally, and the differential diagnosis may be a matter of difficulty. The pain is much more intense and sudden in its onset than epididymitis. The cord, in torsion, can be felt tender and swollen; it cannot be felt in strangulated hernia. Of course in strangulated hernia the constipation is absolute.

Once the diagnosis is assured, an effort to untwist the cord should be made and occasionally it will succeed. It is recorded of patients, who, having had several attacks, learn to give themselves relief. If manipulation fails it is imperative to operate without delay, for there is danger of gangrene of the testicle.

An *incision* extending from near the external ring follows the cord down toward the base of the scrotum. Layer by layer the tissues are divided until the tunica vaginalis is reached. The tissues are often edematous, reddened, and swollen. The tunica presents itself as a thin-walled sac. Open it and drain away the serum and the testicle will be found, possibly deformed, perhaps difficult to recognize, and above it is the twisted cord.

Seize the testicle and rotate it from right to left in order to relieve the torsion and restore the circulation. The further procedure will depend upon the integrity of the testicle. If its violet color fades,

if the congestion diminishes, it is almost certain the testicle will recover, and it is therefore to be preserved. If it is black or mottled or flaky, remove it by tying the cord above the torsion (see Castration). If its integrity is doubtful, preserve the testicle but provide ample drainage for the tunica vaginalis.

Lichtenstern, of Vienna, reports a case of torsion of the spermatic cord in a man of forty-six, which began with lifting a heavy load. The scrotum soon became enlarged, and vomiting and constipation ensued. A diagnosis of inguinal hernia had been made, and efforts to reduce had failed.

At the time of entrance at the hospital his temperature had reached 102° and his pulse was bad. In the scrotum was a large tense tumor and in the inguinal canal another smaller.

On opening the scrotum an enormously swollen, turgid testicle was found whose spermatic cord was twisted to 360 degrees. Part of the omentum was found at the internal ring. The testicle was untwisted and removed, the cord resected and the inguinal canal closed as in herniotomy.

TORSION OF THE PEDICLE OF THE SPLEEN

The pedicle of the spleen may become twisted in cases of wandering spleen. As in other varieties of torsion, it may develop slowly, producing no marked symptoms and resulting only in congestion of the organ and increase in size. Developing suddenly it is accompanied by the symptoms of general peritonitis or intestinal obstruction, and collapse. It may be mistaken for one of these conditions. The tumor may suggest subphrenic abscess.

As Moynihan says, in the great majority of cases, *splenectomy* is the better course to pursue, and this is especially true when thrombosis of the splenic vessels, infarcts in the spleen, gangrene or peritonitis upon or around the spleen are present; when also the organ is enlarged, it should be removed, for even though the pedicle be untwisted, it is useless to try a splenopexy.

The result of fastening in place a small wandering spleen is doubtful. If it is enlarged, failure is certain. Fortunately, as Hartmann has pointed out, a displaced spleen is usually not at all difficult to remove because the lengthened pedicle permits of ready delivery;

and the after-effects are not so serious as those which attend removal for organic disease. (Splenectomy, page 550.)

TORSION OF THE OMENTUM

Torsion of the omentum must naturally be a rare condition, and yet is to be thought of when symptoms of intestinal obstruction arise in those who have a hernia or are obese.

Torsion of the omentum as might be expected is very painful. The pain, which is probably due to the plugging of the omental vessels, may simulate appendicitis. It is not important that the differential diagnosis is sometimes not made, for the symptoms indicate operation.

Rinchea and Corner describe a case in the British Medical Journal, Jan. 20, 1906. The patient, a man of forty-eight, had had a hernia for thirty-seven years, and had worn a truss for thirty-three; the hernia had been reducible and painless. He was suddenly seized with pain, and the hernia became irreducible. The pain increased, and the tumor as well, though after two days the bowels moved, a circumstance which ruled out strangulated hernia. The temperature remained 99°, the pulse 102. The skin over the lower part of the abdomen and inguinal region became reddened and the region tender. An incision over the inguinal canal found the tissues inflamed, and on opening the hernial sac a small mass of omentum was found twisted on itself five times, but not constricted at the internal ring. The *mass was resected*, and the radical operation for hernia performed.

In another case, the patient, a man of forty-five with recent direct hernia, a mass of omentum was found, pedunculated, the size of a walnut, and containing a hemorrhagic cyst.

Cullen, of Baltimore (Johns Hopkins Hospital Bulletin, Dec., 1905), reports a case occurring in a very heavy man. The patient, a railway conductor, had found it necessary to eject a recalcitrant passenger and succeeded only after a struggle. In a few hours he had developed the symptoms of appendicitis.

At the operation a gray, vascular, nodulated mass was found which ended above in a tightly twisted pedicle and which on removal proved to be the omentum.

CHAPTER XVII

RUPTURE AND HEMORRHAGE OF TUBAL PREGNANCY

Rupture of the sac of an ectopic gestation is far from being a rare accident (Fig. 518). When it occurs, it is a major emergency, one in which the doctor, isolated though he may be, must act and without delay. Eighty-five per cent. of these cases operated upon recover; 85 per cent. of those treated by expectancy die. These figures are in themselves sufficient argument, but when we add that the

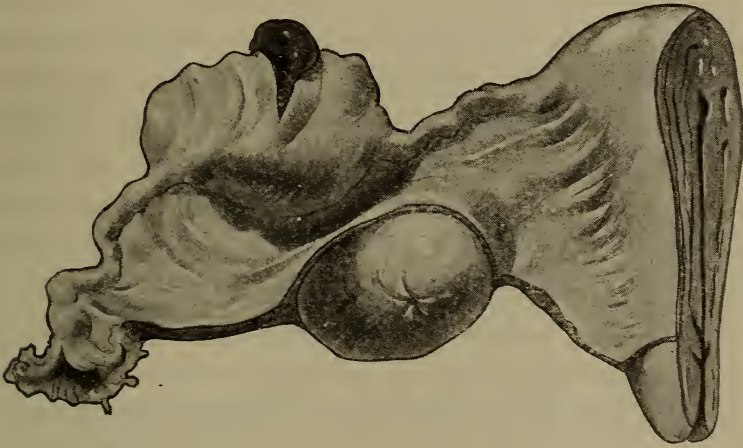


FIG. 518.—Ruptured tubal pregnancy. Clot protruding from sac. (Montgomery.)

gravity of the condition grows out of *hemorrhage*, the reason for immediate intervention must be admitted by all. Even in case the hemorrhage tends to cease spontaneously, the *urgency* is scarcely less pressing to *prevent infection*. For, from a diseased tube or a stagnant fecal current, bacteria may escape to find a culture medium in the blood free in the peritoneal cavity.

That the *diagnosis* of an extra-uterine pregnancy, even when suspected, is difficult, no one will deny. After the most careful examination, one may not avoid error. More often, the condition is not even suspected until rupture occurs.

A tubal pregnancy may be unrecognized, but there can be *no excuse for overlooking a ruptured tubal pregnancy*. It can scarcely be mistaken for anything else. Even if we admit that exact diagnosis may be impossible, yet the indications for intervention are unmistakable. And that, after all, is the important thing. One does not do grave emergency operations on mere impressions or suspicions or the fear that such and such may be the case. We must have a clear clinical picture in mind.

The attack comes on suddenly. There are pain, shock from the peritoneal tear, and vomiting, suggestive of acute intestinal obstruction. One might also think of appendicitis or a renal calculus. There is often a bloody uterine discharge. Brickner says of the pain that it is usually localized over the site of the lesion. It has no definite character; it may be cramp-like over the affected tube; it may simulate labor pains; it may be sharp and sudden. The usual symptoms of pregnancy may be present, but their absence does not argue against the extra-uterine pregnancy. We have, as yet, no definite data by which we differentiate between the various forms (Medical Standard). The history of the case and, finally, the signs of progressive internal hemorrhage point to the nature of the accident. The pulse grows more rapid and feeble, the temperature falls, the features are blanched, dyspnea appears and all the symptoms of collapse. *Vaginal examination* completes the diagnosis. One may find the uterus but little enlarged, but on one side or the other, rising out of the retro-uterine pouch, a boggy mass of variable size is felt. Dixon, of St. Louis (Interstate Medical Journal), says that in fifteen cases, he found the pregnancy on the right side in all but one, and this patient had the peculiar fortune to have one on both sides. The right side was relieved by operation, and six months later the left side necessitated a second operation. Dixon adds that rigidity of the abdominal walls was present in most of these cases, though the absence of rigidity is often named as a differential diagnostic point.

There may be an element of confusion. Vineberg, of New York (New York Med. Jour., Feb. 22, 1906), reports two cases out of his fifty-three in which there was a combined intra- and extra-uterine pregnancy. He notes that a persistence of uterine bleeding after an operation for extra-uterine pregnancy should suggest the possibility

of an intra-uterine gestation. He adds, with respect to diagnosis of the condition generally, that amenorrhea, followed later by pain and irregular uterine bleeding, should always put one on his guard.

From the history, then, and from the physical examination one must diagnose the condition. On the signs of *progressive internal hemorrhage* the decision to operate immediately is based, and one should scarcely ever deem it too late, for even in the face of the most menacing conditions, we must hold bravely to the last resource in which, even in the desperate cases, there is often safety and life.

Operation.—As Lejars says, the operation is moving and dramatic, but presents no especial difficulties if one but keeps cool and knows what is to be done.

Instruments.—The instruments necessary are scalpel, scissors, artery forceps, two long clamp forceps, two retractors, and curved needles.

General Anesthesia.—General anesthesia is necessary and must be closely watched. A continual hypodermoclysis is an excellent means of combating the combined effects of shock and anesthesia. It should not be begun, however, until the hemorrhage has been controlled.

Antisepsis.—It is scarcely necessary to say that it is of little use to save the patient from hemorrhage to die a few days later from sepsis. The peritoneal cavity, under the conditions assumed, is a dangerous culture medium.

The *Trendelenburg position* is almost indispensable, and if necessary may be improvised.

Incision.—A median incision extending from the umbilicus toward the pubes is made. Do not wound the bladder, which may be pushed upward and forward. This, however, is not particularly serious unless the wound should be overlooked. Waste no time. As soon as the peritoneum is opened, catch its edges with artery forceps and enlarge the orifice upward and downward. Do not try to sponge out the cavity. Without regarding the clots, which may mask the viscera, plunge a hand into the pelvic cavity and locate the uterus, which is easily recognized. To one side, a thick, doughy or friable mass will be felt. Slip your fingers under it, break the adhesions, and enucleate it. This will empty the retro-uterine pouch—the cul-de-

sac of Douglas. Feel with finger and thumb for the pedicle and, if possible, pull the entire mass up into the wound and *clamp*. If the mass is not adherent, a single clamp enclosing the broad ligament from the outer side and passing under to include the tube will suffice (Fig. 519). If there is too much adhesion, clamp on either side of the pedicle. When the clamps are placed, the chief end of the operation has been attained. Do not waste time trying to catch the bleeding points, but ligate *en masse*.

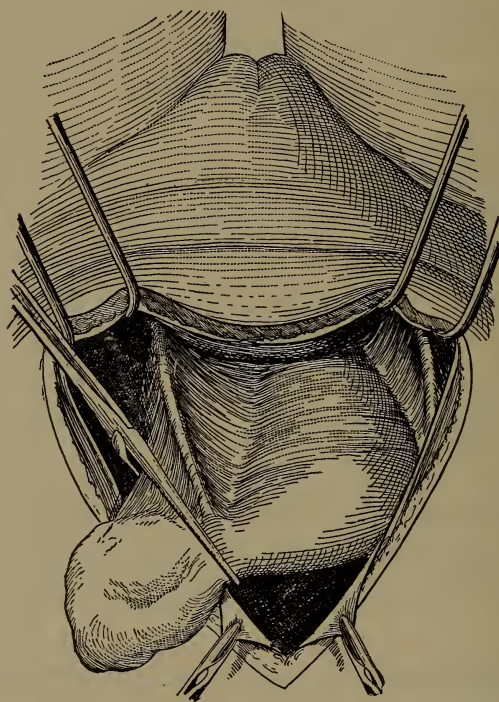


FIG. 519.—Forceps applied to the tubo-ovarian pedicle. Trendelenburg position. (Veau.)

Ligate the pedicle. With a blunt, curved needle armed with No. 3 catgut, transfix the pedicle close to the cornu of the uterus, between it and the forceps (Fig. 520). Ligate and then carry the ligature around the lower segment of the pedicle and tie again, directing the assistant to pull up on the clamp, and finally carry the ligature around the entire mass and tie a third time. Preserve the ends of the ligature. Resect the tumor and lift up the stump by means of the threads to see if there is any bleeding (Fig. 521). This ligature stands between the patient and death. If two clamps have been used, it will be necessary to ligate "*en chaîne*."

Now *clean out the clots*, mop out the blood, and lower the pelvis to drain the upper part of the abdominal cavity. The quantity of blood is often enormous. If the patient is very weak, do not prolong the task of cleansing it all out; yet in the long run, it is better to take the time to cleanse out the fossa and wipe the intestine and omentum, for then the abdomen may be closed without drainage.

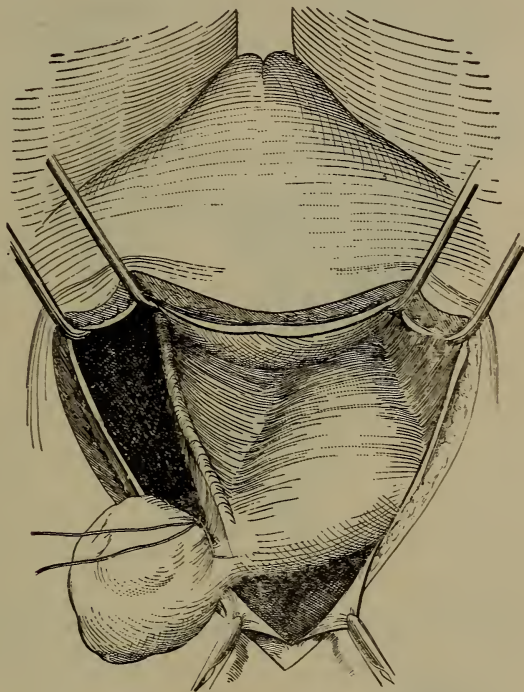


FIG. 520.—First ligature applied. (Veau.)

Drainage. If there is oozing, apply a gauze drain at the site of the tumor, and insert three or four drainage-tubes into different parts of the cavity to carry out the blood left behind. Do not forget to *fix* the drains, lest they be lost in the abdomen.

Suture the wound *partially*, unless able to dispense with drainage, in which case suture completely. Apply a dry dressing of gauze and absorbent cotton. Inject salt solution. After twelve hours, change the dressing, which will probably be saturated; thereafter change daily. About the seventh day the tubes may be shortened, and about the fifteenth day, or often sooner, altogether removed.

Interstitial tubal pregnancy (Fig. 522) may occasionally be met with and present complications. A case described by O. G. Pfaff, of

Indianapolis (Western Clinical Recorder, March, 1903) illustrates the subject. On opening the abdomen a large reddish bag presented, which seemed to develop from the right wall of the uterus, involving

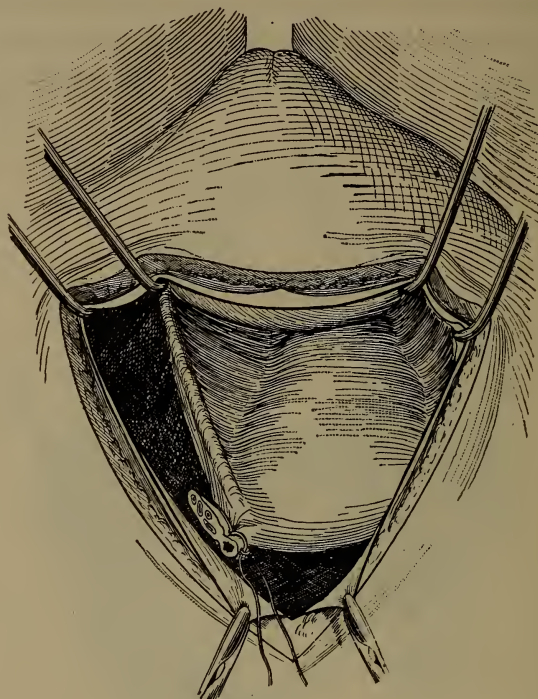


FIG. 521.—Ligation and division of the tubo-ovarian pedicle. (*Veau.*)

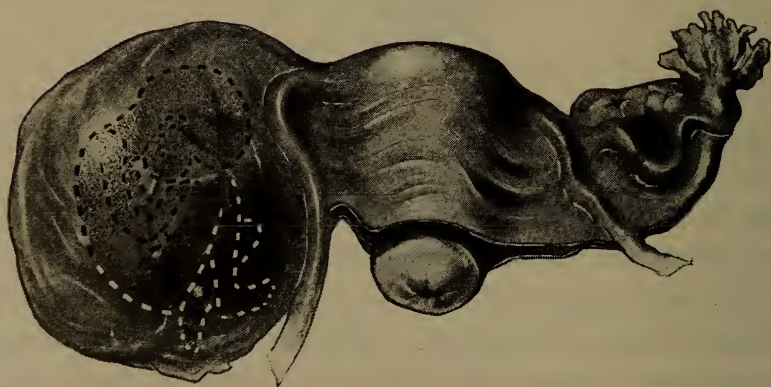


FIG. 522.—Tubo-ovarian pregnancy. (*Montgomery.*)

the right tube. In order to minimize the hemorrhage as well as to secure the tumor, the upper portion of the broad ligament was clamped and another clamp placed to the left of the tumor passing

obliquely across the fundus and including the uterine artery. The sac was now incised at its summit and the fetus, membranes, and placenta turned out. No ligatures were required. The sac was partially sutured, a drainage-tube fastened in its cavity and brought out through the lower angle of the abdominal wound. The drainage-tube was removed on the fifth day, and recovery was complete.

In certain of these cases the hemorrhage may be very difficult to control. A "V" shaped section from the uterus in the region of the cornua with firm suturing may succeed.

Finally in more obdurate cases a *hysterectomy* may be necessary.

CHAPTER XVIII

CESAREAN SECTION

Cesarean section, designed primarily as an operation to save the babe after the mother's death, is to-day of far broader application. Without considering its exact indications, which for that matter the whole profession is not yet agreed upon, it may be stated broadly that it is the method of choice when the child cannot otherwise be delivered alive. Unfortunately at the present time it is usually what it should not be, viz., an emergency operation.

The Technic of Operation. *First Stage: Laparotomy.*—Incise the abdominal wall. The incision extends in the middle line to within 2 inches of the pubes and should be at least 4 inches in length. If the uterus is to be brought out of the abdominal wound it will require to be longer. The peritoneum is to be exposed and opened up in the usual manner. The abdominal walls are often quite thin. As soon as the peritoneum is opened the uterus pushes into view. Correct any lateral deviation. Hurriedly wall off the uterus with sterile compresses, or deliver the uterus, protect with sterile compresses and suture the upper angle of the peritoneal wound.

Second Stage: Incision of the Uterus.—Keep exactly in the middle line. Make a small incision in the uterus at the level of the lower end of the abdominal wound that you may not later encroach upon the lower segment of the uterus.

The peritoneum and superficial muscular layers are divided with the bistoury, the deeper muscular fibers separated with the fingers. Make a small opening in the mucous membrane. Through this wound slip a finger into the uterus and on it as a guide divide the uterine wall with scissors toward the summit; the incision should be 6 or 7 inches long. If the placenta is attached over the median line, cut through it also. It makes no difference if the work is done rapidly.

Third Stage: Deliver the Child.—Slip the hand into the uterus. Grasp the feet, delivering the breech first. Clamp the cord in two places and cut between.

Fourth Stage: Remove the Membranes.—As soon as the child is delivered the uterus contracts and often the placenta is detached at once. If not it must be peeled off with the fingers.

Fifth Stage: Suture the Uterus.—Repair the uterine wall with 7 or 8 interrupted catgut sutures deeply placed but not reaching the mucosa; or suture the mucosa first. Complete the repair by a few superficial sutures. Suture is the best means of hemostasis, but the bleeding is usually inconsiderable, especially if the uterus is brought outside and bent toward the pubes.

Sixth Stage: Suture the Abdominal Wall.—Repair the peritoneum with continuous suture; the fascias with chromic gut or plain catgut; the skin with silkworm-gut.

These are the principles involved, bared of details which, of course, vary with the operator and with the environment. Examples are not wanting in current literature. A few will serve to bring out practical points.

Lanphear, of St. Louis (American Jour. Surgery, Dec., 1906), formulates a technic for country practice. The operator should have a physician for assistant, or a trained nurse. The anesthetic should be given by a physician.

Instruments.—Vaginal retractor (for cleansing the vagina), knife, scissors, 4 hemostats, needles, chromic catgut No. 2, silkworm-gut, safety-pins.

The containers for the solutions must be boiled and singed with burning alcohol—one for bichloride, 1 to 2000, one for alcohol, and one for sterile water, a small dish or two for the instruments.

Dressings and Sponges.—Boil 15 yards of gauze and 12 towels free from fringes.

Preparation of Patient.—Pubes and vulva shaved. Abdomen scrubbed. When the anesthesia is complete scrub the vagina with gauze and soap and water, followed by alcohol.

Preparation of the Hands.—They are to be scrubbed for five minutes before disinfecting the patient and for five minutes after, followed by immersion in alcohol and then in the bichloride solution. Again

sponge the abdomen before covering the field with four sterile towels fastened with sterile safety-pins.

Abdominal Incision.—Deliver the uterus and surround with four towels wrung out of very hot water. Protect the edges of the wound with sterile towels packed in around the uterus.

Incise the uterus; deliver the child; clamp and cut the cord. The anesthetist may now look after the child if there is no one else to do so. Be careful in handling the child that your hands do not come in contact with anything not sterile. Deliver the placenta, mop out the uterus; suture. Lanphear advises a final row of Lembert sutures for the peritoneal covering of the uterus. Repair the abdominal wall; dress as usual; pack the vagina lightly and treat subsequently as after any other confinement. Brown, of Manchester, N. H., recommends practically the same procedure (*American Jour. Surgery*, Feb., 1907). He observes that the uterus should be kneaded for a moment to stimulate contraction. He uses in suturing the uterine wall, a row of twenty-day chromicized gut sutures, passing through all the layers a second row of Lembert sutures of silk.

Paul Martin, of Indianapolis, reports a case (*Medical Record*, Oct. 27, 1906). Operated after twelve hours of labor complicated by eclampsia and a narrow pelvis and in which the bladder was greatly distended and which could not be emptied by catheter. The bladder extended half-way to the umbilicus. The uterus was emptied through a 4-inch incision and the bleeding controlled by the assistant who grasped the cervix. The uterine sutures employed by Martin were a double row of interrupted muscular sutures of chromic gut and a continuous chromic gut for the serous coat. The bladder was not injured and afterward easily emptied. Mother and child both survived.

S. A. Reynolds (*Gaillards Southern Medicine*, Feb., 1905) reports an operation which, as he says, illustrates the principle that we should never be afraid to put forth an effort to relieve our patients when absolutely demanded, however hazardous and difficult the intervention and however meager the means at our command. Place, a log cabin with one room, lighted by a lamp without chimney. Patient, a colored girl of thirteen with pelvic diameters less than 2 inches; labor for twelve hours with a midwife in attendance. Both he

and Dr. Keen, with whom he consulted, realized the urgency, but neither had ever done a laparotomy. Their equipment consisted of two pocket cases of instruments, carbolic acid, a few ligatures, an earthen pitcher and bowl, with teakettle of hot water. They sterilized their instruments and hands in carbolic solution. Patient was laid across the bed with feet on the floor. The abdomen washed. While Dr. Keen gave the chloroform Reynolds made an incision from the umbilicus down. The sides of the abdomen were pressed against the sides of the uterus to prevent bleeding into the abdominal cavity, and the uterus opened and emptied.

One suture was put in the uterus. Abdominal wall closed with silk. On the fourth day the temperature was 103.5° , pulse 150, resp. 36, but the symptoms of infection subsided and by the fourth week the patient was well.

CHAPTER XIX

RUPTURE OF THE URETHRA¹

By a fall astride a hard or sharp-margined object, by accidents of saddle or bicycle, by a kick or blow, by a fracture of the pelvis, the urethra may be ruptured. The urethral canal is forced up against the pubic arch or against the sharp edge of the triangular ligament, and is lacerated while the more elastic integument of the perineum escapes.

Any part of the urethra may suffer, although usually only one part is involved in a given case. The prognosis, and in some degree the treatment, depend upon the portion injured, though the exact location is not always easily determined.

Again the prognosis and treatment depend upon whether the

¹ "We consider it unnecessary to speak of the medical treatment which is absolutely valueless, and while the mechanical treatment has been in favor even with the surgeon, it must be condemned if it becomes a general procedure.

The introduction of sounds and catheters into a lacerated urethra will almost invariably be followed by infection at the point of laceration, notwithstanding the aseptic conditions under which the catheterization is performed. The general practitioner has been accused of inefficiency and carelessness in sterilizing his instruments. While this is true to some extent, it will be seen later, when speaking of the Bacteriology of the Urethra, that a small aseptic instrument may cause infection because the traumatism produced by the passage of a sound increases the virulence of the urethral flora, which normally is in a semi-saprophytic state of life.

On the other hand, the general practitioner with less ability in the handling of sounds, especially when the urethra is inflamed and edematous, will cause false passages, increase the liability of stricture at the point of laceration and predispose the deep structures to infection and its consequences. It is our object to urge early surgical treatment in these cases and rational treatment of the later consequences. The expression, "traumatic stricture," must disappear from the medical vocabulary if the intervention in acute cases be immediate and rational."—Surgery, Gynecology, Obstetrics, Oct., 1906. Neff and Schroyer, Murphy's Clinic, Chicago.

rupture is total or incomplete, for upon the degree of laceration depend the rapidity of extravasation and later the dimensions of the stricture.

These, then, are the dangers: extravasation of urine, and in its wake suppuration, abscess formation, and general septic infection; on the other hand and later, stricture formation and all its attendant difficulties.

Rupture of the urethra, therefore, is always a serious injury, and in order that its dangers may be obviated, promptness of recognition and intervention is imperative.

The symptoms of injury to the urethra are definite though varying in degree and are: retention of urine, hemorrhage from the urethra, and perineal tumor.

These symptoms, together with the history of the case, readily make the diagnosis, but only by a careful study of each, recalling at the same time the anatomy of the urethra, may one decide upon the *location* of the injury.

(a) *Retention of urine* accompanies in some degree all traumatic ruptures, though one should not make a diagnosis from this symptom alone for retention may follow a mere contusion—an interstitial rupture, without any solution of the continuity of the canal and without obstruction. It has its origin in “shock,” perhaps, with temporary paralysis of the bladder musculature. In such a case, there is gradual development of a perineal tumor from the contusion, but, on the other hand, the bladder slowly fills and rises out of the pelvis.

In a few hours, the urine begins to dribble; a little later micturition becomes voluntary though painful, and gradually the function is restored to the normal. In actual rupture, the retention is *complete* and *continuous*.

(b) *Hemorrhage from the urethra* is indicative of rupture, but its amount in nowise points to the degree of urethral destruction. No inference may be drawn from it as to the severity of the lesion. In fact, the slighter the hemorrhage, the worse the outlook if the other symptoms are aggravated. For instance, if the mucous membrane alone is torn, the hemorrhage is immediate, perhaps voluminous, and yet the lesion is of minor importance. On the other hand, if the rupture is complete, the blood pours out into the lacerated tissues of

the perineum, and only a few drops may find their way through the occluded canal. Therefore, one must never conclude that because the hemorrhage from the meatus is slight, the injury is slight.

(c) *Perineal Tumor*.—There is always swelling in some degree following contusions of the perineum whether the urethra is injured or not. The perineal and scrotal tissues are ecchymosed and the scrotum especially is likely to be engorged with exudates. If the urethra is ruptured the bladder empties itself into the bruised perineal tissues, the ecchymosis rapidly becomes an *edema*, gradually thickening and expanding. It is at first an ovoid swelling in the middle of the perineum, but gradually spreads until the scrotum, the pelvis, and finally the abdominal walls are infiltrated, thickened or edematous to a marked degree. But do not forget that the absence of a perineal tumor does not always mean that the injury is slight. If the rupture is situated behind the anterior layer of the triangular ligament and if this is not torn, the transudates cannot reach the perineum, for this tendinous band limits the forward movement of the urine; and so, taking the direction of least resistance, it percolates through the cellular tissues of the pelvic cavity and passes up along the side of the bladder to the abdominal wall. Since, however, the anterior layer of the triangular ligament is nearly always torn to some extent, perineal swelling is nearly always present. Slight swelling will give no feeling of security that the injury is slight. It is obviously essential that one must have clearly in mind the anatomy of the urethra.

THE ANATOMY OF THE URETHRA

Stretched across the anterior segment of the pelvic outlet, between the rami of the pubes, is the triangular ligament, dense and fibrous, and arranged in two layers, separated by a $\frac{1}{2}$ -inch space. In contact with the deep or pelvic surface of the triangular ligament, is the apex of the prostate gland. In contact with the superficial or perineal surface is the bulb of the urethra, the knobbed posterior extremity of the corpus spongiosum. The urethra traverses the prostate, perforates and bridges the space between the two layers of the triangular ligament and then tunnels the bulb, runs the length of the corpus spongiosum, and emerges at the glans penis, the anterior

knobbed extremity of the corpus spongiosum. The part of the urethra anterior to the triangular ligament consists, then, of two portions, the penile and bulbous; the deep urethra of two, the prostatic and membranous, which later is the part which bridges the $\frac{1}{2}$ -inch space between the two layers of the triangular ligament. The clinical manifestations of rupture depend upon whether the bulbous or membranous portion is involved and in a minor degree upon whether the rupture is partial or complete. (See Fig. 546.)

CONTUSION OF THE BULBOUS PORTION

Injury to the bulbous portion is by far the more frequent; it is the form which the practitioner will nearly always find. It remains for him to decide whether the injury is a *contusion* or *rupture*, for the prognosis and treatment are quite different in the two degrees of injury. If the case is one of contusion, it is likely the hemorrhage was abundant; the patient complains of pain and inability to pass water; there is no perineal tumor though the tissues may be much bruised. After a few hours he begins to pass water after painful effort. The urethral bleeding may persist, but the bladder keeps well emptied.

Treatment.—The treatment is very simple. Keep the patient quiet, relieve the pain if necessary with small doses of morphine, and give some urinary antiseptic such as urotropin.

Do not pass a catheter. Why should you? The bladder empties itself; there is no perineal infiltration; and to do so would only increase the risk of infection. The normal micturition will return in a few days in the cases of mild contusion, and perhaps in a week the patient will be well. If, however, in such a case, after a few days micturition should become more painful and finally impossible, due to urethral swelling or spasm, catheterization is indicated. Try a large, soft, aseptic catheter first; try to carry it gently along the upper wall of the urethra. You may fail and be forced to fall back on a catheter of small size, but in no case must violence be used or the attempts prolonged. The catheter may be left in if the introduction was difficult, but it must be kept under constant surveillance, and at the first appearance of a *perineal tumor*, indicative of infiltration,

operation is imperative. If a catheter of small size has to be employed, it may not fill the urethra and there may be some dribbling of urine, which favors infection. In such a case the catheter remaining in the bladder may keep it empty by siphonage.

Contusion, with the formation of a large hematoma in the perineum, might simulate rupture, but the presence of a distended bladder demonstrates that the perineal tumor is not infiltrated urine. In such a case again, an attempt should be made to pass a catheter if the urine does not begin to flow after three or four hours. If successful, the size of catheter may be increased from day to day.

It must be borne in mind in making the first attempt that too persistent effort may result in rupture of the already contused urethra, or insure infection.

In case of failure, you may follow the recommendation of Lejars, and proceed to drain the bladder by suprapubic puncture and it may be, after a day or two when the swelling has subsided, a catheter can be passed and drainage secured in that manner as before, but hold yourself ready *to operate at the first sign of infiltration*.

This line of treatment can only be recommended to those who are sure they can distinguish between hematoma following contusion and infiltration following rupture. In case of doubt, always treat the case as one of rupture.

RUPTURE OF THE BULBOUS PORTION

Urethral hemorrhage, rapidly increasing perineal tumor obviously due to infiltrating urine, and retention of urine following injury point at once to some destruction of the urethral wall.

There is no use of wasting time attempting to pass a catheter; prepare at once for an external urethrotomy. Even if you succeed in passing a catheter, it will not prevent extravasation in the end, as Reginald Harrison and others have pointed out. Nor is there need to wait for additional symptoms. The indications for operation are unmistakable. Delay merely exposes the patient to all the risks of infection. The end in view is to furnish a free outlet for the urine and if possible to repair the ruptured canal.

Operation for External Urethrotomy.—Provide for the operation soft rubber catheters of various sizes; a grooved staff or steel sound; small, curved needles, silk No. 0, and three or four sizes of catgut.

General anesthesia is indispensable. Place the patient in the lithotomy position with the perineum exposed to a good light. The entire field must be disinfected with extreme care.

As soon as the patient is anesthetized, an effort may be made to pass a catheter, and, if successful, the operation will be greatly facilitated. Otherwise pass the guide as deeply as possible without using

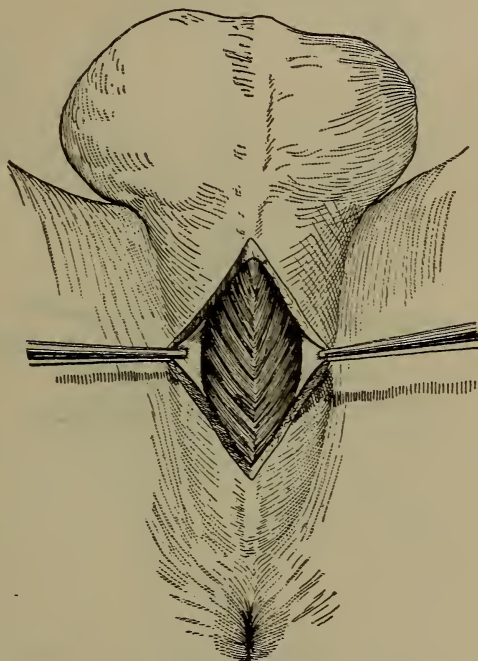


FIG. 523.—Incision exposing the bulb of the urethra. (Duval.)

force, and let it be held in position by an assistant who also supports the scrotum.

The *median incision* extends from the base of the scrotum to within an inch of the anus. Divide the skin and fascia, when you may reach an area filled with clots and lacerated tissues, the site of the bulb and its muscular coverings (Fig. 523). You may not be able to recognize the bulb if the destruction has been great, but after wiping out the clots and débris, a cavity is exposed (Fig. 524). Expose the point of the guide, and you have thus located the opening

into the distal half of the urethra. Determine the nature of the urethral tear, whether partial or complete. The subsequent procedure will depend largely upon the type of injury present.

(a) If you find rupture of the lower wall only, the remnant of the upper wall, a mere band perhaps, will be a great help in the next step, which is to locate the orifice of the urethra on the farther side of the tear. The search for this opening must be patient and minute. Let the point of a probe or grooved director follow the remnant of the

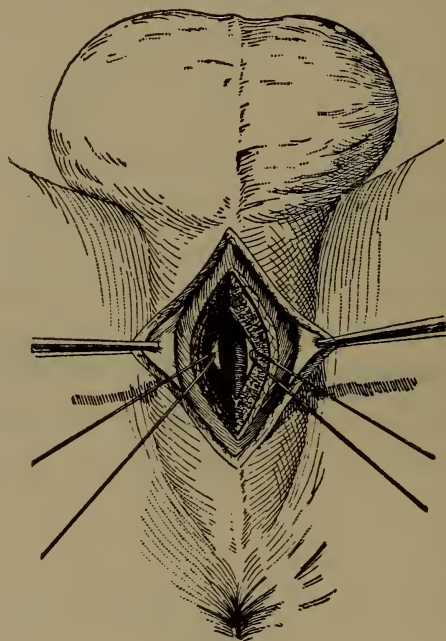


FIG. 524.—The muscular and erectile tissue of the bulb divided, exposing the urethra. (*Duval.*)

upper wall backward and it may haply engage in the orifice and pass on into the bladder; if it does not, every bit of the mangled tissue must be examined.

Another maneuver may be tried: if you have a soft-rubber catheter in the urethra, pull it down into the wound and endeavor to engage its point in the hidden orifice. Once the orifice is found and the catheter carried into the bladder, try to suture the urethral wound over the catheter. Place lateral sutures of fine silk or catgut, beginning at the upper wall and suturing toward the lower where the

separation is greatest. If possible, pass the suture through the outer coats only.

(b) If the rupture is complete and the two ends are widely separated, the difficulties are aggravated. There is no trace of the upper wall left to assist in the slightest degree in locating the orifice of the proximal segment of the urethra.

"With the point of the grooved director, every small orifice, every

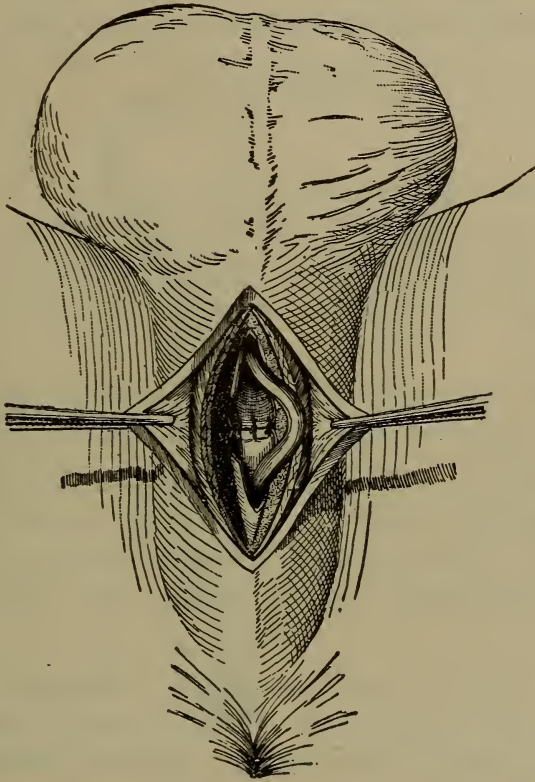


FIG. 525.—Soft catheter passed into the bladder after repair of the upper wall. (*Duval.*)

depression, every fringed tubercle must be examined in the hope that it represents the opening."

If you find something which looks like mucosa and the lumen of the canal, introduce the point of your catheter and if it is in the right track, it will glide into the bladder.

"A good light, patience, perseverance, and an accurate knowledge of the anatomical relations of the injured parts often lead to success in the most difficult cases." (*Senn's Practical Surgery.*)

Pressure on the bladder may sometimes help by forcing a drop or two of urine through and thus exposing the urethral opening. Sometimes bleeding from the ruptured artery of the bulb will serve as a guide to the hidden opening.

The incision may be extended backward with a view to exposing the canal, but this is often unsatisfactory and care must be taken not to wound the anal sphincter.

If, by any of these means, the orifice is finally located and the catheter passed into the bladder, it remains to adjust and suture the

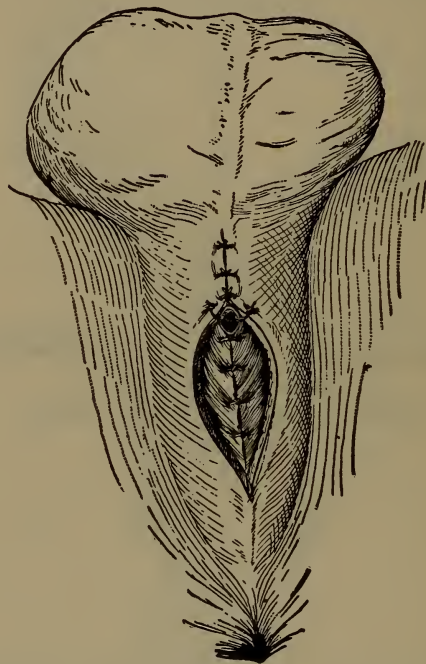


FIG. 526.—Repair of the muscular layers. (*Duval.*)

divided ends. The ideal way consists in making an end-to-end anastomosis, passing the sutures through the outer coats only. Occasionally you will be satisfied if, by passing sutures through all the coats, you can approximate, in some degree, the two ends, favoring by that much the ultimate restoration of the canal and minimizing the stricture formation (Fig. 525).

“In twenty-nine reported cases of rupture of the urethra treated by immediate suture, all are announced as successful. These results are astonishing and commend repetition.” (Bryant’s Operative Surgery.)

After suture of the urethral tear, the perineal wound may be shortened a little by one or two sutures, but ample space must be left for drainage. A wound unnecessarily large is much less dangerous than one too small (Fig. 526).

Pack the wound with iodoform gauze. The catheter should be left in the bladder for three to four days, when it is removed and a steel sound passed thereafter every two or three days until repair is complete.

(c) What are you to do in case patient search fails to locate the bladder end of the torn canal and you are unable, therefore, to pass the catheter into the bladder and to suture? Two procedures are recommended:

(1) Pack the wound with iodoform gauze and empty the bladder as necessary by suprapubic puncture. Perhaps at a later examination the opening may be found, or, as will nearly always happen, the bladder is sufficiently drained after a day or two, through the perineal wound.

(2) Do a suprapubic cystotomy and "retrograde catheterization." Where the general condition of the patient and other circumstances permit, this procedure is the better, since it assures drainage and facilitates primary repair by definitely locating the bladder end of the torn urethra in the perineal wound. It is necessarily a delicate operation and should not be undertaken by the wholly inexperienced.

To perform **suprapubic cystotomy and retrograde catheterization**, begin by carefully disinfecting the abdominal wall. Make an incision $2\frac{1}{2}$ inches long in the middle line, beginning at the pubes and cutting through the skin and subcutaneous tissues and the fascias. Retract the lips of the wound widely. You may not be able to distinguish the peritoneal covering of the bladder, for it may be above the upper level of the wound. In any event, it must be pushed up out of the way. Next locate the bladder, which is easily felt if it is distended; but if it is not, follow the posterior surface of the pubes.

Transfix the anterior wall by a suture on each side of the proposed line of incision, and lift the bladder upward to the abdominal wound and open it by a free incision. A small incision is a nuisance, while

a large incision renders the subsequent steps easier and is easily sutured at the end of the operation.

With the bladder opened, the next step is to pass the catheter. If possible locate the urethral orifice in the bladder and pass the catheter by sight, but you will usually have to depend upon touch for this procedure.

Introduce the left index and middle fingers into the bladder and touch the base. Now draw the fingers forward in the middle line and the neck of the bladder will be recognized by its relation to the prostate, and the urethral opening feels like a pimple on the base of the gland. The catheter is now slipped along the finger resting on the orifice. Once engaged, it is pushed on through the urethra until its point emerges in the perineal wound. Couple it onto the soft catheter in the anterior part of the urethra and retract it through the abdominal wound, and by this means the catheter in front is drawn into place and should be left in the bladder after the urethra and perineal wounds are sutured, as before described.

We must now provide for the drainage of the bladder through the suprapubic wound. Employ a medium-sized catheter and let it reach almost to the bottom of the bladder and anchor it in place with a safety-pin. Suture the bladder wound tightly about the tube. Repair the abdominal wall, leaving enough room for light gauze packing about the tube.

"Many elaborate methods of suprapubic drainage are described, but this tube connected to a long rubber tube by means of a glass coupler and terminating beneath the bed in a bottle filled one-quarter full of bichloride solution, will meet all the requirements of the case." (Taylor, G. U. and Venereal Disease.)

The tube may be replaced by a smaller one after two or three days. As soon as possible, the wound is allowed to fill up by granulation and the drain is entirely removed.

RUPTURE OF THE MEMBRANOUS URETHRA

This accident is rare except in connection with fractures of the pelvis. Under any circumstances, it is even more dangerous than rupture in front of the triangular ligament, for the extravasated

urine may easily spread up into the pelvic cavity and induce cellulitis and general infection. Examination per rectum will often reveal the edema, no signs of which appear in the perineum.

Nothing but free incision and drainage through the perineum is of any use.

Finally the *pendulous portion* of the urethra may be ruptured, sometimes in coitus, and the hemorrhage may be quite alarming to the patient; there may also be retention of urine. Usually catheterization will be sufficient.

CHAPTER XX

ACUTE RETENTION, CATHETERIZATION, SUPRAPUBIC PUNCTURE, CYSTOTOMY, URINARY INFILTRATION

Every acute retention of urine demands immediate relief. It must be relieved not only on account of pain and discomfort, but more especially to avoid damage to the bladder or urethra and the evil effects of sepsis. This rule applies equally to the cases due to temporary insufficiency of the bladder musculature and to those due to urethral obstructions.

Urethral obstruction may assume various forms. In general practice, it will usually originate in one of three ways: spasm of the urethra, enlargement of the prostate gland, or stricture. Very many more times than we suspect in those cases regarded as simple retention from spasm, the real and predisposing cause is organic. In every case before instituting measures for relief, it is wise to make minute inquiry into the patient's history with respect to this function. At least one should be suspicious of the presence of stricture and on his guard.

It is true that, in a particular case, certain circumstances tend to make one or the other of the causes of retention the more probable. Thus, if the patient is in a febrile attack or has suffered some slight trauma of the urethra or has undergone an operation on a region adjoining the urinary tract, one thinks of retention from urethral spasm. If the patient is known to have a sexual history, has been a votary at the shrine of Bacchus and Venus, the logical inference is organic stricture. If the afflicted one is elderly, one thinks of enlarged prostate, though mere age does not rule out other causes of obstruction. One may be past the hey-day of life and yet strictured, paying late the price of pleasures long since fled.

But after all, whether the predisposing cause is temporary or permanent, the actual exciting cause is usually *congestion*. This is a

practical point constantly to be borne in mind, for it is congestion which makes urethral instrumentation potent to produce trouble, and which makes strict asepsis an absolute necessity.

CATHETERIZATION

The first measure of relief to be tried in actual retention, if opium and a prolonged warm bath are not practical, is catheterization. To meet the possible indications every practitioner should be armed. A certain *equipment* is indispensable.

A cylindrical metal case capped at one end is most convenient in which to keep and carry these instruments. The most essential are



FIG. 527.—Conical.



FIG. 528.—Olivary.

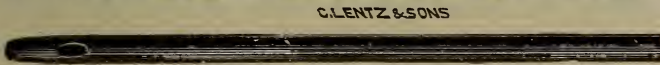


FIG. 529.—Cylindrical.
(Stewart.)

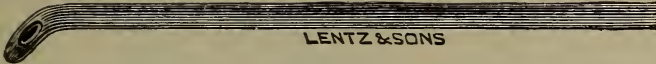

FIG. 530.—Elbowed flexible catheter.



FIG. 531.—Mercier double elbowed flexible catheter.

soft-rubber catheters of various sizes, flexible bougies with olivary and conical tips, gum catheters with single and double elbows or armed with stylets, filiform bougies (Figs. 527, 528, 529, 530, 531).

Sterilization of these instruments may be a problem, except as to the rubber catheters, which may without injury be disinfected by boiling. The other instruments are best sterilized by formaldehyde vapor and should be prepared before leaving the office and carried wrapped in sterile cloths.

Without the special sterilizer, one must boil these instruments, risking eventual injury. They may be fairly well cleaned by rubbing with an antiseptic ointment or by immersion in a 1-20 carbolic or

1-1000 bichloride solution. Previous to its introduction, anoint the catheter with sterile vaseline or similar lubricant.

Position of Patient.—The patient should lie upon a table high enough that the operator does not need to stoop. The pelvis should be elevated and the thighs flexed and abducted. Begin by thoroughly cleansing the field; cleanse the penis, the foreskin on both sides, the glans and the meatus, wiping each part with a separate compress. If possible, irrigate the urethra with boric acid or normal salt solution.

Whatever condition may be suspected in an unexplored urethra, make the first attempt at relief with a large catheter, seventeen or eighteen French, which, as is well known, excites less resistance than one of smaller size. Standing at the patient's left side, hold the penis between the finger and thumb of the left hand, elongating it, while managing the catheter with the right. Usually it is best to hold the instrument parallel with the groin as its beak enters the meatus, gradually bringing the handle to the middle line of the abdomen as the instrument penetrates. As the catheter progresses it may be helped along by giving it a slightly boring motion. Proceeding thus gently but steadily, always avoiding force, the bladder may be reached. If not, a smaller catheter is to be tried, and so on until one is found that will enter. If all these efforts fail and it becomes evident that a practically *impermeable stricture* is present, resort must be had to filiform bougies, which may be bent into various shapes, bayonet shape, or corkscrew form, and kept so by a thick collodion coating.

A filiform bougie is passed until it engages, and then various back and forth, side to side, movements are imparted with the hope of finding a passageway through the scar tissue. The point may engage in *lucunæ* or in false passages, and often it is useful to leave the bougie *in situ*. A half-dozen may be left in the urethra to occupy the false passages, until happily one finally passes into the urethral canal. Once a bougie is introduced into the bladder, it should be fastened and left until the second day, when often it may be replaced by a soft catheter or a larger bougie. In the meantime, the urine trickles past the stricture drop by drop, until, in a short time, the distention is relieved.

If the retention is known from the first to be due to stricture, the procedure may vary somewhat. Valentine and Townsend have defined the technic of emergency dilatation of urethral stricture in such a satisfactory manner (*American Journal of Surgery*, May, 1907) that it is transposed for present use practically in its entirety.

The hyperesthesia of the urethra, often so great an obstacle in

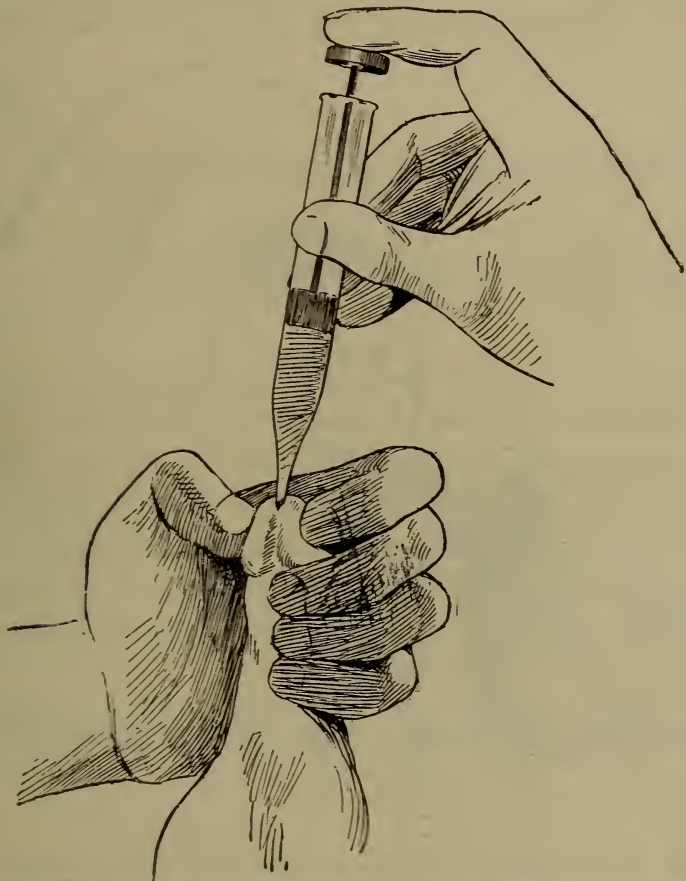


FIG. 532.—Lubricating the urethra. (*American Journal of Surgery*.)

catheterization, is greatly relieved by filling the urethra with a 33 per cent. solution of malaleuca sempervirens in sterile oil and holding it for three to five minutes. *Local or general anesthesia is undesirable.*

No lubricant is used for filiforms, but the urethra is to be filled with 10 per cent. suspension of iodoform in glycerin, injecting with a sterile glass syringe of 1-ounce capacity. The penis is held in the

left hand, the index finger and thumb pressing the meatus open. The tip of the syringe is inserted and the contents slowly injected until it can be felt that the urethra is full (Fig. 532). When the injection is complete the finger and thumb compress the meatus to prevent the escape of any of the fluid to make the fingers or penis slippery.

The filiform is to be inserted. A straight bougie, 5 French, is in-

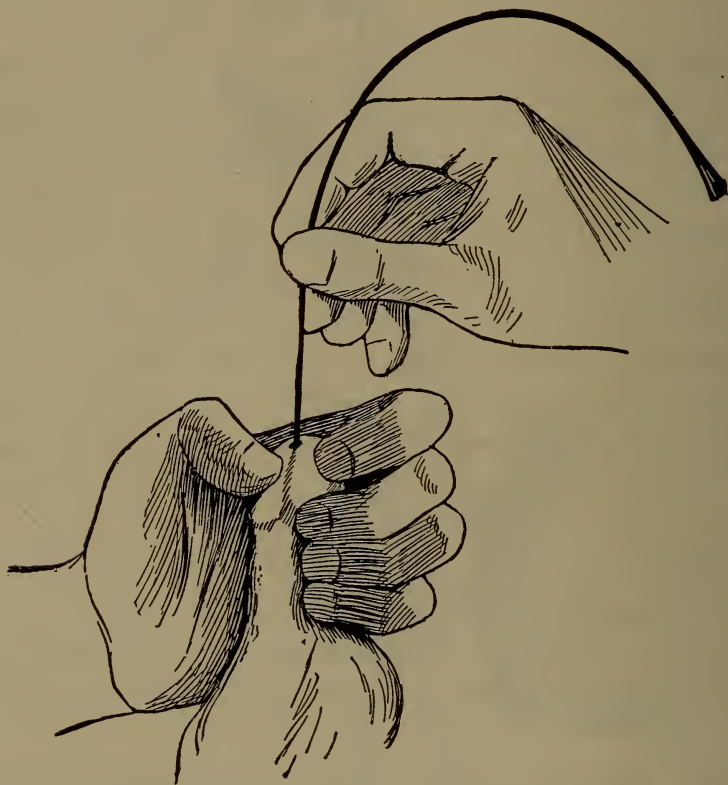

FIG. 533.—Inserting a filiform. (*American Journal of Surgery.*)

serted as far as it will go without force (Fig. 533). A smaller one is then passed alongside the first and the procedure continued with smaller straight bougies until a No. 1 has been inserted as far as possible. This is then left in place and from three to six more introduced, each one being left at the point of arrest.

When as many filiforms as will pass the meatus without stretching it are thus inserted, the one first introduced may be urged slightly forward. If its point is free but cannot progress, it may be withdrawn

and an angular filiform inserted in its place. It should be gently rotated to the right and left as obstruction is met with. If it makes no progress, it may be left in place and another of the straight filiforms withdrawn to be replaced by a bayonet filiform. The bayonet filiform is to be pressed forward and then withdrawn slightly and again advanced in a different direction, hoping to find the lumen. If this fails, the corkscrew filiform is to be tried, removing some of the straight filiforms if necessary to have more room.




FIG. 534.—Kollmann filiform guides. (*American Journal of Surgery.*)

When the corkscrew's tip reaches the face of the stricture, it is to be rotated, trying first the right spiral and then the left. If the second one fails, leave it in place and try each of the straight ones again, pushing it gently forward, and if it fails to enter, withdrawing it. After all the straight ones are tested and removed, try the corkscrew that remains in the urethra and then the one tried first.

If all these maneuvers have failed, an attempt may be made with




FIG. 535.—Valentine-Townsend filiform carrier. (*American Journal of Surgery.*)

the Kollmann guide (Fig. 534). A straight or curved guide is to be used, depending upon the location of the stricture. It is passed up to, and pressed firmly against the face of the stricture, while a straight filiform is introduced and lightly pushed up against the stricture, changing the position of the guide from time to time. If this attempt with the Kollmann guide fails, a metal sound as large as will pass to the stricture by its own weight is introduced and held against the

stricture for five minutes or more and quickly withdrawn and the urethra refilled with the iodoform-glycerin solution and all the maneuvers with the filiforms repeated, often with the result that the first inserted will traverse the stricture and enter the bladder smoothly.

The urethroscope is sometimes useful in locating the orifice, but even then the filiform may be difficult to enter, manifesting the "perversity of things inanimate;" although the shortest urethroscope

tube be used, the filiform will cling to its sides or will sway to and fro, touching every point of the exposed region except the orifice. Under the circumstances, the Valentine-Townsend filiform carrier (Fig. 535) is to be recommended and its use is thus described:

After the urethroscopic tube is inserted, the urethral mucosa dried, and the light in place, the carrier, armed with a filiform, is inserted. The lowermost ring containing the filiform's tip is pressed against the face of the stricture at the point where its lumen is visible. Once fixed by slight pressure, the filiform is very slowly projected into the exposed lumen. If it fails to traverse the stricture, an angular and then a corkscrew filiform are tried as before described.

Whenever a filiform reaches the bladder, the fact is announced by the ease with which the instrument can be moved to

and fro, and by the increased desire to urinate when the filiform touches the bladder walls. A few drops of urine trickle by the filiform.

The filiform must be fastened in place: No effort must be made at this time to pass a larger instrument. Valentine and Townsend recommend the following method of holding the filiform in place:

Two pieces of sterile cord 6 inches long are used, one tied about the bougie in front of the meatus so that the knot corresponds to the dorsum of the penis, and the other tied so that the knot corresponds

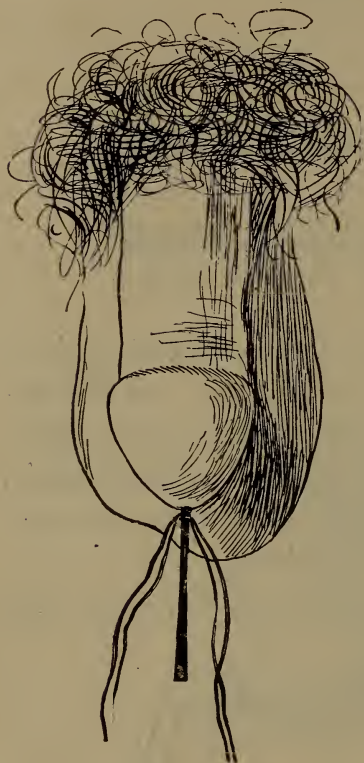

FIG. 536.—Cord attached to instrument in urethra. (*American Journal of Surgery.*)

to the insertion of the frenum (Fig. 536). "Take the cords projecting from one side of the glans and pass them through one of the four holes of a common pearl shirt button, draw the button upon the two joined cords until it rests exactly at the post. coronary sulcus. Tie a knot in each cord at that point to fasten the button in place" (Fig. 537). Proceed in the same manner on the opposite side.

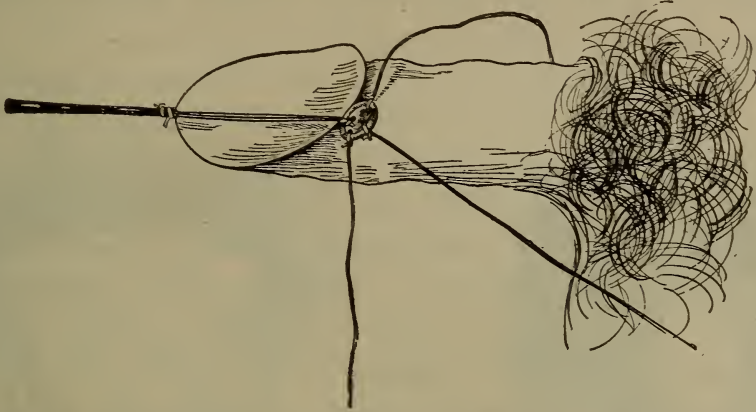


FIG. 537.—Attaching button to cord. (*American Journal of Surgery.*)

A cord passing over the penis connects the two buttons; another passing under the penis is threaded onto the two buttons and tied, care being taken not to disturb the position of the two buttons (Fig. 538). Finally a cord 12 inches long is fastened into the remaining hole of each button, and carried backward to be attached to the pubic hairs after Guyon's method (Fig. 539).

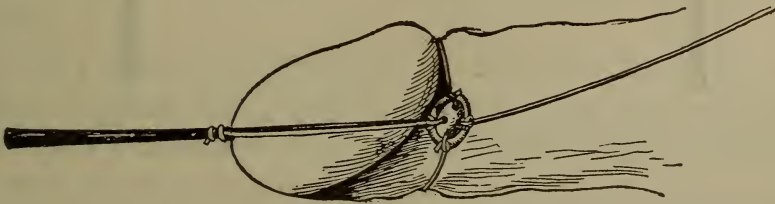


FIG. 538.—Uniting cords attached to button, lateral holes. (*American Journal of Surgery.*)

"The penis is then to be dressed, covering it with an aseptic garment.

"Three layers of sterile gauze 10 inches square are folded to form a triangle. This is passed under the penis with the base toward the scrotal angle. The apex is tied to the instrument at its projection

from the meatus. The two angles at the base are carried in front of the penis, one above the other, and their points are attached to the pubic hairs by the extremities of the cords left after tying in the instrument" (Fig. 540).

A pad of cotton should cover the genitals, and the whole be covered by a towel, to be changed as often as soiled.

"While it is better that the patient with a filiform fixed in his

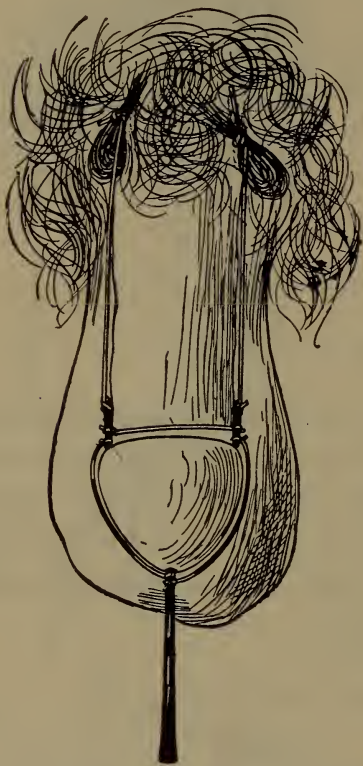

FIG. 539.—Cords attached to pubic hairs.
(*American Journal of Surgery.*)

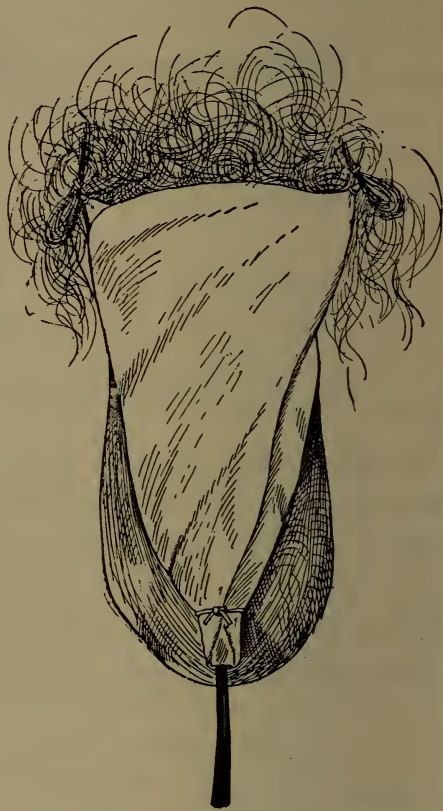

FIG. 540.—Penis dressed. (*American Journal of Surgery.*)

bladder remains in bed, there are circumstances in which it is imperative that he be allowed to go about and attend to his occupation. Protected against the dangers of retention as above, this is permissible unless he be engaged at hard labor."

In the case of retention due to enlarged prostate, the mode of procedure is quite different if the primary effort at passing a soft catheter fails.

The prostatic catheter with long curve may be tried, passing it as deeply as possible before depressing the handle between the thighs, pulling the penis upward, elongating it to facilitate the movement of the sound. Once the point is in the perineal region, the handle is to be depressed rapidly, at the same time pushing the sound on, hoping in this manner to carry it over the prostatic projection. No force must be employed. Often the Mercier elbowed or double-elbowed catheter will surmount the difficulty (see Figs. 453 and 454).

Sometimes a large gum elastic catheter armed with a stylet may be useful. The catheter is introduced to the obstruction, the stylet slightly withdrawn, which serves to tilt the end of the catheter and permits it to be pushed on into the bladder.

In these cases of chronic enlargement of the prostate, frequent catheterization may be required. As Stewart (Surgery, page 653) says, if it becomes difficult, if there is marked irritability of the bladder, if the residual urine steadily increases in quantity, or if there is stone or persistent cystitis, catheterization must be abandoned and operation advised.

PUNCTURE OF THE BLADDER

When catheterization has failed and relief is imperative, *suprapubic puncture* is the next resort. It is in nowise dangerous if aseptic, except possibly in those long strictured or long troubled with enlarged prostate, when the peritoneal covering of the bladder may approach the pubes.

Begin with a careful disinfection. Shave and scrub the abdomen and pubes. Select for puncture the point immediately above the pubes in the middle line exactly. The instrument, which may be an aspirator or simply a trocar, is to be entered at the point indicated, without fear of going too deep, and pushed backward and slightly downward until resistance ceases. Withdraw the stylet and the urine follows in a steady stream. A rubber tube may be attached to the trocar. The bladder should not be emptied rapidly, but slowly, interrupting the flow from time to time. When the bladder is emptied, the trocar is to be withdrawn with a rapid movement

and the opening covered with a sterile compress, or, if quite small, with collodion.

Aseptic puncture may be practised once or twice a day for a number of days without serious consequences, and at the end of this time the congestion of the urethra may be relieved and the urinary function restored. If, however, at this time the urethral obstruction cannot be overcome, then one must proceed to establish permanent drainage.

Permanent drainage is indicated from the first if distance precludes two or three daily visits, for there is no use to relieve the patient by puncture and then leave him to the danger and pain of a new retention, certain to occur.

Again, if the urethra has been lacerated by rough attempts at catheterization, and if to the symptoms of retention are added those of sepsis and the signs of beginning infiltration, it is imperative to establish permanent drainage of the bladder.

Under these circumstances the puncture may be performed with a large trocar, and after the bladder is emptied a catheter can be passed through the cannula into the bladder as far as possible and the cannula gently withdrawn.

The catheter must be fixed in position, and this can readily be done by threads attached to the skin with collodion. To the catheter a long rubber tube should be attached, ending below in a vessel containing an antiseptic solution. By this means a siphonage is established and the bladder kept constantly emptied and prevesical infiltration avoided.

CYSTOTOMY

Permanent drainage through the suprapubic puncture is often alone available, though by no means ideal. Whenever possible, the bladder is to be opened formally and the drainage established by that means, nor is the operation beyond the skill of the general practitioner.

No special equipment is necessary: scalpel, scissors, artery forceps, dissecting forceps, small curved needles. Local anesthesia may be employed in case of necessity, though, of course, general anesthesia is desirable. The region is to be carefully prepared.

Operation.—Begin with an *incision* 3 inches long commencing at the pubes and extending upward in the middle line (Fig. 541). Divide the skin and fat down to the aponeurosis. Divide the aponeurosis and expose the prevesical fat (Figs. 542–543). Draw this fatty tissue upward, and with it the vesical peritoneum, exposing the bladder. The bladder appears dark and globular, marked by large veins.

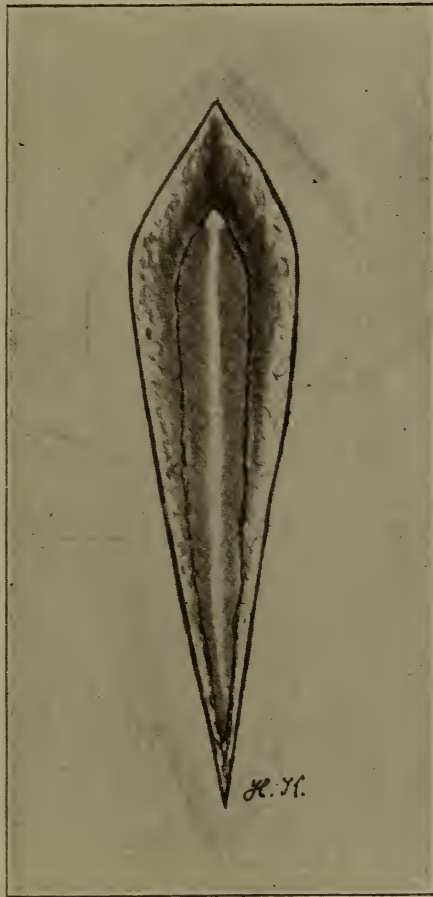


FIG. 541.—Cystotomy. Primary incision exposing linea alba.

In fat subjects it may seem deeply situated in spite of its distention, but one need not fear to get into something else.

It is helpful in controlling the bladder and, later on in suturing, next to pass a suture on either side of the proposed line of incision. The sutures should pass through only the superficial tissues and be parallel to the bladder incision. Next proceed to open the bladder

in the middle line, making the puncture at the level of the pubes with the cutting edge of the bistoury turned upward, prolonging the incision from a half-inch to an inch. If the sutures have not been passed, catch up the edges of the vesical wound with forceps while the urine flows out.



FIG. 542.—Partial incision of the deep layer of the sheath of the recti, exposing the prevesical fat.

The bleeding, often considerable at first, is not a matter for concern and ceases spontaneously as the emptied bladder contracts.

When the bladder is emptied, douche it thoroughly with warm sterile water and explore its cavity for possible calculi.

It remains to *suture* the edges of the bladder wound to those of the skin wound (Fig. 544). If the traction sutures mentioned were passed, they may now be used to draw the bladder up into close con-

tact with the abdominal wall, passing them through the entire thickness, and tying them on the outside.

The mucous membrane is now brought in contact with the skin and sutured with catgut (Fig. 545). If the condition of the vesical walls does not permit the careful coaptation described, then four or five sutures may be employed, passing through all the layers of the

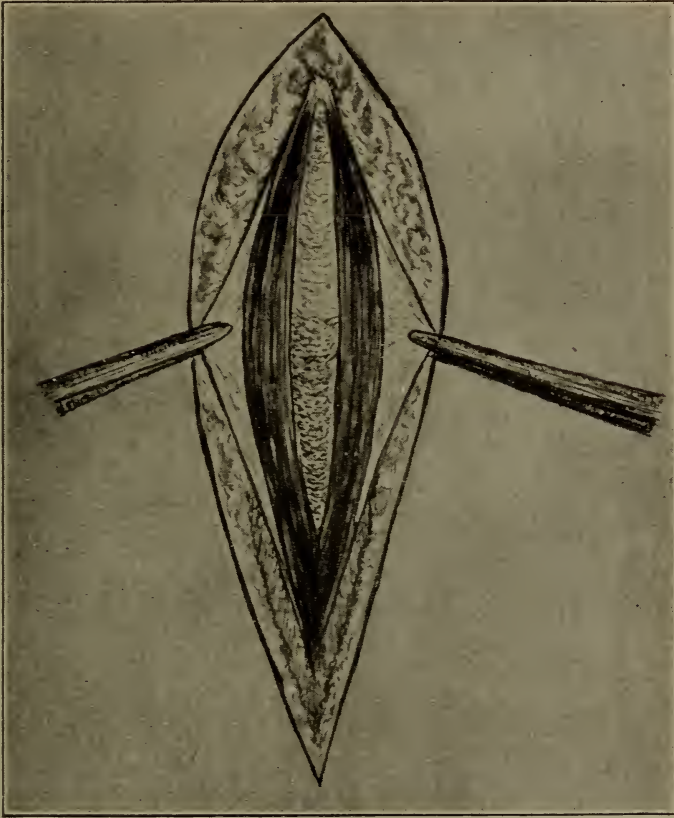


FIG. 543.—Cystotomy. Recti separated, prevesical fat exposed.

bladder and abdominal walls, bringing them into contact. In this case a catheter must be introduced and siphonage instituted. In the first case, where the skin and mucosa are exactly coapted, it is not necessary to leave a catheter in the bladder. The skin wound is, of course, sutured above and gauze should be packed around the catheter. The after-history will depend upon the condition present, but the ultimate aim will be to restore the urethral functions.

INFILTRATION OF URINE

Sometimes it happens that following a retention, partial or complete, the urethra gives way and the urine percolates through the adjoining tissues. Under these circumstances, the urine is nearly always septic, the patient debilitated, and the conditions are thus ripe for a rapid fatality.

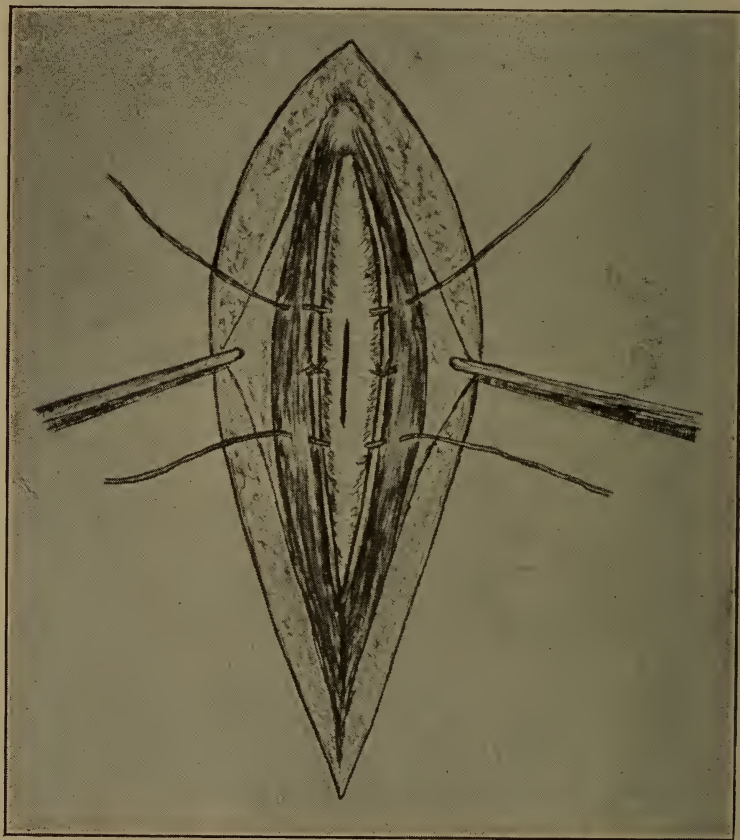


FIG. 544.—Cystotomy. Bladder fixed to the abdominal wall, sutures passing through the recti; bladder opened.

Shortly after the rupture of the urethral wall, the perineal tissues become edematous, and the scrotum and penis markedly swollen. The infiltration soon involves the pubic and hypogastric region.

The symptoms are those of sepsis: rigors, fever, pulse rapid and weak, tongue dry, anxious facies, profound depression generally, the symptoms depending in degree upon the duration of the accident,

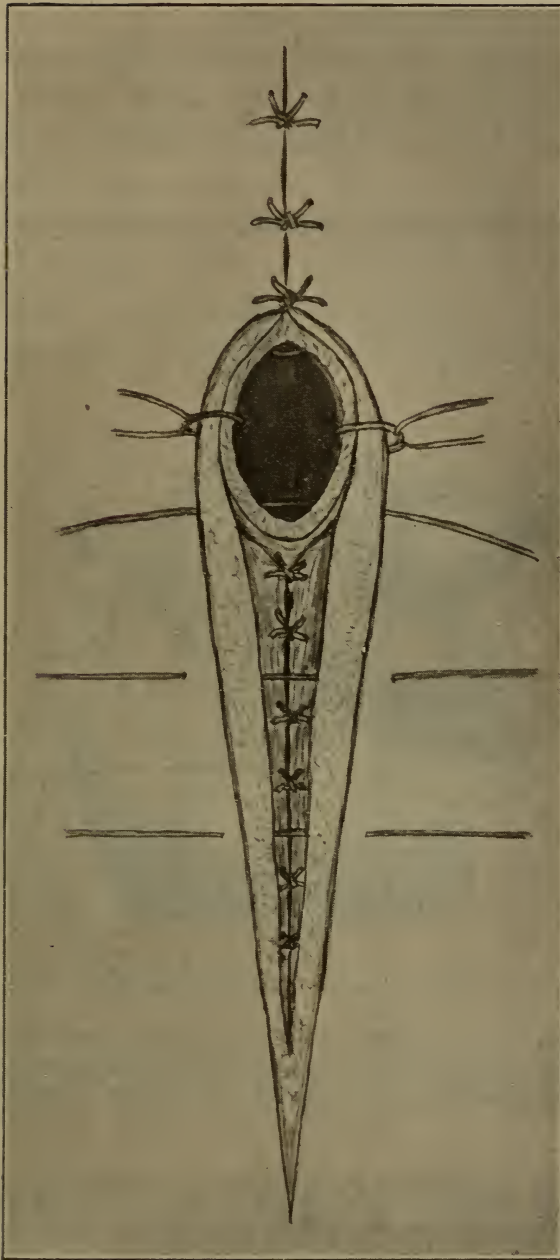


FIG. 545.—Cystotomy. Sutures connecting the edges of the bladder wound and the skin.
Repair of the abdominal wall.

the rapidity of the urine's spread and its septicity. Diffuse phlegmon and gangrene may rapidly ensue.

The rupture usually occurs in front of the triangular ligament—the deep perineal fascia—and so the urine moves forward toward the scrotum and pubes, which is the direction of least resistance (Fig. 546).

The treatment has two ends in view: to relieve the burdened tissues

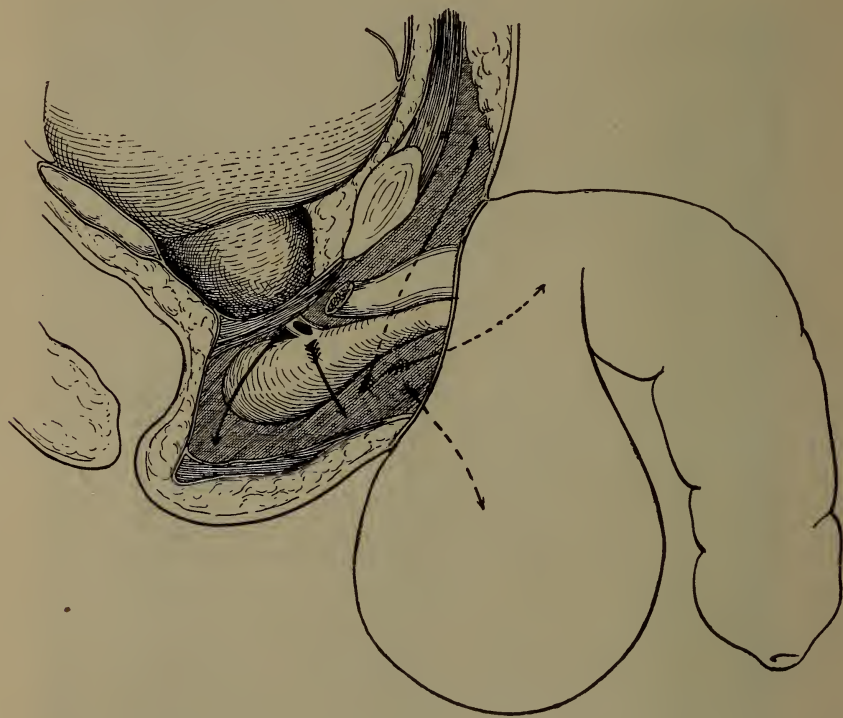


FIG. 546.—Rupture of the urethra in front of the deep perineal fascia and at point of entrance to the bulb; showing the direction which the infiltrating urine may take into penis and scrotum, perineum, and suprapubic region. (*Veau after Hartmann.*)

and to open up a passage to the point of rupture. To relieve the engorged tissues, a series of parallel incisions are to be made, extending beyond the limits of apparent infiltration, for the deeper tissues are always more widely involved than the superficial. The incisions should be deep enough to reach the deep fascia. The bleeding is not likely to be serious, but any bleeding points may be caught up, and if the oozing still persists, the incisions may be packed with iodoform gauze.

To expose the urethra, put the patient in the lithotomy position and make an incision in the middle line, beginning at the base of the scrotum and terminating in front of the rectum (Fig. 547). There is no guide but the middle line, for the tissues, thickened and infiltrated, are unrecognizable. There is nothing to do but continue to cut, keeping in the middle line, until rewarded by a spurt of urine.

All the incisions are to be thoroughly irrigated with hot normal salt solution, the tissues gently squeezed and the dead tissues removed. A compress saturated with peroxide is next applied, this covered with absorbent cotton, and the whole retained by a T-bandage.

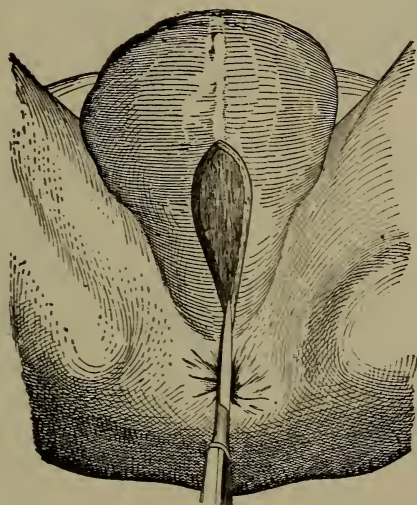


FIG. 547.—Infiltration of urine: Perineal incision. (Veau.)

Ordinarily drainage is unnecessary, for the open wounds give free escape to the fluids. Often one is surprised at the completeness of the repair.

At first the urine flows out through the breach in the perineum, but after a little while a catheter may be passed and fastened in the bladder and the perineal wound allowed to heal.

Lejars prefers the thermo-cautery to the bistoury, both because the hemorrhage is less and because it exercises a salutary action upon the tissues about to become gangrenous, but Veau believes the knife to be better, because it does not seal the mouths of interstitial drains.

If, in the course of intervention, an abscess cavity extending up

toward the pubes is found, a drainage-tube must be passed as high as possible and fastened in position (Fig. 548).

Sometimes it happens that the urethral rupture occurs behind the perineal fascia, and again taking the direction of least resistance, the urine may pass up along the side of the bladder to the deep layers of the abdominal wall; or it may pass downward and backward into the

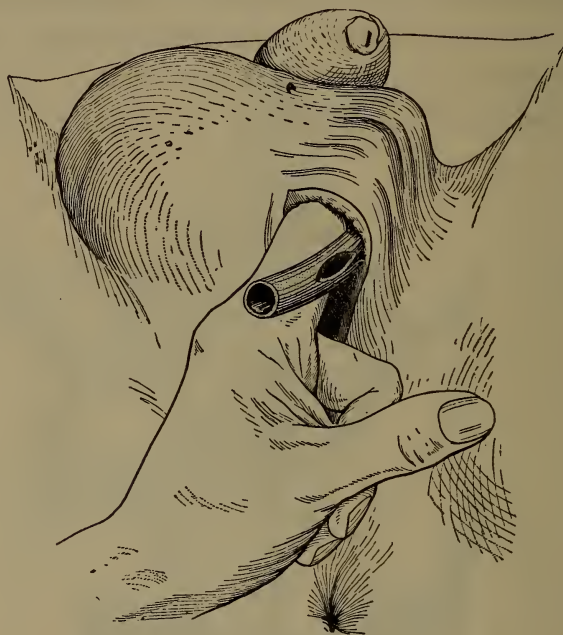

FIG. 548.—Infiltration of urine; placing drain. (Veau.)

ischio-rectal fossæ. This condition is all the more dangerous for the reason that the external manifestations are often delayed and in consequence the true condition is not suspected until too late.

But whenever a zone of infiltration is found, wherever it may be, incise it and reach the urethra if possible. In the intra-pelvic infiltrations it may be necessary to open and drain through the bladder.

CHAPTER XXI

SUTURE AND LIGATION OF ARTERIES

In emergency surgery the *suture* of a divided vessel is occasionally applicable, but the doctor will usually prefer ligation, which will nearly always suffice.

To *suture* a vessel, the blood current must be under temporary control by means of a clamp protected with rubber, that the tunica interna may not be injured.

The vessel wall is seized with a fine forceps. The silk sutures are placed one-sixteenth of an inch apart in a longitudinal wound, and only the outer coats are pierced.

If an end-to-end anastomosis is required, three sutures are recommended by Murphy and the proximal end is invaginated in the distal, the sutures being passed first through the proximal and finally through the distal end from within outward and tied.

The indications for arterial suture are as follows:

1. Where ligation might bring about serious nutritional change.
2. In all wounds of large vessels.
3. Operative wounds where a part of the vessel must be sacrificed.

LIGATION OF ARTERIES

It is a rule almost without exception that a divided artery must be exposed and both ends tied.

Occasionally, in the case of secondary hemorrhage, it will be impossible to secure the artery at the site of the hemorrhage and ligation at some point in the course of the artery above the lesion will then be imperative. So that though only rarely to be used in emergency surgery, yet the technic of special ligations should be kept in mind.

General rules for all ligations may be formulated:

1. Put the patient in some position best to expose the artery and its landmarks.

2. Outline the course of the vessel, using aniline if necessary.
3. Tie the vessel, but avoid tying near the origin of a large branch if possible.
4. Let the middle of the skin incision correspond to the point of ligation and let its length depend upon the depth of the vessel.
5. Let the first incision include the skin and superficial fascia; the incision in each succeeding layer should be the same length as the first.
6. Each structure must be identified as exposed.

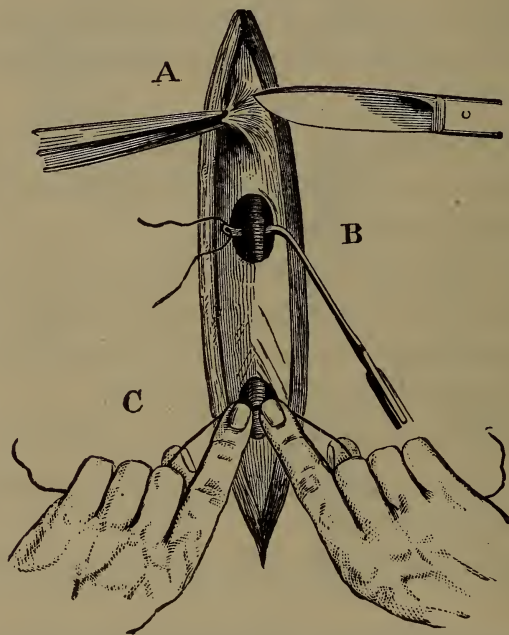


FIG. 549.—Ligation of an artery. A, opening the sheath; B, passing the ligature; C, tying the ligature. (*Moullin.*)

7. The sheath of the vessel is to be recognized by its position, pulsation, and feel to the examining finger.
8. The sheath is pinched up in the form of a cone, the base of which is incised with edge of the scalpel turned away from the vessel.
9. Through this small opening the vessel is gently detached and the aneurism needle passed, beginning usually on the side in relation with the vein and keeping it in close contact with the artery (Fig. 549).
10. After the needle is threaded and withdrawn, be assured that no other structures will be included in the ligature.

11. Draw the knot tightly enough to occlude the lumen of the vessel, but not tightly enough to crush the inner coat.
12. The subsequent treatment is that of an ordinary wound.

THE COMMON CAROTID (Fig. 550)

The *line of the artery* corresponds to the anterior border of the sterno-mastoid.

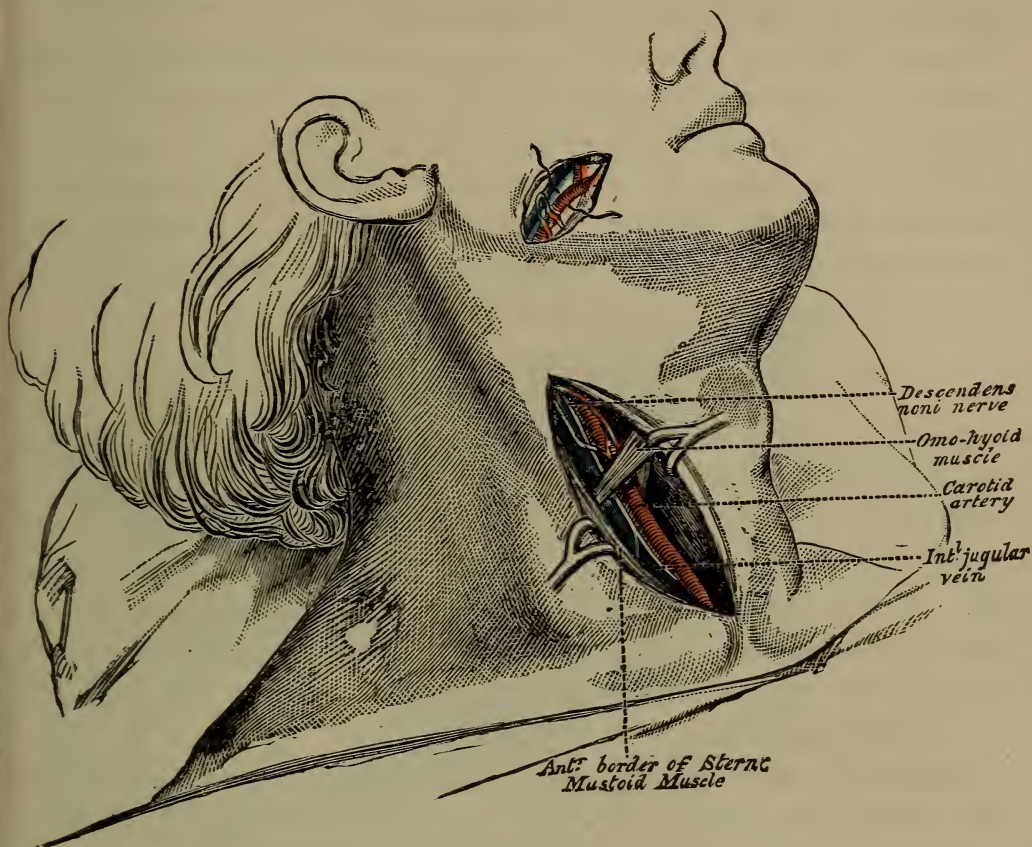


FIG. 550.—Ligation of the common carotid and facial arteries. (Moullin.)

The *incision* should be 3 inches long in this line, the middle of the incision corresponding to the cricoid cartilage. Divide the skin, fascia, platysma; catch the bleeding veins, and divide the deep fascia along the sterno-mastoid, exposing the sheath upon which lies the descendens hypoglossi and the omo-hyoid. Just above the omo-hyoid, open the sheath from the inner side so as to avoid the internal jugular. Pass the needle from outside, also to avoid the internal jugular.

EXTERNAL CAROTID

Line.—Continuation of the common carotid.

Incision.—From the angle of the jaw to the thyroid cartilage, dividing the skin, fascia, and platysma. Ligate divided veins.

Divide the deep fascia, exposing the sterno-mastoid, which is to be retracted. Locate the posterior belly of the digastric, the hypoglossal nerve, and the tip of the cornu of the hyoid.

Expose the artery opposite the cornu; pass the ligature between the superior thyroid and the lingual arteries, avoiding the decedens hypoglossi and the superior laryngeal nerve behind. The operation presupposes patience and a thorough knowledge of the anatomy. Through this same incision the *superior thyroid*, the *lingual*, the *facial*, the *occipital*, and the *ascending pharyngeal* arteries may be tied at their origin.

LINGUAL (Beneath the Hyoglossus)

Position.—Place the patient on his back, turn the head to the opposite side and raise the chin (Fig. 551).

Incision.—Curved, its center just over the greater cornu of the hyoid, extending from the symphysis of the chin to the angle of the jaw. Divide the skin, superficial fascia, platysma and deep fascia. Ligate the numerous veins which may be divided. Locate the lower border of the submaxillary gland and divide its fascia, thus exposing it, and lift it upward out of the way.

Develop the mylo-hyoid; also the two bellies of the digastric and draw them down firmly. In the bottom of the wound is the hyoglossus muscle. Identify the hypoglossal nerve with the lingual vein, which cross the hyoglossus. Incise the hyoglossus below, and parallel with, the hypoglossal nerve. Incising carefully, the artery bulges into the wound. Ligate the artery on the proximal side of the *dorsalis linguæ*.

SUBCLAVIAN (Third Portion)

Position.—Place the patient on his back with shoulders raised, head turned to opposite side, and angle of shoulder depressed (Fig. 551).

Incision.—From the posterior border of the sterno-mastoid, over the clavicle, to the anterior border of the trapezius, drawing the skin down first to prevent wounding the external jugular. Relax the skin. The incision now lies $\frac{1}{2}$ inch above the clavicle. If more room is needed, partially divide the trapezius and sterno-mastoid. Divide the deep fascia and ligate veins.

If the transversalis colli or the suprascapular arteries present, draw them to one side.

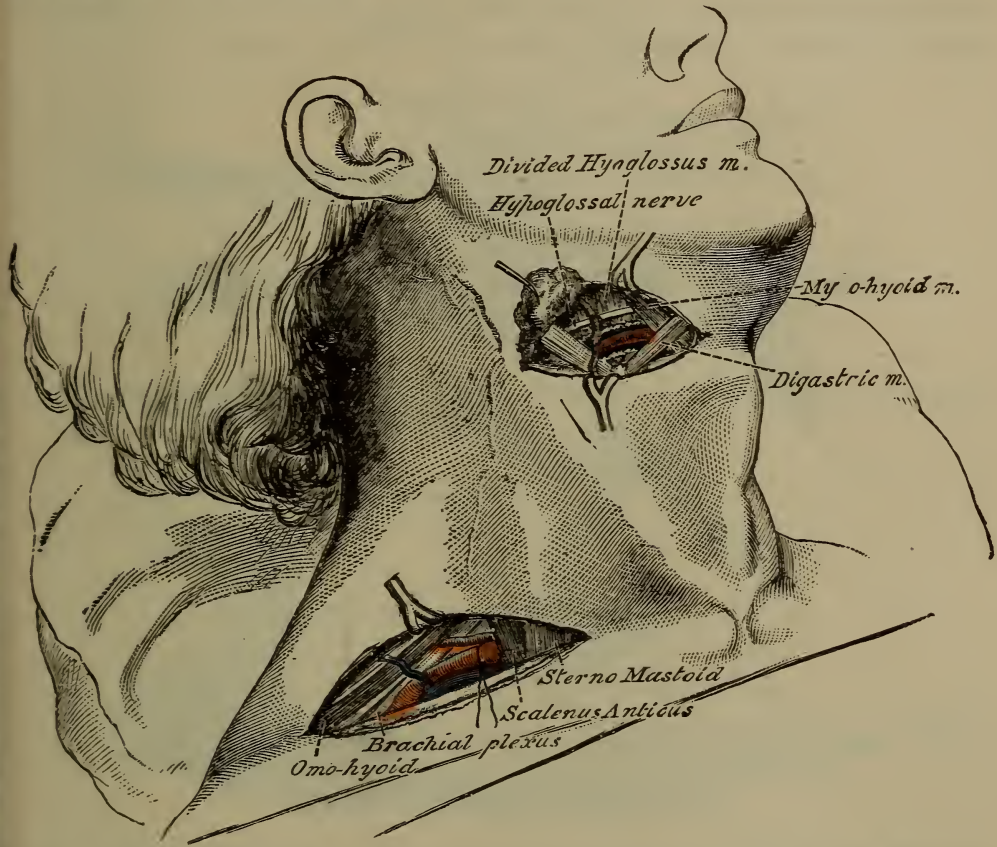


FIG. 551.—Ligation of the subclavian and lingual arteries. (Moullin.)

Now identify the scalenus anticus muscle—a very important step, as it is the guide to the artery. Follow the external border of the muscle down to the first rib and there the pulsations of the artery will be felt.

Identify the lowest cord of the brachial plexus, which, as well as the pleura and the subclavian vein, must be avoided in passing the ligature.

THE AXILLARY (Third Portion)

Position.—Patient supine, shoulders raised, arm at a right angle; operator between arm and body (Fig. 552).

Incision.—Along the line of junction of the middle and anterior third of the floor of the space.

Divide the skin and fascia and expose the inner border of the coraco-brachialis. Draw the coraco-brachialis, the median and musculocutaneous nerves outward, the ulnar and internal cutaneous nerves inward. Avoid the basilic and axillary veins.

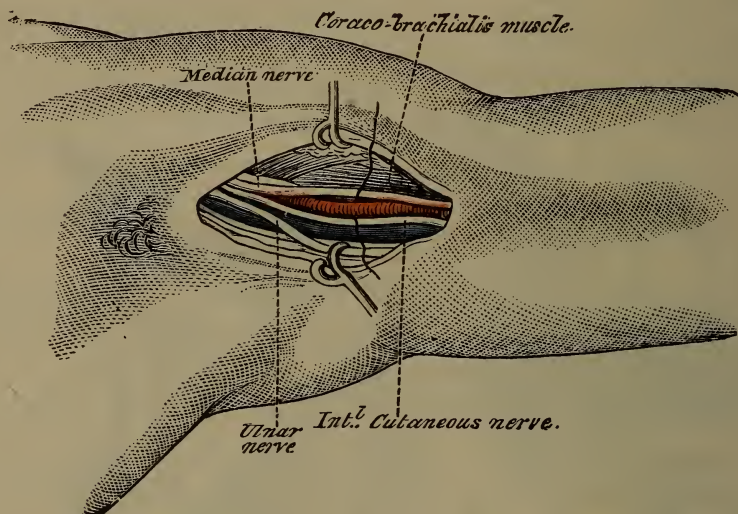


FIG. 552.—Ligation of the axillary artery. (Moullin.)

BRACHIAL (In the Middle of Arm)

(See Operation for Exposure of Median Nerve.)

BRACHIAL (Bend of Elbow)

Position.—Limb extended and abducted, operator outside of arm (Fig. 553).

Incision.—Follow the internal border of the bicipital tendon, the center of the incision corresponding to the bend of the elbow. Divide the skin and superficial fascia. Isolate the median basilic vein and the internal cutaneous nerve, retracting them inward. Next divide the deep and the bicipital fascia and beneath this latter lies the artery with its venæ comites, the median nerve to the inner side.

Do not neglect to repair the bicipital fascia.

RADIAL (In the Upper Third of Forearm)

Position.—Hand supine, surgeon to outside cutting downward (on the right) (Fig. 554).

Incision.—Along the inner border of the supinator longus for 3 inches, dividing the skin and superficial fascia. Divide the deep fascia and separate the supinator longus and pronator radii teres. The

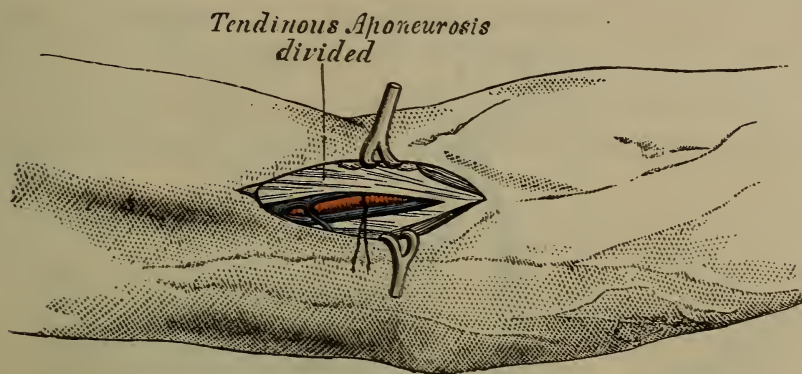


FIG. 553.—Ligation of the brachial at head of the elbow; the median basilic vein and internal cutaneous nerve drawn inward. (Moullin.)

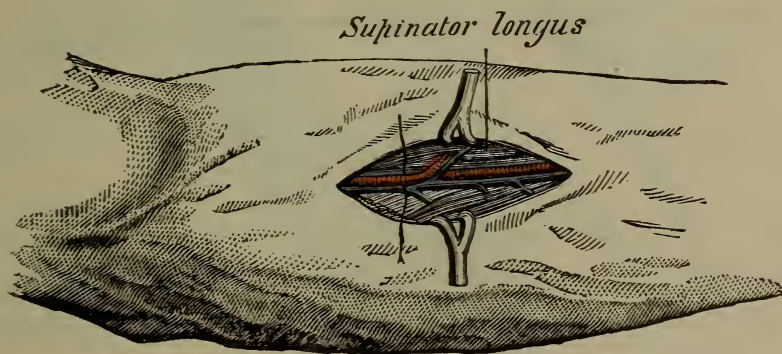


FIG. 554.—Ligation of the radial artery. In the floor of the wound is the pronator radii teres. The nerve lies some distance to the radial side. (Moullin.)

artery lies under the border of the supinator longus with the nerve to the outer side.

RADIAL (At Wrist)

Position.—The position is the same as before.

Incision.—The incision is along the supinator tendon. Avoid the radial vein and the superficialis volæ artery. Divide the deep fascia

and separate the tendons of the supinator longus and flexor carpi radialis and between them lies the artery and its venæ comites.

ULNAR (At Wrist)

(See Exposure of Ulnar Nerve, page 362.)

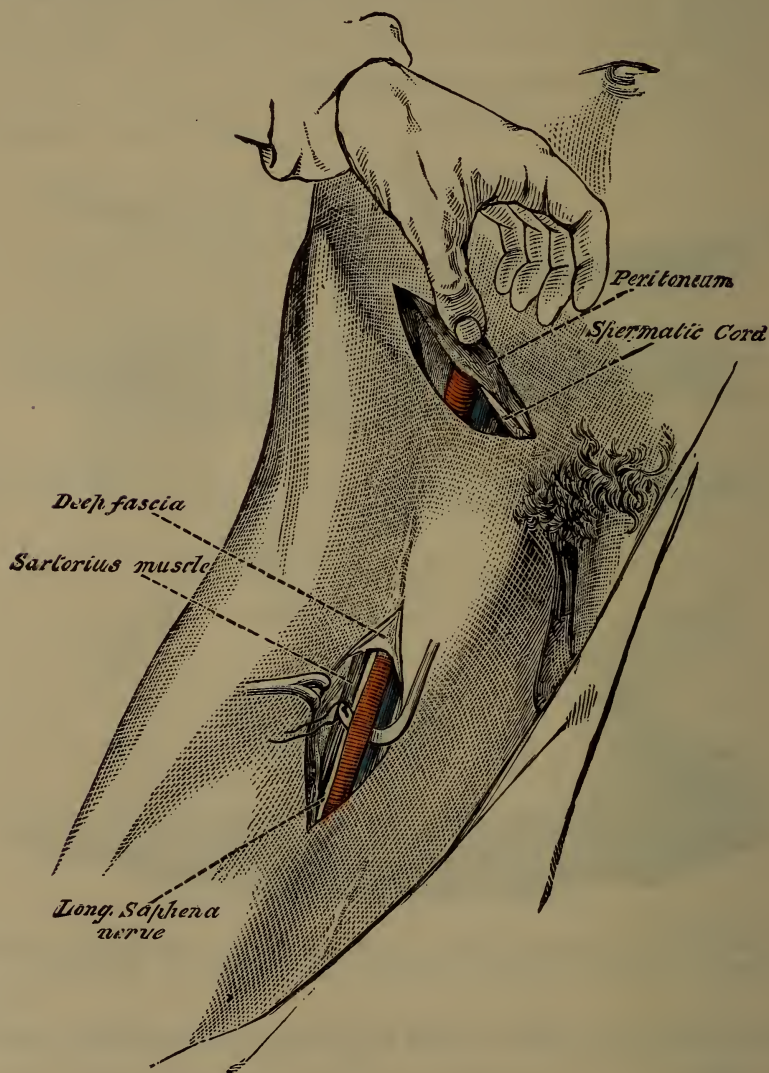


FIG. 555.—Ligation of external iliac and femoral arteries. (Moullin.)

SUPERFICIAL FEMORAL (At Apex of Scarpa's Triangle)

Position.—Thigh slightly flexed, rotated externally, abducted surgeon to outer side (Fig. 555).

Incision.—Three inches long, with center over apex of triangle. Divide the skin and superficial fascia. Avoid the long saphenous vein. Divide the deep fascia and draw the sartorius outward; the adductor longus, inward. Avoid the internal cutaneous and the long saphenous nerves. The vein lies to the inner side and a little behind the artery.

FEMORAL (In Hunter's Canal)

Position.—The position is the same as before.

Incision.—Three inches in the line of the artery in the middle third of the thigh. Divide the skin and superficial fascia. Avoid the internal cutaneous nerve and the long saphenous vein. Divide

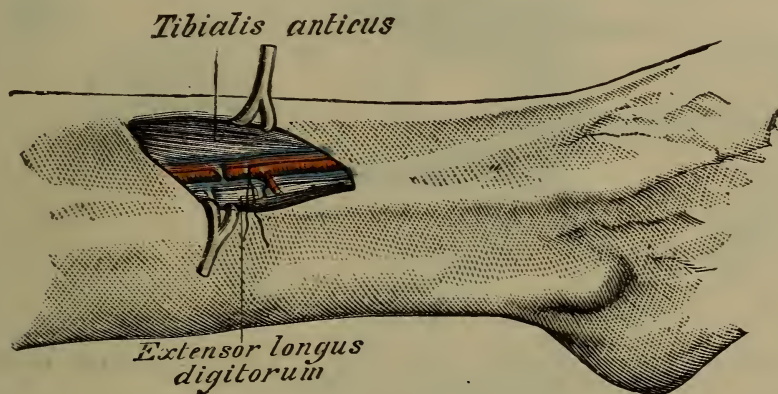


FIG. 556.—Ligation of the anterior tibial artery. The nerve lies to the fibular side. (Moullin.)

the deep fascia, expose the sartorius and draw it inward. Incise the roof of the canal, but do not wound the long saphenous nerve which is just beneath. Draw it inward and expose the sheath of the vessels.

ANTERIOR TIBIAL (Middle Third)

Position.—Thighs extended, leg turned inward and the foot extended to indicate the position of the tibialis anticus muscle.

Incision.—Four or five inches long in the line drawn from the head of the fibula to the middle of the front of the ankle-joint (Fig. 556). Expose the fascia. Divide it in the same line. By the sense of touch locate the septum between the tibialis anticus and extensor longus digitorum. Flex the foot to permit the separation of these muscles,

and follow the septum down to the artery. The nerve is to the front and outer side. Pass the ligature from without inward.

ANTERIOR TIBIAL (Lower Third)

Position.—Same as above.

Incision.—Locate the tendon of the tibialis anticus; along its external border divide the skin for 3 inches. Find the septum between the tibialis and the extensor proprius hallucis. In this

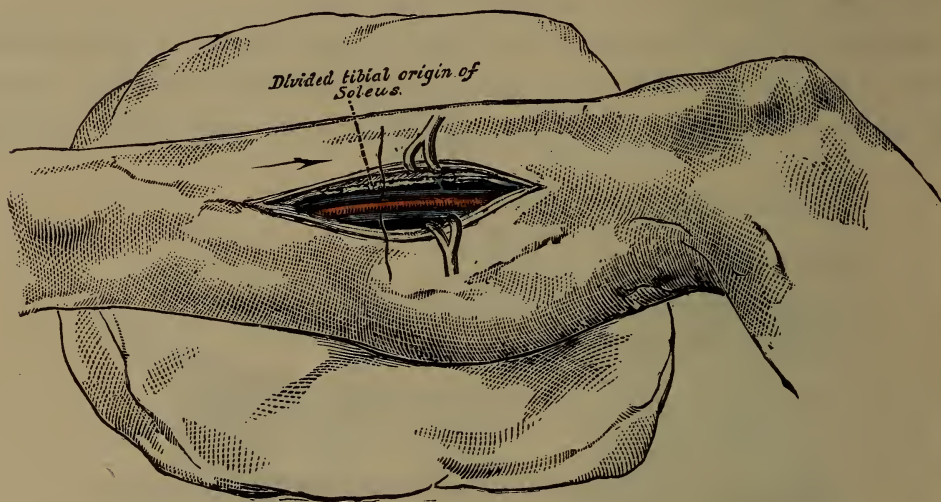


FIG. 557.—Ligation of the posterior tibial artery. The gastrocnemius retracted; the soleus divided. (Moullin.)

space lies the artery with the nerve to the front and outer side. Pass the ligature from without inward.

DORSALIS PEDIS

Position.—Patient on back with foot extended and resting on heel.

Incision.—Two inches long beginning at the middle of the lower border of the annular ligament. Expose and separate the tendons of the extensor proprius hallucis and extensor longus digitorum; the artery is seen lying upon the tarsal ligaments. The nerve lies to the fibular side. Pass the ligature from without inward.

POSTERIOR TIBIAL (Middle Third)

Position.—Patient on back; leg and thigh flexed; thigh rotated outward so that leg lies on its outer side (Fig. 557).

Incision.—Four inches long, along the line $\frac{3}{4}$ inch behind the internal border of the tibia. Expose and divide the deep fascia. Expose and develop the inner border of the gastrocnemius; retract and thus expose the soleus attached to the inner border of the tibia. Divide the soleus vertically, and at the bottom of the wound is seen the yellow fibrous aponeurosis which covers the vessel and deeper layer of muscles. Divide the aponeurosis about $1\frac{1}{2}$ inches from the internal border of the tibia and expose the artery. Draw the nerve to the outer side and pass the ligature from without inward.

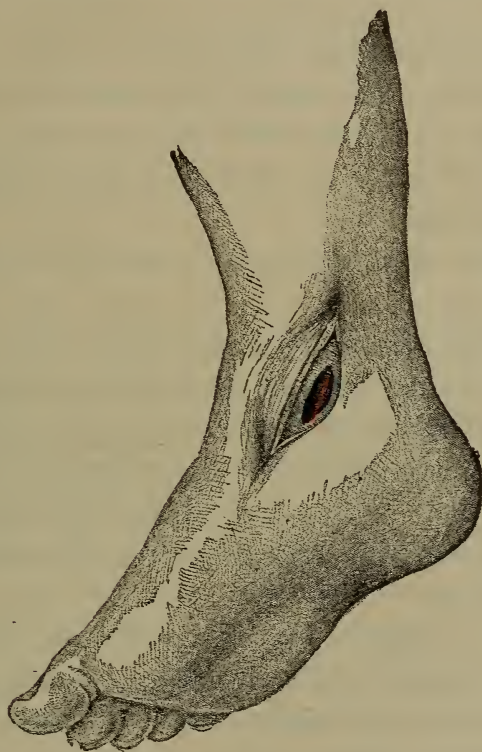

FIG. 558.—Ligation of the posterior tibial behind the ankle. (Moullin.)

POSTERIOR TIBIAL (At the Ankle)

Position.—Turn the foot on its outer surface (Fig. 558).

Incision.—Curved, 3 inches long, with center midway between malleolus and the inner tuberosity of the os calcis. Divide the fascia and the internal annular ligament cautiously. The artery is just beneath the ligament. Separate the veins and pass the ligature from without inward.

CHAPTER XXII

SOME PRACTICAL AMPUTATIONS

The primary aim of an amputation is to conserve the life or health of the patient; the secondary aim is to conserve, as much as possible, the function of the member. The first requires that as much as necessary be removed; the second, that no more than necessary be removed. The good surgeon will always adjust and harmonize these two principles and they will determine the time and technic of the particular operation.

The time element is of especial concern in traumatism and gangrene, for if the operation is done too early, too much may be removed in one case and too little in the other. In traumatism, tissue that at first sight seemed beyond remedy may survive; in gangrene, tissue that seemed viable may be left, only to necessitate another dangerous operation; so that following traumatism it is better not to operate until the limit of the devitalized tissue has been definitely determined; and in the case of gangrene, until the line of demarcation has definitely formed.

The *technic* is principally concerned with conservation of function, and looks to the formation of a good stump. "A stump to be serviceable, should be sound, unirritable, with good circulation and abundant leverage" (Bryant, Operative Surgery). To produce a stump with these qualities requires prevision of the flaps, particularly their shape, length, and vascularity. Upon their shape will depend the position which the cicatrix will take; upon their length, the comfortable adjustment of skin and bone; upon their vascularity, the prompt repair, proper nutrition, and subsequent freedom from disease.

The cicatrix should fall where it will be least subject to pressure and friction wherever that may be done without the sacrifice of useful tissues. In determining the position of the cicatrix, one must then

consider the occupation of the patient and the possibility of an artificial limb being worn.

In the case of the leg, for example, the greatest tension might fall on the end of the stump, and a scar there be some source of annoyance; in the case of an arm, more pressure might fall on the side, from artificial appliances, and an end scar would therefore be more satisfactory. Nerves likely to be pinched up in the cicatrix should always be resected. The ends of severed tendons should likewise be resected, but not so high that their empty sheaths may be left to favor the lodgment of infection.

That the stump may be sound and uniform in its outline, it is necessary that the different degrees of contractility of the various groups of divided muscles be known and their division accomplished accordingly so that finally their ends may occupy the same level. The bones must also be sawed squarely and care taken that the division is not completed by fracture. The periosteum must not be roughly handled.

The technic is concerned also with the prevention of hemorrhage. This is best secured by first elevating the limb for several minutes and then applying an Esmarch tube above the site of the operation.

After the section of the limb is completed and the large vessels secured and ligated, the tube must be removed and each bleeding point ligated separately. The tube has the disadvantage that there is nearly always a temporary vaso-motor paralysis due to the pressure, and on that account the oozing is considerable.

The occasional surgeon will be called upon to do amputations under two entirely different circumstances, and his mode of procedure will be quite different in the two cases. In one case, he will attempt the *typical* amputation of the text-book; in the other, his sole guide will be the preservation of tissue: he will do an *atypical* amputation.

(A) **The soft parts are more extensively destroyed than the bone.** This is nearly always the case in traumatism and always the case in gangrene. The site of amputation will depend upon the limit of the sound skin; the rule is to remove none of the healthy soft parts; the line of incision should follow the line of demarcation, and having fashioned the flap following this indication, divide the bone high

enough to accommodate the flaps, and no higher. (See also Injuries to the Extremities.)

(B) In case the **bone is more extensively destroyed than the soft parts**, as in tuberculosis, sarcoma, etc., one has more option; he can fashion the flaps in any manner desired, for usually much that is healthy will have to be removed. The position of the cicatrix can be determined and such is the *typical amputation*.

FINGER AMPUTATIONS

Practical anatomical points (Jacobson, Operative Surgery):

"The three creases in front almost correspond to the joints. The lower crease is just above the joint; the middle is opposite the joint; the highest, nearly $\frac{3}{4}$ of an inch distal to the metacarpo-phalangeal joint.

"The prominence of the knuckles is formed by the higher of the two bones; by the head of the metacarpal bone, the head of the first phalanx, the head of the second phalanx for the three joints respectively.



FIG. 559.—Typical amputation of finger; palmar flap, dorsal scar. (Farabeuf.)

"The joint in each case is below, or distal to, the prominence; the metacarpo-phalangeal joint is about $\frac{1}{3}$ inch below the knuckle; the second joint, $\frac{1}{6}$ inch below the knuckle; the terminal joint $\frac{1}{12}$ inch beyond the knuckle.

"In the distal and interphalangeal, the joint is concave from side to side and presents a concavity toward the finger tips. In the metacarpo-phalangeal joint, the convexity is toward the finger tip.

"From the readiness with which the tendons conduct infection, care should be taken to keep even so small an amputation as that of a finger strictly sterile, and in amputating through damaged parts the flaps should not be too closely united with sutures."

It is a rule with but few exceptions to save as much of the finger as possible, and it will almost always happen in removing part of a finger

that an atypical amputation will be indicated. Let the scar fall where it will, making a dorsal or a lateral flap if necessary. - The palmar flap and dorsal scar is ideal, but rarely attainable (Fig. 562). There are, however, surgeons of large experience who insist that a palmar flap be secured even at the cost of more finger, and that less than half a phalanx should not be saved, but cut back to the joint to avoid flexure. (See Injuries to the Hand.)

If a *distal phalanx* is to be removed, begin by pronating the hand, forcibly flex the phalanx and divide the skin $\frac{1}{2}$ inch distal to

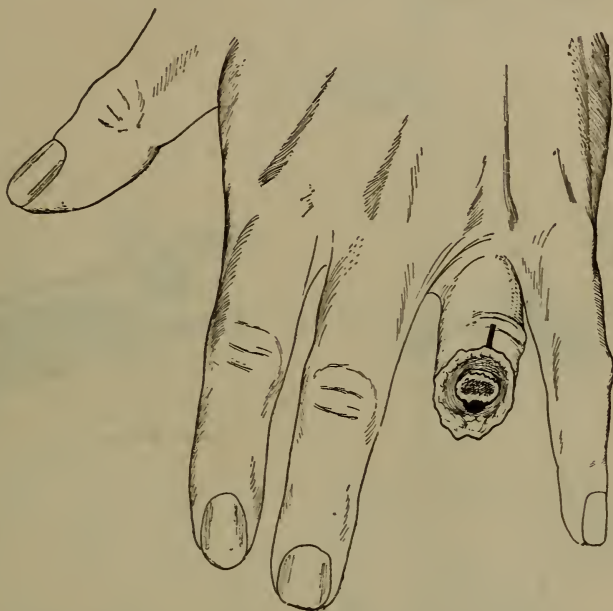

FIG. 560.—Atypical amputation of a finger, the bone projecting beyond the skin. Dorsal incision. (Veau.)

the knuckle; this incision deepened will open the joint. Divide the lateral ligaments. The edge of the knife is carried under the phalanx and swept downward, grazing the bone and cutting with a steady sawing movement. The result is indicated in Fig. 559. Do not cut the flap too short, a common mistake with the inexperienced.

AN ATYPICAL AMPUTATION

Suppose a finger to have been sawed off. The bone projects beyond the retracted skin. It is not possible to fashion a flap without removing some bone.

Local anesthesia (Figs. 10 and 11). Circular constriction at the base will control bleeding and prevent rapid absorption of the solution. Begin by making a dorsal linear incision an inch long down to the bone (Fig. 560).

Liberate the whole circumference of the bone $\frac{1}{3}$ inch up, either with a rugine or a bistoury (Fig. 561), and at that level divide the bone with bone forceps (Fig. 562). Employ two or three sutures with drainage if there is much chance of infection (Fig. 563).

If the dorsal linear incision opens into a joint, the section may be made there—disarticulate.

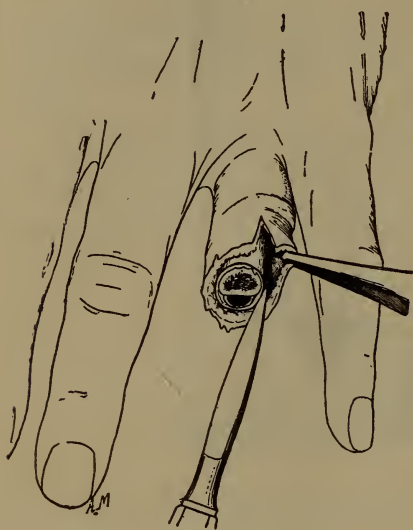

FIG. 561.—Liberating the bone. (Veau.)

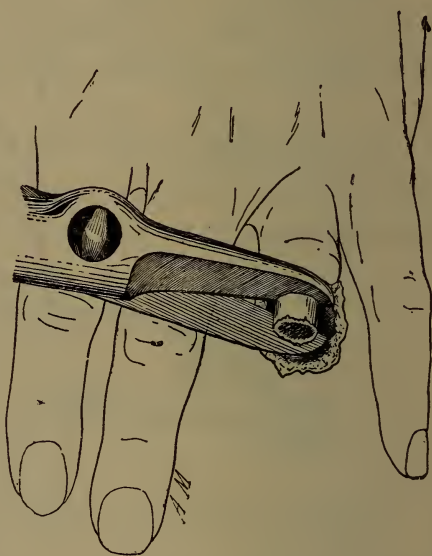


FIG. 562.—Section of the bone. (Veau.)

Divide first the dorsal ligament, then the lateral ligament to the left, and as the phalanx is twisted toward the left, divide the lateral ligament to the right. Suture as before. It may be necessary to slice off the head of the remaining portion of the digit if it is too prominent.

TYPICAL AMPUTATION OF THE WHOLE FINGER

General anesthesia is usually necessary. The method of procedure is different for the middle and ring fingers, the index and little fingers, and the thumb.

(I) **The Middle and Ring Fingers.**—Locate the articular line by making traction on the finger with one hand and palpating each side of the joint with the index finger and thumb of the other hand.

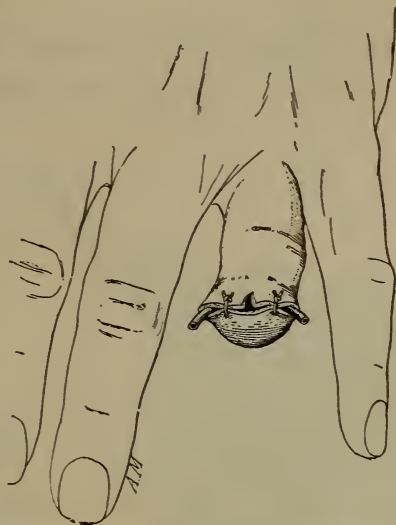

FIG. 563.—Atypical amputation: Suture and drainage. (*Veau.*)

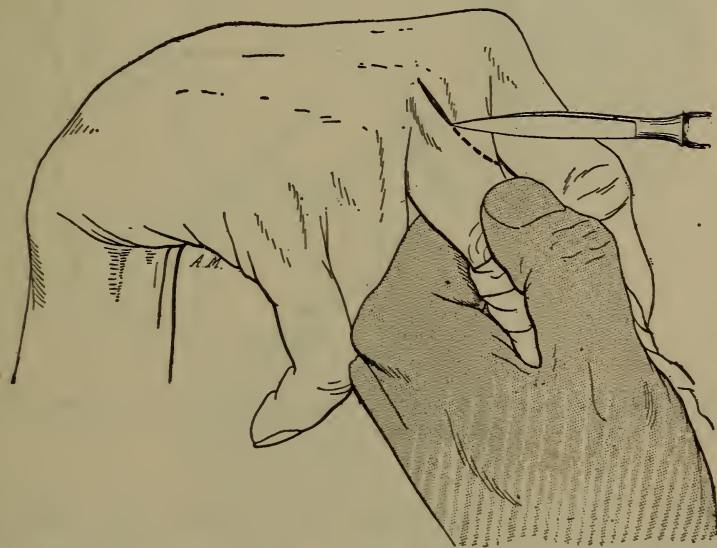


FIG. 564.—Typical amputation of middle finger: Primary incision directed to the right. (*Veau.*)

Begin the incision at the upper level of the joint; carry it obliquely downward and forward between the fingers so that it reaches the palmar surface at the right, a little below the crease (Fig. 564).

Lift up the hand so that you face the palm and cut transversely to the left (Fig. 565). Now lower the hand and complete the incision, bringing it obliquely upward and backward to the knuckle, the starting-point (Fig. 566).

Having outlined the incision in this manner, repeat the movement, cutting to the bone. Retract the flap, exposing the articulation.

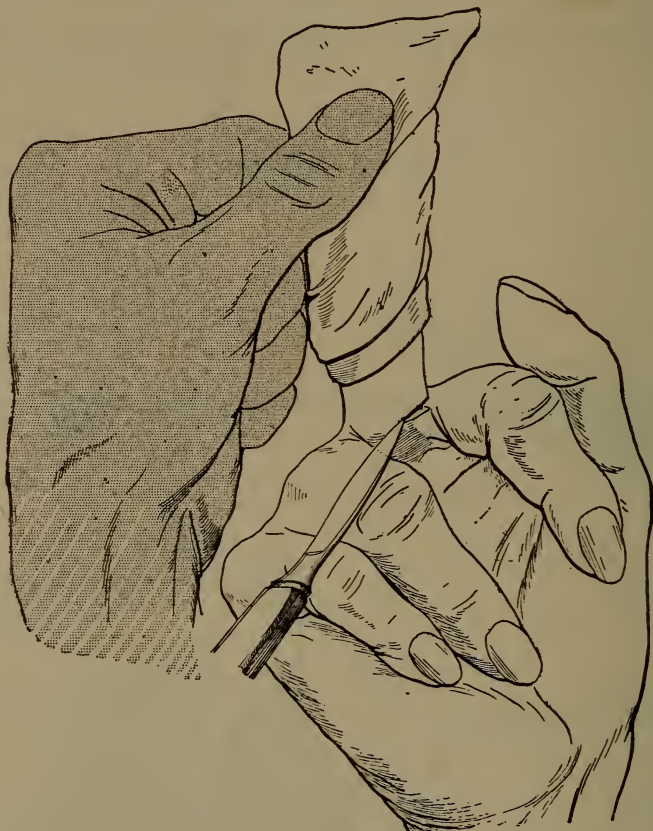


FIG. 565.—Amputation of the middle finger: Lifting the hand while making the transverse, palmar incision. (Veau.)

Disarticulate. Pull on the finger to separate the joint surfaces, which helps to locate the joint line. Hold the bistoury vertically, and with its point divide the lateral ligament to the left, then the dorsal ligament (Fig. 567), then the ligaments to the right, at the same time bending the finger to the right.

Tie the digital arteries, usually one on each side, and suture (Fig. 568).

(II) **Index and Little Fingers.**—In these two instances, the aim is to carry the scar toward the dorsum and the axis of the hand. In

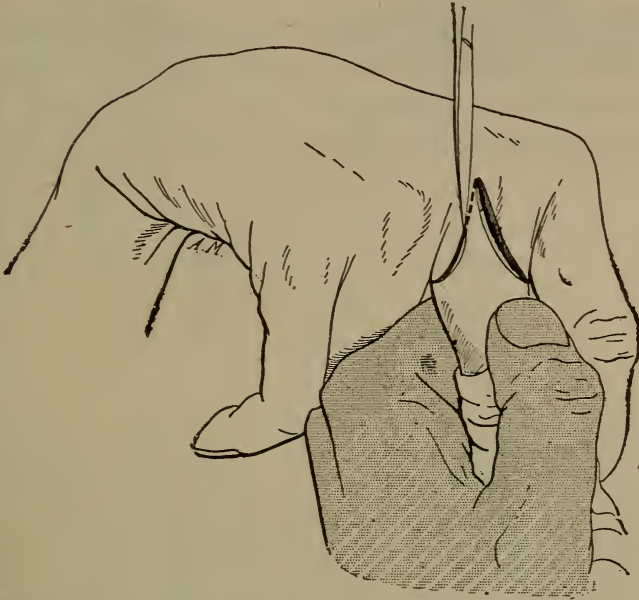


FIG. 566.—Amputation of the middle finger. Completing the skin incision. (Veau.)

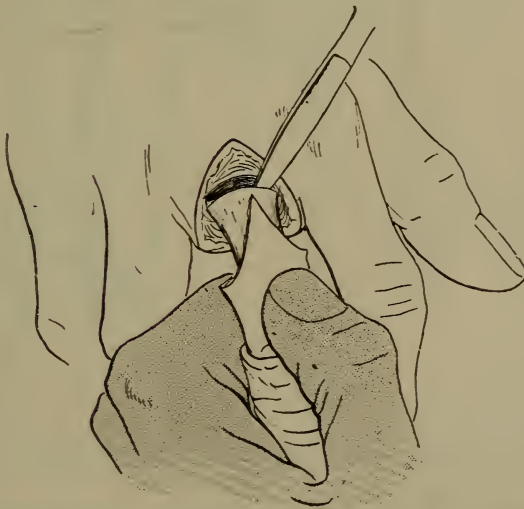

FIG. 567.—Amputation of the middle finger: Traction on the finger while the bistoury cuts first the left and then the dorsal ligaments. (Veau.)

the case of the index, it falls toward the ulnar side; in the case of the little finger, toward the radial side. The scar is, then, in each case, furthest removed from pressure.

The flap itself, of rounded outline, folds over on an axis passing obliquely through the joint cavity and approximates the adjoining finger.

The **removal of the index finger** is conducted along the same lines.

The first semicircular incision is carried around the radial side and completed by a second, following the web of the finger. The appearance of the flap is indicated in Fig. 573, and the final result in Fig. 574.

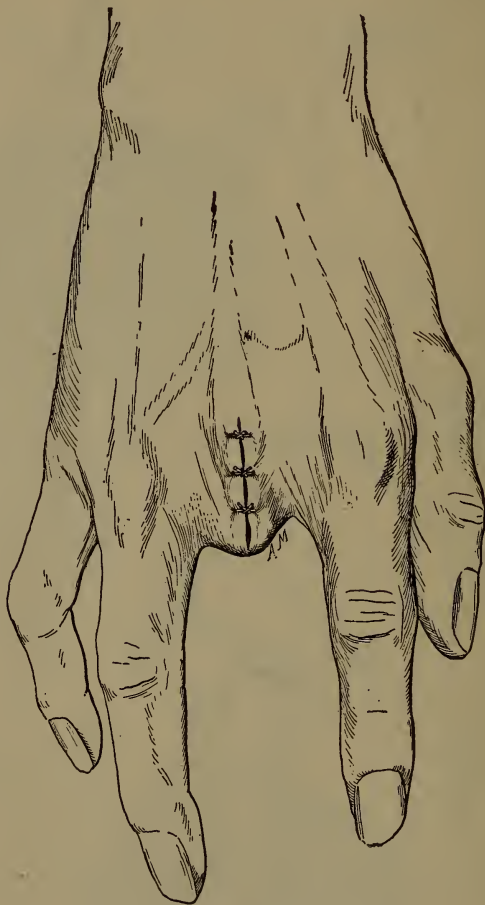

FIG. 568.—Amputation of the middle finger completed. (Veau.)

If the patient is a laborer, it is necessary to render the hand as useful as possible, nor must the cosmetic effect be neglected. It is necessary to reduce the size of the heads of the metacarpal bones.

The head of the metacarpal bone of the index is best reduced by an oblique section of the radial side; of the little finger, the ulnar side; of the ring finger, by transverse section (Fig. 575). With regard to

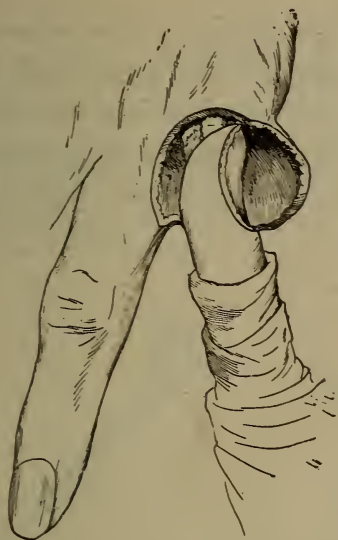


FIG. 569.—Amputation of the little finger: Flaps completed. (Veau.)

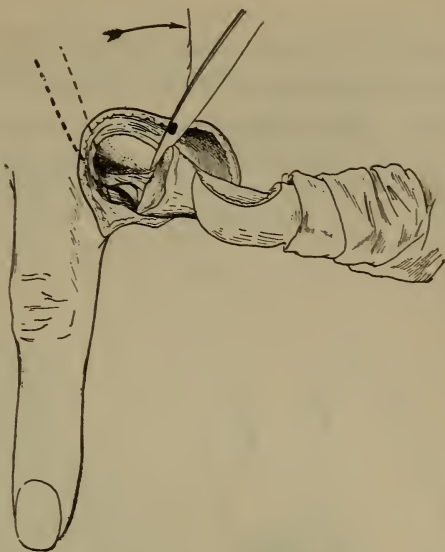


FIG. 570.—Amputation of the little finger: Disarticulation, cutting from left to right. (Veau.)

In the case of the *little finger*, begin the *incision* just below the joint line on the ulnar side of the extensor tendon, and carry it obliquely downward and forward and then across the palmar surface, inscribing a regular semicircle which ends at the free border of the web between the little and ring fingers. Complete the incision by cutting from this point to the starting-point, inscribing a semicircle with its concavity toward the web. Follow this same track again, cutting to the bone. Denude the bone completely (Fig. 569).

Disjoint, dividing the left and the dorsal and finally, the right lateral ligament (Fig. 570), and the flap is free (Fig. 571). Suture (Fig. 572).

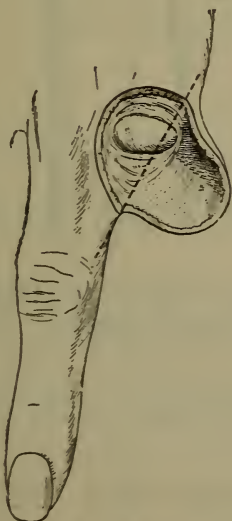

FIG. 571.—Amputation of the little finger: Flap after disarticulation. (Veau.)

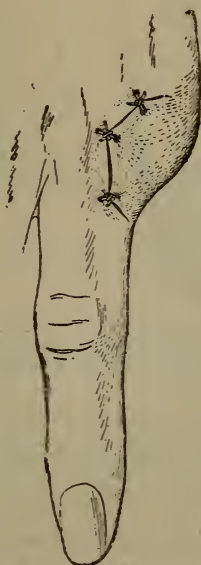

FIG. 572.—Amputation of the little finger: flap sutured. The line of union lies toward the axis of the hand on the dorsum. (Veau.)

the middle finger, the head of its metacarpus should not be removed unless shapeliness rather than strength is desired (see page 105).

(III) **The Thumb.**—The thumb must be treated with the utmost conservatism. The smallest part must never be removed unnecessarily, as it is almost as useful as the rest of the fingers together,

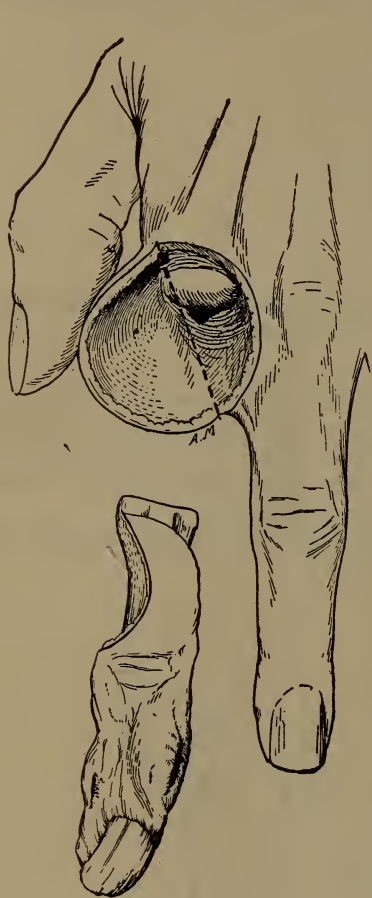


FIG. 573.—Amputation of index; showing form of flap. (Veau.)

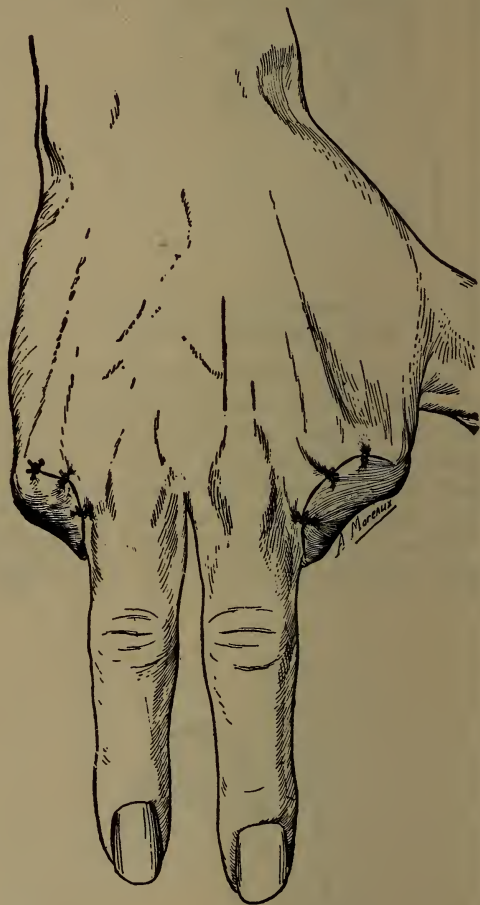

FIG. 574.—Amputation of index and little fingers completed. (Veau.)

and nearly always after a traumatism, it is best to do an atypical amputation. (Figs. 582, 583, 584.)

In the *typical amputation*, employ a palmar flap. Begin on the dorsal surface just below the articular line and incise to the right, reaching the edge of the palmar surface just above the interphalangeal crease. (Fig. 580.)

In the course of a finger amputation, once the finger is disarticulated at the metacarpophalangeal joint (amputation of whole finger), the treatment of the corresponding metacarpal head is to be considered.

The mode of procedure varies with the various fingers and is determined by two factors: The future appearance of the hand; and, second, its usefulness.

Fortunately the best cosmetic effect is consistent for the most part with conservation of function. Formerly we were advised to leave the metacarpal head intact whenever it was desired to maintain the whole strength of the hand. This was based on the notion that destroying the transverse ligaments left the metacarpus unstable and the

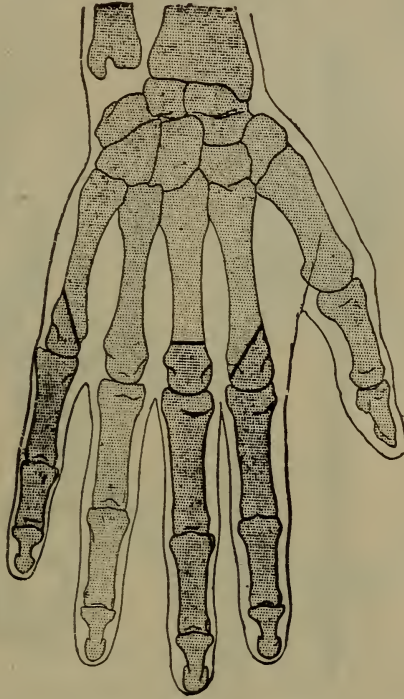

FIG. 575.—Lines of section of the metacarpal heads. (Veau.)

hand weakened in consequence; but the line of section need not extend so far beyond the articular surface. The line of section differs with the various digits as indicated in Fig. 575.

Thus the metacarpal head of the index and little fingers is sectioned obliquely to smooth off, in the one case the radial, in the other, the ulnar border of the hand. Compare Fig. 574 with figures on page 102.

The Ring Finger.—Divide the metacarpal head transversely (see page 103).

The Middle Finger.—The metacarpal head is best treated by slicing off a part of each lateral surface. If none is removed the separation of the adjacent fingers is too wide (Fig. 568). If too much is removed the index finger falls away from the thumb interfering with apposition (see page 104).

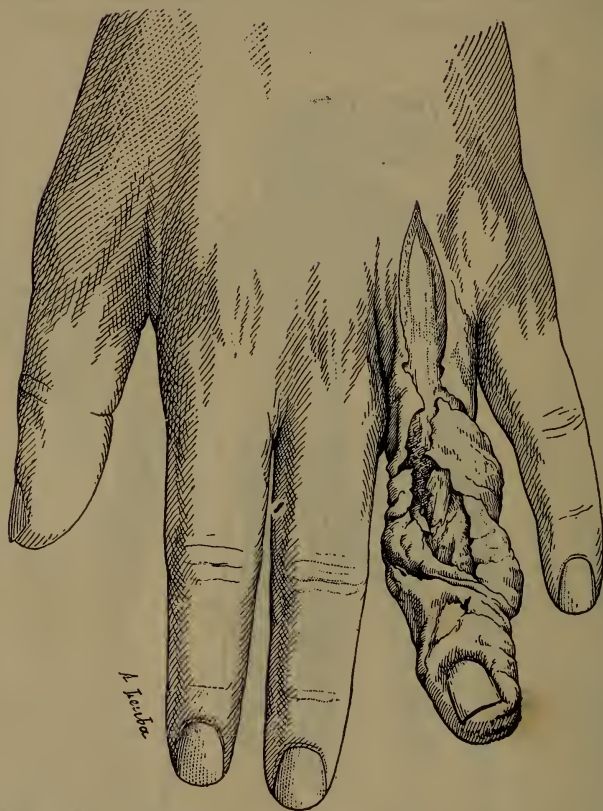


FIG. 576.—Crush of ring finger. Treatment.

Every crush of the fingers must be treated with the greatest conservatism. The temptation to get rid of the mangled tissues and to make a slightly stump is always great but the patient's mind dwells more strongly on the loss of tissue. In many cases it is impossible to say what effort the tissues may make toward repair. Trim the skin sparingly therefore. Carefully disinfect and splint in such manner as not to interfere with the circulation and wait for further indications.

However, a finger crushed in the manner indicated in Fig. 576, it is useless to save, because it will be deformed, unsightly and an actual hindrance. Usually the tissues slough and there is constant danger of infection involving the whole hand. It is best to disarticulate at once at the metacarpo-phalangeal joint.

Begin with a dorsal incision extending $1\frac{1}{2}$ inch above the head of the metacarpal bone, freely exposing the extensor tendon. The incision is now carried around the base of the finger (Fig. 577).

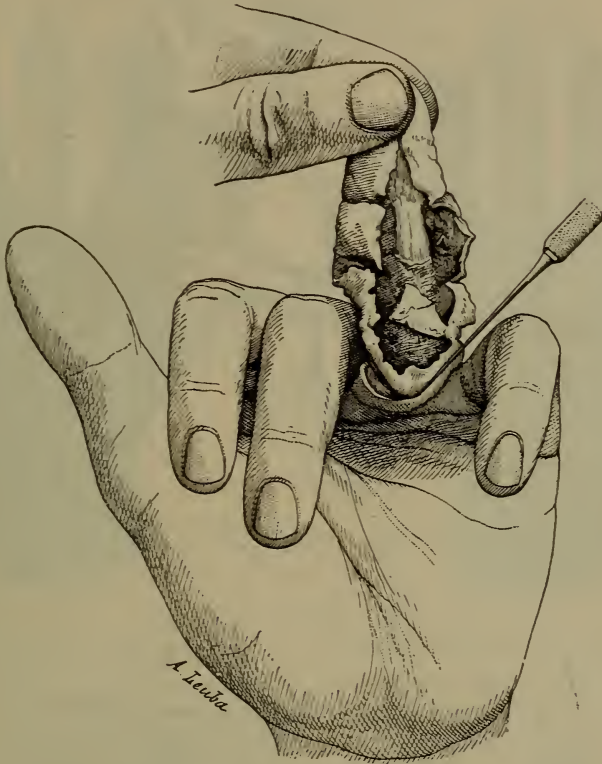

FIG. 577.—Crush of ring finger. Amputation.

Second step: Raise the finger so that the palmar surface presents and beginning at the dorsal incision cut from left to right along the base of the finger keeping within the limits of sound tissue. Cut down to the bone, dividing the flexor tendons and on either side the digital arteries. Having divided all the soft parts denude the bone with a rugine or periosteal elevator, exposing the head of the metacarpus thoroughly (Fig. 578).

Third step: Disarticulate by dividing the ligaments, first the dorsal, then the right lateral, and the left. The joint is now widely opened so that the palmar ligaments are exposed and easily divided (Fig. 578).

Fourth step: Resection of the Metacarpal head. Grasp the exposed bone with a bone-holding forceps and divide it transversely with a saw or bone shears (Fig. 579). Complete the hemostasis, ligating the digital arteries. Suture.

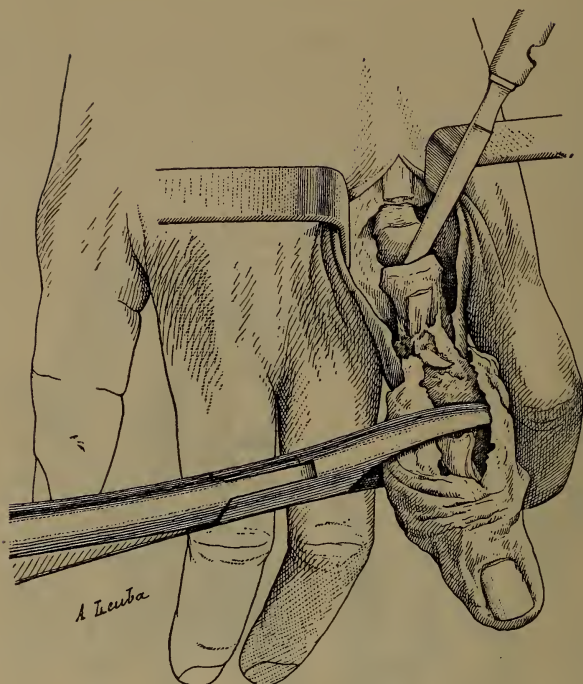


FIG. 578.—Crush of ring finger. Third step in amputation. (*Lejars.*)

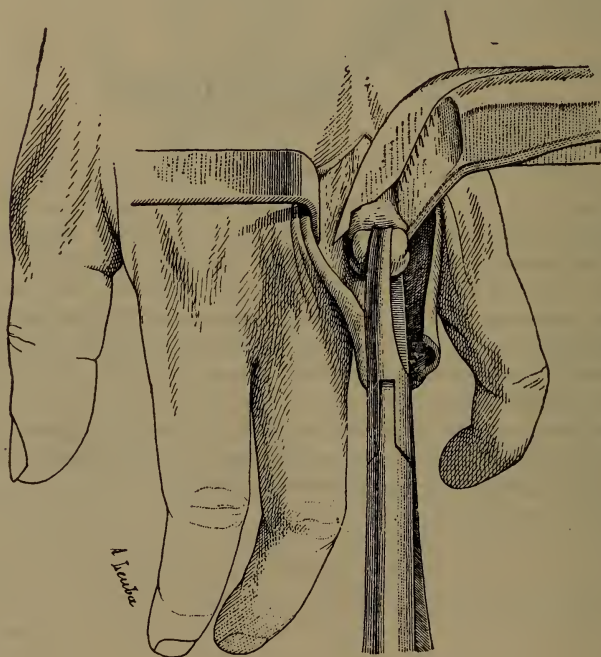


FIG. 579.—Crush of ring finger. Fourth step in amputation. (*Lejars.*)



FIG. 580.—Line of incision in typical amputation of the thumb. (*Farabeuf.*)a

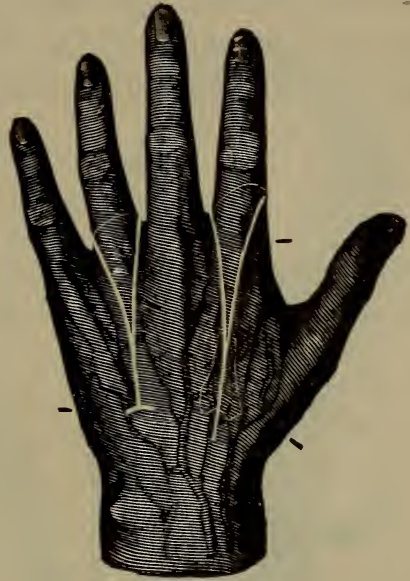

FIG. 581.—Lines of incision in removing a finger with its metacarpus. (*Veau.*)

The line of incision in typical amputation of the thumb should mark off, if possible, a palmar flap (Fig. 580). Begin the incision on the dorsal surface below joint line. Cut to the right, reaching the palmar surface at the interphalangeal crease. Continue the incision across the palmar surface. Now go back to the starting point and make an incision similar to first on the opposite side, completing outline of flap. While the assistant now steadies thumb, dissect the flap including all the soft parts down to the bone, dividing the flexor tendon and finally exposing the joint. Let the assistant now retract the flap while you pull on the thumb bringing the joint line into relief. Section the ligaments to the left, above and to the right successively. Drain and suture.

Trace of incision for removing the finger with its metacarpal. Note that incision begins on the back on the line connecting the bases of the metacarpal bones of thumb and little finger; extends along dorsum of metacarpus and branches above level of its head (Fig. 581). The head of the metacarpus is cleared and the denudation, sometimes difficult, carried toward the wrist. The point of the knife is inserted in the joint lines to disarticulate. Care must be taken to avoid the deep palmar arch which lies adjacent.

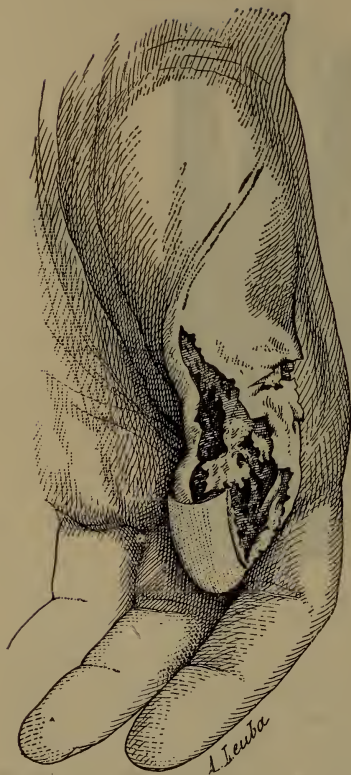


FIG. 582.—Crush of the Thumb.
Atypical amputation.



FIG. 583.—Crush of Thumb. Atypical
amputation. First step.

A crushed thumb must be treated with the greatest conservatism since even the shortest stump is useful, the metacarpal bone has all the value of a phalanx in the other digits (FIG. 582).

Do an atypical amputation. Let the primary incision follow the line of viable tissue, cutting down to the bone. Denude the bone with the rugine (FIG. 583). Resect so that the skin flaps will fall into place without undue stretching.

It must be remembered that the vitality of the flaps is lowered and if they are stretched tightly over the end of the bone are sure to slough. The drainage must be ample (FIG. 584).

ATYPICAL AMPUTATION OF THE HAND (Traumatism of the Metacarpals) (Fig. 585)

It is often inadvisable to amputate at once, for parts that seem devitalized may survive. Check the hemorrhage and disinfect and await the course of events. The limits of viable tissue can soon be determined. The technique is sufficiently indicated in Figs. 585, 586, 587, 588, 589.

AMPUTATION OF THE FOREARM

Disarticulation at the wrist is very rarely done in general practice. If a tuberculosis of the wrist calls for intervention, amputate the forearm (Fig. 590).

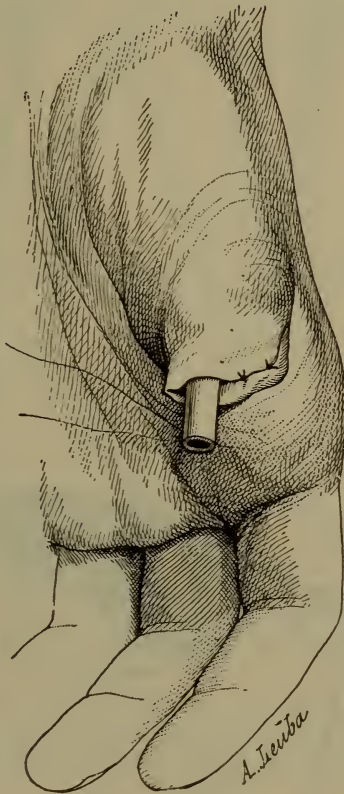


FIG. 584.—Atypical amputation of the thumb complete; part of metacarpus preserved. Drainage. (*Lejars.*)

Following traumatism, do an atypical amputation, conserving as much as possible of the member.

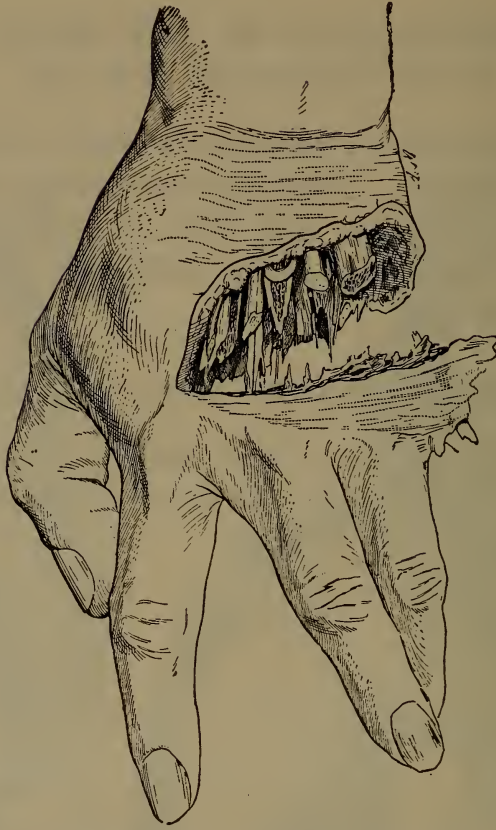

FIG. 585.—Crushing injury to hand. Useless to try to save any but the index finger. (*Veau.*)

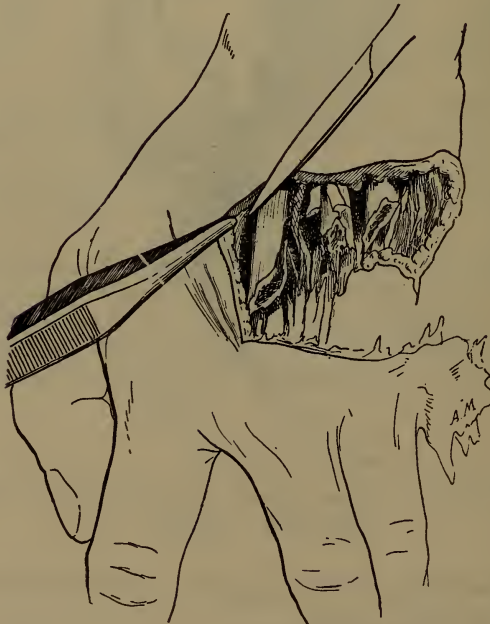

FIG. 586.—The metacarpals are denuded upward for an inch; all the soft parts saved. (*Veau.*)

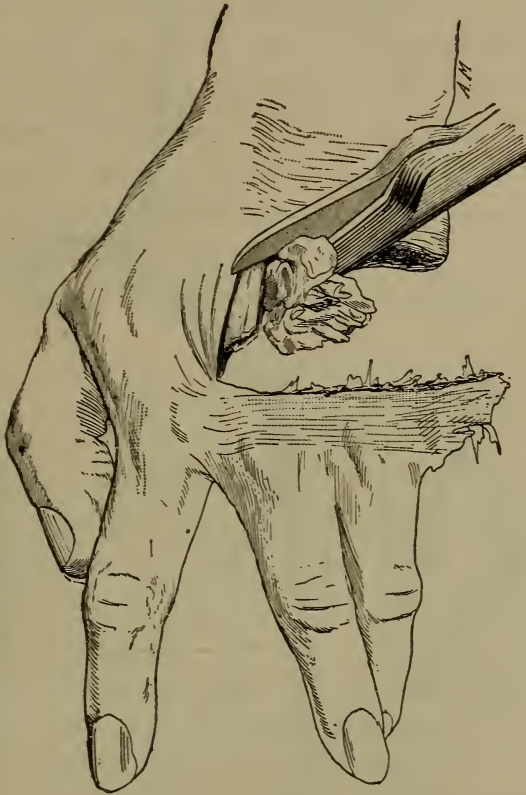

FIG. 587.—Section of metacarpals with bone-cutting forceps. (Veau.)

In the case of a crush of the hand involving the metacarpus, no effort is made to do a typical amputation; the whole effort is to save as much useful tissue as possible. As indicated in Fig. 586 denude the bones as high up as the skin flaps, after having been properly trimmed, require. Sometimes it will be advisable to wait for a day or two to see how much of the soft parts will live. Accordingly the hand is carefully disinfected. A moist antiseptic dressing is applied and kept under close observation until a line of demarcation occurs.

Once the level of bone section is determined resect with bone forceps, suture loosely with ample drainage, but be sure of the hemostasis.

If infection develops, remove the sutures and use prolonged immersion in hot normal salt solution.

Typical amputations of the forearm are most easily performed at any level, by a modified circular incision; for Technic, see Figs. 591, 592, 593, 594, 595, 596, 597, 598.

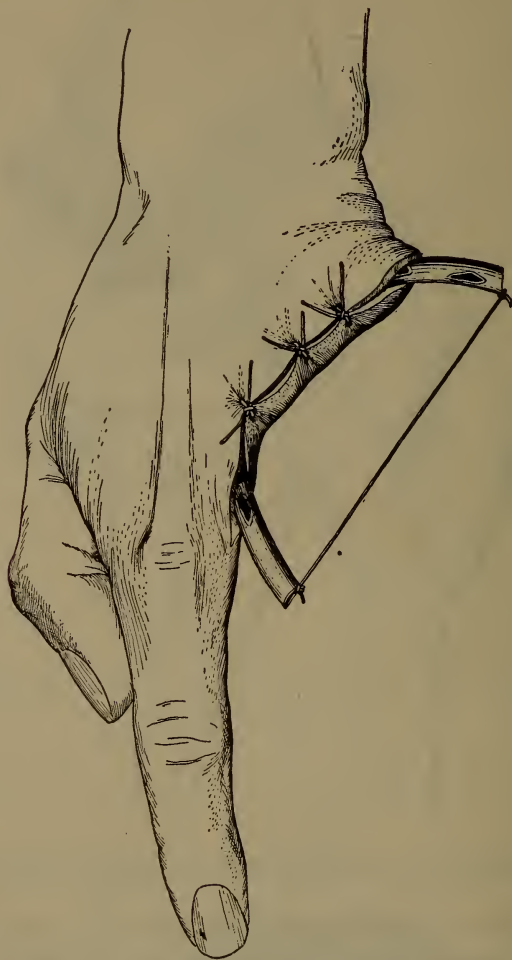


FIG. 588.—Amputation completed. (*Veau.*)

AMPUTATION AT THE ELBOW-JOINT

Make a circular incision 3 inches below the joint, involving the skin and fascia. Turn back the cuff to the joint. Divide the muscles over the joint line. Divide the lateral ligaments. Open the outer side of the joint first and, directing the assistant to make traction on the arm, separate the ulna and divide the triceps. Tie the arteries, resect the nerves, and suture.

AMPUTATION OF THE ARM

Apply an Esmarch tube high up near the axilla, or an assistant may compress the artery in the upper part of the arm or behind the clavicle.

Stand to the outer side of the arm. Retract the skin with the left hand if operating on the right arm, or direct the assistant to retract the skin if operating on the left arm. The skin section must lie about one diameter below the proposed bone section (Fig. 599). The successive steps of the operation are indicated in Figs. 599, 600, 601, 602, 603.

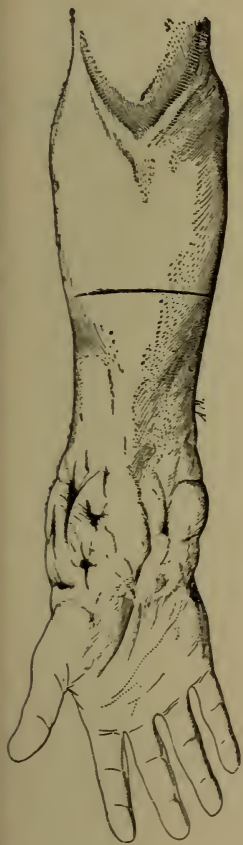

FIG. 590.—Amputation of the forearm. Tuberculosis of the wrist. (Veau.)

AMPUTATION AT THE SHOULDER-JOINT

Amputation at the shoulder may be performed by a variety of methods, each of which has its advantages and disadvantages. The special points to be thought of in making the operation are the control of hemorrhage, good drainage, easy disarticulation and a good stump. No one operation, perhaps, secures all of these principles in equal degree.

Spence's method is recommended as generally serviceable.

Recall the principal landmarks of the shoulder-joint, the acromion process, the coracoid, the tuberosities; recall the attachments of the various muscles; and the relations of the blood vessels.

The patient is placed with his shoulder close to the edge of the table, with shoulder elevated, and face turned to the opposite side. The operator stands to the outer side.

The operator aims at the exposure of the joint and disarticulation, and finally the formation of an axillary flap.

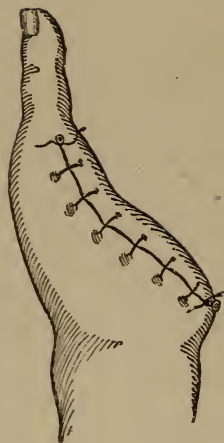


FIG. 589.—Amputation of the hand. Thumb saved. (Senn.)

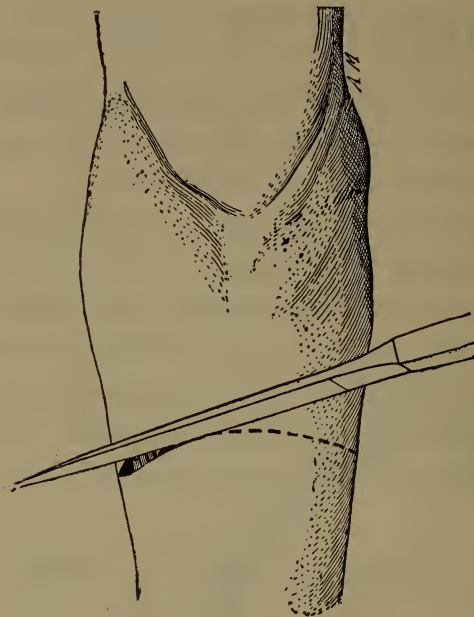


FIG. 591.—Amputation of the forearm. Beginning the circular incision, which must fall well below proposed line of bone section.

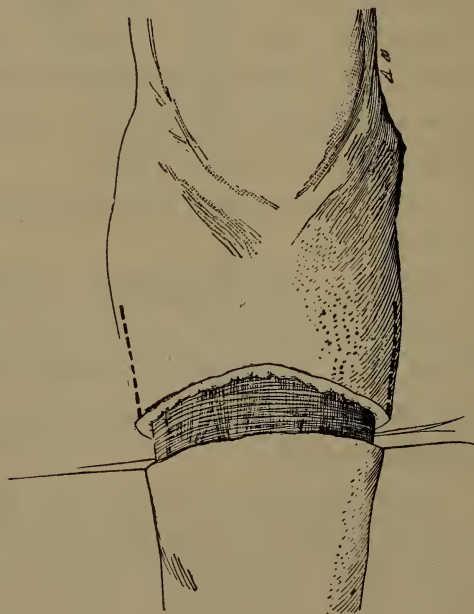


FIG. 592.—Amputation of the forearm. Completing the circular incision. Not only the skin but the fascia as well must be completely divided.

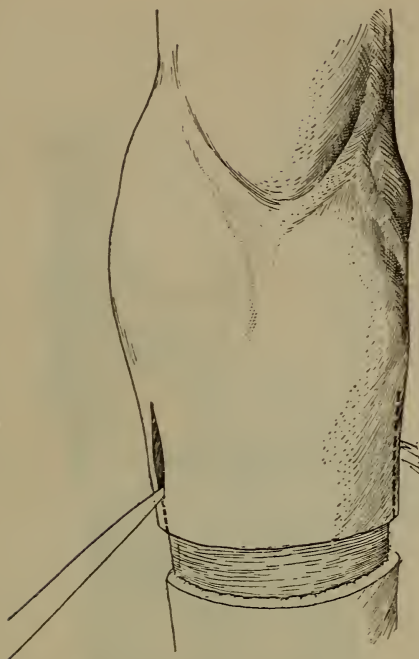

FIG. 593.—Lateral incisions extending upward two or three fingers' breadth, favor retraction of skin cuff.

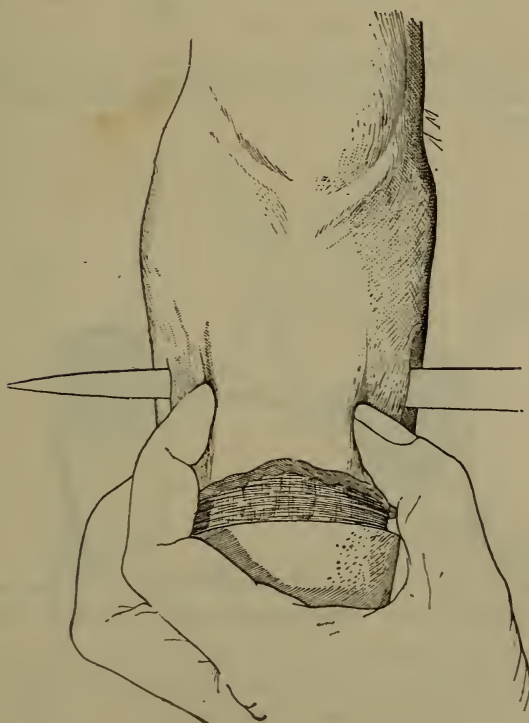


FIG. 594 —Third step. Transfix muscles at upper level of lateral vents, point of knife grazes bones. Hand must be supinated and flexed to relax muscles of forearm.

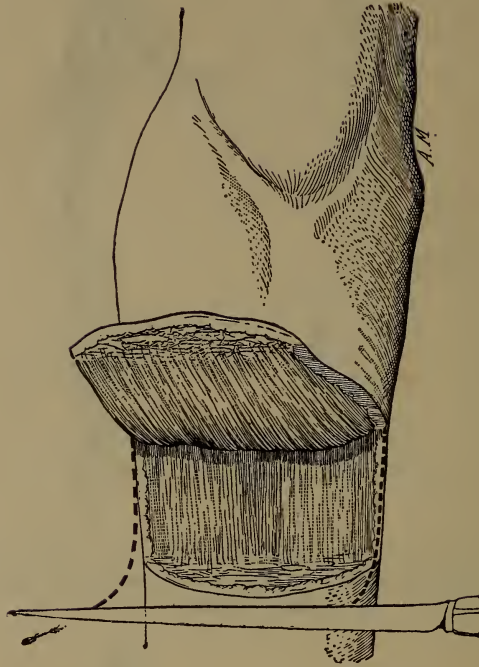


FIG. 595.—Complete the anterior flap by cutting outward following the transfixion. Repeat the process, passing the transfixing blade posterior to bones and fashion posterior flap in same manner. (*Veau.*)

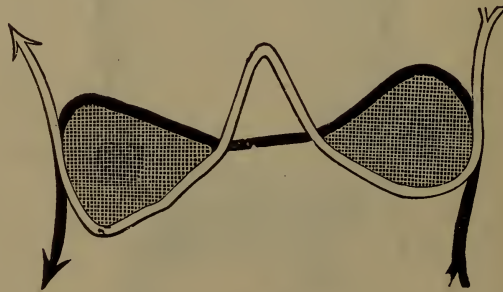


FIG. 596.—The flaps formed, it remains to divide the interosseous membrane and attached muscles, and the periosteum. The direction which the point of knife takes is indicated by the arrows.

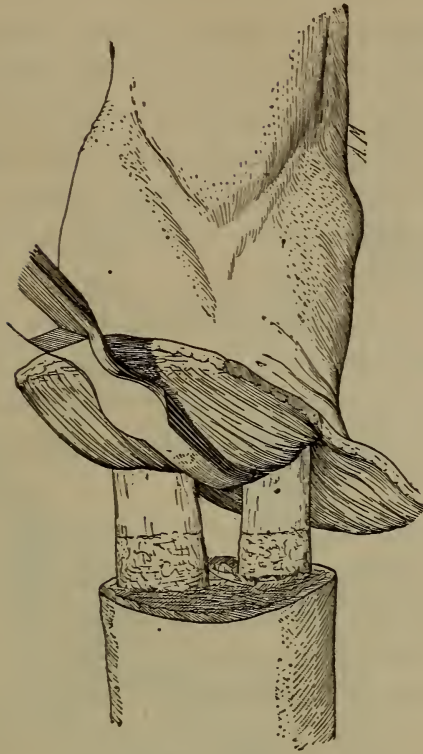

FIG. 597.

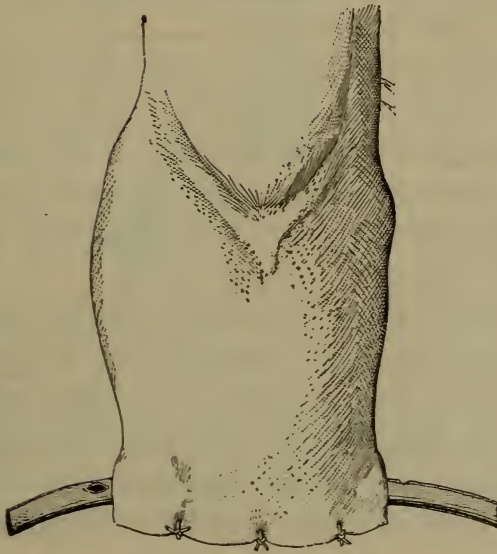


FIG. 598.

Fig. 600 shows manner in which the periosteum is stripped back after all the soft parts are divided. The bones are completely denuded to level of section previously determined. Use a three-tailed retractor to pull the skin flaps out of the way of the saw partly divide the ulna, saw through the radius and complete section of the ulna. Ligate all vessels, trim the median and ulnar nerves. Fig. 601 shows the manner of applying drainage which should nearly always be used, and of suturing the skin flaps.

Incision.—(1) Begin just in front of the coracoid process and cut vertically downward to the lower level of the tendon of the pectoralis major, keeping in front of the groove between the pectoralis major and deltoid. This incision should reach the bone; the pectoralis major tendon is divided. The bleeding comes from the humeral branches of the acromio-thoracic and from the anterior circumflex. These vessels may be clamped.

(2) Next carry the incision outward across the arm, making a slight curve, convex downward, and ending at the axillary border behind. All the structures are divided to the bone. The deltoid is divided just above its insertion and the hemorrhage comes from the muscular branches.

The *next step* consists in outlining the internal flap by making an oval skin incision, which extends from the termination of the first across the inner surface of the abducted arm to the end of the vertical part of the first incision (Fig. 604).

The *third step* consists in elevating the external flap which contains the deltoid. It is easily dissected and by this means the joint is exposed. The posterior circumflex artery must not be injured, and is preserved in the deltoid flap.

The fourth stage: *Disarticulate.* Begin by dividing the biceps tendon and the capsule with a transverse cut. Rotate the arm inward and divide successively the tendons of the teres minor, the infraspinatus, the supraspinatus; rotate the arm outward and divide the tendon of the subscapularis. If the humerus has been broken, rotate the head by means of a bone forceps.

Dislocate the head, divide the capsule behind and push the head up to the level of the acromion; drawing the head outward, slip the knife behind the head and prepare to complete the section of the soft parts. If the axillary has not been previously ligated, the assistant grasps the upper part of the flap about to be divided and his hands follow the knife downward ready to compress the artery as soon as divided.

The knife follows the bone till opposite the skin incision when it cuts directly through the soft parts that the vessels may not be divided obliquely. The arm is now completely removed.

The next step consists in *ligating the vessels* and in trimming the

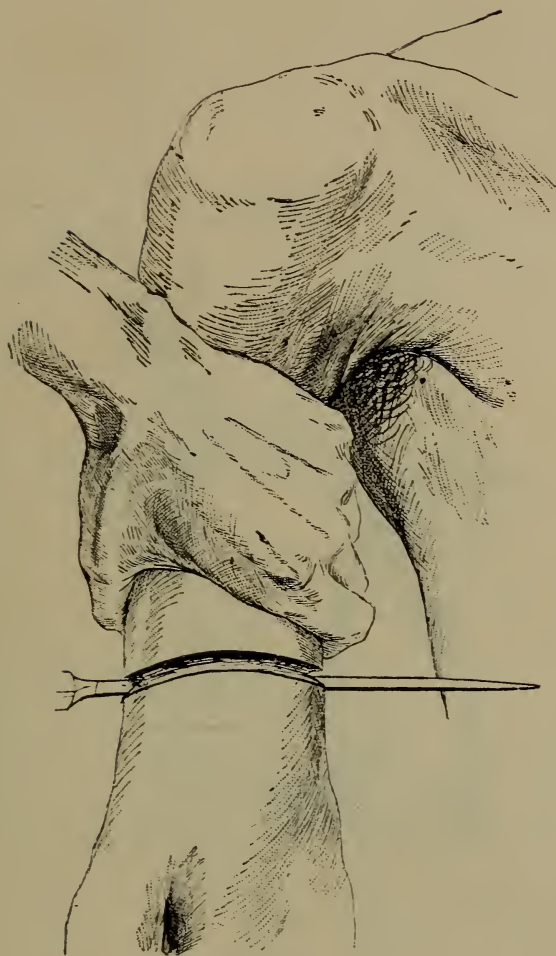


FIG. 599.—Amputation of the Arm. Circular flap. (*Veau.*)

Supposing an amputation of the right arm, grasp the arm above the proposed incision, with left hand, pulling the skin tight while the assistant supports the member. First step: Make a semicircular cut from the inside, over the front and to the outside. Repeat, passing from the inside behind the arm. Avoid wounding the artery on the inside. Divide the skin and fascia only. There will be considerable venous hemorrhage which is to be disregarded. There will be about an inch gap when the skin and fascia are completely divided. The next step is liberation and further retraction of the skin flap.

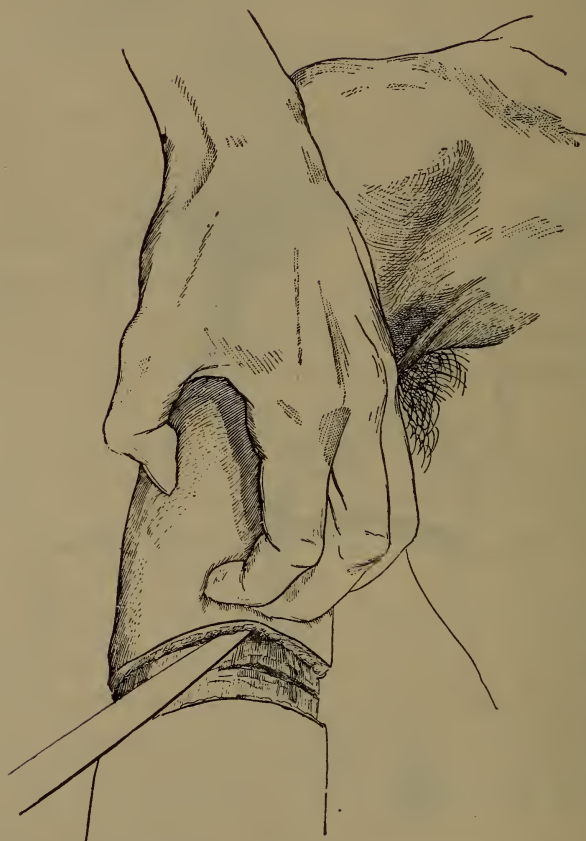


FIG. 600—Amputation of the arm. Circular flap. (Veau.)

Second step: Free the skin flap. Divide the fascial attachments with the point of the knife but do not button-hole the skin flap. The fascial attachments are firmest over the line of the artery and a little patience is necessary in freeing them. Loosen the skin until there is a gap of at least $1\frac{1}{2}$ inches. The flap must be well mobilized. You are ready now to make a circular section of the muscles.

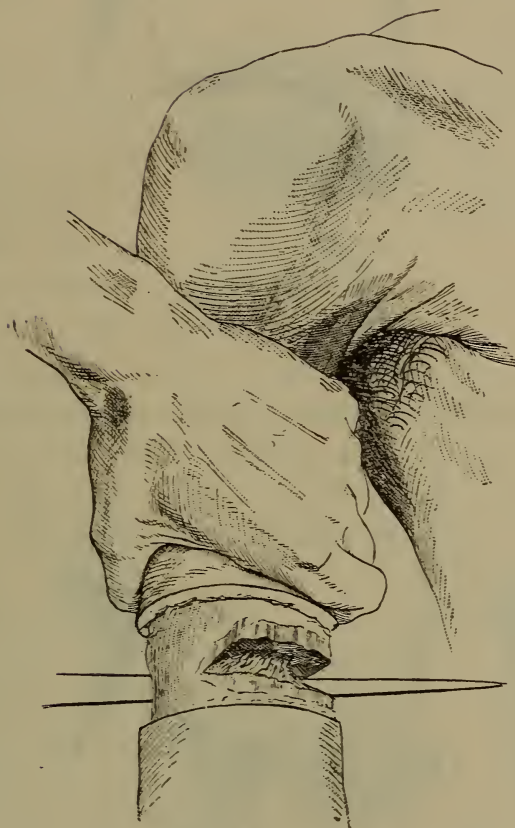


FIG. 601.—Amputation of the arm. Circular flap.

Third step: First circular section of the muscles. The soft parts, skin and muscles are to be strongly retracted, either by the operator's left hand or by an assistant. By a circular sweep of the knife divide the muscles at the level of the retracted skin. Divide all the structures down to the bone. But they do not contract evenly; therefore a second circular section is required.

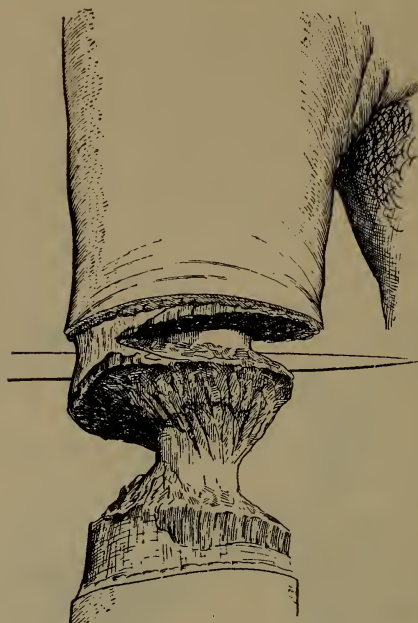


FIG. 602.—Amputation of the arm. Second circular section of the muscles.

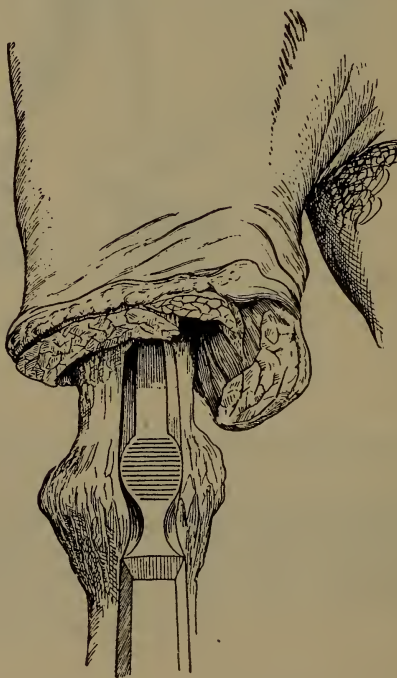

FIG. 603.—Amputation of the arm. Denudation of the periosteum.

Fourth step: Second circular section of soft parts at level of retracted skin, forming a stump with a smooth even surface (Fig. 602). The blood vessels are easily identified and should be ligated at this time. Fig. 603 shows the next step which consists in the denudation of the bone, stripping back the periosteum to the level of the proposed bone section when the bone is sawed. Remove the tourniquet and complete the hemostasis. Suture the periosteal flaps over the bone if possible. Mattress suture the muscles and fascia. Drain. Suture the skin.

axillary nerves and in *suturing the flaps* so as to form a vertical scar as nearly as possible. The glenoid fossa may be curetted.

For the control of hemorrhage, Wyeth's plan of constriction may be followed. An elastic ligature held in place by two pins passed through the soft parts before and behind the shoulder compresses the axillary vessels.

AMPUTATION ABOVE THE SHOULDER

This operation, bloody and often fatal, may need to be undertaken for malignant disease in the vicinity of the shoulder-joint or as an emergency in the case of crushing injury to the shoulder or of gunshot wounds.

The procedure as defined by Berger contemplates the resection of the middle third of the clavicle and ligation of the subclavian; the formation of the antero-inferior and a postero-superior flap; and finally the division of the muscles connecting the scapula with the trunk.

The operation is thus described:

Place the patient on his back close to the edge of the table, with the shoulder slightly elevated. Begin the *incision* over the clavicle at the outer border of the sterno-mastoid, and follow the clavicle outward to the acromial end, cutting to the bone. Denude the middle third of its periosteum with the rugine, and divide the bone at the junction of the inner and middle thirds. Elevate the bone and divide again at the junction of the middle and outer third. Separate by blunt dissection the fascias overlying the subclavian vessels and first ligate the artery at the outer border of the first rib and then the vein.

Now change the patient's position: the shoulder is brought over the edge of the table, the arm abducted, and the head turned to the opposite side.

Form the antero-inferior flap. Begin an incision at the middle of

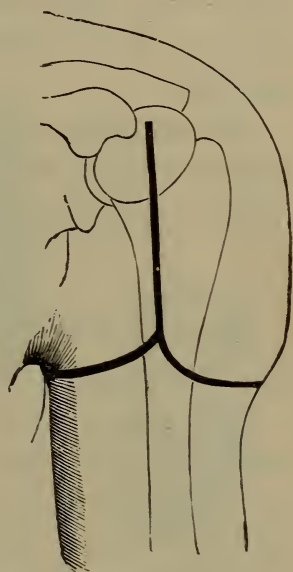

FIG. 604.—Spence's amputation. (Moullin.)

the first and carry it obliquely downward and outward; just to the outer side of the coracoid process, along the anterior border of the deltoid, to the axillary border and thence across the inner surface of the arm just below the axillary fold and thence down the axillary border of the scapula. Divide the pectorals and the latissimus dorsi close to their insertions. Resect the nerves of brachial plexus.

From the postero-superior flap. Begin the incision over and just internal to the acromio-clavicular joint and carry it downward over the spine of the scapula to the lower angle of the scapula, where it joins the preceding incision. Dissect the flap and expose the muscles. Divide first the trapezius and then with heavy scissors divide close to the bone, the muscles attached to the posterior border, the serratus magnus, the rhomboideus major and minor, and the levator anguli scapulæ.

The arm falls away. Complete the hemostasis and drain through button-holes in the flaps in the axilla and scapular region. Bandage firmly so as to obliterate the cavities.

AMPUTATION OF THE TOES

These amputations are more frequently consequent upon traumatism; occasionally for deformity or other painful conditions.

In the amputation of fingers, as much as possible is saved; in the amputation of toes, the whole toe is nearly always removed. In consequence these amputations are usually typical, for one does not so much need to concern himself with the conservation of tissue.

In the case of total ablation of the finger, a part of the metacarpal head must usually be removed to enhance function; the head of the metatarsals must always be saved, where possible, to preserve the functions of the foot.

The position of the cicatrix demands more attention in the case of the toes. A special effort must be made to leave the scar farthest from pressure; that is, dorsal and to the inner side with reference to the axis of the foot.

Local anesthesia is often sufficient, forming an anesthetic ring around the entire toe, involving the skin. The injection may need to be renewed for the deeper tissues; and before disarticulation, inject the joint.

AMPUTATION OF THE GREAT TOE

In amputation of the great toe, the flap resembles that of the index finger and the scar adjoins the base of the second toe.

Begin by locating the joint line. The *incision* commences just below this, and over the tibial border of the extensor tendon, and extends with a slight outward convexity, downward and forward to the interphalangeal crease on the plantar surface and across the palmar surface obliquely, ending at the web.

Begin on the dorsum again at the original starting-point and with a slightly curved incision, join the ends of the first (Fig. 605).

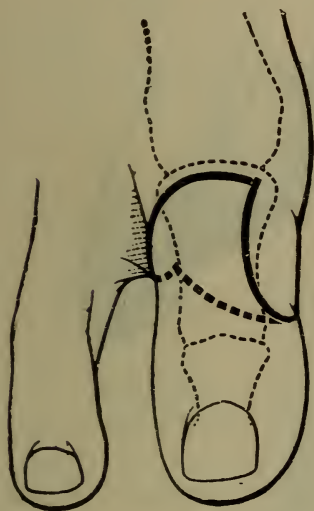

FIG. 605.—Lines of incision for amputation of big toe. (Farabeuf.)




FIG. 606.—Amputation of big toe completed. (Farabeuf.)



FIG. 607.

Dissect the flap, keeping close to the bone, so that all the soft parts shall be preserved in the flap. Divide the flexor tendon—sometimes rather difficult.

Disarticulate. Divide, first, the lateral ligaments to your left, then the dorsal, and finally those at your right. Divide the plantar ligaments, twisting the toe, as in the case of the finger. Employ drainage; pull the flap into position and suture. The shape of the flap and the position it assumes are represented in Figs. 606 and 607.

AMPUTATION OF THE LITTLE TOE

Incision.—Begin at the inner end of the joint line and cut obliquely downward and outward, meeting the plantar surface at the joint line below, and then backward and inward toward the web (Fig. 608). In this manner a convex flap is formed (Fig. 609). Dissect the flap, preserving in it all the soft parts. Expose the joint line.

Disarticulate. Making vigorous traction on the toe, divide in regular order the lateral, the dorsal, the lateral (to your right), and plantar ligaments.

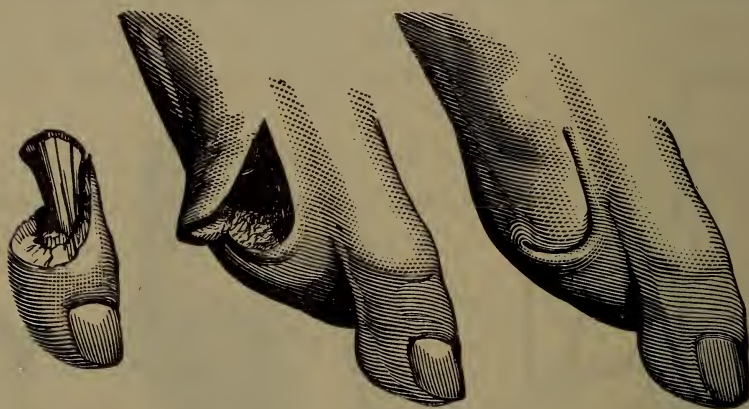


FIG. 608.

FIG. 609.

FIG. 610.

FIGS. 608 to 610.—Amputation of the little toe. (Farabeuf.)

Drain from the upper part of the incision and suture. The position of the cicatrix is represented in Fig. 610.

AMPUTATION OF ONE OF THE MEDIAN TOES

Incision.—The line of the joint having been determined, begin just above it on the dorsum, incising forward and downward to just below the web, crossing the palmar surface and back to the starting-point, completing the racket (Fig. 611). Remember that the metatarso-phalangeal joint is considerably above the line of the web. Denude and divide the flexor tendon.

Disarticulate in the manner already described for the other toes. Drain from the upper end of the incision and suture (Fig. 612).

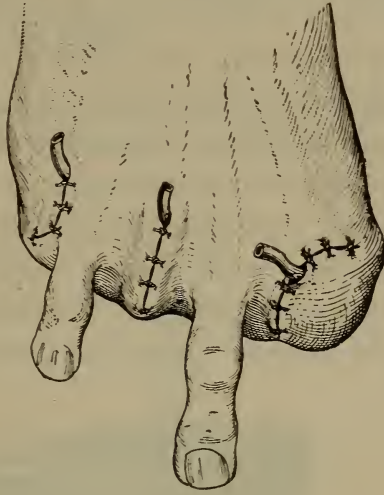
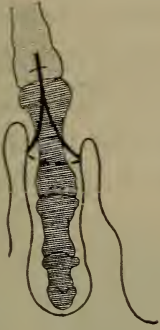


FIG. 611.—Line of incision for amputation of toe. (Veau.)

FIG. 612.—Suture and drainage after amputation. (Veau.)

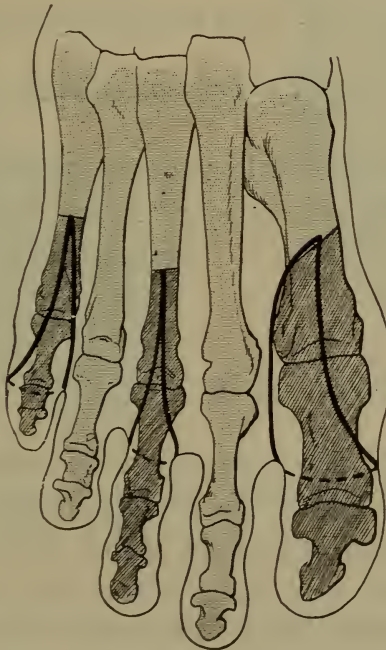

FIG. 613.—Lines of incision for removal of toes with head of corresponding metatarsals. (Veau.)

AMPUTATION OF A TOE WITH PART OF ITS METATARSUS

This amputation presents some difficulties in dissecting the flaps, because of the palmar projection of the head of the metatarsal.

The incision is racket-shaped, as in amputation of the toe, but it begins higher up, above the level of the diseased bone, and runs down to the web, across the palmar surface and back to the starting-point, as represented in Fig. 613. To dissect the flaps for the middle toes, denude the dorsum of the metatarsus and divide it with the bone for-



FIG. 614.—Amputation of big toe with head of metatarsal. (*Farabeuf.*)

ceps, and lifting upon the divided end, dissect forward along the palmar surface.

The metatarsus of the little and great toes may be sawed. In forming the flap for the great toe and its metatarsus (Fig. 614) do not forget to remove the sesamoid. Drain as in amputation of the toes, and suture.

AMPUTATION OF A PART OF THE FOOT

As in the case of the hand, the rule is to conserve as much as possible of the foot with this proviso, that a painful mass of scar tissue does not form in the stump and the action of the flexors of the foot is retained.

In the case of traumatism or gangrene, where the soft parts are more involved than the bone, the line of section follows the healthy skin and the bone section will be made to accommodate itself to the skin flaps.

Atypical Amputation.—If the case is one of tuberculosis, the bone is

more involved than the skin, and one may determine the upper limit of the diseased bone and divide it there. In such a case, one may fashion a palmar flap, and make a dorsal scar—the typical amputation. But, as Veau says, do not concern yourself with the formal operations, such as a Lisfranc or a Chopart—excellent exercises on

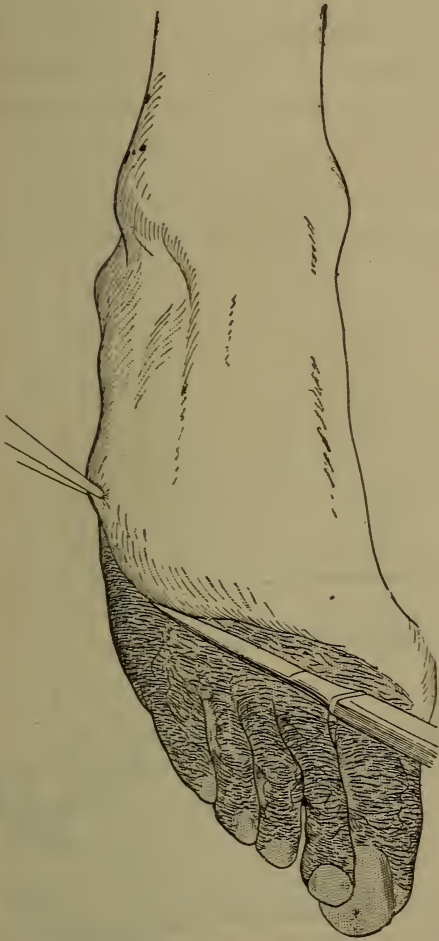


FIG. 615.—Following the line of demarcation. Atypical amputation. (Veau.)

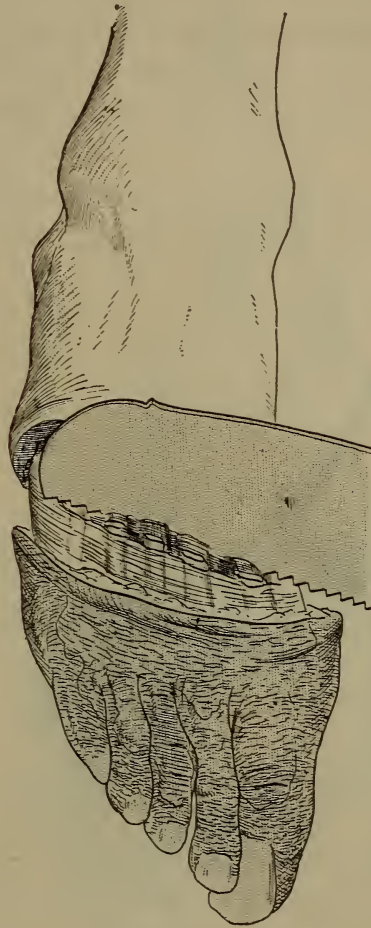


FIG. 616.—Dividing the bones. (Veau.)

the cadaver—but saw the bones where you must, to remove all the disease.

In the case of gangrene or traumatism, then, divide the tissues to the bone, along the line of demarcation.

The borders of the palmar and dorsal flaps must correspond to the borders of the foot (Fig. 615). Once the soft parts are divided,

they should be retracted by dividing their attachments close to the bone, and the bones are divided high enough for the flaps to come together (Fig. 616).

In the case of tuberculosis make a transverse incision dorsally and

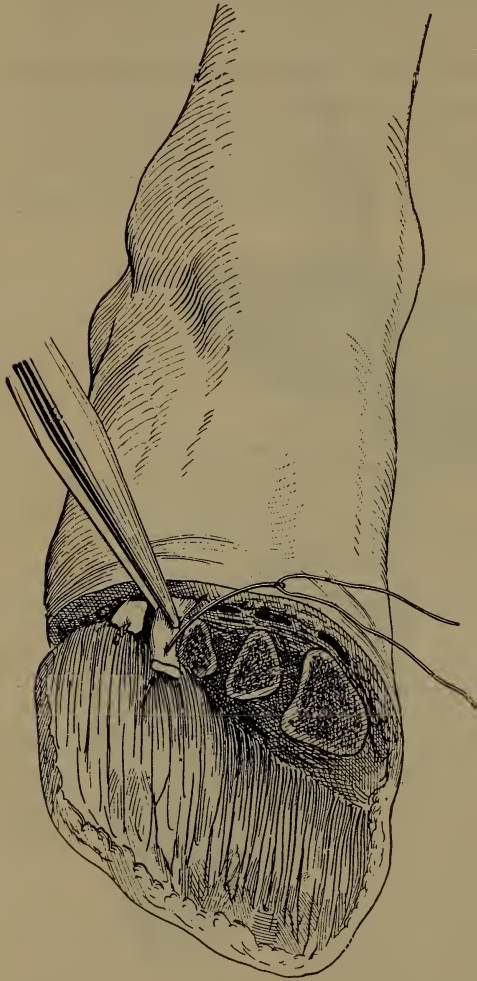


FIG. 617.—Suturing extensor tendons to skin flap. (Veau.)

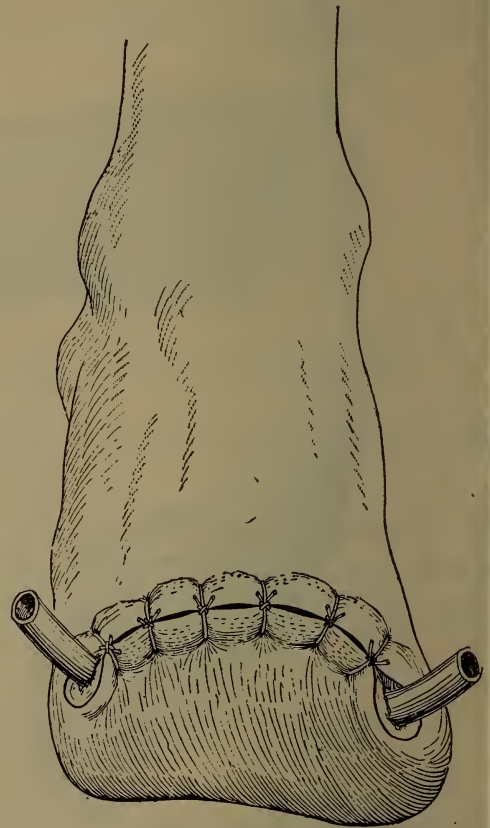


FIG. 618.—Suture and drainage. (Veau.)

shape the *long palmar flap* by transfixion and cutting outward, or by cutting from without inward (Fig. 617).

Suture the tendons to the periosteum or fibrous tissues, for if the tendo-achilles is left unopposed the result will be a useless stump. Resect the nerves and suture, using drainage (Fig. 618).

TOTAL AMPUTATION OF THE FOOT

In total amputation of the foot, the exact procedure will depend chiefly upon the condition of the os calcis. If it is sound, Pirogoff's osteoplastic amputation is indicated. If the os calcis is diseased, Symes' amputation is indicated—a disarticulation at the ankle-joint, with erosion of the malleoli. But one cannot always determine beforehand the state of the os calcis, and therefore an incision should be made which will permit either procedure after the os calcis has been examined.

First Incision.—The first incision extends across the sole with one end at the tip of the external malleolus and the other a finger's

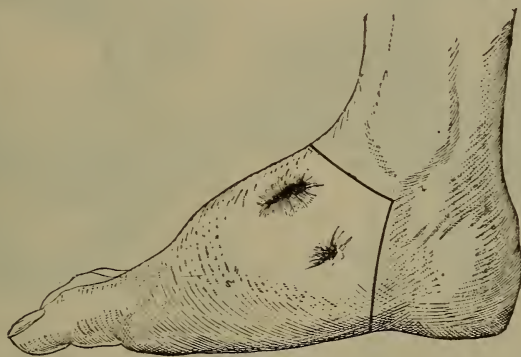

FIG. 619.—Line of incision for complete amputation of foot. (Veau.)

breadth below the tip of the internal malleolus. (The internal malleolus does not extend quite so low as the external) (Fig. 619).

An assistant elevates the limb; you seize the foot with the left hand and make this plantar incision from left to right; that is to say, in the case of the right foot begin the incision at the end of the outer malleolus and terminate it a finger's breadth below the internal. In the case of the left foot, begin at the internal and end at the external malleolus.

Repeat the movement several times, for there is always considerable difficulty in accomplishing complete section of the tendons, some of which are oblique to the line of incision and others deep and imbedded in grooves.

Second Incision.—Connect the extremities of the first incision by a

dorsal incision, which should be slightly convex forward toward the toes. This line crosses over the head of the astragalus. The foot should be lowered and the cut made from left to right. Extension of the foot will facilitate the division of the anterior tendons and ligaments.

Now distinguish the head of the astragalus, and between it and the articular surface of the malleolus pass the point of the knife and cut

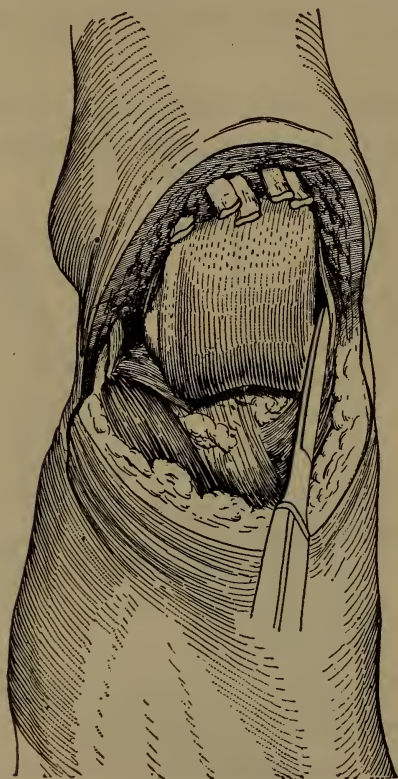

FIG. 620.—Section of the lateral ligaments. (Veau.)

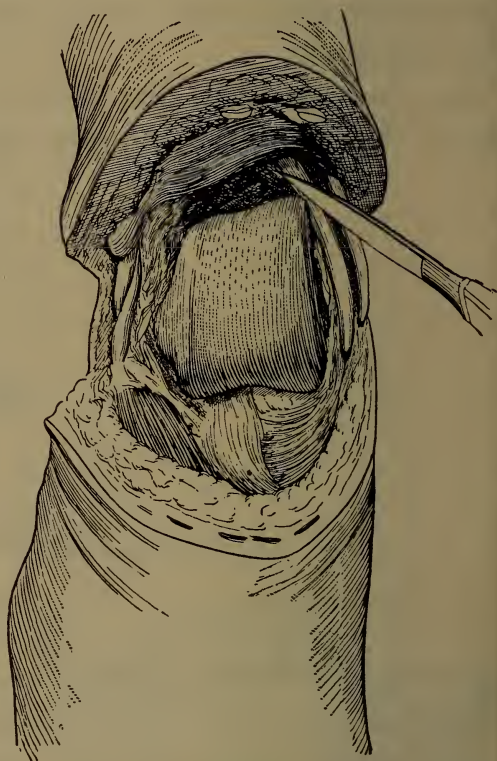

FIG. 621.—Clearing the upper and internal surfaces of the os calcis. (Veau.)

downward (Fig. 620). By this means, the lateral ligaments are divided.

The posterior ligaments are divided by cutting along the upper surface of the os calcis (Fig. 621). The joint is now freely exposed and the os calcis may be brought into view and examined. In examining the outer side, dissect back the soft parts for an inch, but not quite so far on the inner side. To be sure of the condition of the bone, its substance must be inspected.

(A) *Suppose the Os Calcis is Sound.*—Grasp the foot firmly with the left hand, depress it and pull upon it at the same time, while the assistant retracts the flaps, which have been loosed from the sides of the bone.

The flaps are held back by retractors on each side, which are slipped down with the progress of the saw, the assistant bracing his thumbs against the heel.

The saw is started in the upper face of the *os calcis*, a finger's breadth behind the astragalus in a manner to take off a slice from above downward and forward (Fig. 622). With the completion of

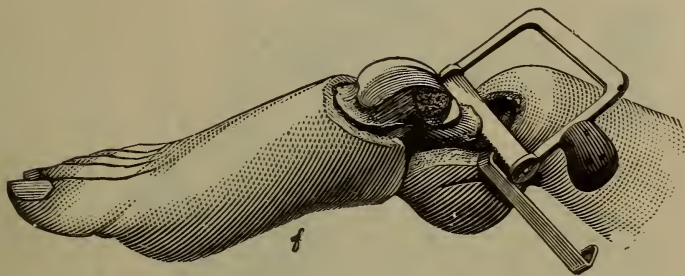


FIG. 622.—Section of the *os calcis*. The saw directed downward and forward. The retractors slipped downward as the saw progresses. (*Farabeuf.*)

this section, the foot is removed, and the posterior part of the divided *os calcis* is left in the heel flap.

The next step is to *saw off the malleoli*. Begin by completely denuding these processes of their covering, skin, fascia and tendons. Carry the denudation upward, a distance of two fingers' breadth behind; just above the level of the articular surface of the tibia, in front. The posterior tendons especially are sometimes difficult to dislodge from their groove.

The line of section being thus cleared, the heel flap is held well up toward the calf, out of the way, by the assistant, who also supports the leg in the horizontal position.

It is well for the operator to steady the limb by seizing one of the malleoli with a bone-holding forceps. The saw enters just above the articular line in front, and emerges a full finger's breadth above that level (Fig. 623). If the section is not carefully made, the coapta-

tion of the sawed surface of the os calcis to that of the tibia may be imperfect.

Complete the hemostasis, bring the two bone surfaces together, and suture the anterior tendons to the fibrous covering of the under surface of the os calcis, the better to fix this stump in position. If it is feared the bone will slip, one or two bone sutures may be employed. Suture the skin, usually employing drainage.

(B) *Suppose the Os Calcis is Diseased.*—In case the os calcis is diseased, it must be entirely removed, instead of sawed.

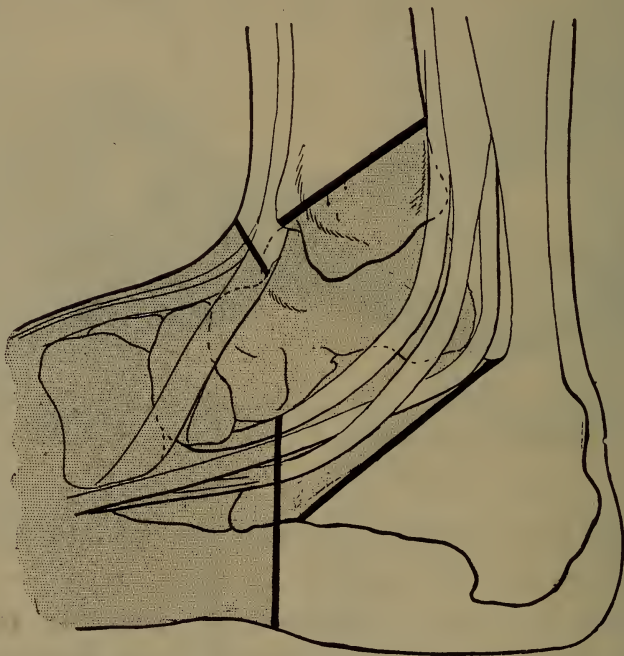

FIG. 623.—Parts removed in Pirogoff's amputation represented in dark. (Veau.)

The left hand strongly flexes the foot, until the posterior end of the os calcis points upward (Fig. 624), and as the point of the knife dissects the tissues off the left side, the foot is rotated to the right, and when working on the right side, rotated to the left; in this manner the os calcis is finally enucleated, being careful to follow the bone closely and not to "button-hole" the flap.

Remember the principal vessels are to the inner side and are to be lifted up with the flap.

Especial care is required when the attachment of the tendo-achilles is divided; the bone must be shaved, for it is here practically sub-



FIG. 624.—Denudation of the posterior surface of the os calcis. (*Farabeuf.*)

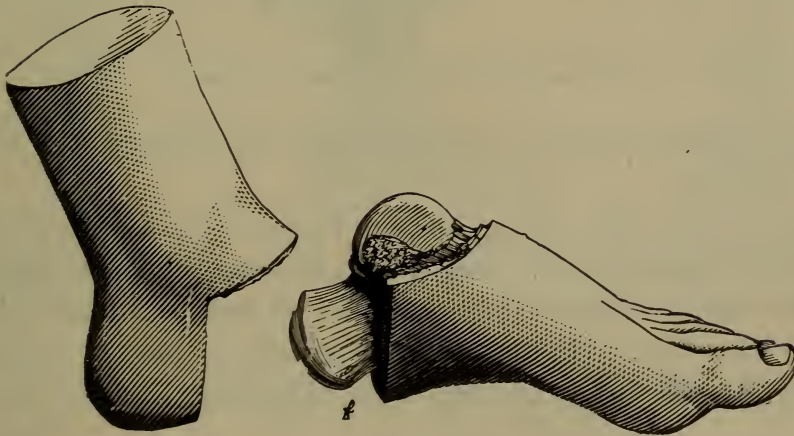


FIG. 625.—Syme's amputation of the foot. (*Farabeuf.*)

cutaneous, and it is easy to puncture the flap. You may expect this stage to be tedious.

Finally the foot will be removed (Fig. 625).

Now denude the lower end of the bones of the leg, observing that the tendons in front are held down by their fibrous sheaths. In order to facilitate this dissection, sweep the point of the knife around the bone, keeping it in close contact with the bone. This dissection

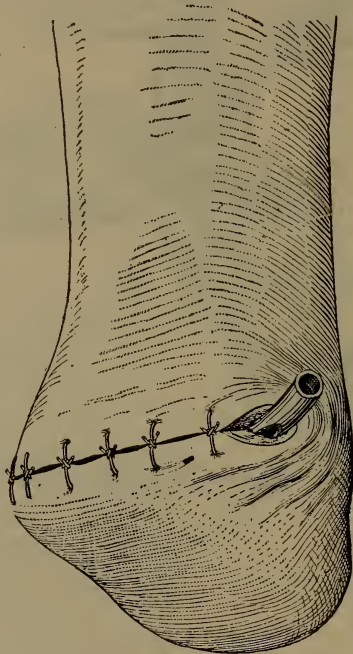


FIG. 626.—Suture and drainage. (*Veau.*)

must be carried upward for an inch and the malleoli will be completely exposed.

Steady the leg with a bone-holding forceps, and saw the bones at the level of the cartilage. Begin by notching the tibia, then complete the section of the external malleolus and terminate with the section of the tibia. If some cartilage remains, it may be scraped off.

Resect the nerves, suture and drain (Fig. 626).

AMPUTATION OF THE LEG

The leg may be amputated at any level. Formerly, when supuration was the rule, and the cicatrix was large, adherent, and pain-

ful, prohibiting the use of artificial limbs, the "point of election" was high up. The knee was flexed and the patient made use of a "peg-leg," the weight falling on the patella (Fig. 627).

With present methods the scar is a matter of less concern and the aim should be to amputate as low down as possible, to the end that

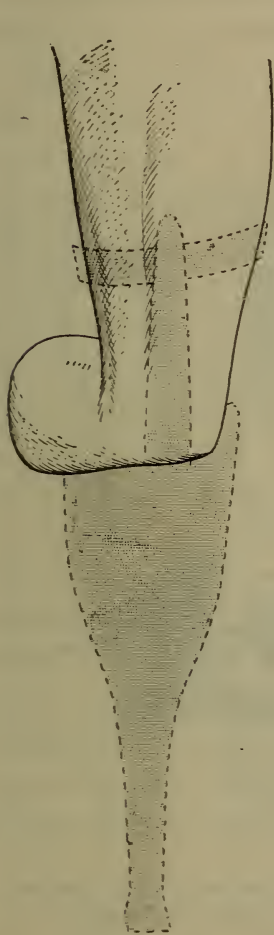


FIG. 627.—Knee flexed for "peg-leg." (Veau.)

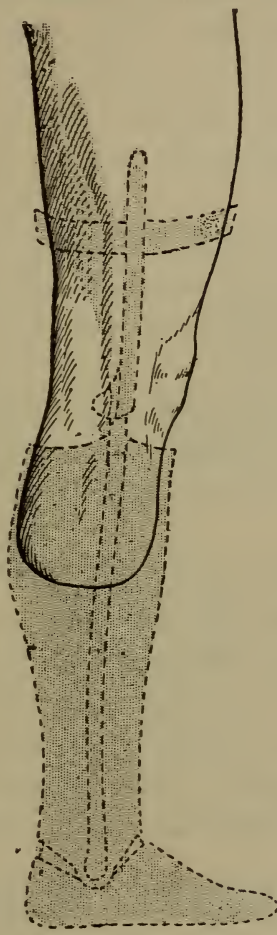


FIG. 628.—Artificial limb applied. (Veau.)

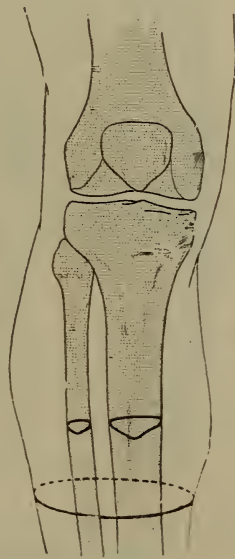


FIG. 629.—Amputation of leg. Lines of section of soft parts and bone. (Veau.)

the muscles may be preserved to render efficient an artificial limb (Fig. 628).

This principle is true only within certain limits. Amputations just above the ankle never furnish a good stump for an artificial limb. It is better to amputate at the junction of the middle and lower thirds.

In the case of traumatism and gangrene, then, do an atypical amputation, preserving carefully the sound tissue and dividing the bone to accommodate the skin flap.

If the bone is involved to a greater extent than the skin, as in tuberculosis, a typical amputation may be done. If the stump below the knee is 4 inches long it can manage an artificial limb.

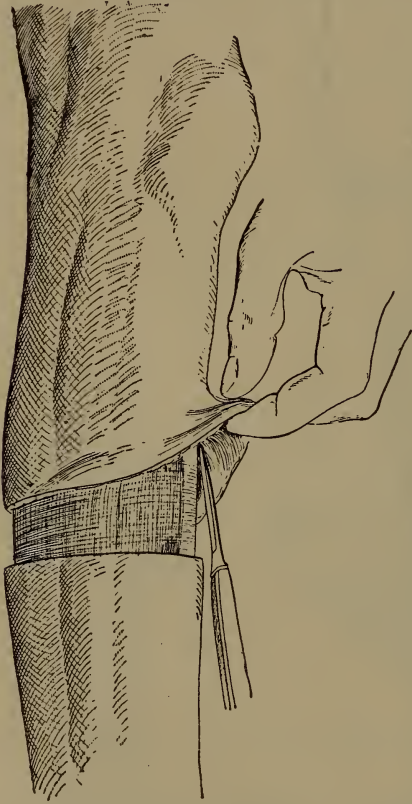


FIG. 633.—Loosening the attachments of the flap to the tibia. (Veau.)

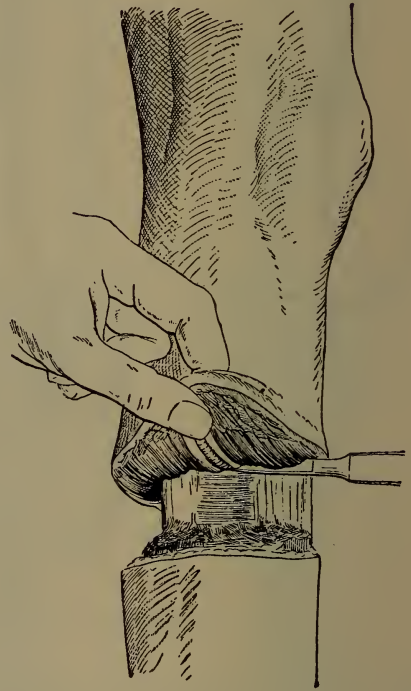


FIG. 634.—Dissecting up the muscles with the artery. (Veau.)

There are numerous methods of amputating the leg, some appropriate to one level and some to another, but for the sake of simplicity but one need be described—one which may be used with fair success in any part of the leg. In any case avoid redundancy of flap if an artificial leg is to be worn.

Incision.—Begin with a circular incision of the skin about $2\frac{1}{2}$ inches below the level of the proposed bone section (Fig. 629). This incision will divide the skin and aponeurosis. If front, carefully

separate the skin from the tibial crest (Fig. 630). Next *divide the muscles* at the level of the retracted skin. Divide the muscles completely, but make the incision oblique to the axis of the limb, so that the incision reaches the bone at a higher level than at the surface (Fig. 631).

To be certain that all the muscles are divided, one may re-pass the bistoury, as in the forearm (Fig. 596). Next denude the bones with the rugine, reaching above the level at which the bones are to be sawed. This denudation is most difficult and tedious behind, on account of the fibrous attachments of various muscles.

The interosseous membrane is to be detached by a few vigorous strokes with the rugine from below upward. Divide it at the level of the proposed bone section.

Retract the flaps with three gauze compresses, one passed between the bones, one applied in front and one behind; all to be held firmly by the assistant.

Begin the sawing by notching the tibia, then completely divide the fibula and end with the section of the tibia. Plane off the projecting angle of the anterior border of the tibia, resect the nerves and ligate the bleeding points. Be sure the fibula is not left longer than the tibia to interfere with an artificial limb. Drain, suture the anterior muscular flap to the posterior, and suture the skin (Fig. 632).

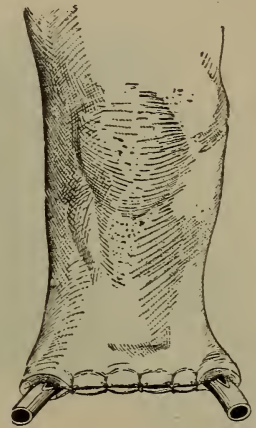


FIG. 635.—Amputation complete. Transverse drainage. (Vean.)

AMPUTATION THROUGH THE KNEE-JOINT

This operation should be done in preference to an amputation of the thigh.

“The femoral artery having been controlled, the limb supported over the edge of the table and slightly flexed, the surgeon standing on the right side of either limb, marks out two broad lateral flaps as follows: his left thumb and index finger being placed, the former over the center of the head of the tibia, the latter at the corresponding point behind, opposite the center of the joint, he marks out (in the

case of the right limb) an inner flap by an incision which commences behind at the index finger and runs down the back of the leg for $3\frac{1}{2}$ inches, and then curves up to the thumb. A similar flap is shaped on the outer side.

"The inner flap must be slightly larger, in view of the large side of the inner condyles.

"The flaps consist of skin and fascia. When they have been raised to the level of the articulation, the ligamentum patellæ is severed,

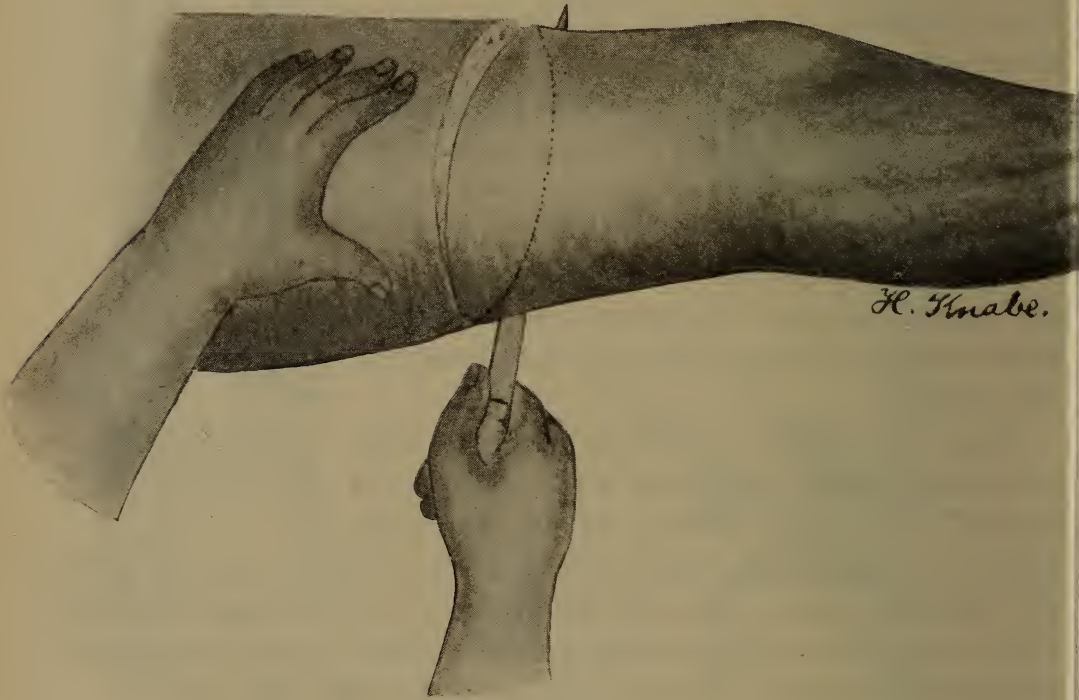


FIG. 633.—Amputation of thigh. Circular incision of the skin.

allowing the patella to go upward. The soft parts around the joint are then cut through with a circular sweep and the leg removed. In doing this, the limb being flexed to relax the parts and facilitate opening the joint, the semicircular cartilages will very likely be found encircling the condyles of the femur and are to be left *in situ* by dividing the coronary ligaments which tie them to the tibia. The condyles should always be saved if possible for they favor the usefulness of an artificial limb. Resect the nerves, ligate the vessels, drain and suture." (Jacobson's Operative Surgery.)

AMPUTATION OF THE THIGH

Determine the level of the bone section. About the distance of one diameter of the limb below this level, describe a *circular incision*, dividing the skin and fascia, which may descend a little further behind than in front, if desired.

The patient's legs are drawn out well over the edge of the table, the sound limb flexed and the injured one held by an assistant. The

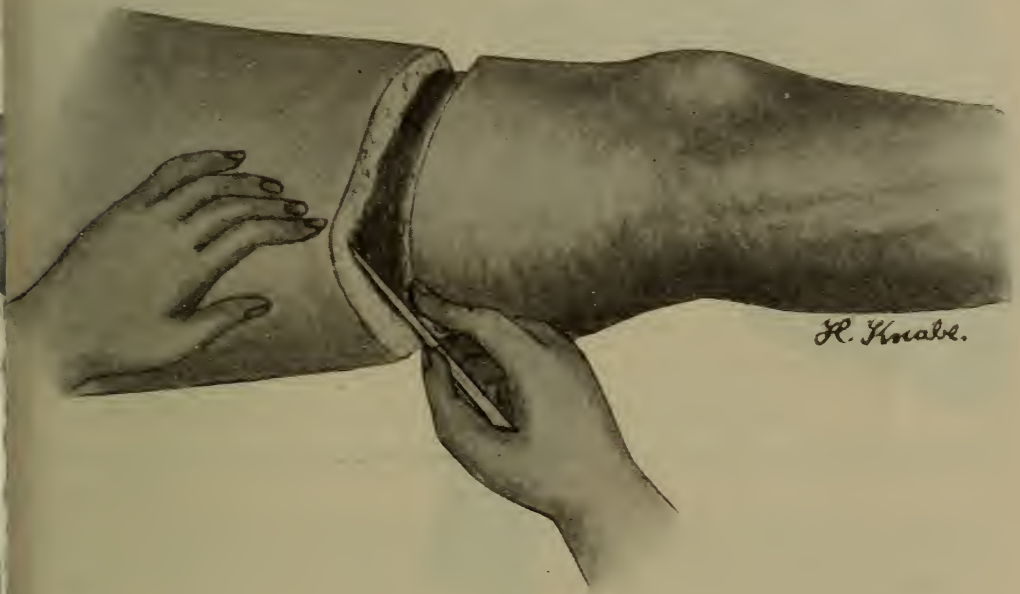

FIG. 634.—Amputation of thigh. Loosening the flap after a circular skin section.

operator stands to the outside. Another assistant encircles the thigh above the level of the incision, with his hands. If the conventional amputating knife is used, begin (on the right thigh) by passing the knife under the limb and with its heel resting upon the upper surface, bring it in a circular sweep back around the thigh, dividing successively the integument of the internal, inferior and external surfaces. The position of the hand may be slightly changed and the incision continued up over the anterior surface; or that may be divided by a second movement (Fig. 633).

In the meantime, the left hand has steadied the skin; the assistant now retracts it while its fibrous attachments are loosened (Fig. 634) until there is a separation of at least three fingers' breadth. At the

level of the retracted skin, divide the muscles as the skin was divided, aiming to reach the bone. But the divided muscles do not equally retract, and a *second circular incision of the muscles* at the level of the retracted skin is necessary to insure a uniform stump (Fig. 638).

Denude the femur beyond the level of the proposed bone section. Direct the assistant to retract the flap with two lateral compresses or retractors.

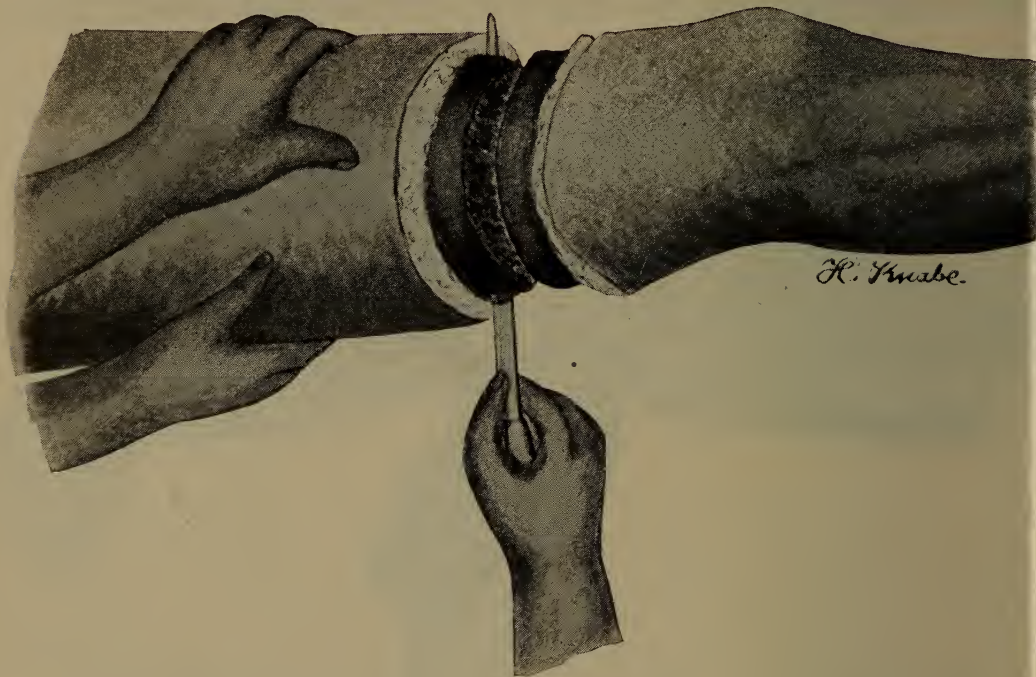


FIG. 635.—Amputation of thigh. Circular section of the muscles after retraction of skin.

Saw the femur, ligate all vessels likely to bleed, suture the muscles over the end of the femur, drain, and suture the skin.

AMPUTATION OF THE HIP-JOINT

“Primary amputation of the hip comes under consideration in any extensive crush of the thigh or gunshot injury, but offers hardly any chance while the primary shock exists.

“The better plan is to try and check the hemorrhage, clean the wound as much as possible, pack with gauze and wait. The patient having rallied from the shock, and gangrene, sloughing and necrosis

being imminent, amputation is indicated with a fair prospect of saving life.* * * The first step is to *control hemorrhage*. * * * But there is one method safe and applicable to all cases and especially when the surgeon is unaccustomed to the operation, and that is to divide the common femoral vein and artery, each between two ligatures. There is then no further bleeding, except from the region of the crucial anastomosis behind, the vessels forming which are easily picked up and divided."

Formation of the Flaps.—"From the lower end of the longitudinal incision for tying the vessels, a circular incision is continued around the thigh, the skin flaps retracted and the soft parts divided as amputation of the thigh." (Walsham's Surgery.)

Senn's Bloodless Amputation at the Hip-joint.—First incision: with the pelvis resting on the lower edge of the table, make a straight incision (beginning about 3 inches above the great trochanter) about 8 inches in length, directly over the center of the great trochanter, and parallel to the long axis of the limb. When the knife reaches the great trochanter, its point should be kept in contact with the bone the whole length of the remaining part of the incision.

The margins of the wound are now retracted and any spurting vessels secured.

The trochanteric muscular attachments are now severed close to the bone with a stout scalpel. The cleaning of the digital fossa and the division of the obturator externus tendon, require special care. The thigh is now flexed, strongly abducted, rotated inward, when the capsular ligament is divided transversely at its upper and posterior aspect. The remaining portion of the capsular ligament is severed, while the thigh is brought back to a position of slight flexion, after which it is rotated outward and, if possible, the ligamentum teres is cut. If this cannot be done, the head of the bone is forcibly dislocated upon the dorsum of the ilium by flexion, adduction and rotation of the thigh.

The trochanter minor and upper part of the shaft of the femur are cleared by using a scalpel and periosteal elevator alternately. At the completion of this part of the operation, the femur is in a position of extreme adduction and the upper portion projects some distance from the wound.

If the surgeon has kept in close contact with the bone and has used the knife sparingly and the periosteal elevator freely, the hemorrhage has been slight.

Elastic constriction is now applied. Bring the limb down in a straight line with the body. A long straight hemostatic forceps is inserted into the wound behind the femur and on a level with the trochanter minor when in a normal position. The instrument is then pushed inward and downward 2 inches below the ramus of the ischium and just behind the adductor muscles. As soon as the point

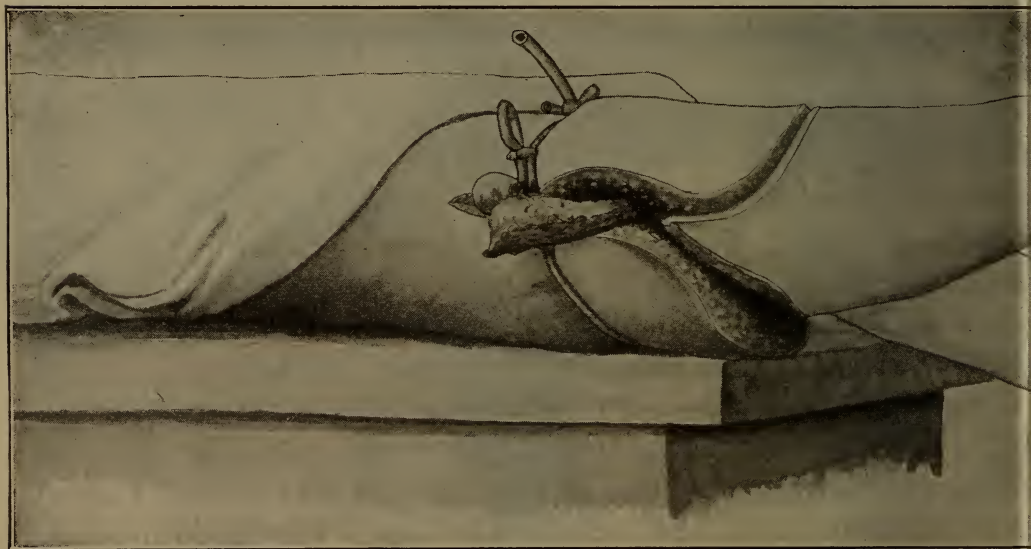


FIG. 636.—Amputation at hip-joint. Elastic constriction completed by constricting the posterior segment of the thigh. Flaps formed, including all the tissues down to the muscles. (Senn.)

can be felt under the skin in this location, 2-inch incision is made through the skin, through which the instrument is made to emerge.

After enlarging the tunnel made in the soft tissues by dilating the branches of the forceps, a piece of aseptic rubber tubing, 3 or 4 feet in length, is grasped in the middle with the forceps and drawn along the tunnel as the forceps are withdrawn, whereupon the rubber tube is cut in two where it was held by the forceps.

With one-half of the tube, the anterior segment of the thigh is constricted sufficiently firmly to intercept both the arterial and venous circulation completely.

Before the constrictor is tied, the limb should be held in the vertical position long enough to render it practically bloodless. The elastic constrictor is either tied or, still better, held with a forceps at the point of crossing.

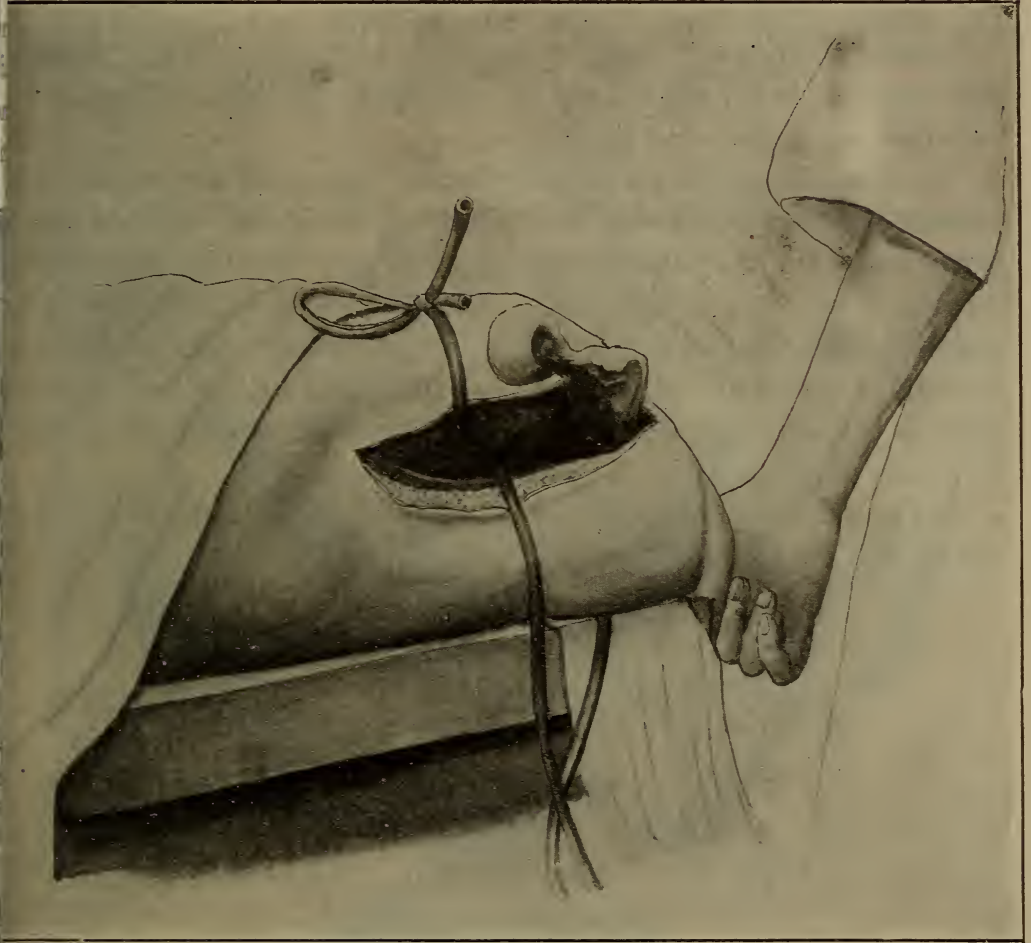


FIG. 637.—Senn's method of performing bloodless amputation at the hip-joint. Dislocation of head of femur and upper portion of shaft through straight external incision. Elastic constrictors in place; the anterior one tied.

The posterior segment of the thigh is constricted by the remaining half of the tube, which is drawn sufficiently tight behind; the ends of the tube are made to cross each other and are brought forward and made to include the anterior segment, when they are again firmly drawn and tied, or otherwise fastened above the first constrictor,

furnishing an additional security against hemorrhage from the larger vessels in the anterior flap, when cut during the amputation (Fig. 636).

After the principal blood vessels have been tied, the posterior constrictor is removed and additional bleeding points are secured before the anterior constrictor is removed (Fig. 637).

Surface compression with a compress wrung out of hot, normal salt solution, is a valuable aid in minimizing the hemorrhage, after the removal of the constrictors.

“As this method of controlling hemorrhage does not require the presence of a skilled assistant, it will prove of especial value in emergency cases. The operation can be performed with the instruments contained in every pocket case. Should an elastic tube not be at hand, the constriction can be made in a satisfactory manner by substituting a cord made of sterile gauze, tightened with a lever of some kind, as is done in applying the ordinary Spanish windlass.” (Senn, Practical Surgery.)

The amputation is completed by cutting antero-posterior flaps as shown in Fig. 636.

CHAPTER XXIII

DILATATION OF THE SPHINCTER ANI; OPERATION FOR PILES; OPERATION FOR FISTULA

DILATATION

Temporary paralysis of the anal sphincter is the preliminary step to most of the interventions on the rectum, and is of itself usually sufficient for the cure of fissures.

The patient should be purged the day preceding the operation

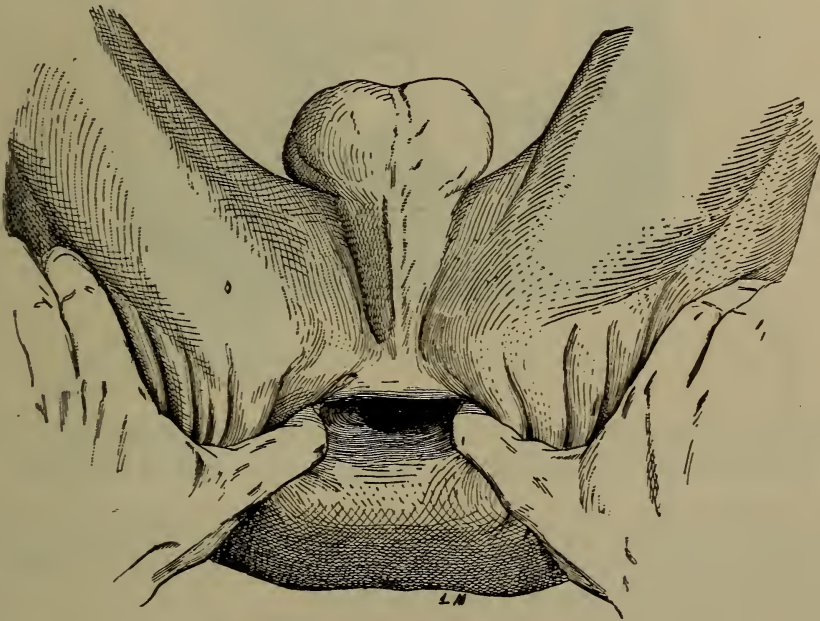


FIG. 638.—Dilatation of the rectum. (Veau.)

and the rectum should be washed out with soap and water, preliminary to the actual operation.

General anesthesia is almost indispensable and it needs to be profound, for the anal reflex is one of the last to yield. Spinal anesthesia is often useful in anal operations.

In the absence of a special dilator, begin by inserting the two thumbs back to back, and bracing the fingers against the outer surface of the hips, stretching the sphincter by rhythmic movements of the thumbs, gradually increasing the force. There is no danger of overdilatation, so continue until the thumbs are in contact with the ischial tuberosities (Fig. 638). Drainage is indicated in simple dilatation for fissure.

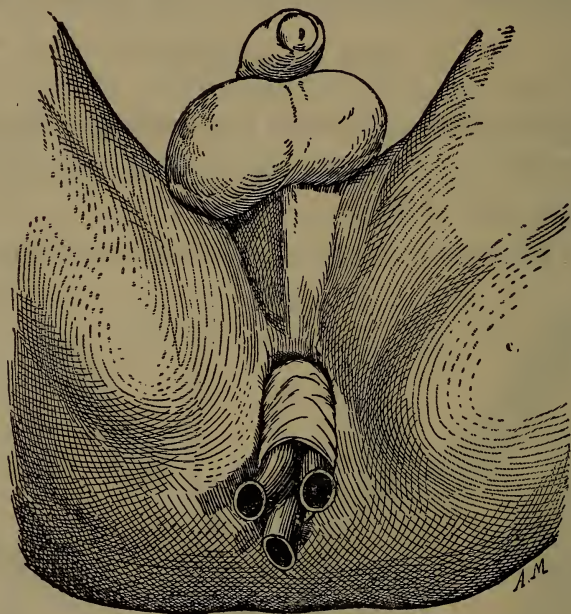

FIG. 639.—Drainage after dilatation. (*Veau.*)

Employ either one large or two or three small tubes well wrapped with iodoform gauze soaked in cocainized vaseline (vaseline thirty parts, cocaine one part), in order that the subsequent pain may not be so severe (Fig. 639). The tubes may be removed on the second day and the bowels moved on the third.

OPERATION FOR HEMORRHOIDS

Most cases of piles are curable by local and constitutional treatment; however, those that are very large, bleeding and inflamed, require an operation for their removal and radical cure.

There are several methods of procedure, many of which are

successful, none dangerous and quite within the scope of every practitioner.

The following may be recommended in those cases in which the marginal tumors are well defined but not pedunculated:

Begin by a careful cleansing of the bowel by purgation and lavage. Three days before the operation, give a free purge and prescribe a liquid diet. Prescribe an enema each morning and evening for the next two days. On the day preceding the operation, it is a good idea to check peristalsis with a small dose of opium.

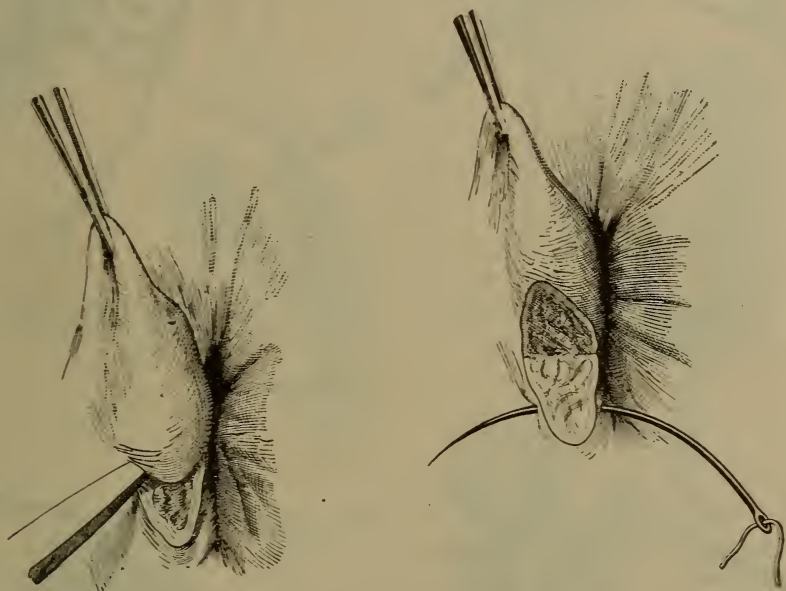


FIG. 640.—Making the first incision. (Veau.) FIG. 641.—Passing the first suture. (Veau.)

Employ general anesthesia. Carefully cleanse the peri-anal region and scrub the rectum with soap and water. Dilate the anus, as previously described; and when the dilatation is complete the anal orifice will be everted more or less, presenting a ring of pile tumors. Fasten the pile tumor with a forceps, and at its lower end, make a short curved incision (Fig. 640). The incision involves only the skin, which is to be loosened from the underlying structures by a little blunt dissection. Suture this part of the skin before proceeding further, using a small curved needle armed with a No. 2 catgut. Tie the suture moderately tight and leave the threads long for a

landmark, which will be appreciated later on. Pass two or three sutures in this manner, depending upon the length of the incision (Fig. 641).

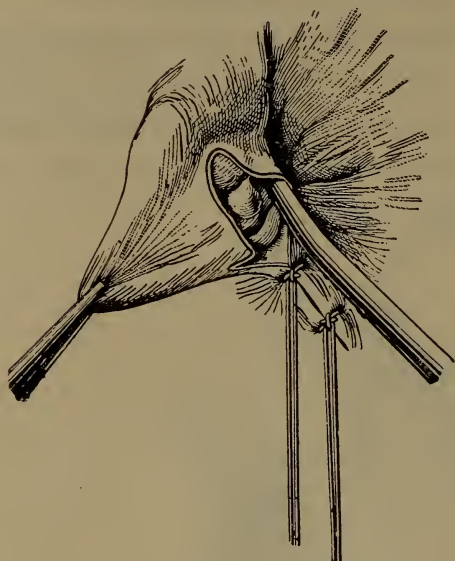


FIG. 642.—Freeing the veins by blunt dissection. (Veau.)

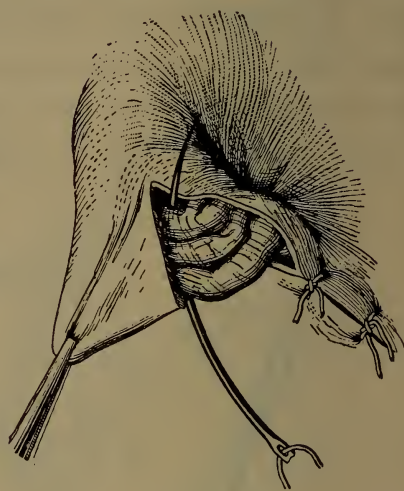


FIG. 643.—Ligation of the first vascular pedicle. (Veau.)

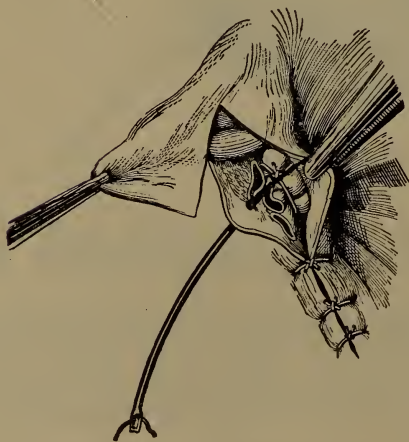


FIG. 644.—Burying the pedicle by suture. (Veau.)

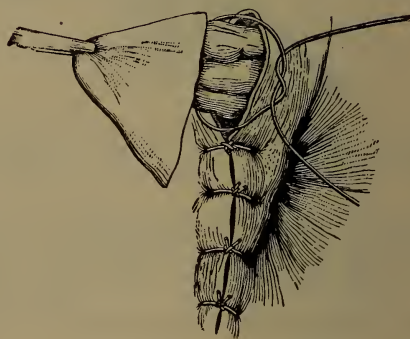


FIG. 645.—Ligation of the last vascular pedicle. (Veau.)

Again prolong the incision on either side a little way and detach, by blunt dissection, the lips of the wound from the veins beneath, by which means a sort of pedicle is formed (Fig. 642). This pedicle consists of a part of the veins which are to be ligated and excised.

Pass a ligature around a part of the veins (Fig. 643) and tie. Divide the ligated veins to the outer side and cut the ligatures short.

Now pass a suture so as to enclose and cover in the stump (Fig. 644).

Again prolong the original incision on each side of the base of the tumor and expose more of the pedicle; ligate, excise and suture as before, until finally the upper pole of the tumor is reached, and the last of the pedicle tied off (Fig. 645).

The terminal sutures enclose the last stump of the pedicle and complete the repair of the incision at the same time (Fig. 649).

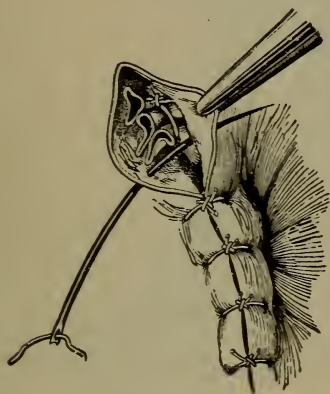


FIG. 646.—Applying the last suture. (Veau.)

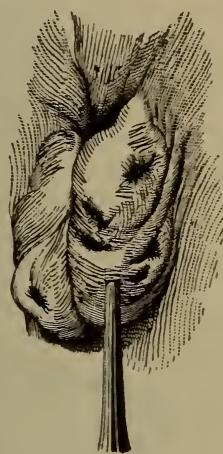


FIG. 647.—Treatment of ulcerated piles by cauterity. (Veau.)

It is better to proceed thus from below upward in order that the blood, always considerable, will flow downward and mask only the field already sutured.

The line of incision must follow closely the base of the tumor, for if the edges of the wound are too widely separated, the strain may cause the sutures to tear out.

If the whole of the anal circumference is involved, it is necessary to treat in the manner described the two sides only.

Do not disturb the anterior and posterior poles of the anal border, although, if necessary, those points may be touched up with the thermo-cautery.

Place drainage-tubes wrapped with iodoform gauze saturated in vaseline, as described under the head of Dilatation of the Sphincter.

The subsequent pain is always severe and will require a hypodermic injection of morphine. Retention of urine is often present. The external dressings should be changed daily and liquid diet maintained for five or six days and the bowels kept under restraint. Do not be concerned with the swelling.

On the sixth day, remove the drainage-tube; on the seventh, open the bowels with castor oil or compound licorice powder, one heaping




FIG. 648.—Laying open the track of fistula on the grooved director. (Veau.)

teaspoonful every four hours till the bowels move, and instruct the patient to cleanse carefully the anal region after each movement.

The sutures will be absorbed and if none give way too soon, the healing will be complete in about two weeks; otherwise there may be a raw surface which will need to be dressed a little longer.

In certain cases there is no well-defined tumor, but the surface is *ulcerated*, infected and exceedingly painful, and is unaffected by patient local treatment.

In such a case, the thermo-cautery will probably give the best results. For one or two days the patient is kept in bed and a moist dressing applied which will diminish the swelling.

Employ general anesthesia, cleanse and dilate the anus. The

thermo-cautery is heated to a dull red. Pressed into the tumor, it loses its glow (Fig. 647). Reheat it and reapply a short distance from the point of application, and in this manner proceed until the pile has been well punctured. It is not necessary to puncture deeply. Apply drainage and a moist dressing. The subsequent pain is always severe and must be controlled by a hypodermic of morphine. There may be retention of urine requiring relief by catheterization.

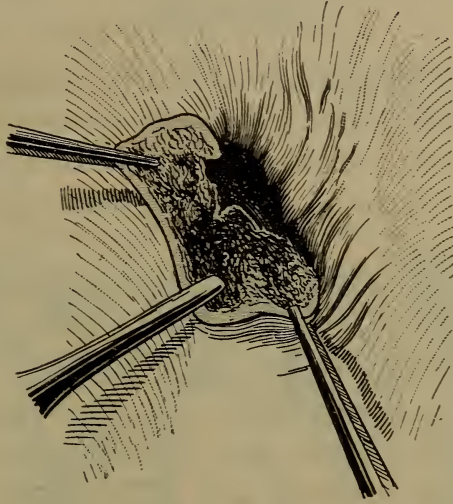


FIG. 649.—Cauterization of the diverticula of the fistula. (Veau.)

The dressing must be renewed twice daily. The eschar will drop off between the fourth and eighth day, and the bowels should be moved about the eighth day. The cure will be complete in about a month.

OPERATION FOR ANAL FISTULA

A grooved director is passed through the fistulous tract and emerging in the rectum, its point is caught by the finger in the rectum and brought outside the anus. The whole length of the tract is laid open (Fig. 648).

The diseased tissues are then curetted or touched with the cautery (Fig. 649). Pack with gauze until repair by granulation is complete.

CHAPTER XXIV

PHIMOSIS; PARAPHIMOSIS; CIRCUMCISION; HYDROCELE; CASTRATION

PHIMOSIS

Phimosis may be congenital or acquired, though it is much more frequently the former. There is usually present one or both of two conditions: a redundant prepuce with contracted orifice; or a frenum so short as not to permit retraction without marked bowing of the organ.

The disturbances produced by congenital phimosis are due either to mechanical interference or reflex irritability, although, of course, many cases of phimosis seem to give rise to the symptoms. The mechanical interference may lead to infection, balanitis, or even urethritis, or to straining which may be the origin of an inguinal or umbilical hernia; the straining may also produce prolapsus ani or hydrocele by pressure on the spermatic vessels.

The reflex symptoms, often due perhaps to the adhesions of the prepuce to the glans, are numerous and varied, the most common being disturbances of micturition, erethrism, and functional nervous derangements.

Every case of phimosis, therefore, should receive attention in infancy, and in general the only treatment worth while is circumcision.

The acquired phimosis of adult life, most often due to acute infective inflammations, is usually to be relieved by antiseptic washes and treatment addressed to the septic cause.

PARAPHIMOSIS

Paraphimosis has its origin in certain malformations, traumatism, or inflammations, and appears in many degrees of severity. In some causes it is easily reduced; in others, irreducible without an operation. There is always the danger, in severe and neglected cases, of ulcera-

tion, sloughing, or gangrene. The appearances are more or less constant: the exposed glans is swollen and reddened; behind it is a collar of congested mucous membrane; behind this a deep furrow in which lies the constricting band; and behind this, another band of swollen integument.

An effort must be made at once to reduce the foreskin. The reduction is always painful. Begin by thoroughly cleansing and cocainizing the parts. Apply a compress saturated with a 20 per cent. solution of cocaine and then wait ten minutes.

Smear a little vaseline on the balano-preputial furrow, but not over the glans generally, else the manipulating fingers will slip.

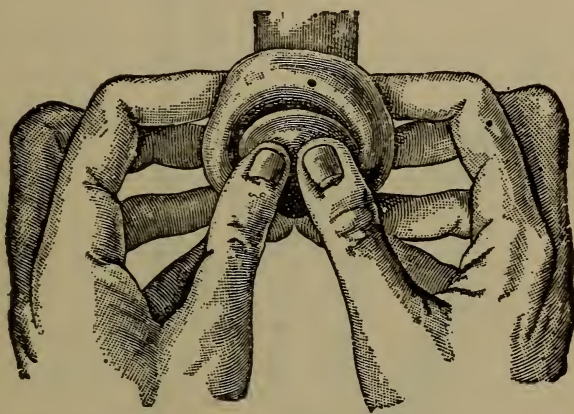


FIG. 650.—Reducing a paraphimosis. (Stewart.)

The purpose is to apply a slow, firm, and progressive pressure to the engorged tissues, at the same time making traction forward on the foreskin and pressure backward on the glans.

There are several ways of doing this, of which the following is an excellent method: grasp the penis behind the glans, between the first and second fingers of each hand, and while these make compression and traction, the two thumbs are braced against the apex of the glans (Fig. 650).

After reduction is accomplished, measures must be employed to subdue the inflammation and the patient advised of the necessity for a circumcision later to insure against a recurrence.

If reduction cannot be accomplished by these measures, an operation must be done without delay. The purpose is to divide the restricting band, which lies in the groove between the two ridges.

Inject a little cocaine along the line of incision which is usually in the middle line of the dorsum and just behind the corona (Fig. 571).

Use the point of the knife, making short, firm, shallow cuts, until the constricting band is felt to yield. A too bold incision may result in seriously wounding the corpora cavernosa.

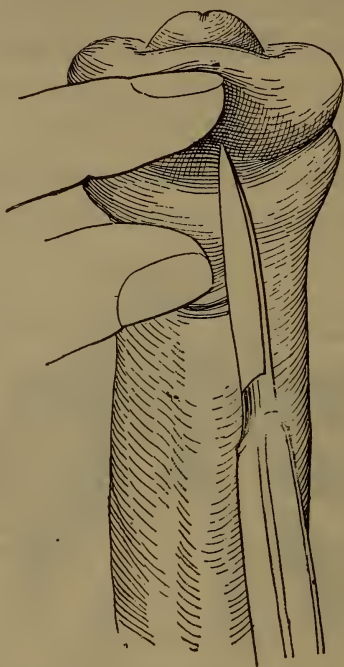


FIG. 651.—Dividing the constricting band in paraphimosis. (Veau.)

The bleeding in any event will usually be free but ceases spontaneously. The wound which at first was vertical, becomes transverse when reduction is completed, and is sutured in that direction.

Apply a moist dressing and if there is no ulceration or gangrene, the swelling will soon subside. But in this case also the patient must be advised of the danger of recurrence unless a circumcision is done for the relief of the narrowed prepuce or the short frenum after the inflammation has subsided.

CIRCUMCISION

This is an excellent operation probably not often enough done in infancy, when it is simple and without danger, and may *prevent* the disturbances of adolescence, consequent upon phimosis.

In adult life it is often the primary step toward the relief of acute disorders and sexual irregularities.

The Operation.—General anesthesia is nearly always indicated in children; local, in adults. To secure local anesthesia, begin by lightly tamponing the preputial orifice with a pledget of cotton saturated with a 10 per cent. solution of cocaine, and left in position for at least five minutes. Next inject the foreskin in the line of the proposed incision, using a 4 per cent. solution of cocaine or Schleich's solution. The too rapid absorption of cocaine may be prevented by constriction of the base of the penis.

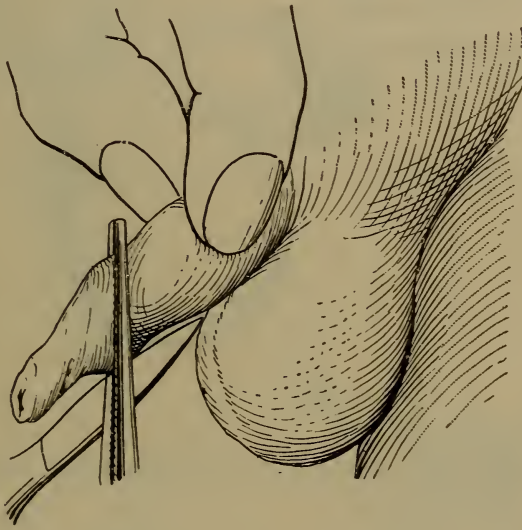


FIG. 652.—Resection of the prepuce. (Veau.)

When the anesthesia is established, break up the preputial adhesions with a grooved director or probe, usually not difficult in an infant but sometimes difficult in the adult, following balanitis.

There are various methods of making the *incision*, any of which, properly employed, will give good results. Suppose the prepuce is long and slender: begin by holding the penis vertically and *without making traction on the foreskin*, apply a forceps so that its blades lie parallel with the oblique line of the corona (Fig. 652). Use care, of course, not to pinch the glans. Divide the foreskin with the bistoury, allowing the blade to hug the upper side of the forceps, that no bruised tissues may be left behind. The skin retracts, leaving the

mucosa covering the glans. Divide this mucous covering along the middle line to within $\frac{1}{5}$ inch of the coronal border (Fig. 653). The glans will now be completely exposed.

Trim off the two mucous flaps so that a narrow cuff is left. It is better to begin near the frenum and trim toward the terminal point of the dorsal incision (Fig. 654). If the frenum is too short, divide it transversely with the scissors (Fig. 655), catching up the little artery which will be divided. This completes the necessary incisions.

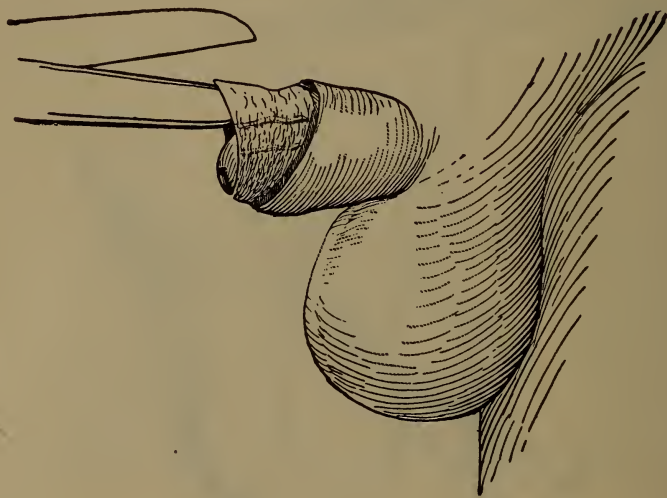


FIG. 653.—Splitting the mucous membrane. (Veau.)

Hemostasis must be assured. It may be necessary to tie two or three small vessels and nearly always the artery of the frenum requires ligation, using catgut No. 1.

A brief application of adrenalin solution on a compress will check the oozing if it should persist.

Suture. The mucous and cutaneous borders are brought into exact contact and united by several small, interrupted sutures of catgut (Fig. 656). The transverse incision of the frenum is made a vertical one by extending the glans, and is sutured in that direction (Fig. 657).

In the case of children, it may be sufficient, instead of suturing, to use small clips, by which means, it is claimed, swelling is avoided.

Dressing.—Wrap the penis in a sterile compress, leaving the glans

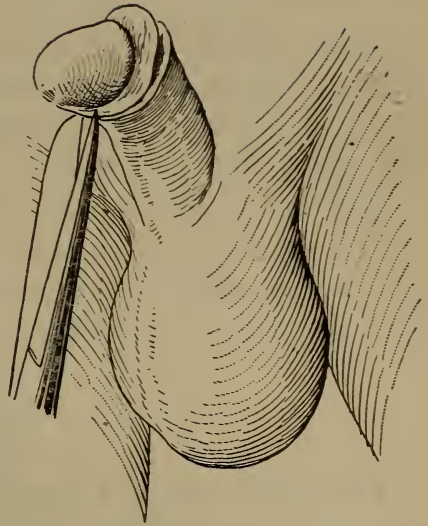
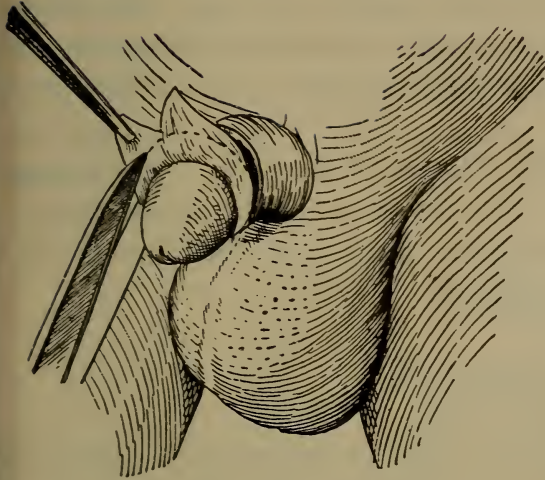


FIG. 654.—Resection of the mucous membrane. (Veau.)

FIG. 655.—Section of the frenum. (Veau.)

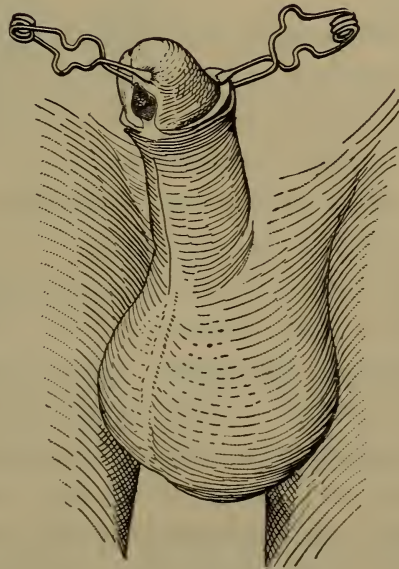
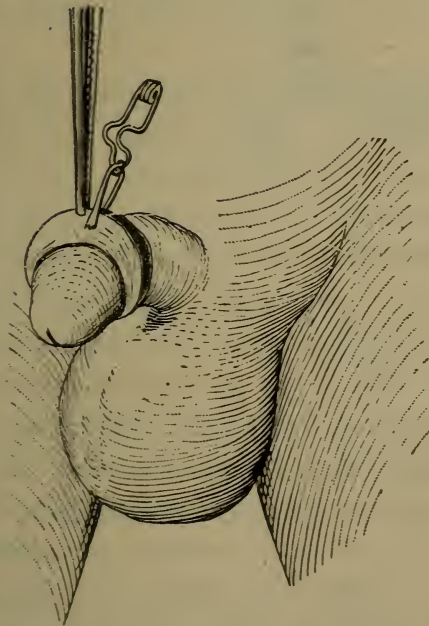


FIG. 656.—Maintaining coaptation by means of a small clip. (Veau.)

FIG. 657.—After section of the frenum the raw edges are coapted. (Veau.)

exposed. Enclose the whole in a second compress perforated over the meatus, and secure with adhesive strips.

Adults require bromides to prevent painful erections. The dressings are not to be changed unless soiled. Remove the sutures and re-dress the fifth day. It will probably require ten to twelve days for repair to be complete.

Children usually need a daily change of dressing. If clips are used instead of sutures, they are to be removed at the end of twenty-four hours, and if the adjustment was perfect, the reunion by that time will often be practically complete.

HYDROCELE

The chief test of a hydrocele is its "translucency." The first treatment usually tried is tapping and the injection of an alterative. If the hydrocele recurs, then a radical operation should be done. Often this should be resorted to from the first without preliminary tapping, especially in the long-standing cases, where the tunica vaginalis is thickened and it is almost obvious that the trouble will recur.

Occasionally the patient will prefer repeated simple puncture and evacuation without subsequent injection, rather than the more radical procedures which will lay him up for some days.

Tapping.—Anesthesia is not necessary. Prepare the field as for a surgical operation. Seize the tumor behind with the left hand so as to make it tense in front. The trocar, held in the right hand with index finger an inch from the point to limit its penetration, is entered with a sharp thrust into the middle and lower part of the anterior surface of the tumor (previously assure yourself that the testicle is not inverted). Withdraw the plunger, being careful that the tube is not displaced. When the fluid is evacuated, attach a syringe to the trocar and inject a drachm of a $\frac{1}{2}$ per cent. solution of cocaine; gently massage the scrotum so as to bring the solution in contact with the whole testicle, wait ten minutes and then let the solution flow out.

In the meantime charge the syringe with a drachm of pure tincture

of iodine and inject. Hold it for five minutes and then let it escape. Withdraw the trocar and seal the puncture with collodion.

The next day the scrotal wall is painful, reddened and swollen. The scrotum must be well supported, and moist compresses may give some relief. The patient should be kept in bed for ten days and warned that several weeks may be required for absorption of the exudates.

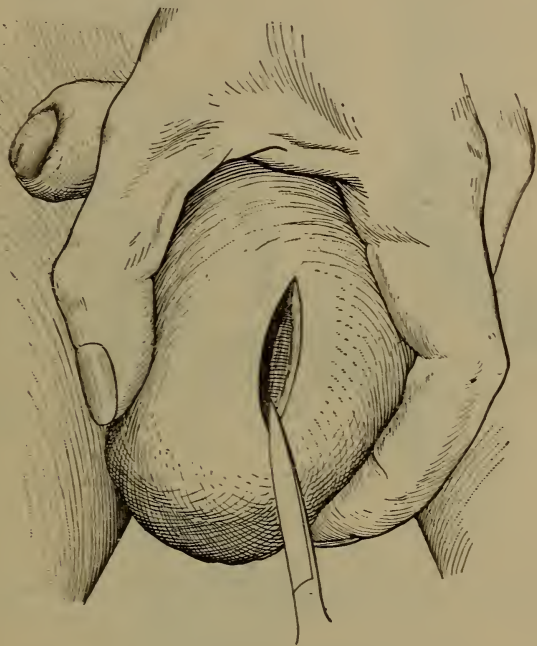


FIG. 658.—Incision for hydrocele. (*Veau.*)

RADICAL OPERATION

Sterilize the penis, scrotum, and perineum. Wrap the penis in a sterile compress and have it held out of the way.

Local anesthesia may be employed, but a general anesthesia is better.

Make an incision 2 inches long over the middle of the tumor, dividing first the several layers over the tunica (Fig. 658). Then open the tunica the whole length of the wound and evert the testicle. The tunica is stitched to the cord above and its free borders, brought together behind the epididymis, are to be sutured to each other

(Fig. 659). Or, the membrane may be resected completely, following close to the epididymis, and if the cut edges bleed, they are to be sewed with a continuous suture (Fig. 660).

Restore the testicle, insert a small drain, and suture the scrotum. The drain should be removed on the second day and the sutures on the sixth, and in a day or two longer, the patient may get up.

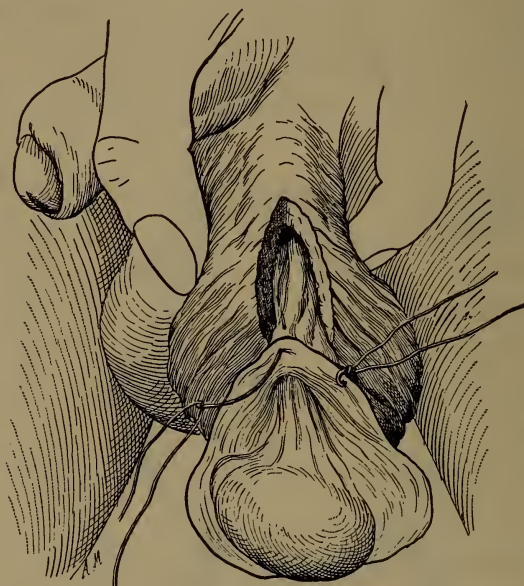


FIG. 659.—Everting the tunica vaginalis. (Veau.)

CASTRATION

The removal of the testicle is more frequently indicated as the result of cancer or tuberculosis, and may be done under either local or general anesthesia.

The *incision* begins just below the external ring (on the right) and follows the direction of the cord for from $1\frac{1}{2}$ to 2 inches (Fig. 661).

Expose and isolate the cord up to the inguinal canal which, if involved, should be opened, as in the operation for hernia. Separate the different elements of the cord, so as to require two or three separate ligatures. Do not include the cremaster in the ligatures (Fig. 662). Just below the catgut ligatures, resect the cord and enucleate the testicle from above downward (Fig. 663).

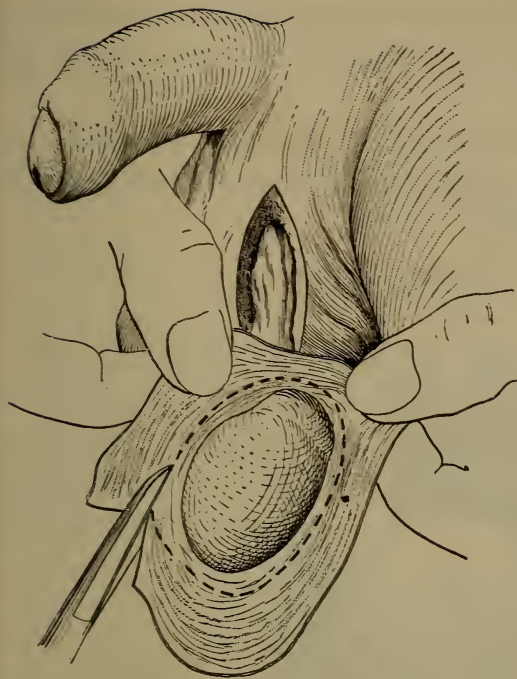


FIG. 660.—Hydrocele. Resection of the tunica vaginalis. (Veau.)

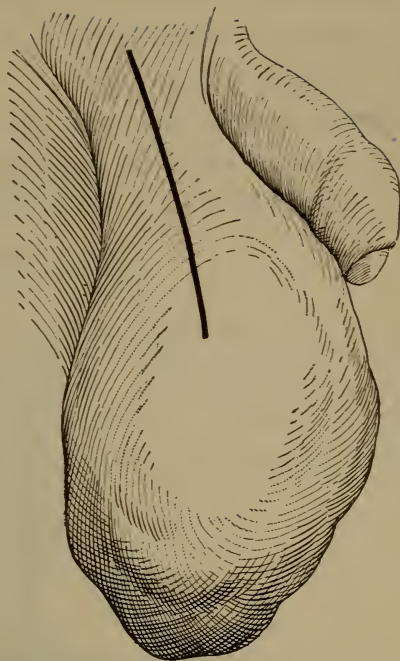


FIG. 661.—Incision for castration. (Veau.)

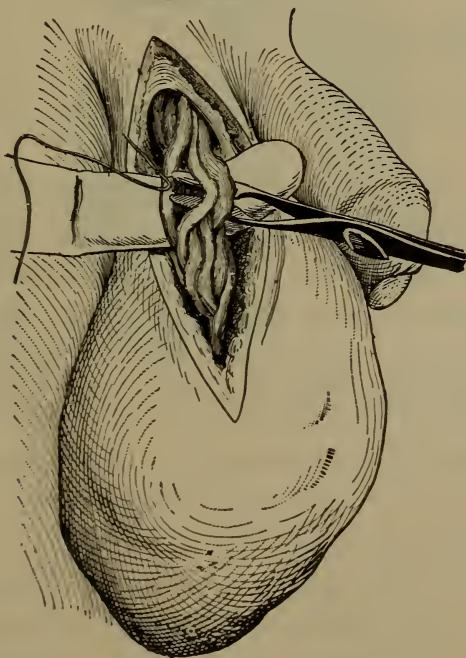


FIG. 662.—Ligation of the spermatic cord. (Veau.)

This step is usually tedious in the tubercular cases on account of the adhesions which may have to be divided with the bistoury, and the bleeding points tied.

Again inspect the cord (you have left the ligatures long till now) to be sure there is no bleeding; and it is recommended to cauterize the end of the vas in tuberculosis.

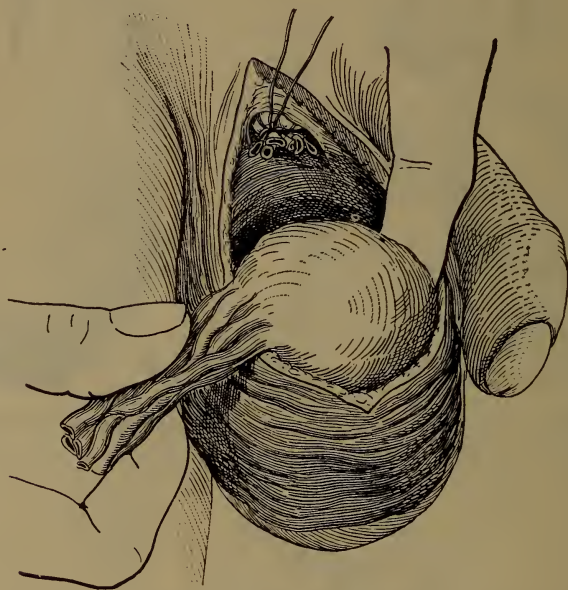

FIG. 663.—Separating the testicle from the scrotal tissues. (Veau.)

Repair first the inguinal canal, if it was opened. Insert a drainage-tube reaching to the bottom of the scrotum and projecting from the upper angle of the wound which is the point least likely to get infected after the dressings are applied. The tubercular cases especially require drainage. Suture and apply a dry dressing. Remove the tube on the third and the sutures on the sixth or seventh.

CHAPTER XXV

INGROWING TOE-NAIL

The particular point in this operation is to obliterate the matrix corresponding to the part of the nail removed. It is insufficient to remove only that part of the nail gouging the flesh. Usually one side only is involved, the outer side, and the removal of half the nail will effect a cure.

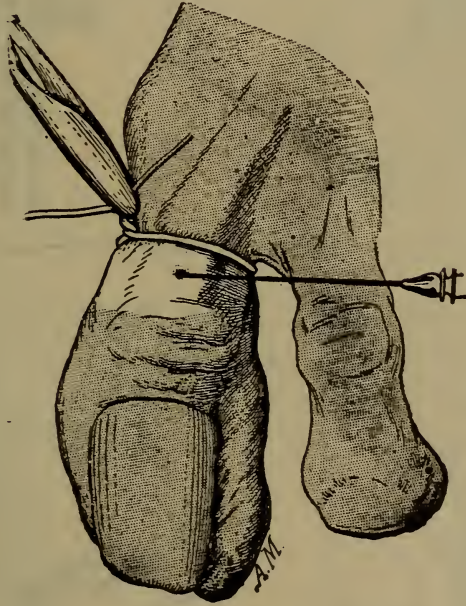


FIG. 664.—Local anesthesia. (Veau.)

Employ local anesthesia. Constrict the base and make a circular injection of cocaine or stovaine (Fig. 664).

Remove the Nail. Introduce the sharp point of the scissors under the nail and divide its entire length (Fig. 665). Next seize the diseased portion with a forceps and tear it out (Fig. 666).

Extirpate the Matrix. Incise the integument of the matrix to be eliminated, with a sharp-pointed bistoury, holding the cutting point

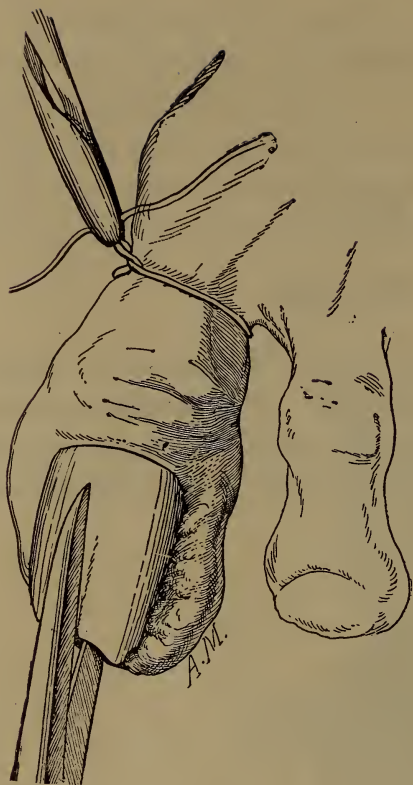

FIG. 665.—Splitting the nail. (Veau.)

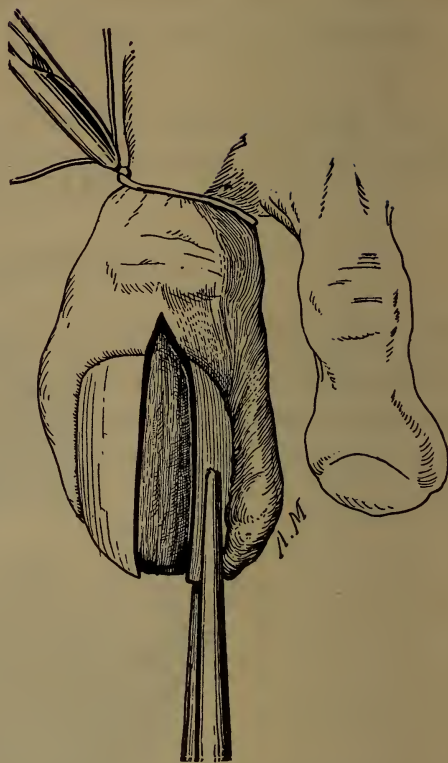


FIG. 666.—Wrenching the nail out. (Veau.)

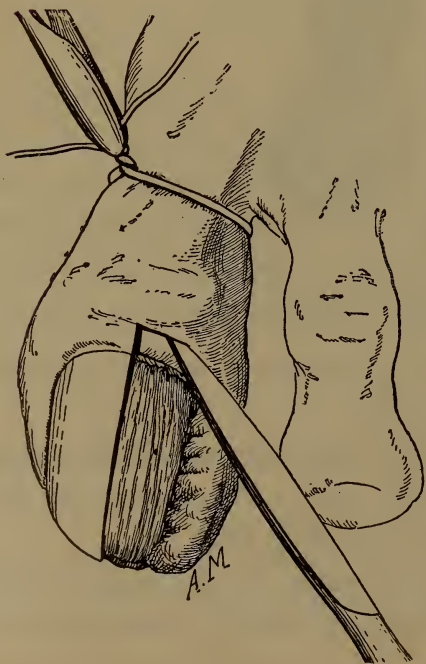


FIG. 667.—Incision over the matrix. (Veau.)

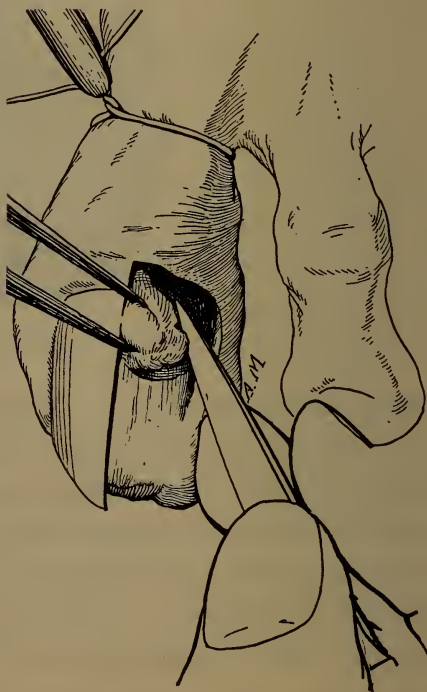


FIG. 668.—Extirpation of matrix. (Veau.)

obliquely, so that it gets a larger bite deeply than superficially (Fig. 667). The soft parts are thus removed down to the bone (Fig. 668). A deep cavity is left in the bottom, of which the bone may be seen (Fig. 669). This cavity should be packed with sterile gauze and

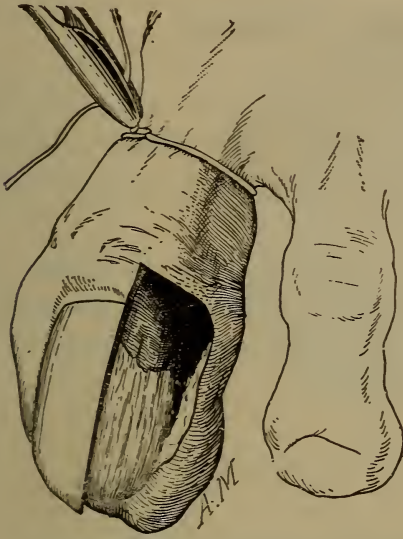


FIG. 669.—The matrix removed. (*Veau.*)

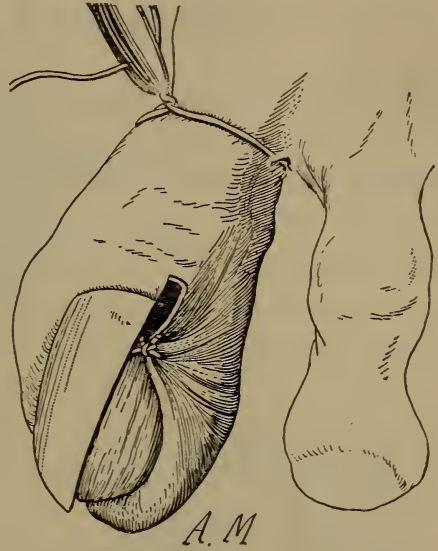


FIG. 670.—Wound sutured. (*Veau.*)

allowed to heal by granulation, which will require two or three weeks. It is advisable to diminish the size of the cavity by a suture, including on one side the skin, and on the other, the subungual tissues (Fig. 670). It will probably give way finally, yet it facilitates repair.

CHAPTER XXVI

REMOVAL OF SMALL TUMORS

The technic for the removal of small tumors on or under the skin should be kept in mind. As in more difficult operations, a definite procedure should be followed. A lack of system may make a minor matter one of difficulty.

Local anesthesia will usually suffice. It should be complete. To secure a complete local anesthesia, begin by determining the lines of incision, and along these lines inject a 2 per cent. solution of co-



FIG. 671.—Anesthesia of the skin.
(Veau.)

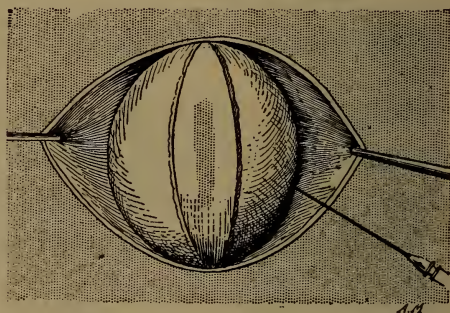


FIG. 672.—Anesthesia of the deeper layers.
(Veau.)

caine; intradermic, not subcutaneous. If the tumor is large or if the skin is loose, redundancy may be avoided by making two semicircular incisions, thus removing an ellipse of the skin (Fig. 671).

Next loosen the edges of the skin and partially expose the tumor and make a new injection along its sides. Later inject the base of the tumor as the dissection proceeds (Fig. 672).

In the case of *sebaceous cysts*, the main point is to remove the sac in its entirety; anything else insures a return of the trouble. If possible,

dissect the sac out without emptying its contents. The dissection will be done with ease only in case all the layers are incised down to the true capsule. If the cyst walls are particularly thick, the contents may be emptied out from the first.

Once the cyst is exposed retract one lip of the skin wound and

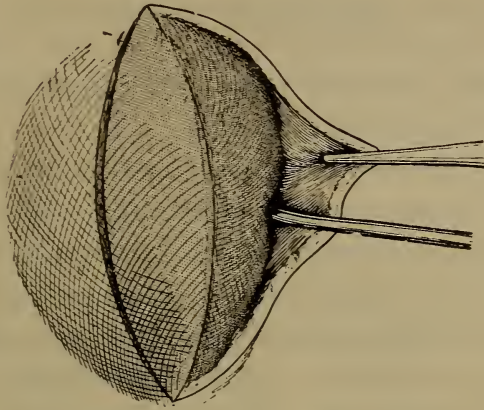


FIG. 673.—Detaching the capsule. (Veau.)

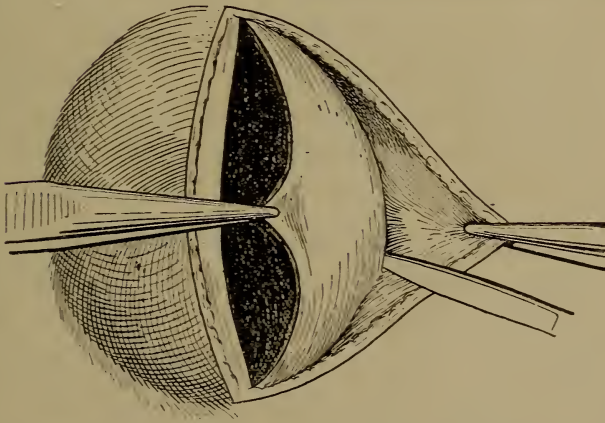


FIG. 674.—Dissecting a loose capsule with the bistoury. (Veau.)

loosen the attachments by blunt dissection (Fig. 673). Or if the fibrous attachments are loose and tough, divide them with scissors or scalpel (Fig. 674).

There will be some slight hemorrhage from the cavity following the removal of the cyst, but it will be easily controlled by pressure or by a hot compress. In case the cyst was emptied in the course of the

operation, be assured that all the cyst wall is removed, or the growth will recur.

The procedure is the same in the case of a *fatty tumor* unless it is pedunculated; if so, make a curved incision on each side of its base. Usually a small blood vessel at the base of the tumor will require ligation.

Synovial cysts require special attention to asepsis or the cavity with which they are connected, and from which they originate, may become infected; thus an arthritis or teno-synovitis might develop. The pedicle requires careful ligation.

Branchial cysts are often intimately connected with the vessels in the neck and their dissection may be extremely difficult. The pedicle of such cysts usually terminates in the thyro-glossal duct.

Angiomas are likely to give rise to dangerous hemorrhage. Only such as are small and well defined should be undertaken by the practitioner. No effort should be made to enucleate; instead elliptical incisions should be made quite beyond the borders of the tumor and the whole removed "*en masse*." Usually a well-defined vascular pedicle will require careful ligation.

CHAPTER XXVII

SKIN GRAFTING

Skin grafting is a measure deserving to be more generally employed by the practitioner. Very often it would save time and trouble in the treatment of those conditions in which epidermitization is long delayed, for this it hastens and also it tends to prevent the formation of scar tissue. Thus chronic ulcers, burns, and lacerated wounds followed by extensive sloughs may require grafting.

The operation is simple in theory yet attended by many failures through lack of attention to detail.

Three factors require the minutest supervision: (1) the field must be properly prepared; (2) the grafts must be cut correctly; (3) the after-treatment must be appropriate.

(1) The area to be grafted must be sterile and must be free of any oozing. If an ulcer is to be treated, the granulations must previously be made as healthy as possible: if sluggish, by currettement; if exuberant, by touching up with nitrate of silver. A few days afterward it will be ready to receive the graft. A dry sterile dressing should be applied a day previous to the operation; before the graft is applied, the surface should be thoroughly douched with normal salt solution.

(2) The skin which is to furnish the graft should be shaved and thoroughly scrubbed with soap and water. Antiseptics had better be avoided for they may compromise the vitality of the cellular elements. A sufficient anesthesia may be obtained by injection of Schleich's solution No. 3.

Two methods of cutting the grafts are currently employed, Reverdin's and Thiersch's.

(I) *Reverdin's Method*.—A small fold of the skin is picked up with fine tissue or mouse-toothed forceps and cut off at its base with small pointed scissors (Fig. 675). This section includes practically all the layers of the skin (Fig. 676). The graft is applied and gently pressed

out. Fifteen or twenty points are thus placed about 15 mm. or say $\frac{1}{2}$ inch apart. If the surface is large enough to require more, the center should be left bare and treated by a second operation (Fig. 677).

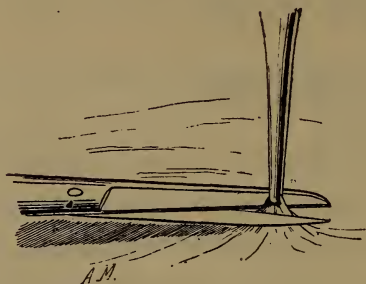


FIG. 675.—Manner of cutting the Reverdin graft. (Veau.)



FIG. 676.—The graft removed. (Veau.)

(II) *Thiersch's Method*.—This method is the better when it succeeds, but the conditions of success are more exacting. Granulation tissue usually needs to be removed by currettement, exposing the

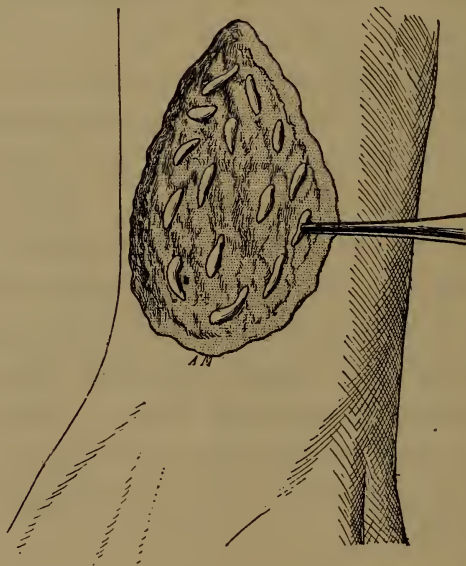


FIG. 677.—Placing Reverdin grafts. Ulcer of leg. (Veau.)

fibrous layer. The edges of the ulcer must be scraped (Fig. 678). The oozing which follows must be completely checked. A firm compress applied for ten or fifteen minutes will usually suffice. If oozing persists, the operation will fail.

The grafts in this case consist of thin slices of the epidermis, as long as necessary and as wide as convenient. They are usually taken

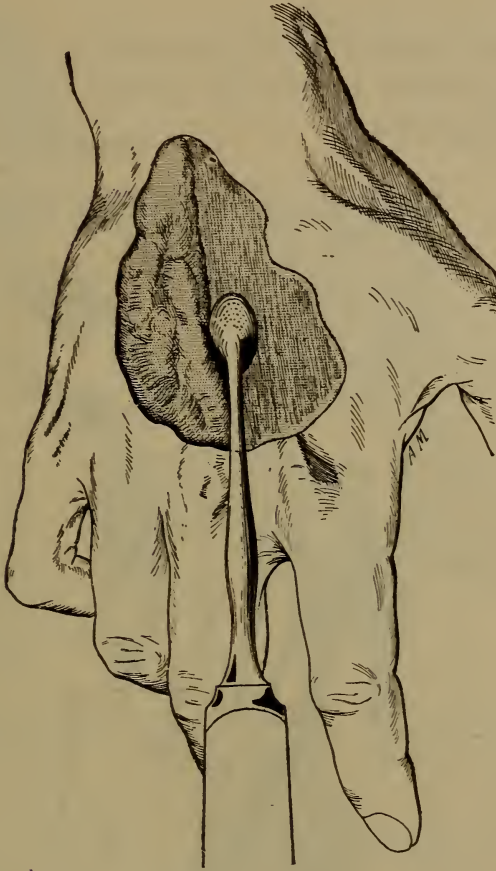


FIG. 678.—Thiersch's method. Preparing the wound for the graft. (*Veau.*)

from the anterior surface of the thigh. A sharp, thin-bladed razor is used in cutting the slice (Fig. 679).



FIG. 679.—Cutting the Thiersch graft. (*Veau.*)

The skin must be put on the stretch. Special retractors are occasionally employed. The two hands of the assistant and the left hand

of the operator can make it sufficiently tense (Fig. 680). The razor is held nearly horizontally and cuts by a rapid, short, sawing motion. As the razor progresses, the thin and pliable tissue piles up on the blade.

The graft is now applied to the raw surface and the free end fixed by a pointed instrument and slowly worked off the blade, and then teased out flat (Fig. 681).

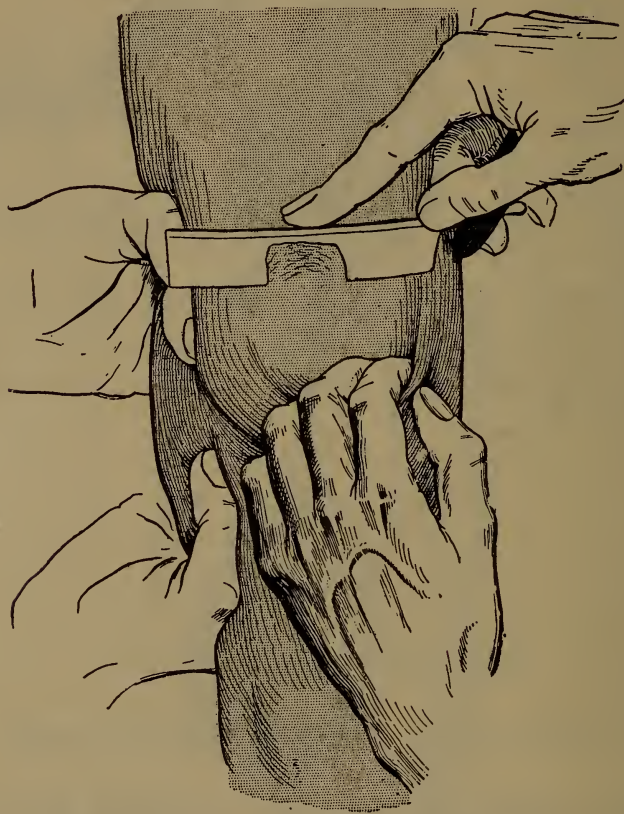

FIG. 680.—Cutting the Thiersch graft. (Veau.)

So proceed until the whole surface is covered. Small angles may be filled in with Reverdin grafts (Fig. 682). The area denuded need only to be covered with a sterile dressing and repair will soon be complete.

(3) The grafted area must be carefully covered with strips of rubber tissue or gutta-percha, placed in various directions so as to hold the grafts in place and at the same time give exit to any exudates. A layer of gauze saturated with salt solution is next applied, which in

turn is covered by absorbent cotton, and the whole held in place by a moderately firm bandage.




FIG. 681.—Method of applying the graft. (Veau.)

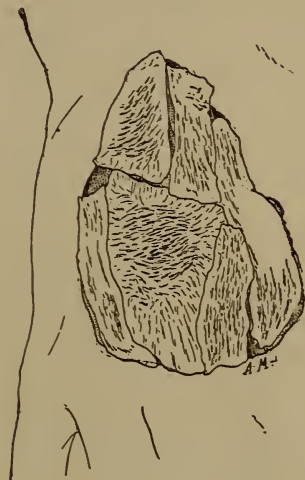

FIG. 682.—Wound covered by grafts. (Veau.)

The part should be immobilized, employing plaster splints if necessary. Change all the dressings except the rubber tissue every day or two and douche gently with normal salt solution. At the end of a week or ten days, change the tissue.

INDEX

- Abdomen, contusions, 125
 gunshot wounds, 151, 171, 219
 incised wounds, 130
 injuries, 125
 laparotomy, 131
 non-penetrating wounds, 127
 penetrating wounds, 129
 punctured wounds, 129
 stab wounds, 129
- Abdominal drainage, 131
 hemorrhage, 533
 section, 531
- Abducens nerve, 396
- Abscess, acute, 375
 alveolar, 384
 anal, 403
 antrum, mastoid, 527
 appendicial, 571
 axillary, 395
 Bartholin's gland, 410
 breast, 393
 cervical glands, 392
 chronic, 378
 definitions, 375
 dental, 384
 drainage, 377
 external auditory meatus, 382
 eyelids, 381
 face, 380
 floor of the mouth, 386
 iliac, 418
 ischio-rectal, 400
 kidney, 552
 labium, 410
 lachrymal, 382
 liver, 414
- Abscess, lung, 502
 mammary, 393
 mastoid, 522
 nasal septum, 381
 palmar, 398
 parotid, 382
 pelvic, 411
 peri-anal, 403
 perineal, 404
 plantar, 400
 popliteal, 398
 prostatic, 404
 psoas, 418
 rectal, 403
 retropharyngeal, 389
 scalp, subaponeurotic, 379
 subperiosteal, 380
 superficial, 379
 seminal ducts, 408
 submammary, 385
 submaxillary, 385
 subphrenic, 414
 symptoms of, 375
 tongue, 388
 tonsillar, 388
 treatment, acute, 376
 chronic, 378
 urinary, 712
 vulvar, 409
 vulvo-vaginal, 410
- Accidents, anesthesia, 16
- Actual cautery, phlegmon, 430
- Acupressure, 61
- Acute intestinal obstruction, 577
 retention of urine, 698
- Adrenalin chloride, anesthesia, 16

- Adrenalin chloride, epistaxis, 68
 gauze tape, 64
 shock, 55
 Air passages, foreign bodies, 459
 burns, 472
 Alcohol, antiseptis, 3
 Allison, strangulated hernia, 609
 Alveolar abscess, 384
 Ammonia after anesthesia, 18
 Amputations, arm, 749
 Chopart, 765
 elbow, 748
 finger, 730
 foot, 767
 forearm, 745
 general technic, 728
 great toe, 761
 hand, 745
 hip-joint, 778
 index finger, atypical, 736
 knee-joint, 775
 leg, 772
 little finger, 735
 toe, 762
 metacarpal, 739
 metatarsal, 764
 middle finger, 733
 toes, 762
 Pirogoff's, 769
 principles, 728
 Syme's, 770
 thigh, 777
 thumb, atypical, 744
 typical, 738
 toes, 760
 scapulo-humeral, 759
 shoulder, 749
 Anal abscess, 403
 dilatation, 783
 fistula, 789
 Anastomosis, intestinal, 650
 Andrews, Colles' fracture, 245
 Anesthesia, 12
 accidents, 16
 ammonia, 18
 Anesthesia, chloroform, 12
 cocaine, 18
 ether, 14
 ethyl chloride, 18
 local, 18
 spinal, 22
 stovaine, 19
 vomiting, 17
 Anesthetics, 3
 Aneurism, gunshot, 138
 Aneurismal varix, 138
 Angina, Ludwig's, 386
 Angiomas, 806
 Angus, torsion, 671
 Ankle amputation, 769
 arthrotomy, 446
 dislocation, 336
 fracture, 276
 sprain, 343
 Anterior crural nerve, exposure, 367
 injury, 366
 Anterior tibial artery, ligation, 725
 nerve, injury, 371
 Antipyrine, epistaxis, 68
 Antisepsis, emergency, 6
 Antiseptics, 3
 Antitetanic serum, 199
 Antistreptococcic serum, phlegmon,
 431
 Antrum, mastoid, 522
 Anus, abscess, 403
 artificial, permanent, 593
 temporary, 589
 dilatation, 783
 fistula, 789
 imperforate, 662
 piles, 784
 Appendectomy, 563
 Appendicial abscess, 571
 Appendicitis, 557
 after-treatment, 574
 catarrhal, 559
 diagnosis, 557
 gangrenous, 561
 operation, 567

- Appendicitis, perforating, 561
 - treatment, 563
 - ulceration, 561
 - varieties, 560
- Appendix in hernia, 615
- Arm, amputation, 749
 - bandages, 45
 - fractures, 209
 - phlegmons, 429
- Army bullet, 135
- Aristol in burns, 471
- Arrest of hemorrhage, 60
- Arterial hemorrhage, 57
- Arteries, ligations, rules, 717
 - suture, 717
 - torsion, 62
 - wounds, gunshot, 138
- Artery forceps, 4
 - ligation, anterior tibial, 725
 - axillary, 722
 - brachial, 722
 - common carotid, 719
 - compression, 66
 - dorsalis pedis, 726
 - external carotid, 720
 - femoral, 724
 - lingual, 720
 - obturator, 368
 - posterior tibial, 726
 - radial, 723
 - subclavian, 720
 - ulnar, 724
- Artificial anus, permanent, 593
 - temporary, 589
- limbs, 772
- respiration, 17
- Arthritis, septic, 440
- Arthrotomy, 441
 - ankle, 446
 - elbow, 447
 - hip, 448
 - knee, 441
 - shoulder, 448
 - wrist, 448
- Arx, heart injuries, 125
- Asphyxia, anesthesia, 16
 - foreign bodies, 456
 - retropharyngeal abscess, 389
- Aspiration, bladder, 707
 - pericardium, 498
 - pleura, 504
- Astragalus, dislocation, 336
 - fracture, 280
- Auditory nerve, injuries, 359
- Automatic centers, paralysis, 13
- Axillary artery, ligation, 722
 - abscess, acute, 395
 - chronic, 395
- Axtell, wound of chest, 119
 - trephining, 520
- Bandage, arm, 45
 - Barton's, 47
 - breast, 44
 - eye, 47
 - finger, 44
 - foot, 38
 - groin, 41
 - hand, 45
 - head, 47
 - knee, 41
 - leg, 41
 - neck, 45
 - shoulder, 45
 - St. Andrew's cross, 44
 - stump, 48
 - thumb, 45
- Bandages, 37
 - method of applying, 38
 - plaster, 49
- Bartholin's gland, abscess, 410
- Barton's bandage, 47
- Base of thorax, wounds, 120
- Bassini, operation for hernia, 632
- Bavarian splints, 51
- Belfield, drainage of seminal ducts, 408
- Bellocq's cannula, 69
- Bennett, Sir W., torsions, 670

- Bennett's fracture, 247
 Biceps tendon dislocation, 347
 Bi-coude catheter, 699
 Bier treatment, 424
 "Black eye," 382
 Bladder, aspiration in retention,
 707
 Bladder, cystotomy, 708
 foreign bodies, 467
 hernia operation, 614
 gunshot wounds, 153
 puncture, 707
 rupture, 553
 suture, 555
 wounds, 554
 Blank cartridges, 198
 Bleeding (see Hemorrhage)
 Bloodgood, intestinal obstruction,
 577
 fractures, 203
 Blood vessels, injuries, 92, 95
 Bolo wounds, 173
 Bone plating, 275
 wiring, 234
 Bonney, emergency operations, 6
 Bowel, acute obstruction, 577
 Bowls, sterilization, 9
 Brachial artery, compression, 66
 ligation, 722
 Brain, abscess, 166
 compression, 306
 concussion, 304
 contusion, 306
 gunshot wounds, 146, 166
 hemorrhage, 510
 injuries, 299
 topography, 510
 Branchial cysts, 806
 Breast abscesses, 393
 bandage, 44
 Brickner, tubal pregnancy, 676
 Bronchi, foreign bodies, 459
 Bronchoscopy, Killian, 461
 Brown, Cesarean section, 684
 Bruises (see Contused wounds)
 Brushes, hand, 2
 Bryant, esophagotomy, 486
 vertical extension, 262
 Bullet wounds, civil, 186
 military, 133
 Bullets, types, 135
 Burmeister, preparation of the
 hands, 10
 Burns and scalds, 468
 Burns, air passages, 472
 Burns, electrical, 473
 Burns, mouth, 472
 Cahill, torsions, 670
 Calmette's antitetanic powder,
 199
 Cannaday, subcuticular suture,
 31
 Capitellum, 46
 Carbuncle, 381
 Carotid artery compression, 66
 ligation, 719
 Carpus, dislocation, 342
 fracture, 246
 Carron oil, 472
 Castration, 798
 emergency, 107
 Catgut, 26
 chromicized, 26
 Catheterization, equipment, 699
 retrograde, 695
 Catheters, acute retention, 699
 box for, 4
 sterilization, 699
 Cecum in hernia, 613
 Cerebro-spinal fluid, characters,
 300
 Cervical glands, suppuration, 392
 Cesarean section, 682
 Championniere, fractures, 205
 Charlton, foreign body in bladder,
 467
 Chest contusions, 114
 wounds, 110
 Cheyne, phlegmon of neck, 431

- Chipman, reduction of shoulder, 321
 Chloral, wounds of tongue, 85
 Chloroform anesthesia, 12
 face in, 13
 pulse in, 13
 pupil in, 13
 container, 13
 Chopart's amputation, 765
 Cigarette drain, 33
 Circular enterorrhaphy, 654
 Circumcision, 792
 Circumflex nerve, exposure, 366
 injury, 366
 Clavicle, fracture, 290
 Cocaine, 4
 anesthesia, 18
 Coley, femoral hernia, 569
 Collapse, 53
 Colles' fracture, 242
 Colon bacillus, 557
 Colostomy, 593
 Colpotomy, 348, 411
 Combs, foreign body in rectum, 464
 Comminuted fractures, 168, 200
 Compound dislocations, 338
 elbow, 340
 hip, 340
 knee, 342
 shoulder, 340
 wrist, 342
 fractures, 283
 ankle and foot, 288
 tibia, 286
 Compression of arteries, brachial, 66
 carotids, 66
 coronary, 66
 facial, 66
 femoral, 67
 intercostals, 68
 occipital, 66
 plantar, 68
 popliteal, 67
 subclavian, 66
 52
 Compression of arteries, temporal, 66
 tibial, 67
 ulnar, 66
 of brain, 304
 Concussion of brain, 304
 Condyles of humerus, fracture, 230
 Congenital hernia, 632
 Coin catchers, 457
 Conjunctiva, foreign bodies, 451
 wounds, 91
 Continuous suture, 27
 Contusions, 72
 abdomen, 125
 brain, 306
 chest wall, 114
 eye, 89
 eyelid, 86
 knee-joint, 342
 lung, 114
 nerves, 358
 scalp, 81
 urethra, 689
 Cook, appendicitis, 564
 Cooper, reduction of elbow, 328
 Coracoid process, examination, 215
 Corner, torsions, 674
 Coronary artery, compression, 66
 Cotton, injuries to testicle, 108
 Cradle splint, 164
 Cranial nerves, injuries, 359
 Craniectomy, emergency, 510
 Crepitus, 201
 Crile, direct transfusion, 55
 shock, 55
 Crucial ligaments, rupture, 345
 Crushing injuries to the extremities, 97
 Cullen, torsions, 674
 Cushing, shock, 56
 Cut throat, 86
 wrist, 91
 Cystotomy operation, 695, 708
 Dayat, foreign bodies, 466
 Deep epigastric artery, 68

- Dental abscess, 384
- Depressed fracture, skull, 302
- Diaphragm, wounds, 122
- Digital arteries, compression, 67
- Dilatation of the anus, 783
 - urethral stricture, 701
- Direct pressure in hemorrhage, 60
- Dislocations, 312
 - ankle, 336
 - compound, 338
 - elbow, 327
 - finger, 330
 - hip, 330
 - jaw, 326
 - knee, 334
 - patella, 336
 - shoulder, 312
 - after-treatment, 325
 - subclavicular, 316
 - subcoracoid, 312
 - subglenoid, 322
 - subspinous, 324
 - semilunar cartilages, 335
 - thumb, 329
 - wrist, 340
- Dixon, tubal pregnancy, 676
- Dorsalis pedis artery ligation, 726
- Dorsum ilii, dislocation, 330
- Double spica, 37
- Downey, fracture of femur, 260
- Doyen's trephine, 514
- Drainage, 32
 - abdominal, 131
 - abscess, 377
 - accidental wounds, 32
 - amputations, 728
 - appendicitis, 571
 - arthrotomy, 442
 - aseptic wounds, 32
 - cigarette, 33
 - compound fractures, 34
 - empyema, 508
 - gauze wick, 33
- Drainage, heart wounds, 495
 - operative wounds, 34
 - tubes, 33
 - urinary infiltration, 716
- Dressings, 35
 - first aid, 153
 - frequency, 36
- Dupuytren's splint, 279
- Dura mater, wounds, 517
- Dutch cane splints, 48
- Dyspnea, heart wounds, 123
- Ear drum, paracentesis, 523
 - forceps, 453
 - foreign bodies, 452
- Eastman, J. R., hernia, 640
 - intestinal obstruction, 578
- Eastman, T. B., appendicitis, 558
- Ectopic gestation, 675
- Edema of glottis, 483
- Elbow, amputation, 748
 - arthrotomy, 447
 - dislocation, 327
 - fracture, 230
 - gunshot wounds, 159
 - wound, 95
- Electrical burns, 473
 - shock, 473
- Elliott, wounds of kidney, 553
- Emergency antisepsis, 6
 - operations, preparation, 7
 - surgery, equipment, 2
 - military, 185
- Emphysema, chest injuries, 113
- Empyema of thorax, 502
 - adult, 506
 - after-treatment, 509
 - child, 505
 - diagnosis, 502
 - puncture for, 504
- Enemas, technic, 580
- Enterectomy, 650
- Enterorrhaphy, 653
- Enterostomy, 589
- Epistaxis, 68

- Equipment, emergencies, 2
- Esophagotomy, 484
- Esophagus, foreign bodies, 455
 - wounds, 89
- Estes, intussusception, 583
- Ether anesthesia, 14
 - adrenalin chloride in, 15
- External auditory meatus abscess, 382
 - carotid artery ligation, 720
 - urethrotomy, 691
- Extravasation of urine, 712
- Extremities, crushing injuries, 97
 - fractures, 200
 - wounds, 92
- Eye bandage, 47
 - foreign bodies, 451
 - injuries, 89
- Eyelid, abscess, 381
 - contusion, 86
 - wounds, 86
- Face, abscesses, 380
 - fractures, 299
 - furuncle, 380
 - gunshot wounds, 169, 190
 - wounds, 84
- Facial artery, compression, 66
 - ligation, 720
 - nerve injuries, 359
 - mastoid operation, 528
- Felon, 423
- Femoral artery, compression, 67
 - ligation, 724
 - stab wound, 95
- hernia, anatomy, 617
- radical cure, 643
- strangulated, 617
 - operation, 619
- taxis, 603
- Femur, amputations, 777
 - fractures, 252
 - after-treatment, 260
 - children, 262
 - epiphyseal, 262
 - Femur fractures, shaft, 257
 - supracondylar, 260
 - osteomyelitis, 438
- Fibula, fractures, 276
- Field of operation, sterilization, 10
- Figure-of-eight bandage, 38
- Fingers, amputations, 731
 - bandages, 44
 - dislocations, 330
 - fractures, 247
 - infections, 422
- First aid, dressing, 153
 - fractures, 208, 251
 - hemorrhage, 65
 - splints, 180
- Fiske, wounds of spleen, 551
- Fistula, anal, 789
 - urinary, 712
- Fitzmaurice-Kelley, amputation for shell wounds, 156
- Floor of mouth, abscess, 386
- Florschütz suspension, 165
- Foot, amputations, 767
 - bandages, 38
 - fractures, 280
- Forceps, artery, 5
 - aural, 453
 - nasal, 455
 - urethral, 465
- Forcipressure, 61
- Ford, ether anesthesia, 16
 - fracture of patella, 265
 - skull, 419
- Forearm, amputation, 745
 - phlegmon, 427
- Foreign bodies, air passages, 459
 - bladder, 467
 - ear, 452
 - esophagus, 455
 - eye, 451
 - larynx, 459
 - nose, 454
 - pharynx, 455
 - rectum, 462

- Foreign bodies, trachea, 459
 - urethra, 465
- Fountain syringe, 3
- Fowling piece, gunshot wound, 198
- Foxworthy, bolo wounds, 173
- Fractures, 200
 - ankle, 276
 - anterior tuberosity of tibia, 276
 - arm, 209
 - astragalus, 280
 - carpus, 246
 - clavicle, 290
 - Colles', 242
 - compound, 283
 - condylar, 230
 - crepitus, 202
 - definitions, 200
 - diagnosis, 201
 - elbow, 230
 - extremities, 200
 - face, 299
 - gunshot, 169, 190
 - femur, 252
 - gunshot, 169, 190
 - fibula, 276
 - fingers, 247
 - first aid, 208
 - foot, 280
 - forearm, 237
 - gunshot, 155, 159
 - hand, 246
 - head, 301
 - humerus, 209
 - immobilization, 205
 - intercondylar, 232
 - jaw, lower, 309
 - upper, 308
 - leg, 270
 - lower extremities, 251
 - malar, 308
 - maxillæ, 180, 308
 - metacarpus, 246
 - nasal bone, 309
 - olecranon process, 233
 - os calcis, 281
- Fractures, pain, 202
 - patella, 264
 - pelvis, 297
 - Pott's, 276
 - prognosis, 201
 - radius, 237
 - head, 236
 - lower end, 241
 - reduction, 204
 - ribs, 295
 - scapula, 294
 - skull, 299
 - compound, 303
 - spine, 296
 - splints, 207
 - supracondylar, 225
 - tarsus, 280
 - thumb, 247
 - tibia, 269
 - toes, 282
 - treatment, 204
 - ulna, 237
 - vertebra, 296
 - wrist, 246
- Freezing, 474
- Frost bite, 475
- Furuncle of face, 380
- Fysche, gunshot wound, 193
- Gage, rupture quadriceps extensor, 350
- Gangrene, amputation, 728
- Garrison, emergency operations, 6
- Gastric lavage, 14, 16, 580
- Gastro-enterostomy, 478
- Gauze, 4
 - drainage, 33
 - dressings, 35
- General practitioner as emergency surgeon, 1
- Genito-crural nerve injury, 369
- Gerster, treatment of peritonitis, 576
- Gibbon, suture of heart, 495
- Gloves, rubber, 10

- Gooch's splint, 48
Gosset, wounds of nerves, 139
Granger, burns, 472
Great toe, amputation, 761
Groin, bandage, 41
Groves, gunshot fractures, 157
Guibal, subphrenic abscess, 414
Gunshot fractures, 155, 159
 wound of abdomen, 151, 171, 192
 bladder, 153
 blood vessels, 138
 bone, 144
 brain, 146, 166
 cranium, 145, 166
 face, 169, 190
 fascia, 138
 hand, 197
 head, 187
 heart, 151
 intestine, 152
 joints, 145, 166, 195
 kidney, 153
 knee, 166, 195
 liver, 153
 lungs, 150
 muscles, 138
 neck, 169
 nerves, 139
 pancreas, 153
 rectum, 153
 skin, 137
 skull, 144, 167
 spine, 148, 170, 189
 spleen, 153
 stomach, 152
 thorax, 149, 171, 196
 trachea, 170
wounds, civil, 186
 effects on tissues, 137
 hemorrhage, 137
 military, 137
 prognosis, 153
 shock, 137
 suicidal, 188
 treatment, 153
Gun-splint, 184
Guyon, catheterization, 705
Hand, abscess, 424
 amputations, 745
 bandages, 45
 brushes, 2
 fractures, 246
 gunshot wound, 197
 infections, 424
 injuries, 100
 sterilization, 9
Harrington's solution, 10
Harsha, torsions, 670
Hartmann, splenectomy, 673
Havard, gunshot wounds, 152, 172
Haynes, wounds of liver, 548
Head wounds, 81
 bandages, 47
Heart, gunshot wounds, 151
 massage, 17
 repair, 490
 suture, 495
 wounds, 122
Heile, treatment of ileus, 587
Hemarthrosis, 166, 197
Hematoma, 72
Hematuria, 552
Hemopericardium, 114
Hemopneumothorax, 112
Hemoptysis, 111
Hemorrhage, 57
 acupressure, 61
 adrenalin chloride, 58
 arrest, 60
 arterial, 57
 capillary, 57
 chemicals in, 60
 constitutional effects, 57
 definitions, 57
 diagnosis, 58
 ectopic gestation, rupture, 675
 fatal, 58
 first aid, 65
 forcipressure, 62

- Hemorrhage, heat, 60
 - hypodermoclysis, 59
 - infusion, intravenous, 59
 - intermediary, 57
 - internal, 57
 - kidney, 541
 - laparotomy, 532
 - liver, 541
 - meningeal, 301
 - mesentery, 541
 - normal salt solution, 59
 - operative, 60
 - parenchymatous, 57
 - primary, 57
 - seccndary, 57
 - spleen, 541
 - spontaneous arrest, 60
 - symptoms, 57
 - torsion, 62
 - tourniquets, 61
 - treatment, 58
 - tubal pregnancy, 675
 - venous, 57
- Hemorrhoids, operations, 784
- Hemostasis, 60
- Hemothorax, 111
- Hennequin's dressing, 211
- Hernia, appendix, 615
 - bladder, 614
 - cecum, 613
 - encysted, 613
 - femoral, 643
 - gangrenous, 609
 - inguinal, 632
 - interstitial, 614
 - lumbar, 631
 - lung, 113
 - obturator, 628
 - ovaries, 631
 - perineal, 631
 - properitoneal, 614
 - radical cure, femoral, 643
 - inguinal, 632
 - umbilical, 626
 - vaginal, 631
- Hernia, sciatic, 631
 - septic absorption, 598
 - sigmoid, 613
 - stomach, 617
 - strangulated, 598
 - umbilical, 622
- Hernial sac, anomalies, 613
- Hernio-laparotomy, 613
- Hertzfeld, epistaxis, 69
- Heyvrosky, bullet wound of blood
 - vessels, 138
- Hilton, abscess, 396
- Hip-joint, arthrotomy, 448
 - amputations, 778
 - dislocations, 330
 - gunshot wounds, 166
- Hodgen's splint, 262
- Holliday, splenectomy, 550
- Humerus, fractures, 209
 - anatomical neck, 220
 - external condyle, 229
 - greater tuberosity, 221
 - gunshot, 157
 - internal condyle, 230
 - lower end, 222
 - osteomyelitis, 437
 - shaft, 209
 - supracondylar, 225
 - surgical neck, 216
 - upper end, 213
 - in children, 221
- Hunt, tubal pregnancy, 681
- Hyde, foreign body in urethra, 467
- Hydrocele, 796
 - radical operation, 797
 - tapping, 796
- Hypodermoclysis, 59
- Hysterectomy, 681
- Ice, appendicitis, 563
- Ileus, post-operative, 586
- Iliac abscess, 418
- Ilio-inguinal nerve injury, 369
- Imperforate anus, 662
- Incised wounds, 73

- Incised wounds of elbow, 95
 - of neck, 88
 - of wrist, 92
- Index finger, amputation, 735
- Infected wounds, 79
- Infections, acute, 421
- Inferior maxilla fracture, 309
- Infiltration of urine, 712
- Ingrowing toe-nail, 801
- Inguinal hernia, anatomy, 632
 - radical cure, 632
 - strangulated, 598, 603
- Injuries, abdomen, 125
 - hand, 107
 - joints, 312
 - nerves, 357
 - thorax, 110
- Instruments, emergency, 5
 - cleansing, 5
 - preparation, 7
- Intercondylar fractures, 232
- Intercostal artery, hemorrhage, 68
- Internal mammary artery, 68
- Interrupted sutures, 29
- Interstitial hernia, 614
 - tubal pregnancy, 679
- Intestinal anastomosis, 650
 - end to end, 654
 - lateral, 657
 - Murphy button, 656
 - termino-lateral, 660
- obstruction, acute, 577
 - gastric lavage, 580
 - laparotomy, 581
 - rectal enema, 580
 - symptoms, 578
 - treatment, 579
- resection, 651
- rupture, 127
- Intestines, suture, 543
 - wounds, 541
- Intracranial hemorrhage, 510
- Intravenous infusion, hemorrhage,
 - 59
 - shock, 55
- Intravenous infusion, technic, 59
- Intussusception, 582
 - operation for, 585
- Iodine, sterilization of the skin, 10
- Irrigator, 3
- Ischiatic dislocation, 331
- Ischio-rectal abscess, 400
- Jaw, dislocation, 326
 - fracture, 308
 - gunshot, 169
- Joints, contusions, 342
 - dislocations, 312
 - compound, 338
 - gunshot wounds, 145, 166
 - hemorrhage into, 146, 167
 - incised wounds, 343
 - injuries, 312
 - punctured wounds, 342
 - sprains, 282, 343
 - stab wounds, 342
 - suppurations, 440
- Jonnesco, spinal anesthesia, 23
- Keen, Cesarean section, 684
- Kelley, torsions, 667
- Kidney, abscess, 552
 - hemorrhage, 541
 - injuries, 552
 - removal, 552
 - rupture, 552
 - wounds, 552
- Killian, bronchoscopy, 461
- King, fracture of extremities, 201
- Knott, suture of liver, 548
- Kocher, shoulder dislocation, 313
- Kollman, filiform guide, 703
- König, preparation of the skin, 10
- Knee, amputation, 775
 - arthrotomy, 444
 - bandage, 41
 - contusions, 342
 - crucial ligaments, 345
 - dislocations, 334
 - gunshot wounds, 146, 167

- Knee, puncture, 445
 - sprains, 343
 - stab wounds, 342
 - wounds, 342
- Kütner, wounds of lung, 192
- Kyle, foreign body in nose, 455
- Labium, abscess, 409
- Lacerated wounds, 77
- Laceration of brain, 299
- Lachrymal abscess, 382
- Lanphear, Cesarean section, 683
- Laparotomy for Cesarean section, 682
 - general technic, 530
 - gunshot wounds, civil, 186
 - military, 133
 - intestinal obstruction, 579
 - for traumatism, 537
- Laplace, peritonitis, 576
- Laryngotomy, 484
- Larynx, foreign bodies, 459
 - wounds, 88
- Lateral anastomosis, intestine, 657
 - sinus thrombosis, 523
- Lavage, gastric, 151, 580
- Leg, amputations, 772
 - bandage, 41
 - fractures, 269
 - osteomyelitis, 435
- Lejars, appendicitis, 563
 - preparations for operation, 7
 - reduction of shoulder, 313
 - thumb, 329
 - rupture of the lung, 115
 - splint for leg, 272
- Lembert suture, 544
- Lichtenstern, torsion, 673
- Ligation, 62
- Ligation en masse, 63
- Ligations, anterior tibial, 725
 - arterial, principles, 717
 - axillary, 722
 - brachial, 722
 - common carotid, 719
 - dorsalis pedis, 726
 - external carotid, 720
 - facial, 720
 - femoral, 724
 - lingual, 720
 - occipital, 720
 - posterior tibial, 726
 - radial, 723
 - subclavian, 720
 - superior thyroid, 720
 - ulnar, 724
- Ligations, dorsalis pedis, 726
- Ligations, external carotid, 720
- Ligations, facial, 720
- Ligations, femoral, 724
- Ligations, lingual, 720
- Ligations, occipital, 720
- Ligations, posterior tibial, 726
- Ligations, radial, 723
- Ligations, subclavian, 720
- Ligations, superior thyroid, 720
- Ligations, ulnar, 724
- Lingual artery, ligation, 720
- Link, tracheotomy, 482
- Lipomas, removal, 801
- Lips, wounds, 85
- Little-finger amputation, 735
- Little toe amputations, 762
- Liver, hemorrhage, 541
 - injuries, 546
 - suture, 547
- Local anesthesia, 18
- Lower extremity, fractures, 251
- Lower jaw, dislocation, 326
- Lowery, compound fracture, 285
- Luckett, Fourth-of-July injuries, 199
- Ludlow, wounds, diaphragm, 121
- Ludwig's angina, 386
- Lung, abscess, 502
 - gunshot wounds, 150
 - hernia, 113, 118
 - rupture, 116
 - stab wounds, 116
 - suture, 490
- Malaleuca sempervirens, 701
- Malar bone fracture, 308
- Mammary gland abscess, 393
- Marsee, fracture of fingers, 24
 - injuries to hand, 102
 - suture of tendons, 355
- Martin, Cesarean section, 684
- Mastoiditis, 522
- Mastoid operation, 523
- Materials for sutures, 25
- Maxilla, fractures, 308

- Mayo, umbilical hernia, 630
 Mayor's sling, 293
 Meatus, foreign bodies, 452
 Median nerve exposure, 362
 injury, 361
 Meningeal hemorrhage, 307
 Mesentery, hemorrhage, 540
 repair, 541
 Metacarpals, amputations, 743
 fracture 246
 Metal splints, 50
 McEwen, strangulated hernia, 617
 McFarland, antitetanic powder, 199
 McGrath, appendicitis, 564
 Middle-finger amputation, 733
 Middle meningeal artery, hemorrhage, 307
 Miller, kidney, injury, 553
 Miller, pelvic abscess, 414
 Mitchell, peritonitis, 574
 Morley, bandage for eye, 47
 Morris, appendicitis, 558
 Morrison, wounds of eye, 89
 Mosetig-Moorhof bone wax, 434
 Mothe, dislocation of shoulder, 317
 Motor-oculi nerve injury, 360
 Mouth burns, 472
 Moynihan, intestinal anastomosis, 650
 purulent peritonitis, 573
 Murphy, anesthesia, 24
 Murphy button, 656
 purulent peritonitis, 574
 suture of arteries, 717
 olecranon, 235
 Musculo-cutaneous nerve, 371
 Musculo-spiral nerve exposure, 371
 injury, 370
 Nares, plugging, 68
 Nasal bone, fracture, 309
 septum, abscess, 381
 Nassau, esophagotomy, 487
 Nausea, anesthesia, 17
 Neck, bandage, 45
 Neck wounds, 86
 gunshot, 169
 Neff, rupture of urethra, 688
 Nélaton's line, 251
 Nephrectomy, 553
 Nerve, compression, 358
 contusion, 358
 grafting, 359
 suturing, 357
 wounds, 358
 gunshot, 139
 Nerves, individual, 359
 abducens, 359
 anterior crural, 367
 auditory, 359
 circumflex, 366
 facial, 359
 fifth, 360
 genito-crural, 369
 ilio-inguinal, 369
 laryngeal, 360
 median, 361
 motor-oculi, 360
 musculo-cutaneous, 371
 musculo-spiral, 365
 obturator, 368
 optic, 360
 peroneal, 370
 phrenic, 360
 pneumogastric, 360
 popliteal, 370
 radial, 365
 recurrent laryngeal, 360
 sciatic, 369
 tibial anterior, 371
 posterior, 372
 trifacial, 361
 ulnar, 362
 Noetzel, wounds of spleen, 550
 Nose, foreign bodies, 454
 hemorrhage, 68
 Obstruction of bowel, 577
 Obturator artery ligation, 368
 dislocation, 333

- Obturator hernia, strangulated, 628
 - nerve, 368
- Occipital artery ligation, 720
- Œdema of the glottis, 483
- Œsophagotomy, 484
- Œsophagus, foreign bodies, 455
 - injuries, 87
- Ointment of Reclus, 471
- Olecranon, fracture, 233
- Oliver, strangulated hernia, 617
 - jaw fracture, 310
- Omentum, hemorrhage, 539
 - resection, 645
 - torsion, 674
- Open wounds of thorax, 115
- Operation in private houses, 6
- Operative hemorrhage, 64
 - wounds, 75
- Opium, appendicitis, 563
- Optic nerve injury, 360
- Os calcis, Pirogoff's amputation, 769
 - fracture, 281
- Oschner, appendicitis, 564
 - femoral hernia, 645
 - torsion, 670
- Osteomyelitis, acute, 432
 - femur, 438
 - humerus, 437
 - tibia, 435
- Ovarian cysts, torsion of pedicle, 667
- Pagenstecher, linen, 25
- Palmar abscess, 398
 - arches, 66
- Panaris, 422
- Pancreas, gunshot wounds, 153
 - injuries, 549
 - suture, 549
- Pannett, shell wounds, 174
- Pantzer, appendicitis, 559
- Paracentesis, ear-drum, 523
 - pericardium, 498
 - pleura, 504
- Paraphimosis, 790
- Parotid gland abscess, 382
- Patella, dislocation, 336
 - fracture, 264
 - wiring, 266
- Peck, wounds of heart, 497
- Pedicles, ligation, 667
- Pelvic abscess, 411
- Pelvis, fractures, 297
- Penis, injuries, 106
- Perborate of soda, epistaxis, 70
- Peri-anal abscess, 403
- Pericardiotomy, 500
- Pericardium, paracentesis, 498
 - puncture, 498
 - suture, 490
 - wounds, 122
- Perineal abscess, 404
 - bruises, 714
 - section, 715
- Peritonitis, purulent, 576
 - treatment, 577
 - typhoid, 576
 - septic, 576
- Peroneal nerve, 370
 - tendons, dislocation, 347
- Pfaff, appendicitis, 562
 - tubal pregnancy, 679
- Phalanges, fractures, 247
- Pharynx, foreign bodies, 455
- Phimosis, wounds, 89
- Phlegmon, 421
 - arm, 429
 - fingers, 424
 - forearm, 427
 - neck, 429
 - perineum, 714
 - tendon sheaths, 424
- Phrenic nerve, 360
- Picric acid, burns, 471
- Piles operation, 784
- Pinna, wounds, 84
- Pirogoff's amputation, 769
- Plantar abscess, 400
- Plaster-of-Paris bandages, 49
 - Bavarian, 51
 - preservation, 4

- Plaster-of-Paris splints, 50
- Pleura, empyema, 509
 - incision, 509
 - puncture, 504
 - wounds, 116
- Pneumogastric nerve, 360
- Pneumothorax, 112
- Poisoned wounds, 71
- Popliteal abscess, 398
 - artery compression, 67
- Porter, treatment of wounds, 78
- Posterior nares, plugging, 69
 - tibial artery, 726
 - nerve, 372
- Post-operative ileus, 586
- Potain's aspirator, 504
- Pott's fracture, 276
- Precordial wounds, 122
- Pregnancy, extra-uterine, 674
- Préparation, emergency operations, 8
 - hands, 9
 - skin, 8
- Primary hemorrhage, 57
- Probang, foreign bodies, 458
- Properitoneal hernia, 614
- Prostatic abscess, 404
- Psoas abscess, 418
- Pulse, abdominal injury, 126
 - appendicitis, 559
 - chloroform anesthesia, 13
 - ether anesthesia, 15
 - hemorrhage, 58
 - shock, 53
- Puncture, bladder, 707
 - knee-joint, 445
 - pericardium, 498
 - pleura, 504
 - scrotum, 796
- Punctured wounds, 76
- Purulent pericarditis, 500
 - pleurisy, 502
- Quadriceps extensor tendon, rupture, 348
- Quenu, preparation of room, 8
- Quinsy, 388
- Radial artery, compression, 67
 - ligation, 723
 - synovial sheath drainage, 424
- Radius, fractures, 237
 - gunshot, 160
 - head, 236
 - lower end, 241
 - neck, 236
 - shaft, 238
- Ranzi, torsions, 668
- Reclus, lacerated wounds, 100
 - ointment, 471
- Rectal injections, 581
- Rectum, abscess, 403
 - dilatation, 783
 - foreign bodies, 462
 - hemorrhoids, 784
 - wounds, 108
- Recurrent laryngeal nerve, 360
- Reduction "en masse," 602
 - dislocations, 313
 - fractures, 204
 - hernia, 601
- Removal of small tumors, 804
- Resection of bowel, 651
- Respiratory paralysis, 14, 15
- Responsibility of general practitioner, 2
- Retention of urine, 698
- Retropharyngeal abscess, 389
- Reverdin, skin grafting, 807
- Reynolds, Cesarean section, 684
- Ribs, fracture, 295
 - resection, 504
- Rinchea, torsions, 674
- Ring-finger amputation, 733
- Robinson, shock, 56
- Romer, fracture, clavicle, 292
- Rongeur forceps, 511
- Rossi, fractures, 205
- Rosving, appendicitis, 558
- Royster, fracture of humerus, 220

- Rubber gloves, 10
- Rugine, 506
- Rupture, tubal pregnancy, 675
 - urethra, 686
- Saber splint, 184
- Sacro-iliac synchondrosis, 298
- Saline solution in hemorrhage, 55
 - sepsis, 574
- Sayres' dressing, 291
- Scalds, 468
- Scalp, abscesses, 379
 - arteries, 66
 - contusion, 81
 - hematoma, 303
 - wounds, 81
- Scapula, amputations, 759
 - fracture, 294
- Schaute, Cesarean section, 685
- Schleich's formulæ, 20
- Sciatic nerve injury, 369
- Sclerotic wounds, 90
- Scrotum, injuries, 106
- Scudder, fracture of leg, 272
- Sebaceous cysts, removal, 804
- Secondary hemorrhage, 57
- Semilunar cartilages, dislocation, 335
- Seminal ducts, abscess, 408
- Senn, first aid on battlefield, 179
 - fracture of femur, 254
 - hip-joint amputation, 779
 - intussusception, 584
- Septic arthritis, 440
- Septum nasi abscess, 381
- Shaving skin, 8
- Shell wounds, 172
- Shock, 52
 - diagnosis, 53
 - treatment, 54
- Shoulder amputation, 749
 - arthrotomy, 448
 - bandage, 45
 - dislocations, 312
 - fractures, 213
- Shrapnel wounds, 172
- Silk sutures, 25
- Silkworm sutures, 26
- Simons, crushing wounds, 99
- Skin grafting, 807
 - preparation, 10
- Skull, bullet wounds, 144, 167
 - fracture, base, 299
 - compound, 303
 - vault, 301
 - trephining, 510
- Spence, shoulder amputation, 754
- Spermatic cord, ligation, 800
 - torsion, 671
 - vasectomy, 408
- Spica for breast, 44
 - foot, 39
 - groin, 41
 - shoulder, 45
- Spinal anesthesia, 22
 - cord injuries, 297
- Spine, fractures, 296
 - gunshot wounds, 148, 170
 - wounds, 104
- Spleen, hemorrhage, 549
 - injuries, 549
 - removal, 550
 - rupture, 550
 - torsion, 615
- Splenectomy, 550
- Splint, Bavarian, 51
 - Dupuytren's, 277
 - first aid, 180
 - Hodgen's, 262
- Splints, 48
 - cradle, 164
 - Dutch cane, 48
 - Gooch's, 48
 - metal, 49
 - plaster-of-Paris, 50
 - silicate of potash, 48
 - trough, 164
 - wire gauze, 49
 - wooden, 48
- Sprains, 343
- St. Andrew's cross, 44

- Stab wounds, 76
 abdomen, 129
 heart, 425
 knee, 342
 thigh, 95
 thorax, 110
- Sterilization, dressing, 7
 hands, 9
 instruments, 8
 skin, 10
- Stimson, pain in fracture, 202
- Stomach, hemorrhage, 152
 hernia, 617
 suture, 546
 wounds, 546
- Stewart, suture of heart, 496
- Stovaine, spinal anesthesia, 22
- Strangulated hernia, 598
 complications, 612
 diagnosis, 599
 femoral, 617
 inguinal, 603
 obturator, 628
 operation, 603
 taxis, 600
 umbilical, 622
- Stricture of urethra, 694
- Stump bandage, 48
- Subclavian artery; compression, 66
 ligation, 720
- Subclavicular dislocation, 316
- Subcoracoid dislocation, 312
- Subcutaneous wounds, 72
- Subcuticular suture, 30
- Subglenoid dislocation, 322
- Submammary abscess, 395
- Submaxillary abscess, 385
- Subphrenic abscess, 414
- Subpubic dislocation, 332
- Subspinous dislocation, 324
- Suicide, attempts, 186
- Superior maxilla fracture, 308
 thyroid artery ligation, 720
- Suprapubic cystotomy, 695
 puncture, 707
- Surgical dressings, 35
- Suture of arteries, 717
 bladder, 555
 heart, 495
 intestine, 543
 liver, 547
 lung, 490
 nerves, 357
 pancreas, 549
 tendons, 353
 ureter, 556
 wounds, 25
- Sutures, catgut, 26
 continuous, 27
 horsehair, 25
 interrupted, 29
 Lembert, 544
 linen, 25
 methods and materials, 25
 Pagenstecher linen, 26
 quilted, 25
 sero-serous, 543
 silk, 25
 silkworm-gut, 26
 subcuticular, 30
- Syme's amputation, 770
- Syncope, 58
- Synovial sheath suppurations, 424
 cysts, 806
- Tampon for intercostal hemorrhage, 68
- Tapping, hydrocele, 796
- Tarso-metatarsal, amputation, 767
- Tarsus, dislocations, 336
 fracture, 280
- Taxis, indications, 600
 technic femoral hernia, 603
 inguinal hernia, 601
 umbilical, 533, 603
- Taylor, empyema, 502
 fracture of humerus, 221
- Temporal artery compression, 66
- Temporo-maxillary joint dislocation, 326

- Tendon, dislocations, 347
 - divided, 351
 - rupture, 347
 - suture, 353
 - wounds, 347
- Testis, removal, 798
 - suture, 107
 - wounds, 107
- Tetanus, bolo wounds, 174
 - Fourth-of-July injuries, 199
 - prophylaxis, 199
 - punctured wounds, 76
- Thiersch, skin grafting, 808
- Thigh, amputations, 777
 - wounds, 95
- Thoracotomy, indications, 488
 - technic, 488
- Thorax, injuries, 110
 - open wounds, 116
- Throat, cut, 86
- Thrombosis, lateral sinus, 523
- Thumb, amputations, 738
 - bandage, 45
 - dislocations, 329
 - fracture, 247
- Tibia, fractures, 270
 - osteomyelitis, 435
 - trephining, 436
- Tibial arteries, ligation, 725
 - compression, 67
- Tillaux's dressing, 258
- Toe-nail, ingrowing, 801
- Toes, amputation, 760
- Tongue, abscess, 388
 - suture, 85
 - wounds, 85
- Tongue-traction, asphyxia, 16
- Tonsil, abscess, 388
- Torsion, arteries, 62
 - diagnosis, 667
 - omentum, 674
 - pedicle ovarian cysts, 667
 - spleen, 673
 - spermatic cord, 671
 - uterus, 669
- Townsend, catheterization, 699
- Toy-pistol wound, 198
- Trachea, foreign bodies, 459
 - gunshot wounds, 169
 - incised wounds, 88
- Tracheotomy, after-treatment, 479
 - foreign bodies, 481
 - indications, 477
 - operations, 477
 - tubes, 477
- Transfixion apparatus, 162
- Travers, suture of the heart, 496
- Trephine, Doyen, 514
 - Galt, 514
- Trephining, femur, 438
 - fracture of skull, 510
 - gunshot wounds, 520
 - humerus, 437
 - tibia, 435
- Treves, strangulated hernia, 608
- Trunk injuries, 110
- Tubal pregnancy, diagnosis, 675
 - operation, 677
 - rupture, 675
- Tubercular abscess, 378
- Tuffier, chest wounds, 150
- Tumors, superficial, 804
- Tunica vaginalis, resection, 797
- Turpentine burns, 471
- Tuttle, imperforate anus, 666
- Typhoid perforation, 577
- Ulna, fractures, 237
- Ulnar artery, ligation, 724
 - nerve exposure, 362
 - injury, 362
 - synovial sheath, 424
- Umbilical hernia, strangulated, 622
 - radical cure, 550, 627
- Ureter, repair, 556
 - wounds, 556
- Urethra, anatomy, 688
 - catheterization, 695
 - contusions, 689

- Urethra, foreign bodies, 465
 - rupture bulbous portion, 690
 - diagnosis, 687
 - membranous portion, 696
 - pendulous portion, 697
 - symptoms, 688
 - treatment, 690
- Urethral forceps, 465
- Urethrotomy, 691
- Urgent craniectomy, 510
 - thoracotomy, 488
- Urinary abscess, 712
- Urine, extravasation, 712
 - retention, 698
- Uterus, torsions, 669
- Vagina, abscess, 410
 - injuries, 105
- Vagus nerve, 360
- Valentine, emergency catheteriza-
tion, 699
- Van der Walker, emergency
surgery, 6
- Van Hook's anastomosis, 556
- Vasectomy, 408
- Vaughn, wounds of heart, 124
- Vault of skull fracture, 301
 - compound, 303
- Veins of liver, ligation, 547
- Velpeau's bandage, 290
- Venous hemorrhage, 57
- Vincent, trephining, 518
- Vineberg, tubal pregnancy, 676
- Vertebræ, fractures, 296
- Viscera, abdominal, rupture, 126
- Volvulus, 579
- Von Bergman, gunshot wounds,
144
- Vulva, wounds, 105
- Vulvar abscess, 409
- Vulvo-vaginal abscess, 410
 - injuries, 105
- Walker, fractures of femur, 255
- Warbasse, treatment of fracture,
205
- Wathen, wounds of liver, 547
- Westmoreland, tracheotomy, 478
- Whitehorne-Cole, gunshot wounds of
brain, 147
- Whitman, fracture of femur, 255
- Wick drains, 33
- Wire gauze splints, 49
- Wiring fractured fingers, 249
 - olecranon, 233
 - patella, 266
- Wooden splints, 48
 - trough splint, 165
- Wounds, abdomen, 128
 - aseptic, 74
 - base of thorax, 119
 - bend of elbow, 95
 - bladder, 554
 - blank cartridge, 199
 - bolo, 173
 - chest, 110
 - cleansing, 79
 - contused, 72
 - definitions, 71
 - diaphragm, 122
 - drainage, 93
 - dressings, 78
 - elbow, 94
 - esophagus, 89
 - extremities, 92
 - eye, 89
 - eyelids, 85
 - face, 84
 - femoral artery, 95
 - fingers, 101
 - general principles, 71
 - gunshot, civil, 186
 - military, 133
 - hand, 102
 - head, 81
 - heart, 122
 - hemorrhage, 73
 - incised, 73
- Wagner, heart injuries, 124
- Waite, shock, 52

Wounds, infected, 79

intestine, 543

kidney, 552

lacerated, 76

larynx, 88

lips, 84

liver, 546

lung, 116

neck, 86

open, 71

operative, 75

pancreas, 549

penis, 106

pericardium, 122

pharynx, 89

pinna, 84

pleura, 116

precordial, 122

punctured, 76

rectum, 108

scalp, 81

scrotum, 106

shell, 172

special regions, 81

spine, 104

spleen, 549

Wounds, stab, 76

stomach, 546

subcutaneous, 72

suture, 26

symptoms, 72

testicle, 107

thigh, 95

thorax, 110

tongue, 85

toy pistols, 199

trachea, 88

treatment, 70

trunk, 110

ureter, 556

vagina, 105

vulva, 105

wrist, 92

Wrist, arthrotomy, 448

dislocation, 340

fractures, 246

wounds, 92

X-ray, foreign bodies, 457

fractures, 203

Zone of anesthesia, 19





LIBRARY OF CONGRESS



0 027 325 127 3